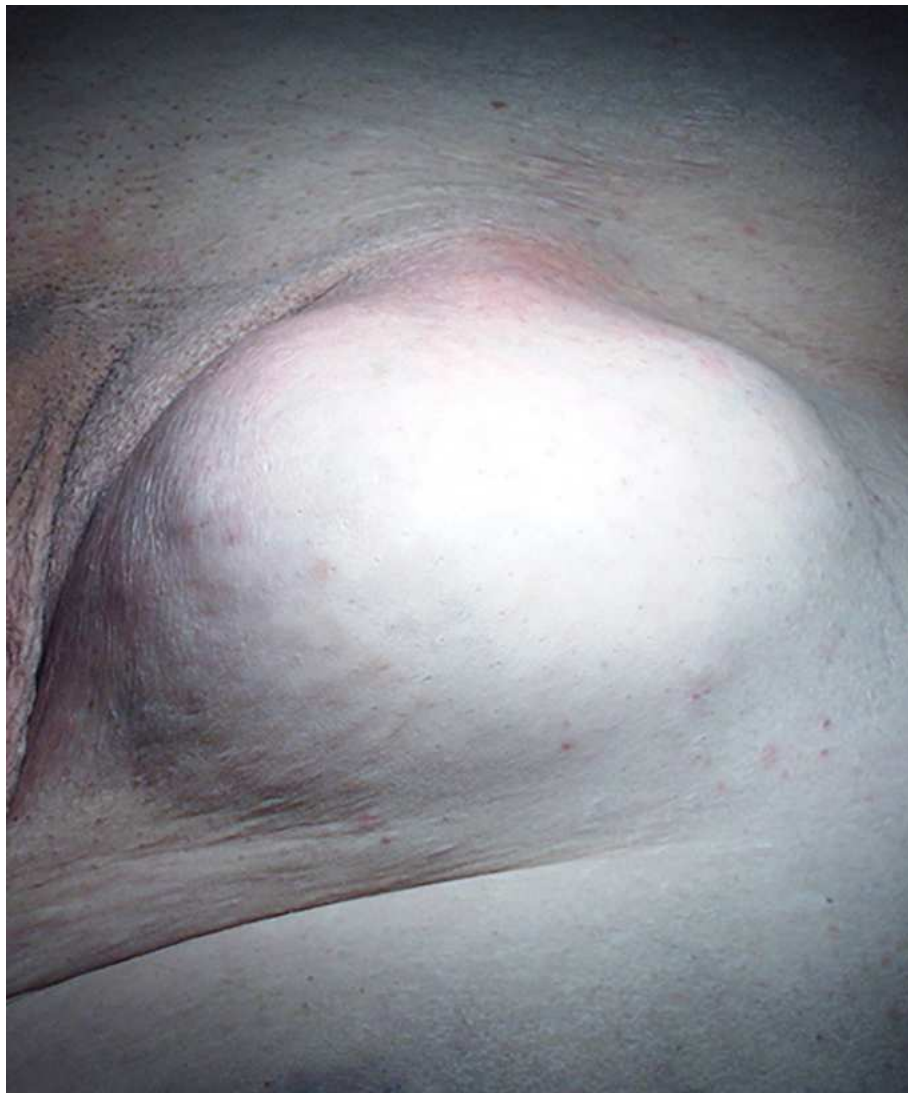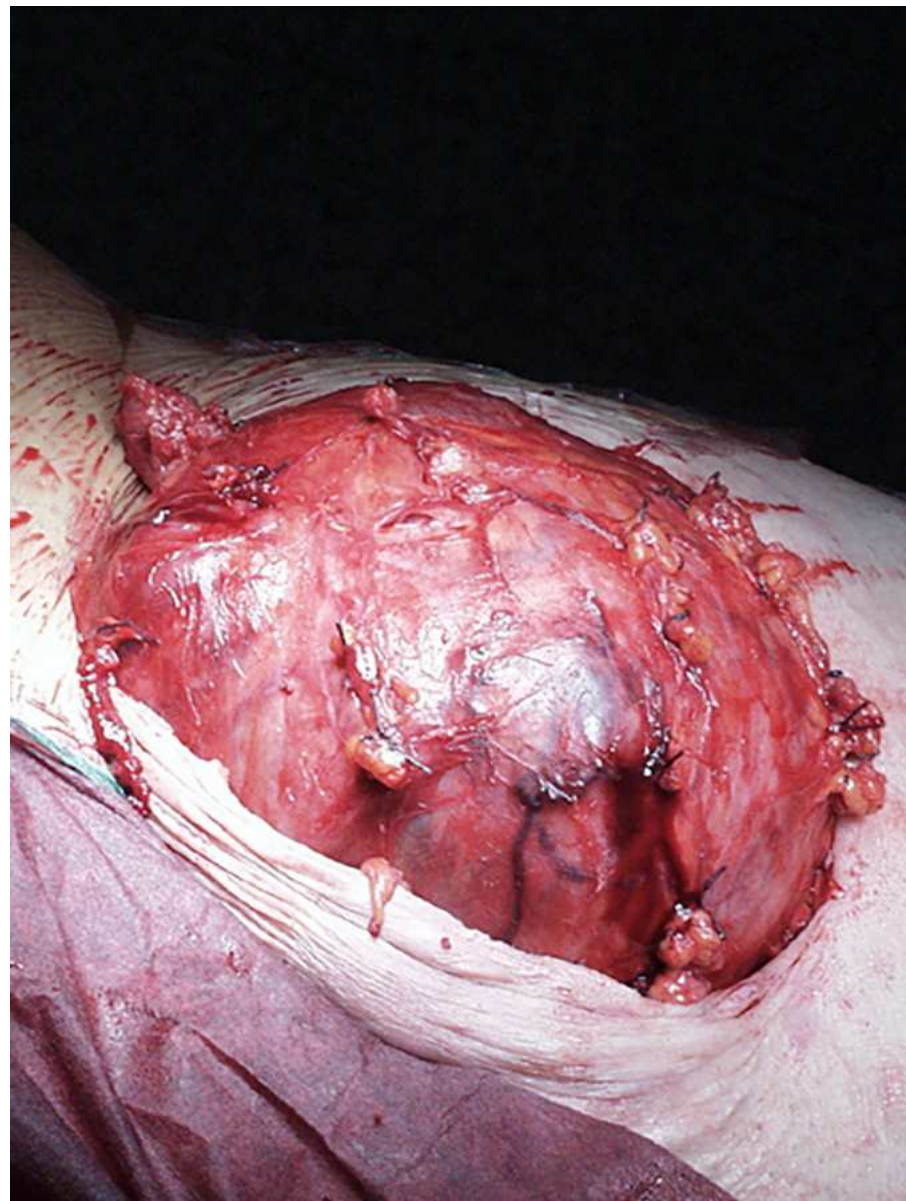
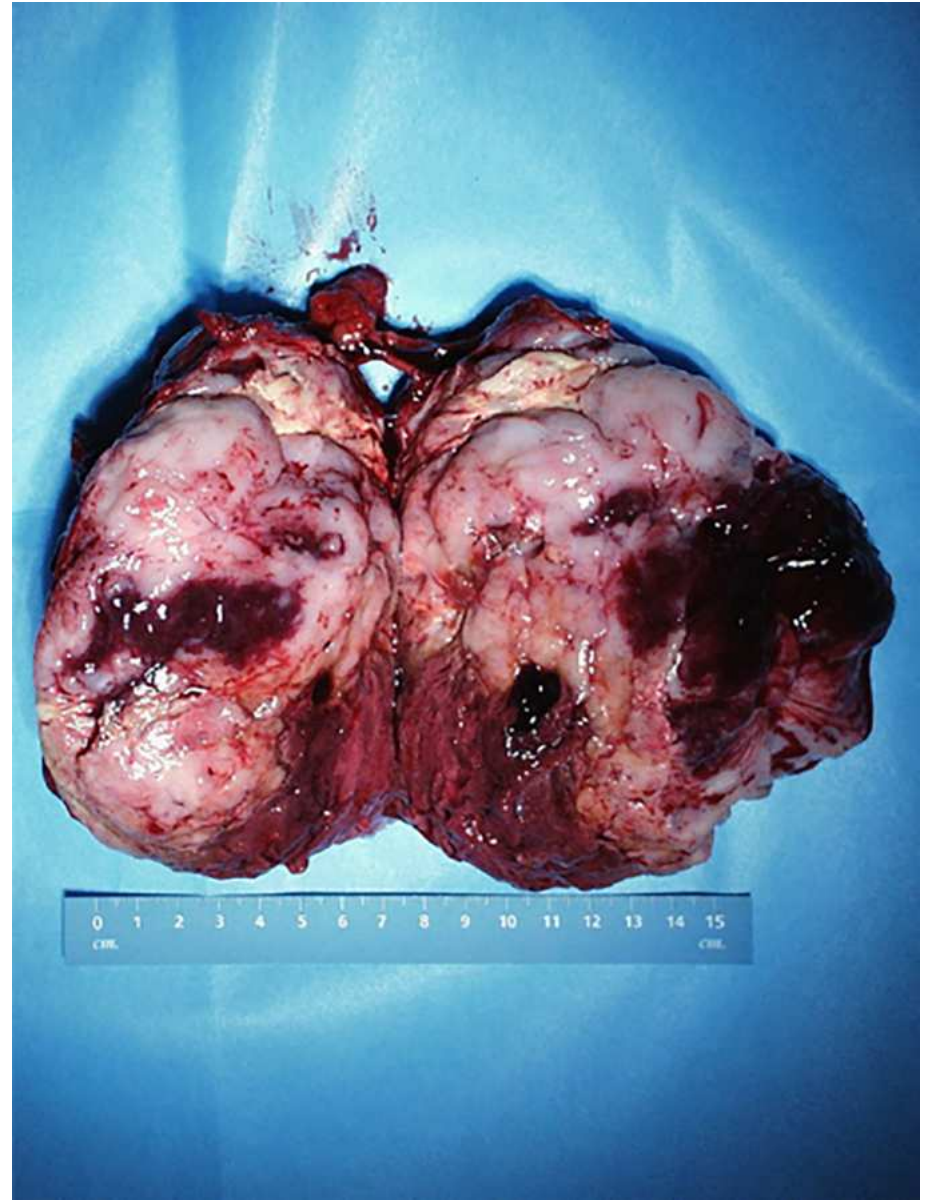

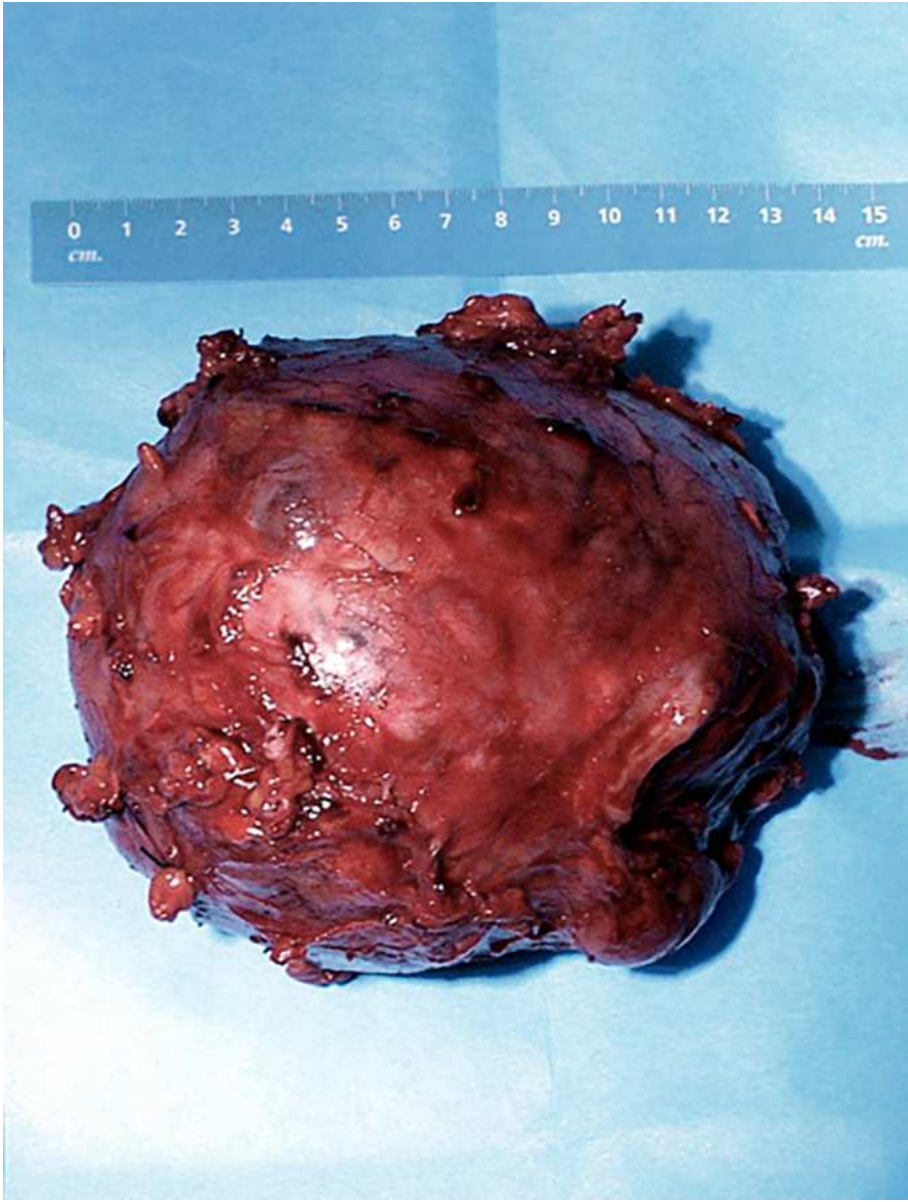
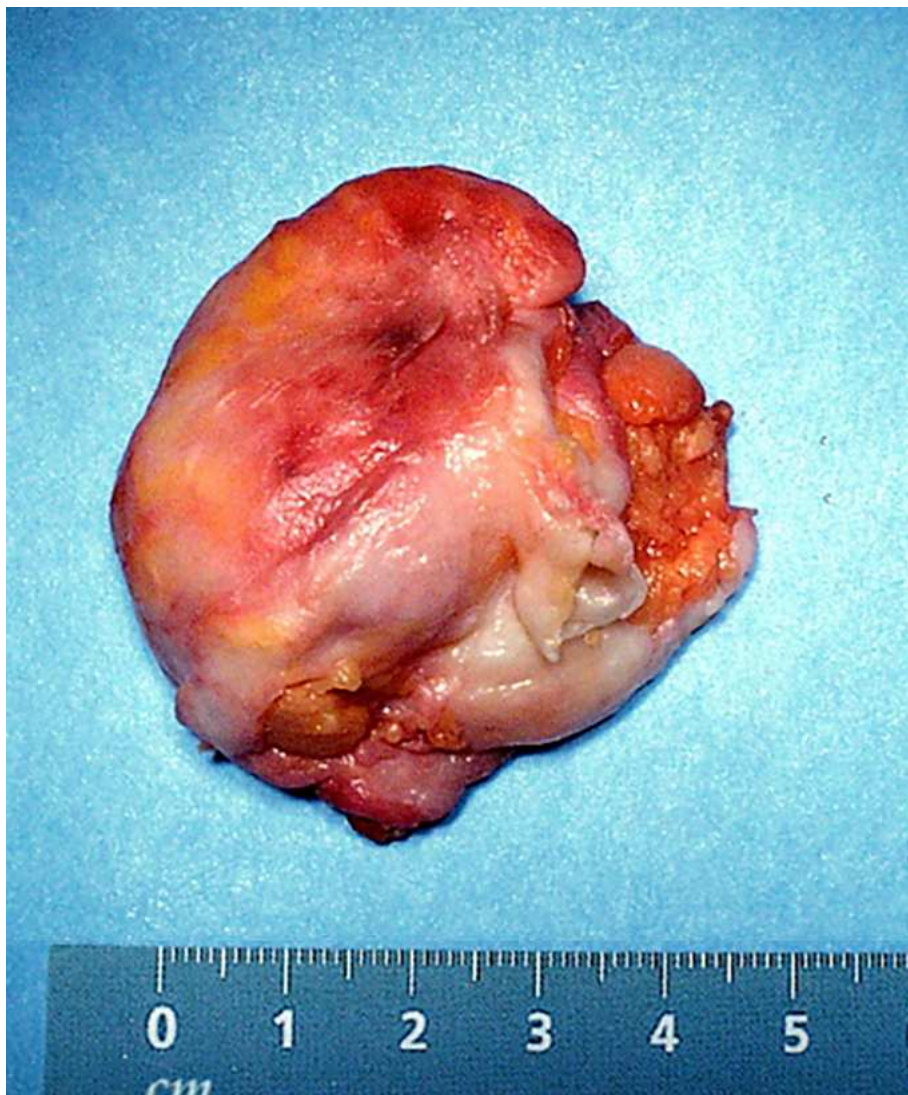S.A. • Anni: 69 - M • Record 1 • 18-07-2001

Enucleazione di linfoma non Hodgkin del triangolo di Scarpa sn

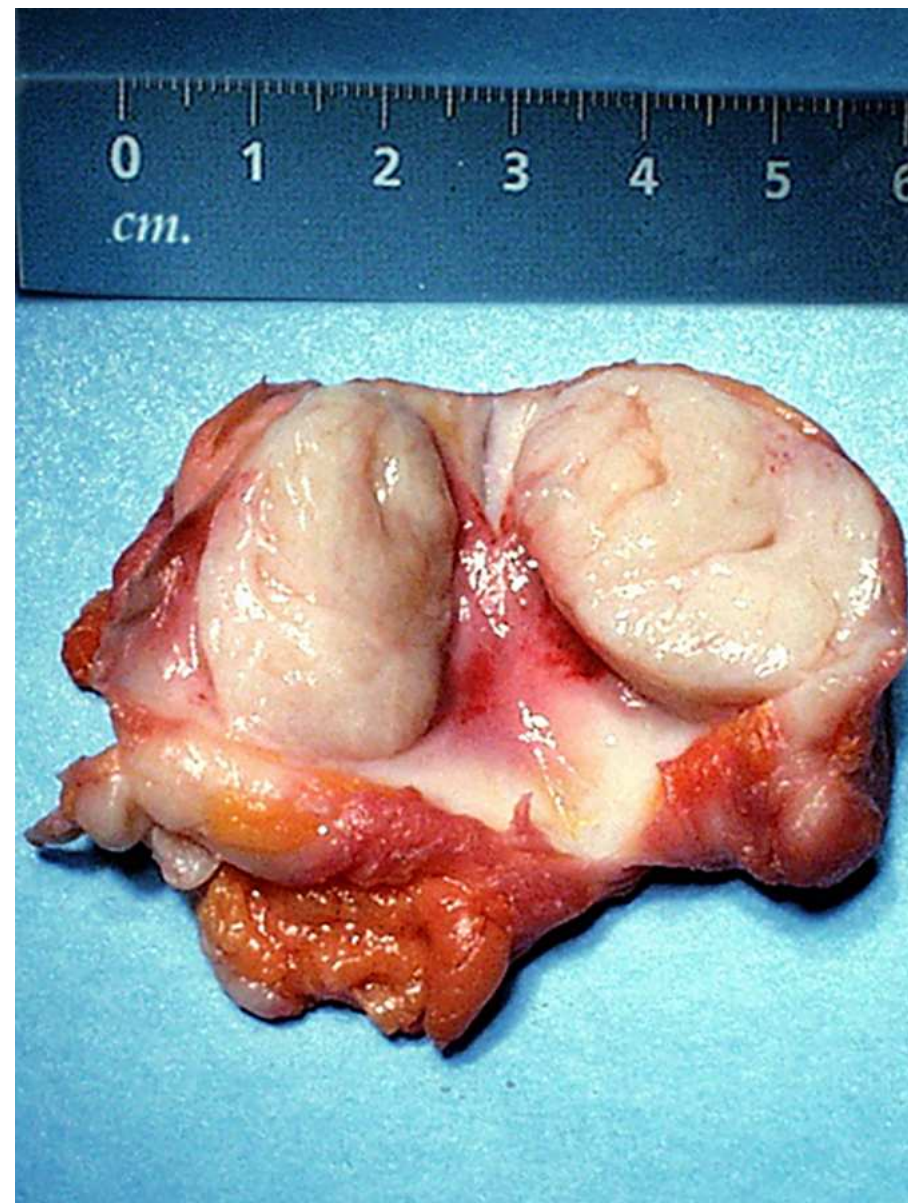


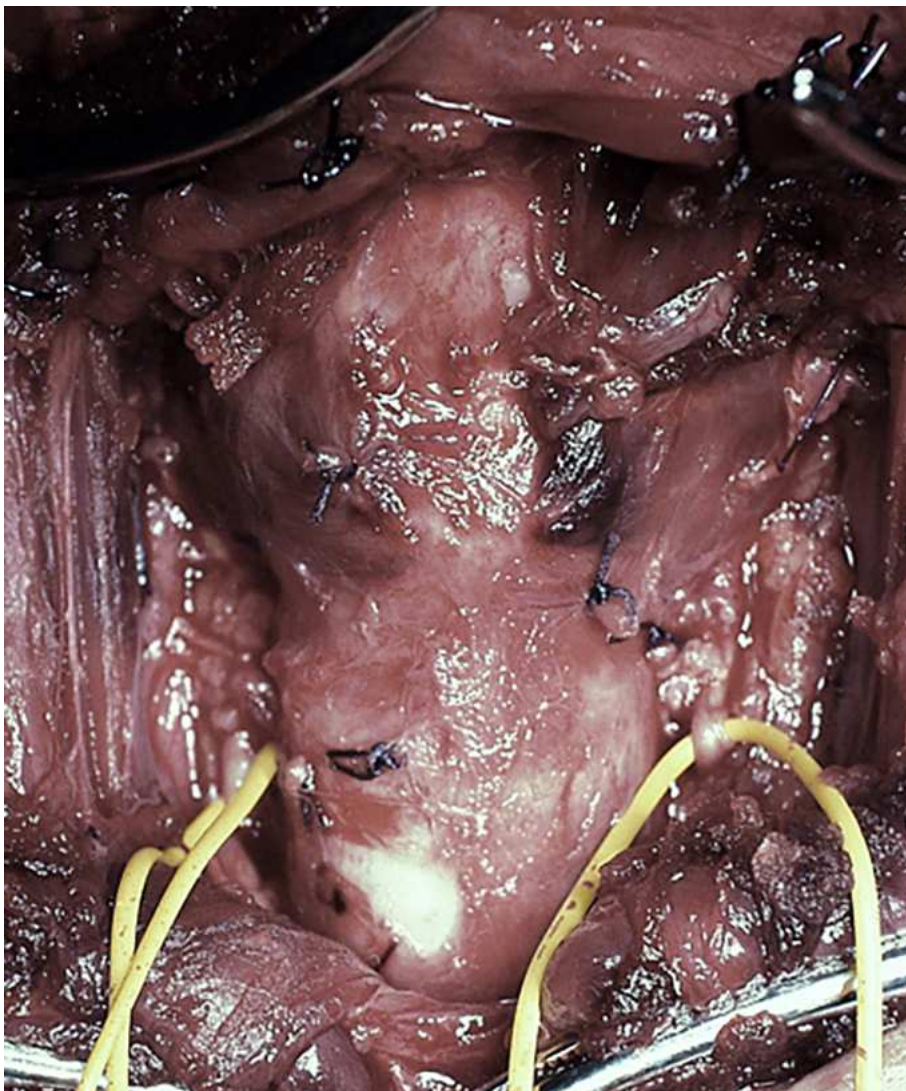




I.M.V. · Anni: 16 - F · Record: 2 · 25-07-2001

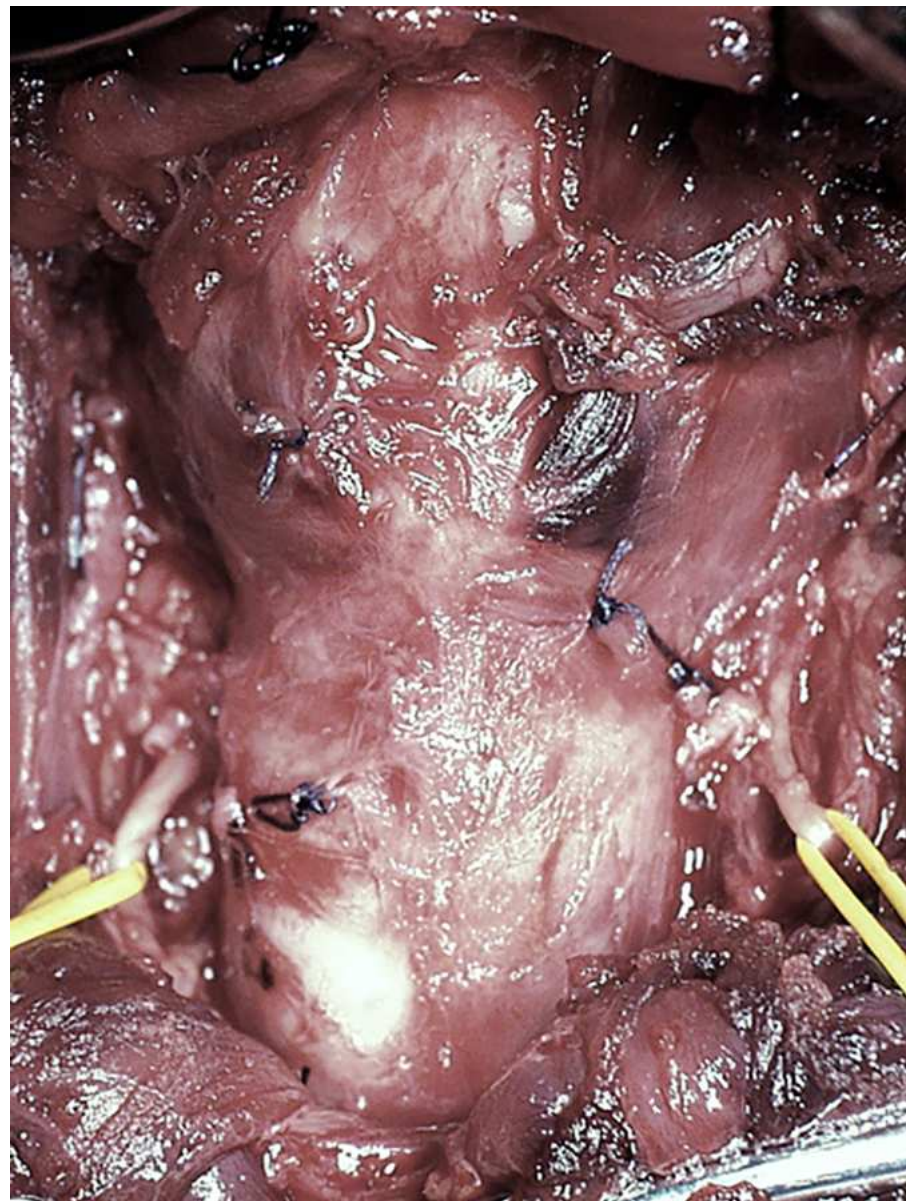
Enucleoresezione per via periareolare superiore di fibroadenoma QSI mammella sn



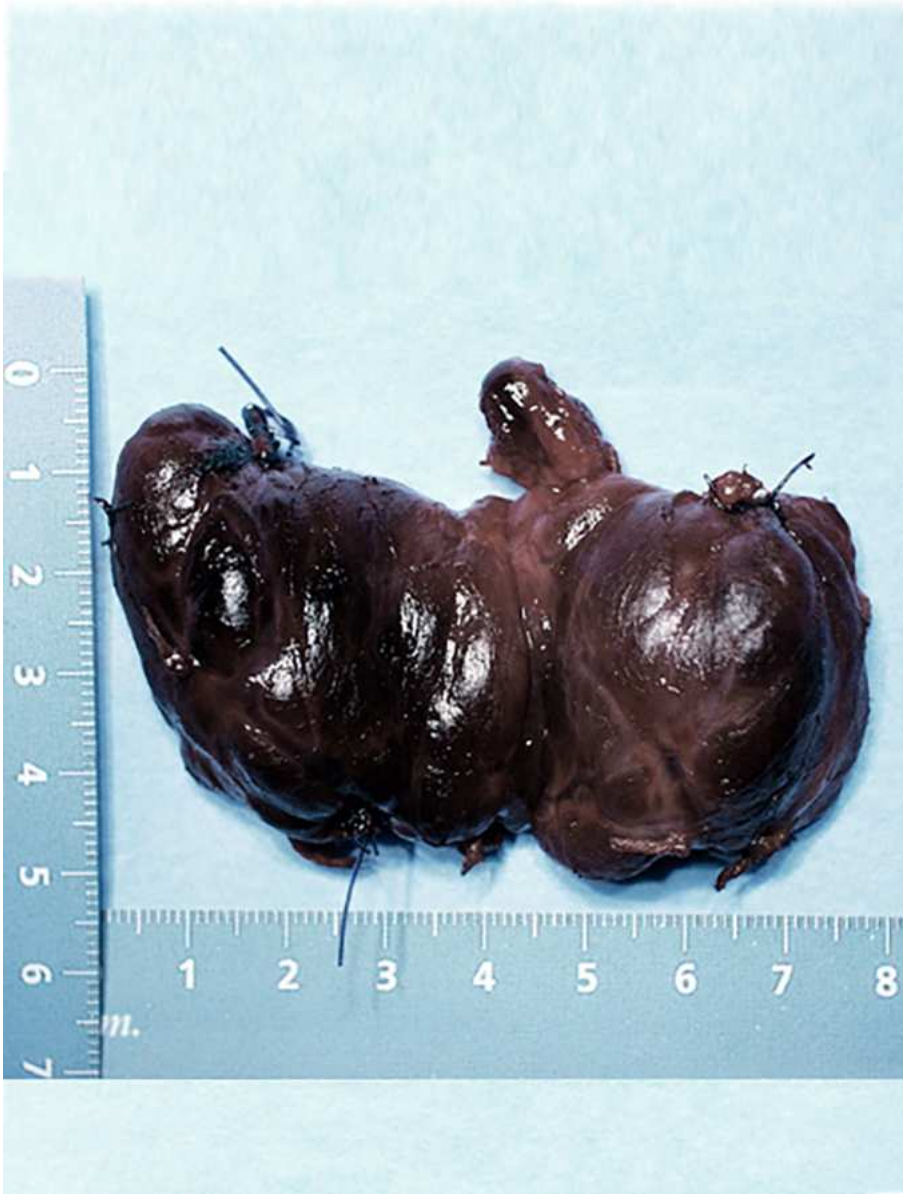

I.G. · Anni: 36 - M · Record: 3 · 25-07-2001

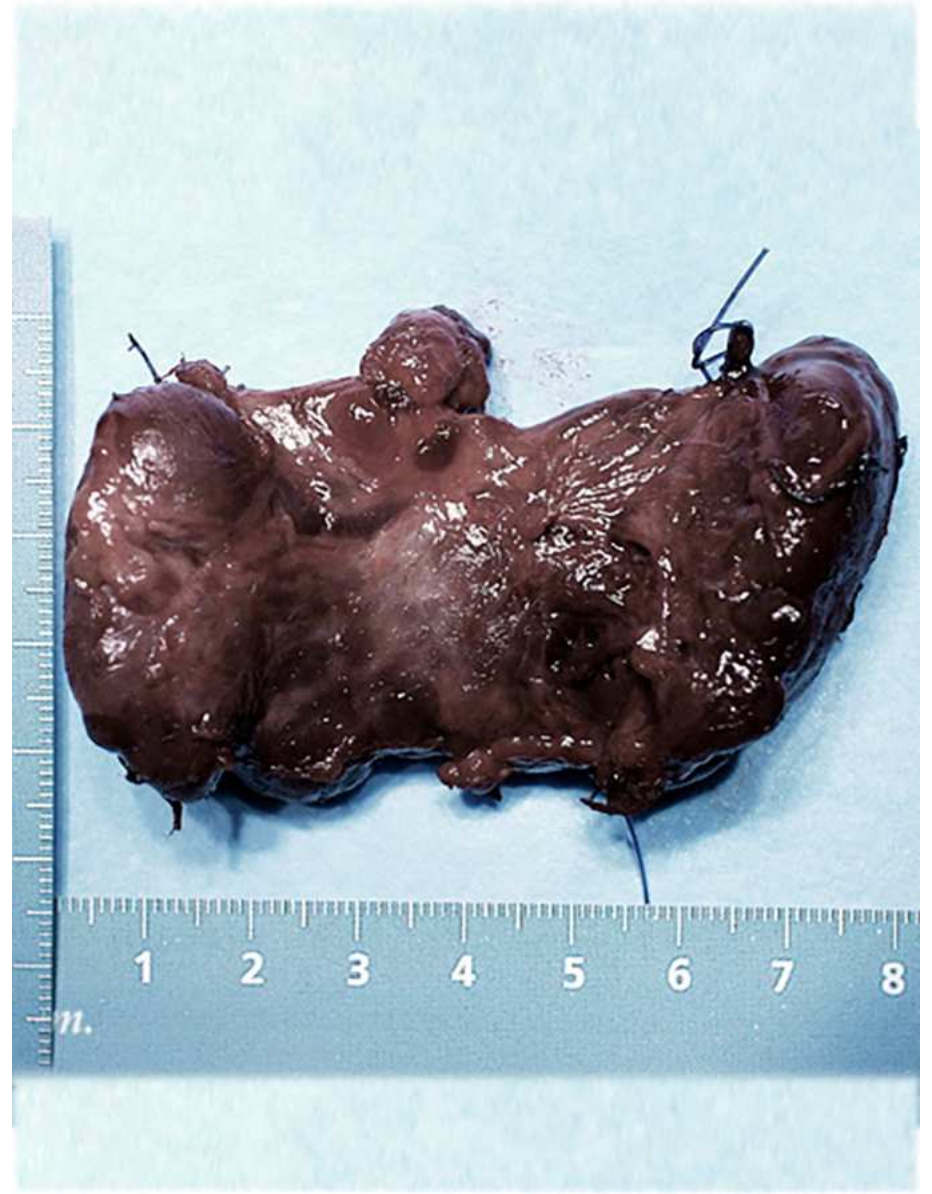Tiroidectomia totale extracapsulare per gozzo plurinodulare tossico



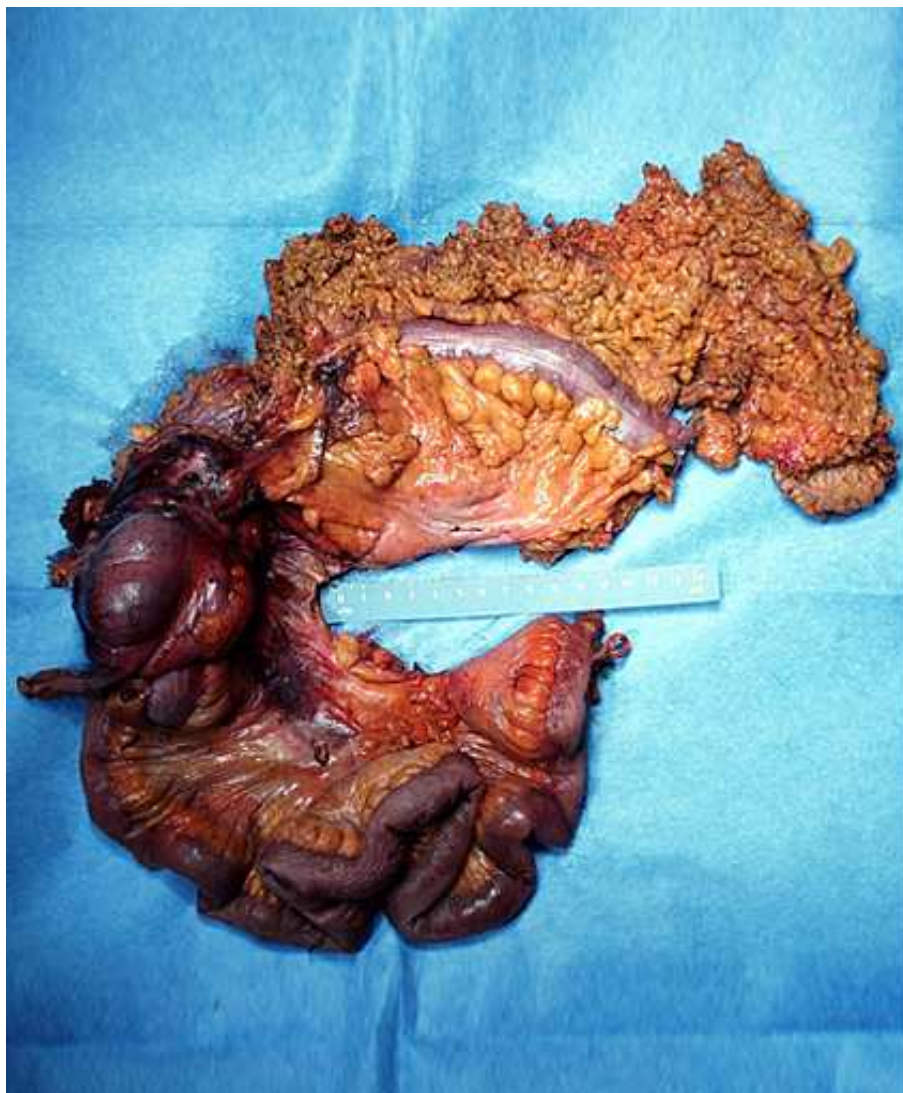Isolamento dei nervi laringei inferiori (ricorrenti)



Lobo destro - Istmo - Lobo sinistro (superficie anteriore)

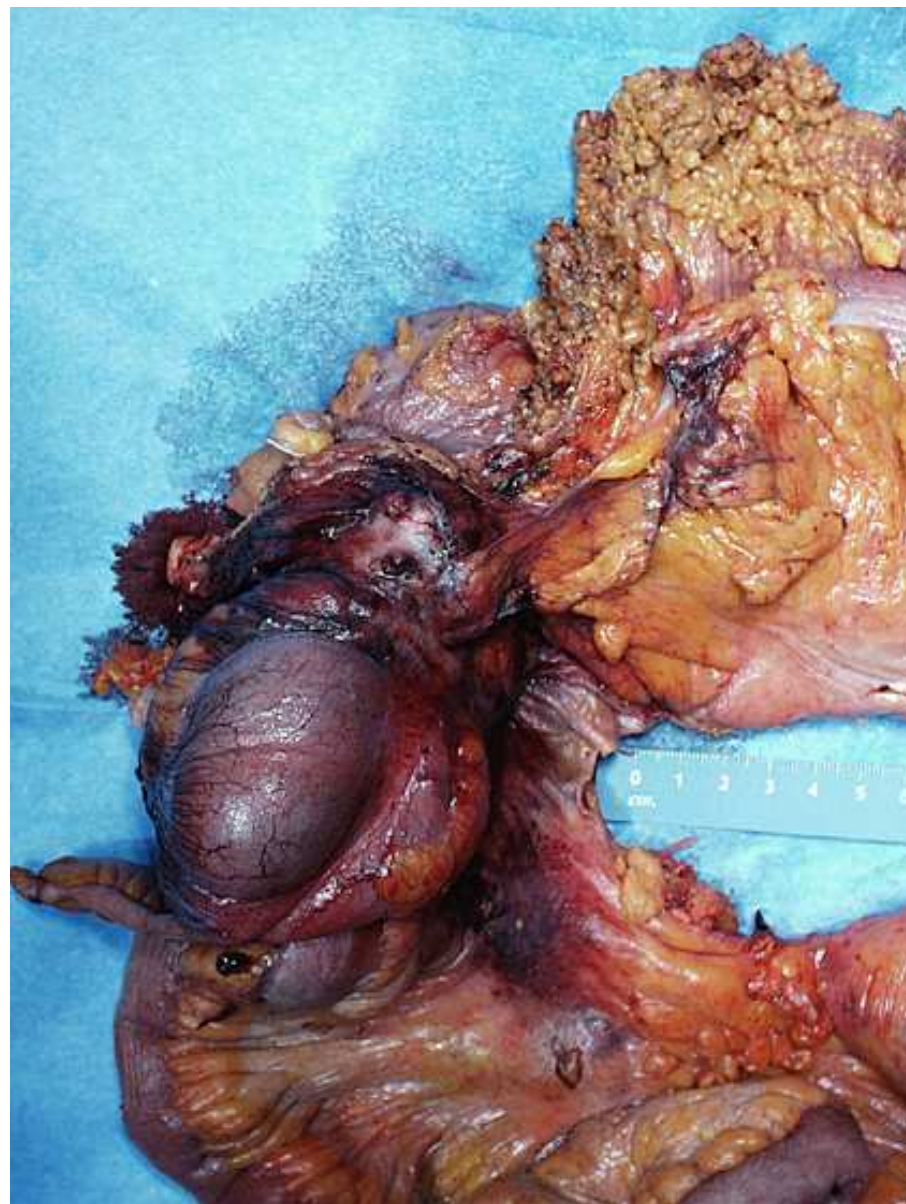

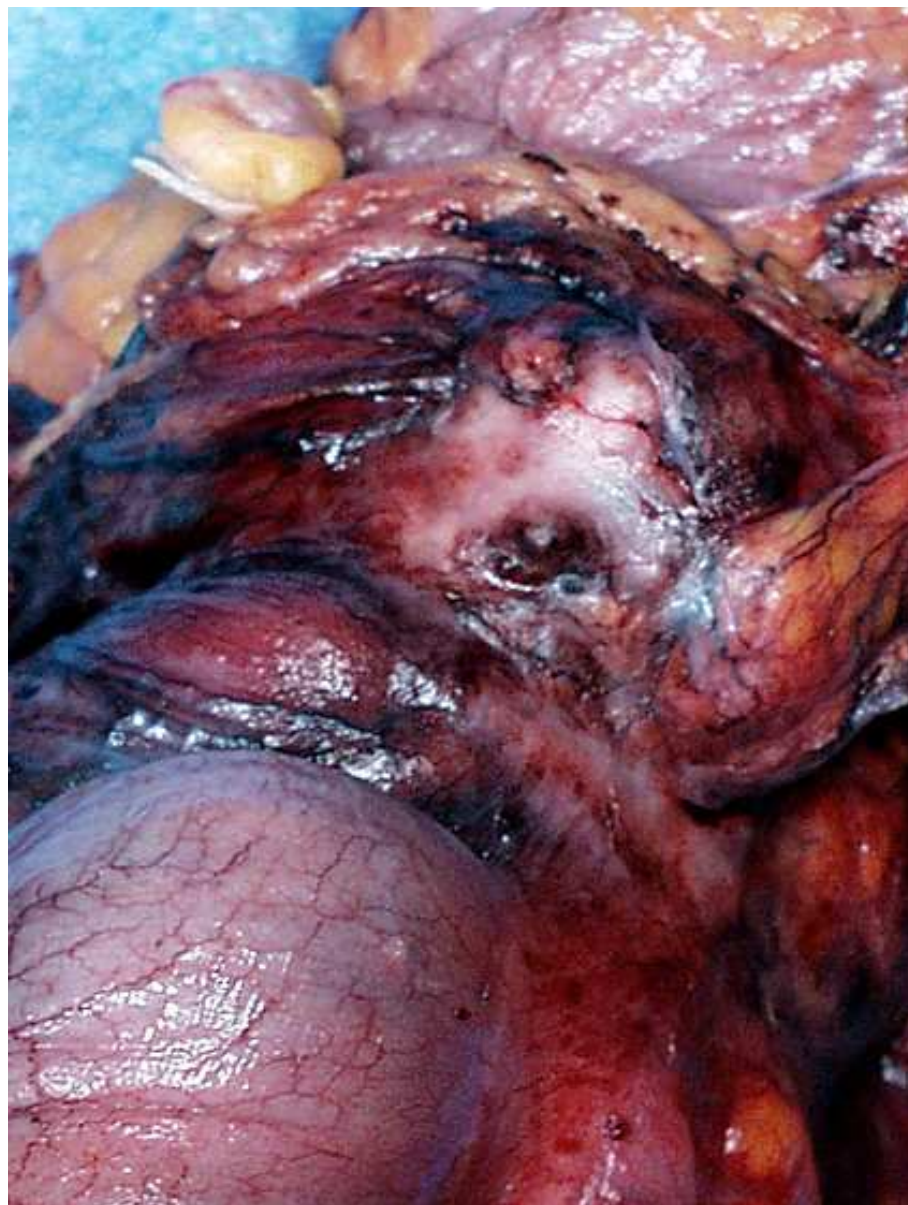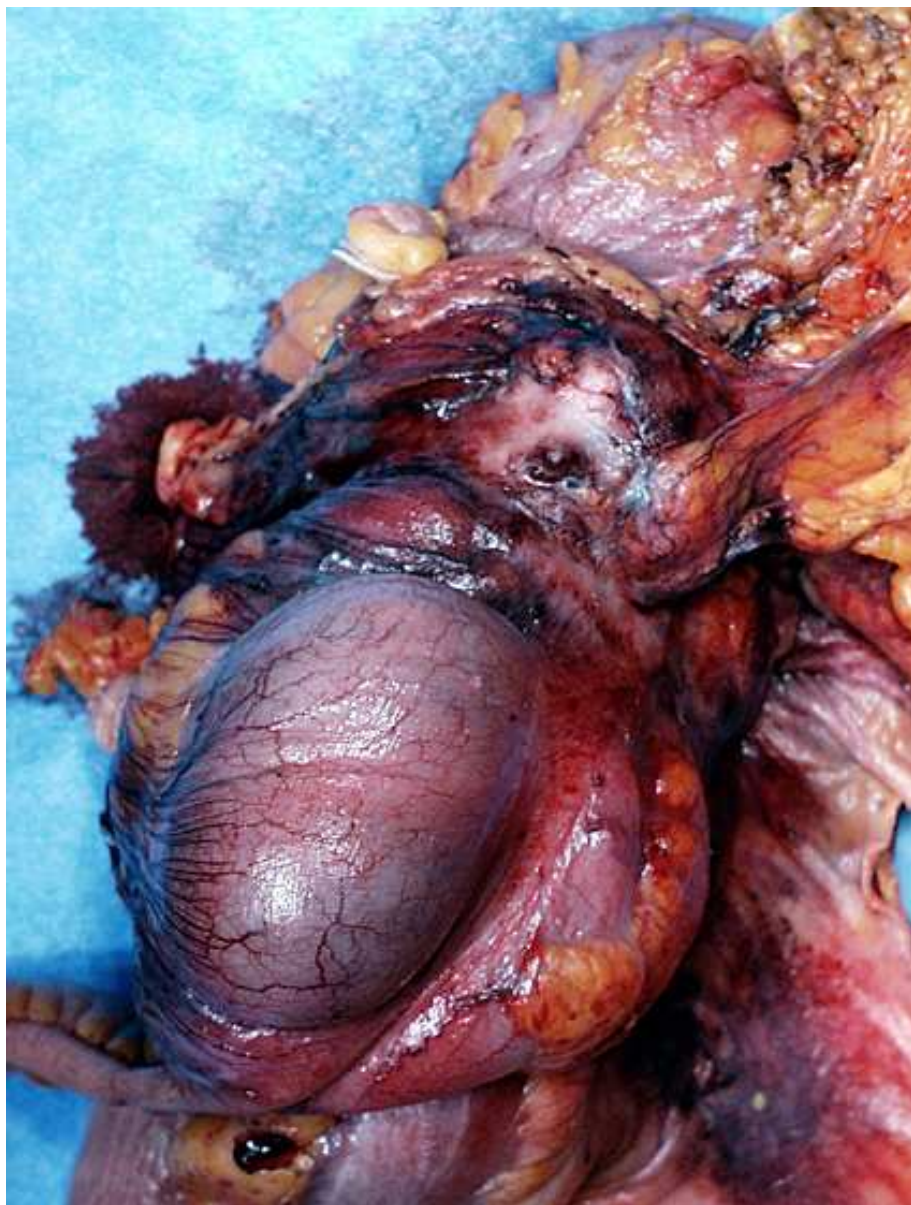Lobo sinistro - Istmo - Lobo destro (superficie posteriore)

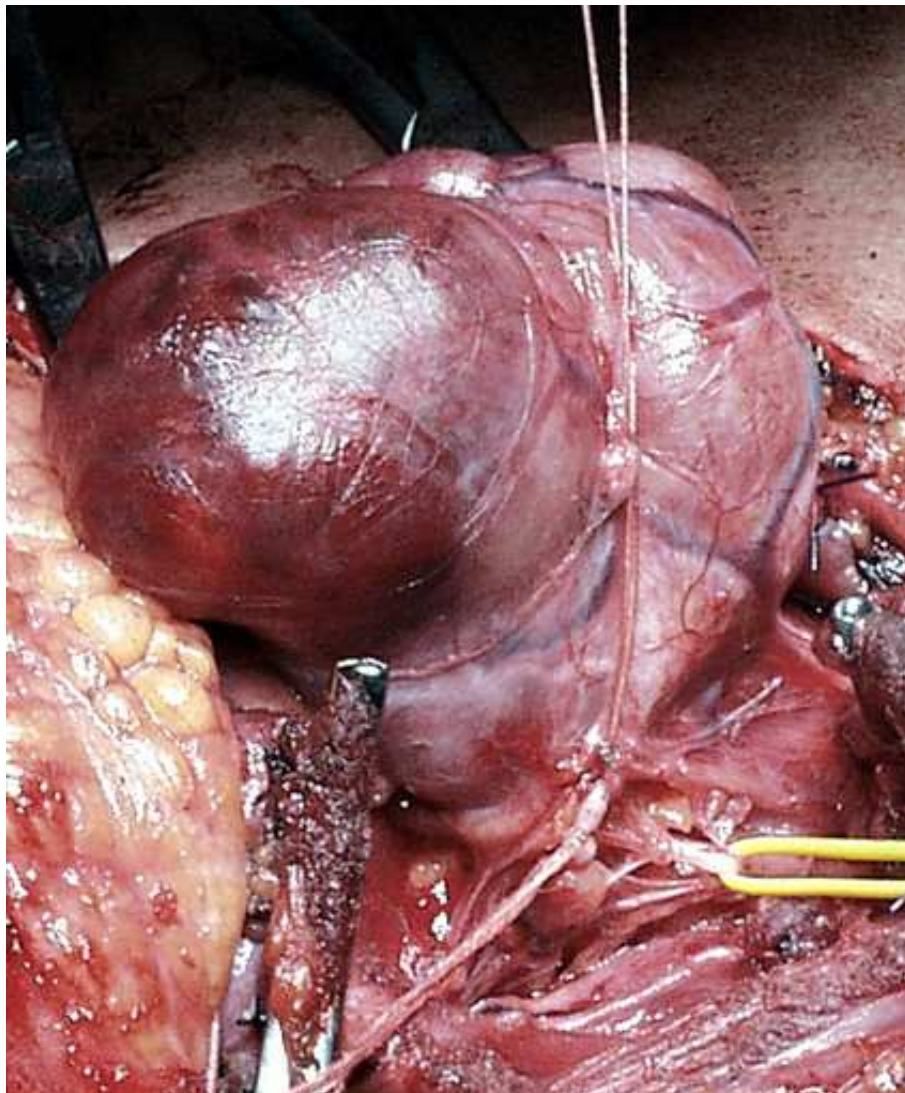


E.G. · Anni: 88 - F · Record: 4 · 01-09-2001

Colectomia destra allargata e linfadenectomia perimesenterica superiore per adenocarcinoma sanguinante del colon destro

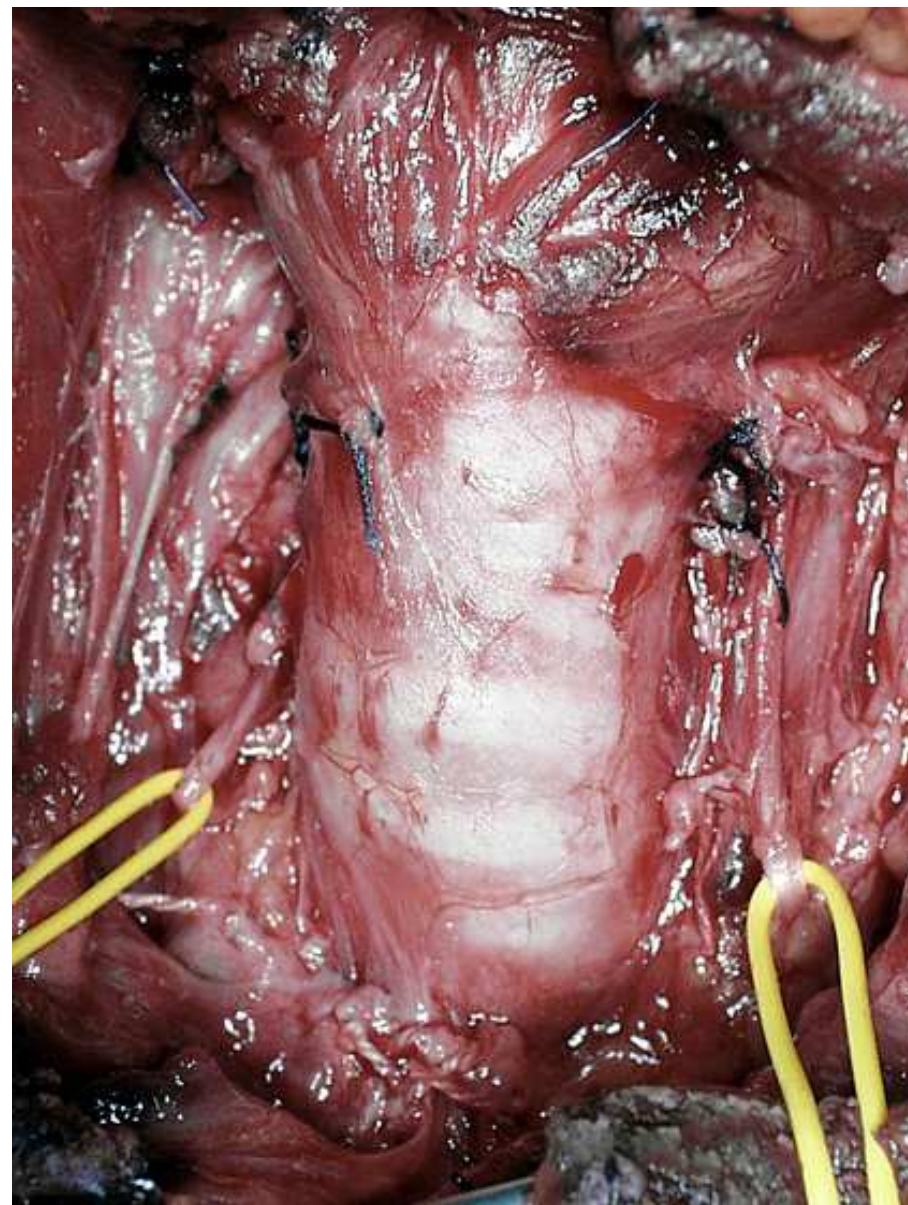






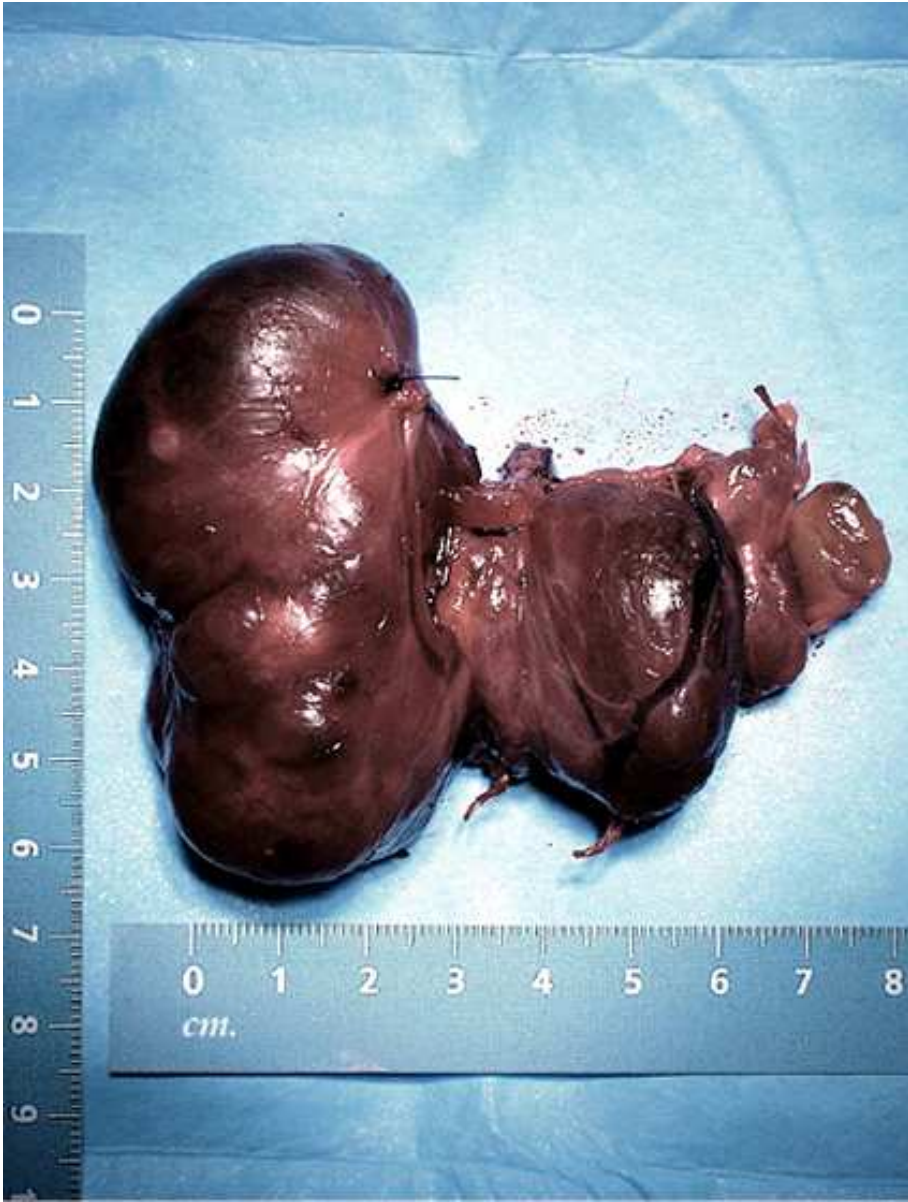F.A. • Anni: 42 - F • Record: 5 • 12-09-2001

Tiroidectomia totale extracapsulare e paratiroidectomia sn per gozzo plurinodulare ed adenoma paratiroido

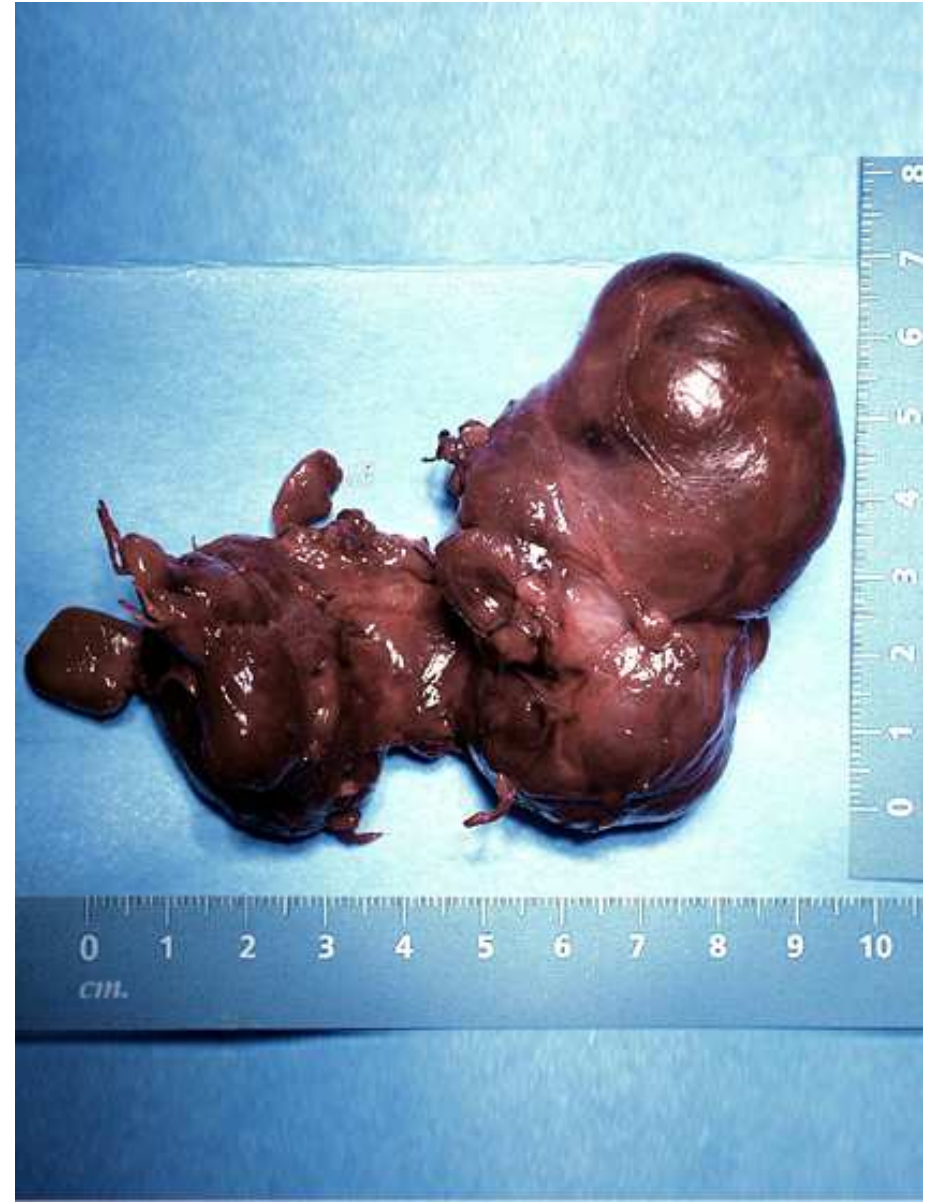

Isolamento dei nervi laringei inferiori (ricorrenti)

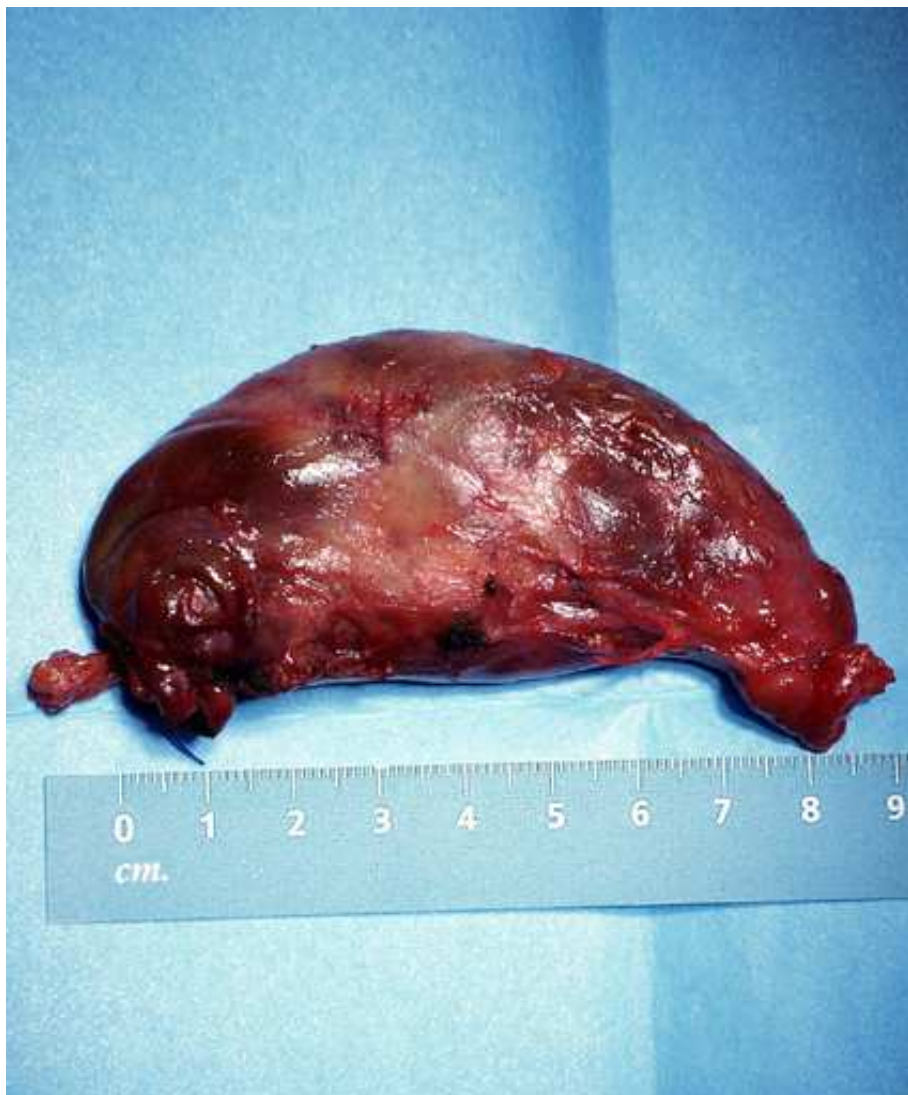



Lobo destro, Istmo e Lobo sinistro della tiroide - Paratiroide (superficie anteriore)

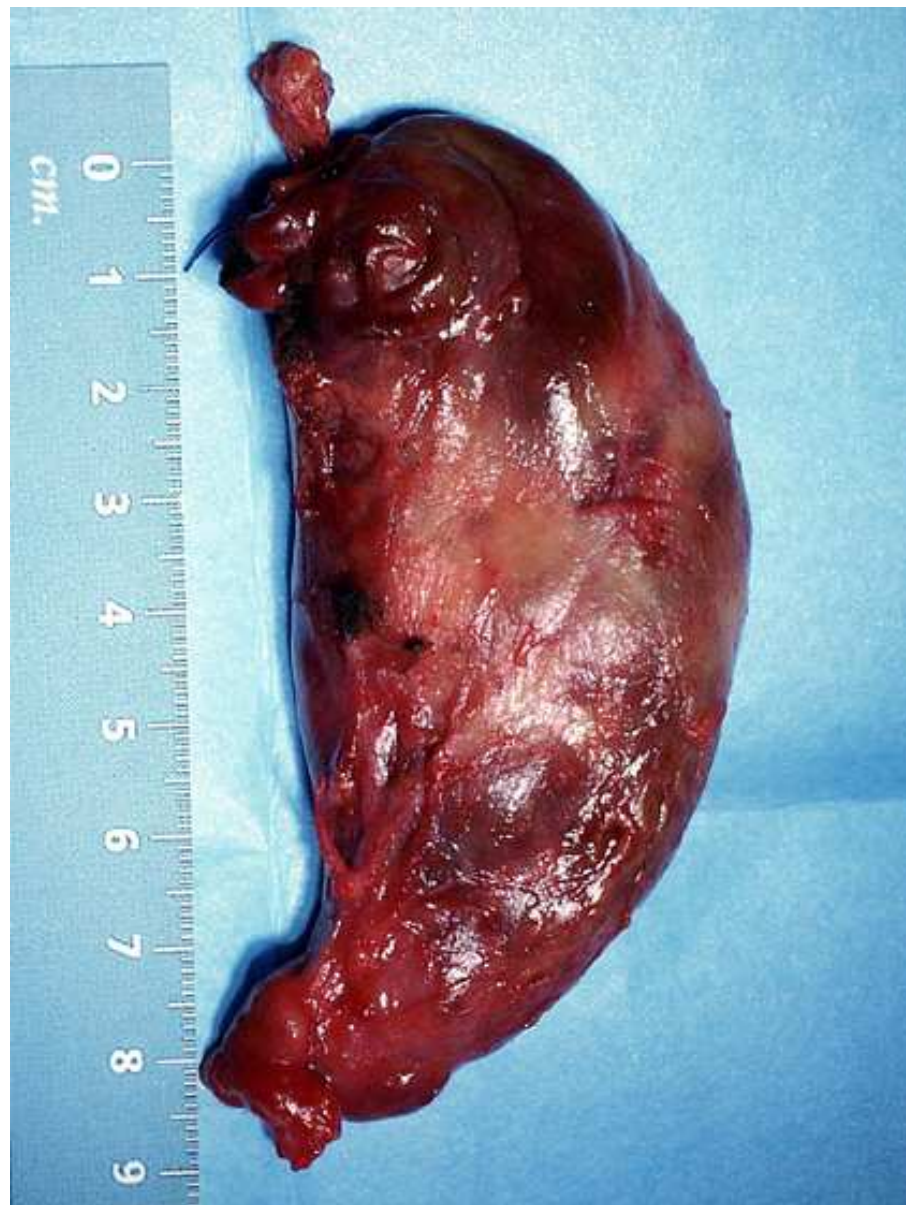

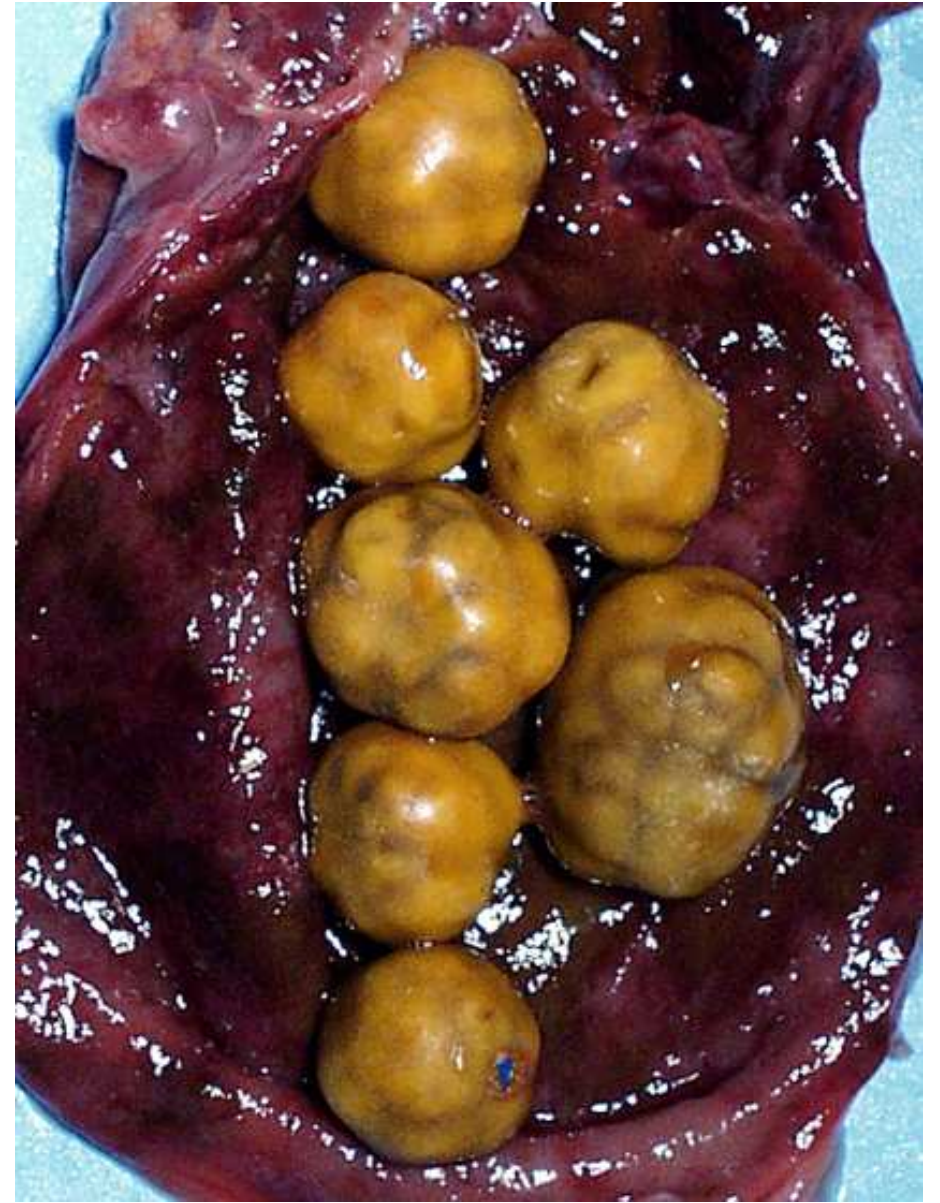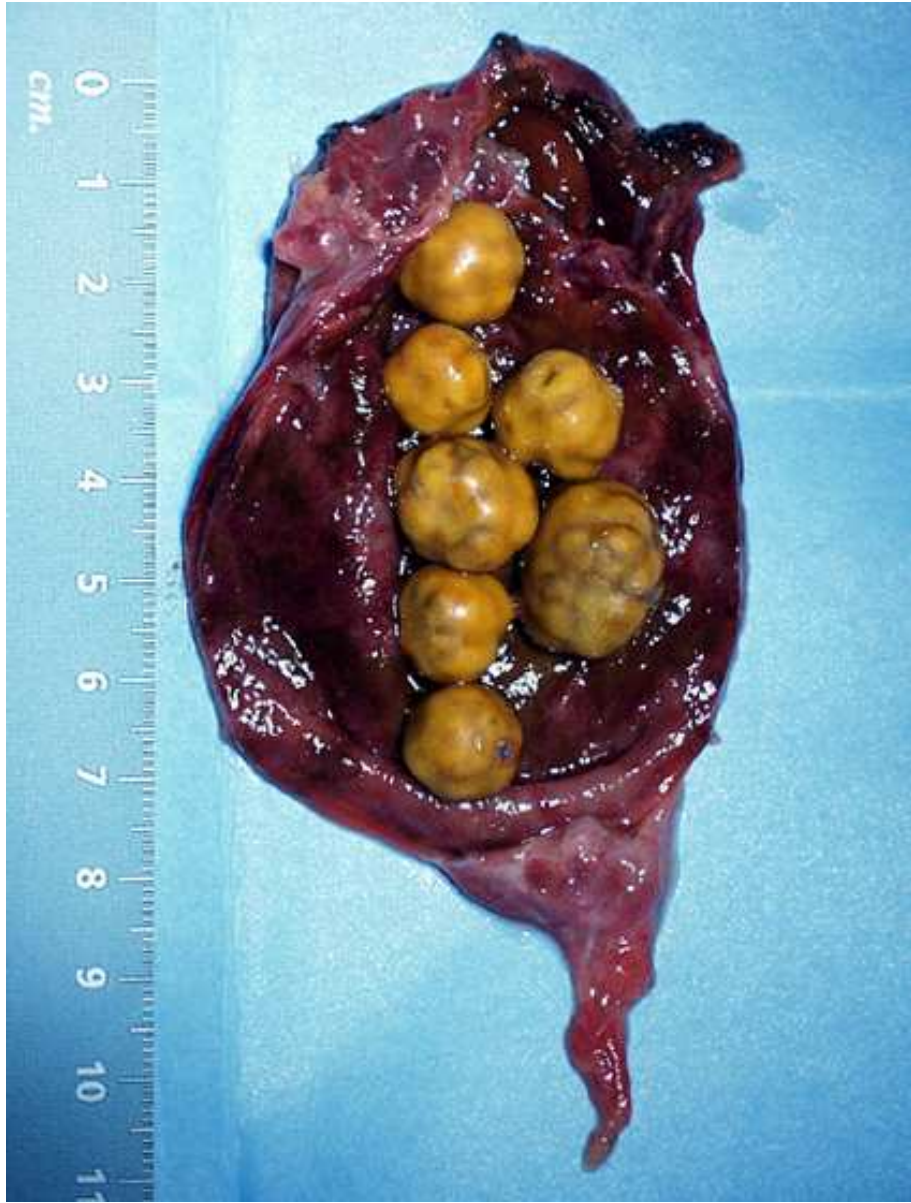
Paratiroide - Lobo sinistro, Istmo e Lobo destro della tiroide (superficie posteriore)

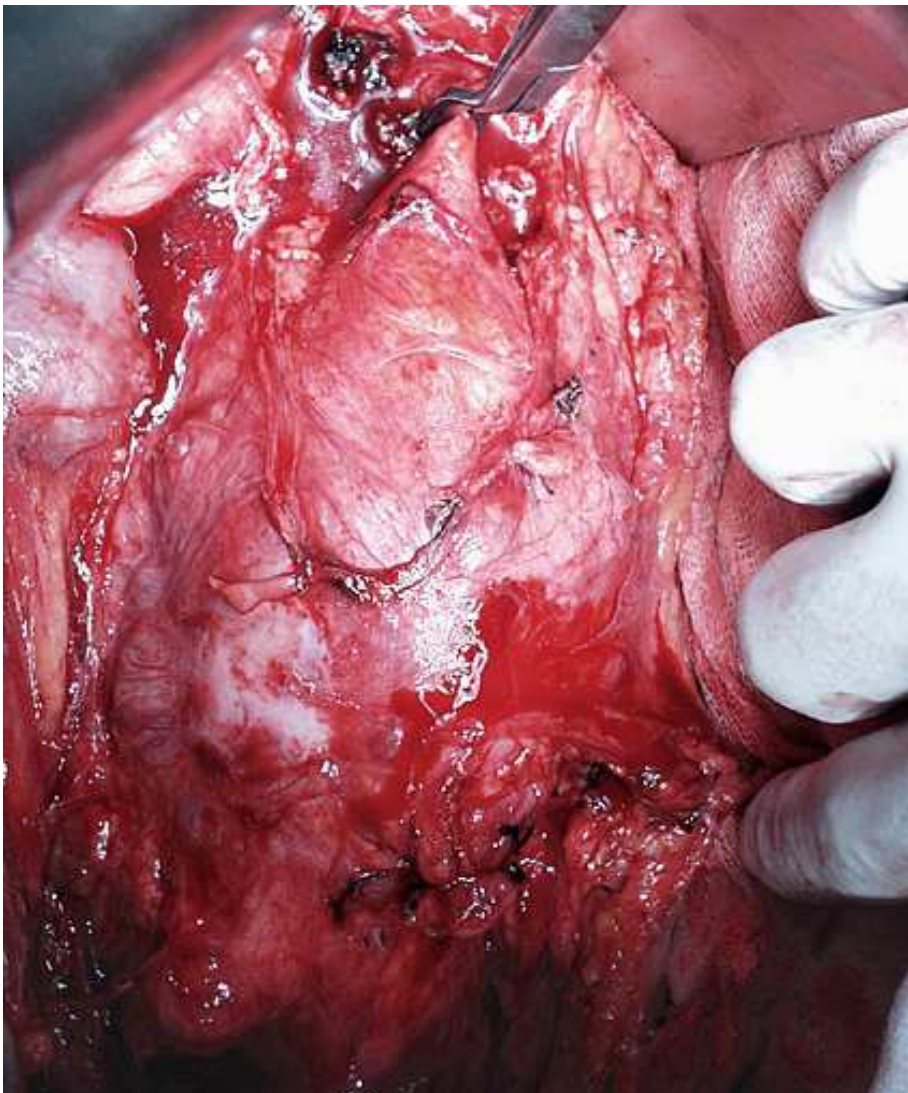


C.M. • Anni: 37 - M • Record: 6 • 12-09-2001

Colecistectomia retrograda per peritonite biliare da colecistite acuta flemmonosa litiasica filtrante

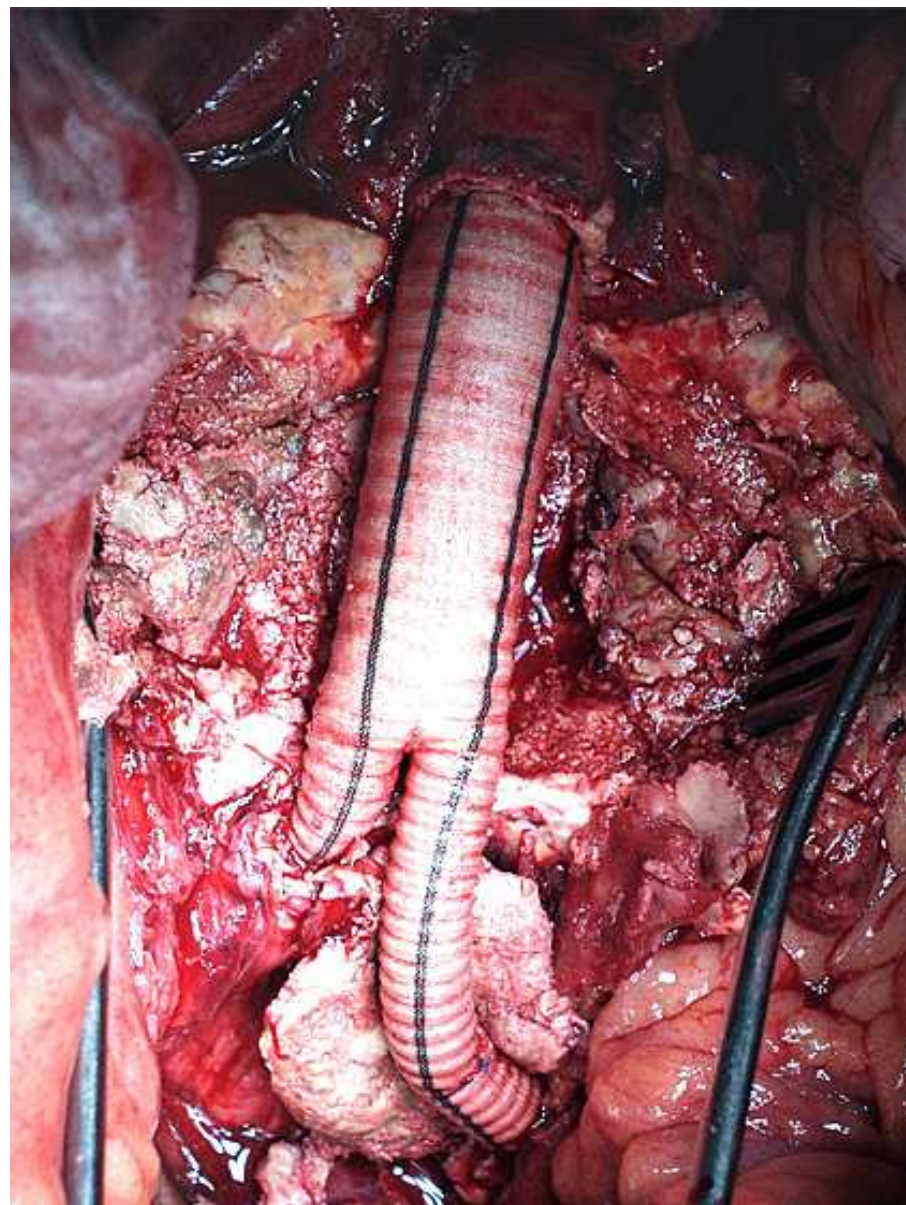


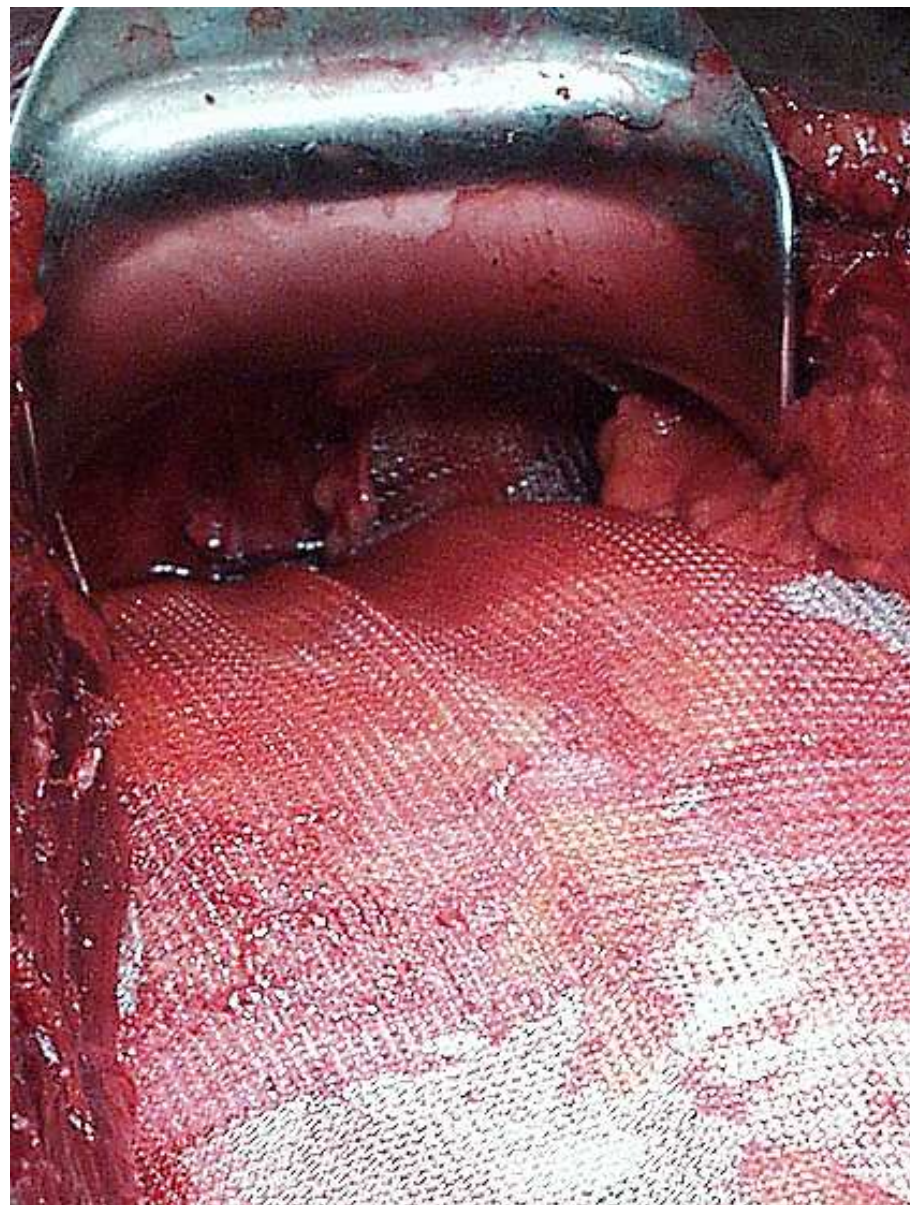
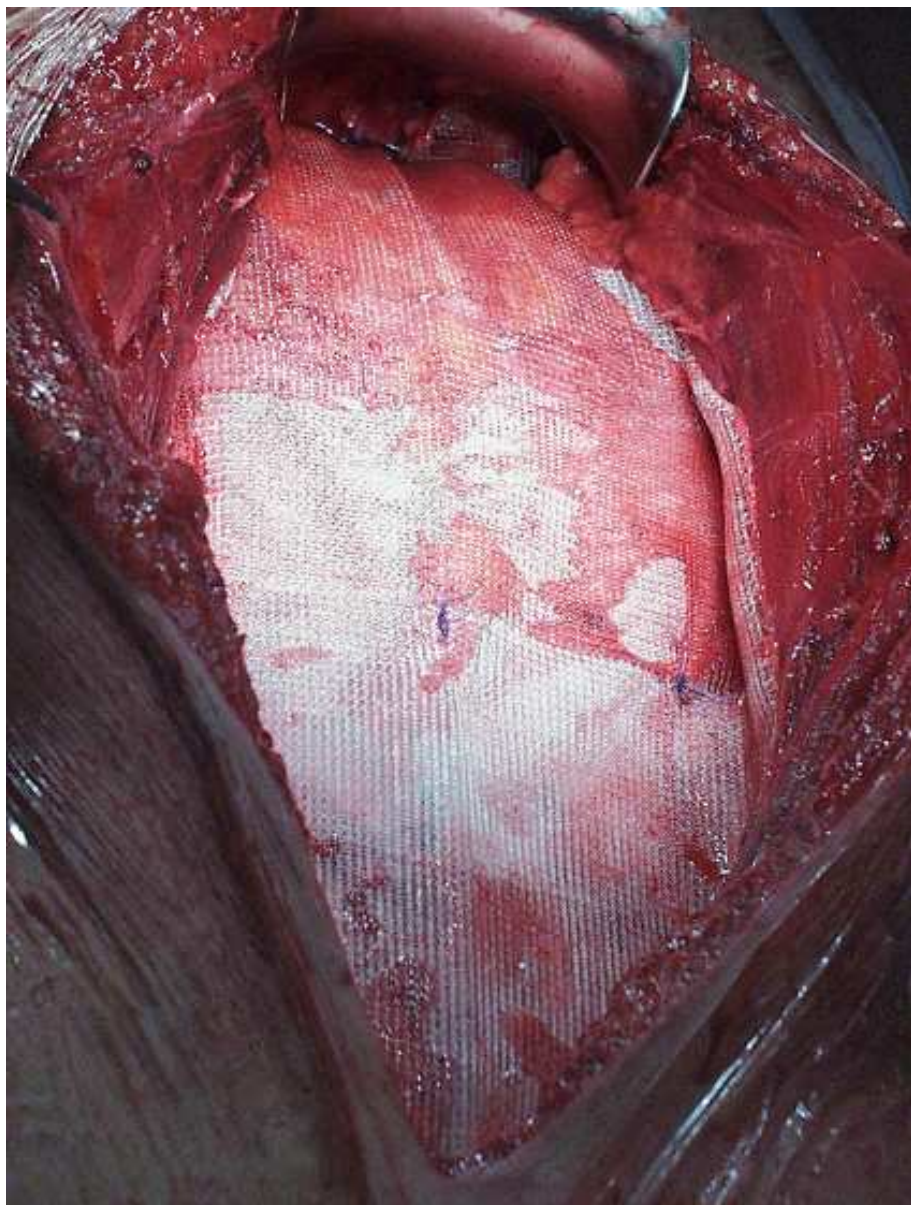

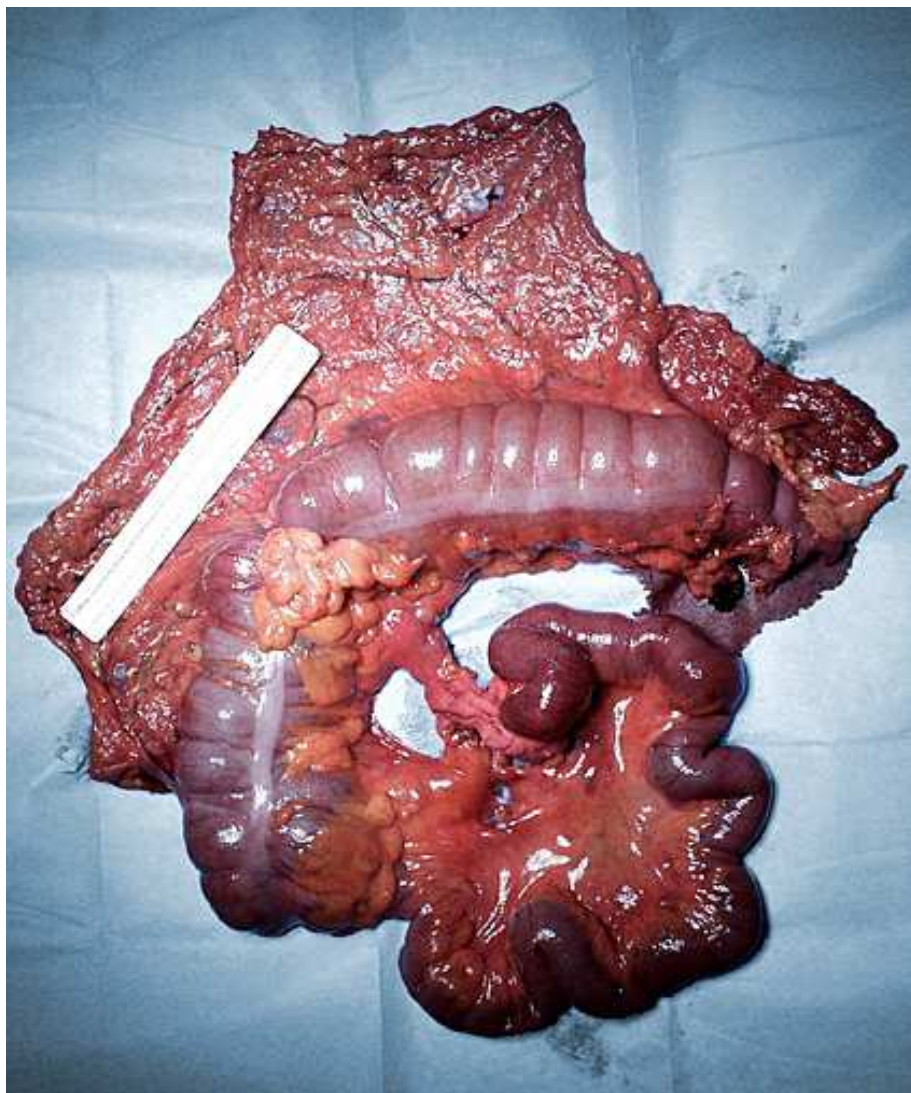


M.A. • Anni: 71 - M • Record: 7 • 28-09-2001

Laparoalloplastica sec. Stoppa e drenaggio tubulare del Retzius per laparocèle xifo-ombelicale ed ernia inguinale bilaterale in corso di intervento per AAA

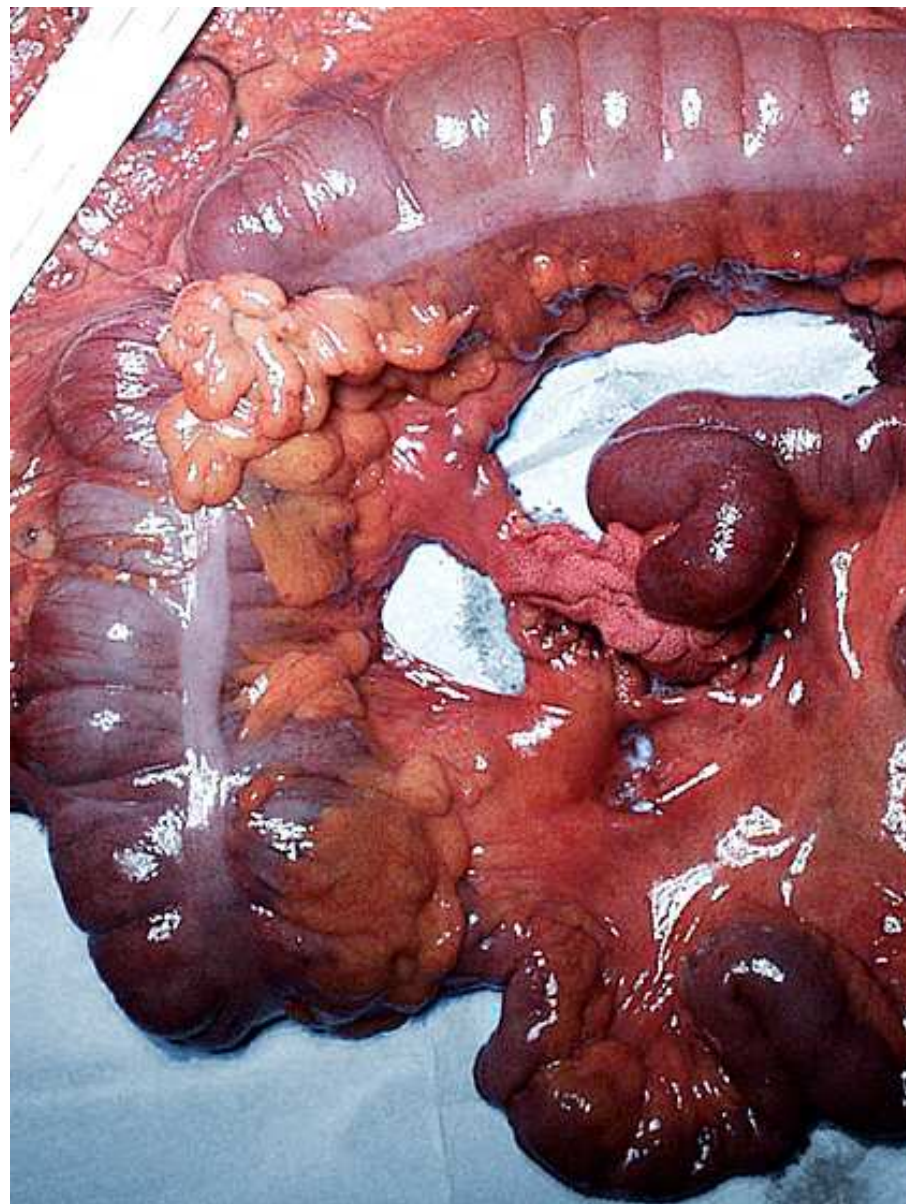


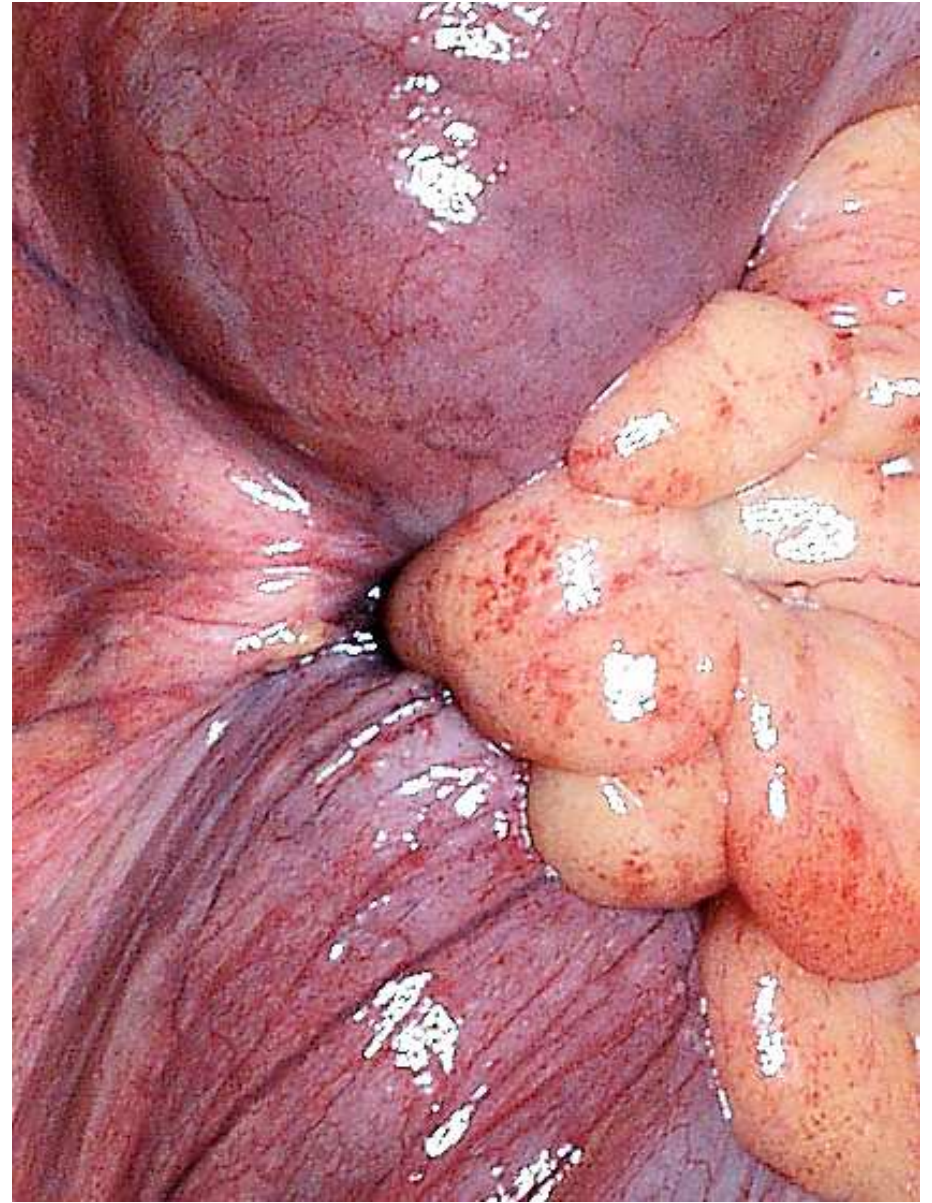
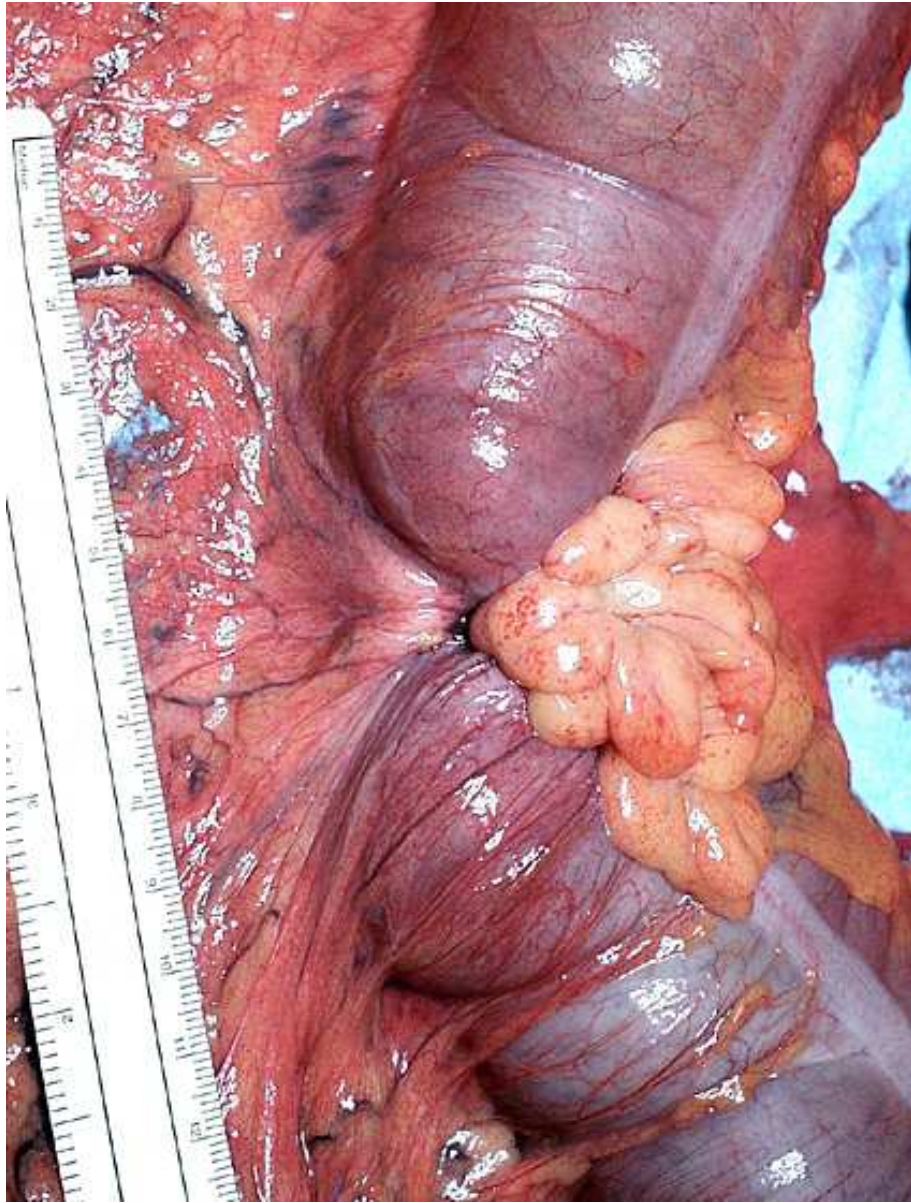


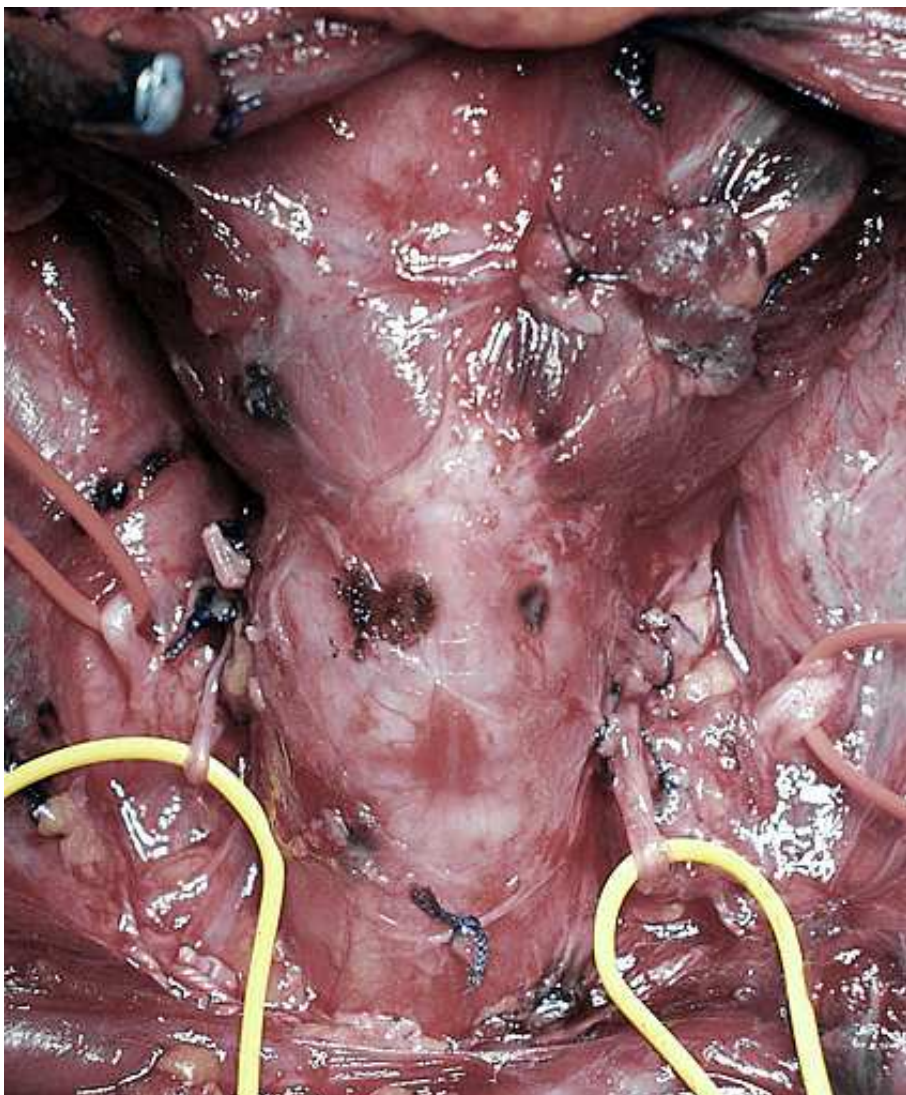


B.P. · Anni: 53 - M · Record: 8 · 01-10-2001

Emicolectomia destra estesa al terzo distale del colon trasverso e linfadenectomia gastroepiploica e perimesenterica superiore per adenocarcinoma stenotante della flessura epatica del colon (pT3 N0 G1)

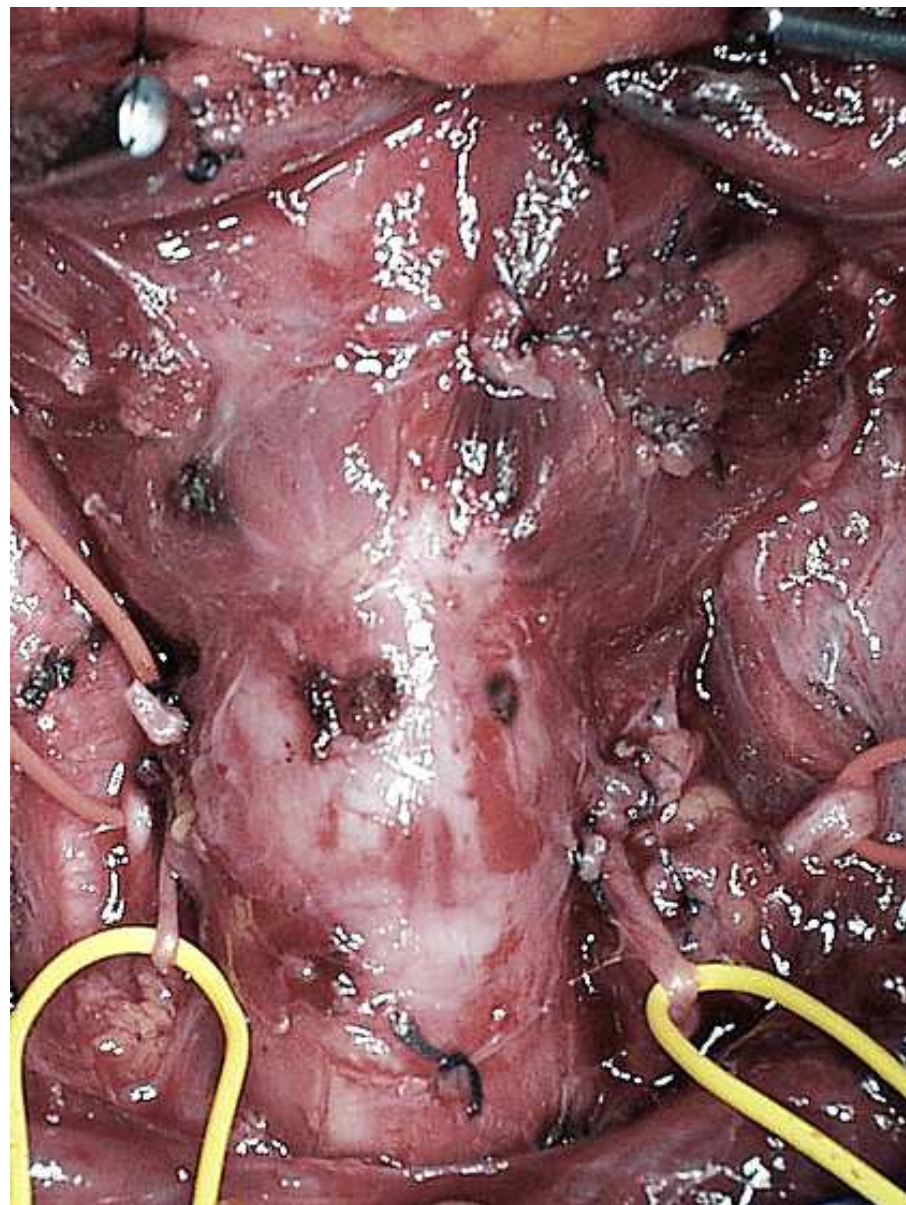






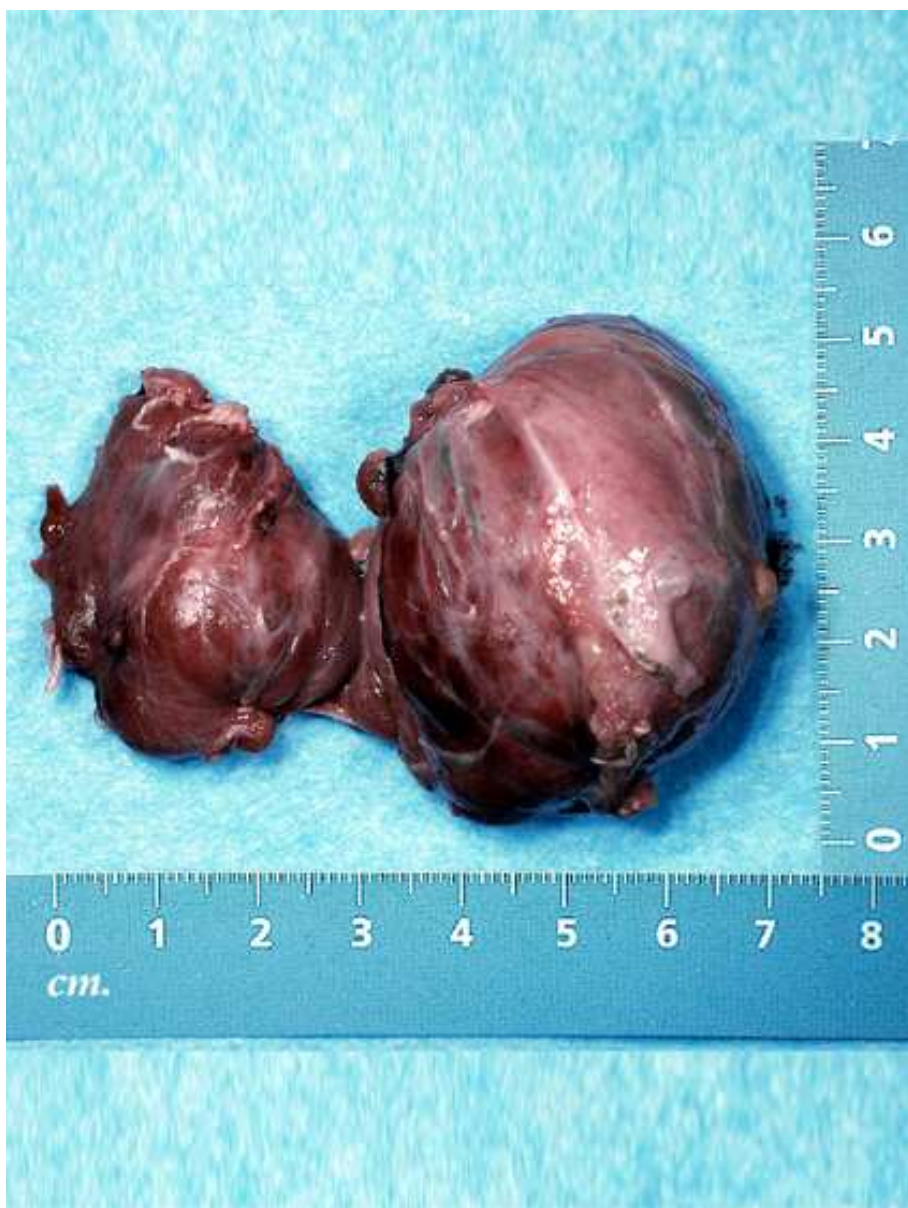L.M. • Anni: 56 - F • Record: 9 • 03-10-2001

Tiroidectomia totale extracapsulare per gozzo plurinodulare

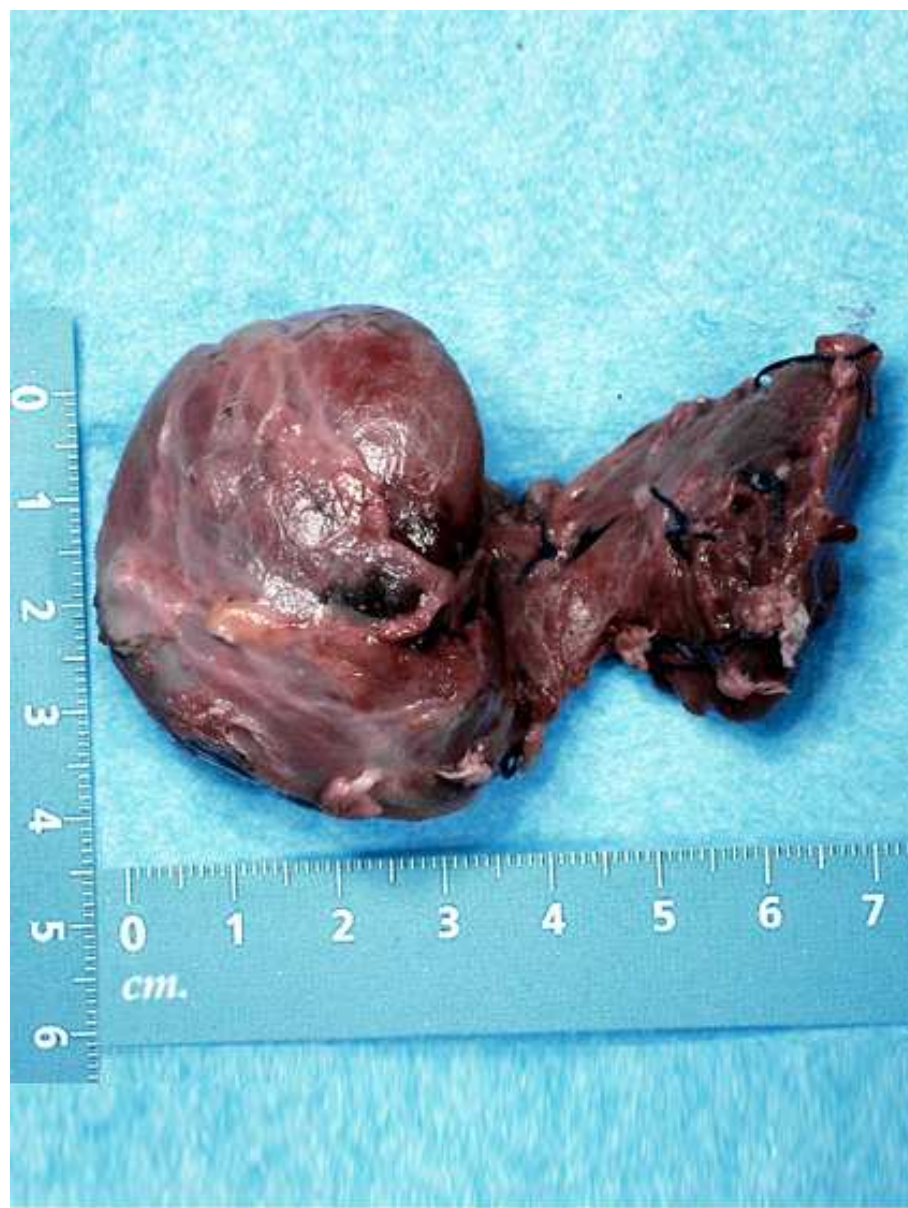

Isolamento delle arterie tiroidee inferiori e dei nervi laringei inferiori (ricorrenti)

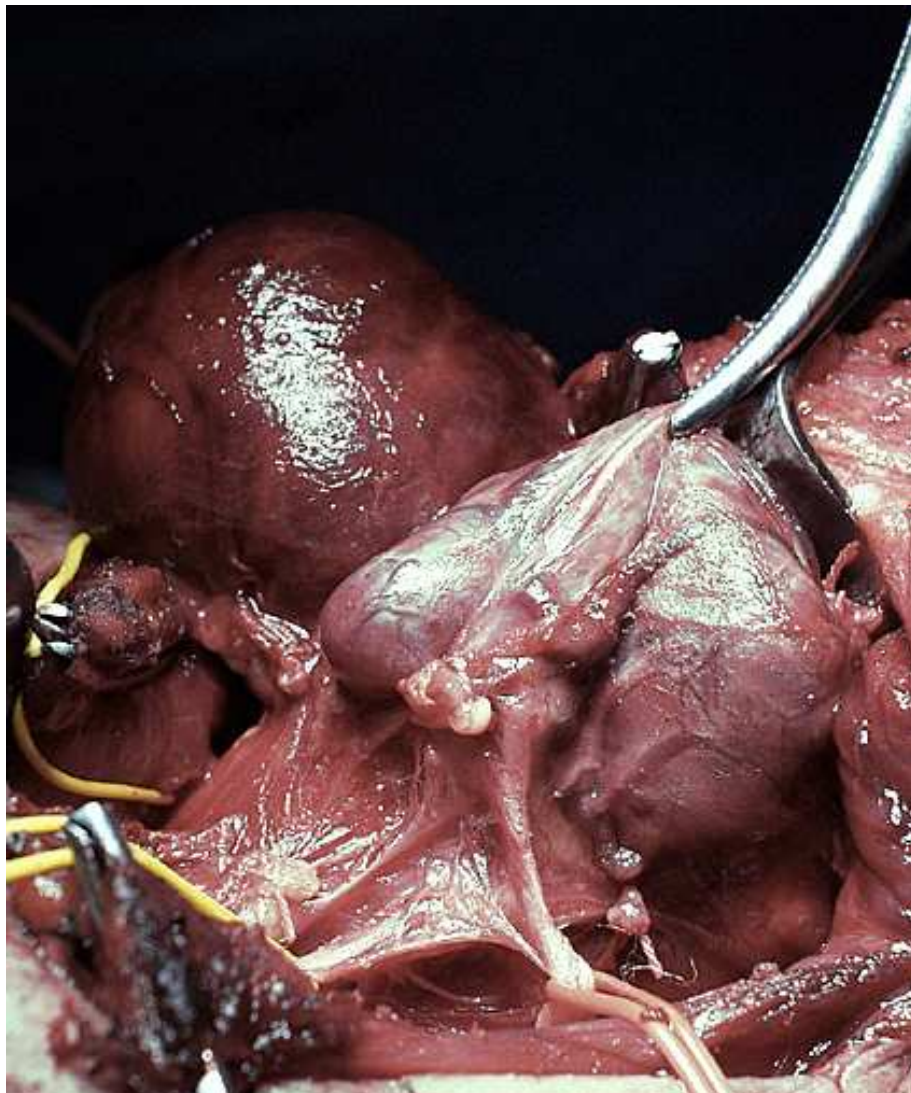




Lobo destro - Istmo - Lobo sinistro (superficie anteriore)

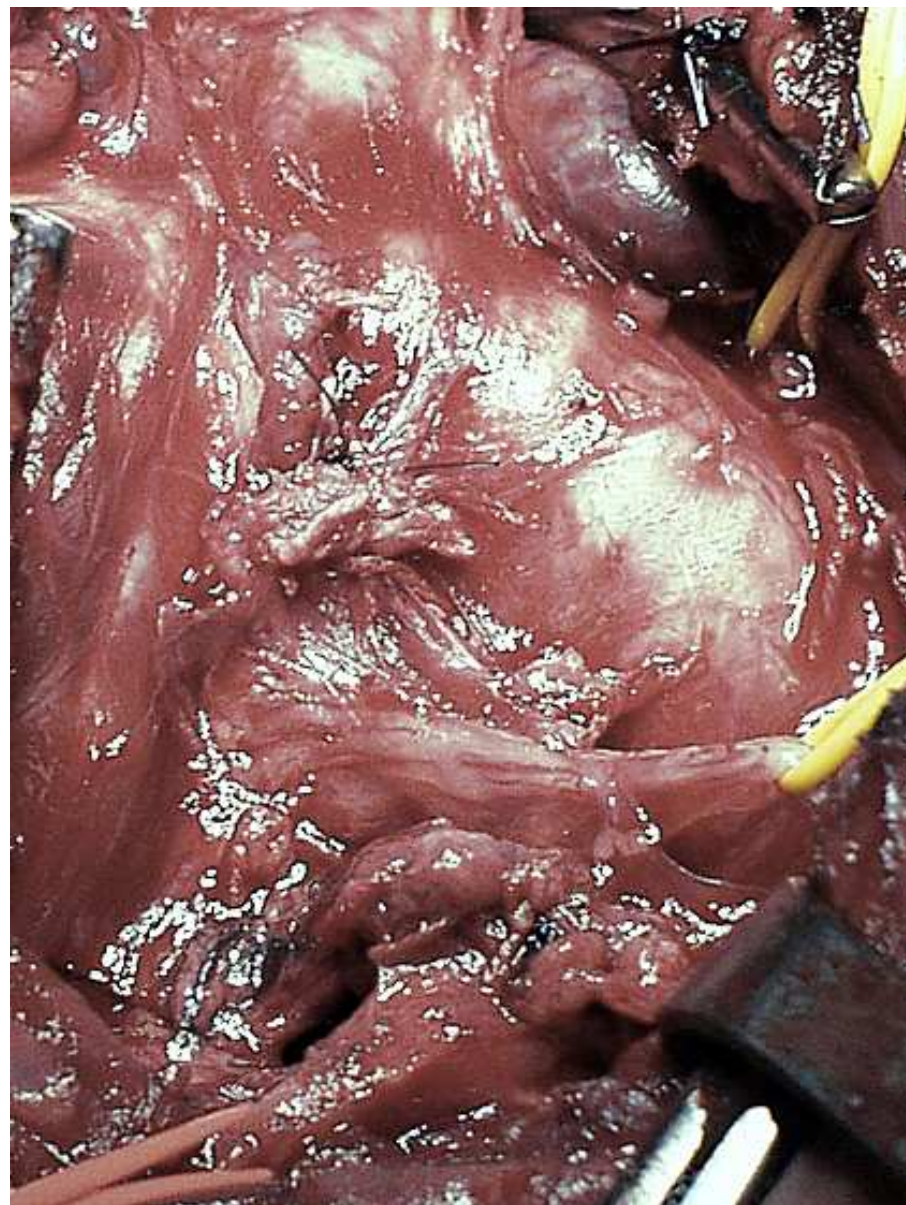

Lobo sinistro - Istmo - Lobo destro (superficie posteriore)

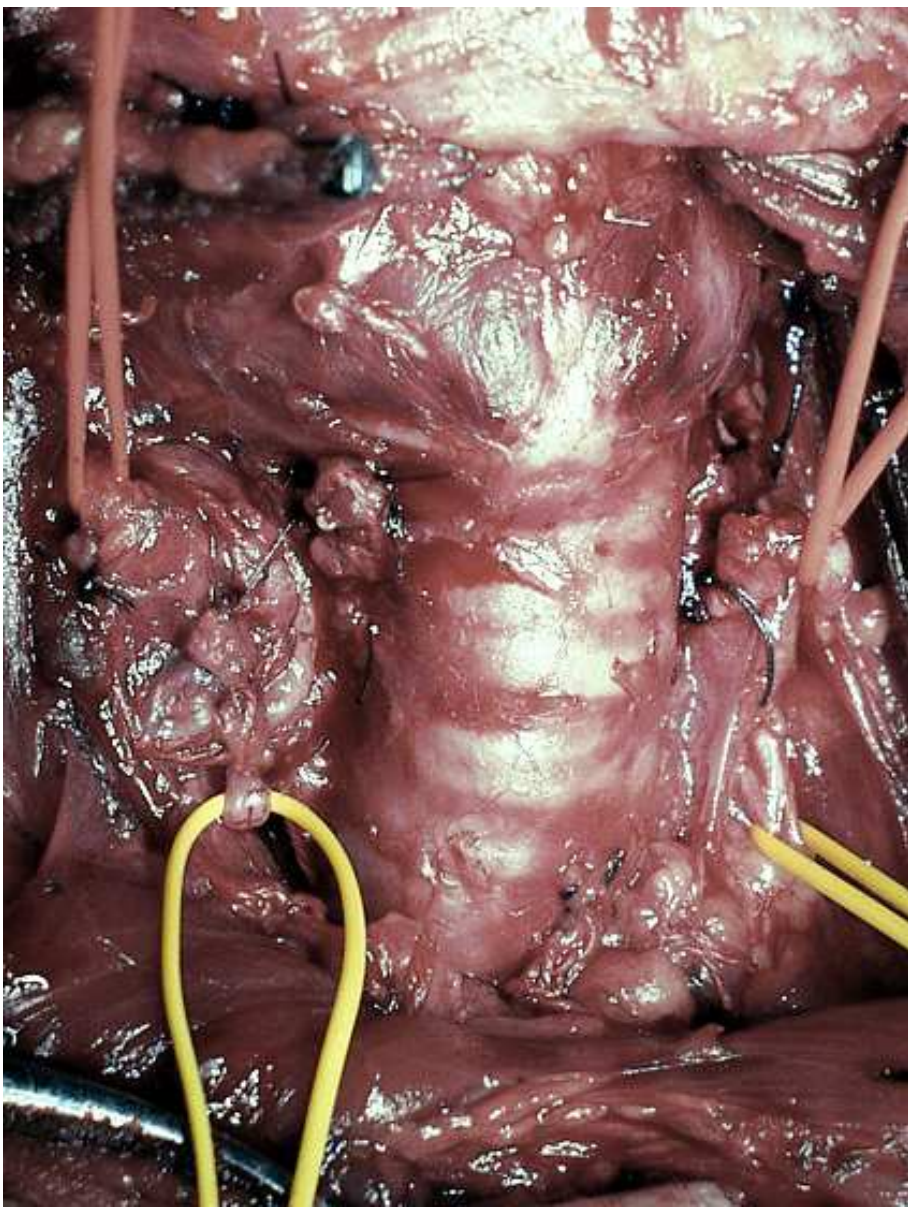


I.S. • Anni: 53 - M • Record: 10 • 10-10-2001

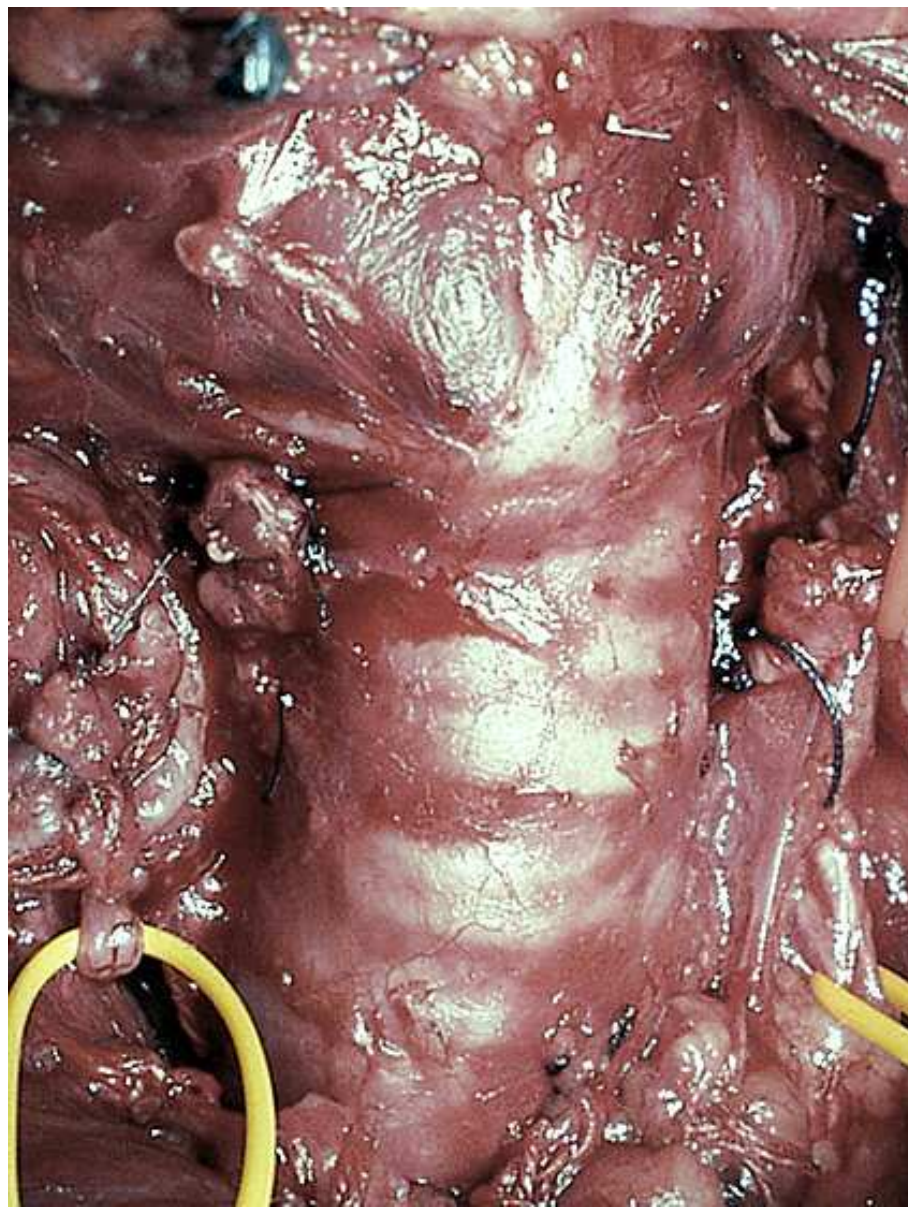
Tiroidectomia totale extracapsulare per gozzo plurinodulare tossico plongeant a dx



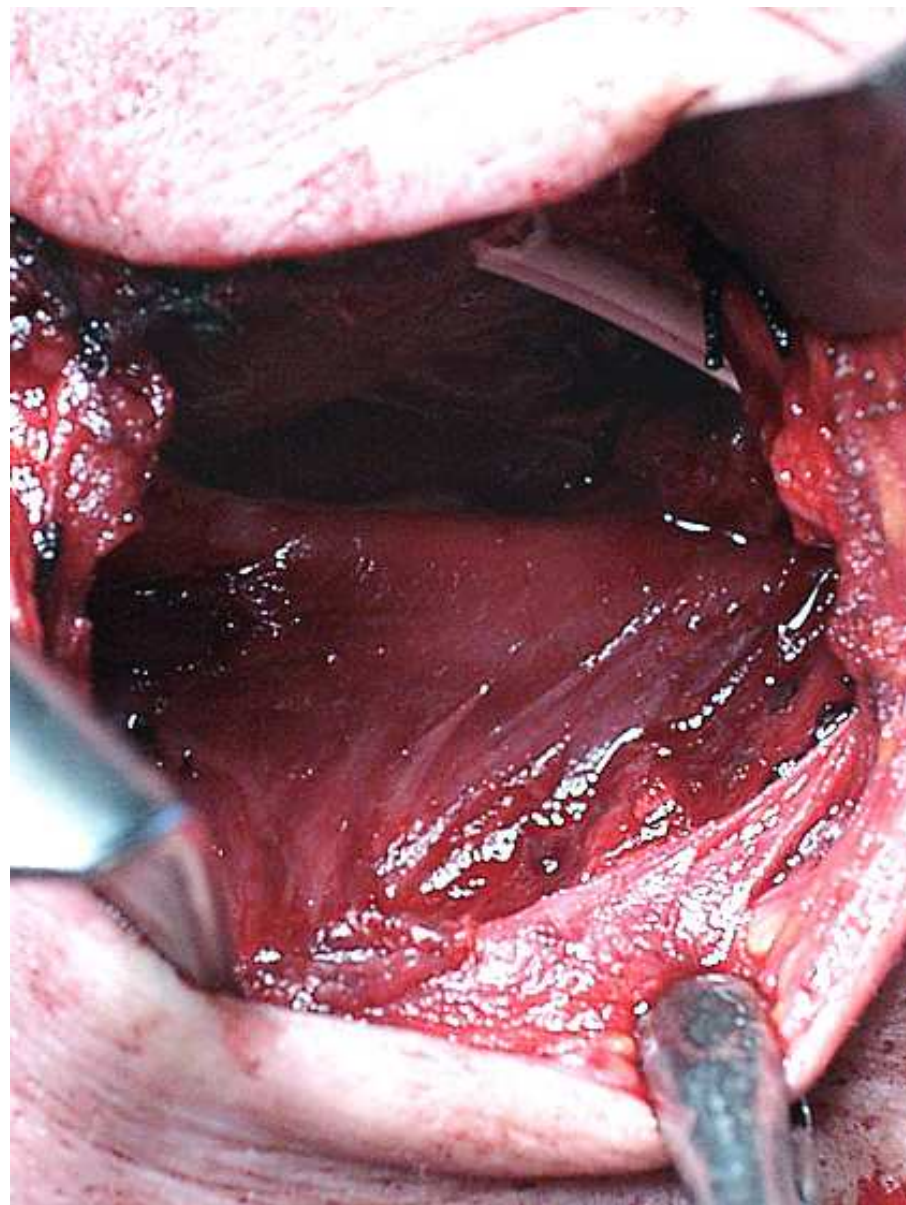
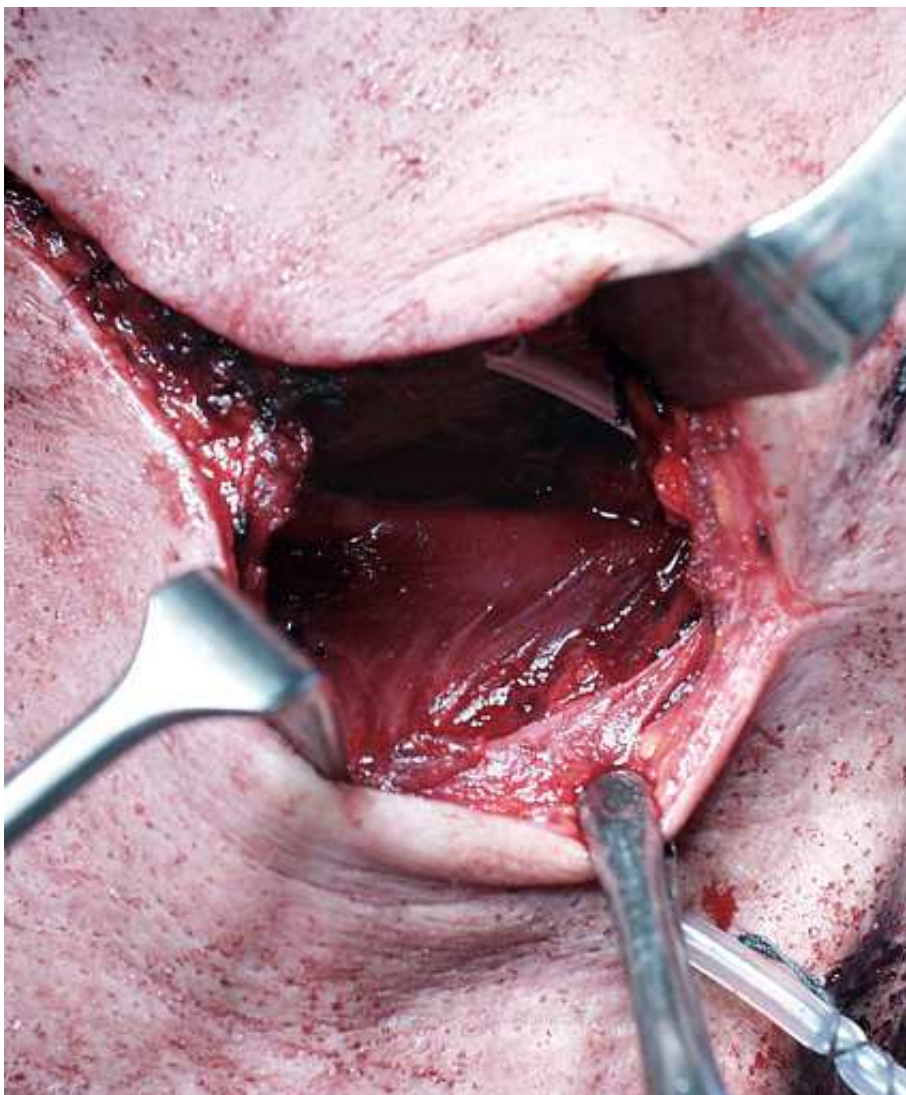
Isolamento dell'arteria tiroidea inferiore dx e del nervo laringeo inferiore dx



Isolamento delle arterie tiroidee inferiori e dei nervi laringei inferiori (ricorrenti)

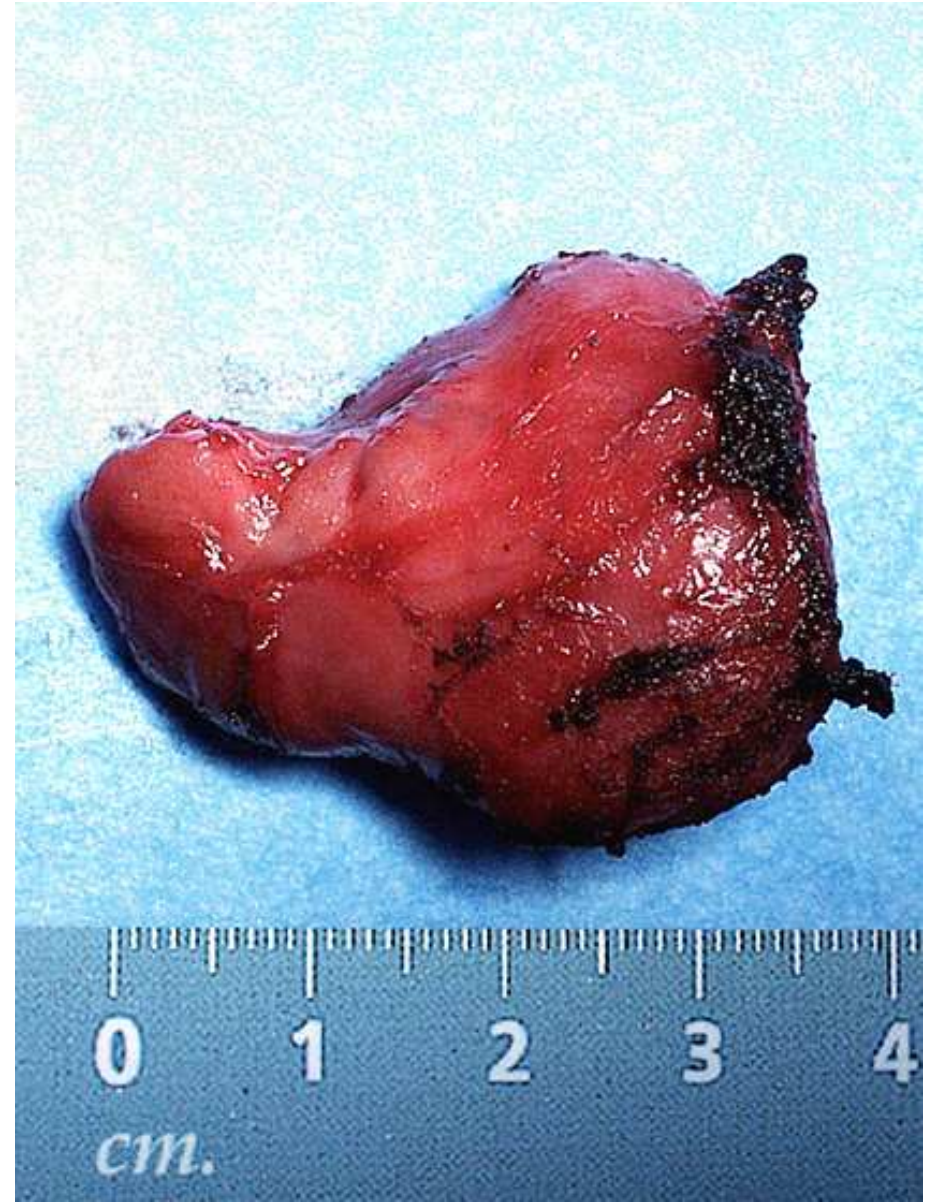
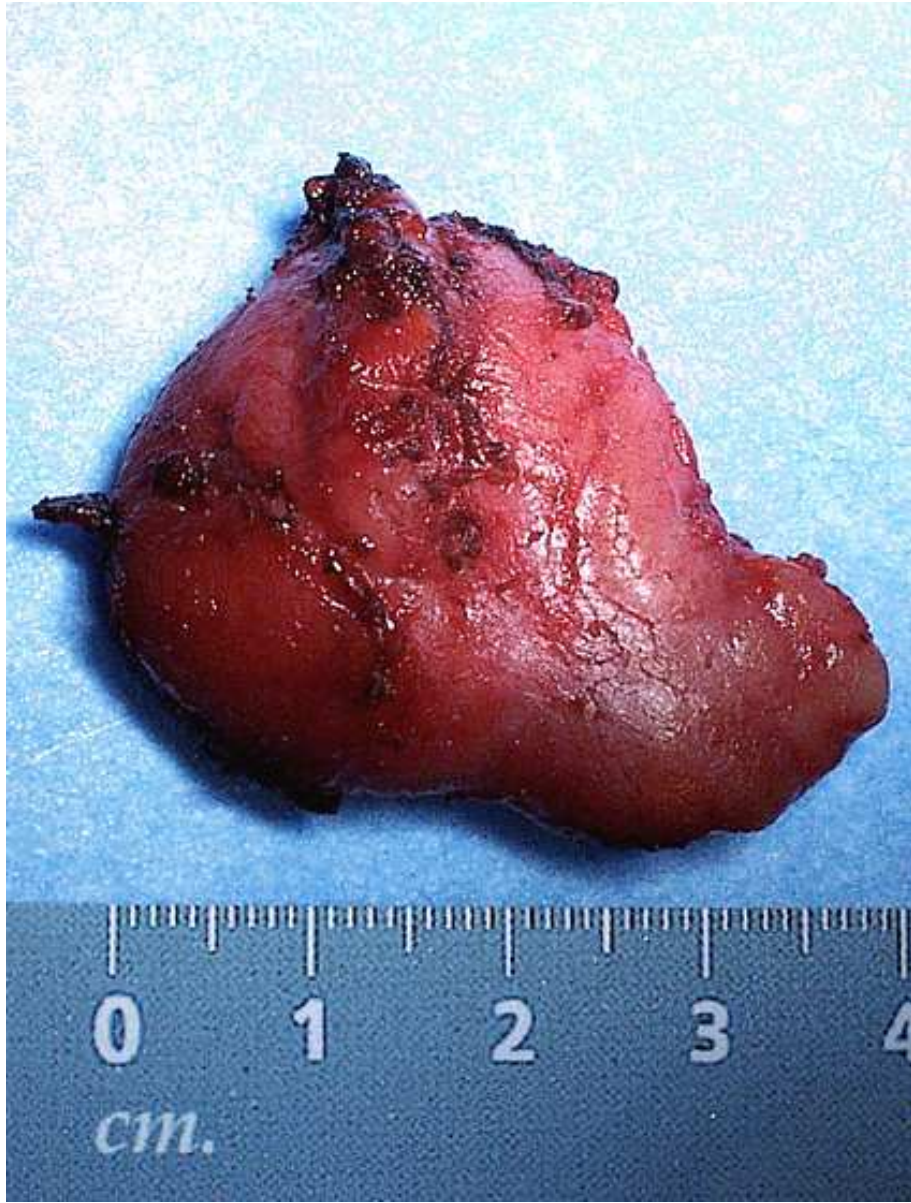

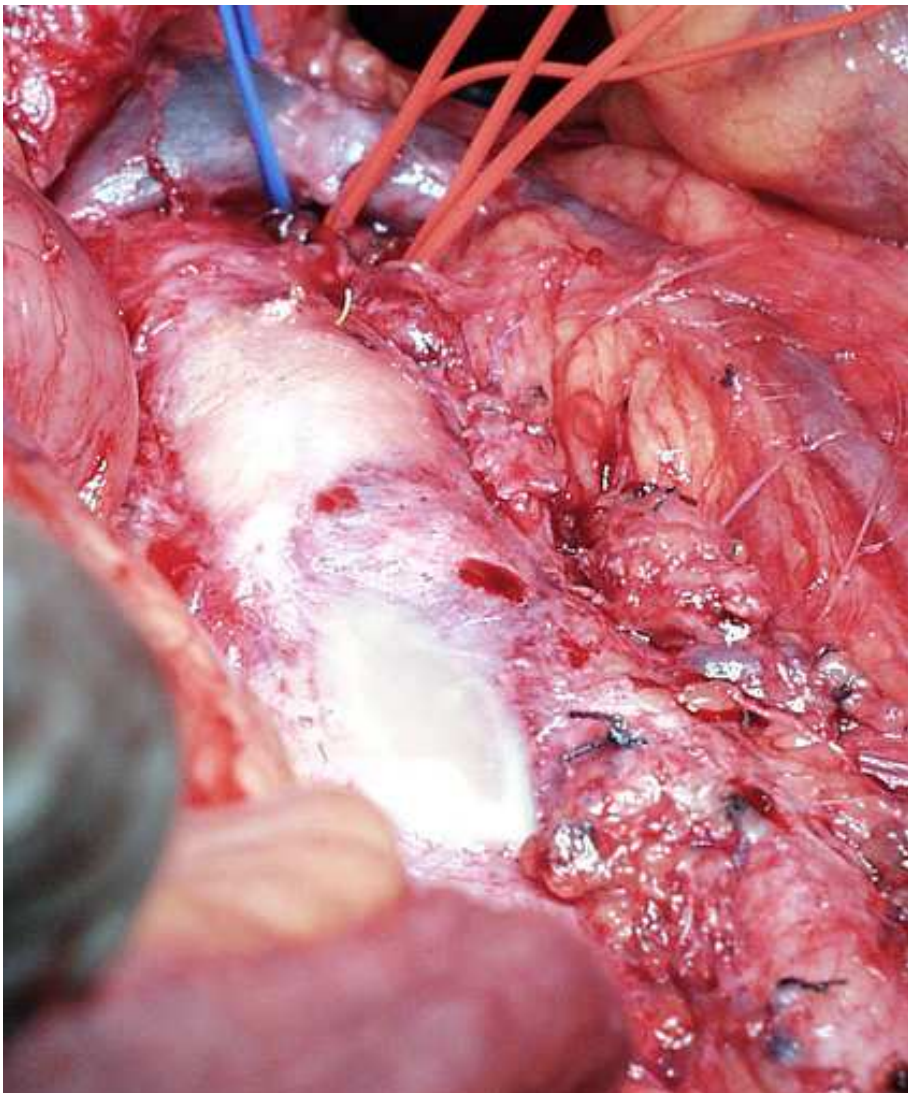
Isolamento dei nervi laringei inferiori (ricorrenti)



I.D. • Anni: 68 - M • Record: 11 • 12-10-2001

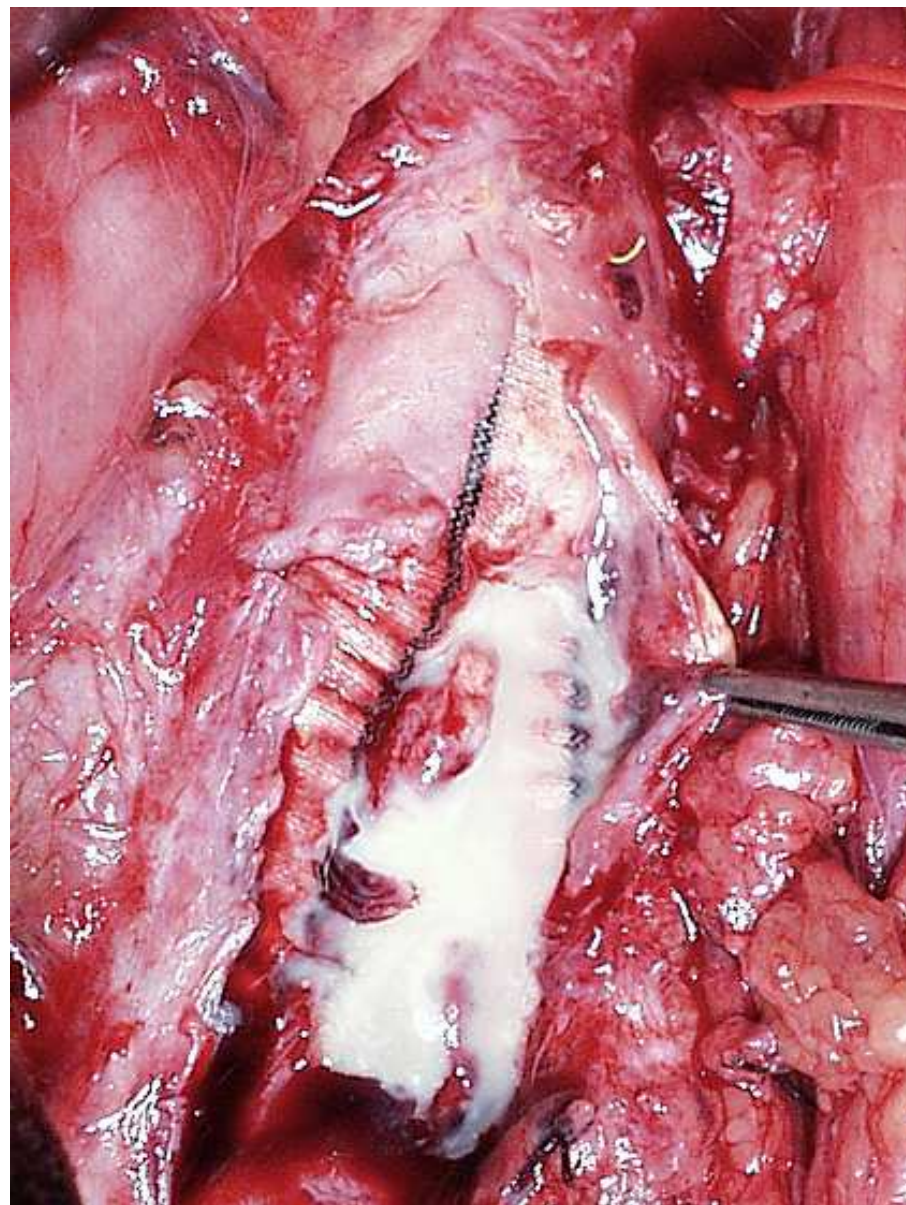
Asportazione ghiandola sottomandibolare sn per scialodochite litiasica

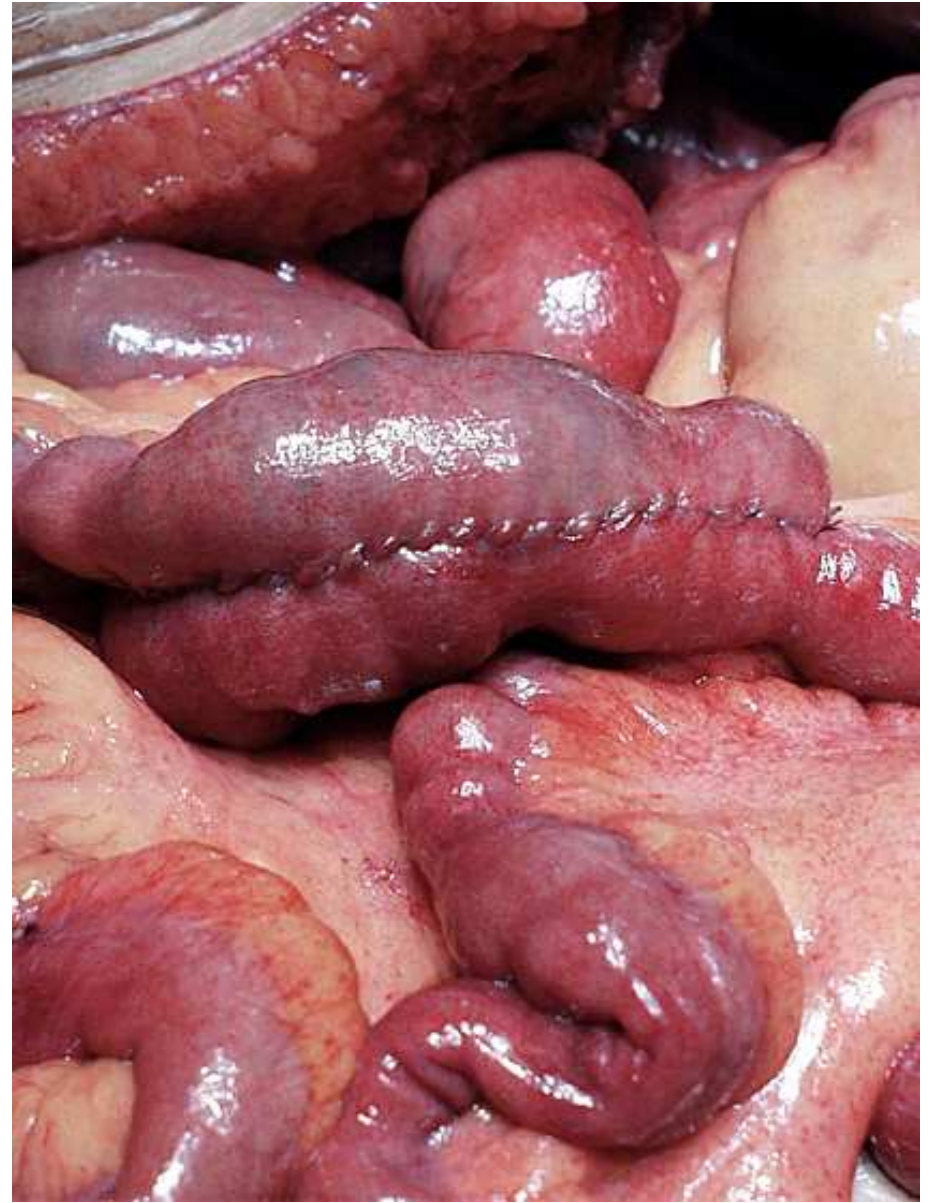
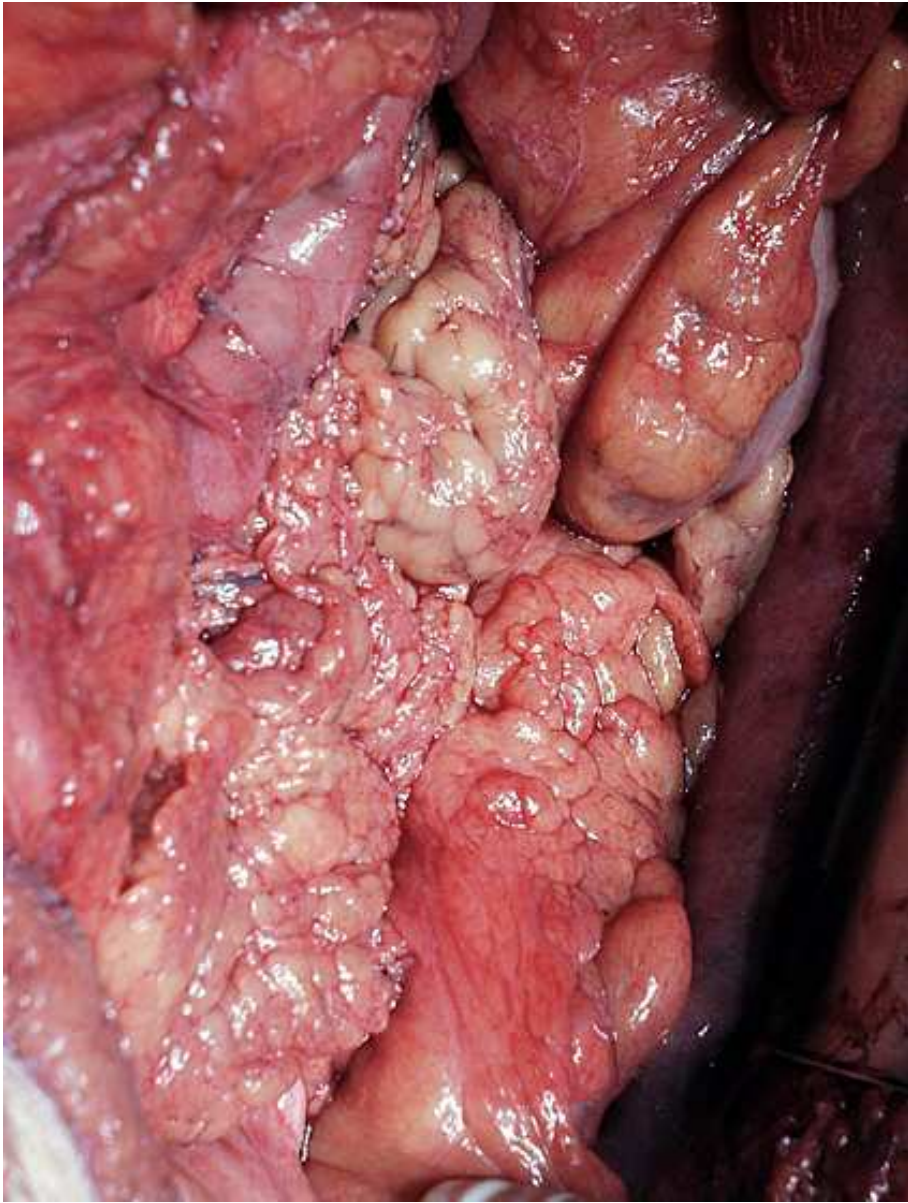


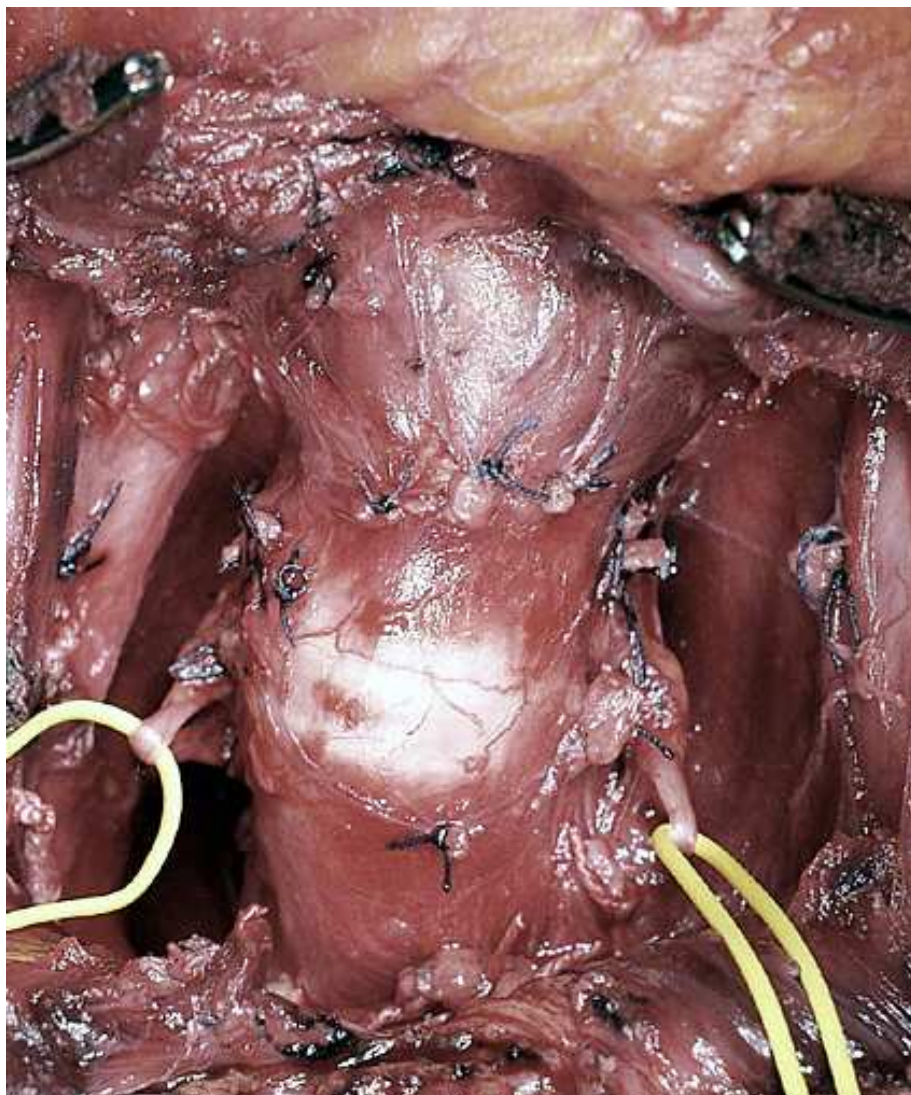


B.N. • Anni: 57 - F • Record: 12 • 17-10-2001

Epiploonplastica transmesocolica e resezione digiunale in corso di rimozione e reimpianto di by-pass aortobifemorale per infezione protesica

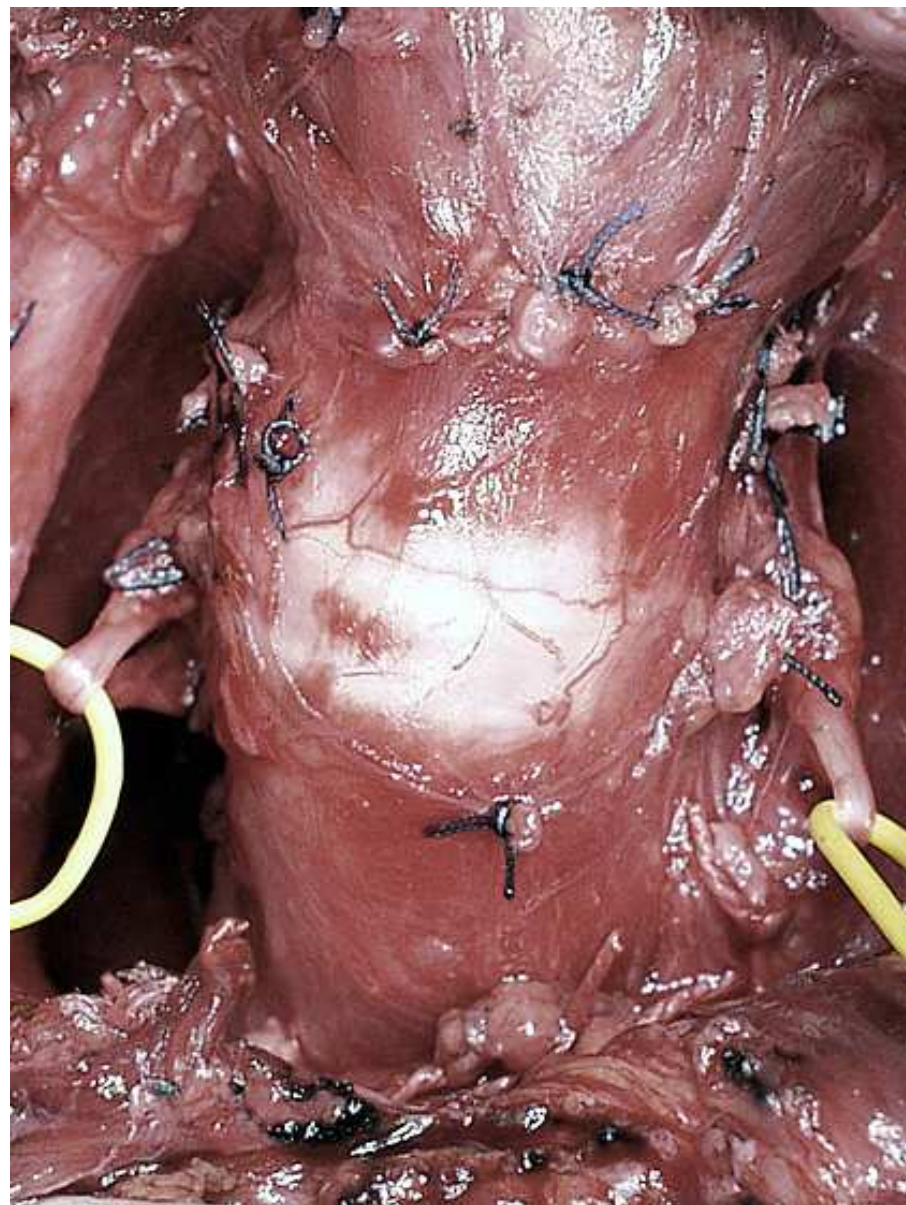






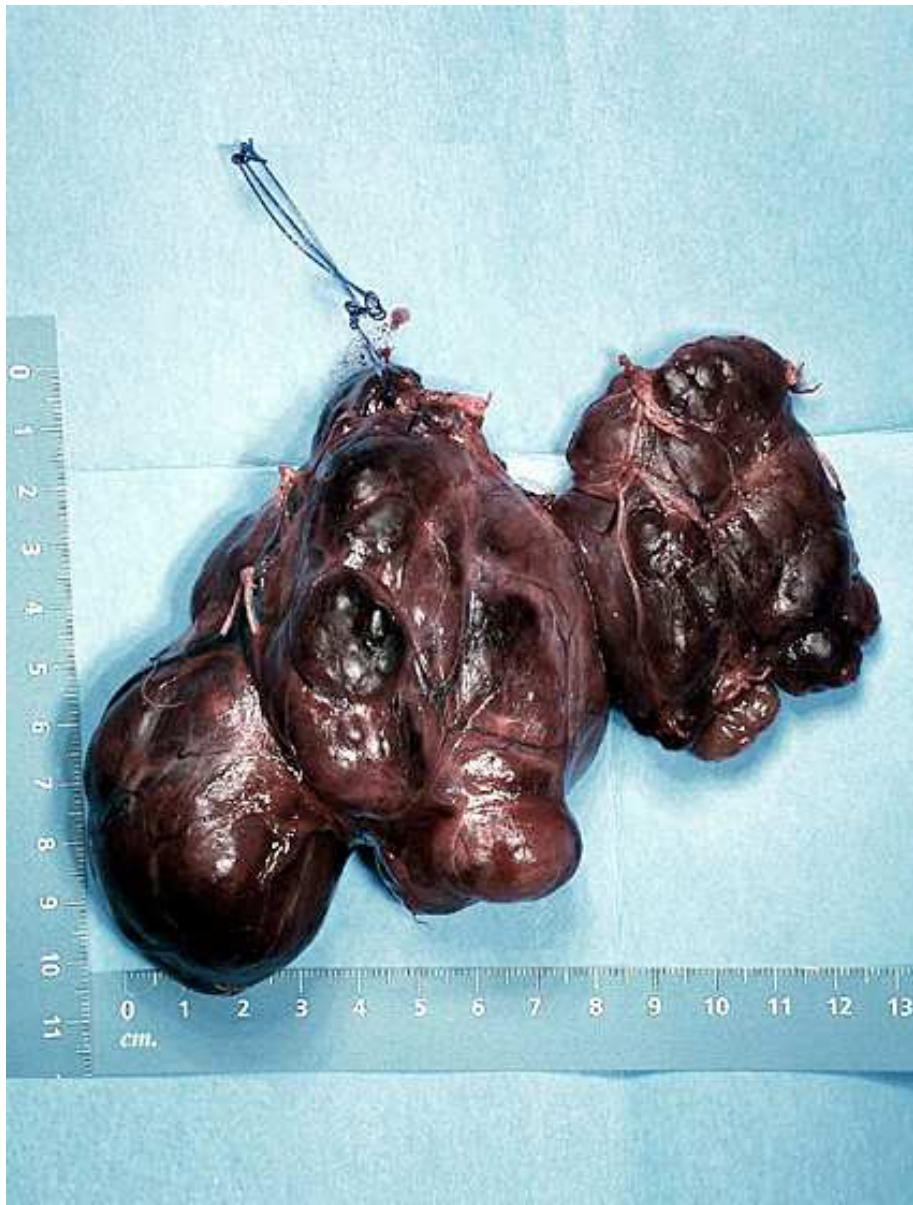C.M. • Anni: 61 - F • Record: 13 • 19-10-2001

Tiroidectomia totale extracapsulare per gozzo plurinodulare tossico plongeant a dx

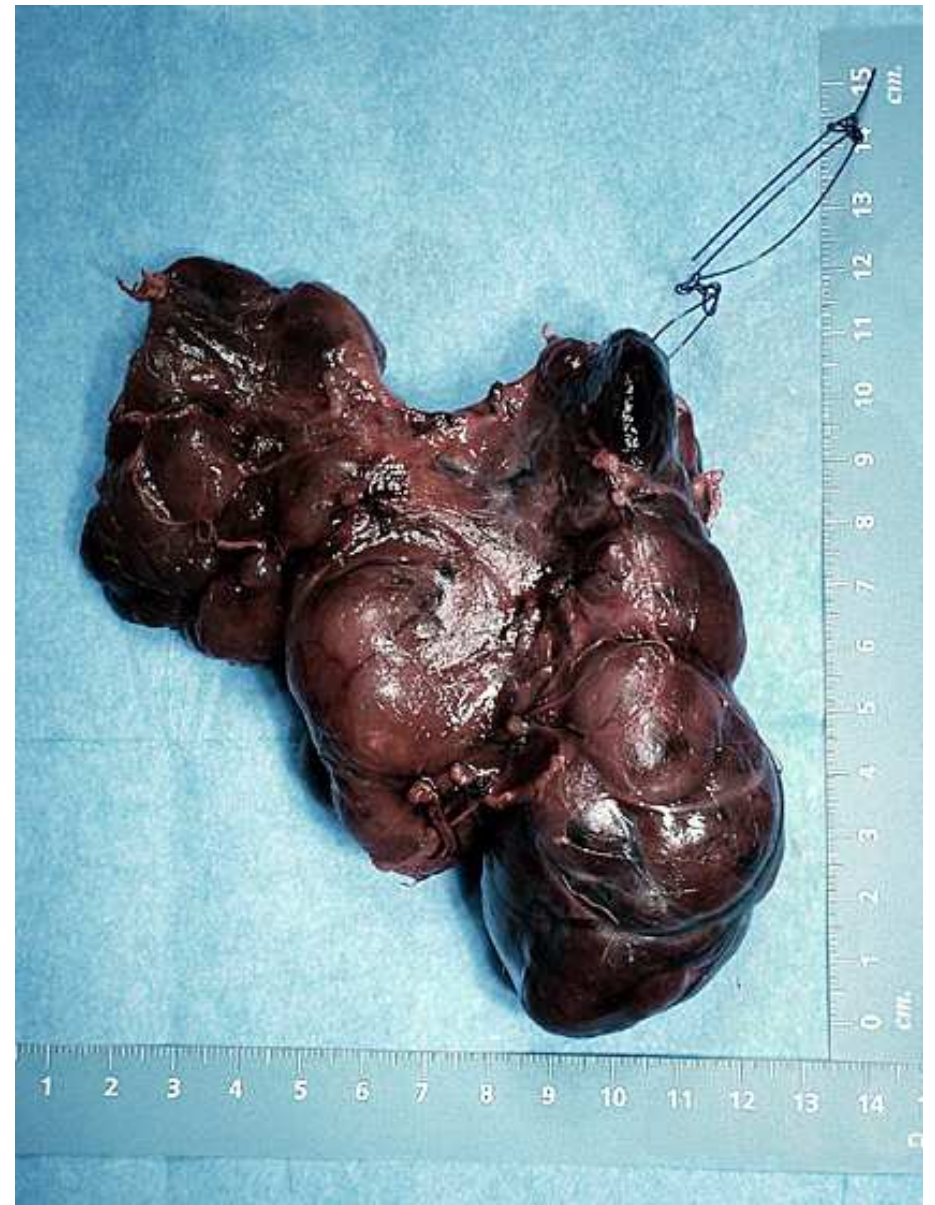


Isolamento dei nervi laringei inferiori (ricorrenti)

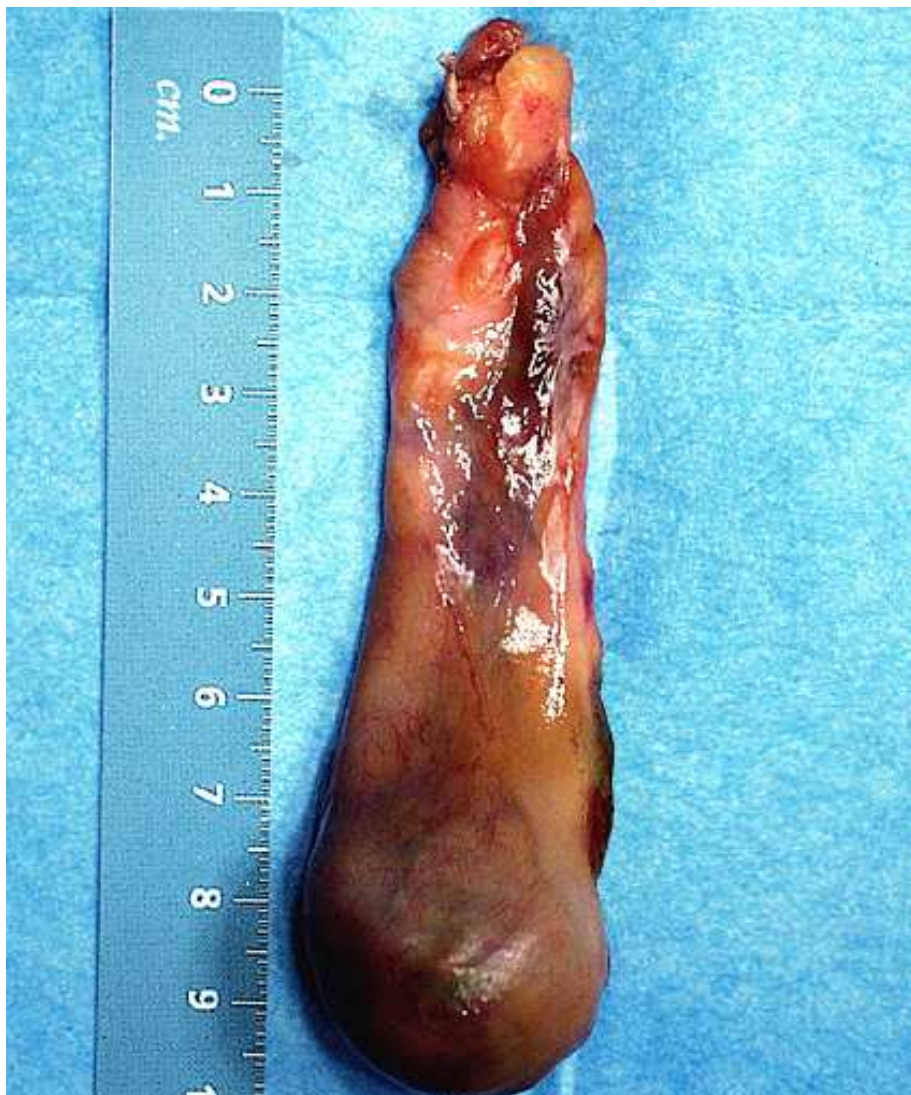



Lobo destro - Istmo - Lobo sinistro (superficie anteriore)

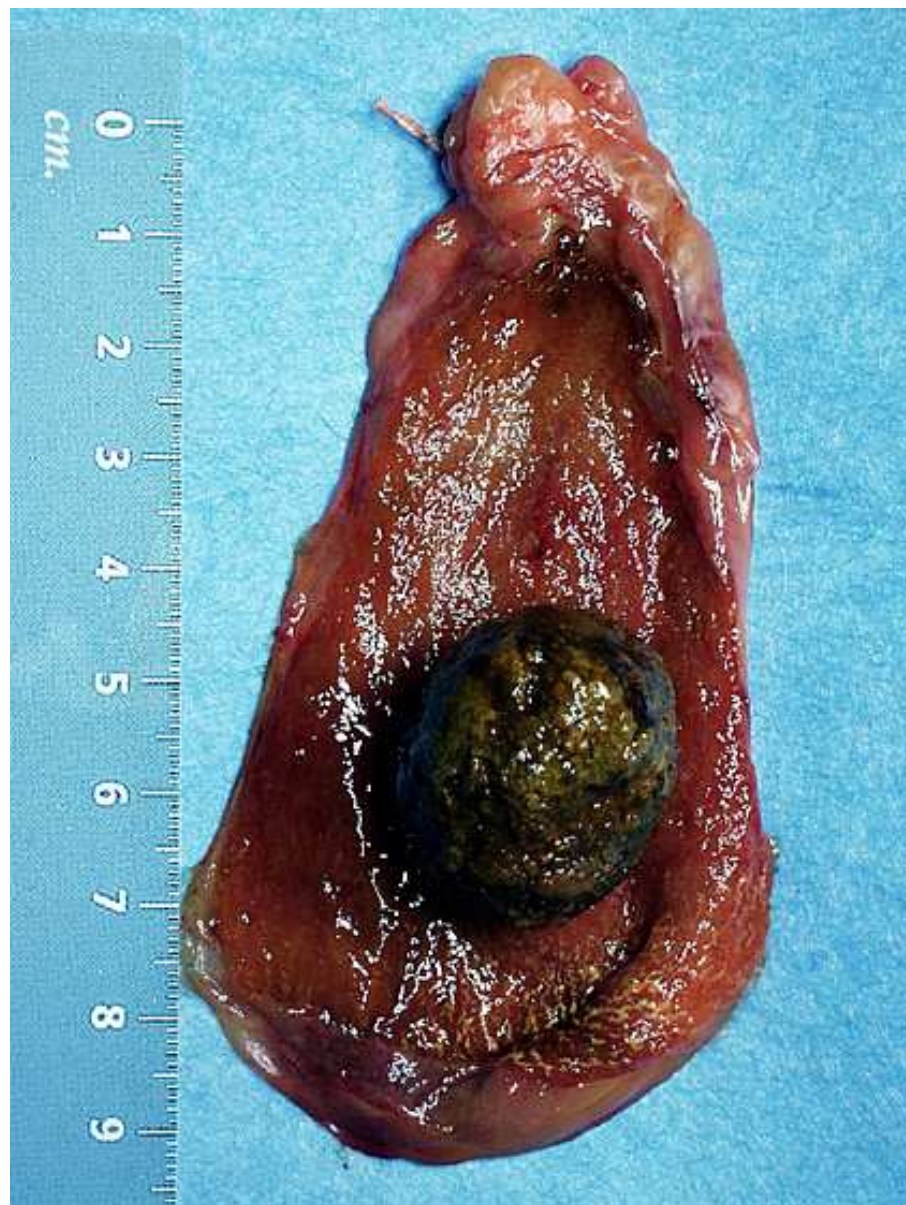

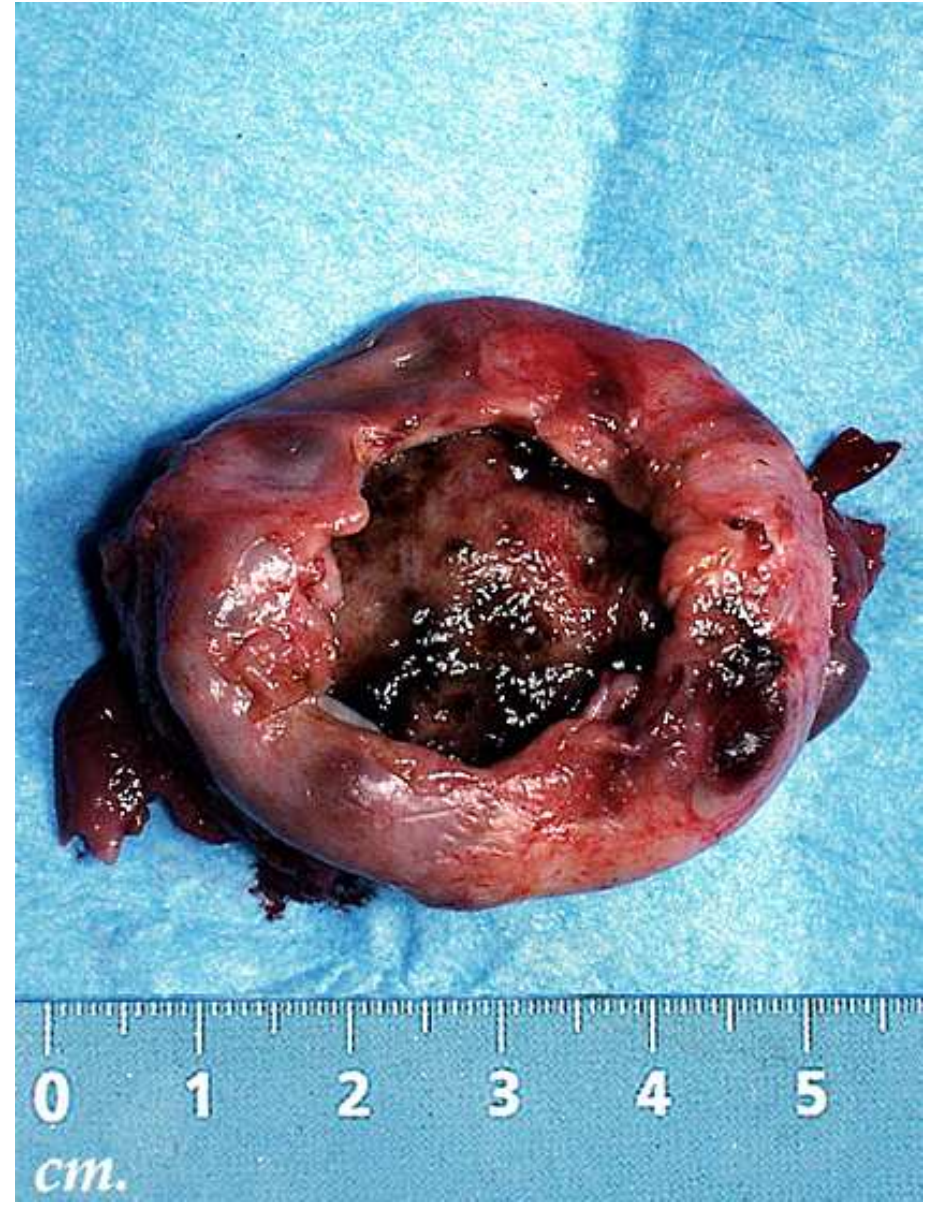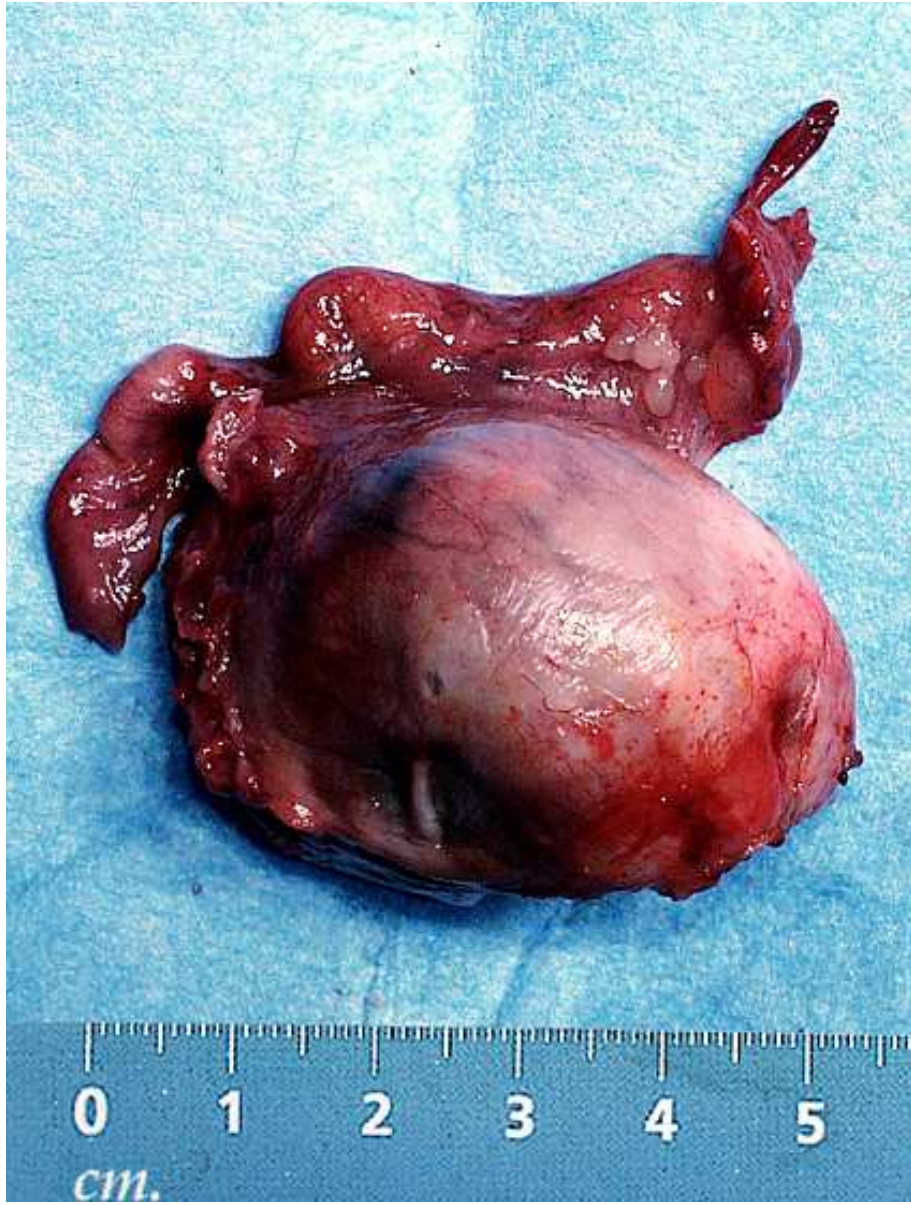
Lobo sinistro - Istmo - Lobo destro (superficie posteriore)

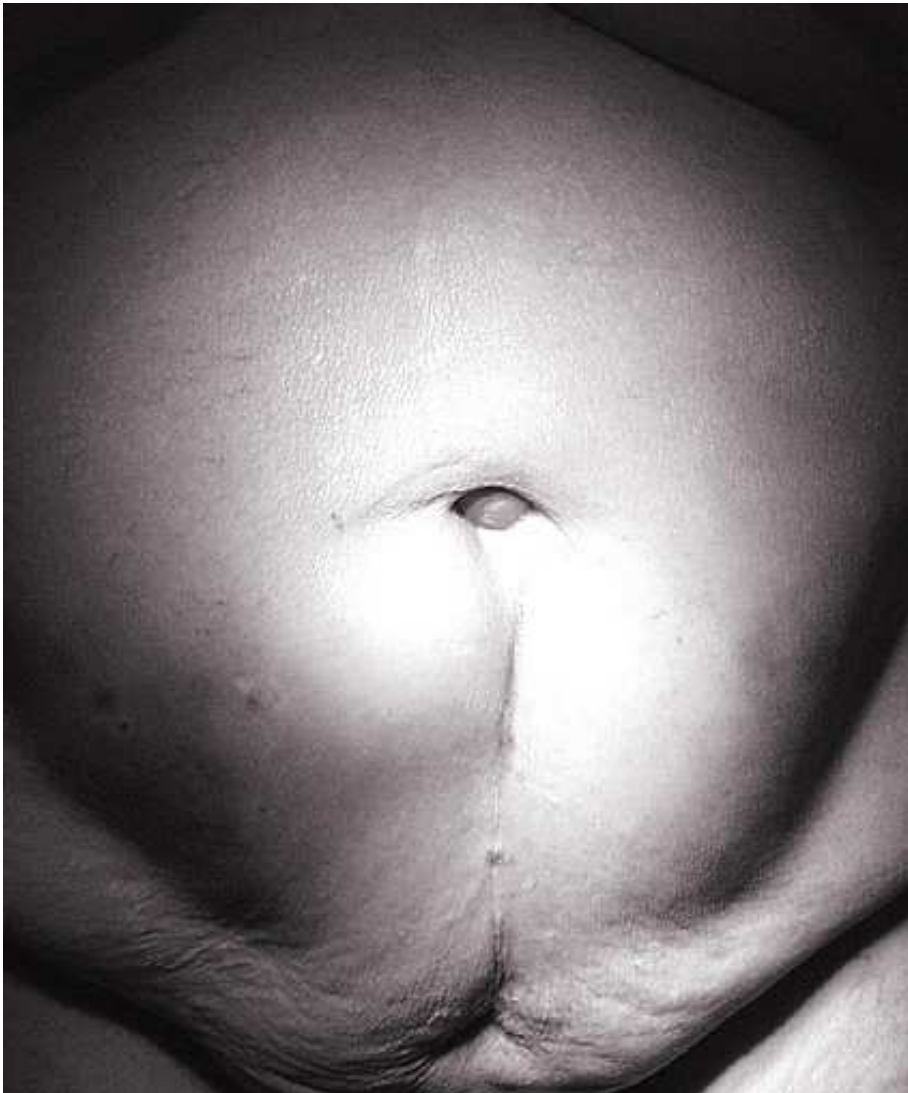

M.M. • Anni: 47 - F • Record: 14 • 07-11-2001

Colecistectomia ed annessectomia dx per litiasi ed endometriosi ovarica cistica

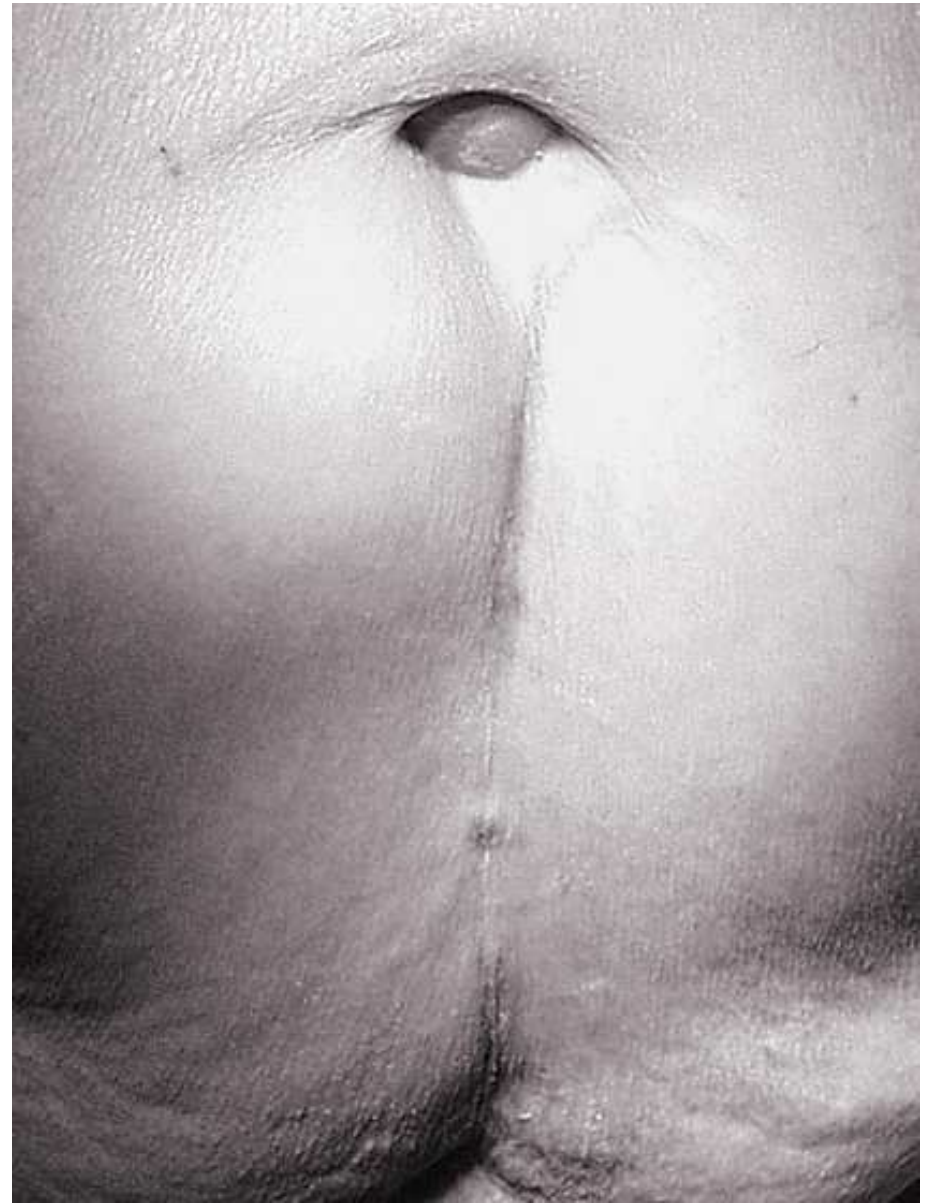

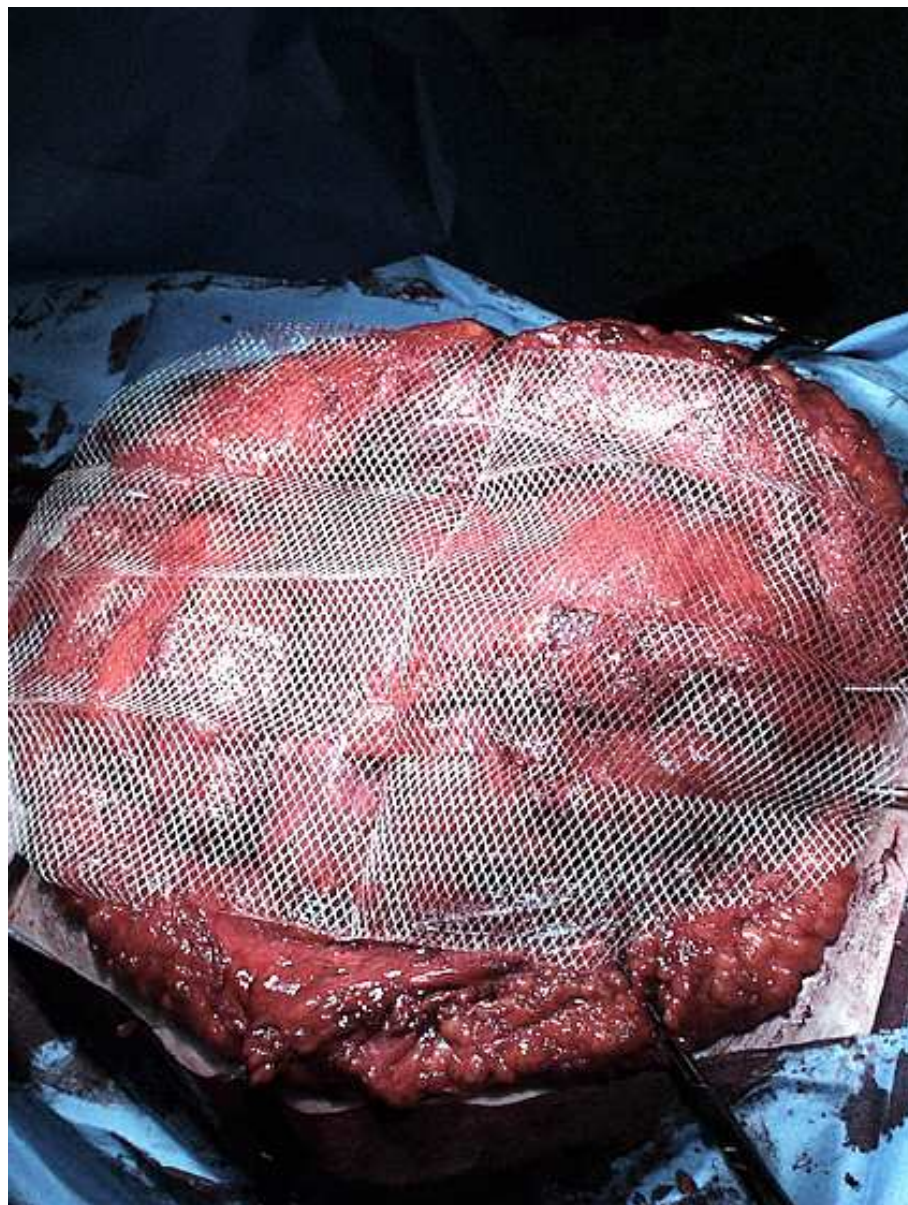

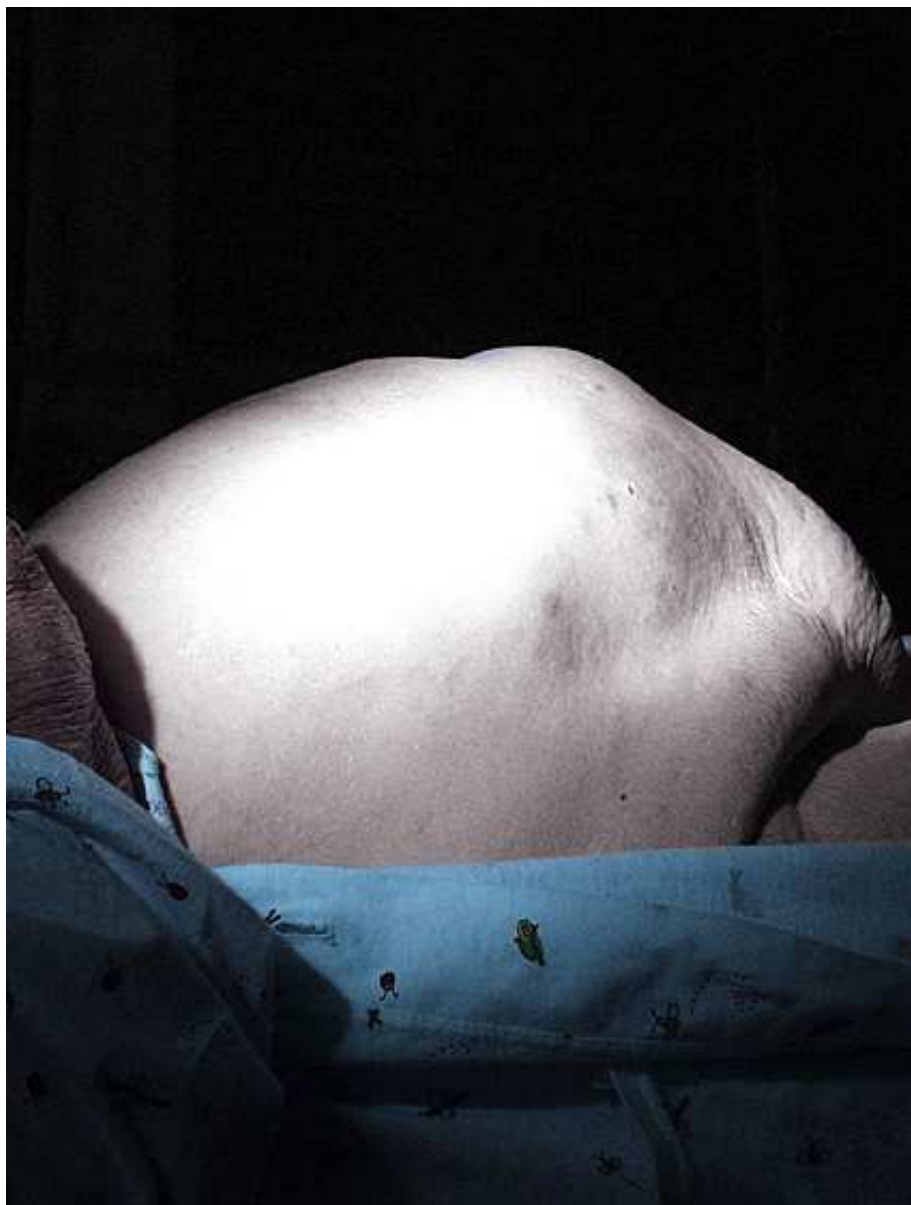


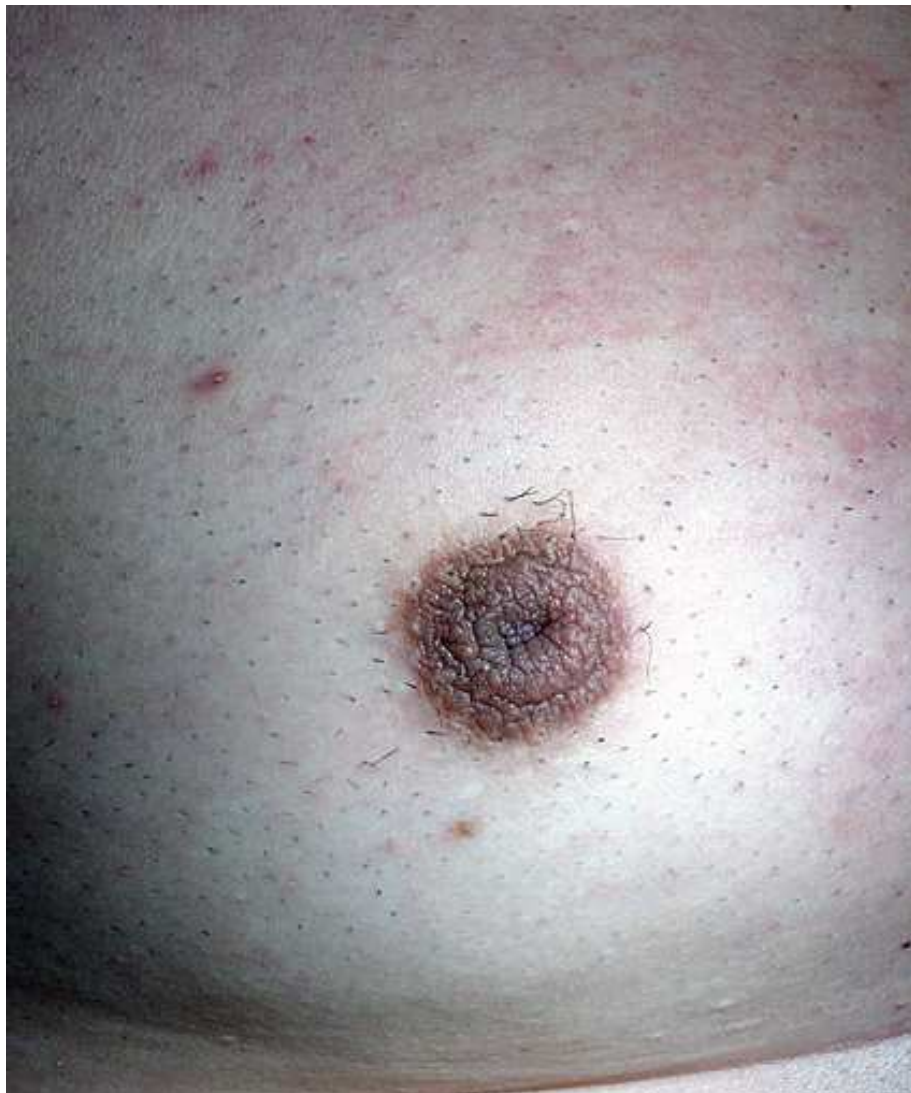H.M. • Anni: 79 - F • Record: 15 • 03-12-2001

Laparoaloplastica per laparocèle mediana in plurilaparatomizzata

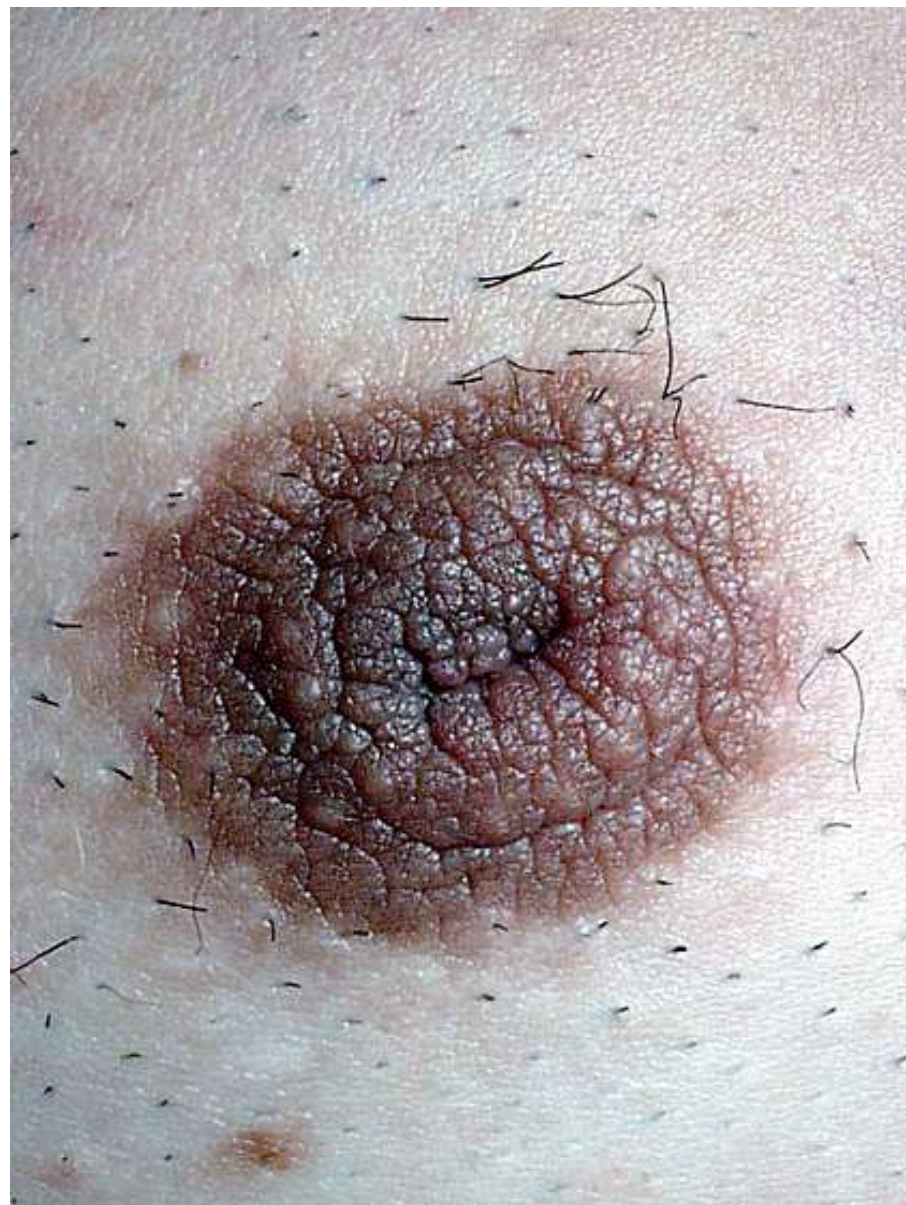

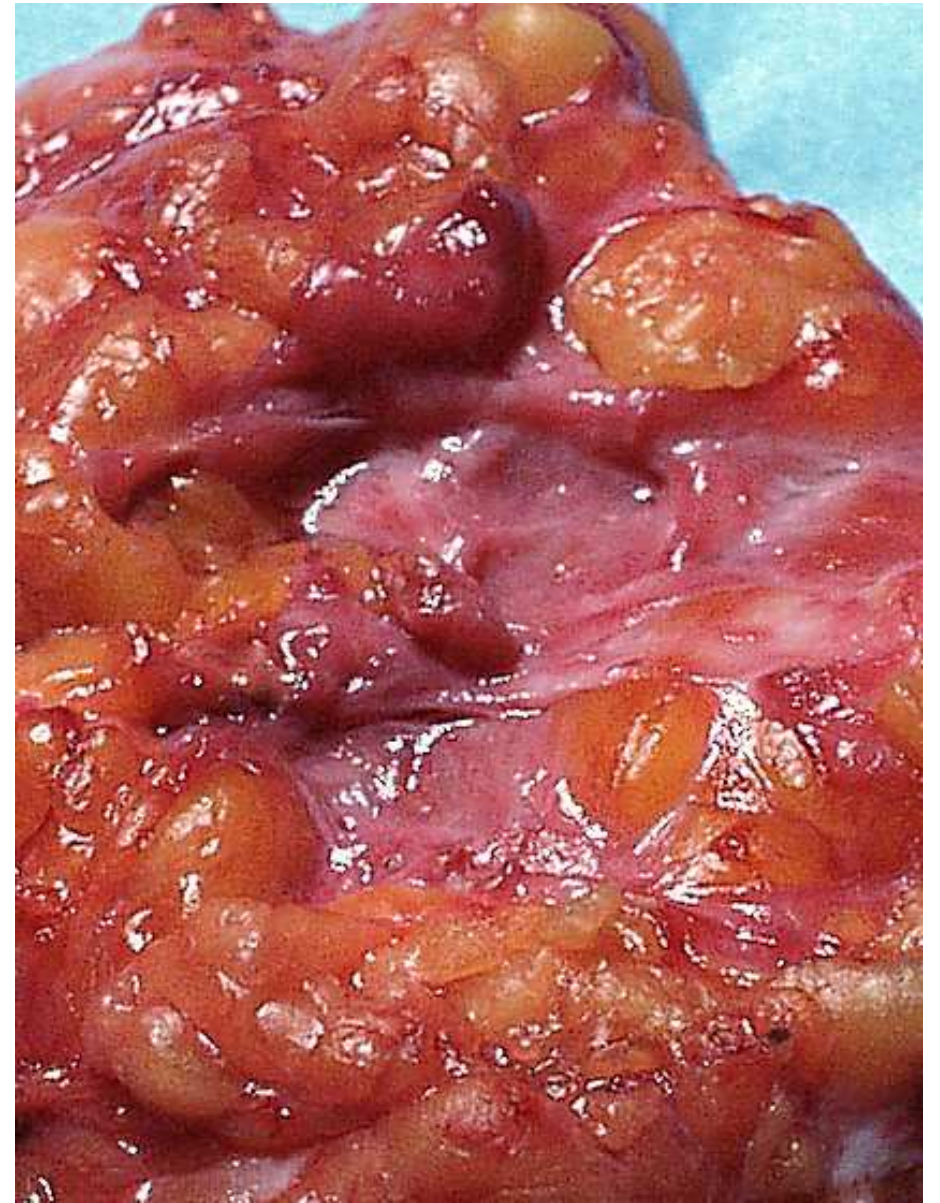

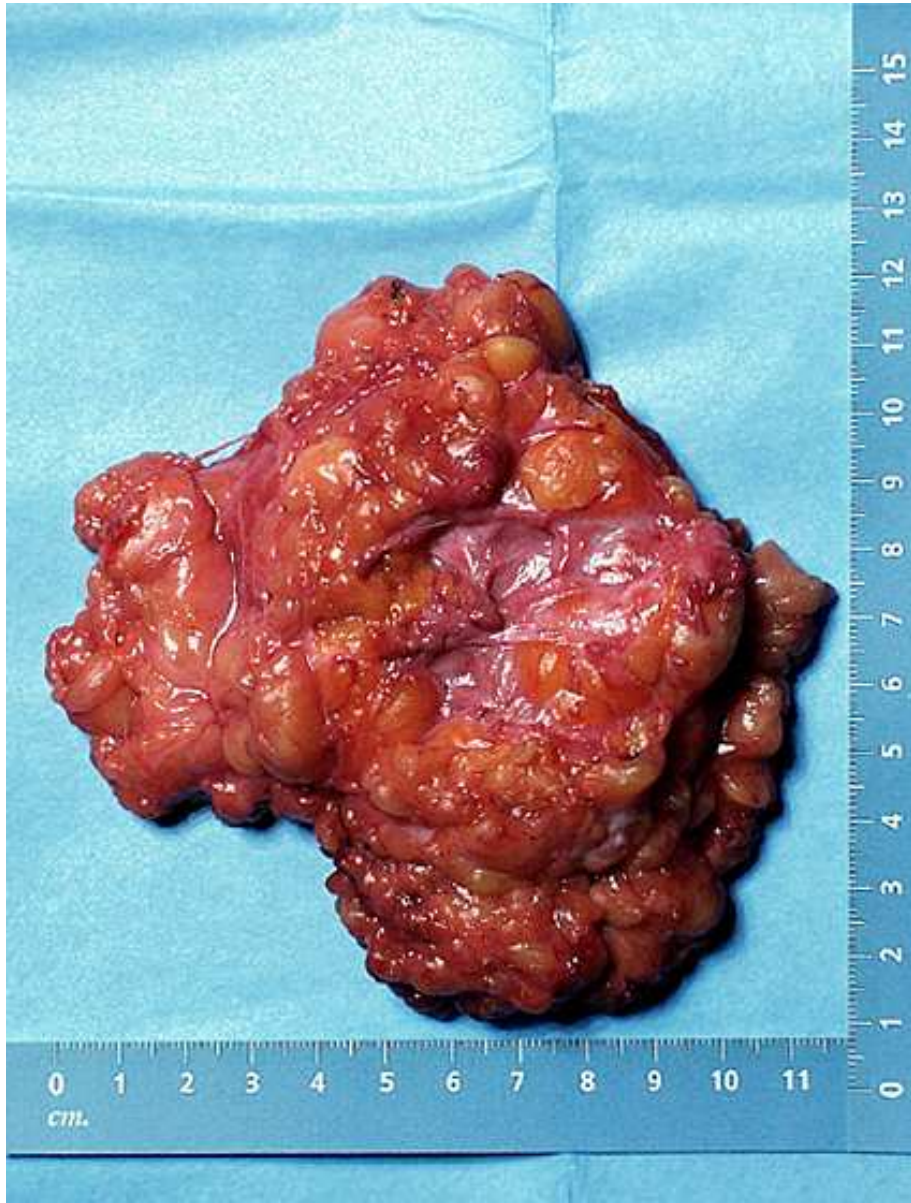
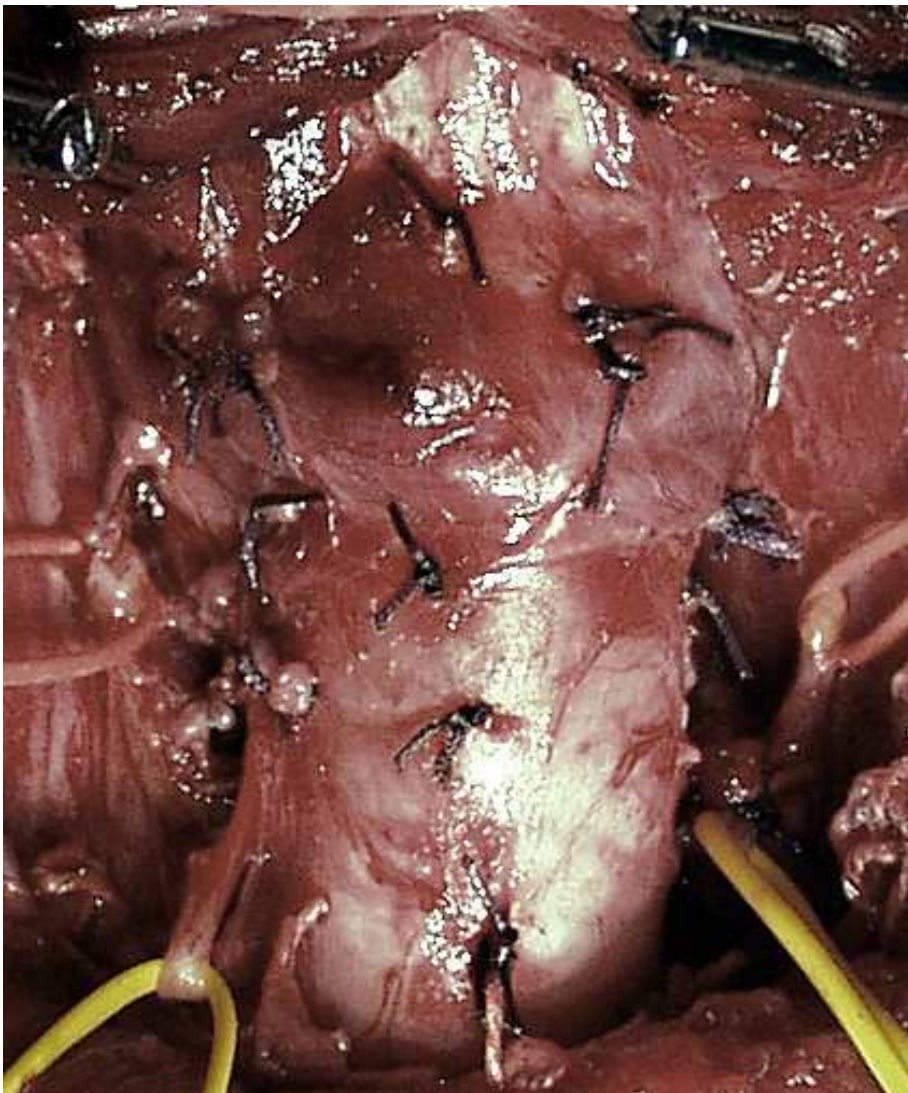


P.E. • Anni: 36 - M • Record: 16 • 07-12-2001

Mastectomia sottocutanea (adenomammectomia) a dx per ascesso retroareolare e di Zuska

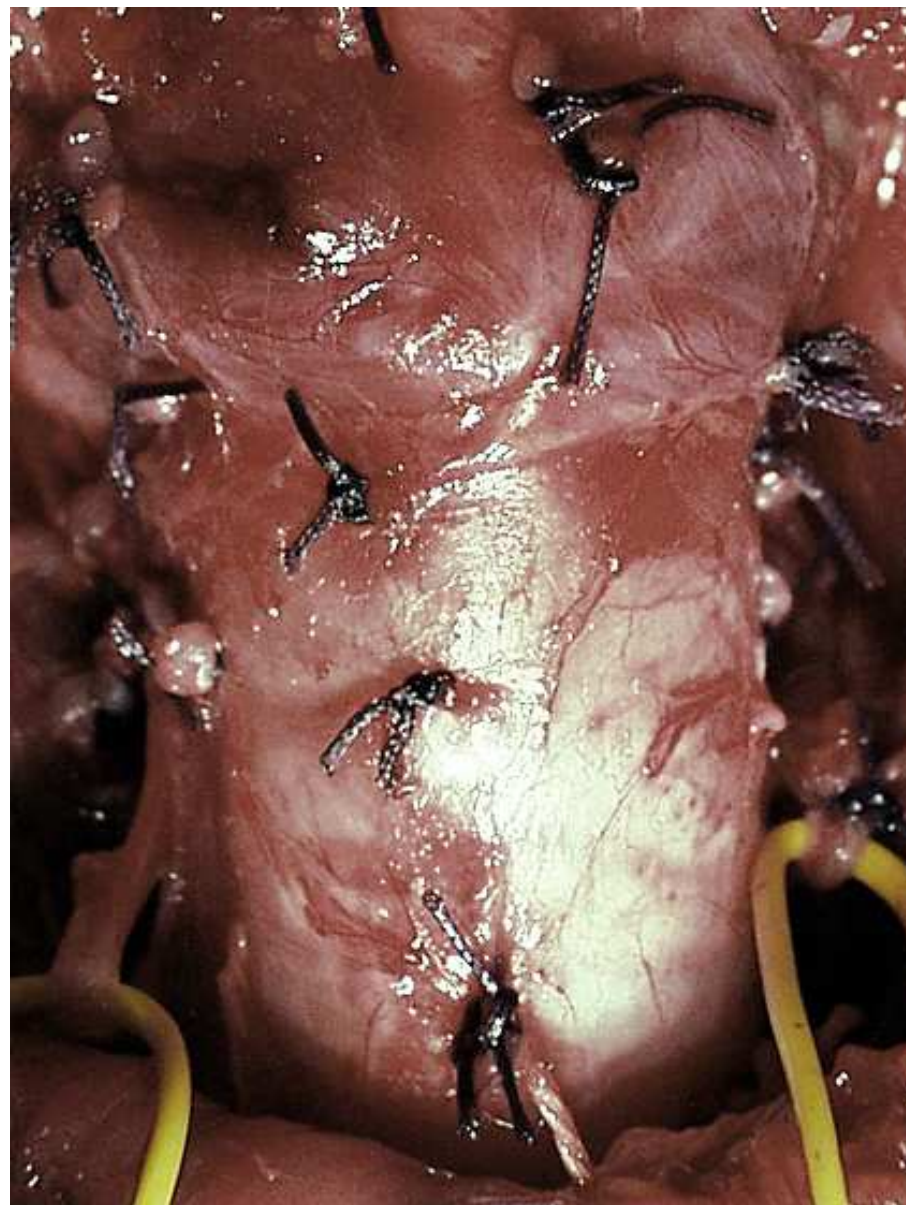





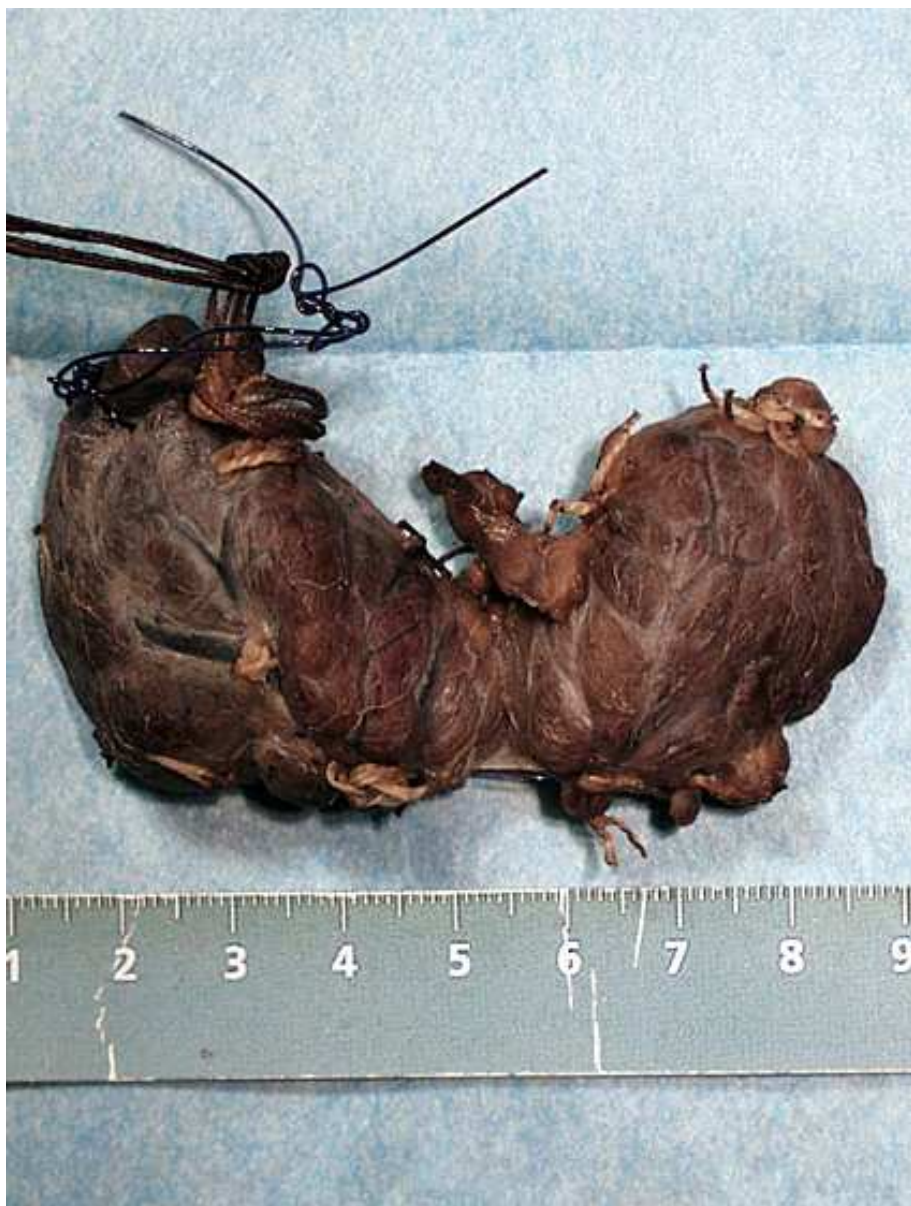A.S. · Anni: 36 - F · Record: 17 · 09-01-2002

Tiroidectomia totale extracapsulare per gozzo plurinodulare basedowizzato

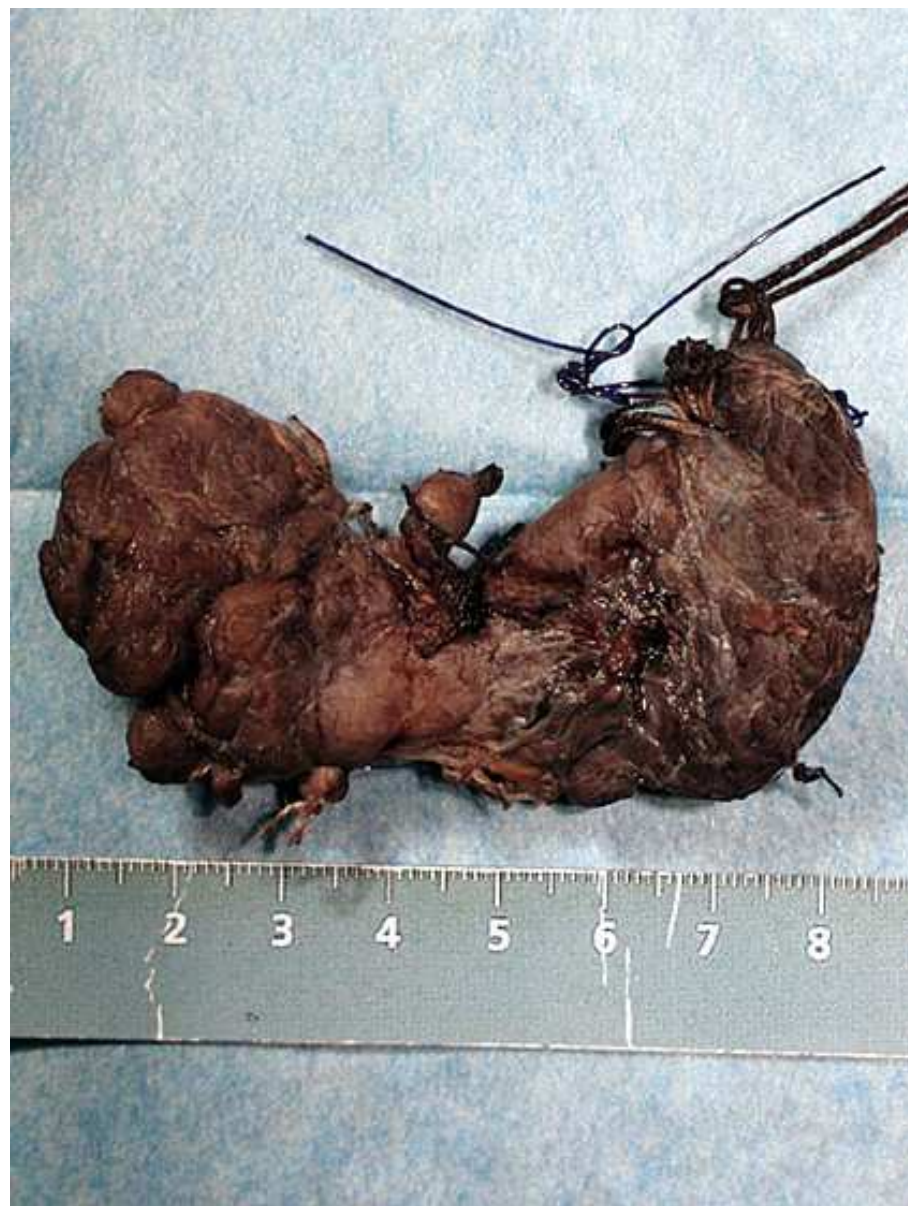

Isolamento dei nervi laringei inferiori (ricorrenti)

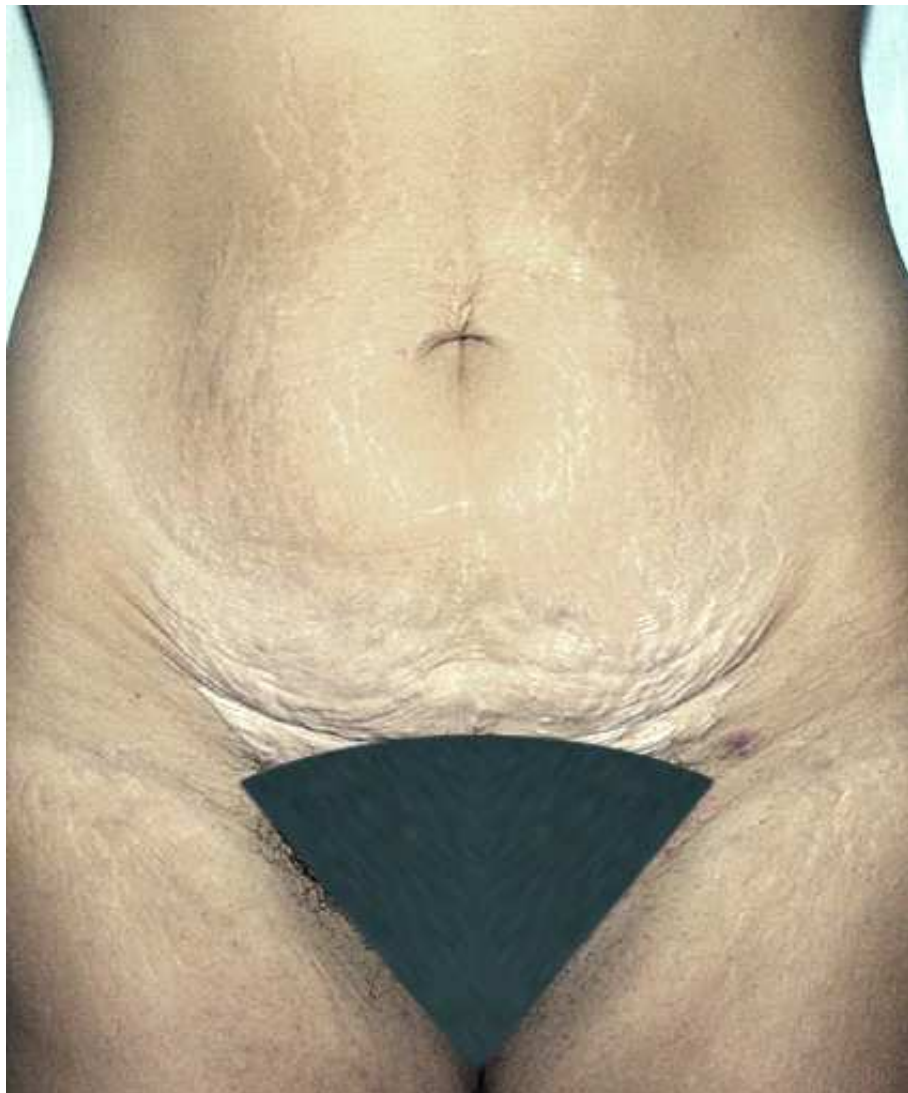



Lobo destro - Istmo - Lobo sinistro (superficie anteriore)

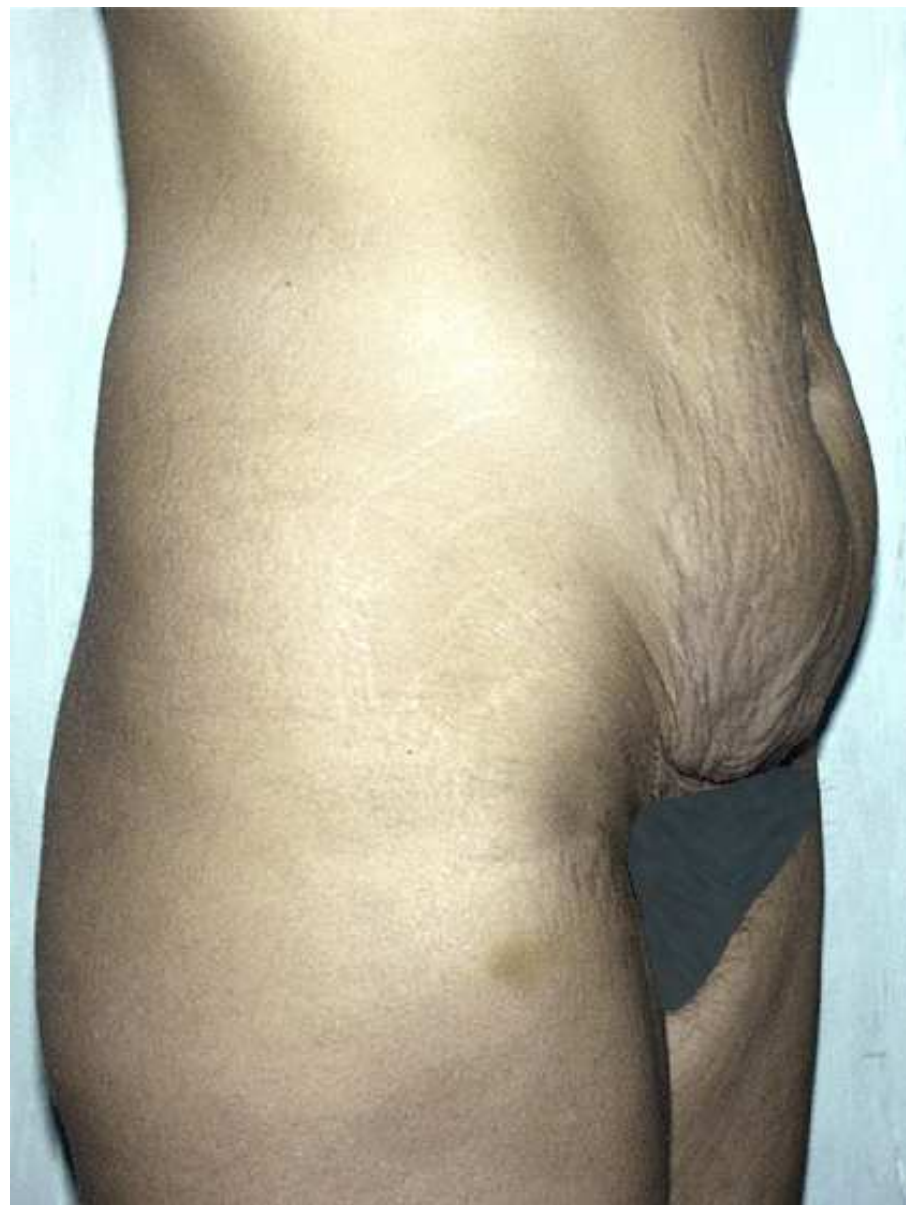

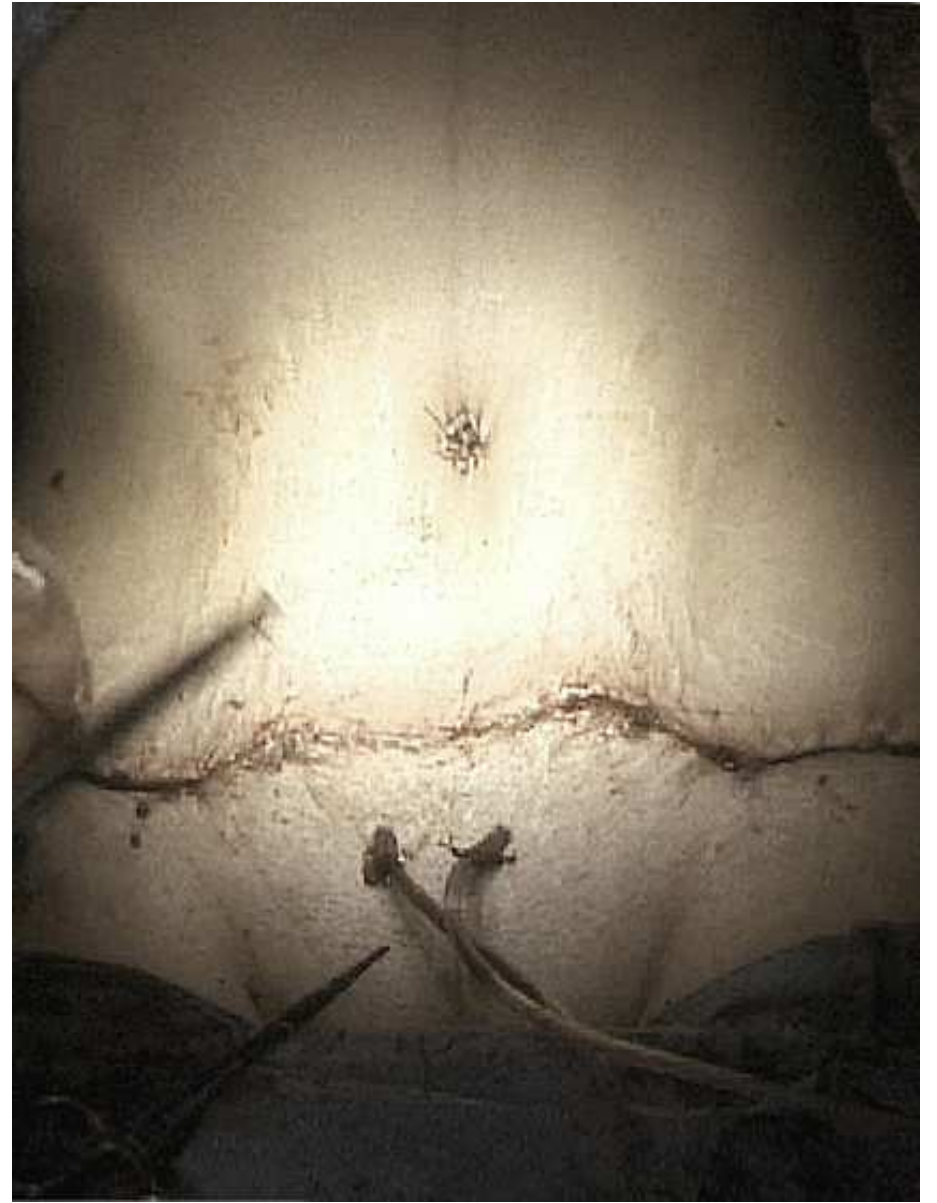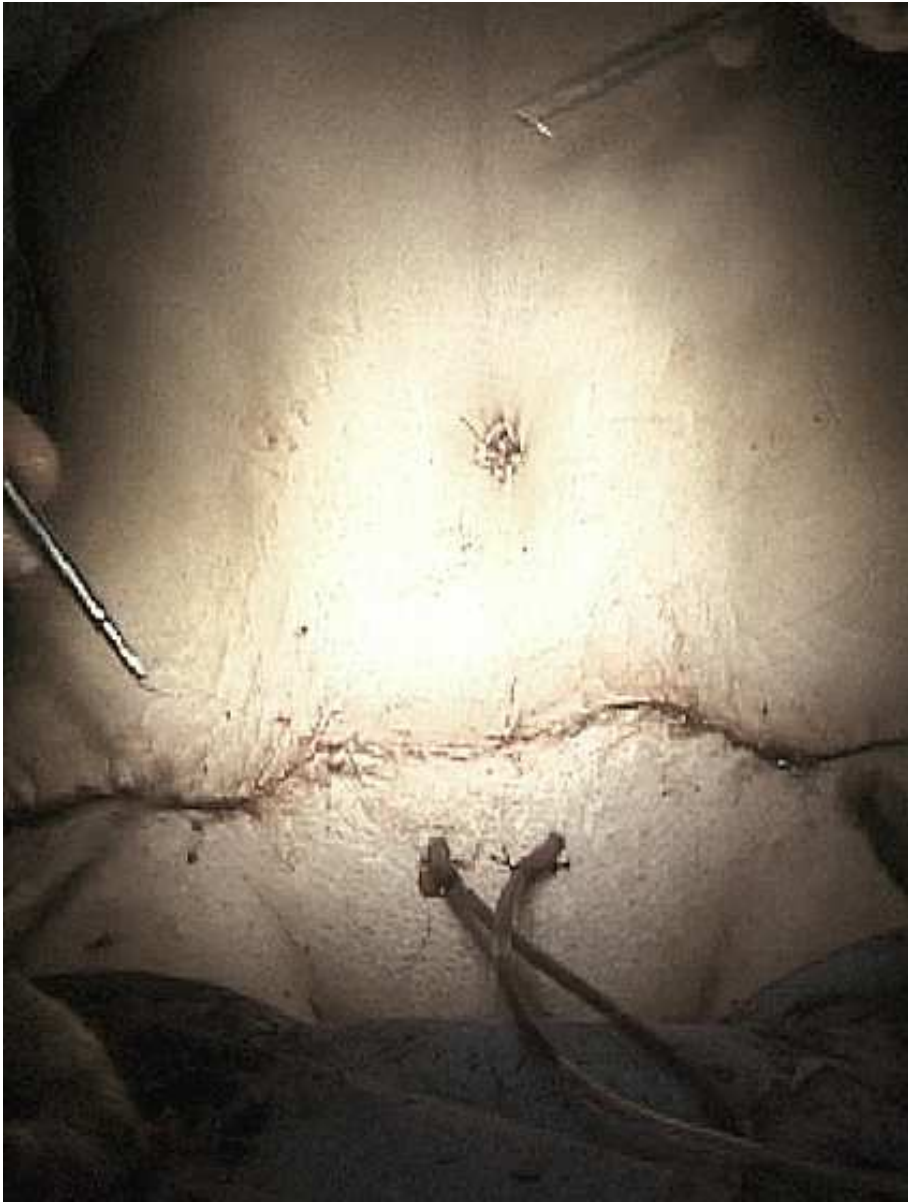Lobo sinistro - Istmo - Lobo destro (superficie posteriore)

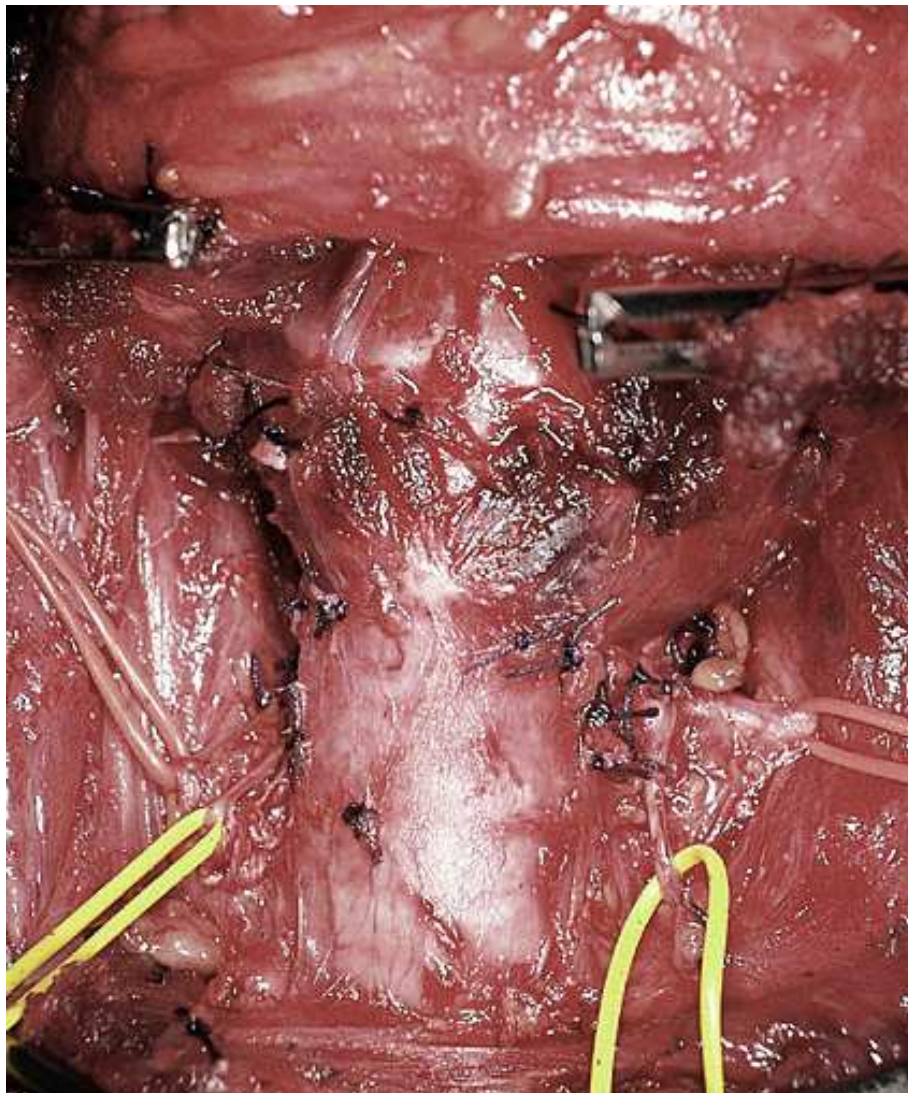


O.P. • Anni: 28 - F • Record: 18 • 09-01-2002

Addominoplastica sec. Serson modificata per addome pendulo

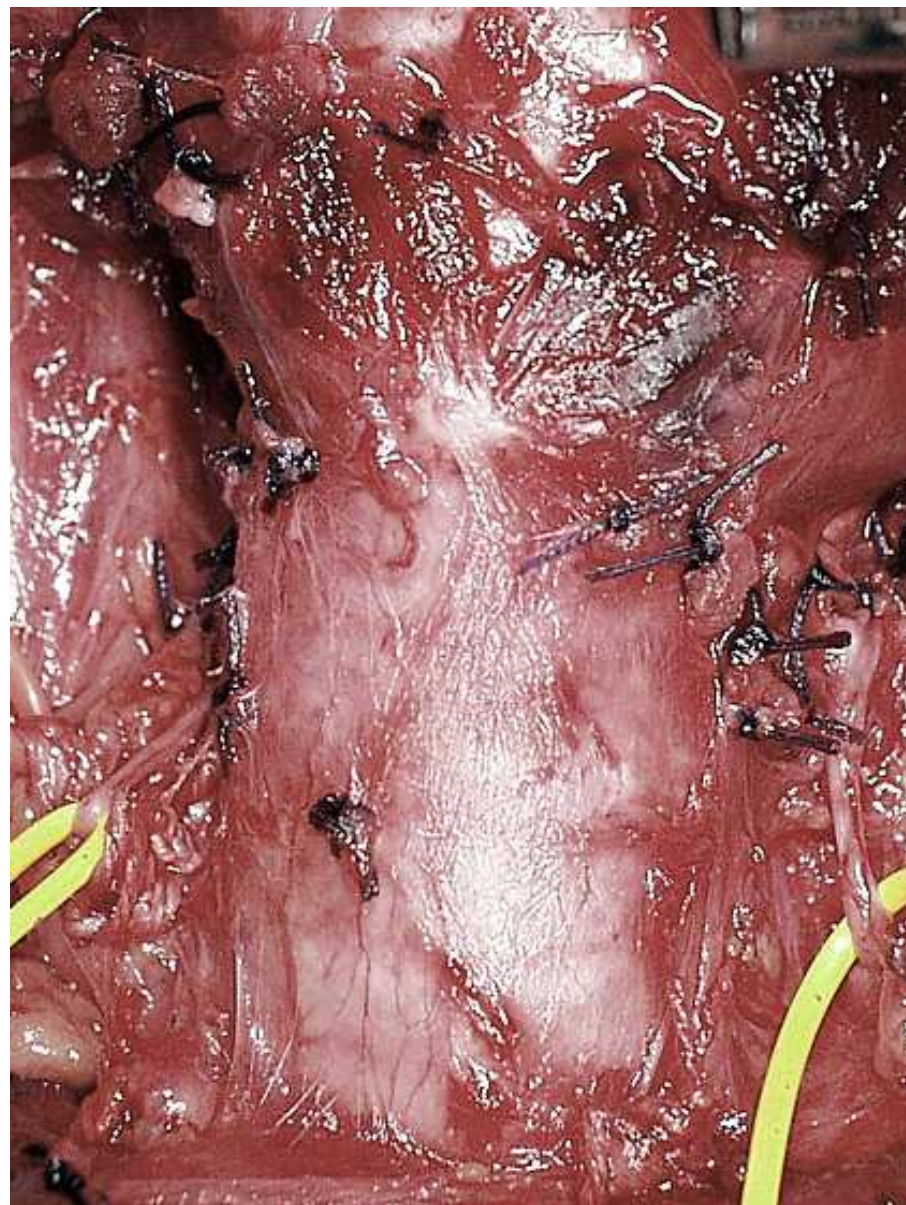




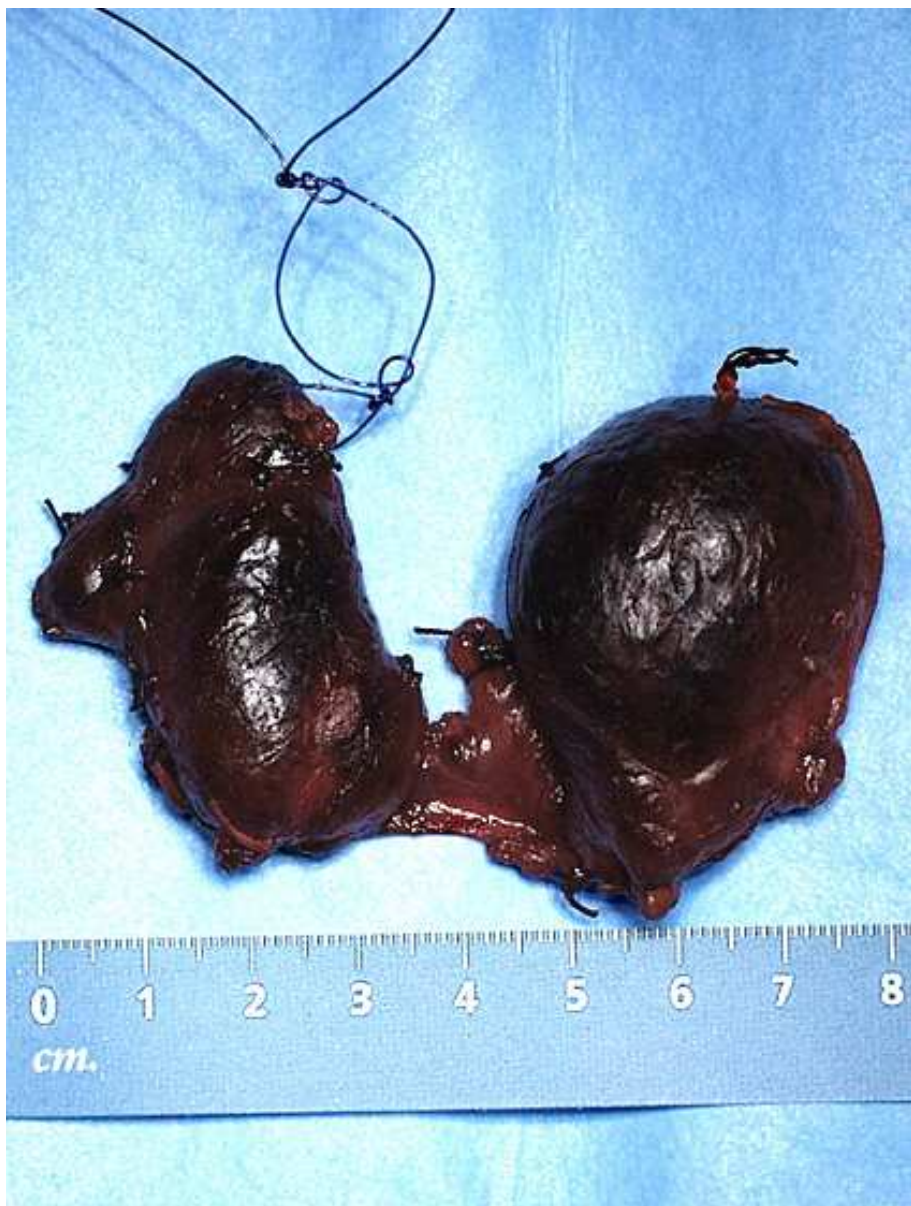

P.A. • Anni: 34 - F • Record: 19 • 19-01-2002

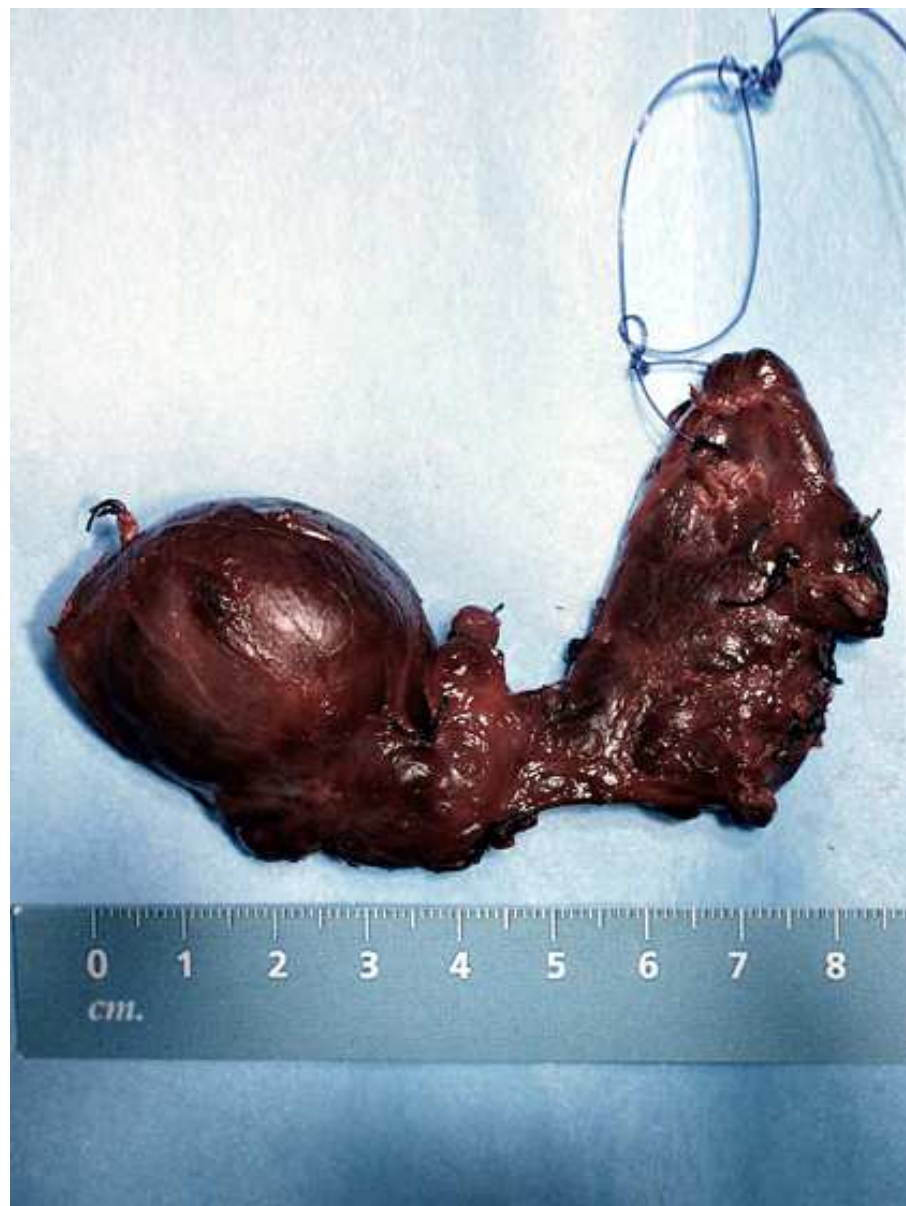
Tiroidectomia totale extracapsulare per carcinoma papillifero del lobo dx in gozzo plurinodulare



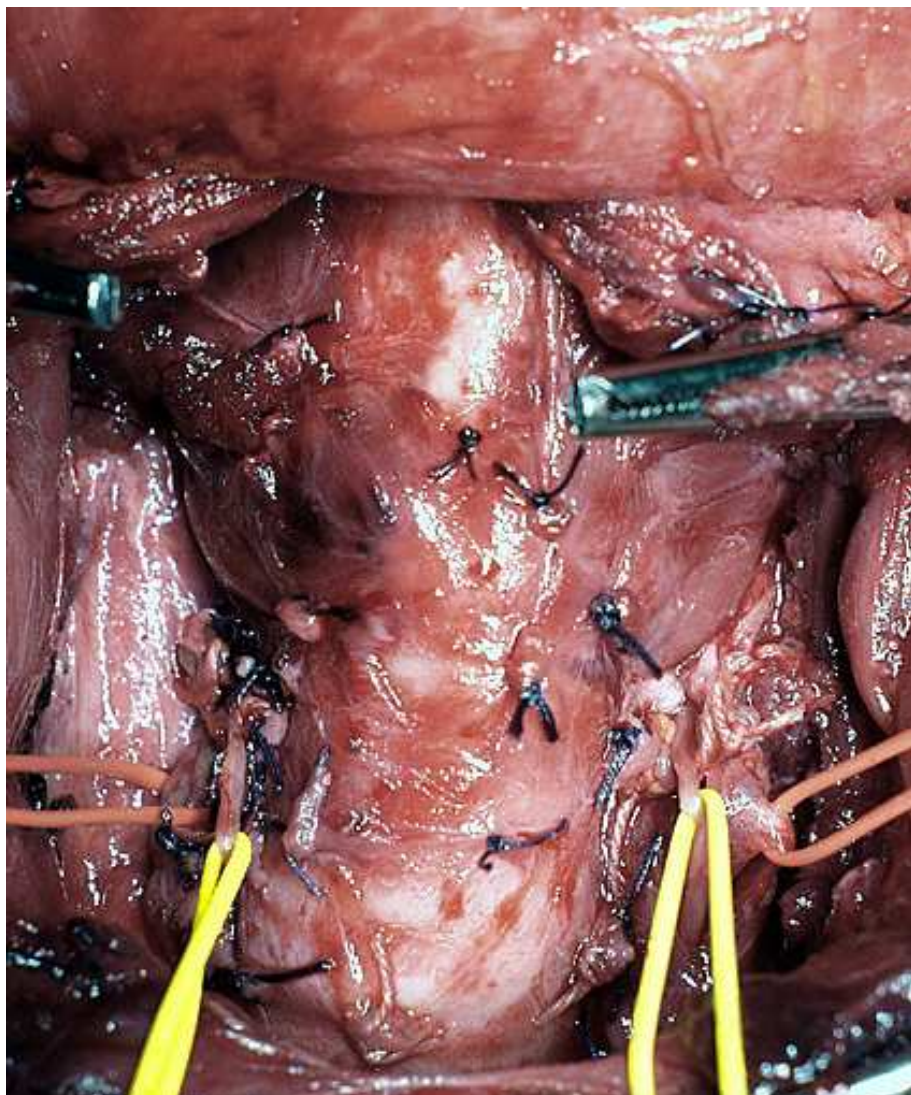
Isolamento dei nervi laringei inferiori (ricorrenti)



Lobo destro - Istmo - Lobo sinistro (superficie anteriore)

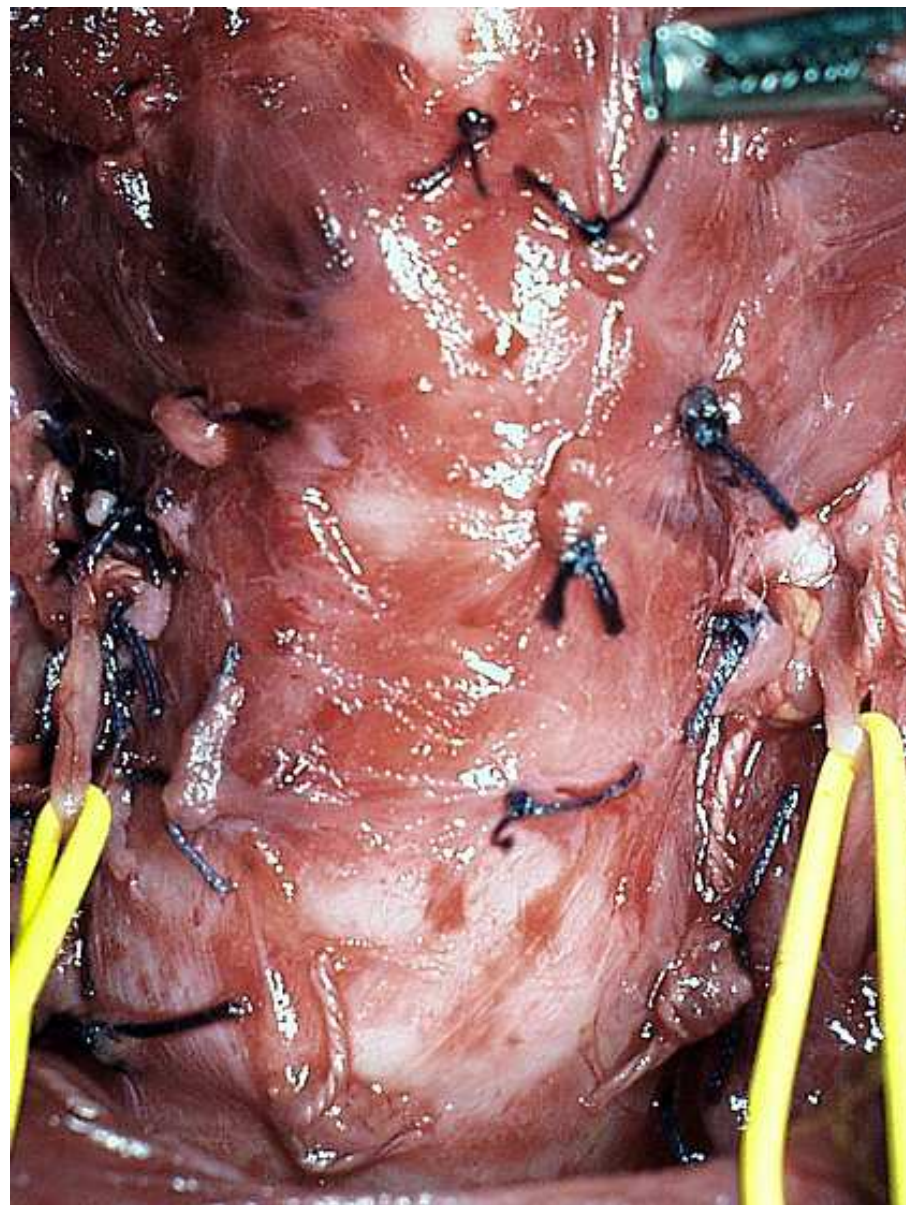


Lobo sinistro - Istmo - Lobo destro (superficie posteriore)

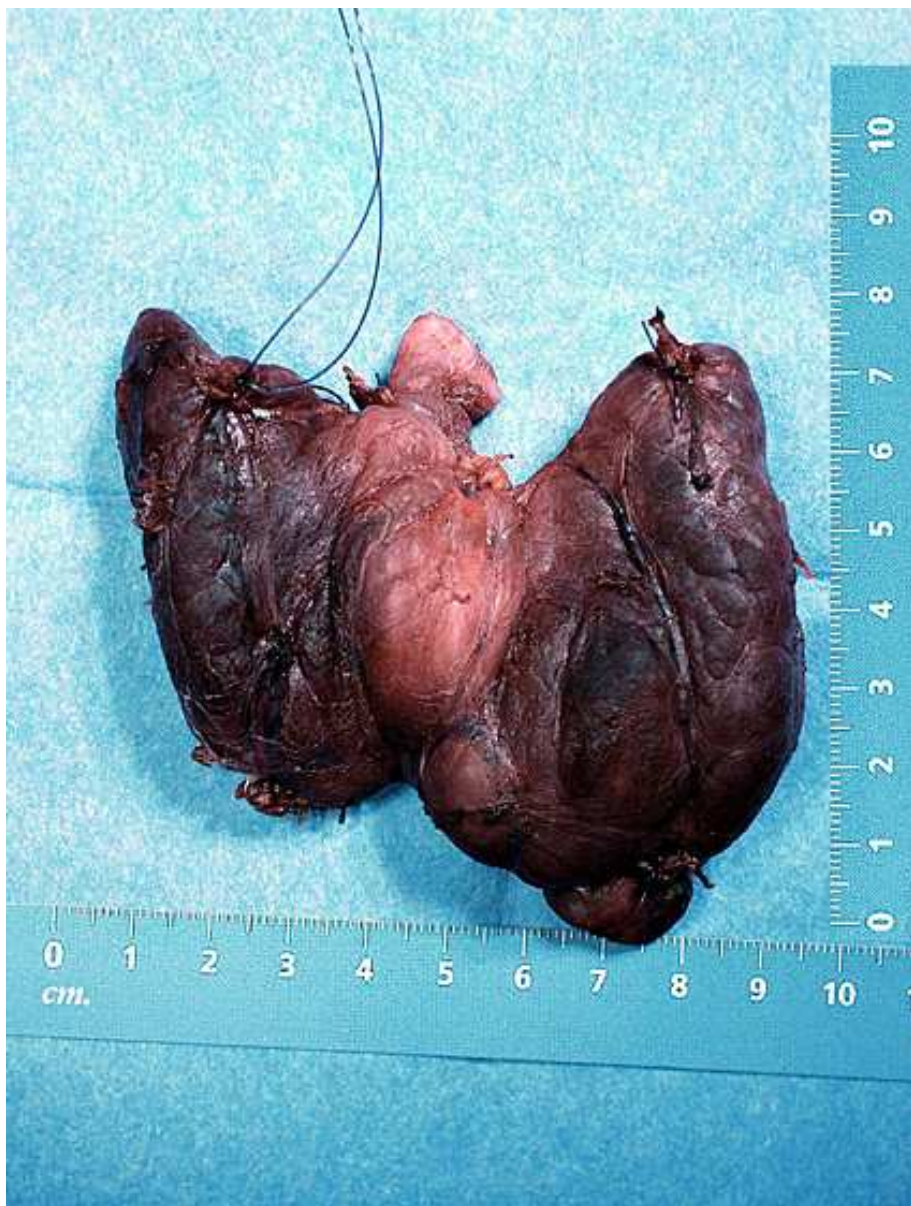


V.P. • Anni: 41 - F • Record: 20 • 23-01-2002

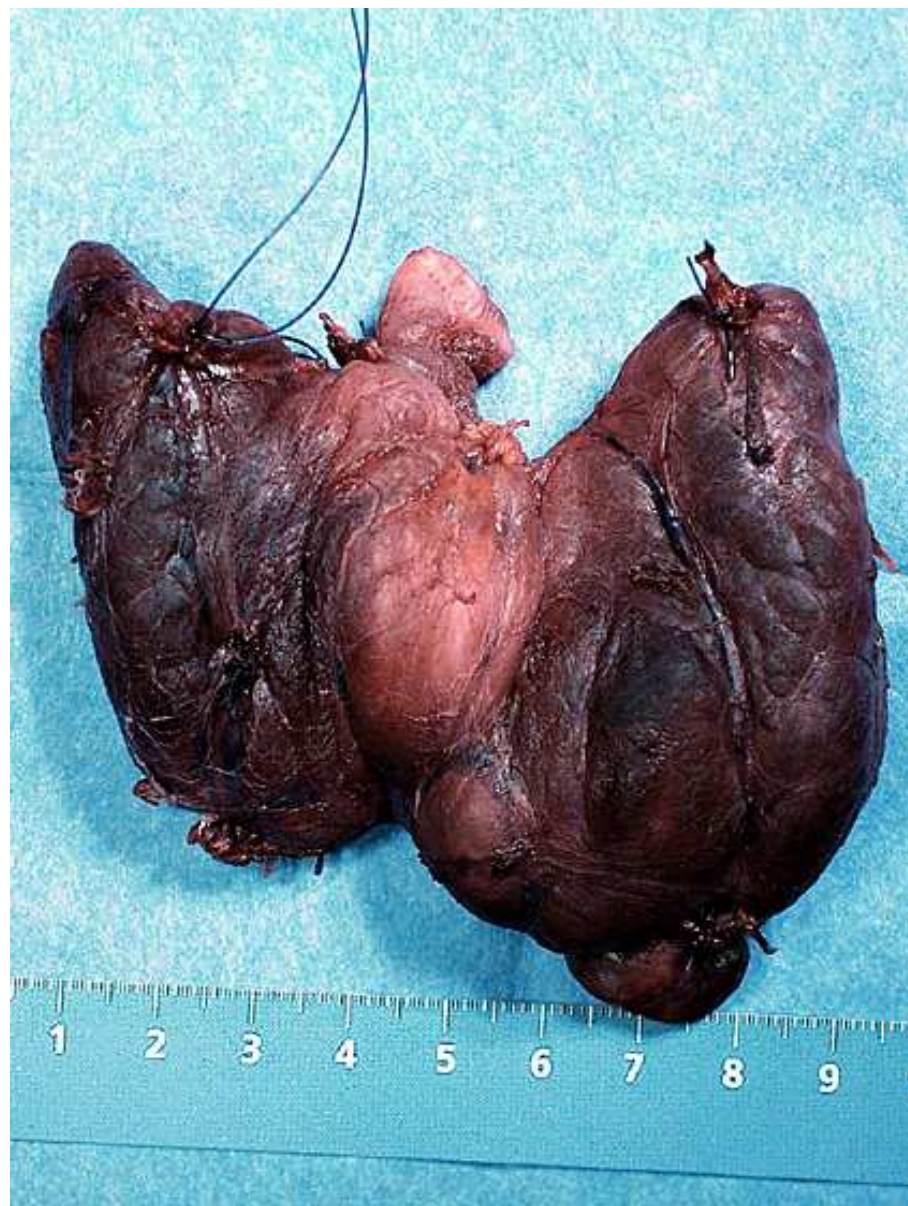
Tiroidectomia totale extracapsulare per adenoma follicolare del lobo dx in gozzo plurinodulare plongeant a sn



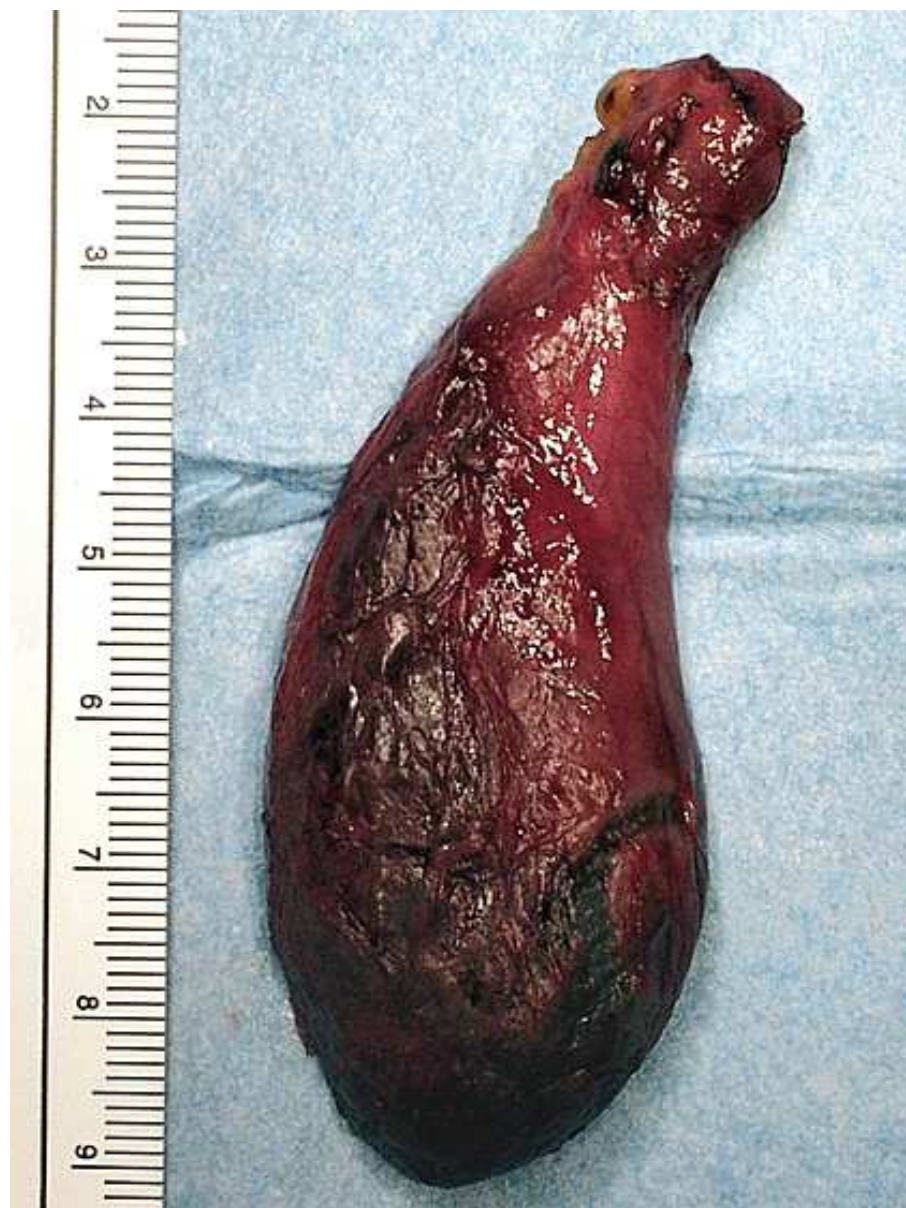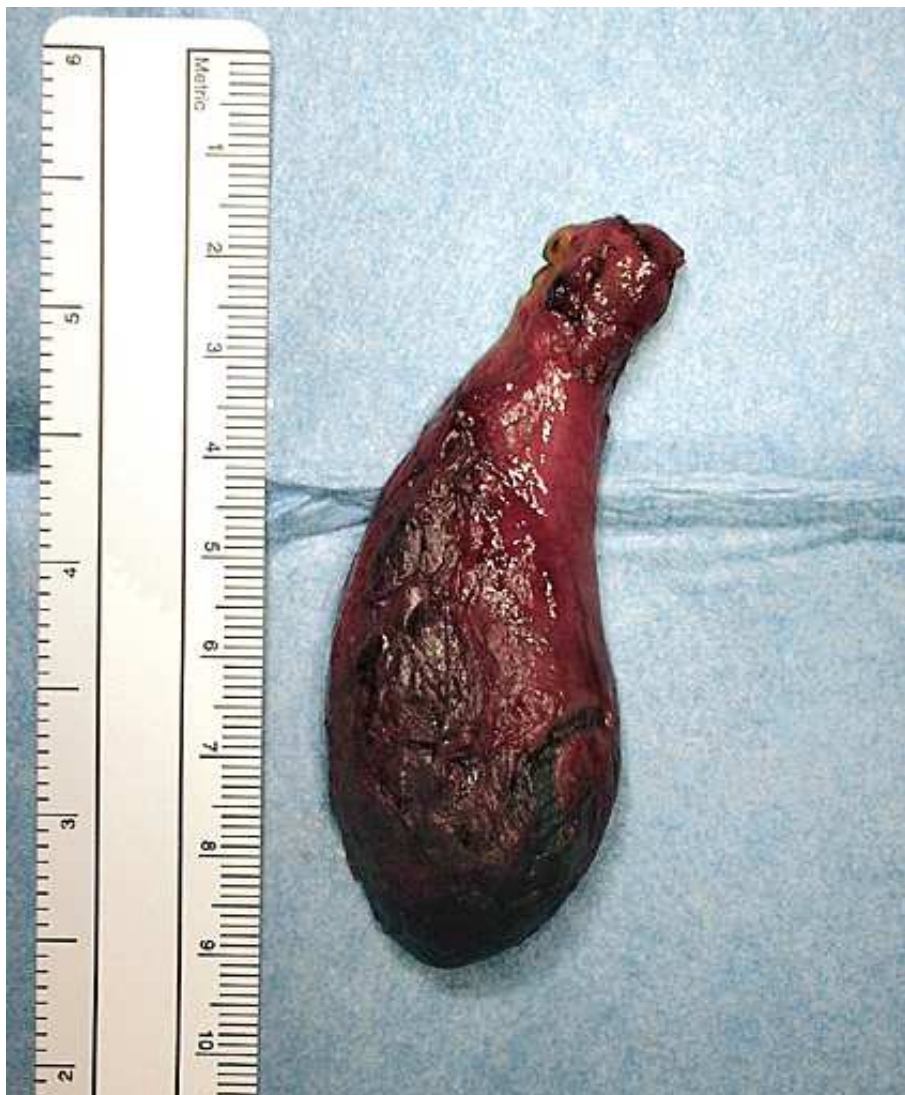Isolamento dei nervi laringei inferiori (ricorrenti)



Lobo destro - Istmo - Lobo sinistro (superficie anteriore)



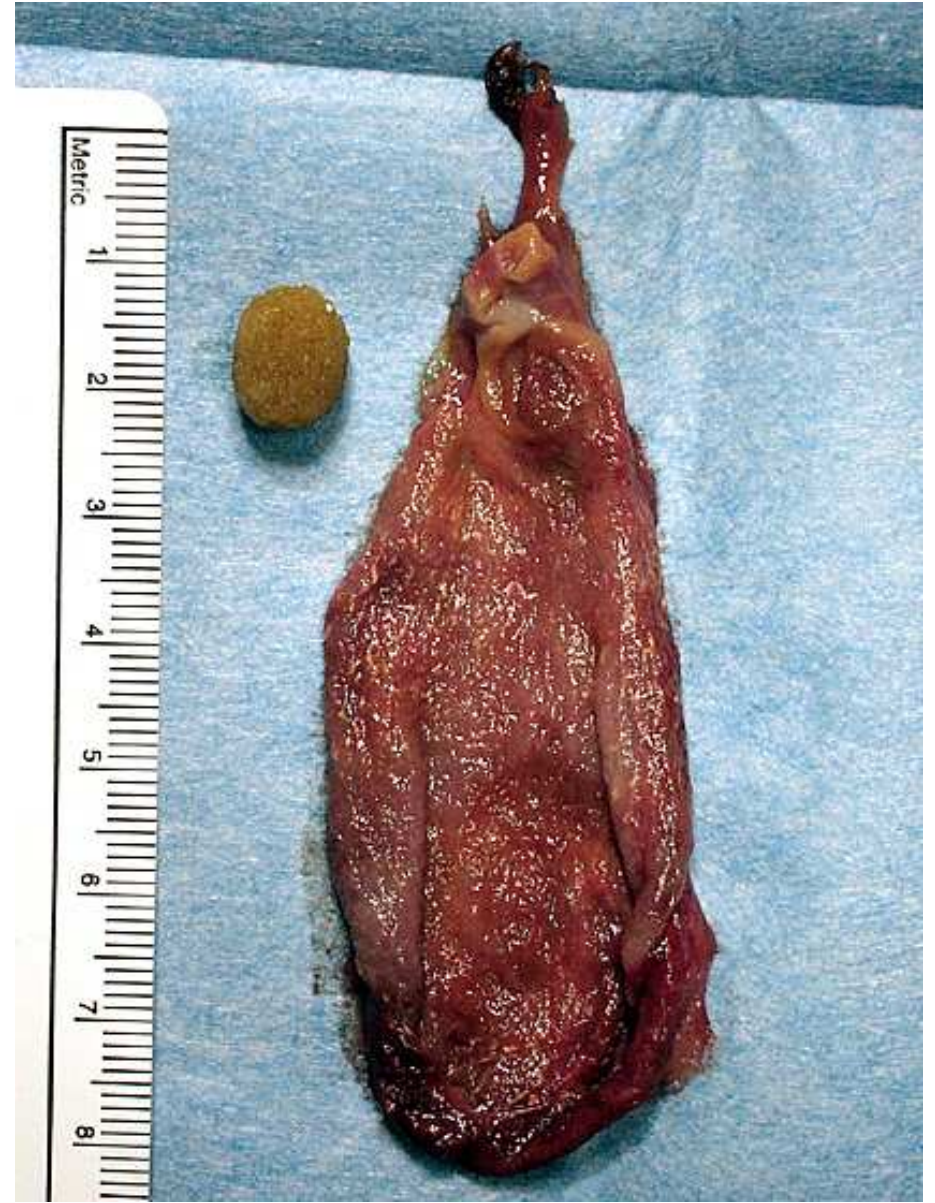
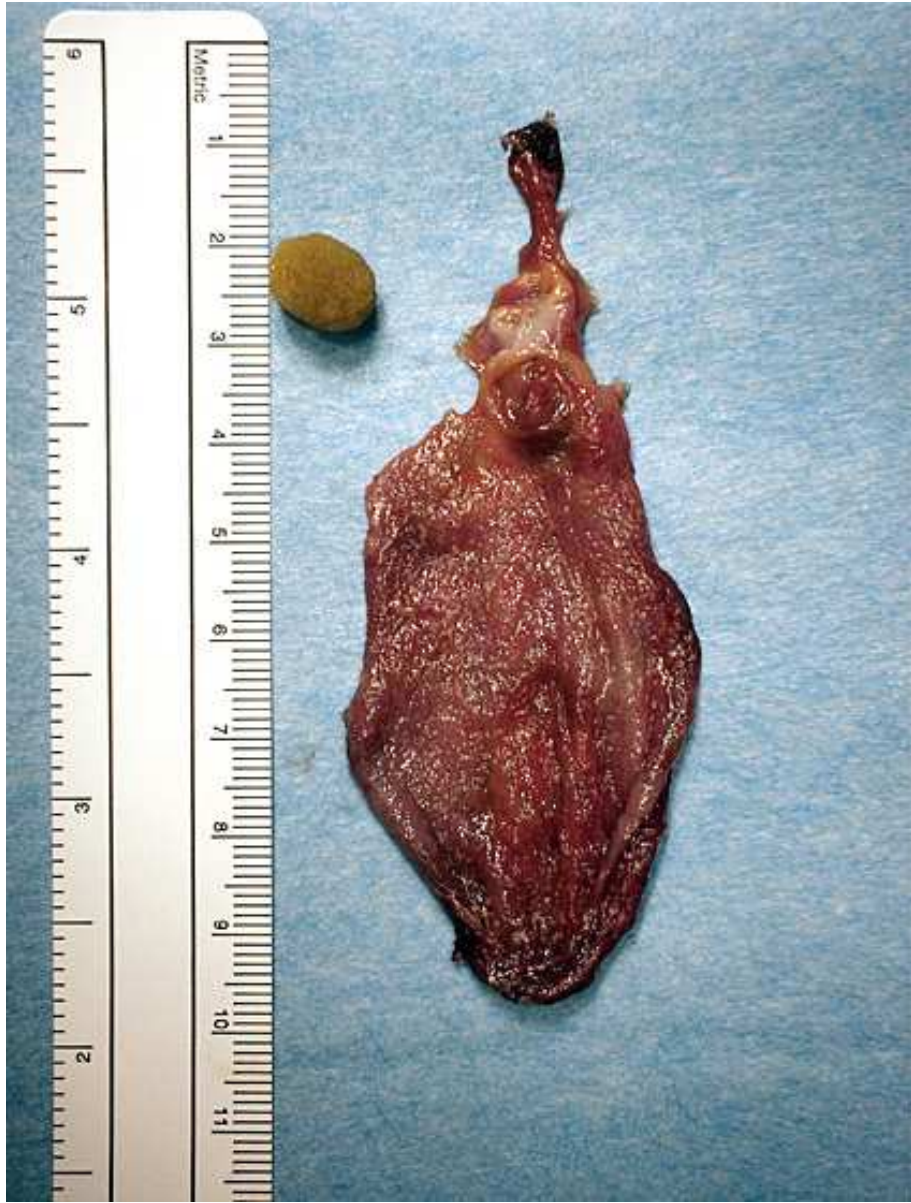Lobo sinistro - Istmo - Lobo destro (superficie posteriore)

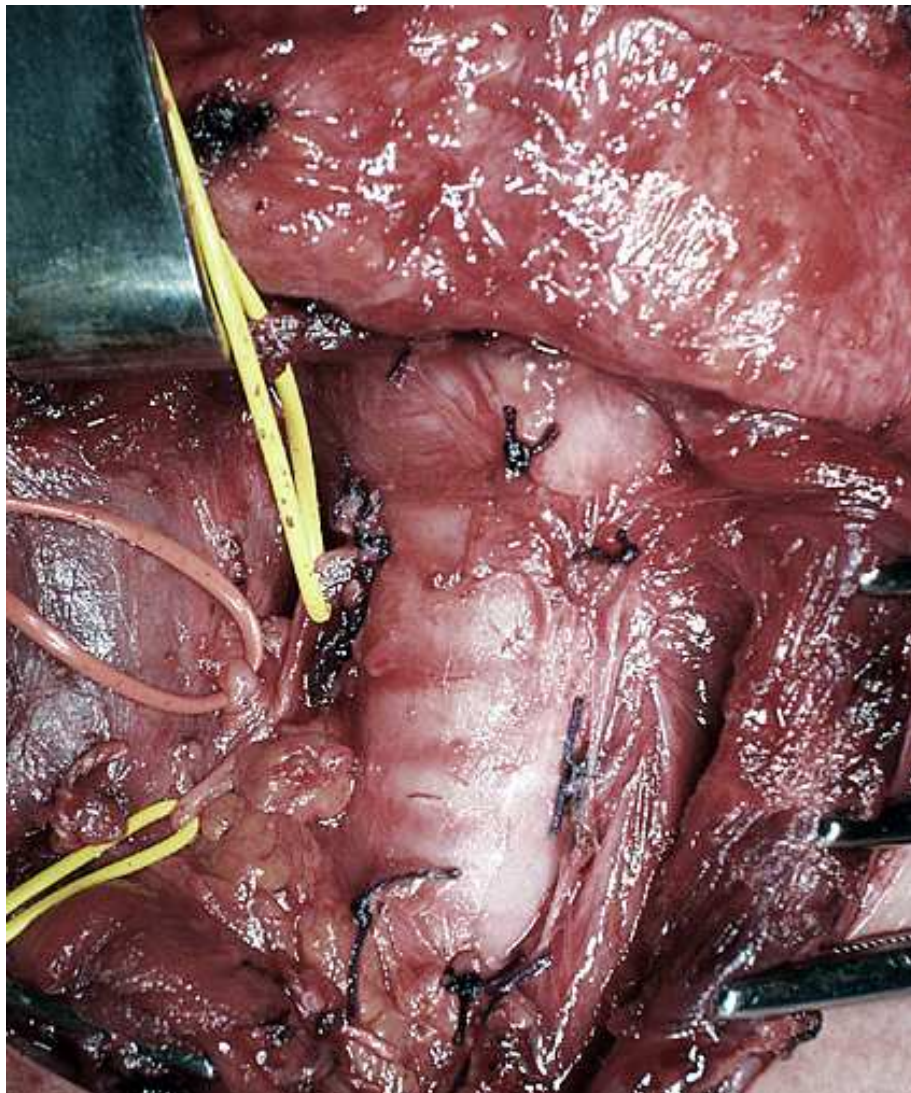


J.C. • Anni: 29 - F • Record: 21 • 02-02-2002

Colecistectomia retrograda per litiasi

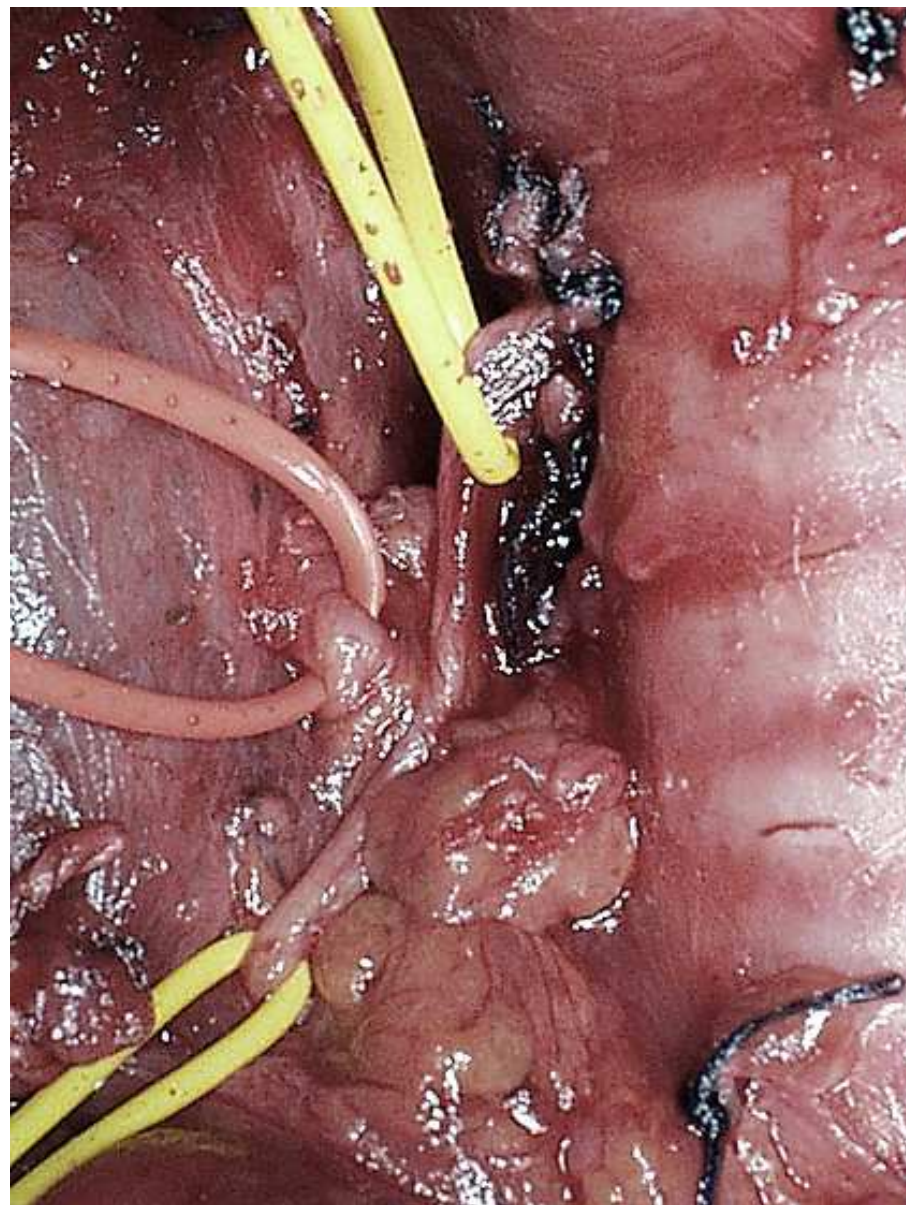




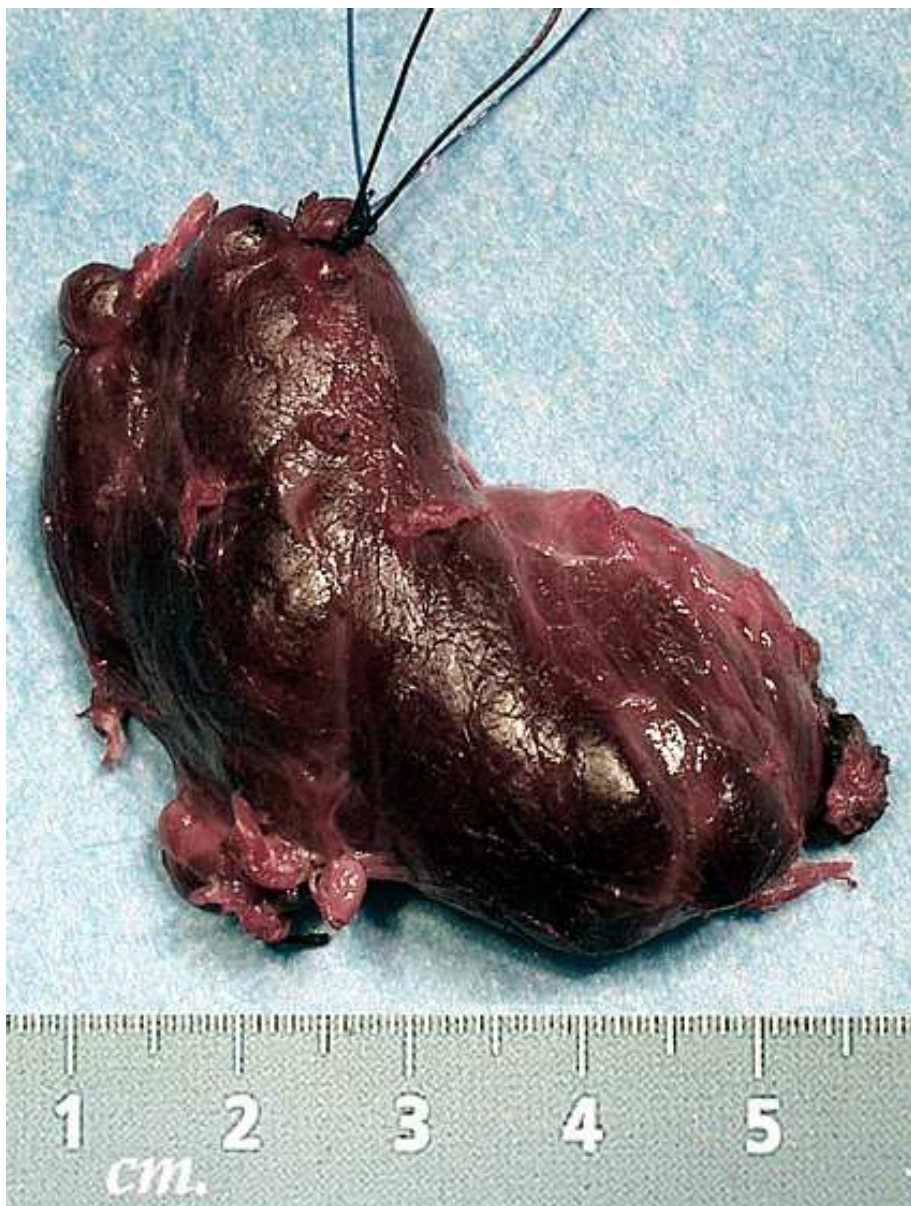

C.A. • Anni: 42 - F • Record: 22 • 06-02-2002

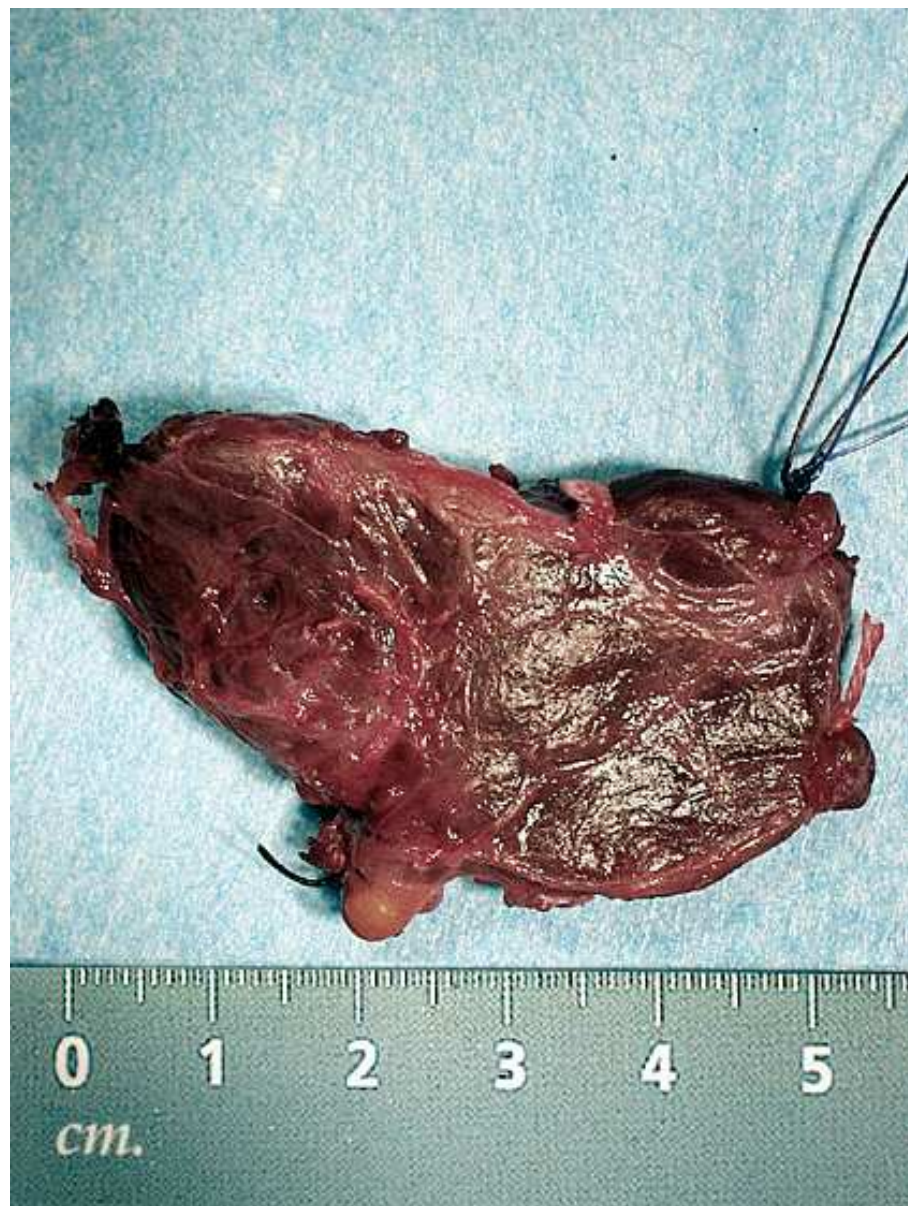
Lobectomia dx ed istmectomia totale extracapsulare con asportazione di piccolo residuo tiroideo sn per gozzo plurinodulare recidivo in lobectomizzata a sn



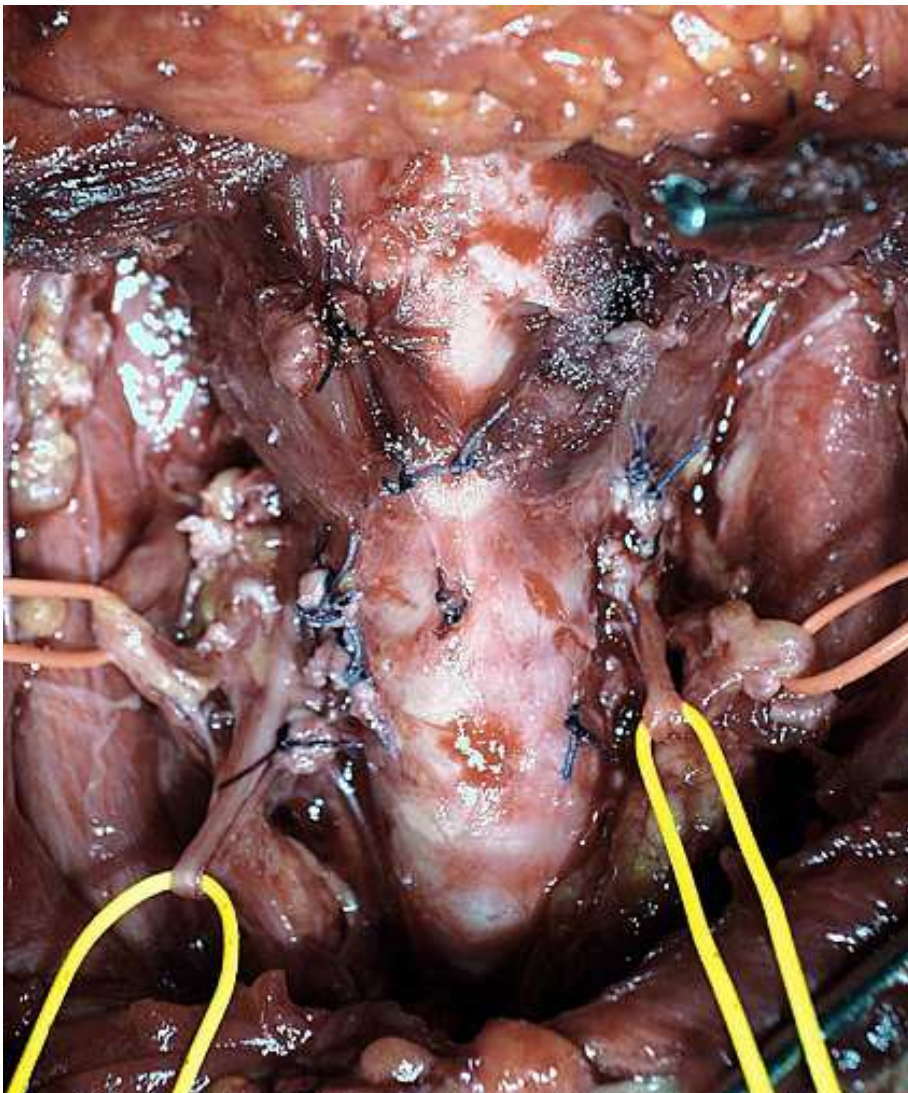
Isolamento dell'arteria tiroidea e del nervo laringeo inferiore destro (ricorrente)



Lobo destro - Istmio - Residuo lobo sinistro (superficie anteriore)

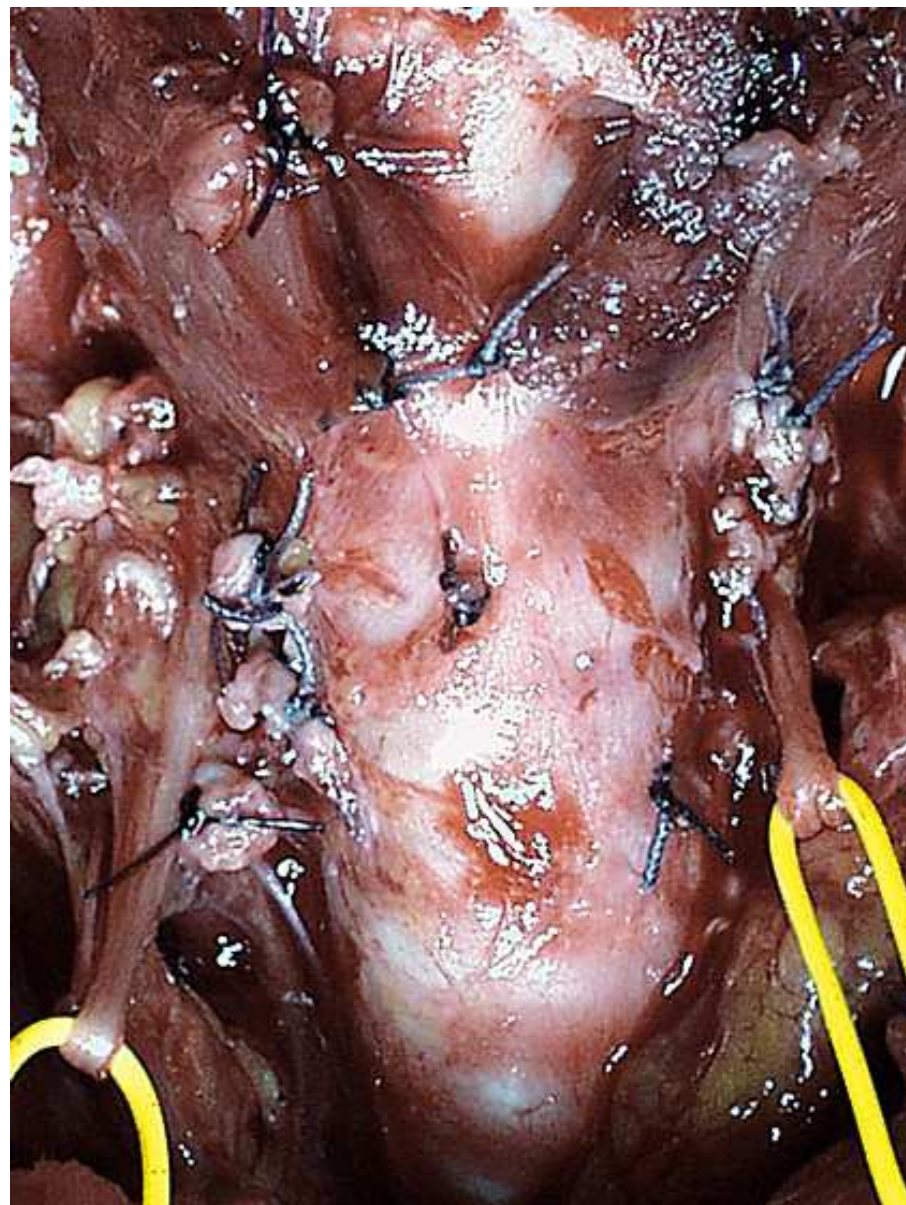


Residuo lobo sinistro - Istmio - Lobo destro (superficie posteriore)

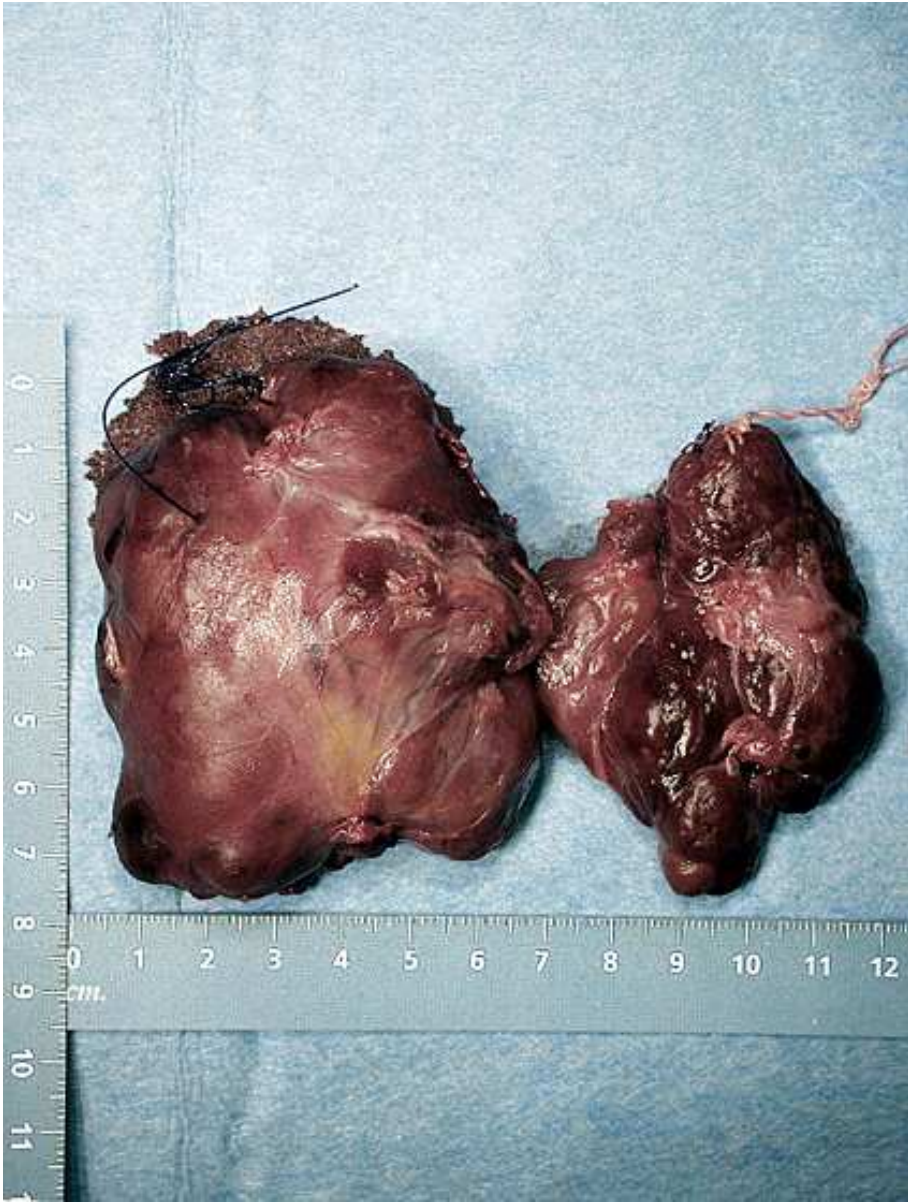


Z.C. • Anni: 56 - F • Record: 23 • 09-02-2002

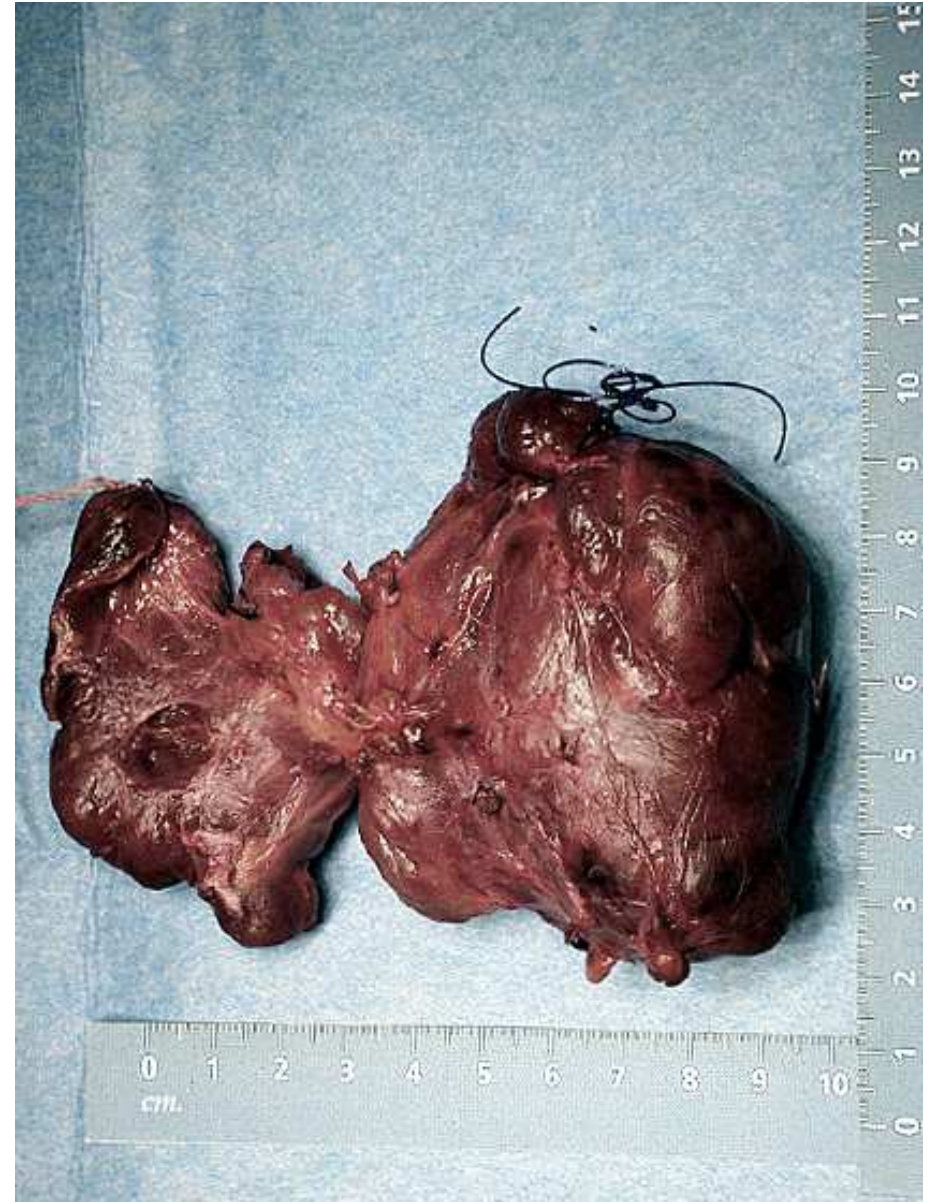
Tiroidectomia totale extracapsulare per gozzo plurinodulare plongeant a dx



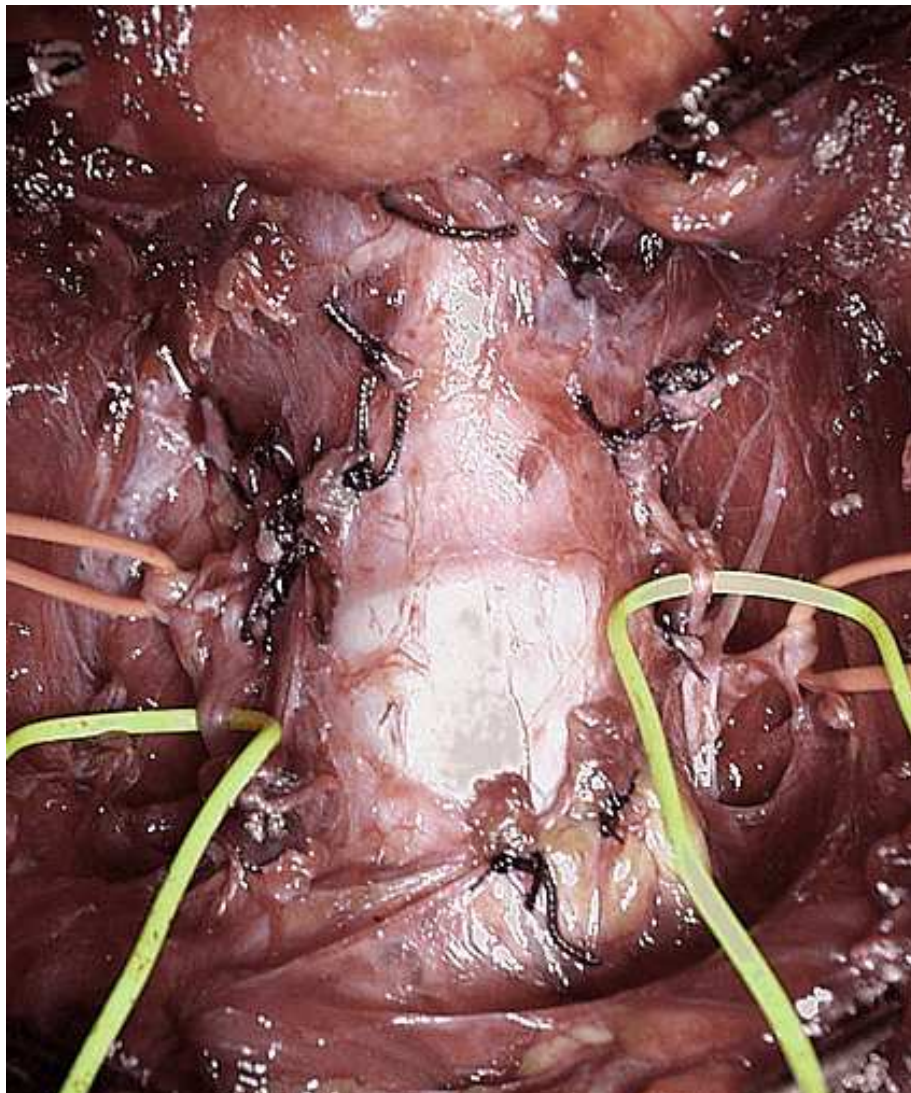
Isolamento dei nervi laringei inferiori (ricorrenti)



Lobo destro - Istmo - Lobo sinistro (superficie anteriore)

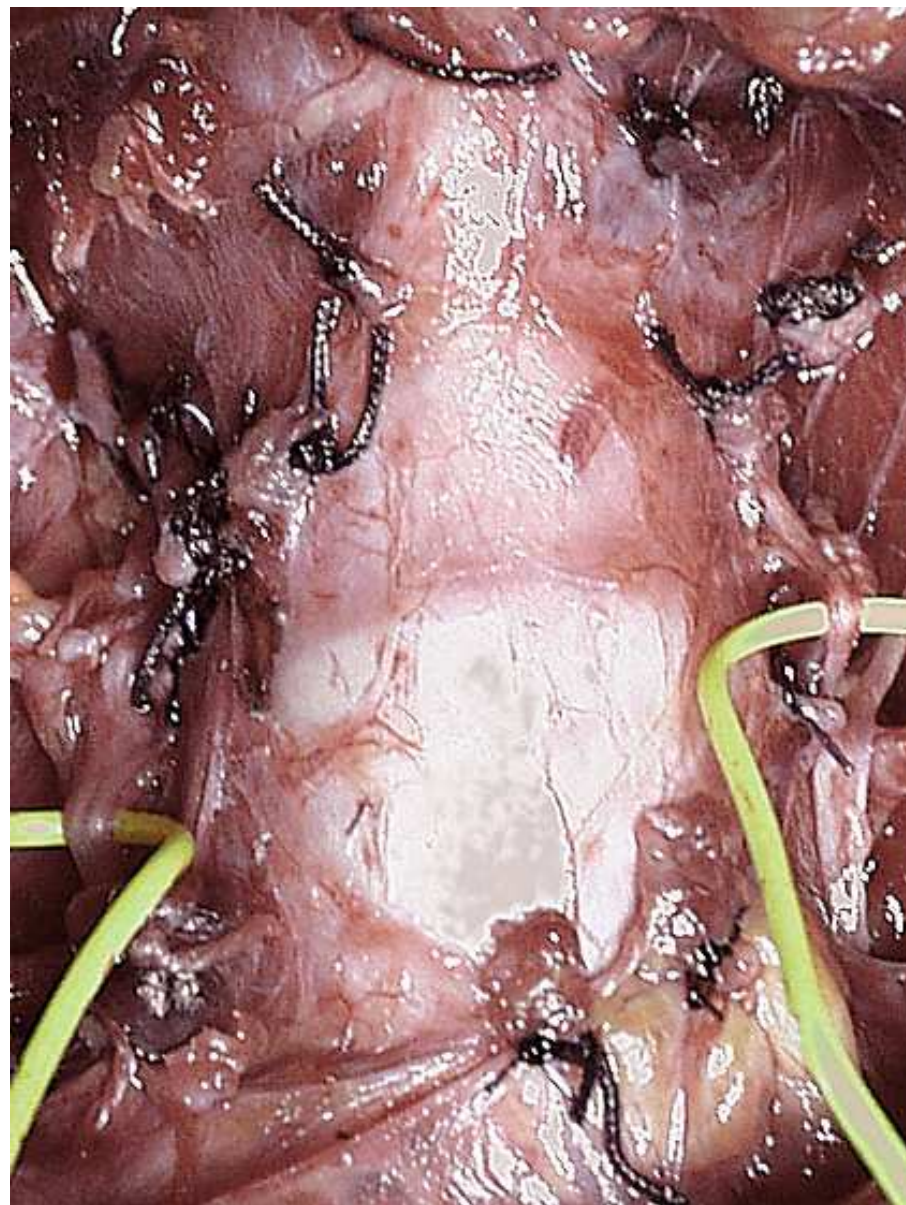


Lobo sinistro - Istmo - Lobo destro (superficie posteriore)

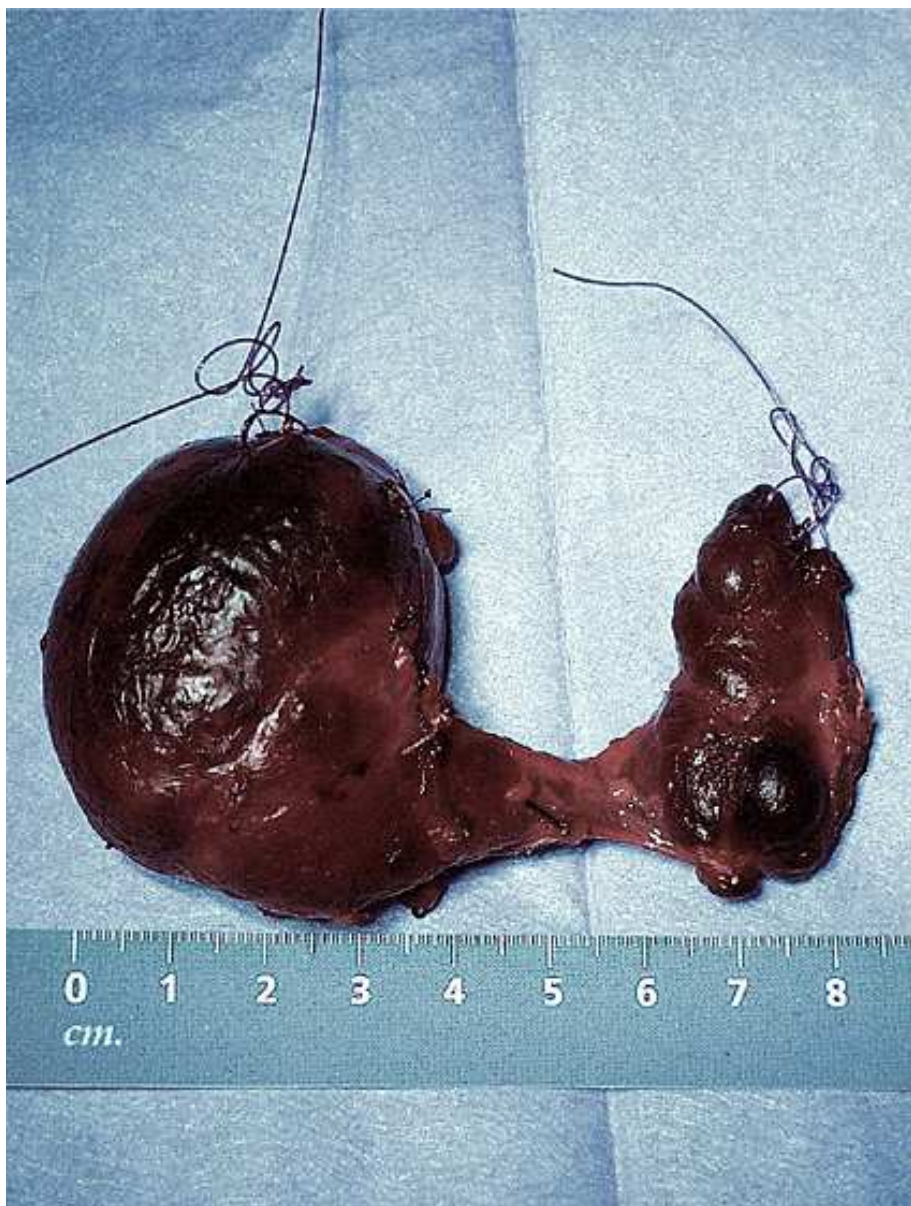


D.A. • Anni: 27 - F • Record: 24 • 24-02-2002

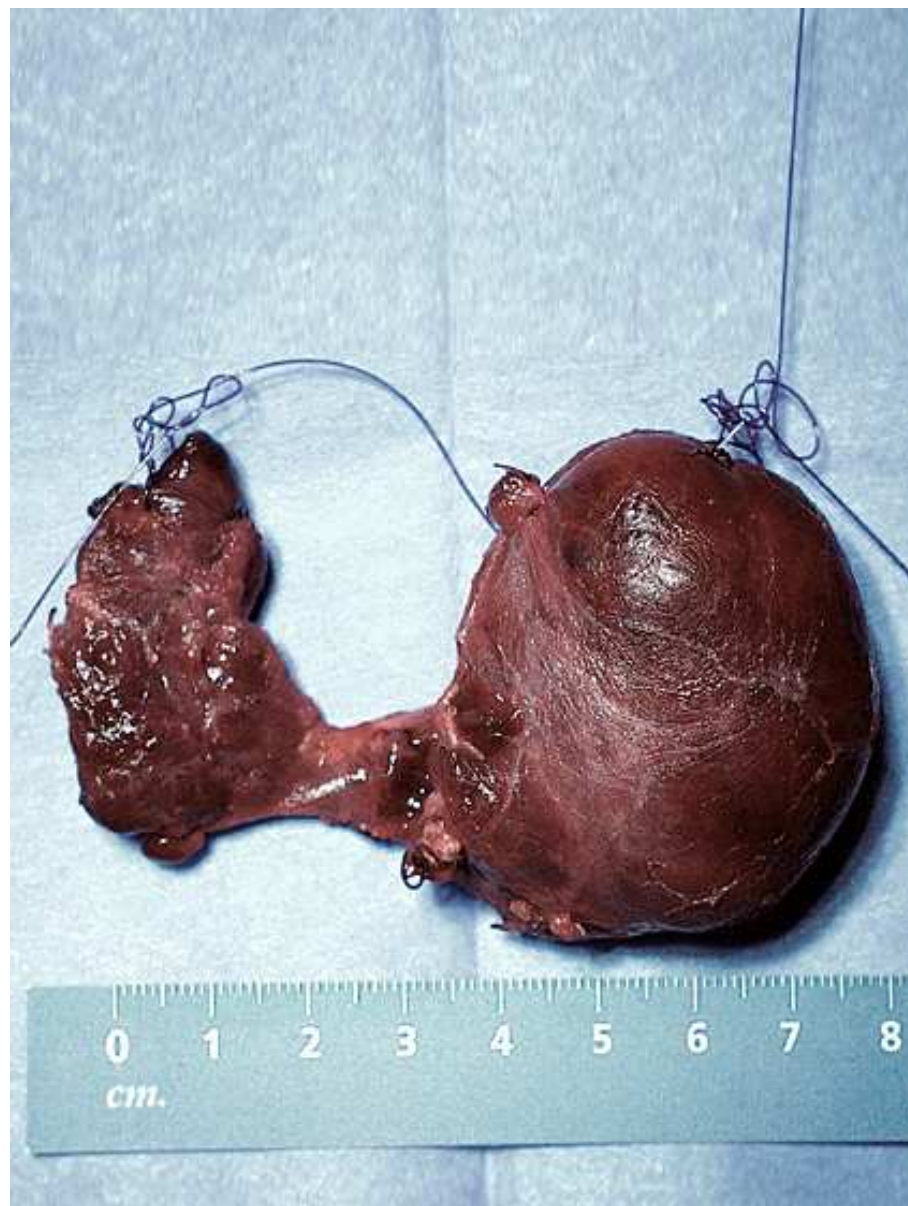
Tiroidectomia totale extracapsulare per gozzo plurinodulare tossico



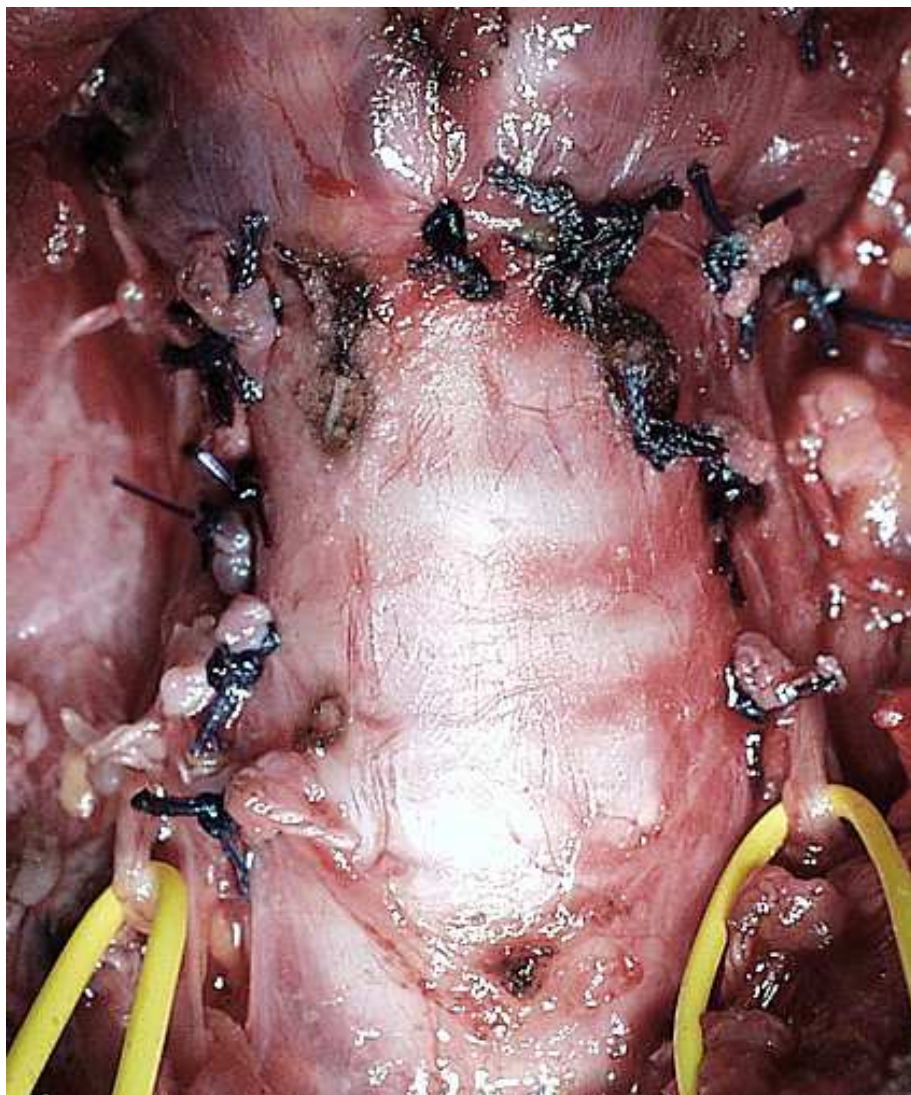
Isolamento dei nervi laringei inferiori (ricorrenti)



Lobo destro - Istmo - Lobo sinistro (superficie anteriore)

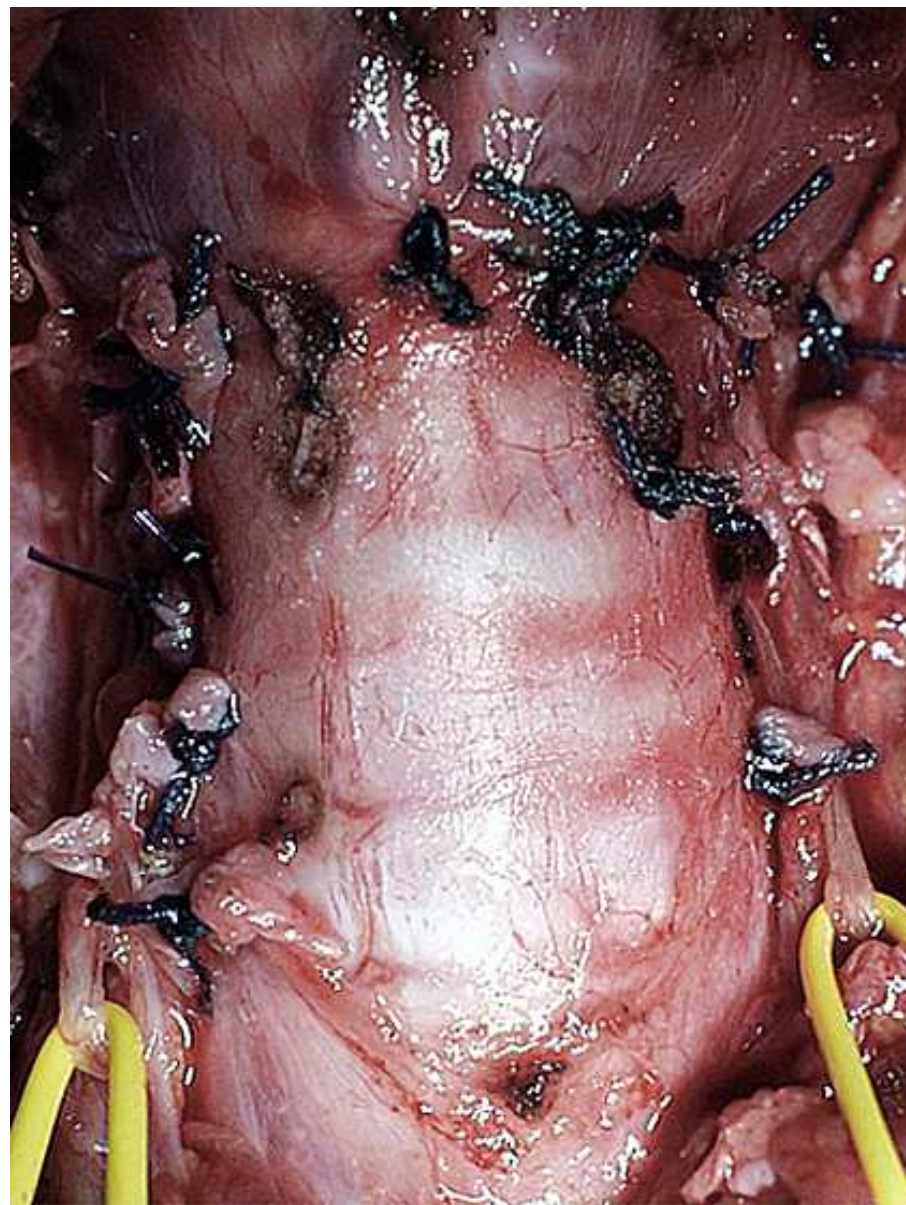


Lobo sinistro - Istmo - Lobo destro (superficie posteriore)



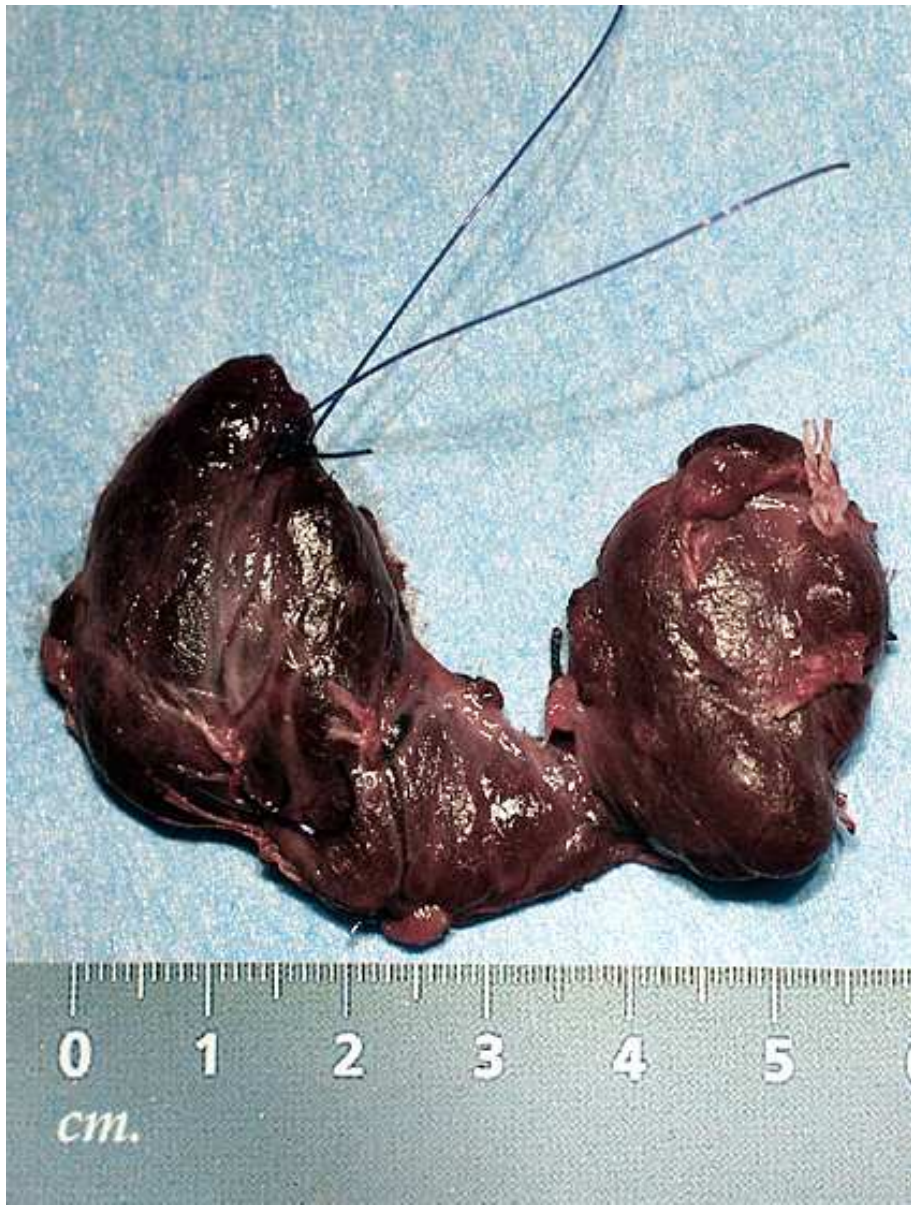A.S.L. · Anni: 47 - F · Record: 25 · 27-02-2002

Tiroidectomia totale extracapsulare per gozzo plurinodulare pretossico

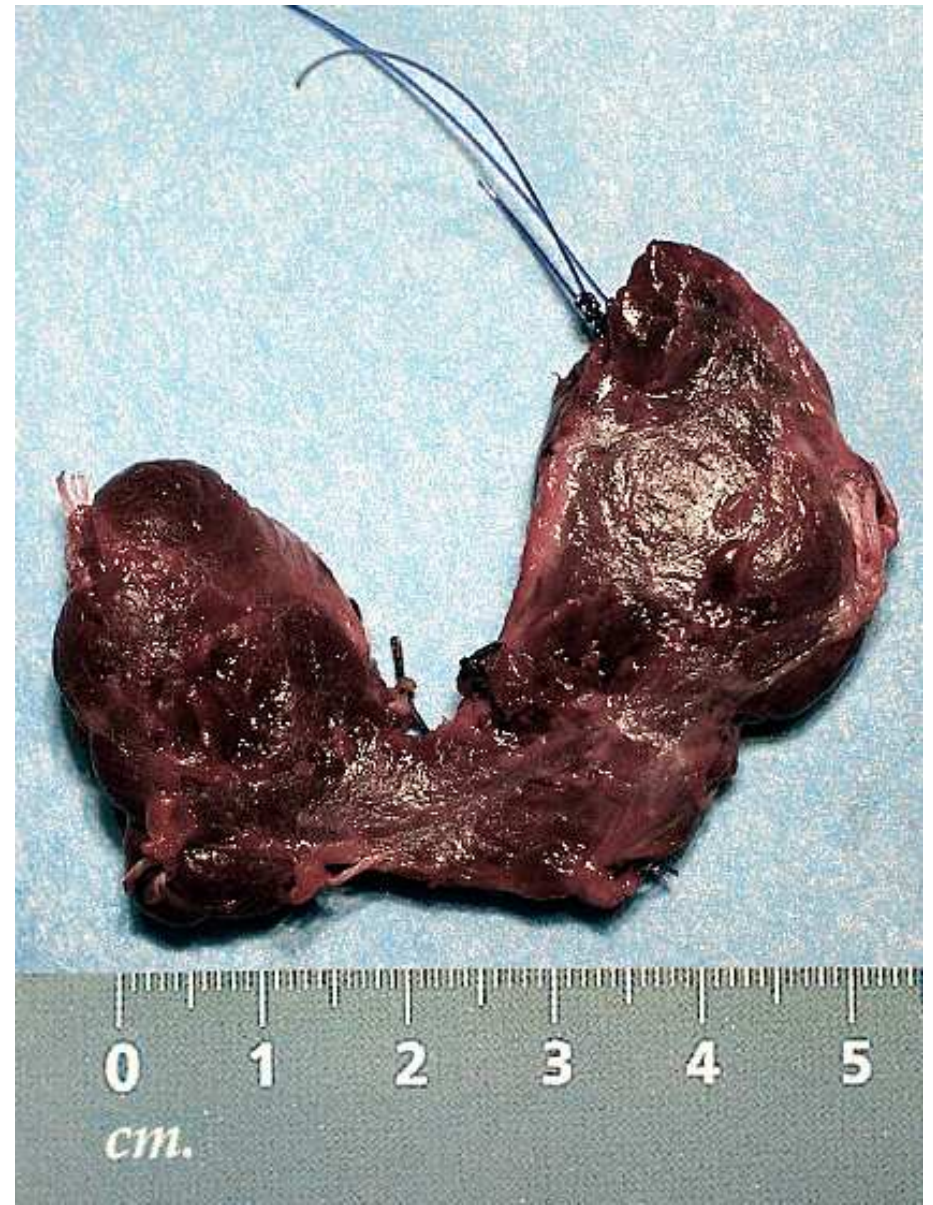


Isolamento dei nervi laringei inferiori (ricorrenti)

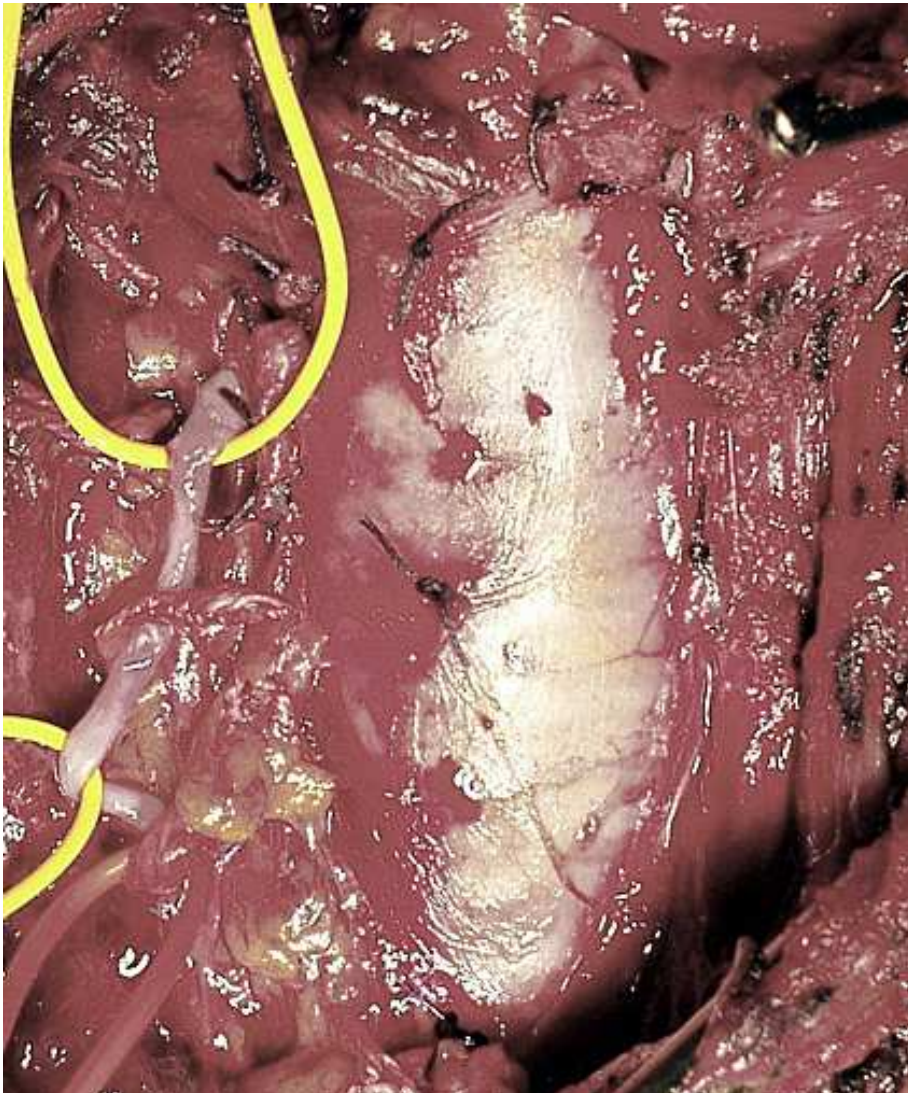




Lobo destro - Istmo - Lobo sinistro (superficie anteriore)

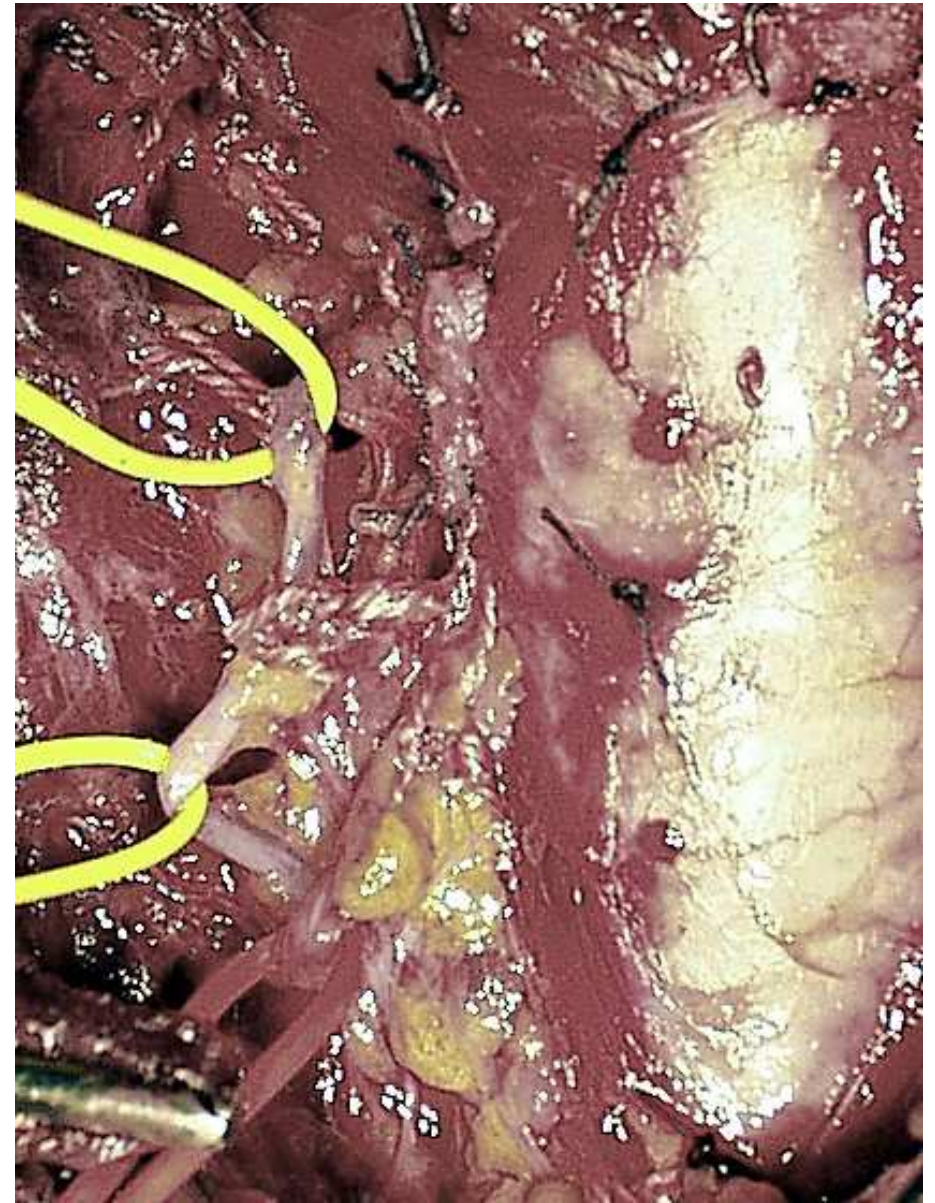


Lobo sinistro - Istmo - Lobo destro (superficie posteriore)

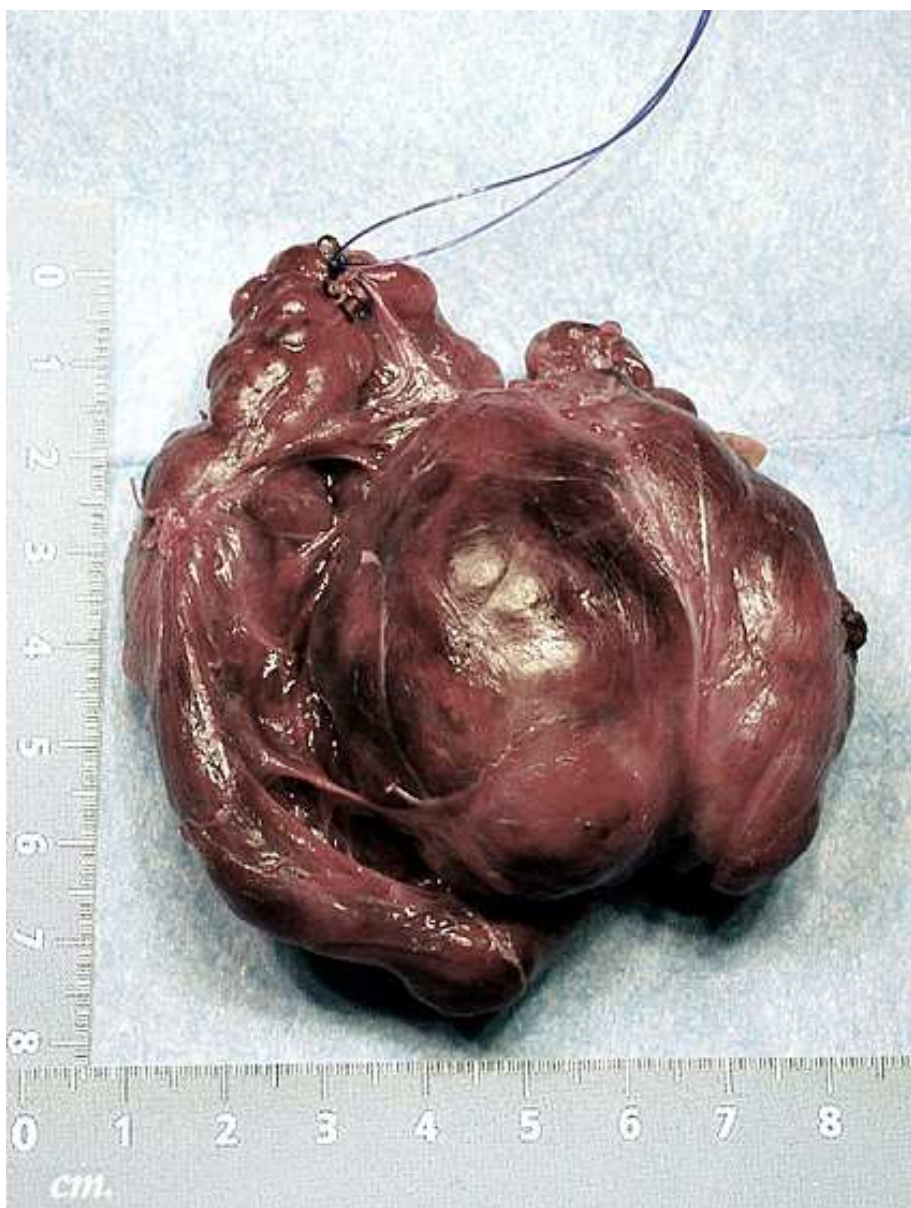


C.R. • Anni: 51 - F • Record: 26 • 13-03-2002

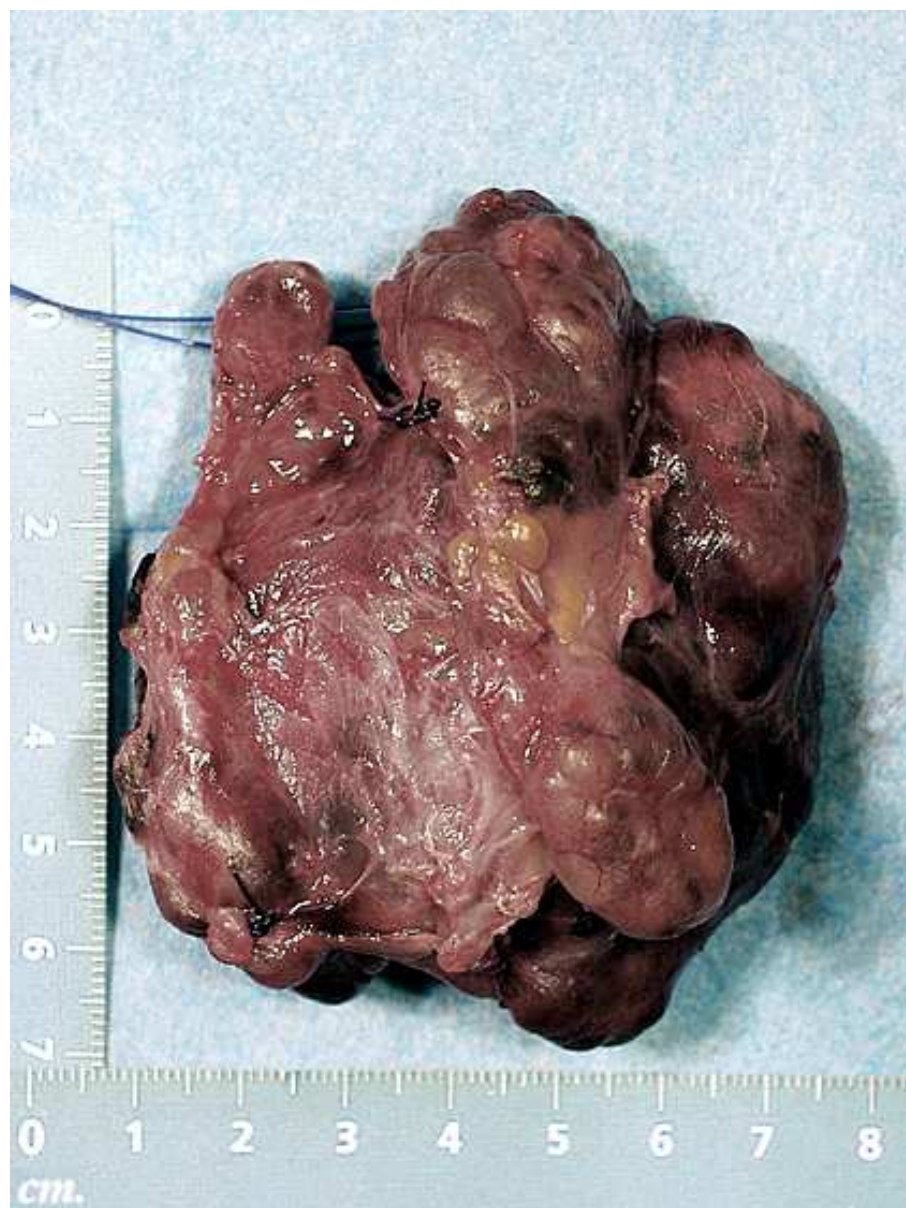Lobectomia dx ed istmectomia totale extracapsulare con asportazione di residuo tiroideo sn per gozzo plurinodulare recidivo in lobectomizzata con emiplegia laringea a sinistra



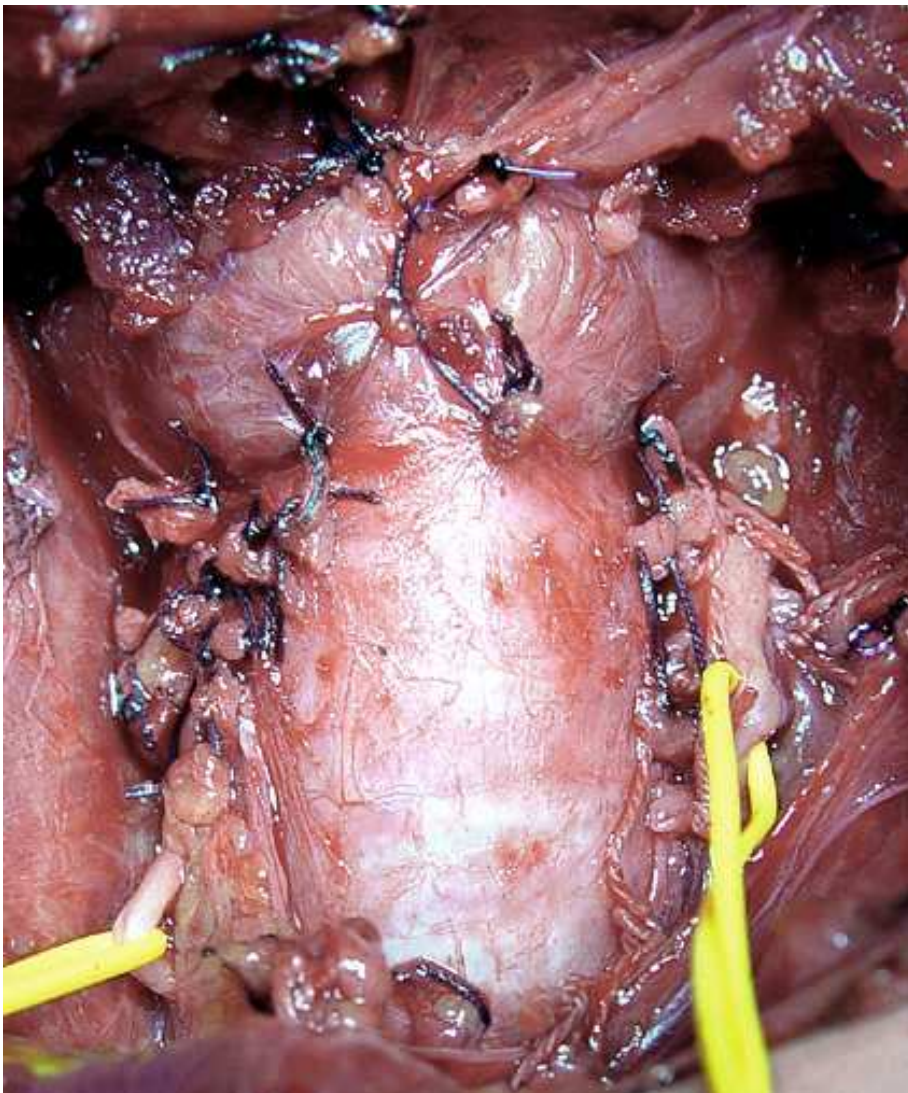
Isolamento dell'arteria tiroidea e del nervo laringeo inferiore destro (ricorrente)



Lobo destro - Istmo - Residuo lobo sinistro (superficie anteriore)

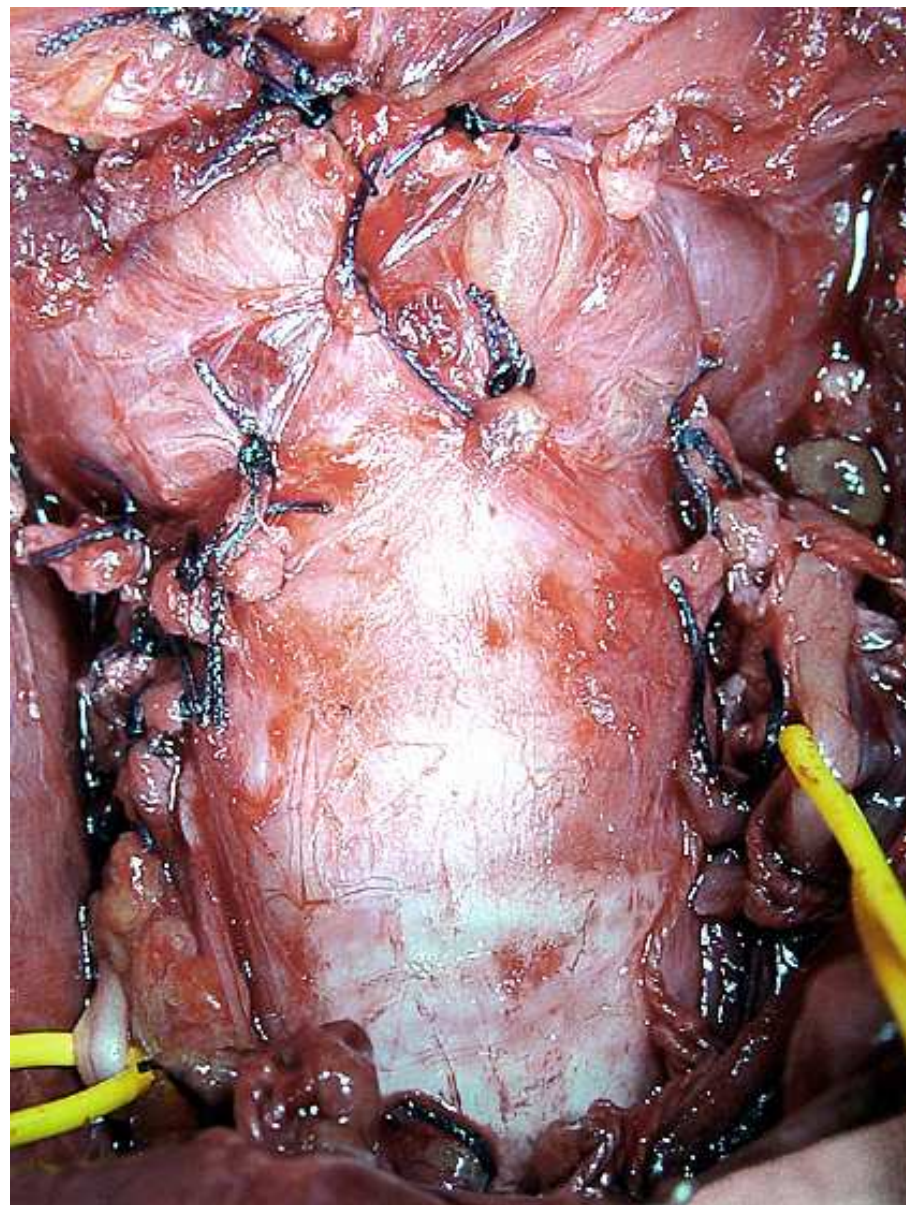


Residuo lobo sinistro - Istmo - Lobo destro (superficie posteriore)

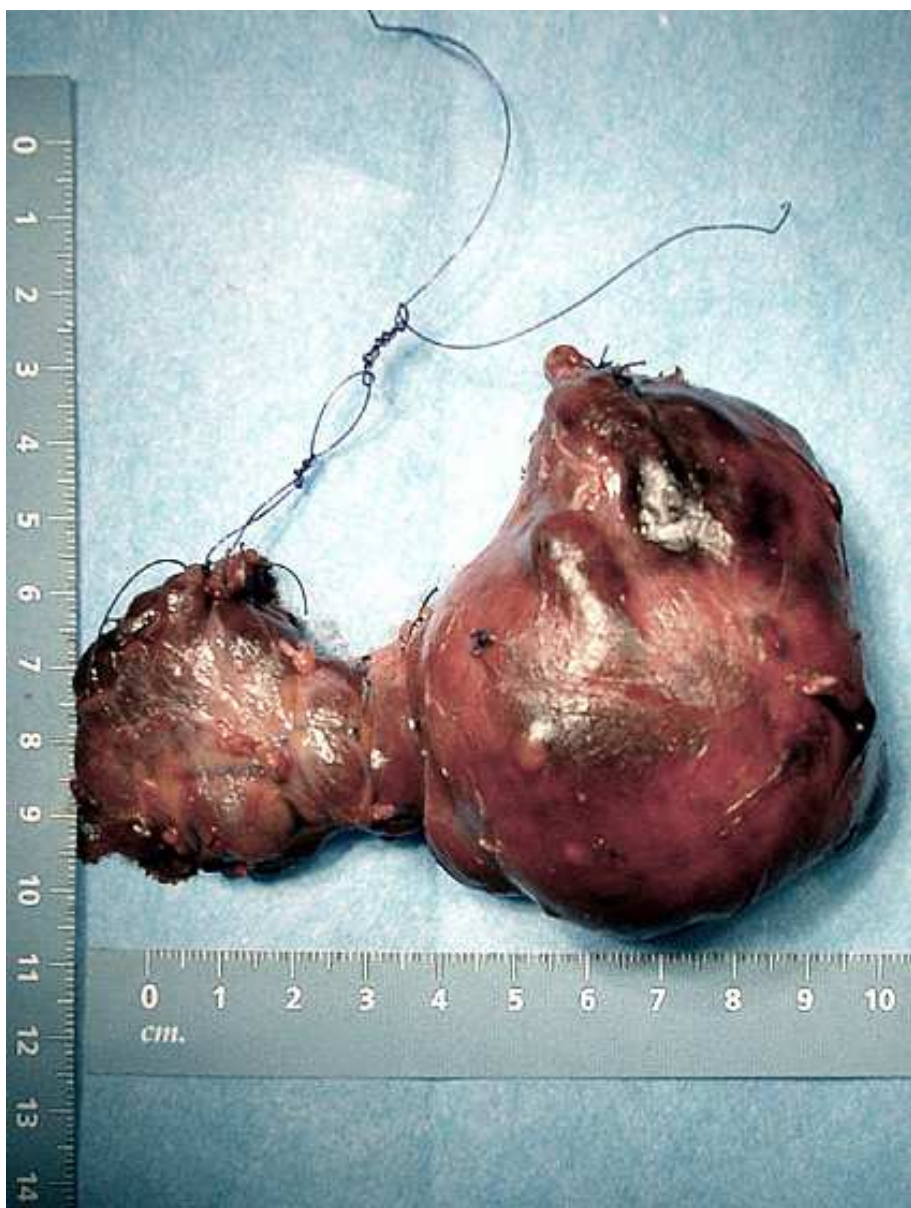

C.S. • Anni: 47 - F • Record: 27 • 16-03-2002

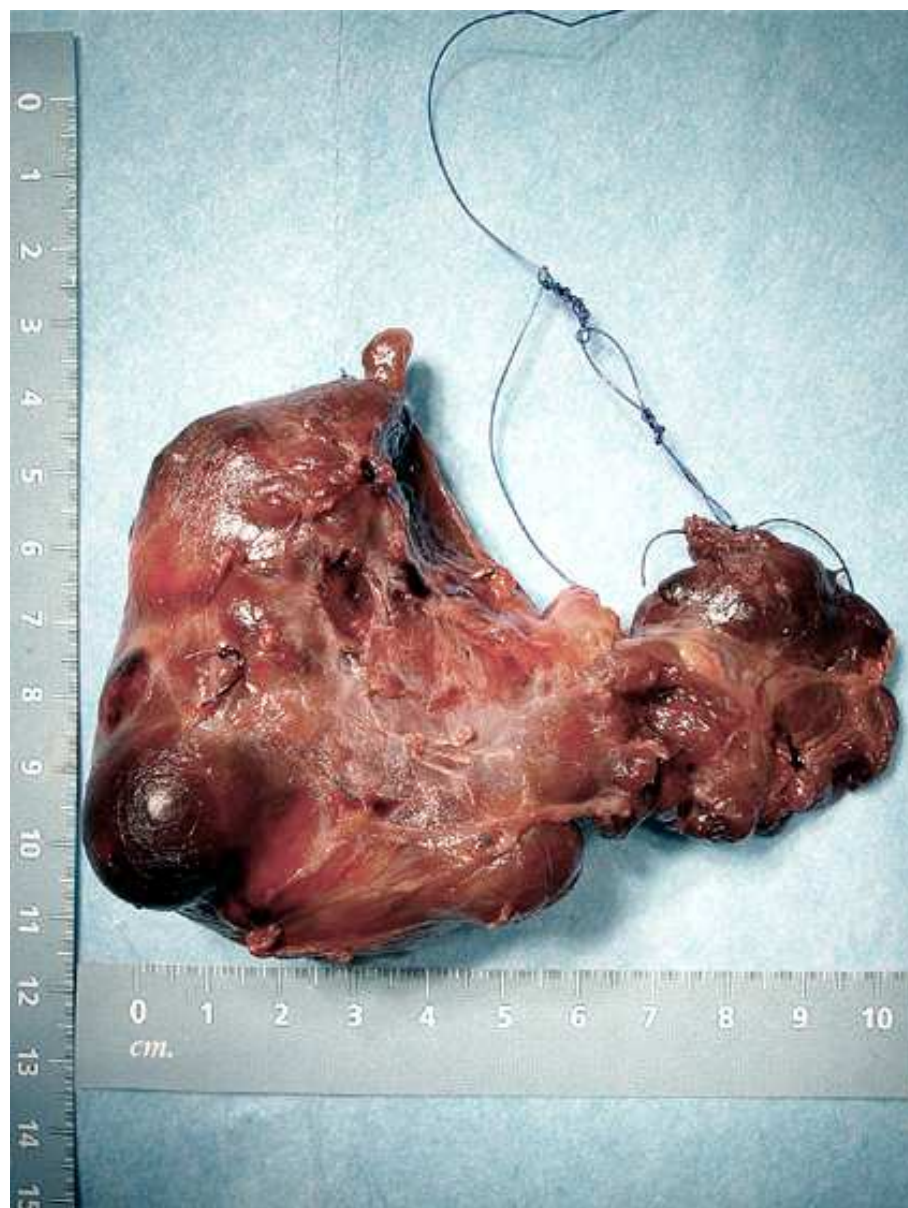
Tiroidectomia totale extracapsulare per gozzo plurinodulare plongeant a sn



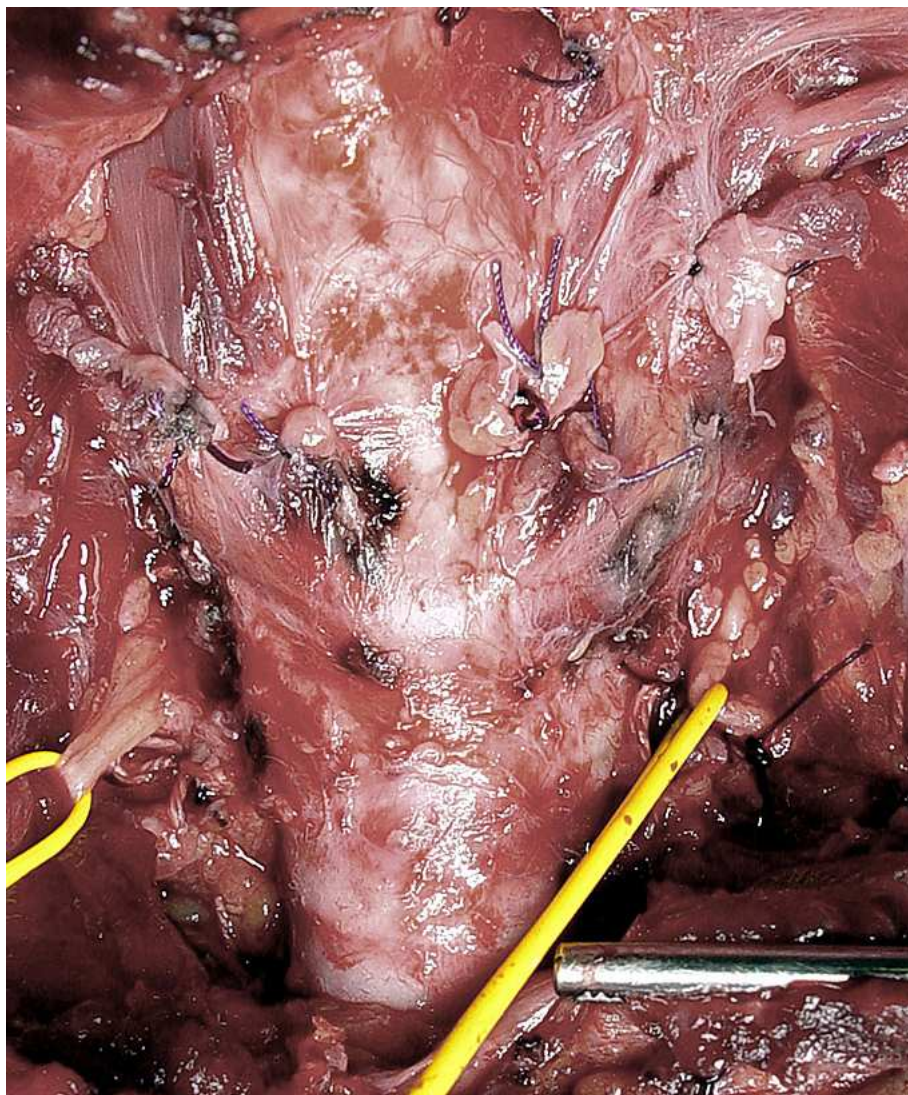
Isolamento dei nervi laringei inferiori (ricorrenti)



Lobo destro - Istmo - Lobo sinistro (superficie anteriore)

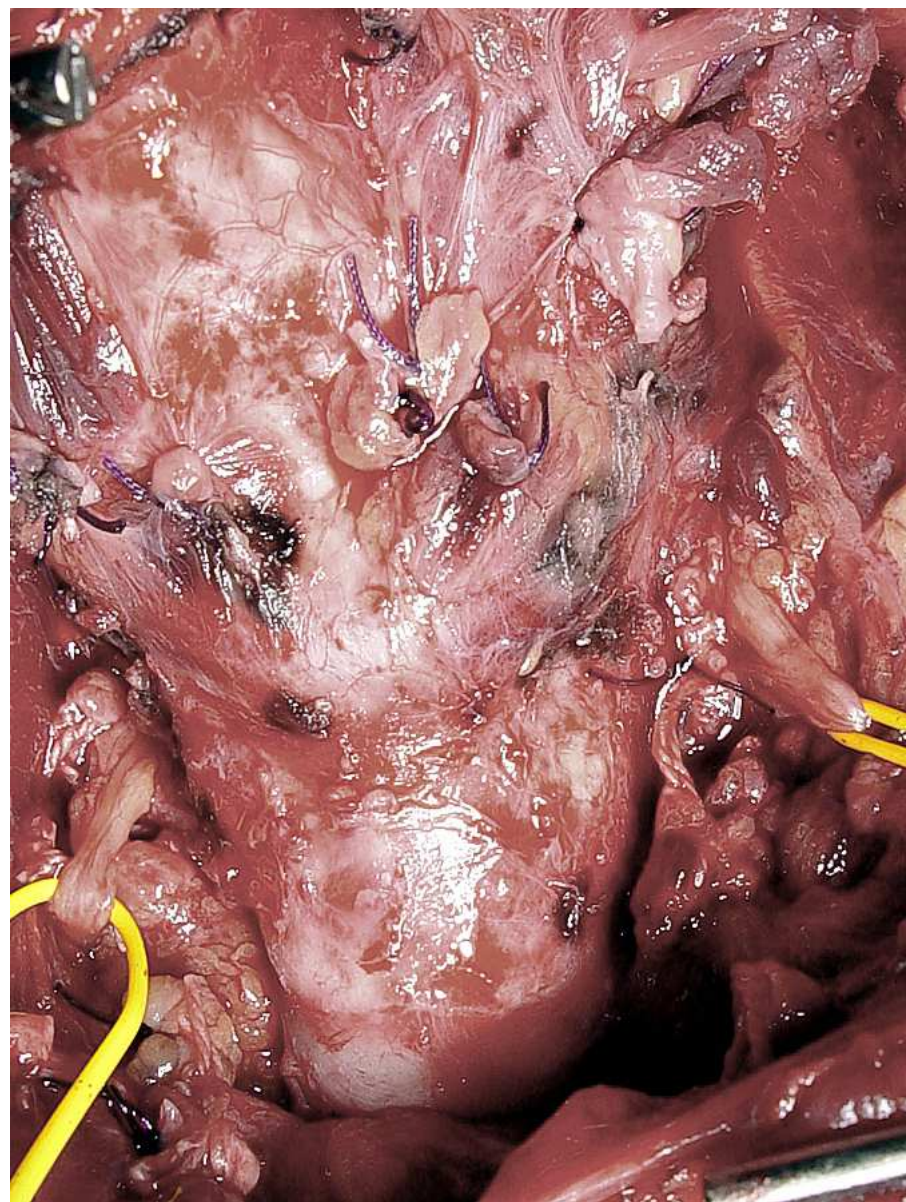


Lobo sinistro - Istmo - Lobo destro (superficie posteriore)

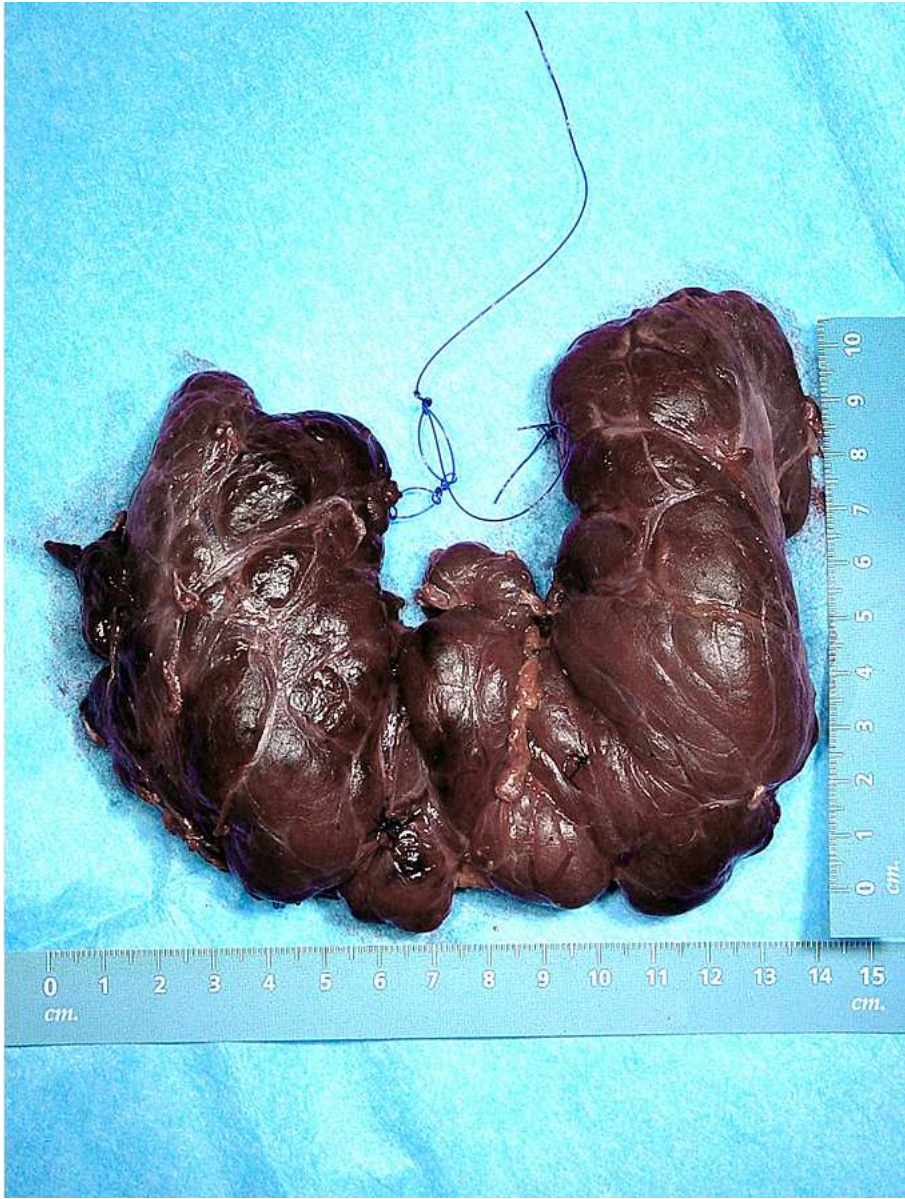

P.L. • Anni: 47 - M • Record: 28 • 20-03-2002

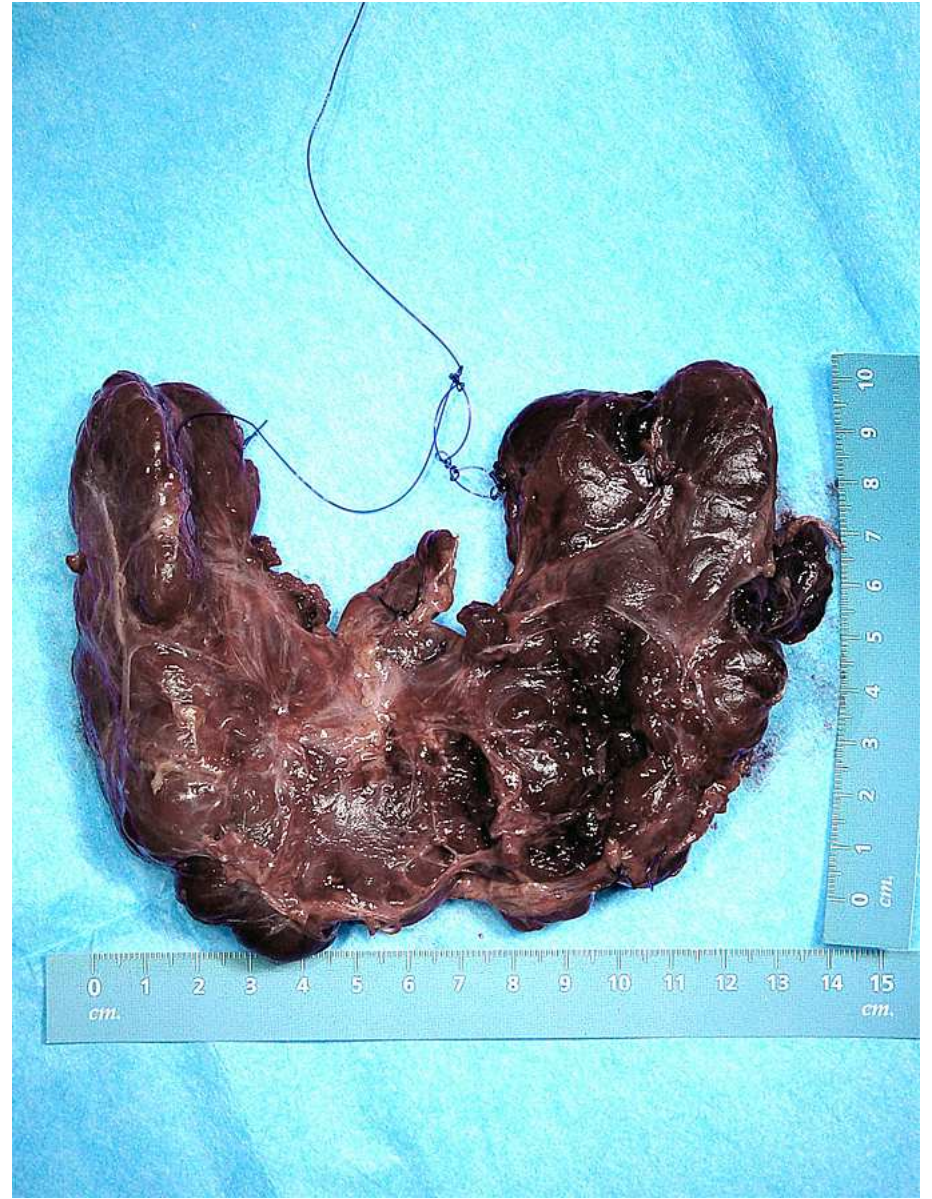Tiroidectomia totale extracapsulare per gozzo plurinodulare tossico plongeant



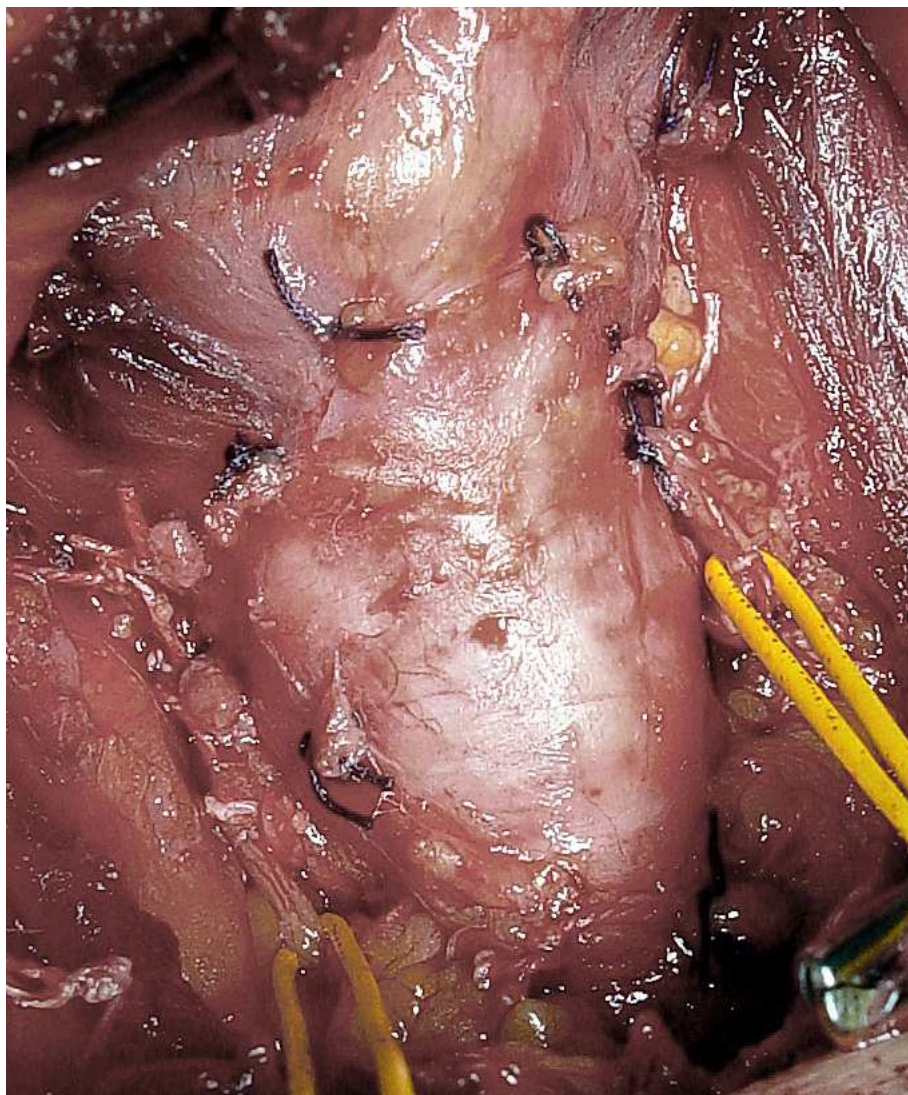
Isolamento dei nervi laringei inferiori (ricorrenti)



Lobo destro - Istmo - Lobo sinistro (superficie anteriore)

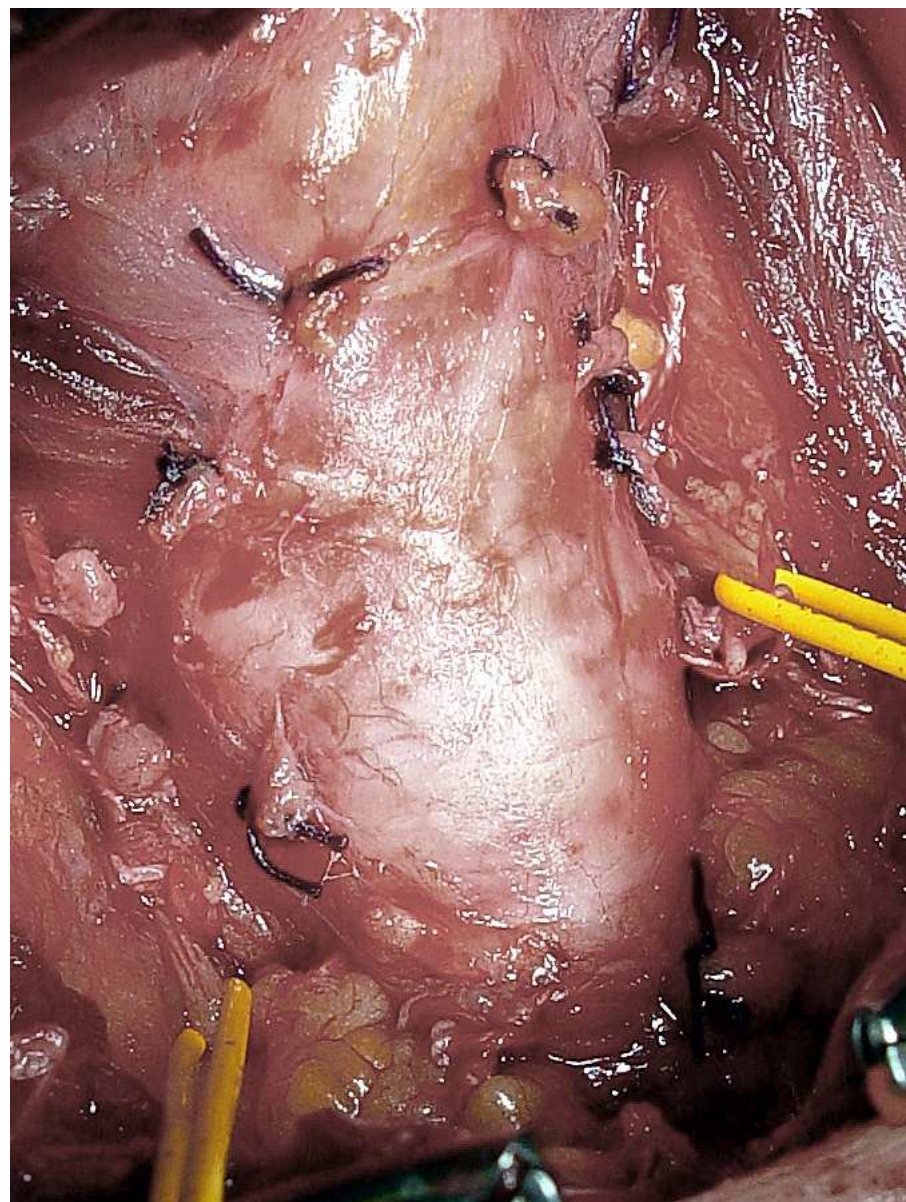


Lobo sinistro - Istmo - Lobo destro (superficie posteriore)



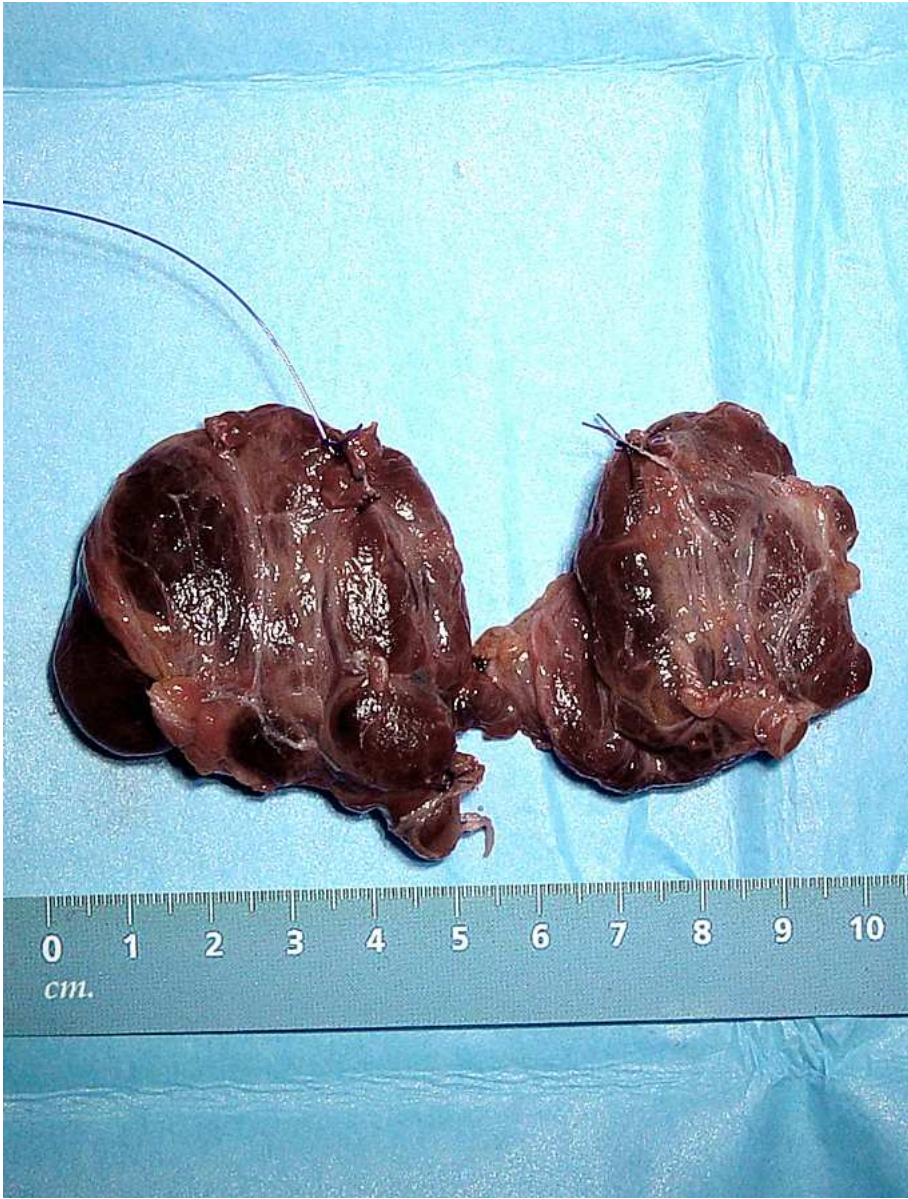F.G. • Anni: 63 - M • Record: 29 • 03-04-2002

Tiroidectomia totale extracapsulare per gozzo plurinodulare

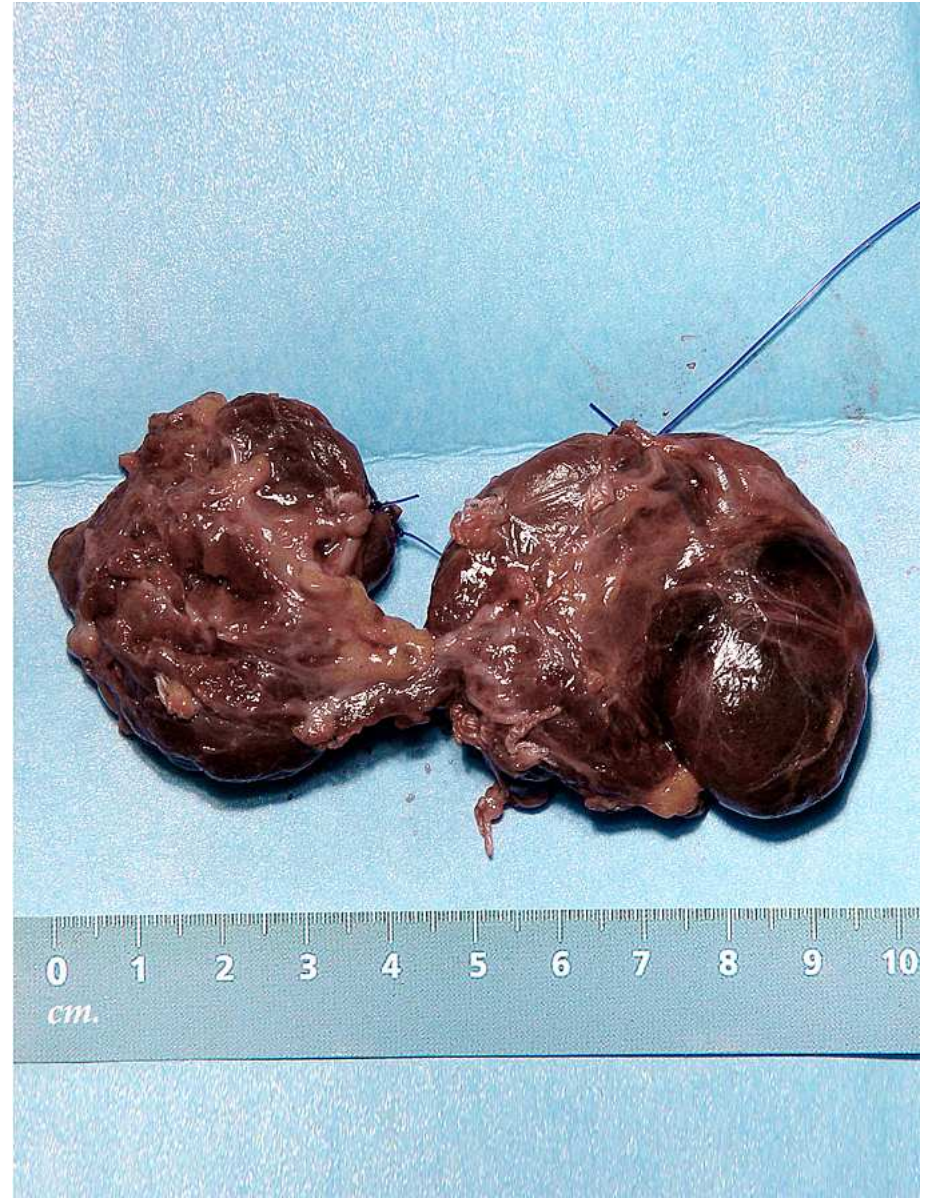

Isolamento dei nervi laringei inferiori (ricorrenti)

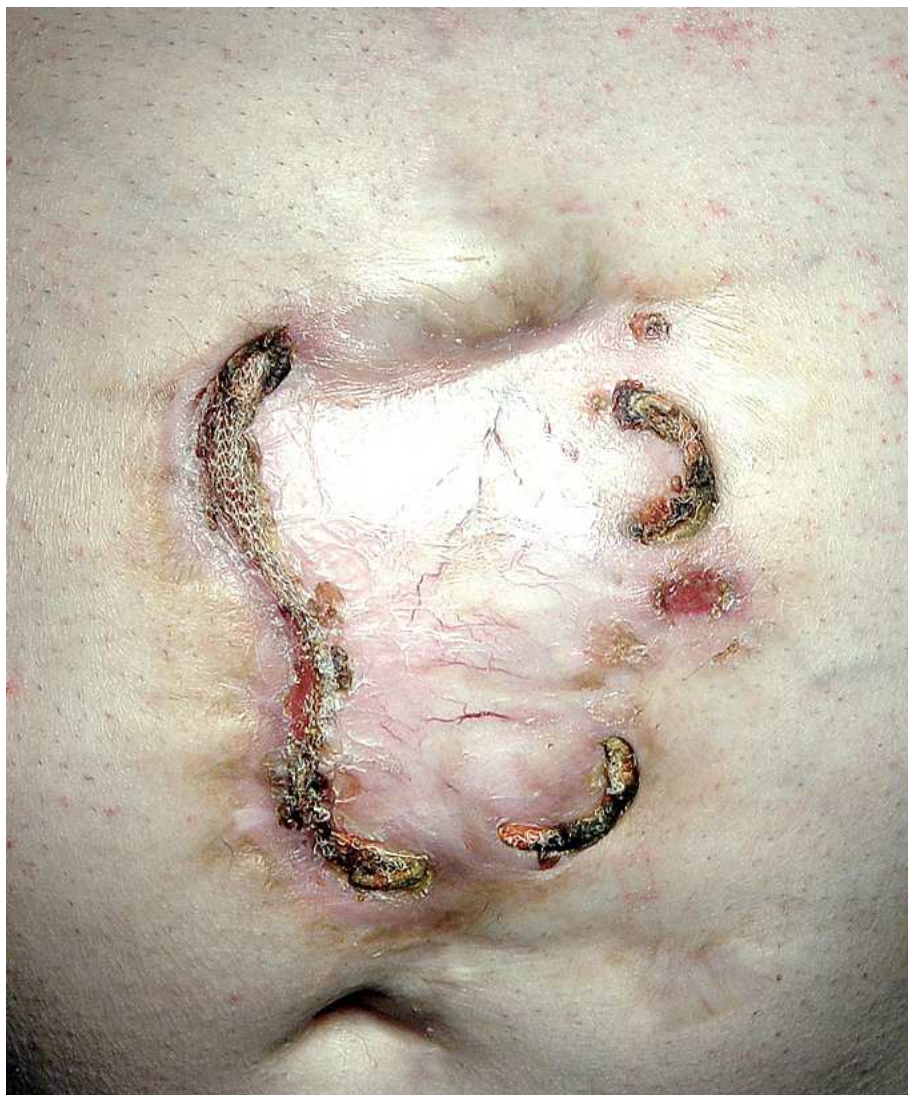



Lobo destro - Istmo - Lobo sinistro (superficie anteriore)

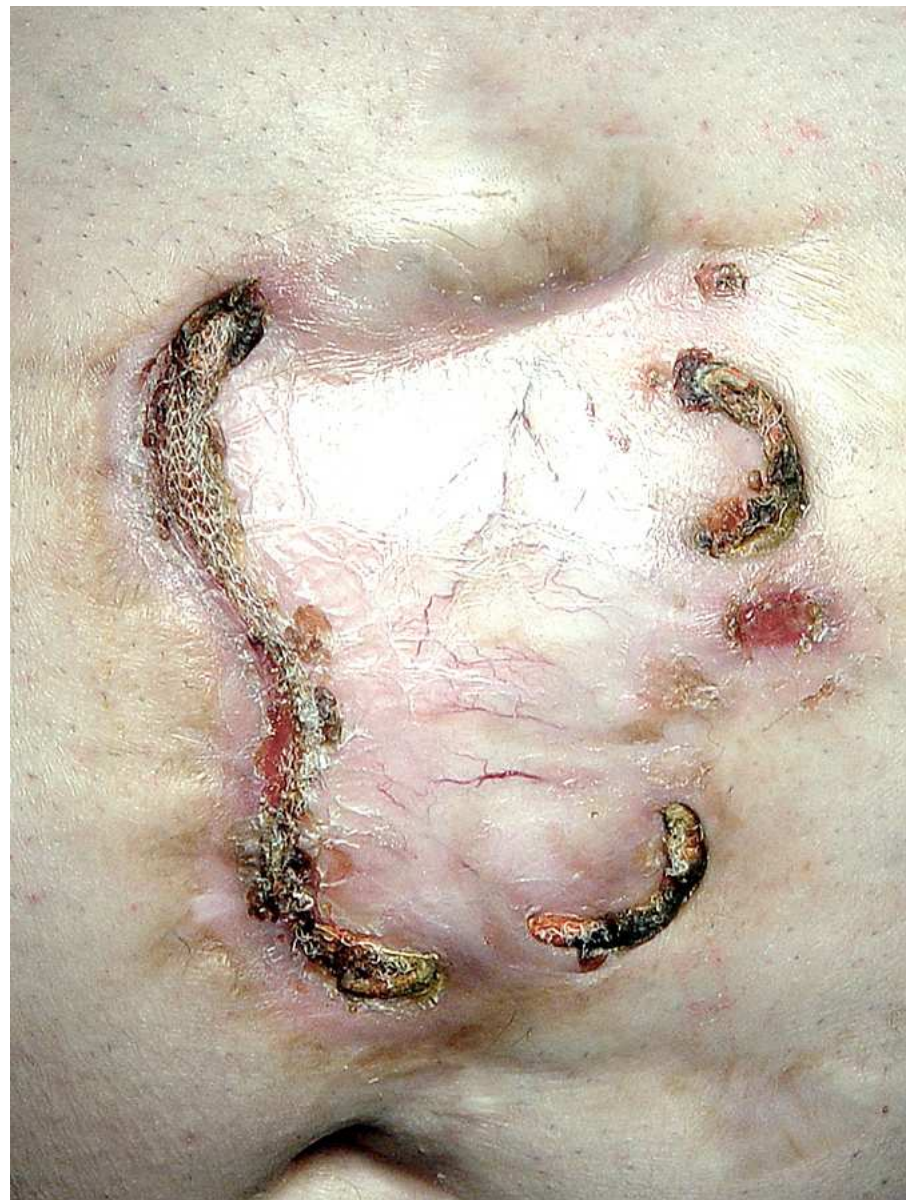

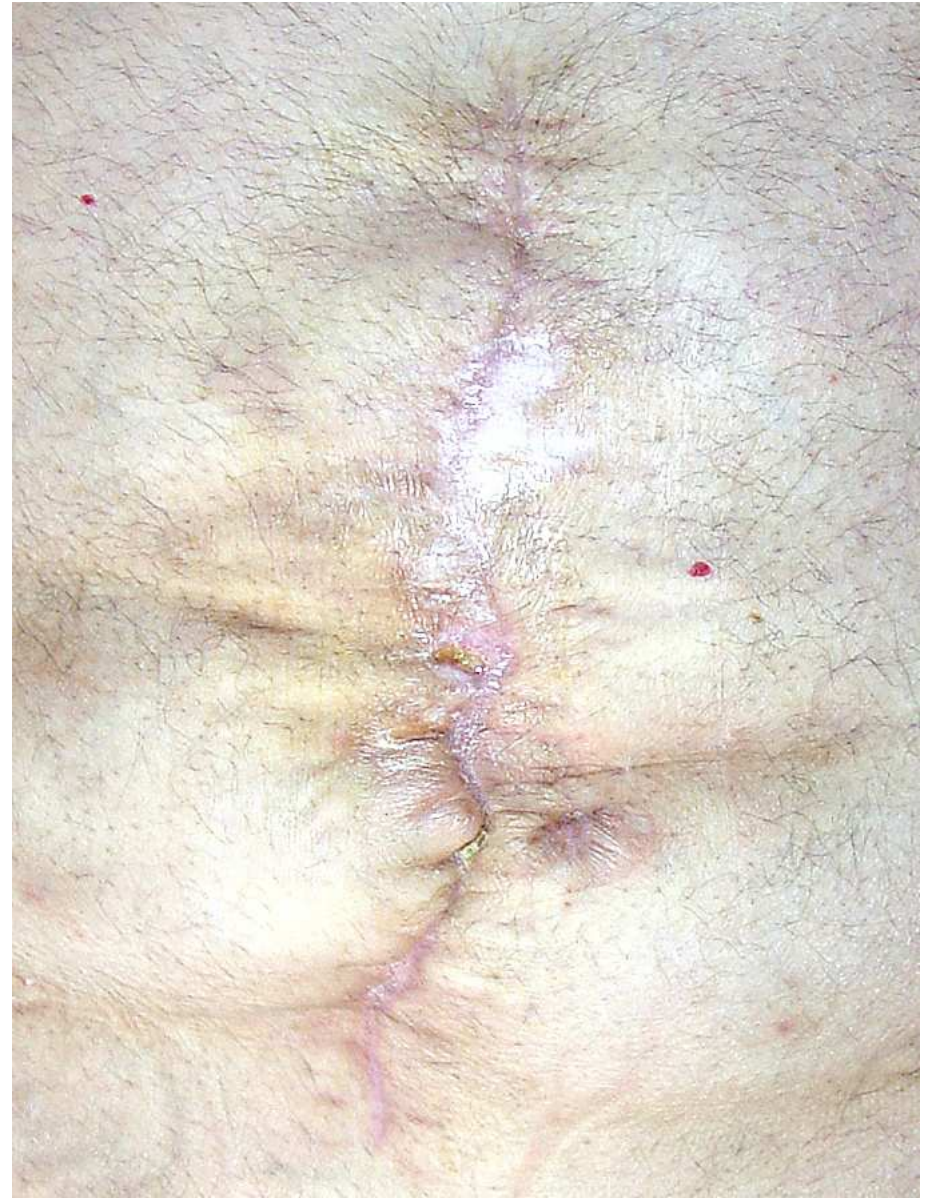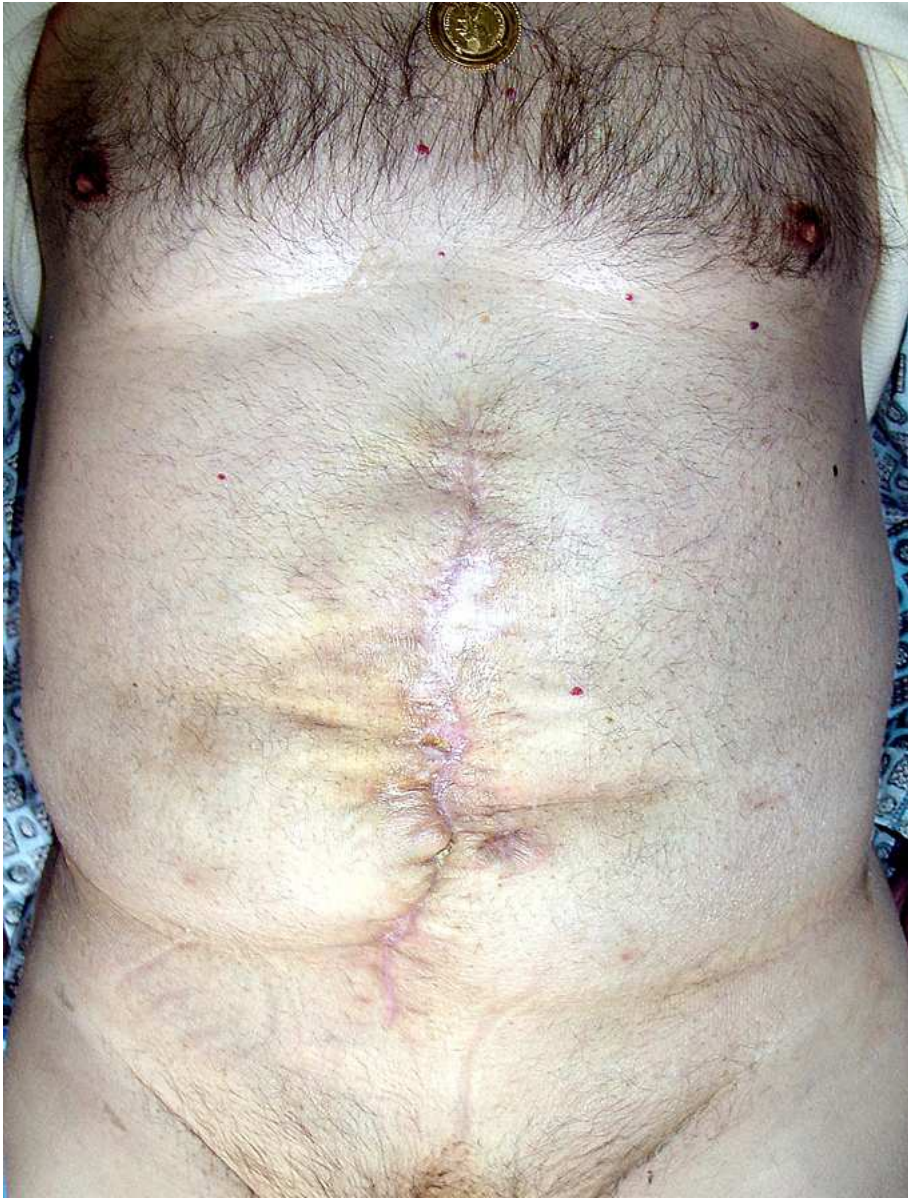Lobo sinistro - Istmo - Lobo destro (superficie posteriore)

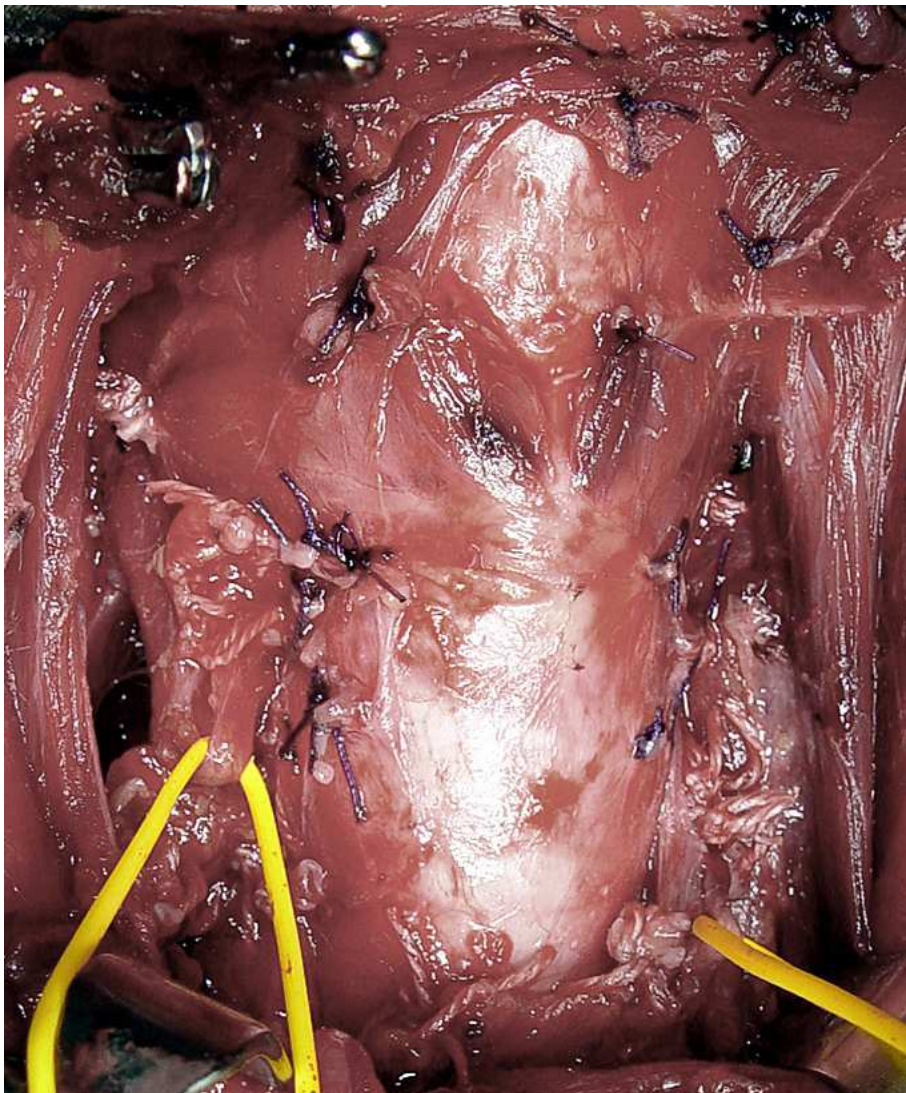


T.V. · Anni: 72 - M · Record: 30 · 03-04-2002

Resezione ileale e laparoalloplastica per laparocele mediano recidivo in plurilaparotomizzato, iperteso, portatore di ACO arti inferiori

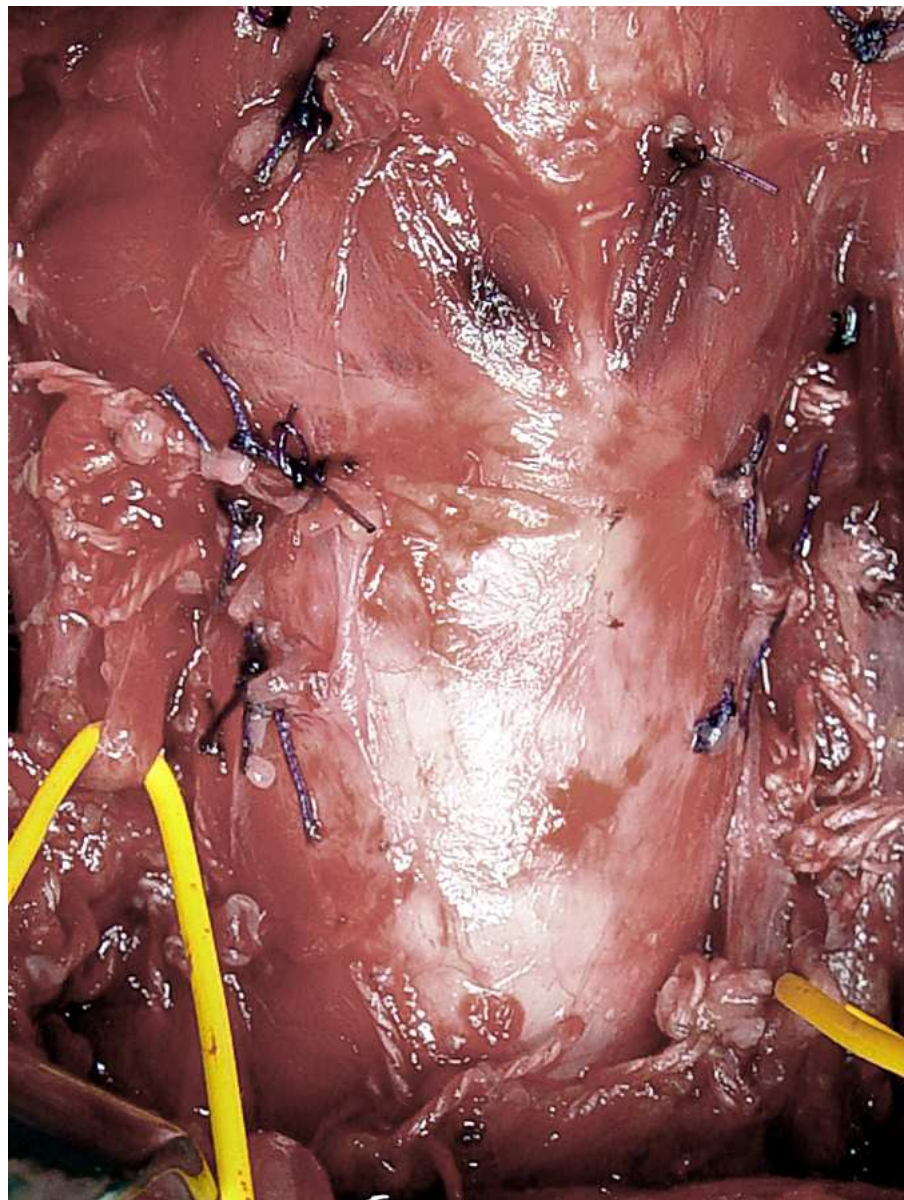




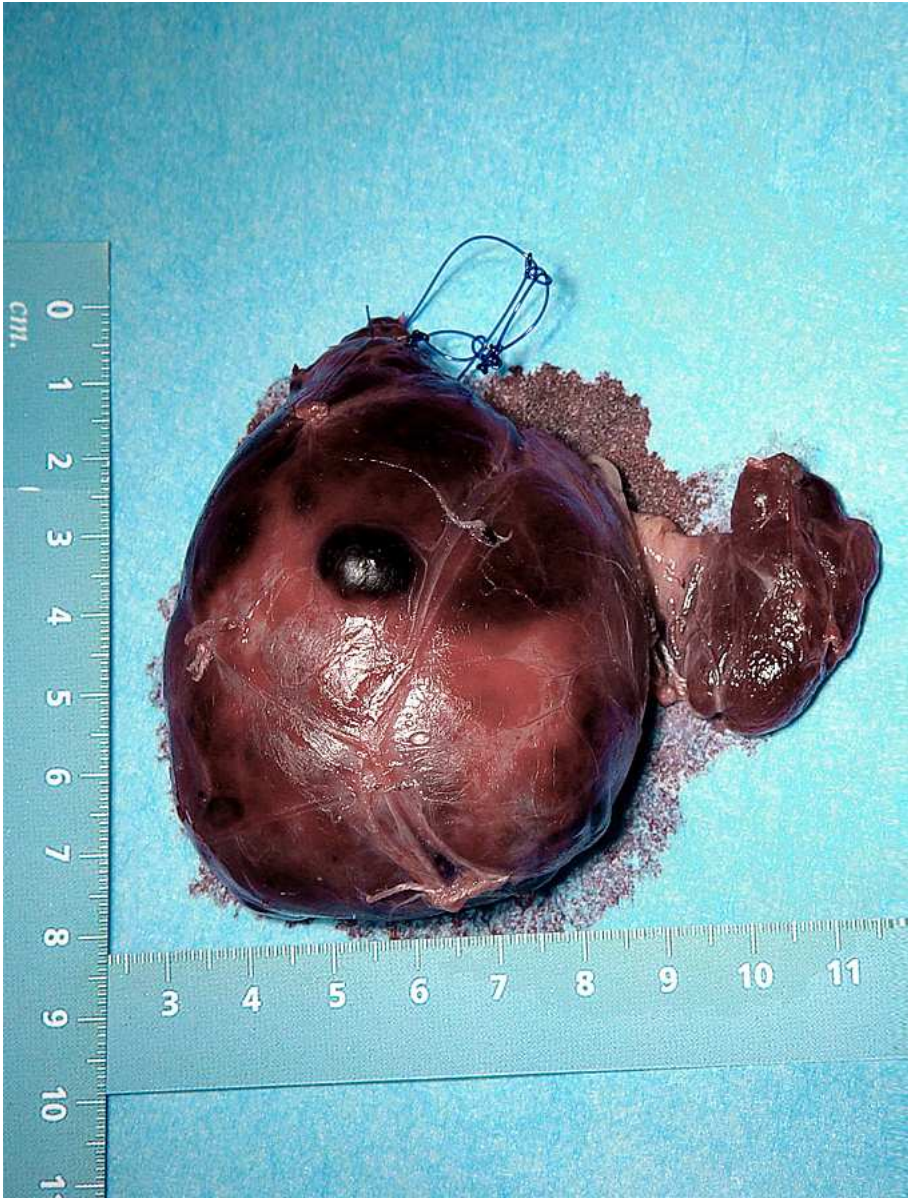

M.A. · Anni: 67 - F · Record: 31 · 06-04-2002

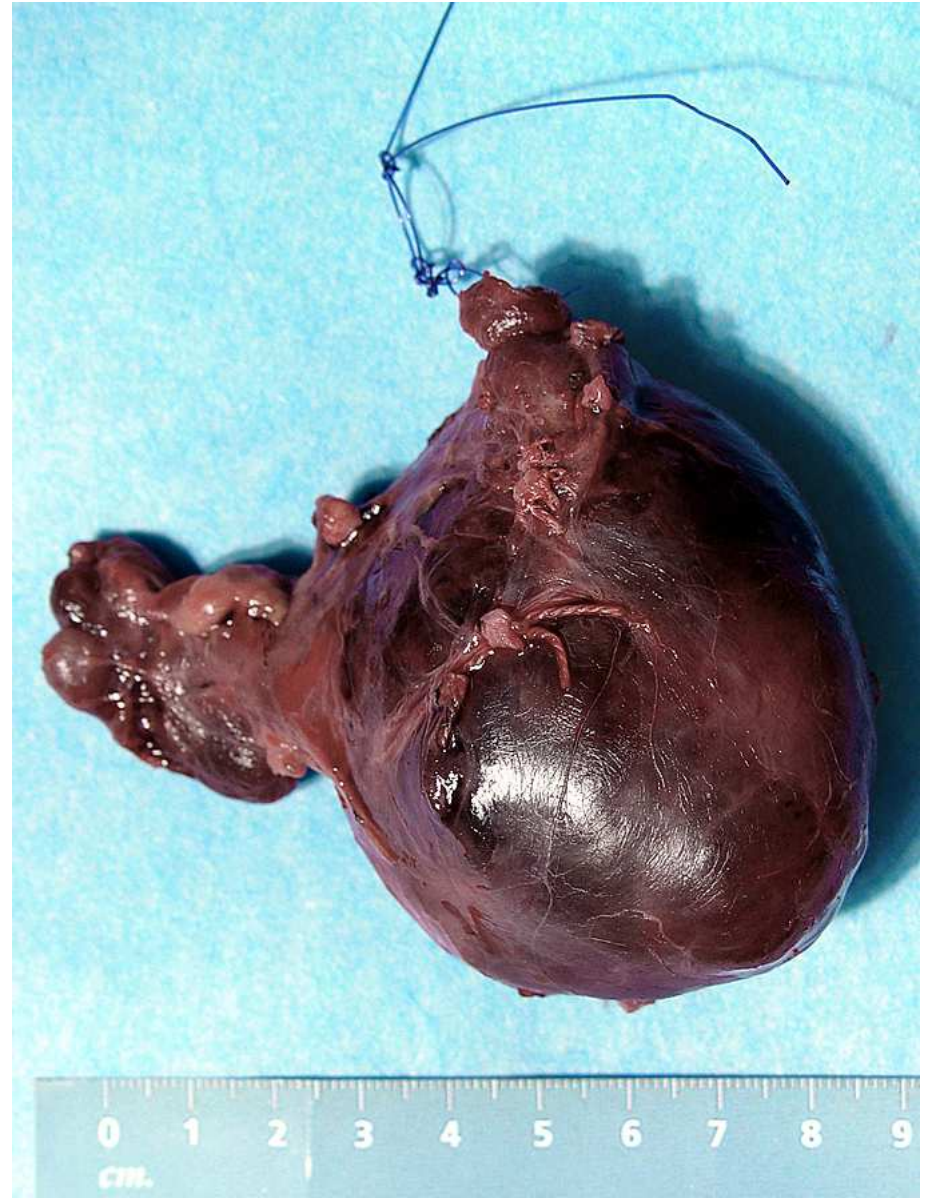
Tiroidectomia totale extracapsulare per gozzo plurinodulare plongeant a dx



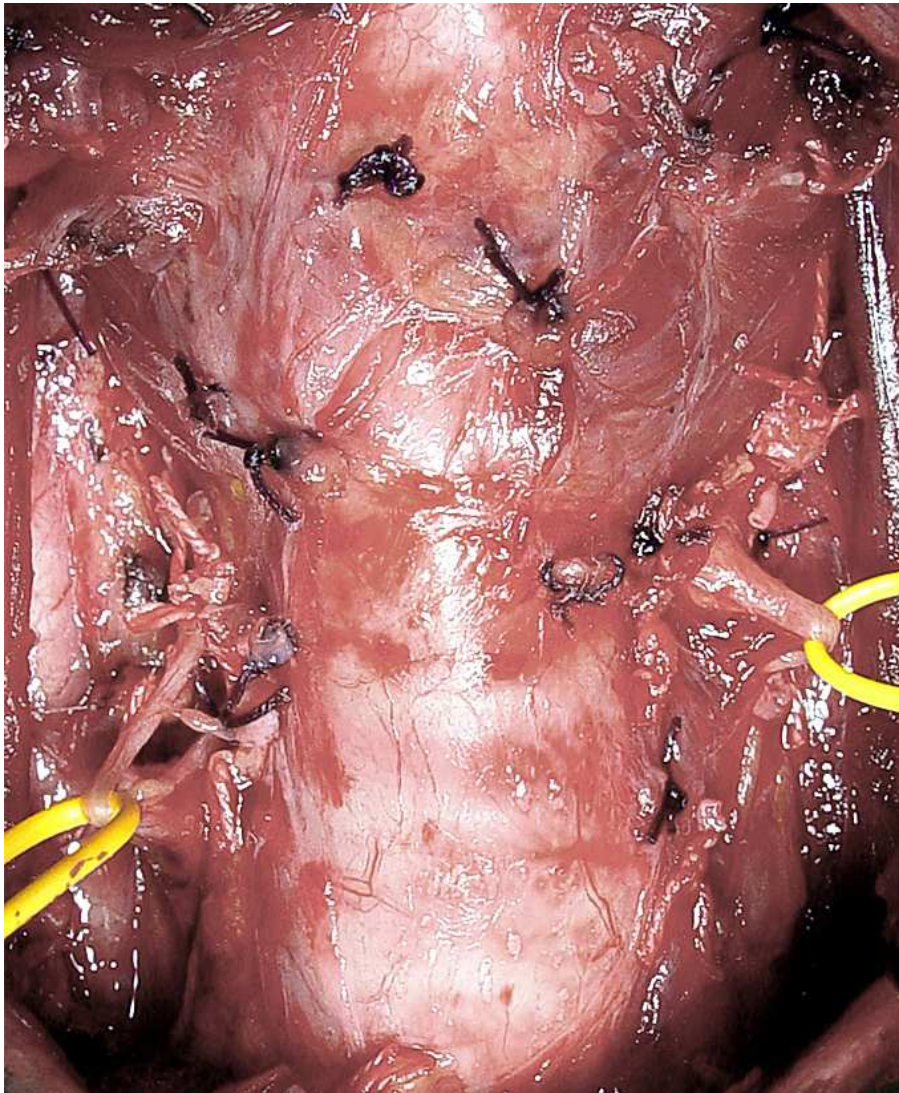
Isolamento dei nervi laringei inferiori (ricorrenti)



Lobo destro - Istmo - Lobo sinistro (superficie anteriore)

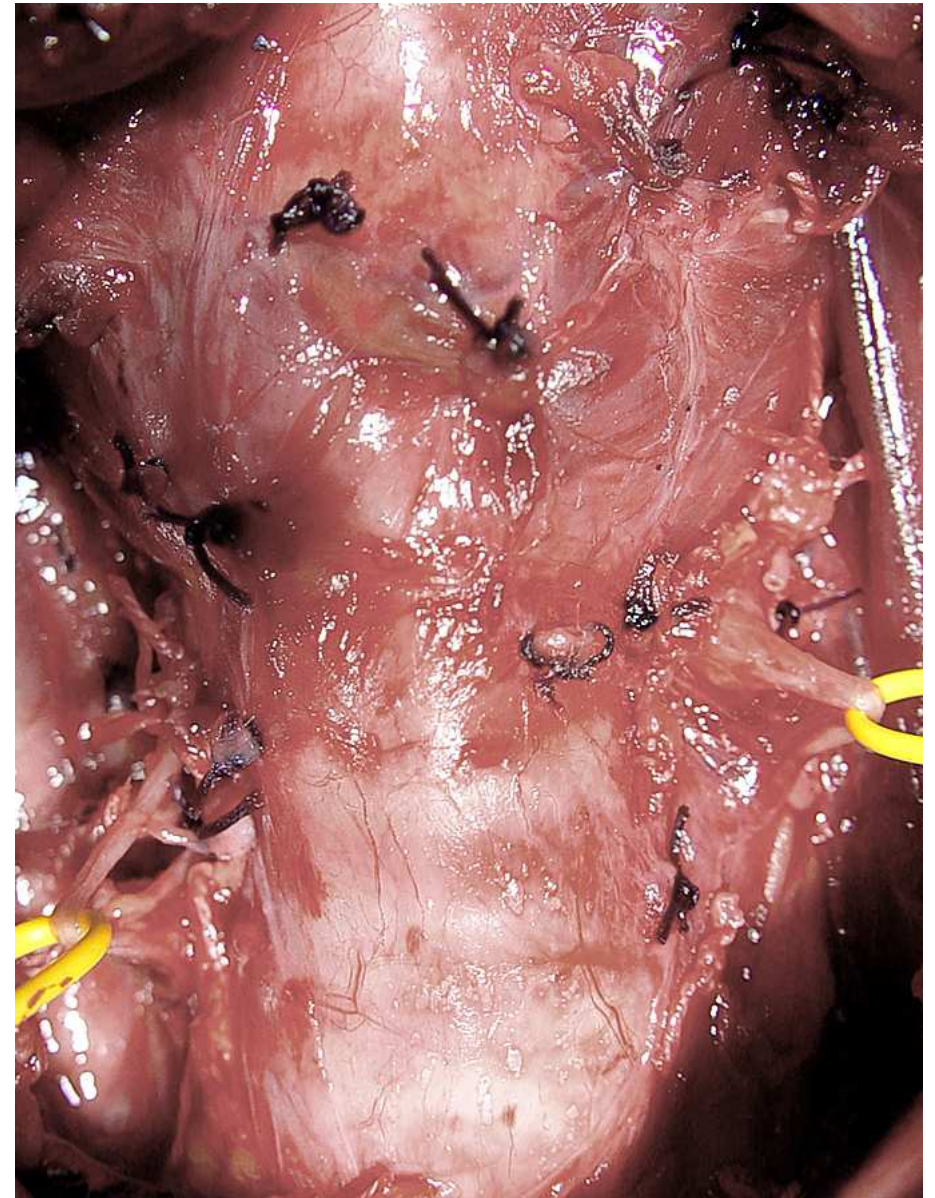


Lobo sinistro - Istmo - Lobo destro (superficie posteriore)

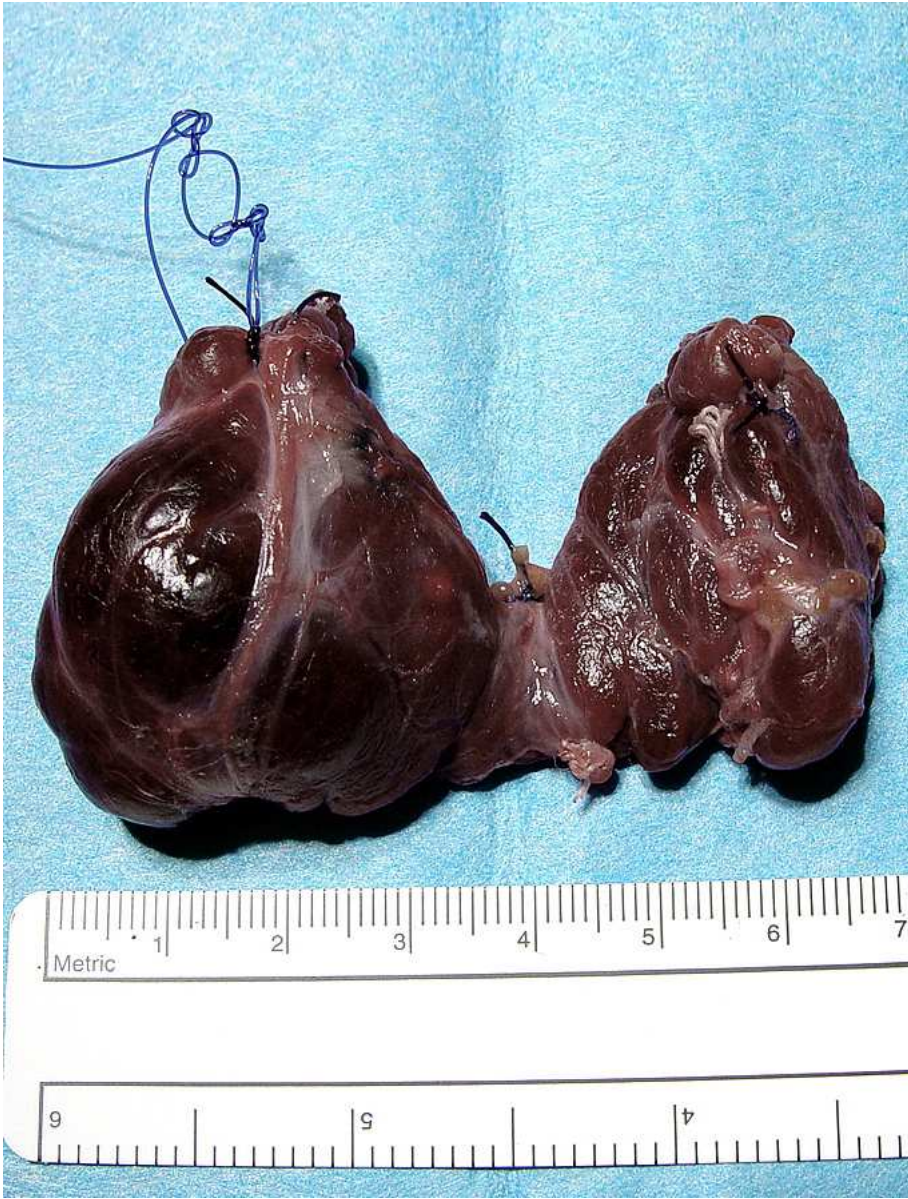

A.L. • Anni: 55 - F • Record: 32 • 10-04-2002

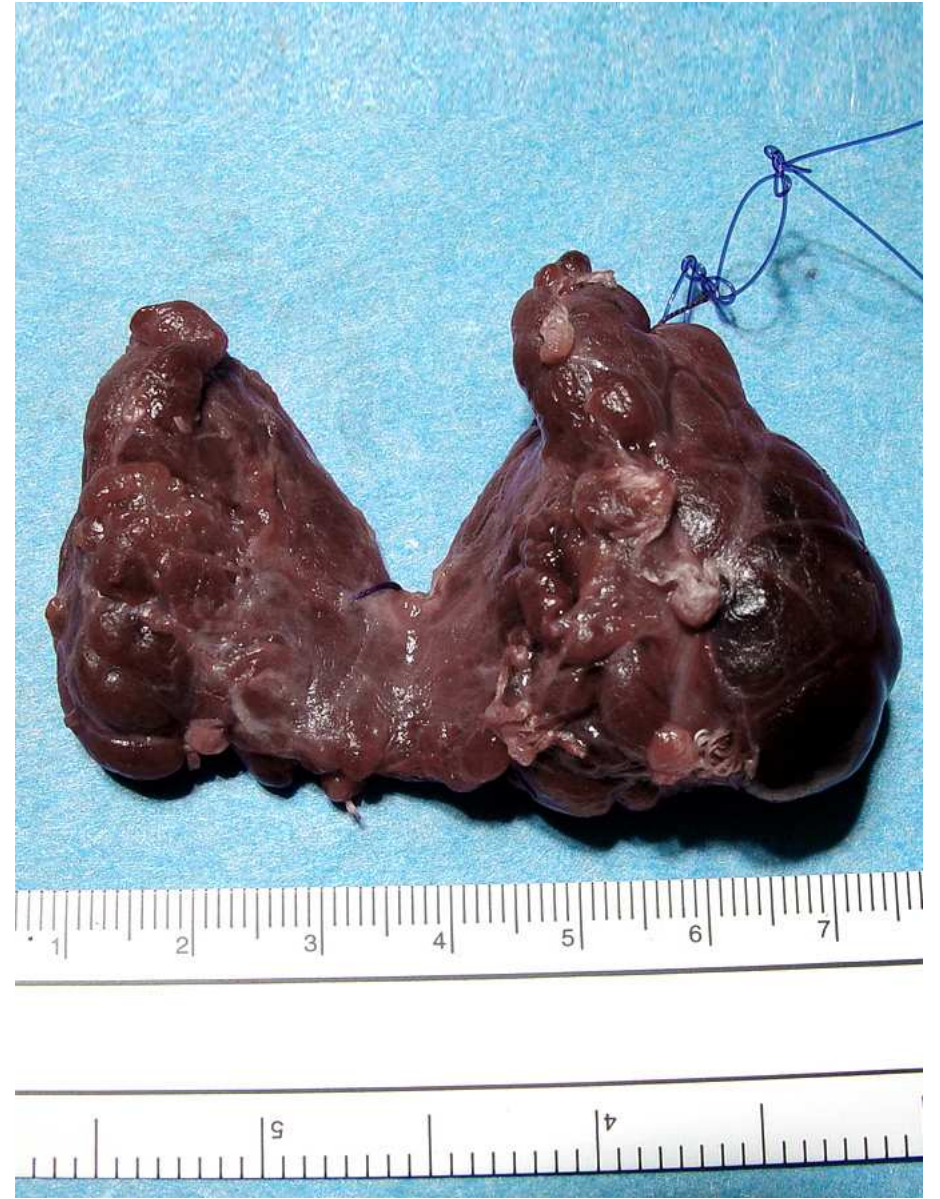Tiroidectomia totale extracapsulare per adenoma tossico del lobo destro in gozzo plurinodulare



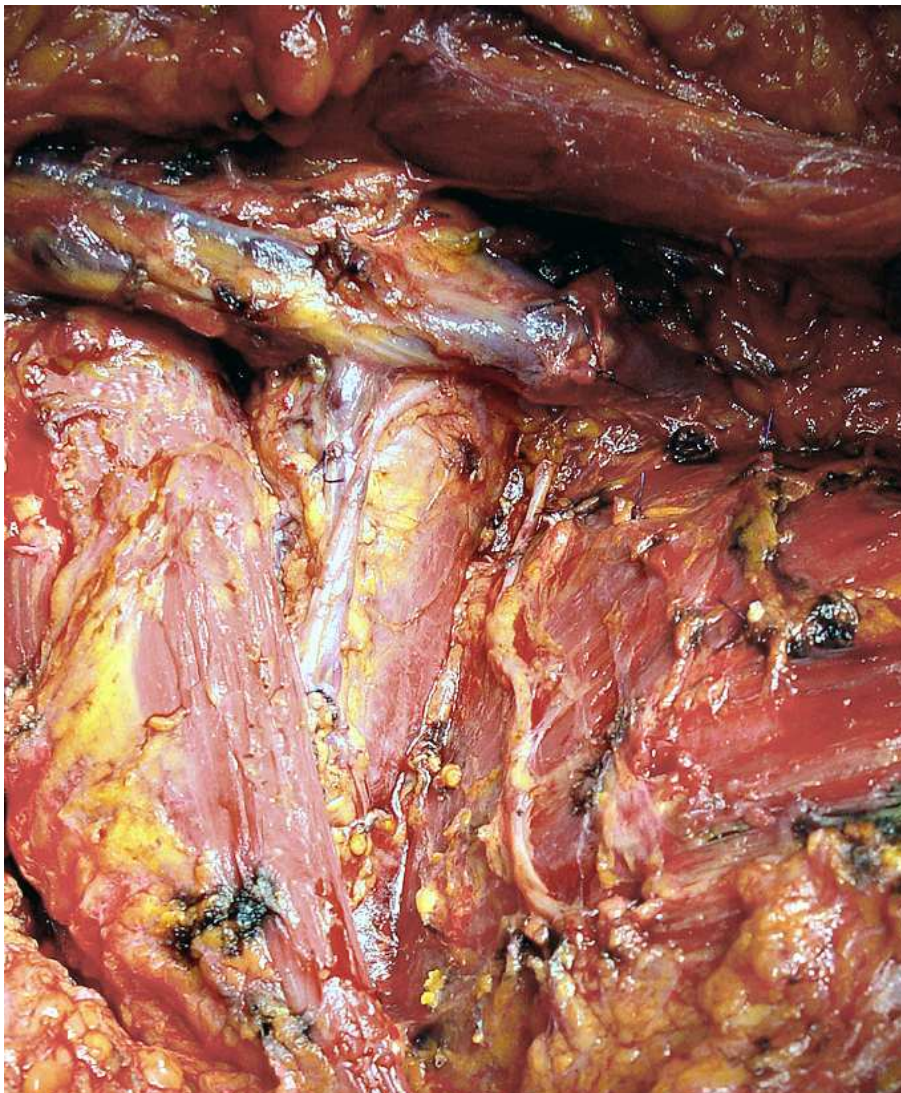Isolamento dei nervi laringei inferiori (ricorrenti)



Lobo destro - Istmo - Lobo sinistro (superficie anteriore)

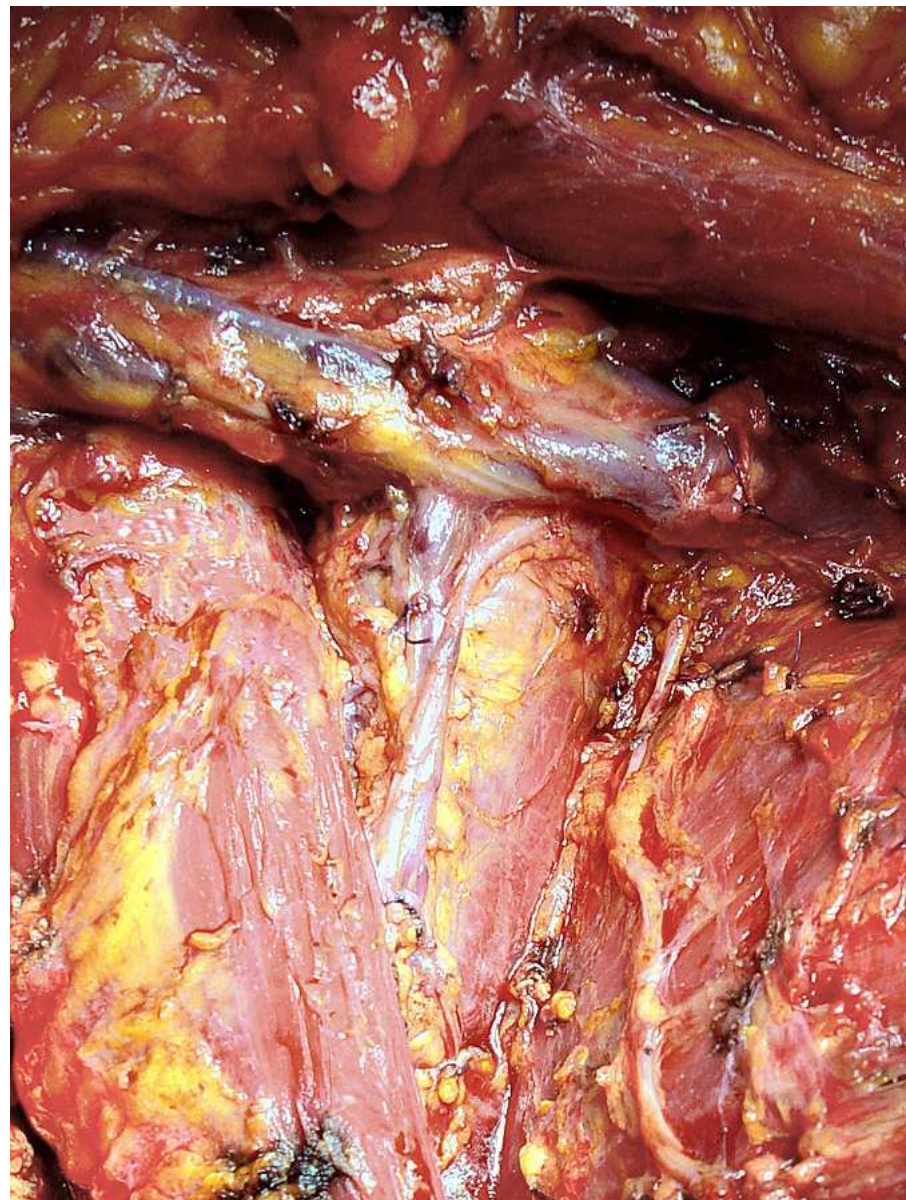


Lobo sinistro - Istmo - Lobo destro (superficie posteriore)

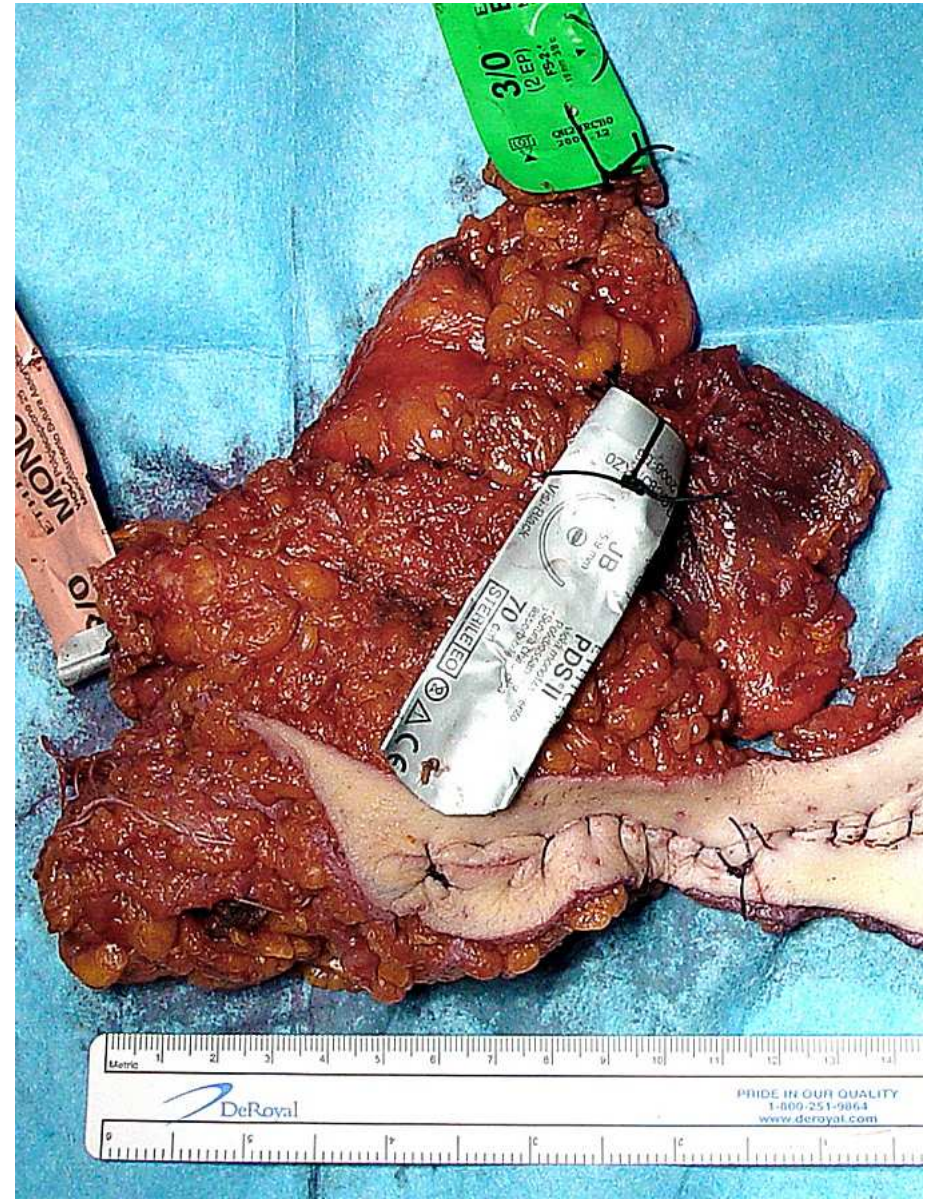
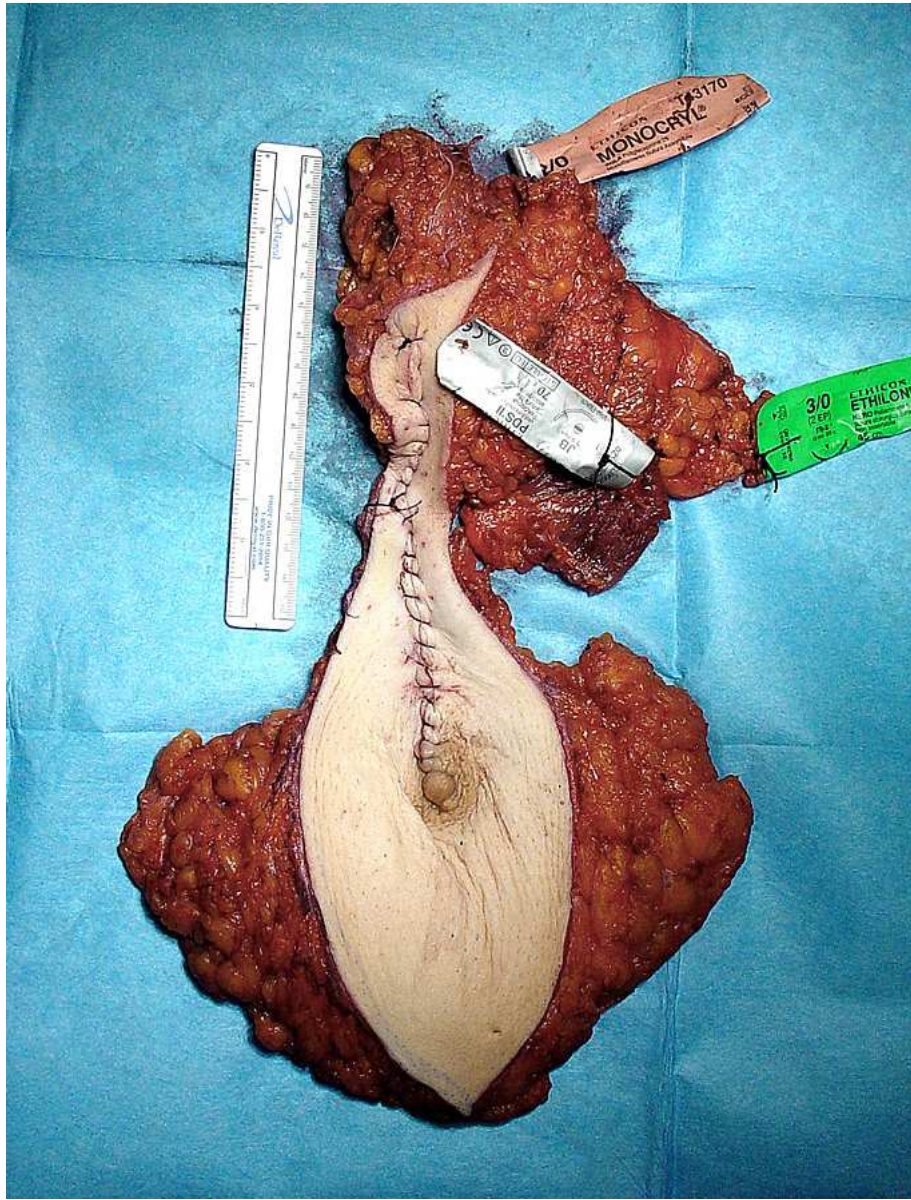


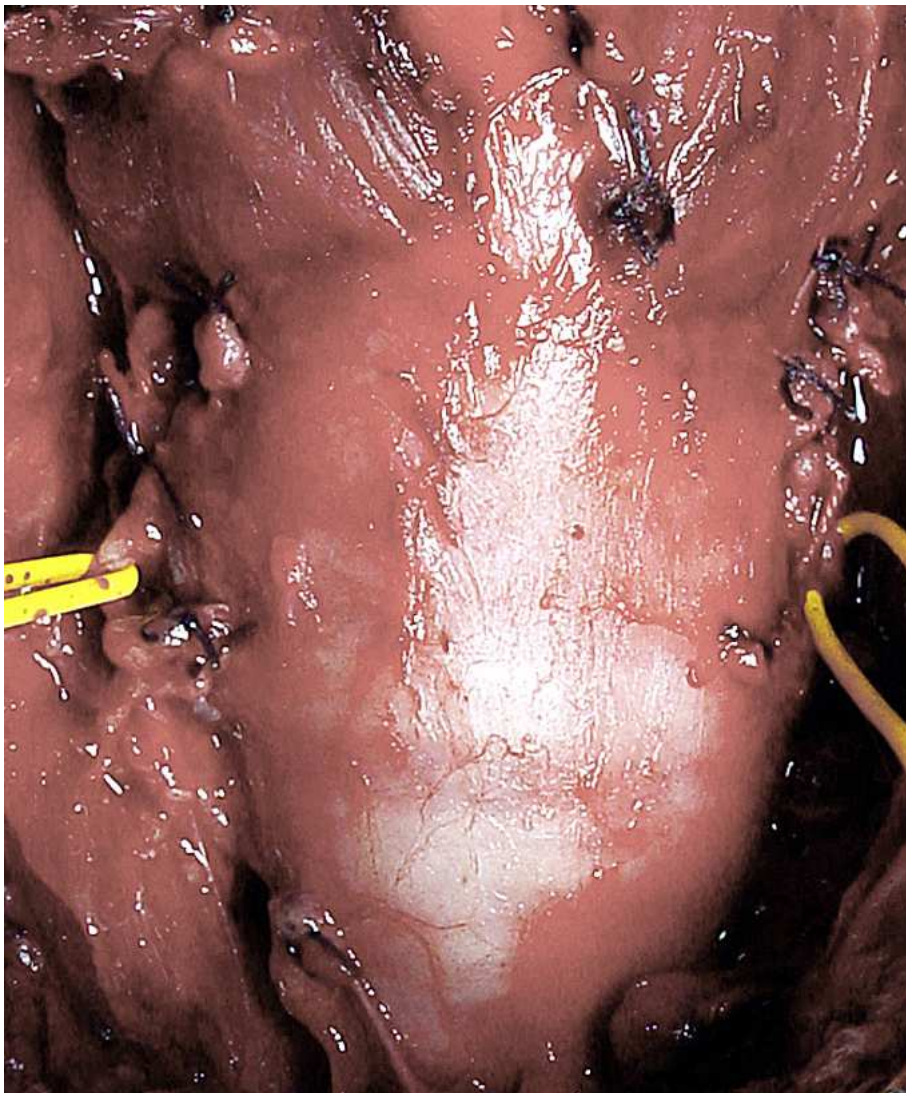
D.I. • Anni: 46 - F • Record: 33 • 13-04-2002

Mastectomia radicale modificata sec. Patey con svuotamento ascellare in continuità per duplice carcinoma duttale del QSE dx



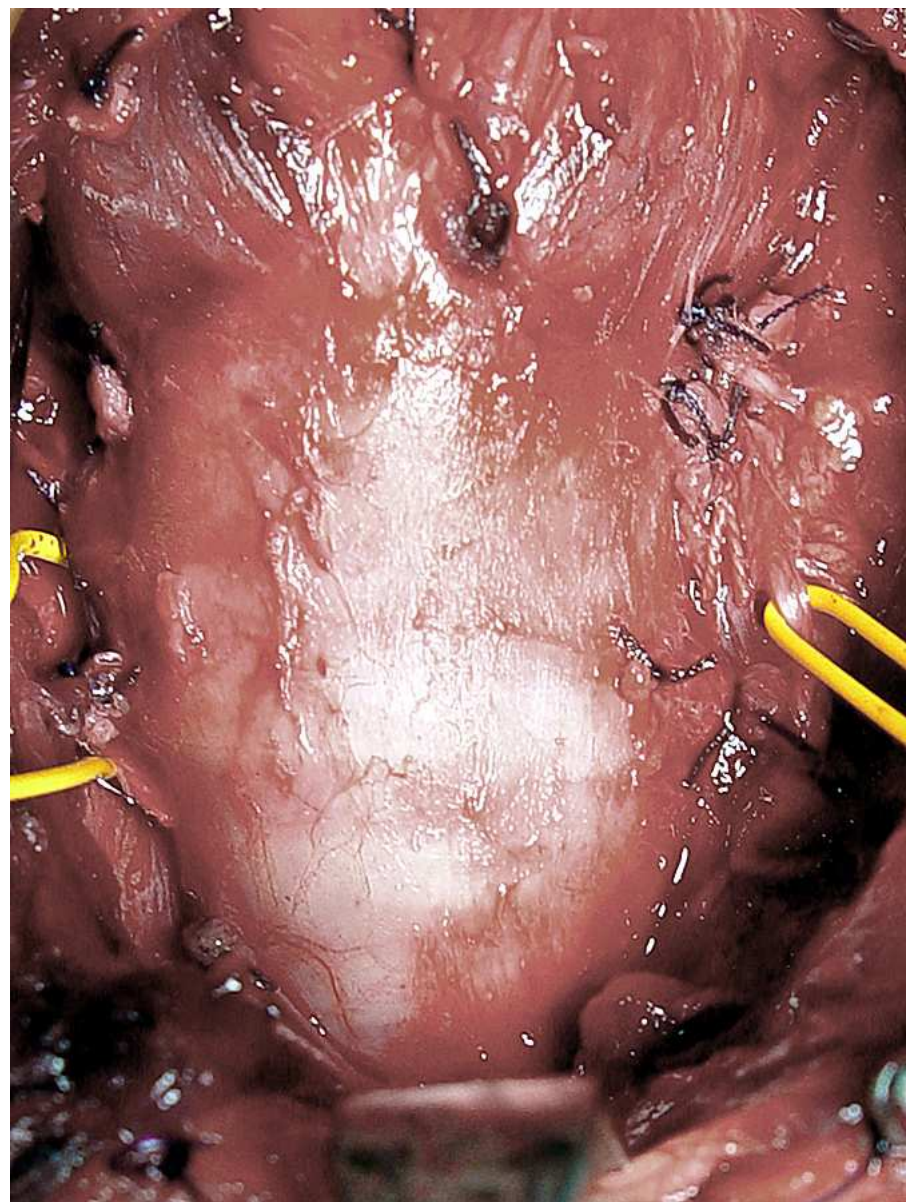




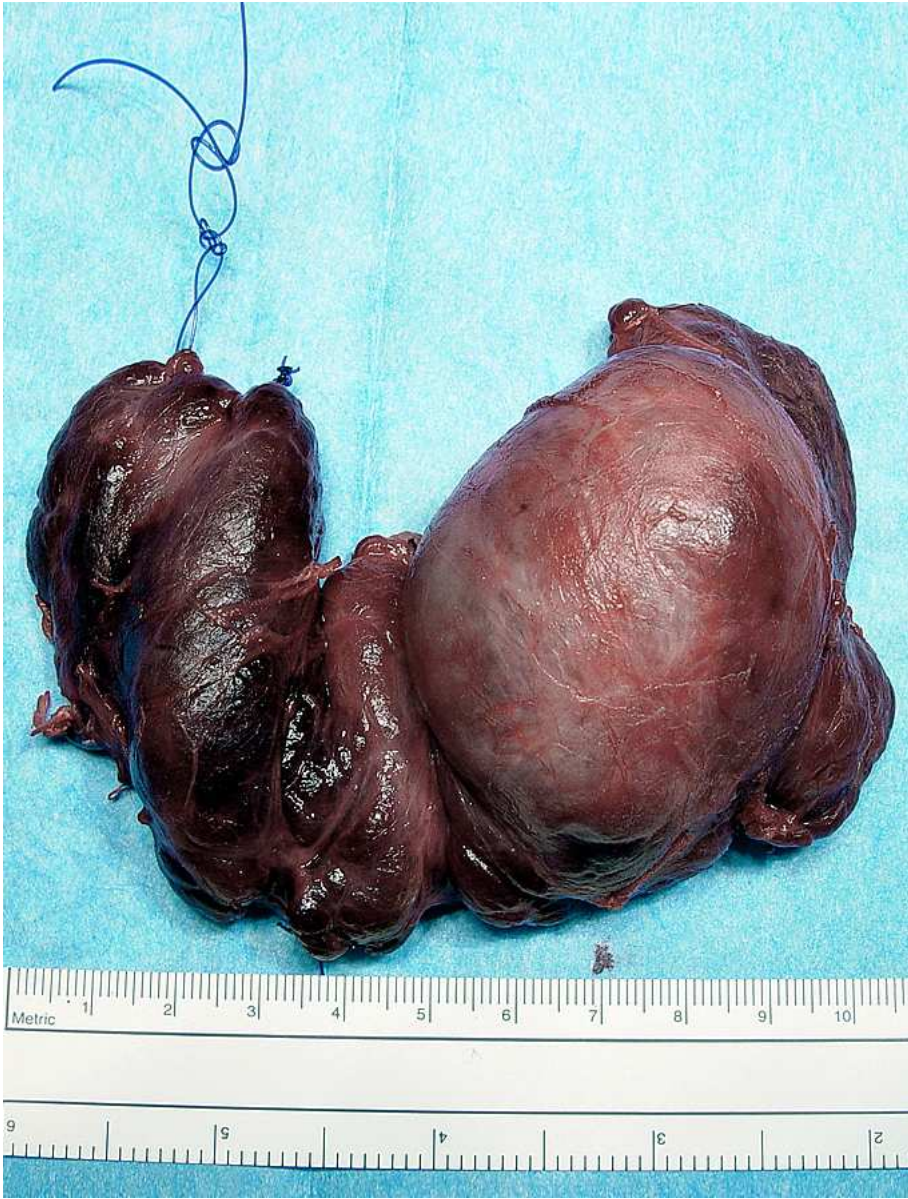

M.M. • Anni: 45 - M • Record: 34 • 14-04-2002

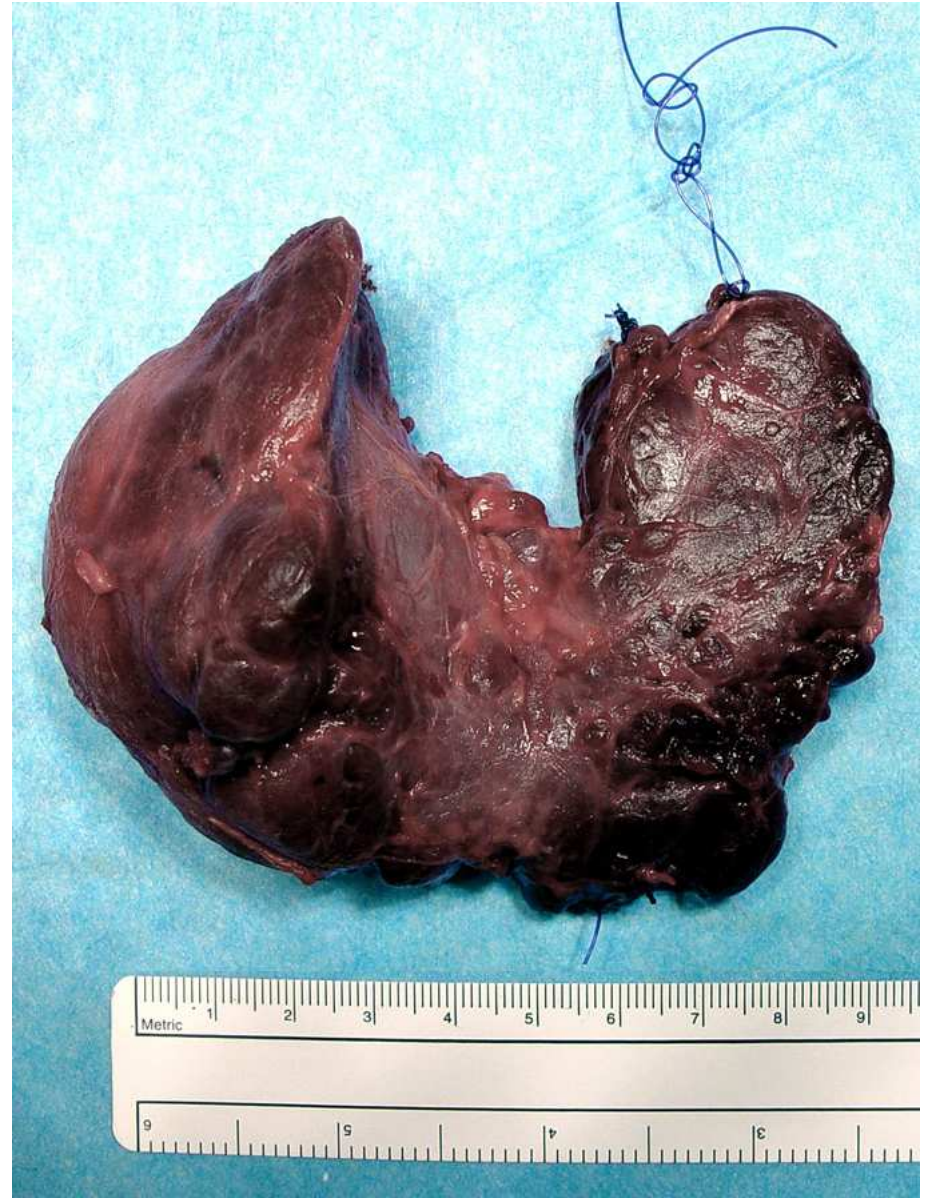Tiroidectomia totale extracapsulare per adenoma follicolare del lobo sn in gozzo plurinodulare plongeant



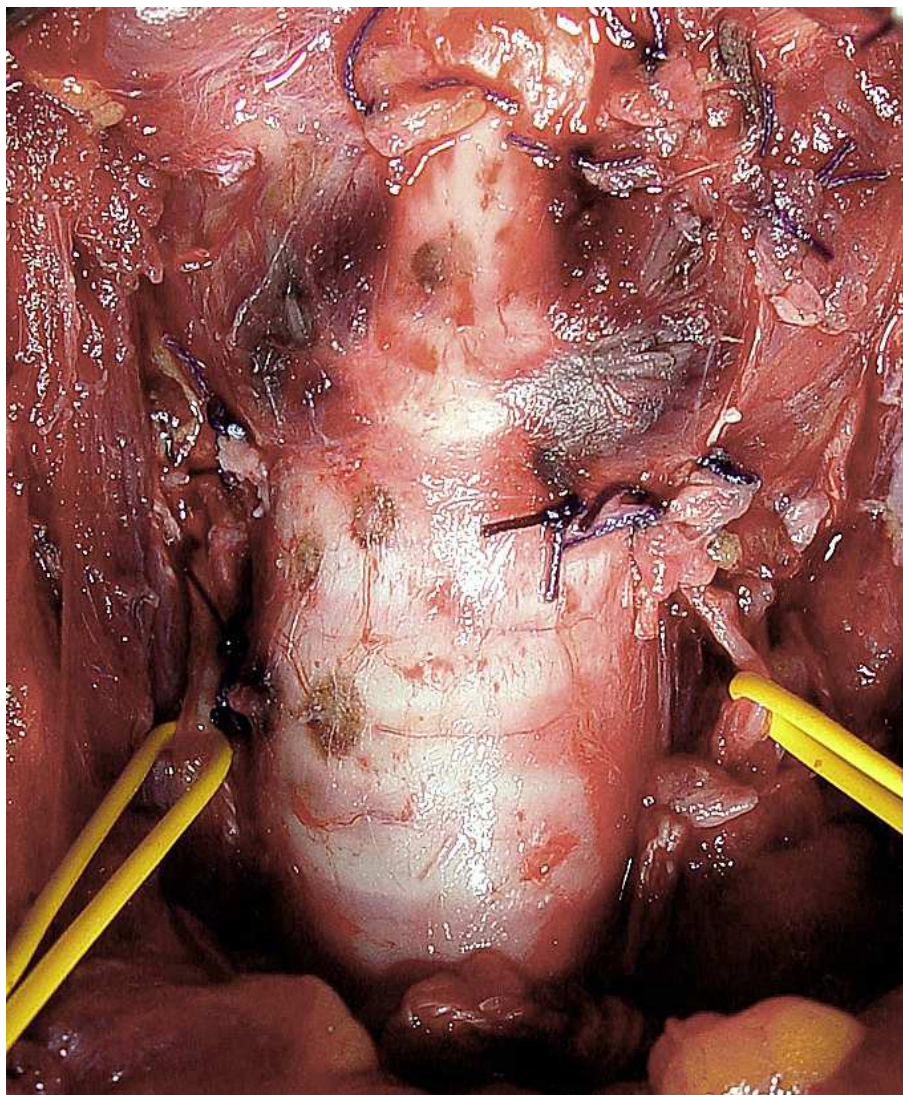
Isolamento dei nervi laringei inferiori (ricorrenti)



Lobo destro - Istmo - Lobo sinistro (superficie anteriore)

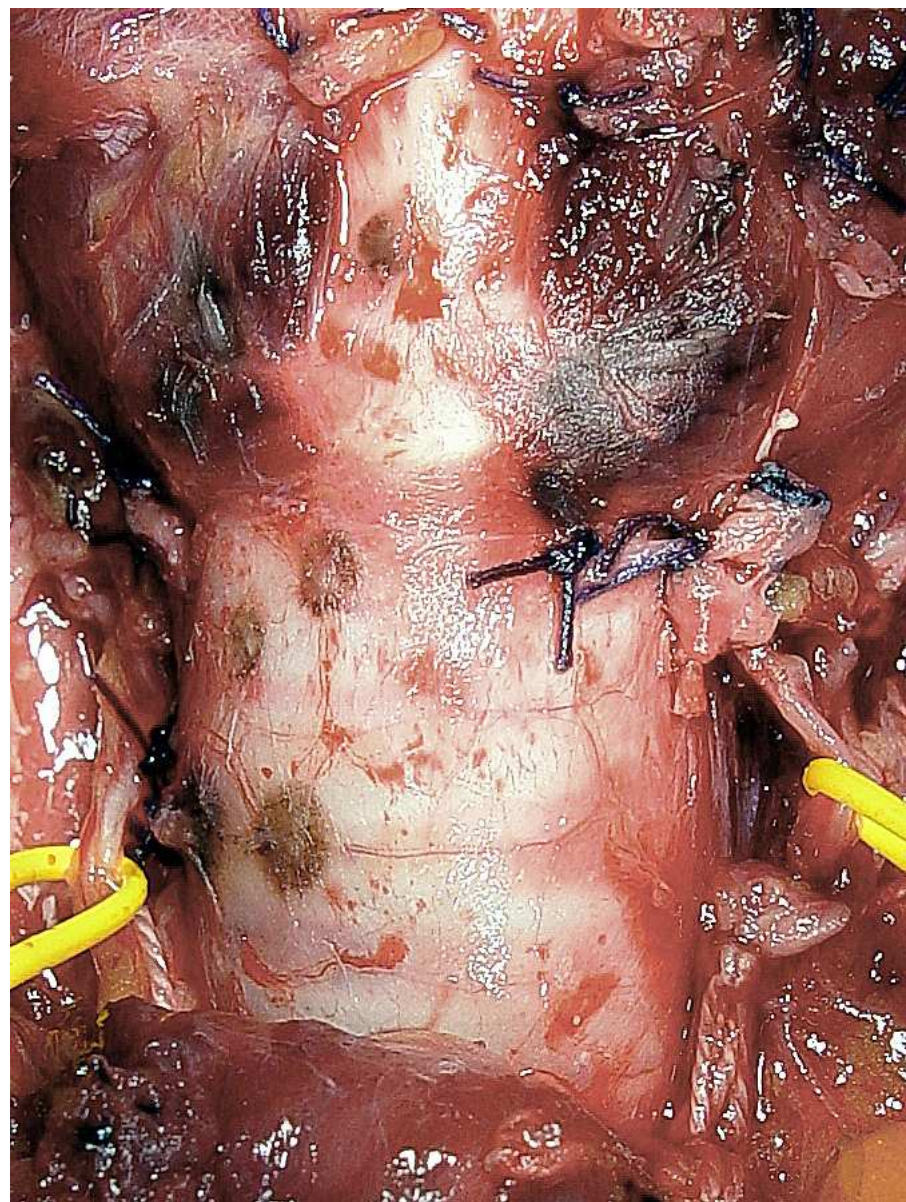


Lobo sinistro - Istmo - Lobo destro (superficie posteriore)

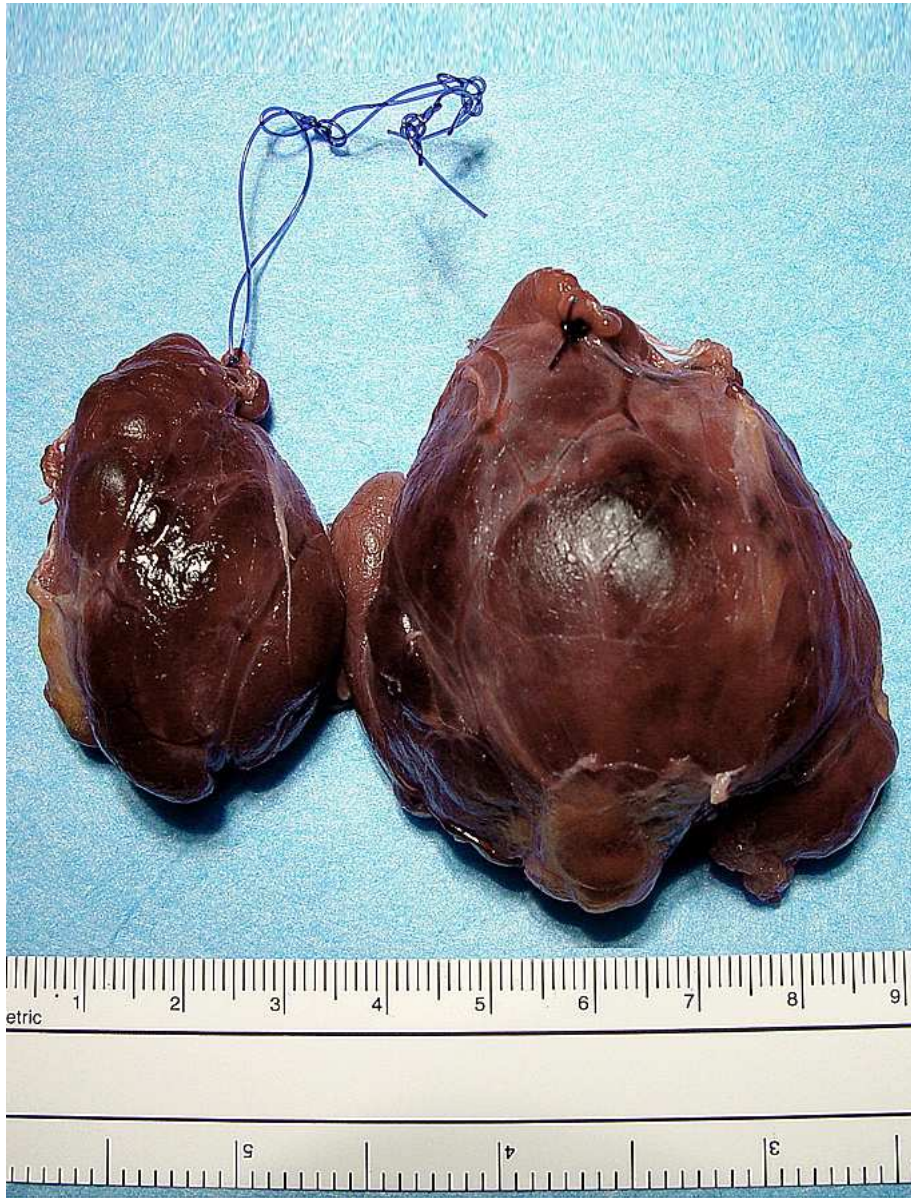

D.F.C. • Anni: 65 - F • Record: 35 • 18-04-2002

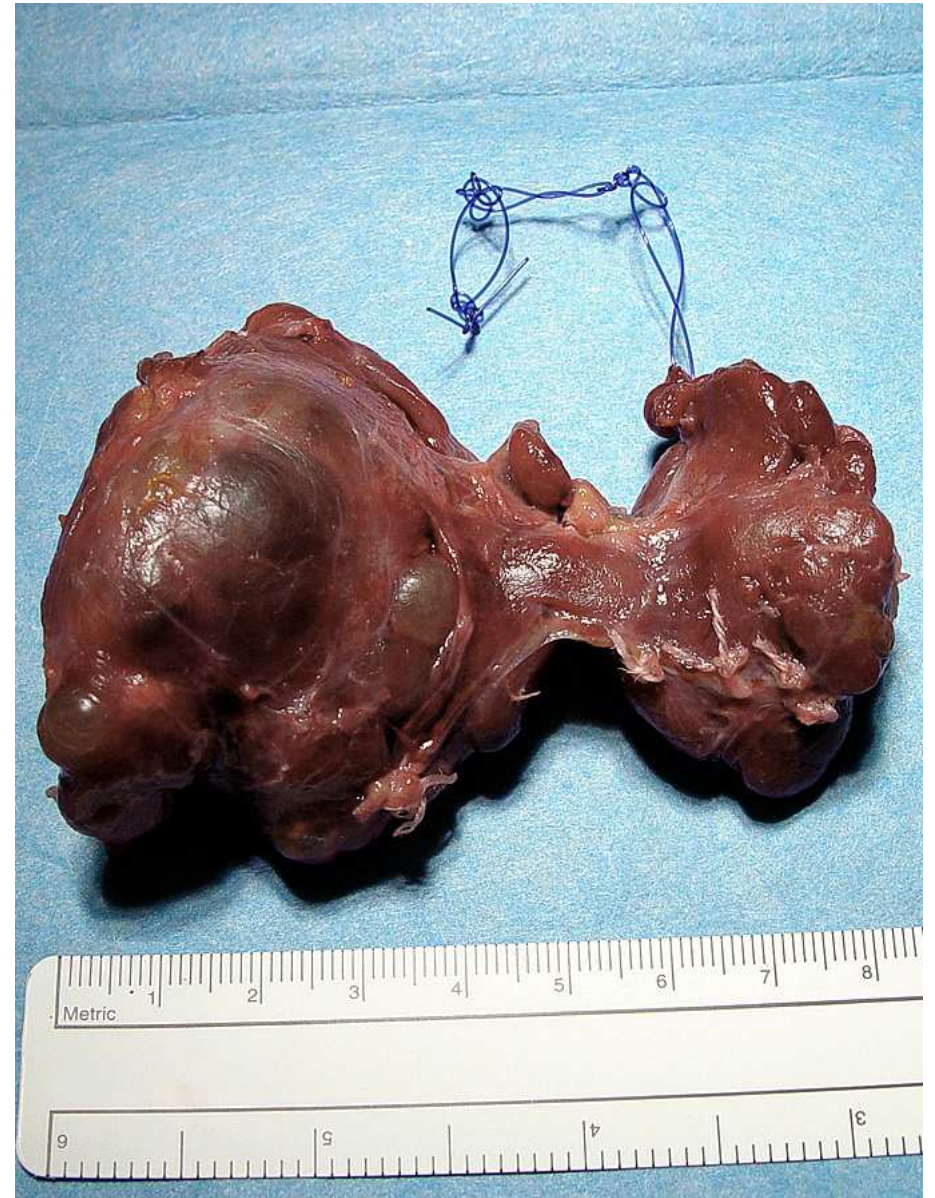Tiroidectomia totale extracapsulare per gozzo plurinodulare



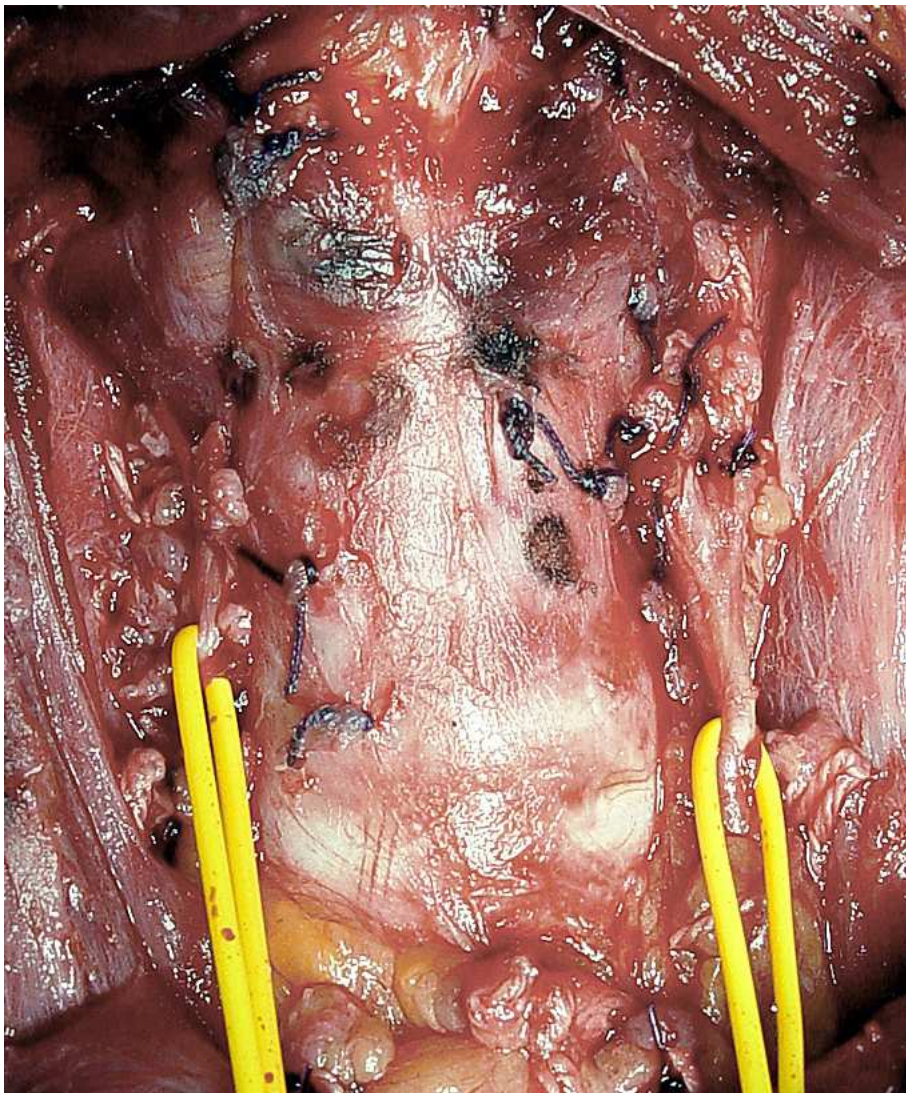
Isolamento dei nervi laringei inferiori (ricorrenti)



Lobo destro - Istmo - Lobo sinistro (superficie anteriore)

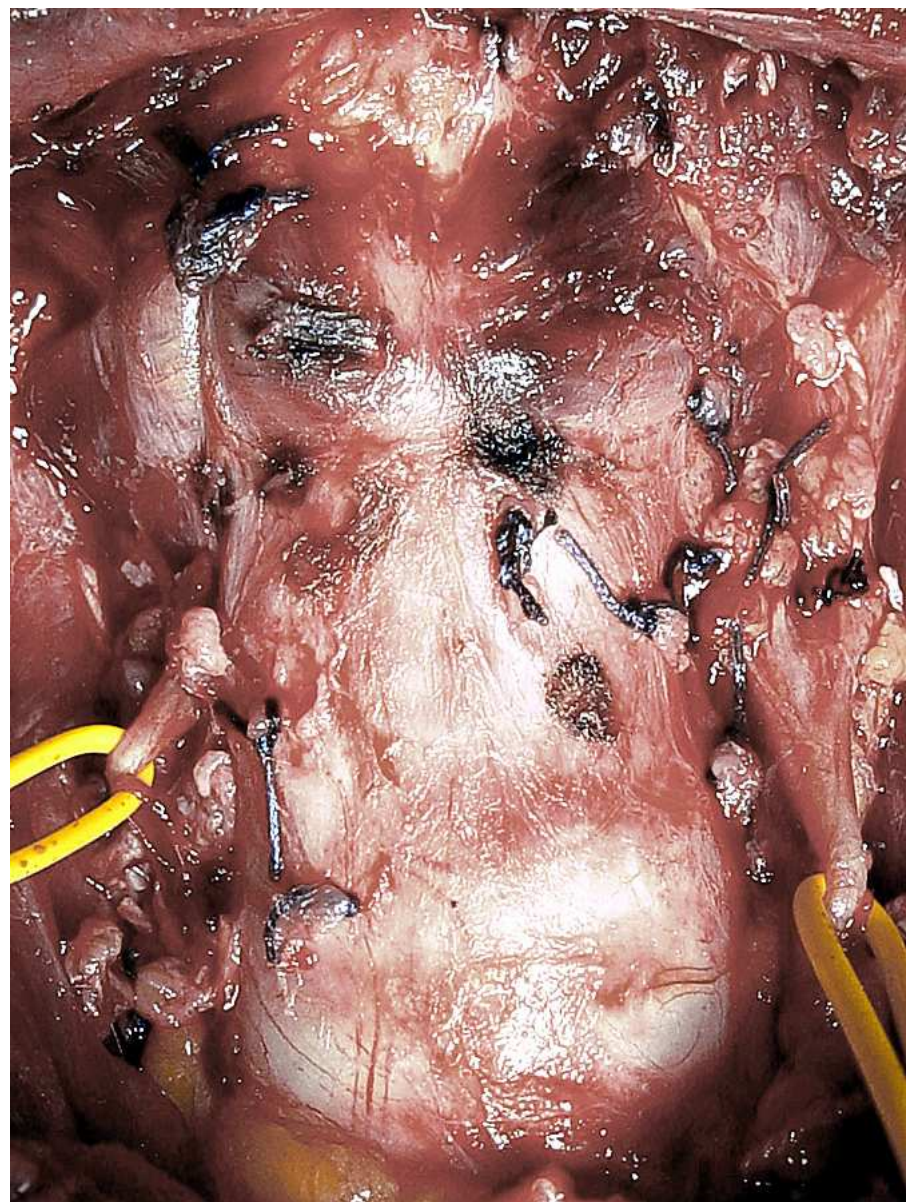


Lobo sinistro - Istmo - Lobo destro (superficie posteriore)

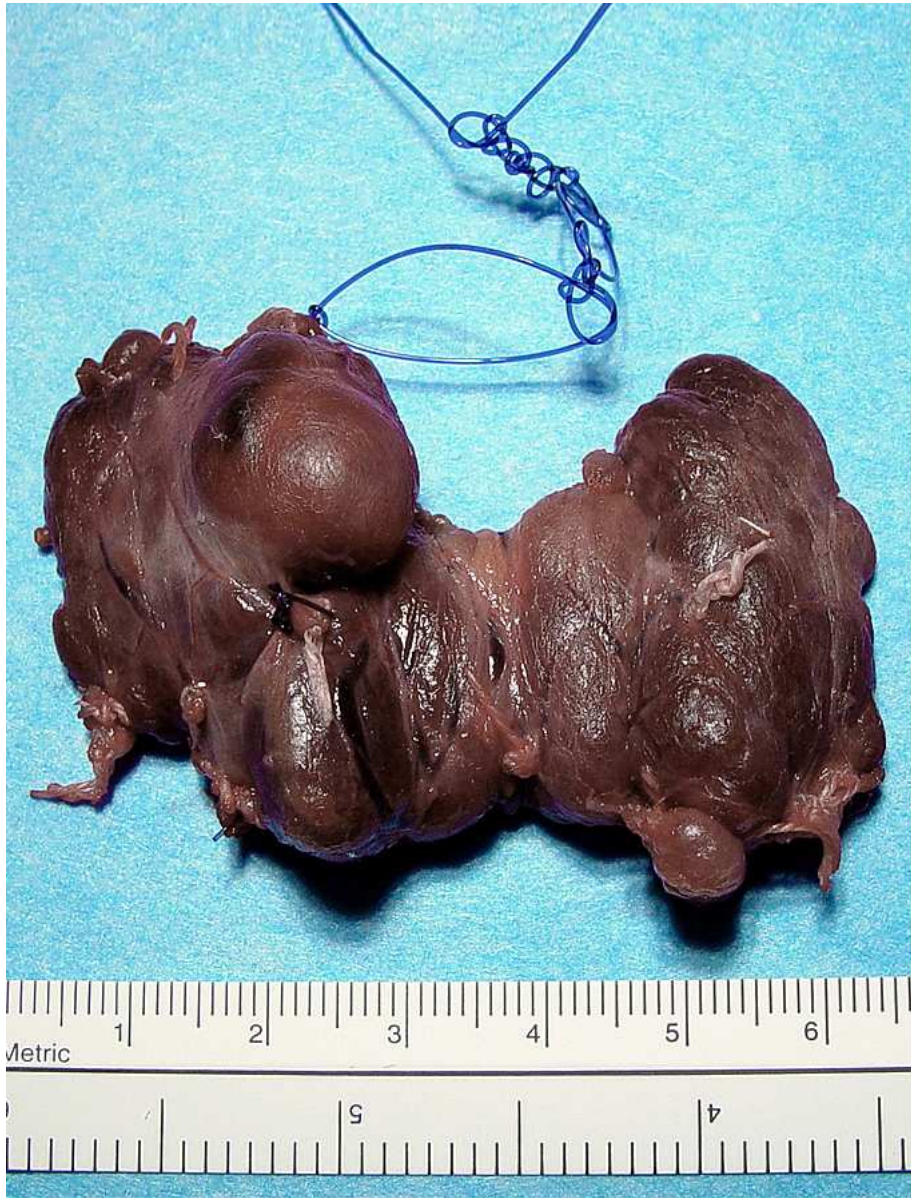

D.D.A. · Anni: 43 - F · Record: 36 · 20-04-2002

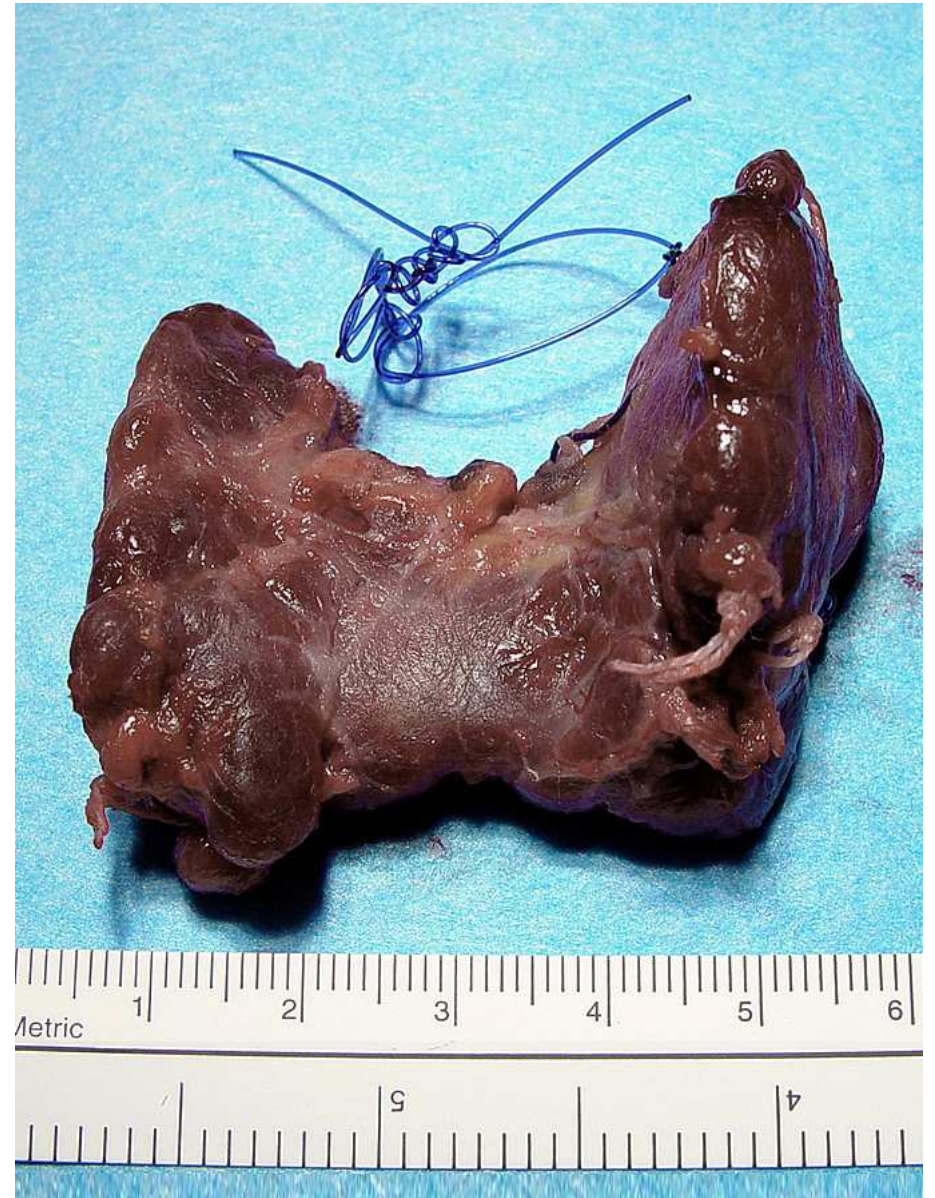Tiroidectomia totale extracapsulare per adenoma follicolare del lobo dx in gozzo plurinodulare



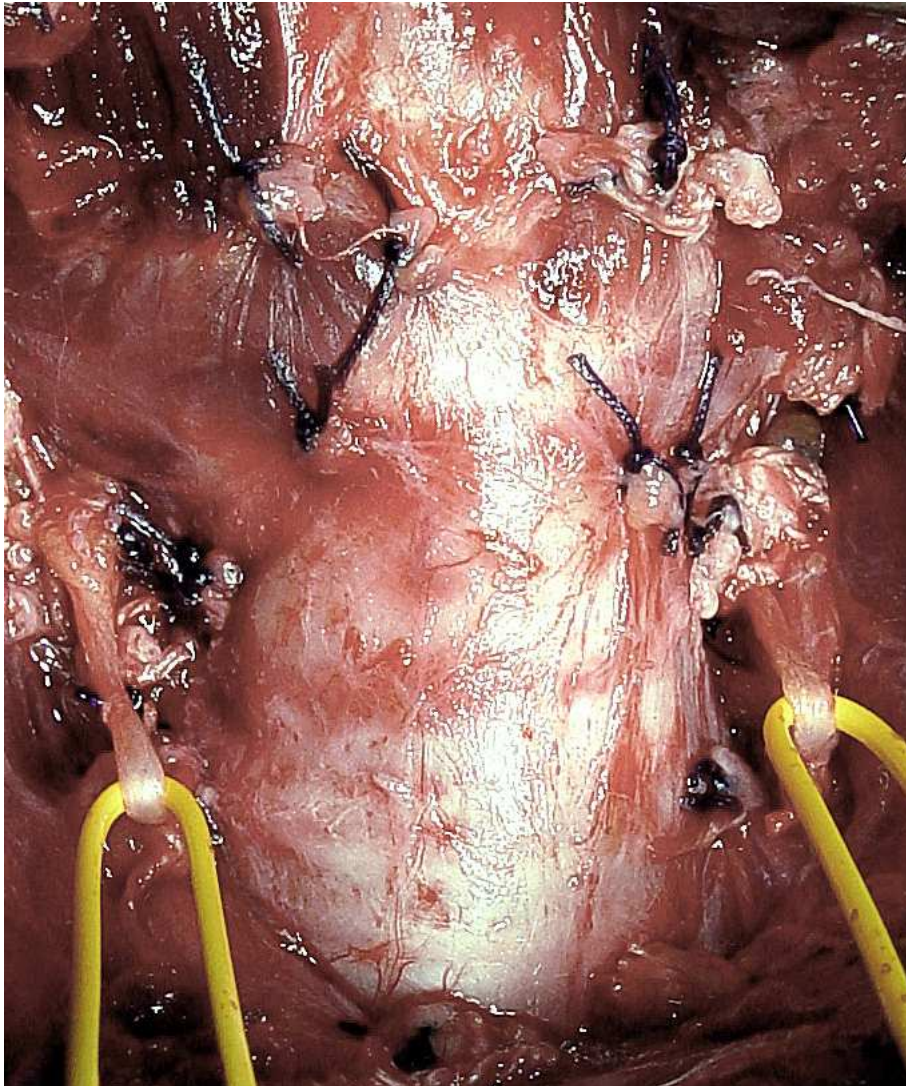
Isolamento dei nervi laringei inferiori (ricorrenti)



Lobo destro - Istmo - Lobo sinistro (superficie anteriore)

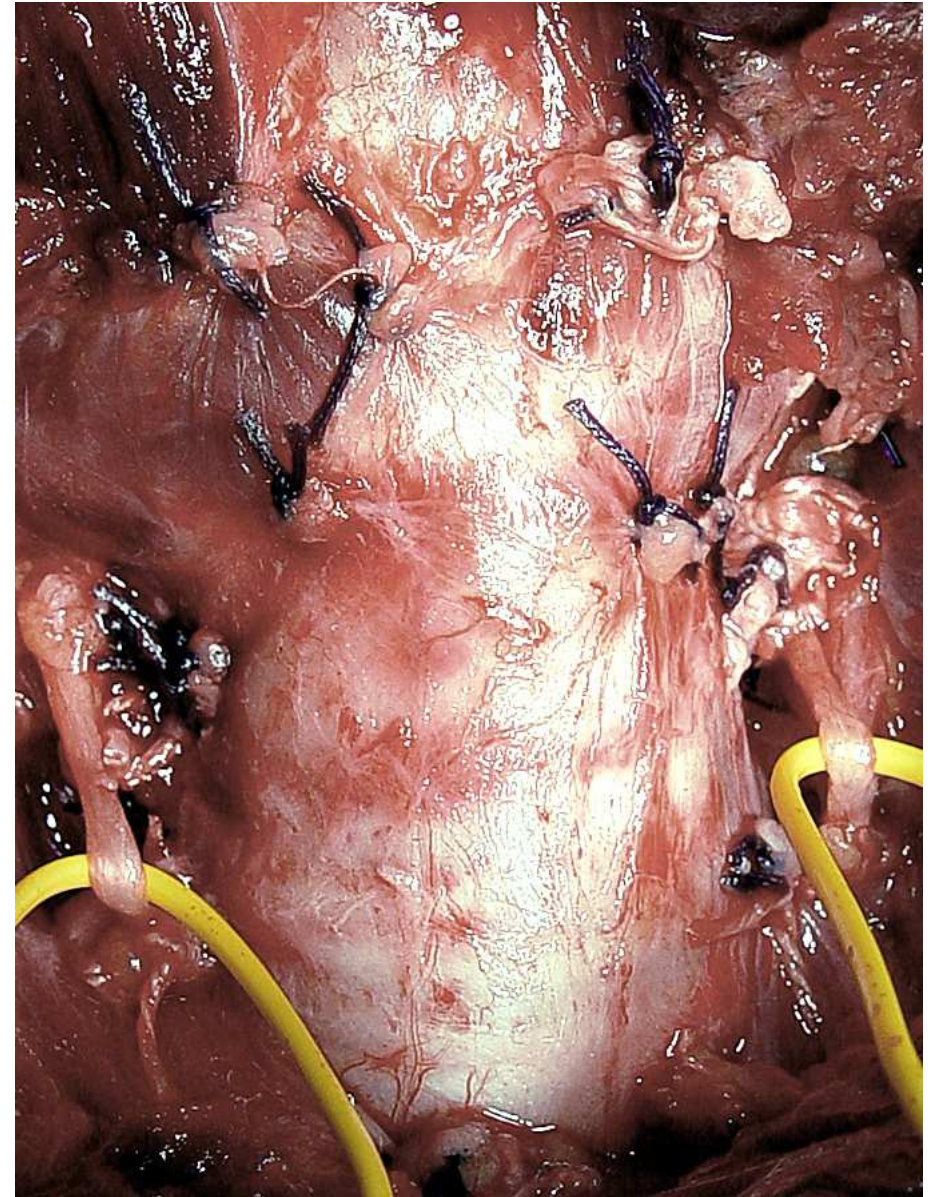


Lobo sinistro - Istmo - Lobo destro (superficie posteriore)



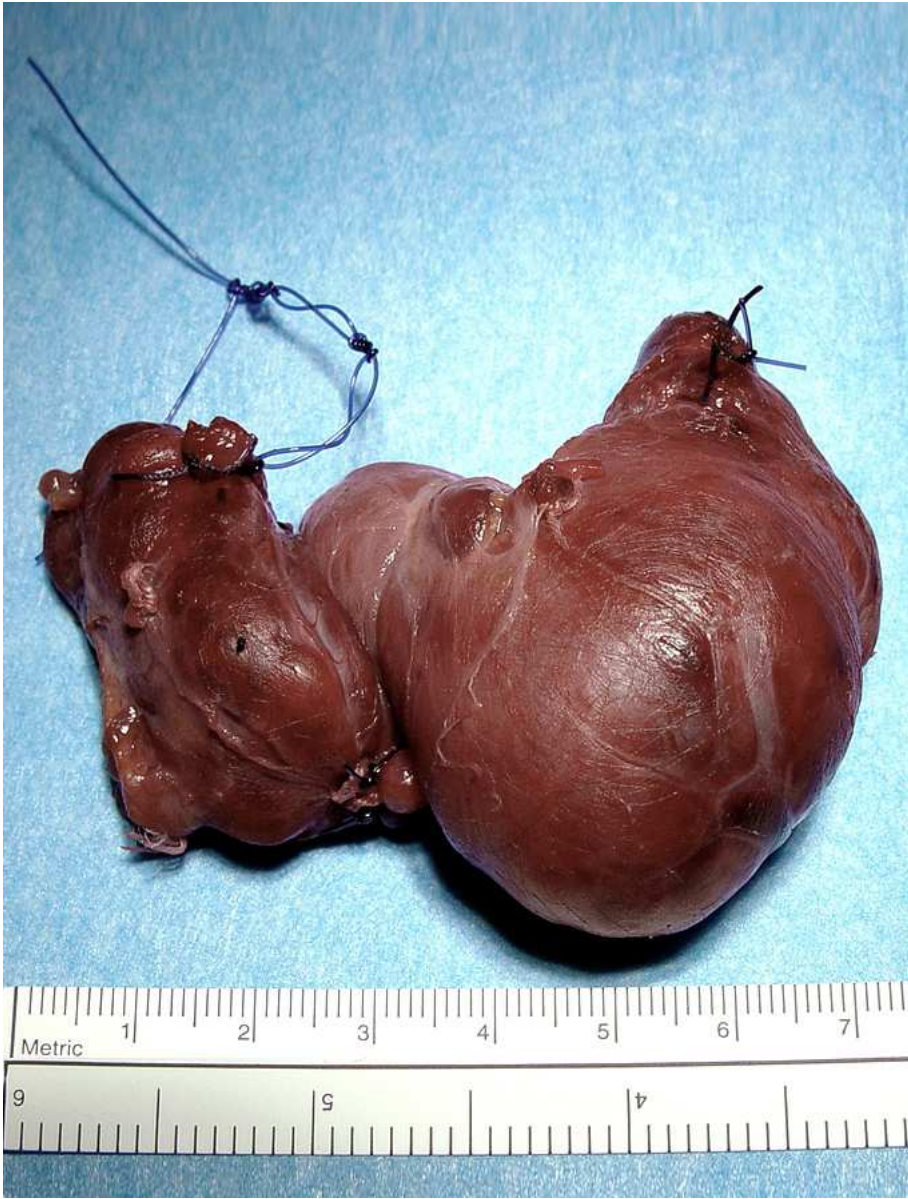
V.R. • Anni: 54 - F • Record: 37 • 26-04-2002

Tiroidectomia totale extracapsulare per microcarcinoma papillifero del lobo sn in tiroidite di Hashimoto e gozzo plurinodulare plongeant

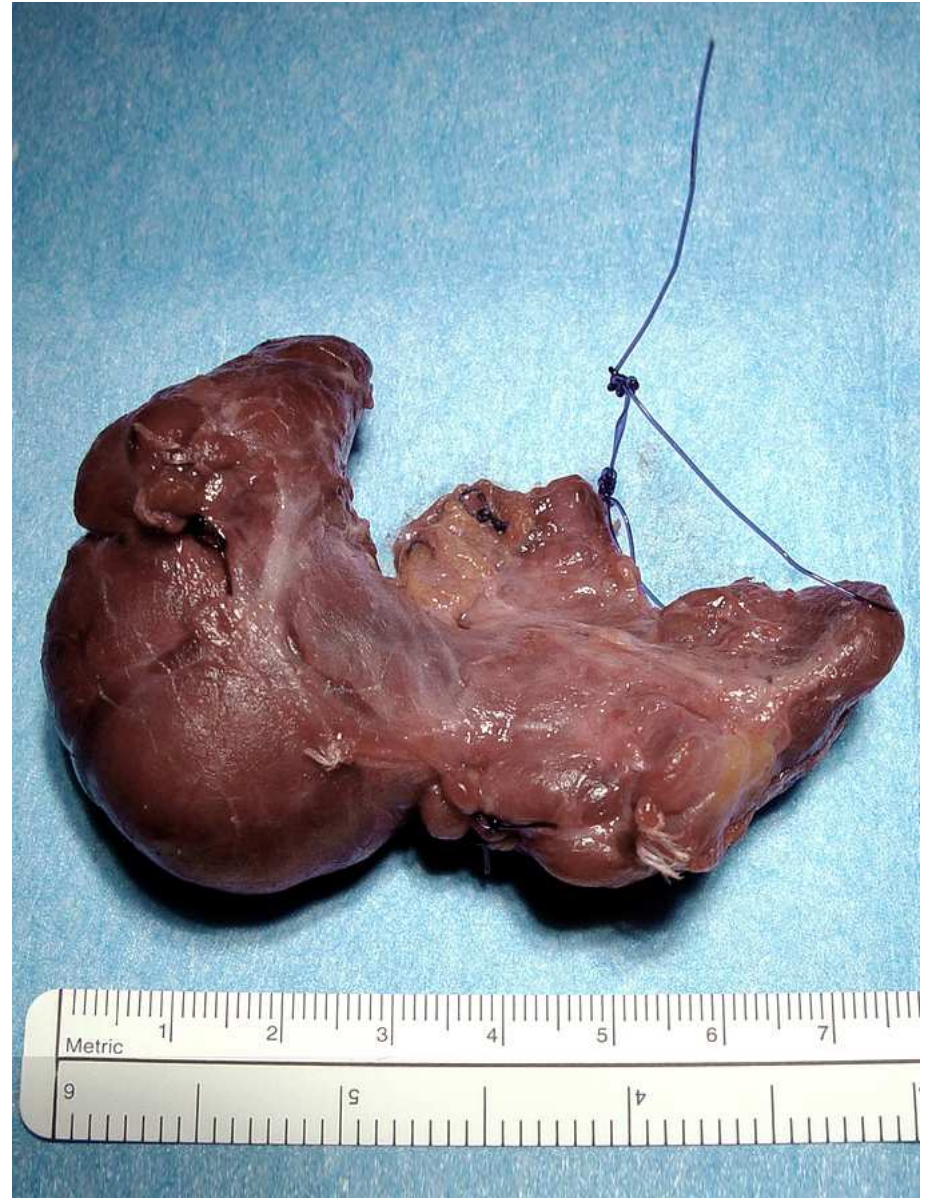


Isolamento dei nervi laringei inferiori (ricorrenti)

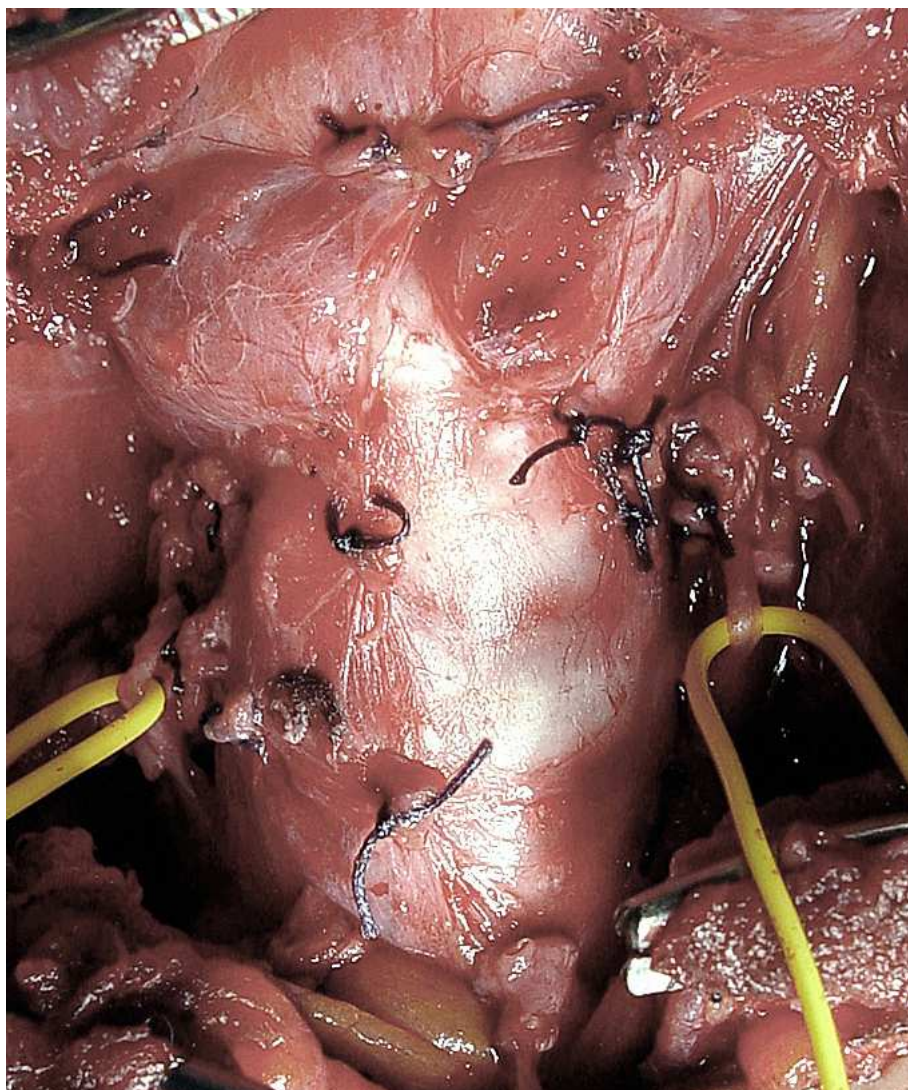




Lobo destro - Istmo - Lobo sinistro (superficie anteriore)

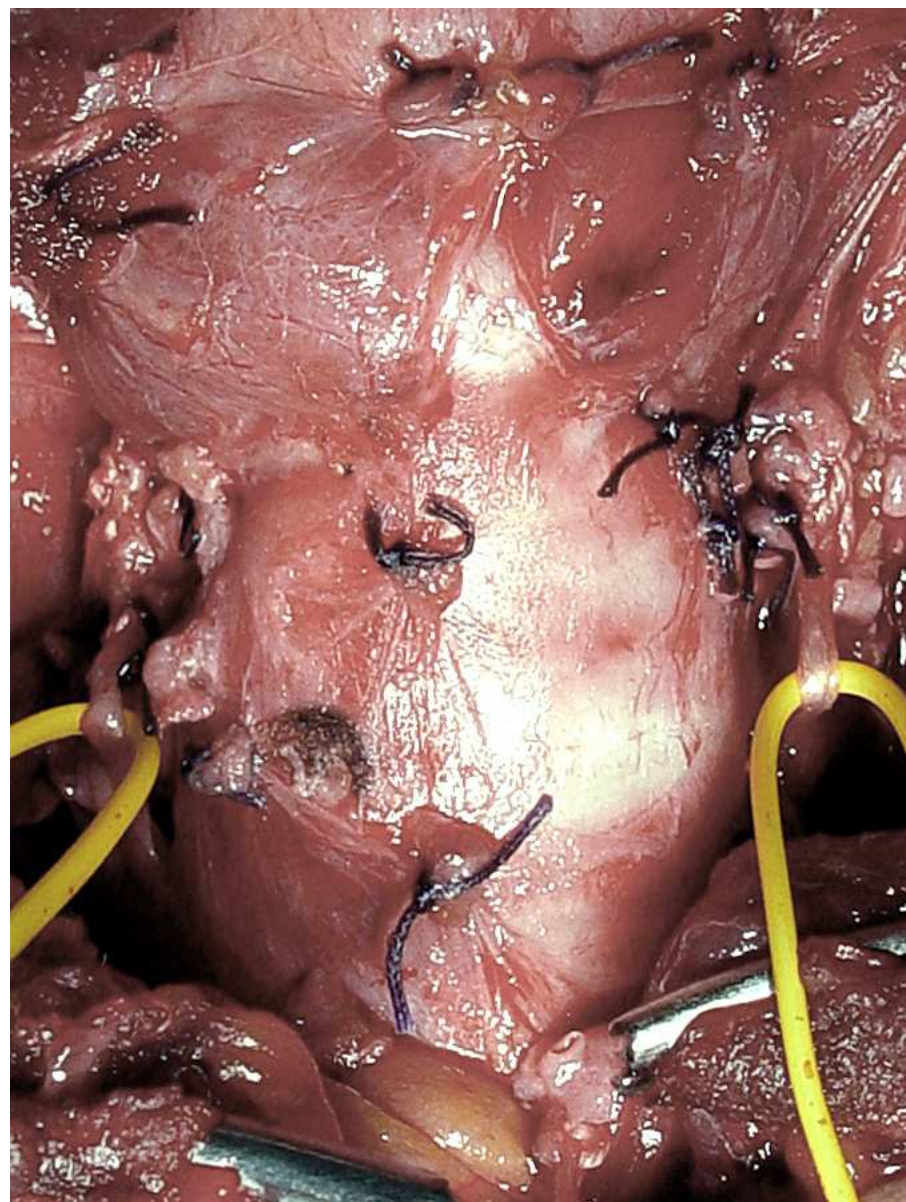


Lobo sinistro - Istmo - Lobo destro (superficie posteriore)

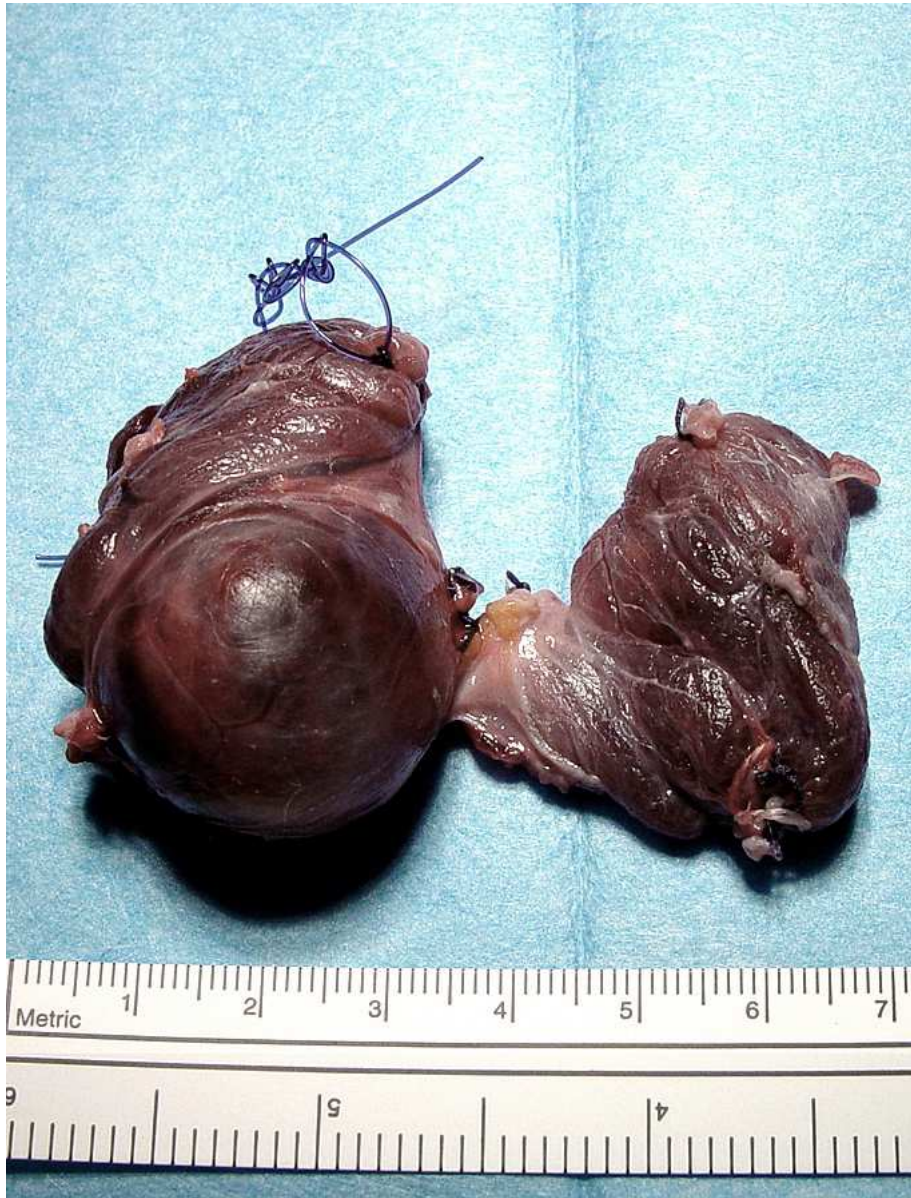

S.M. • Anni: 48 - F • Record: 38 • 04-05-2002

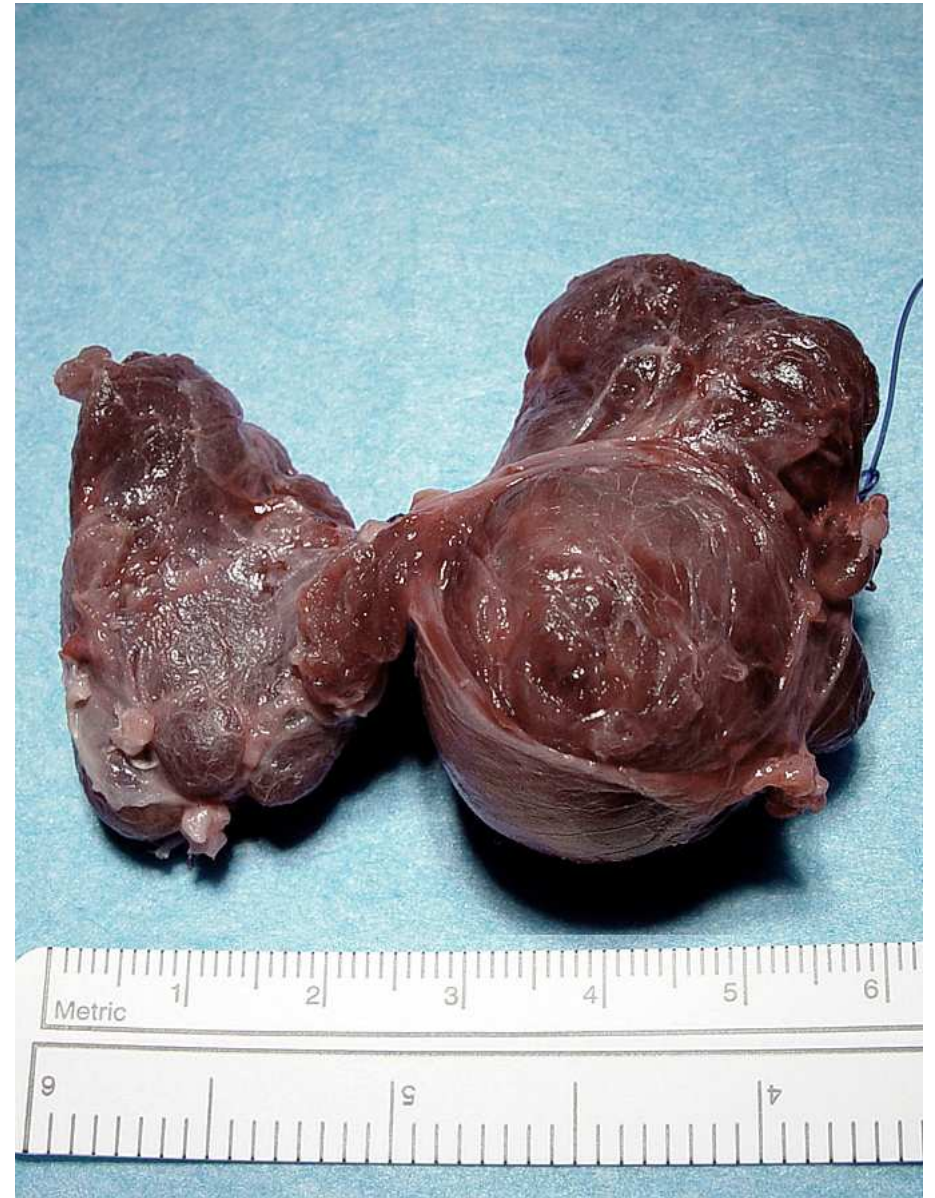Tiroidectomia totale extracapsulare per microcarcinoma papillifero del lobo sn ed adenoma macrofollicolare del lobo dx in gozzo plurinodulare



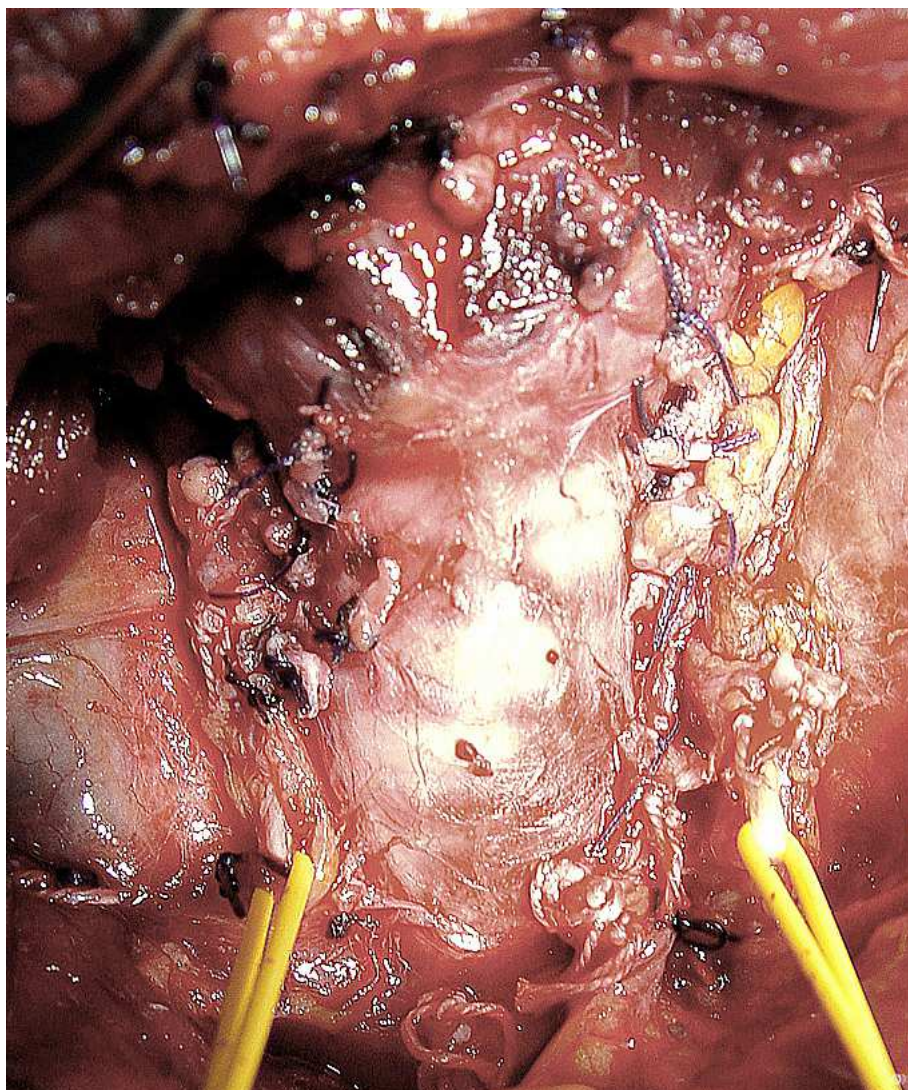
Isolamento dei nervi laringei inferiori (ricorrenti)



Lobo destro - Istmo - Lobo sinistro (superficie anteriore)

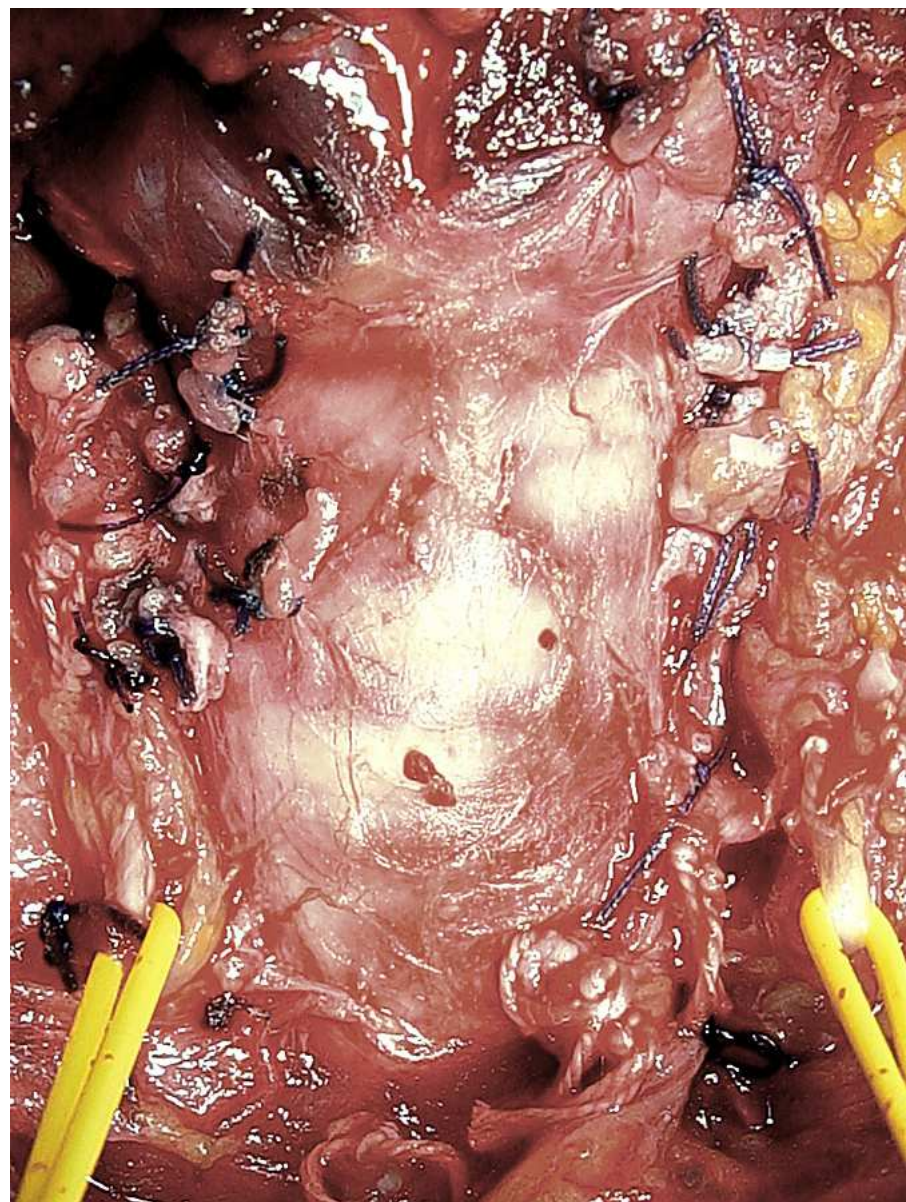


Lobo sinistro - Istmo - Lobo destro (superficie posteriore)

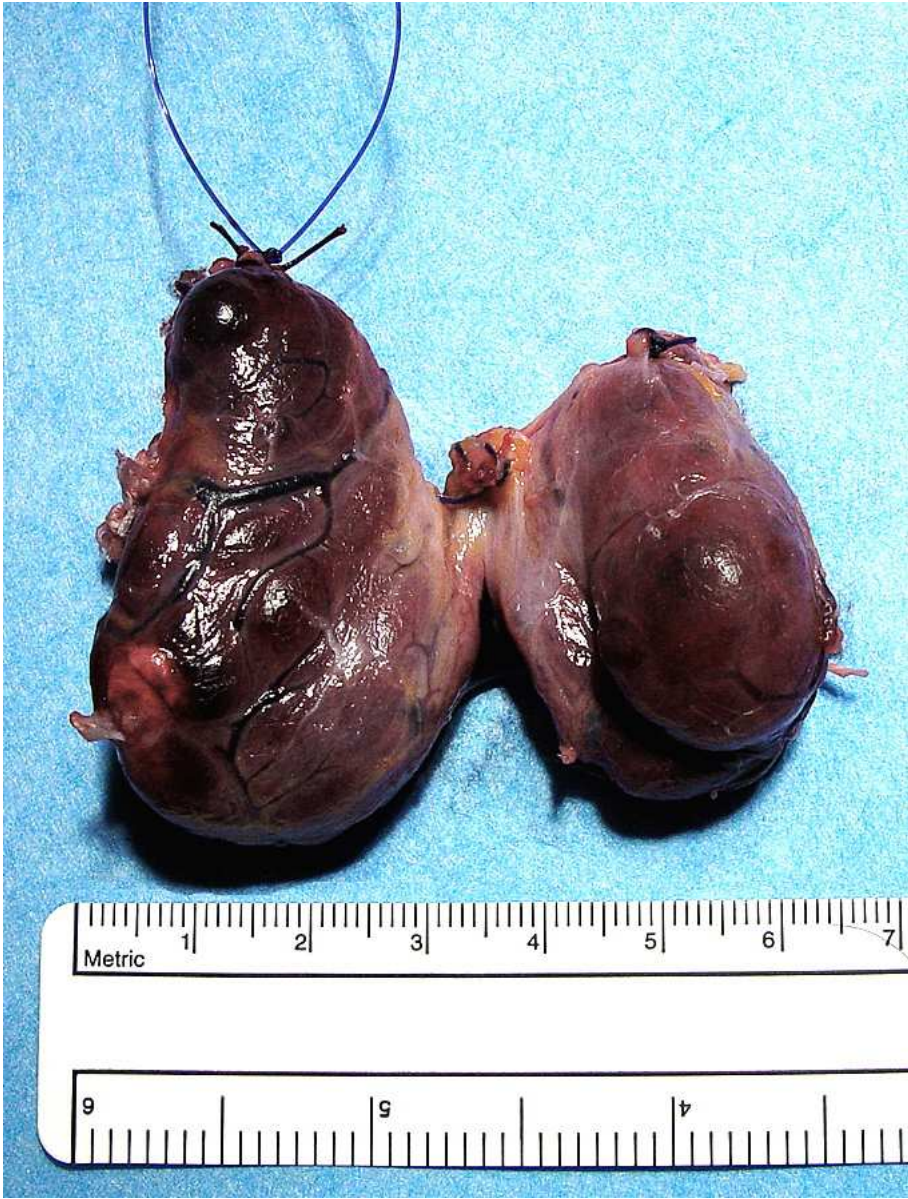


P.M.I. • Anni: 56 - F • Record: 39 • 15-05-2002

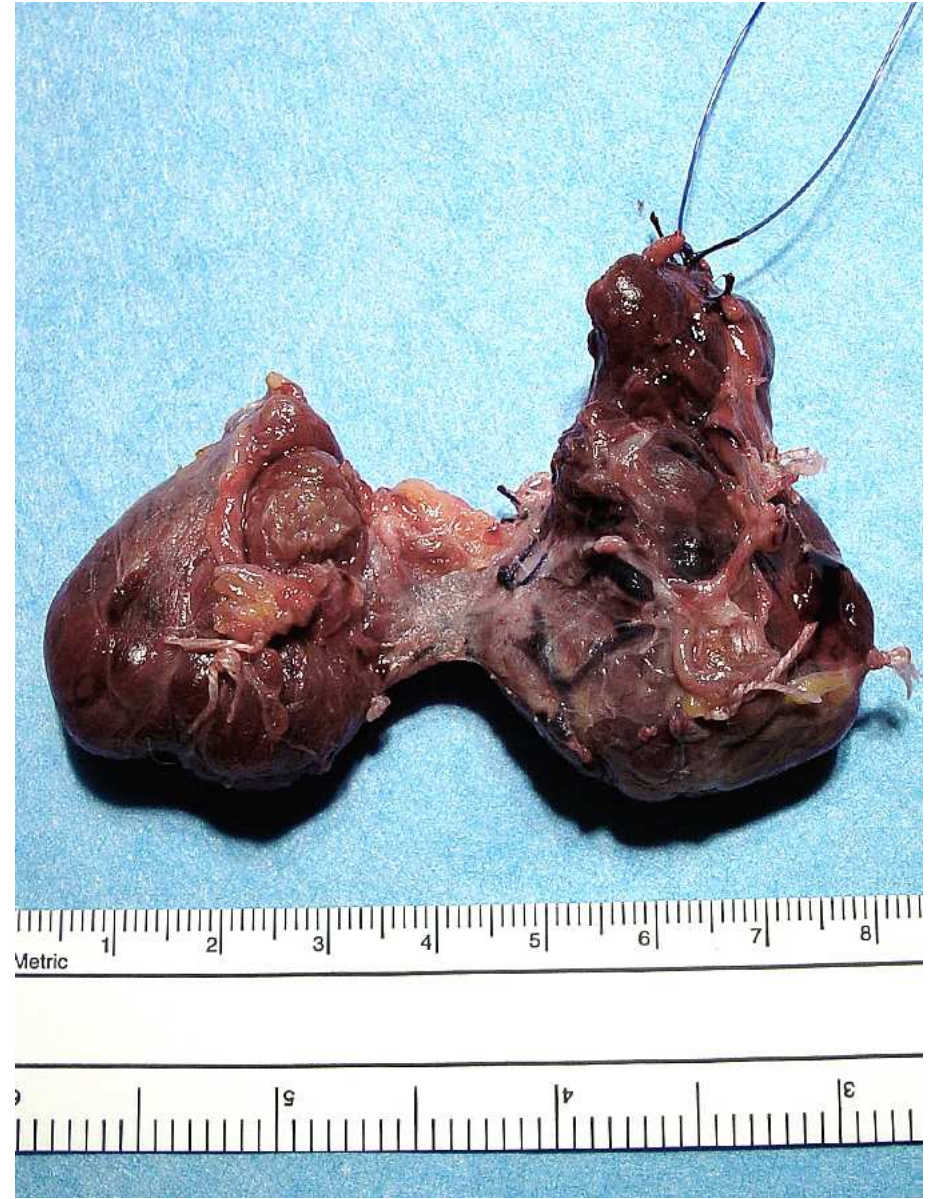
Tiroidectomia totale extracapsulare per gozzo plurinodulare tossico



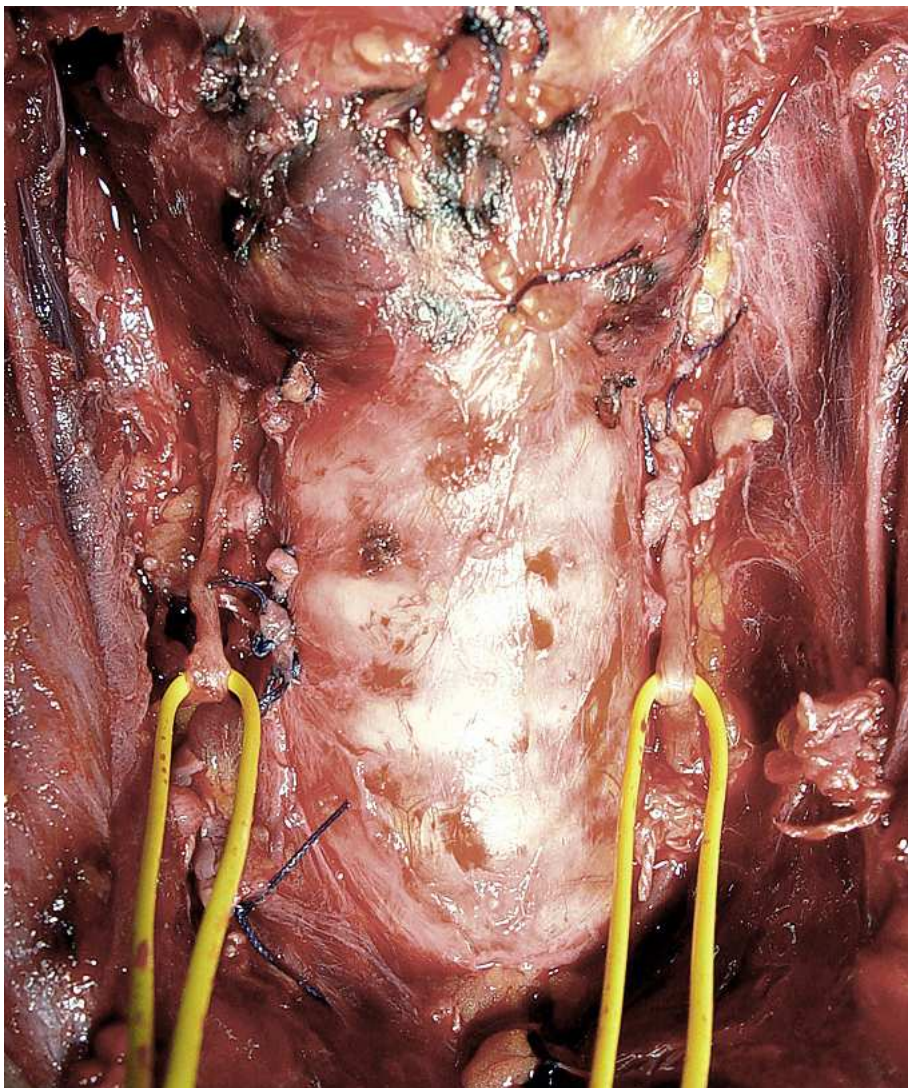
Isolamento dei nervi laringei inferiori (ricorrenti)



Lobo destro - Istmo - Lobo sinistro (superficie anteriore)

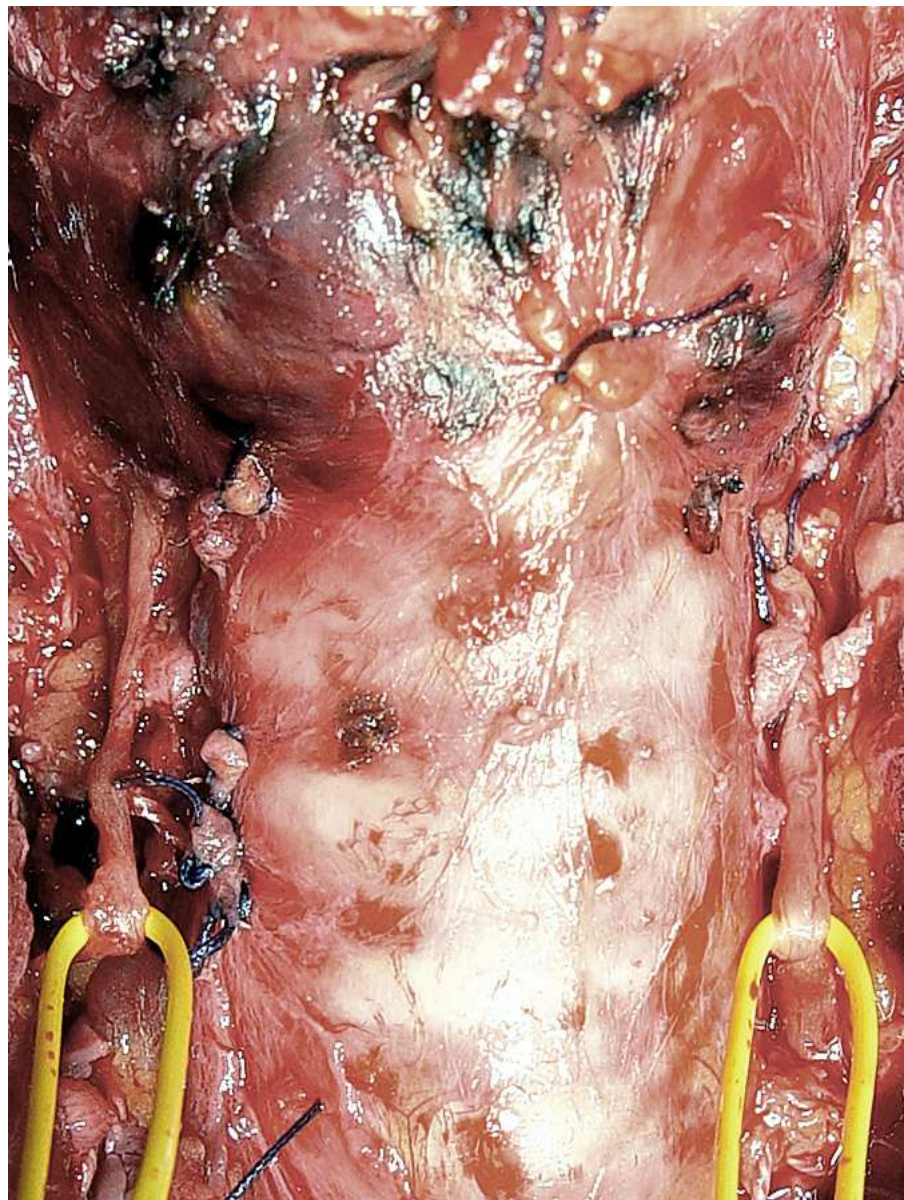


Lobo sinistro - Istmo - Lobo destro (superficie posteriore)

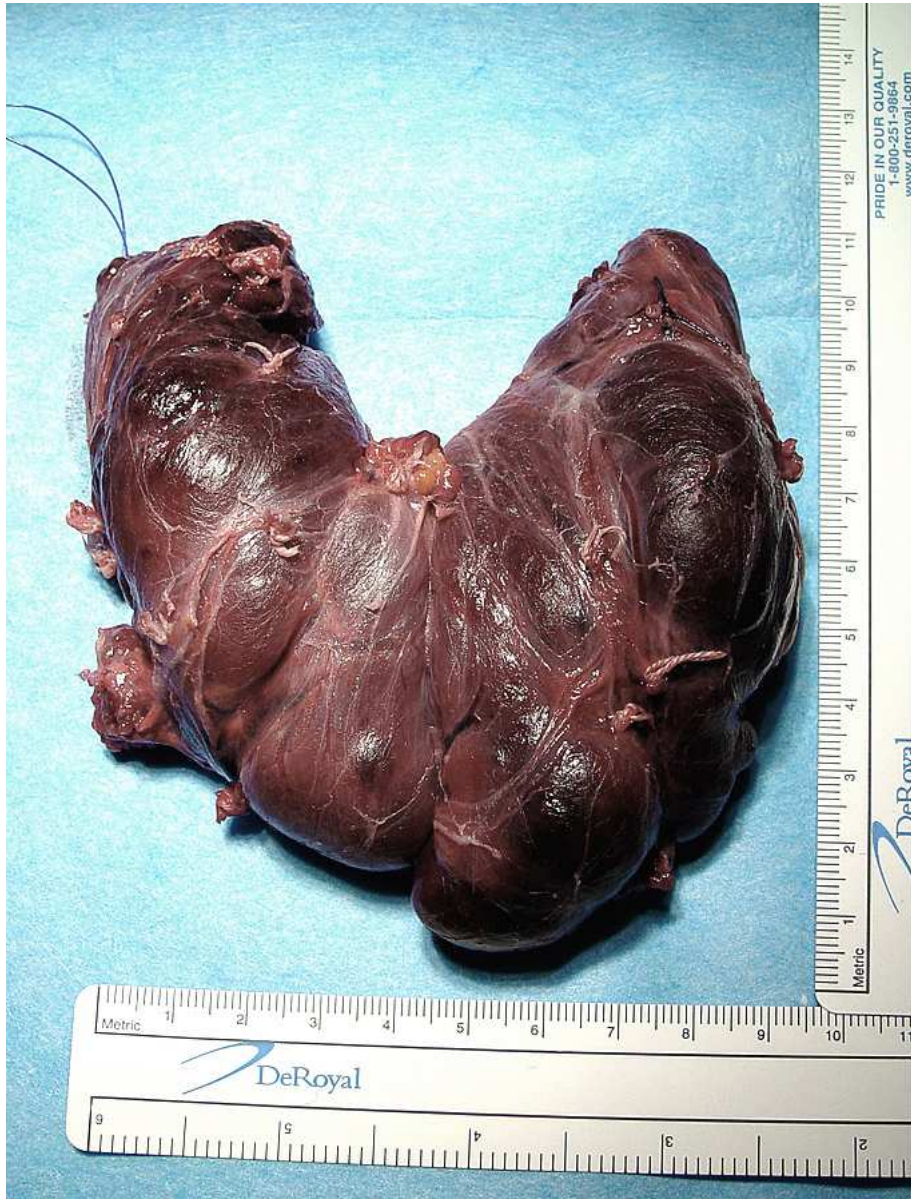

S.P. • Anni: 43 - M • Record: 40 • 15-05-2002

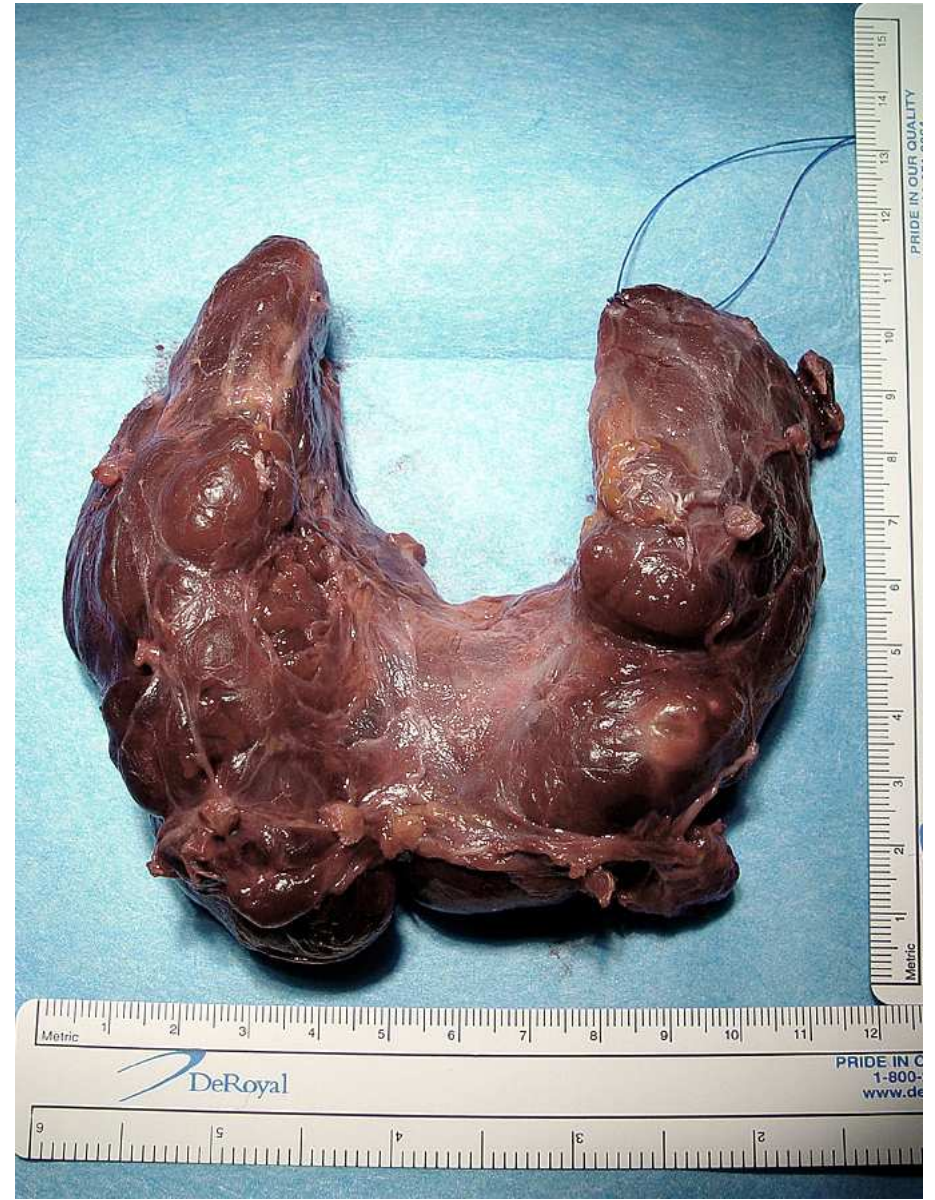Tiroidectomia totale extracapsulare per gozzo plurinodulare plongeant



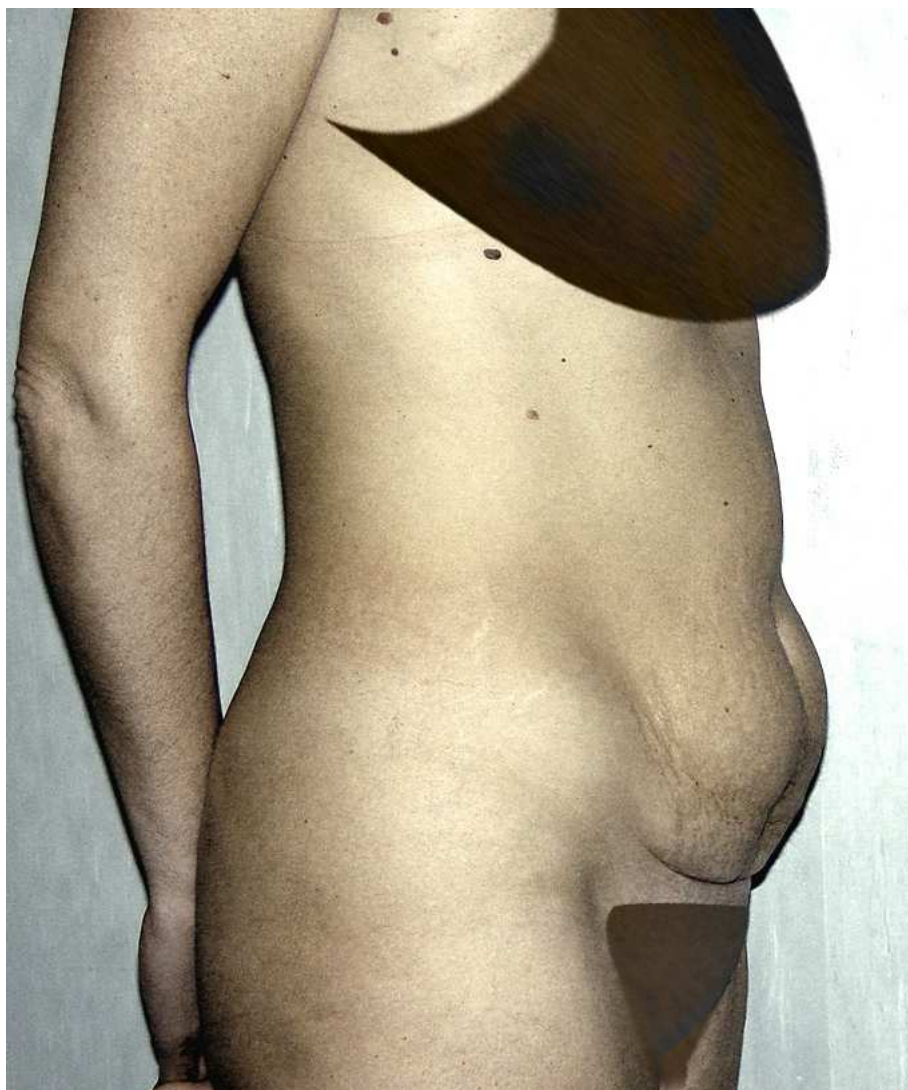Isolamento dei nervi laringei inferiori (ricorrenti)



Lobo destro - Istmo - Lobo sinistro (superficie anteriore)

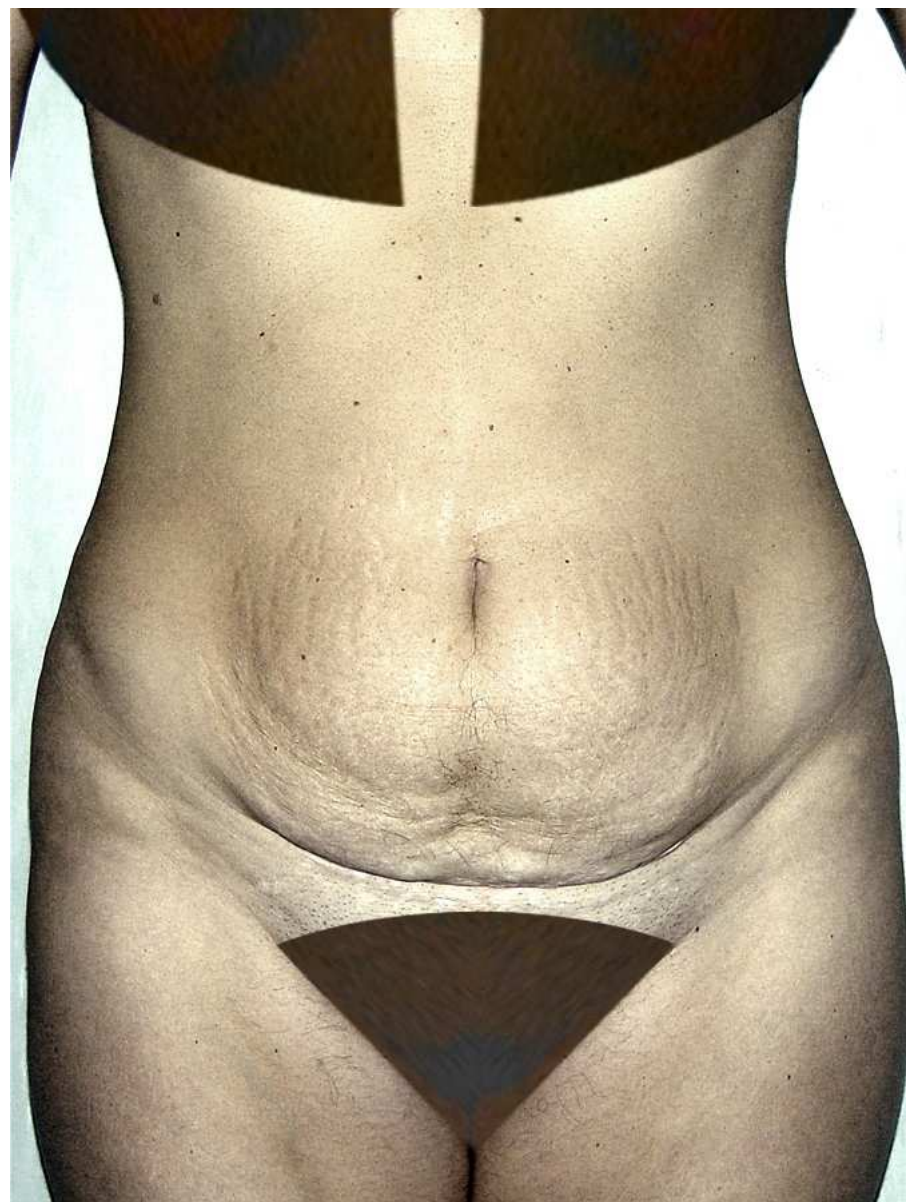

Lobo sinistro - Istmo - Lobo destro (superficie posteriore)

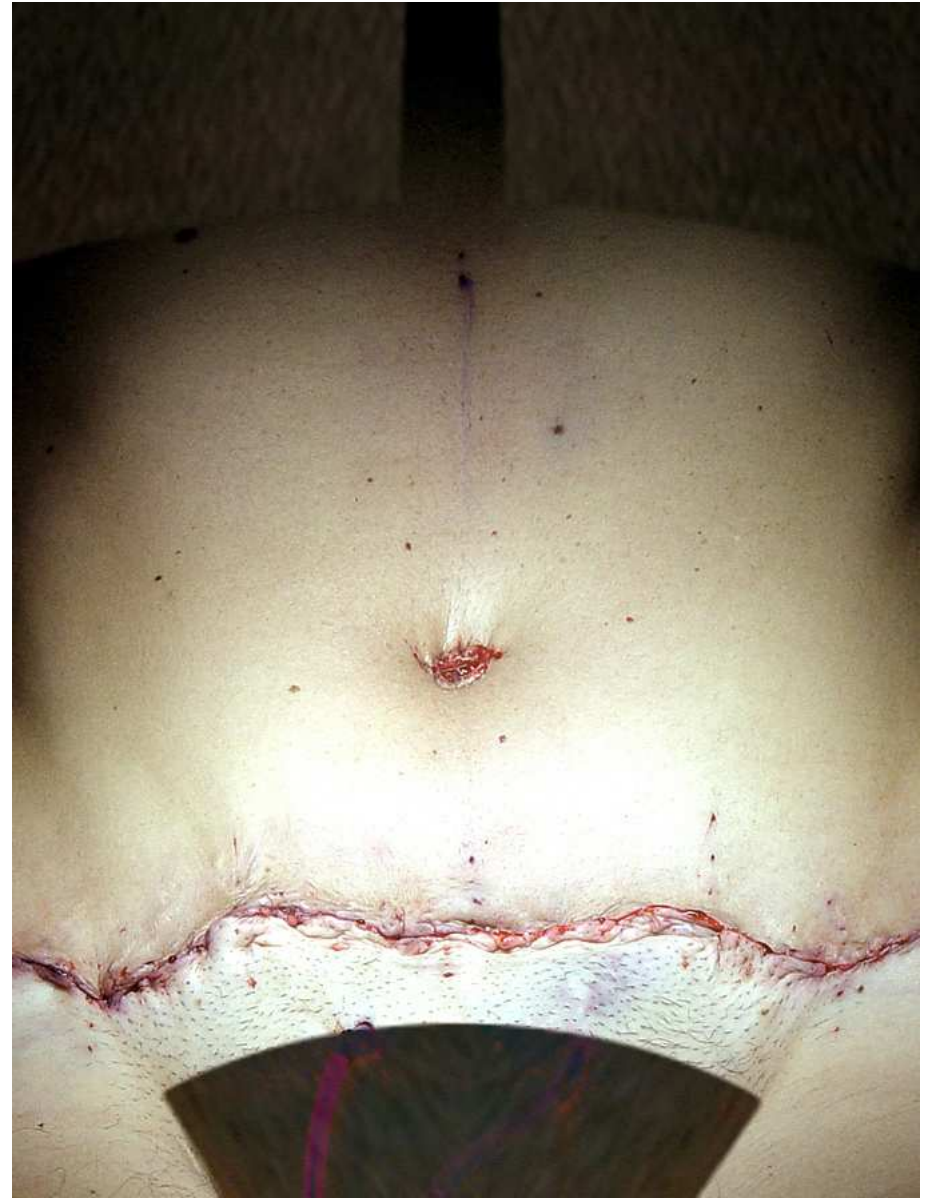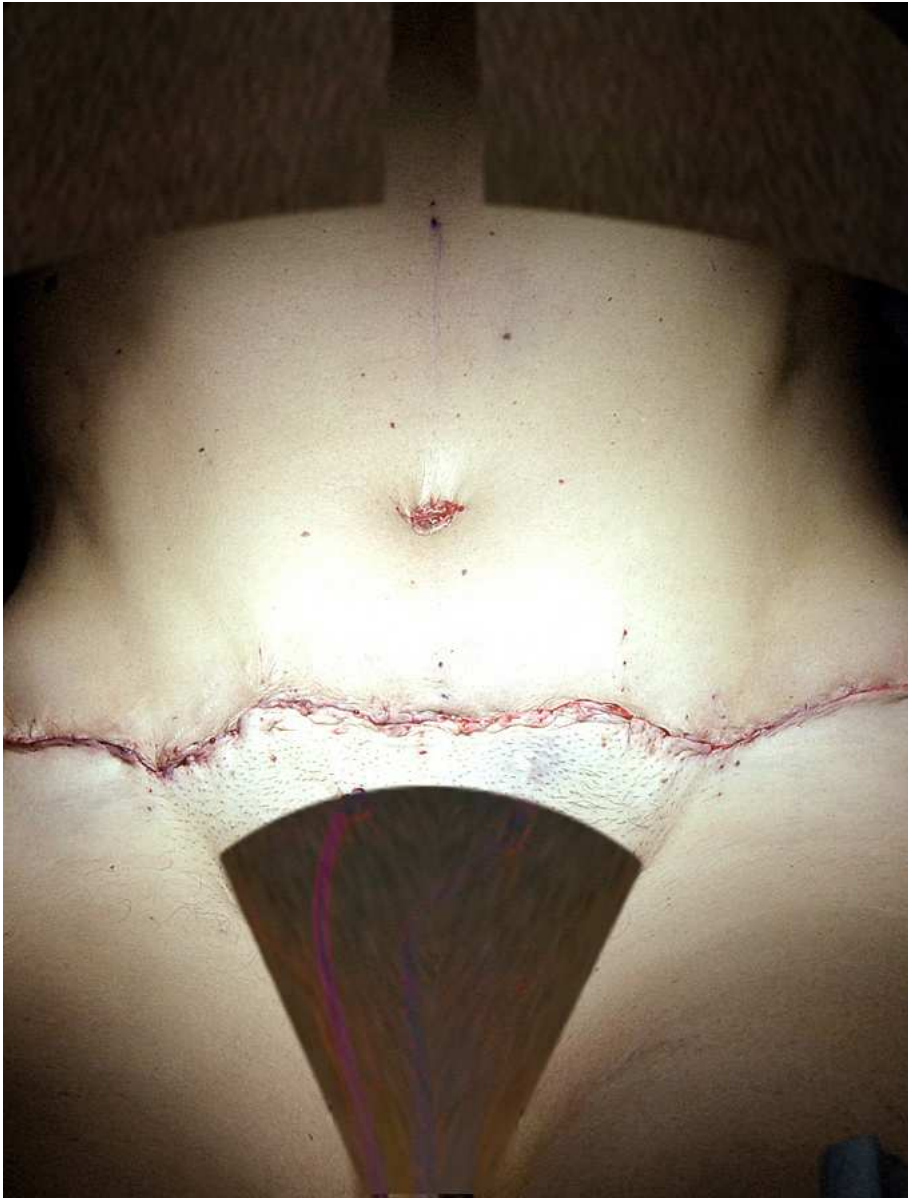


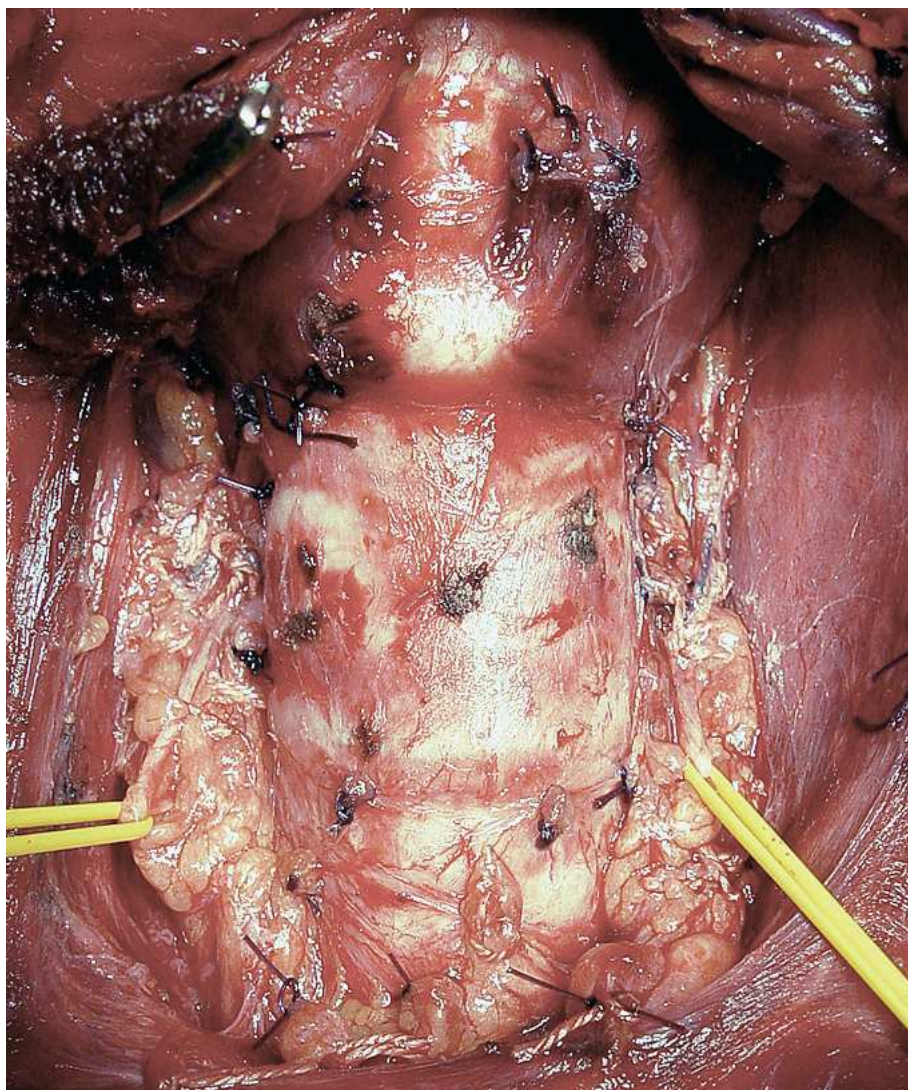
F.A. • Anni: 40 - F • Record: 41 • 26-05-2002

Addominoplastica sec. Serson mod. per addome pendulo



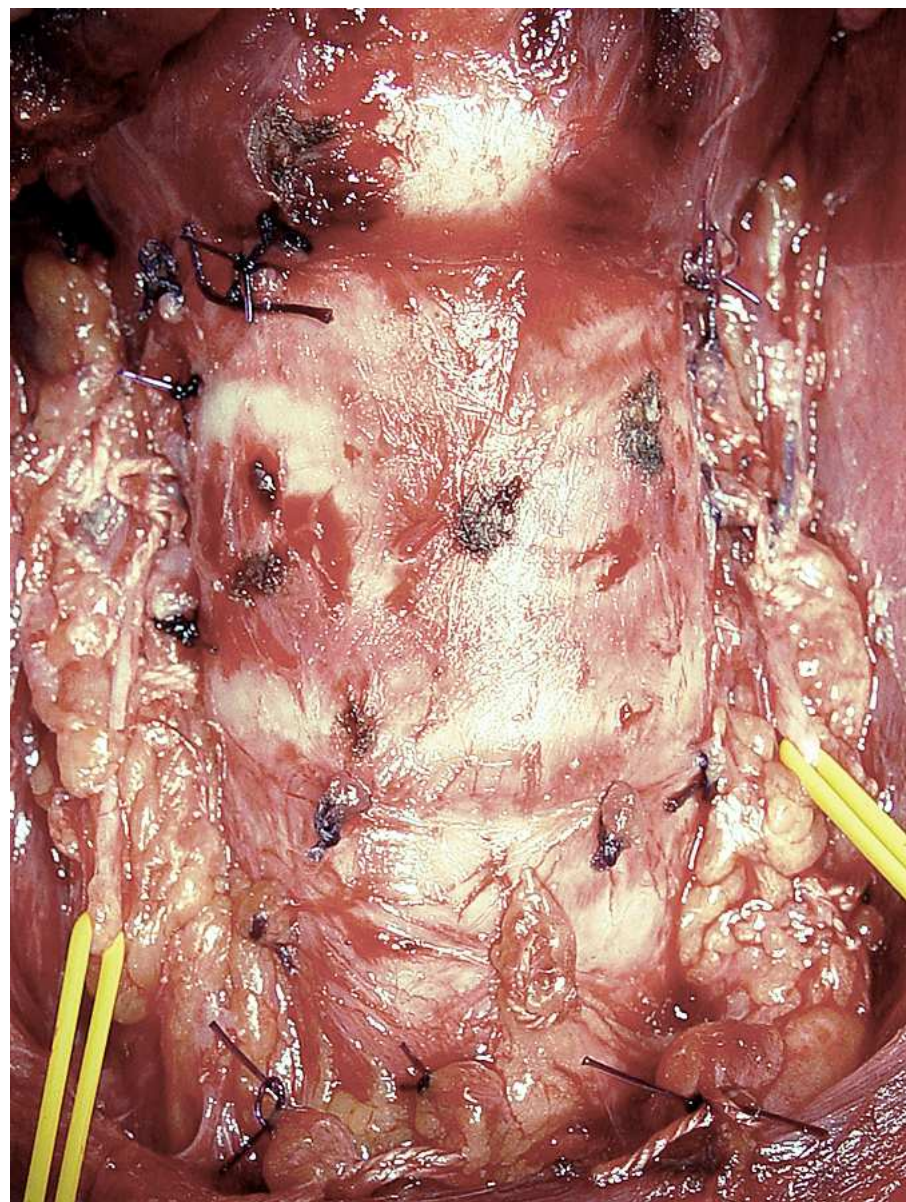




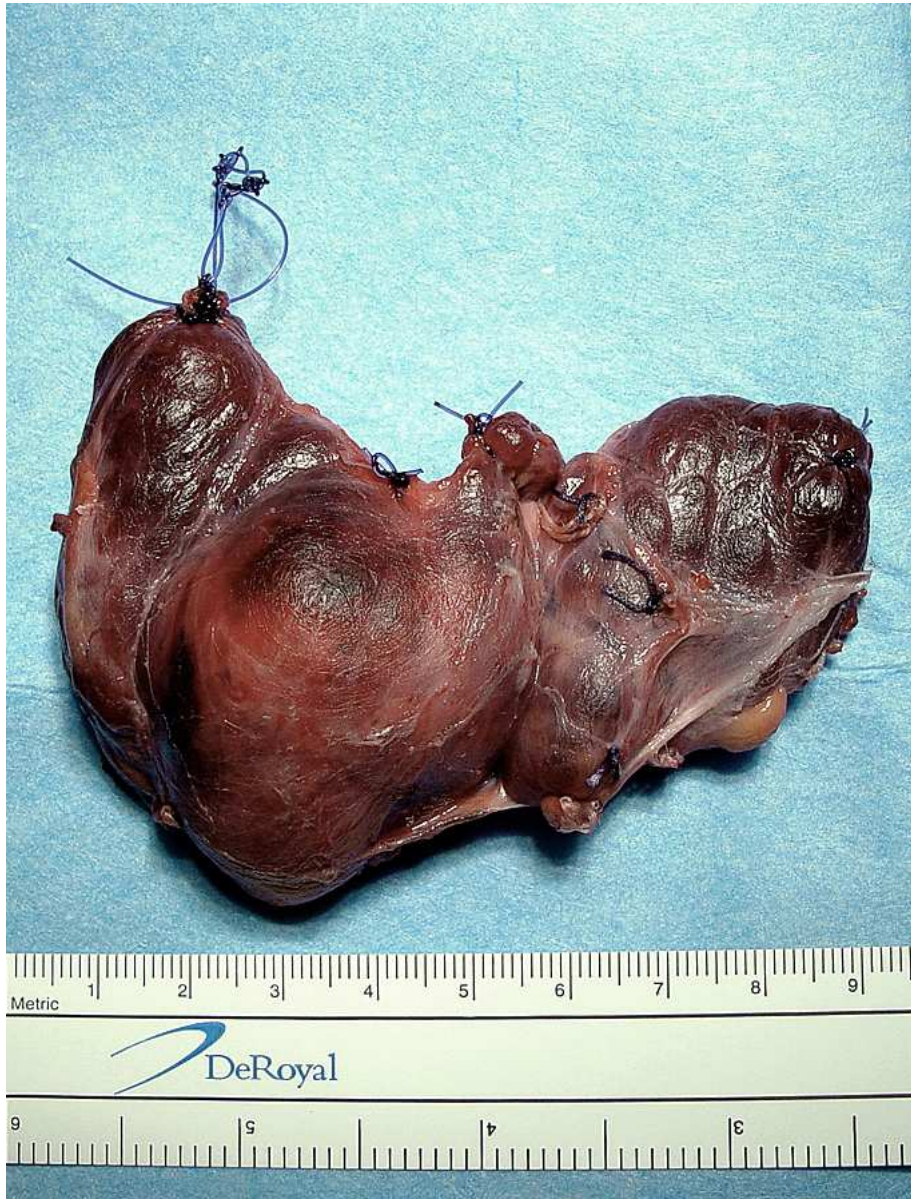

V.A. · Anni: 22 - M · Record: 42 · 27-05-2002

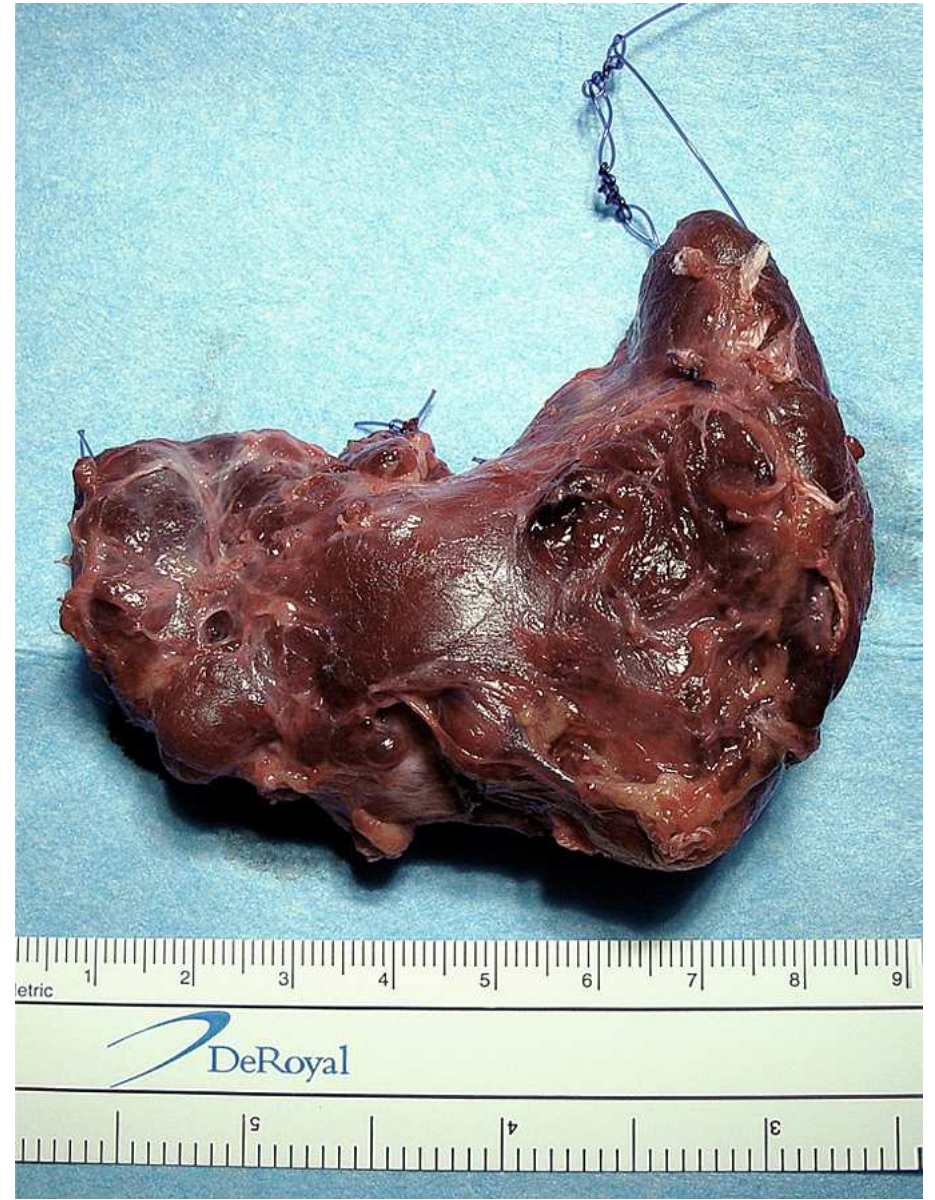Tiroidectomia totale extracapsulare per adenoma follicolare del lobo destro in gozzo plurinodulare



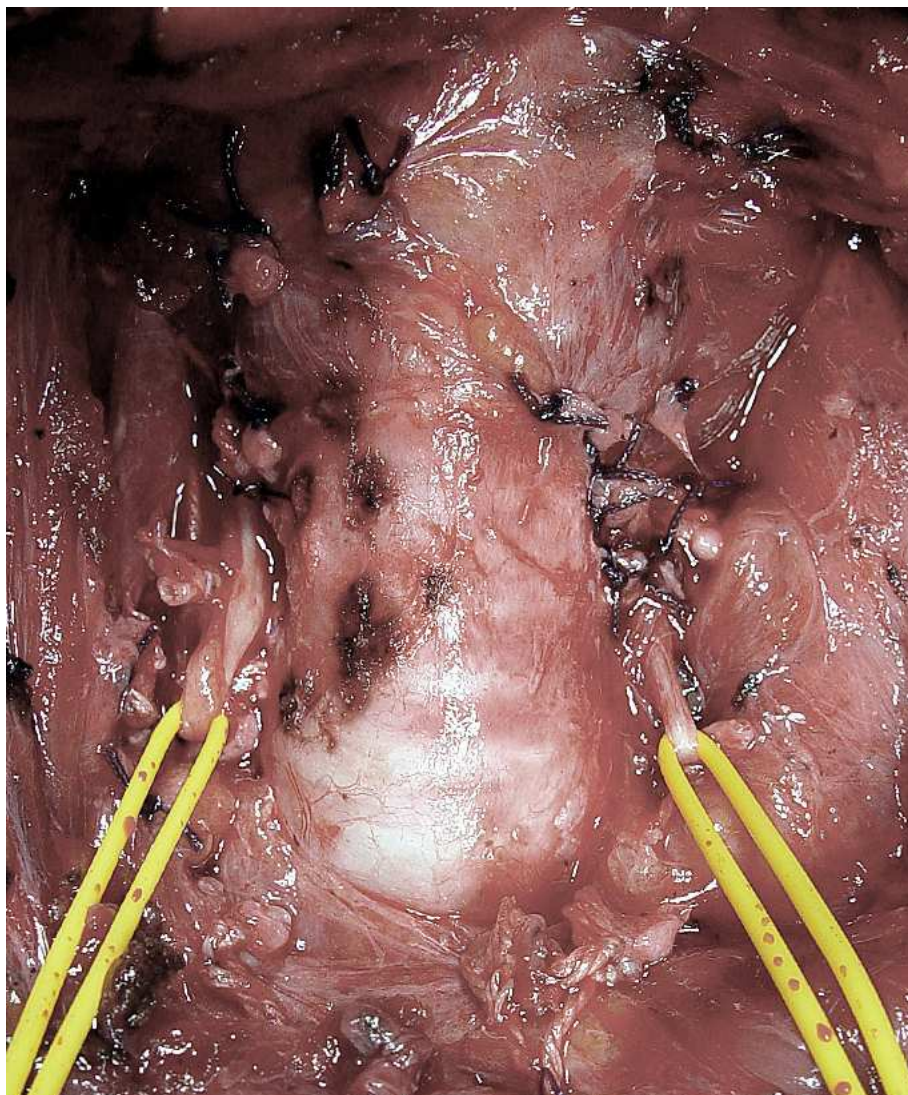
Isolamento dei nervi laringei inferiori (ricorrenti)



Lobo destro - Istmo - Lobo sinistro (superficie anteriore)

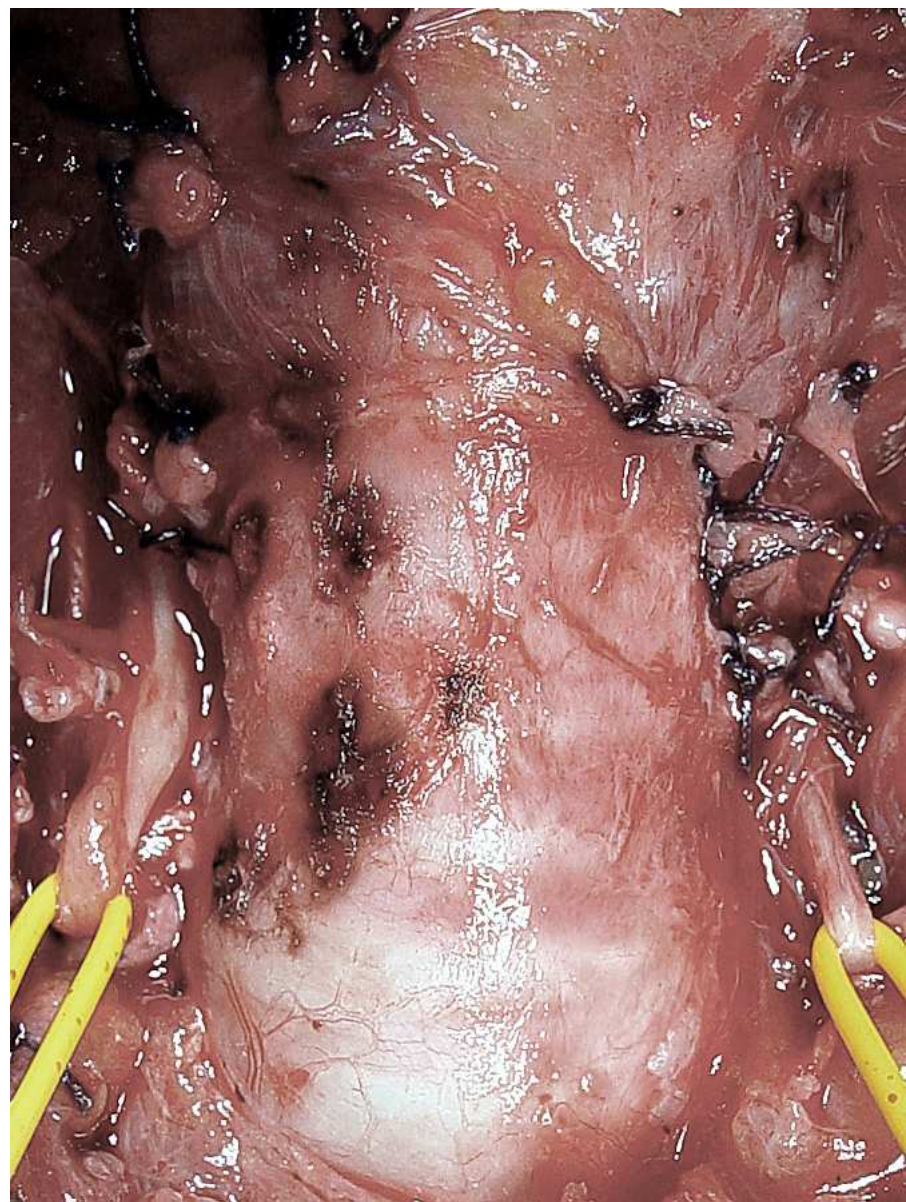

Lobo sinistro - Istmo - Lobo destro (superficie posteriore)

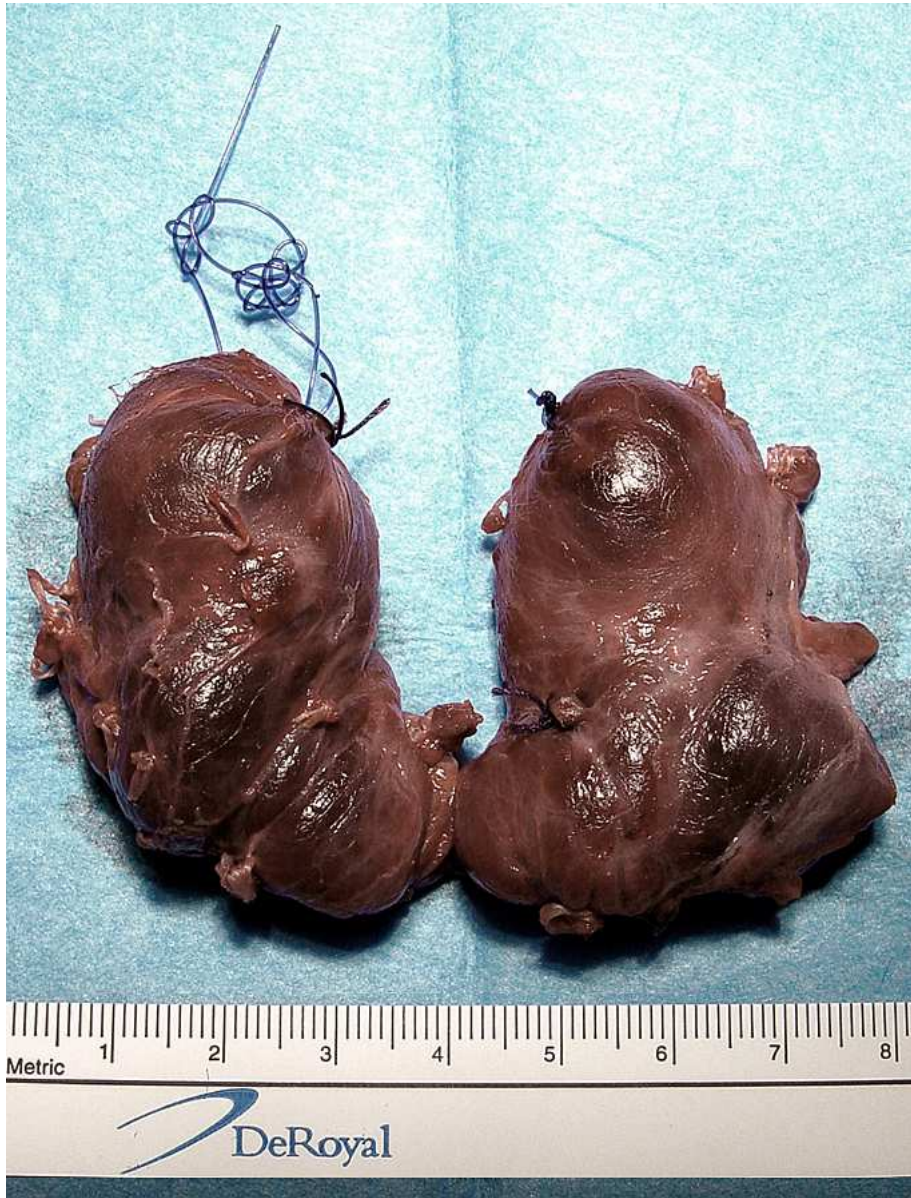

E.L. • Anni: 53 - F • Record: 43 • 12-06-2002

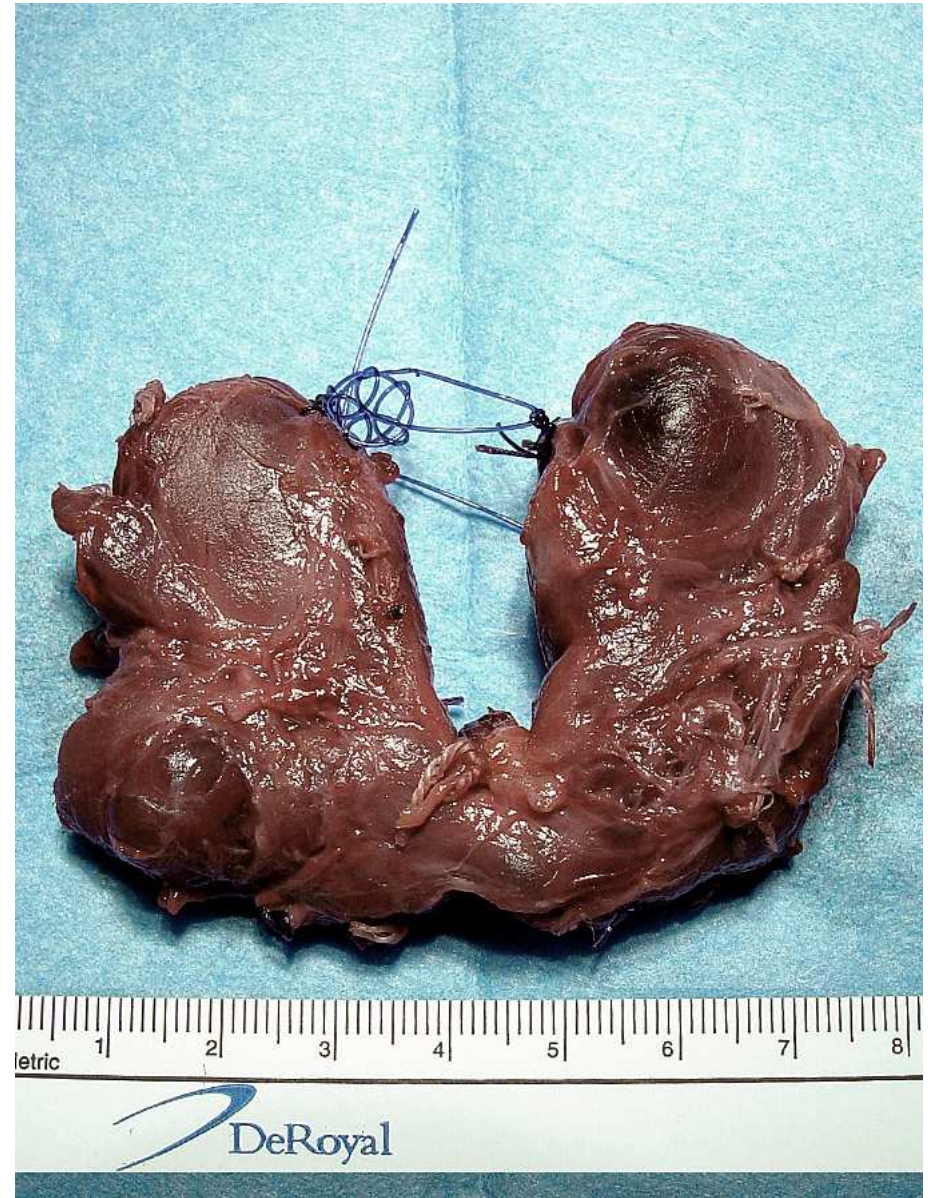
Tiroidectomia totale extracapsulare per gozzo plurinodulare pretossico



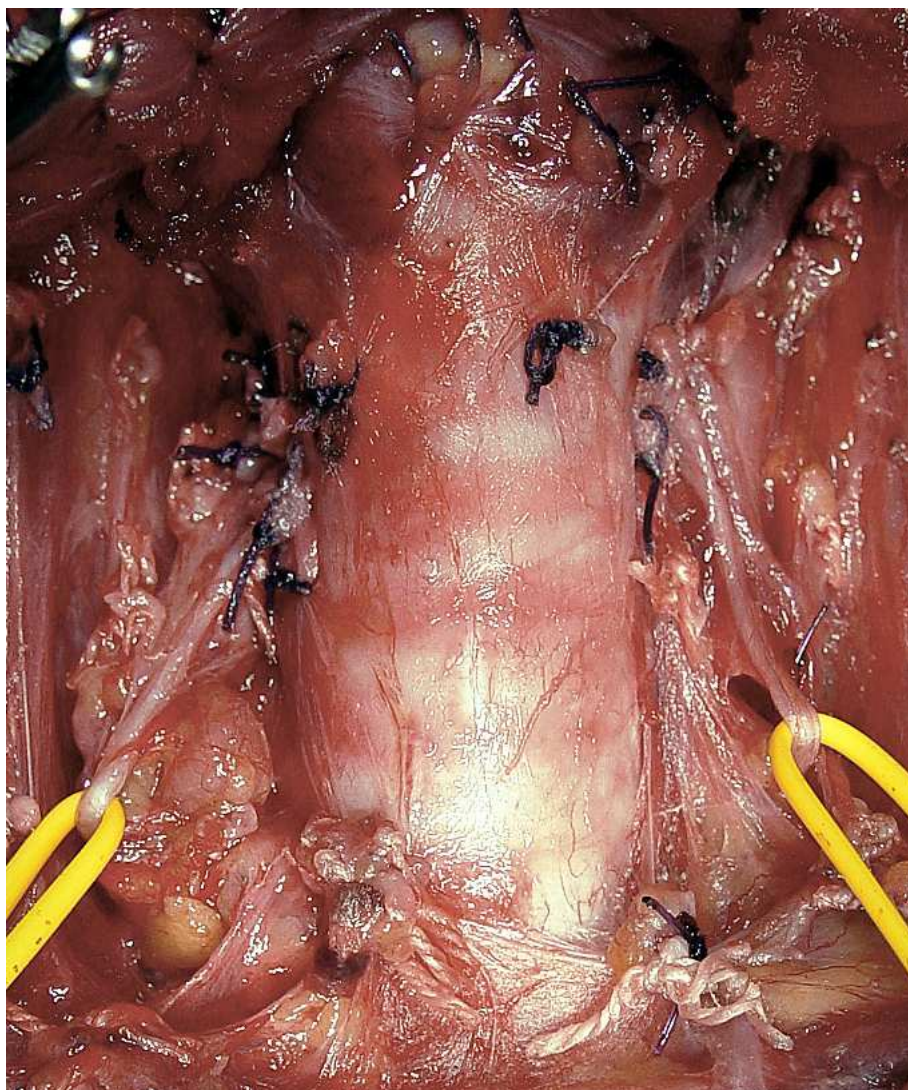
Isolamento dei nervi laringei inferiori (ricorrenti)



Lobo destro - Istmo - Lobo sinistro (superficie anteriore)

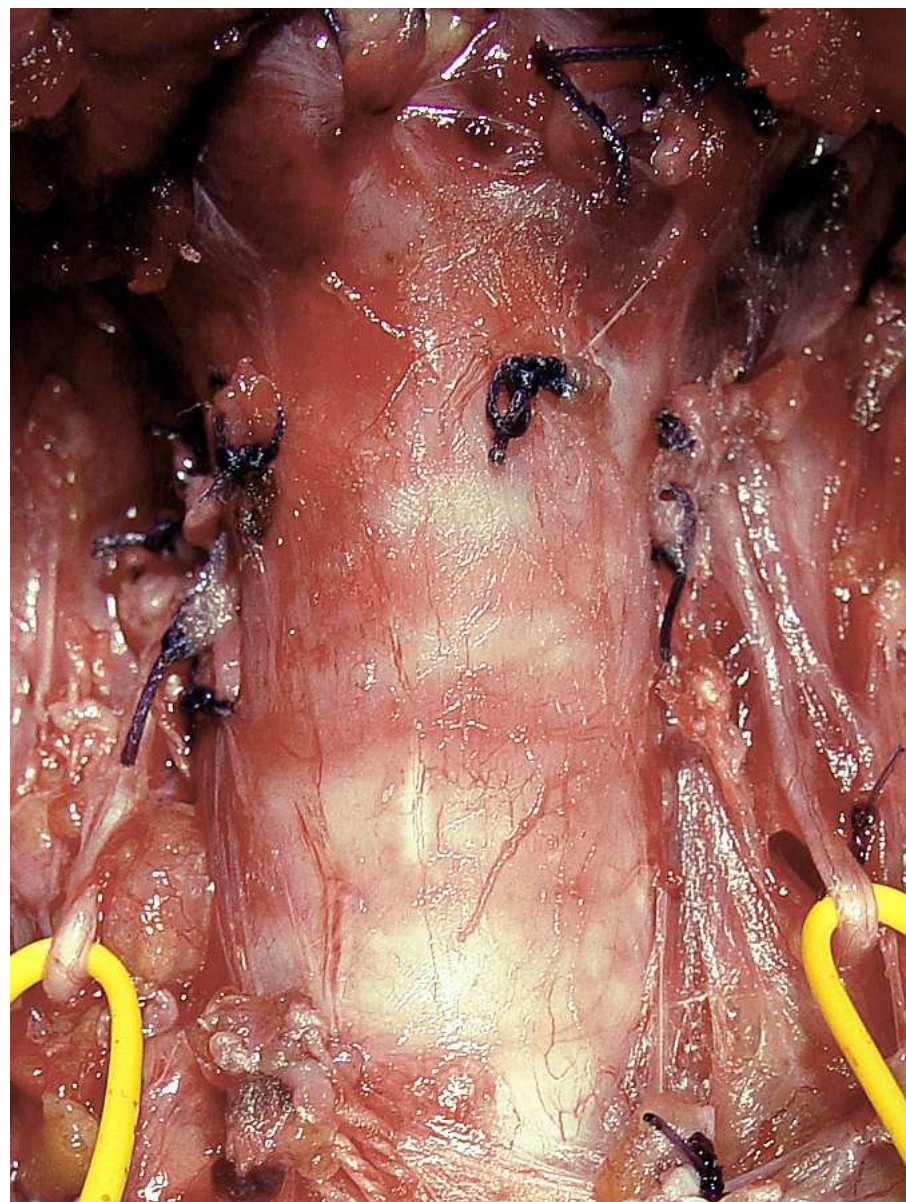


Lobo sinistro - Istmo - Lobo destro (superficie posteriore)

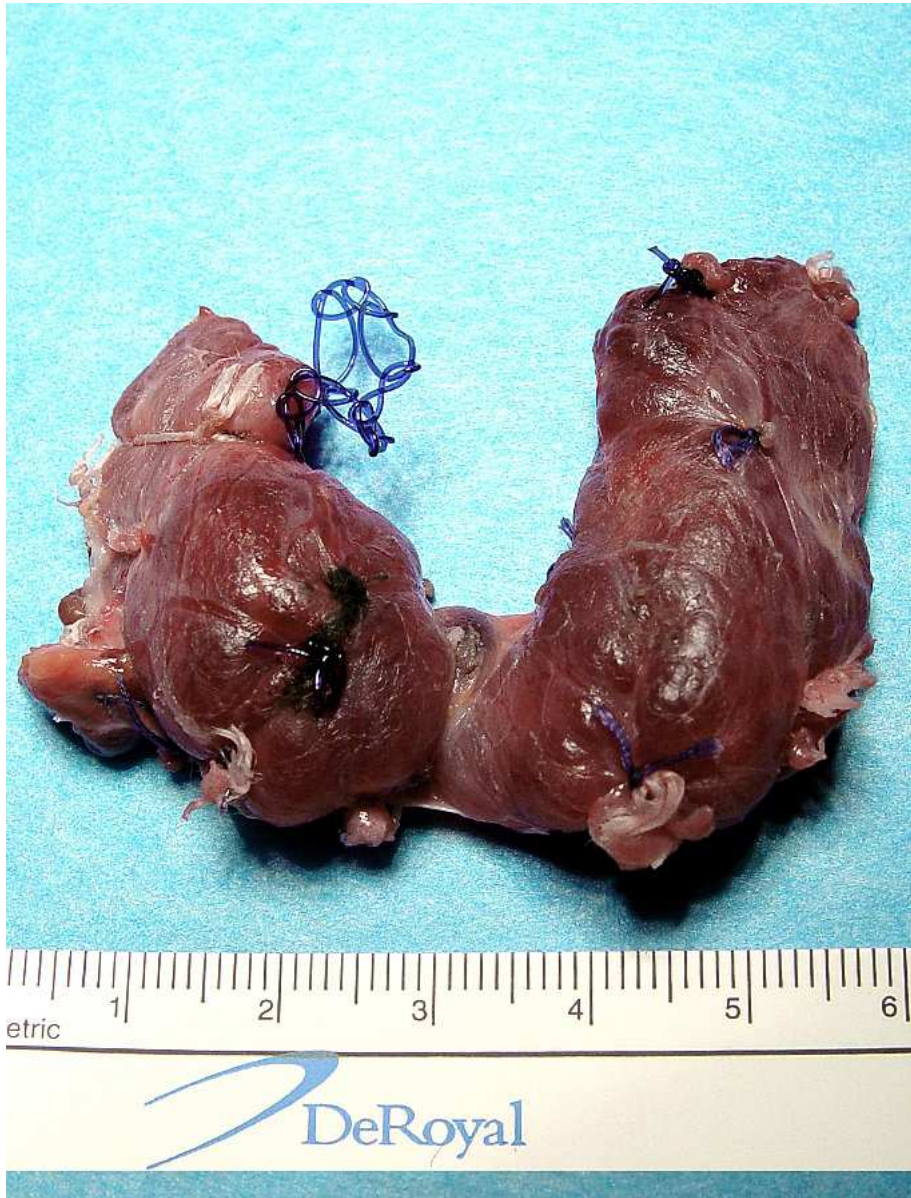

R.G. • Anni: 20 - F • Record: 44 • 14-06-2002

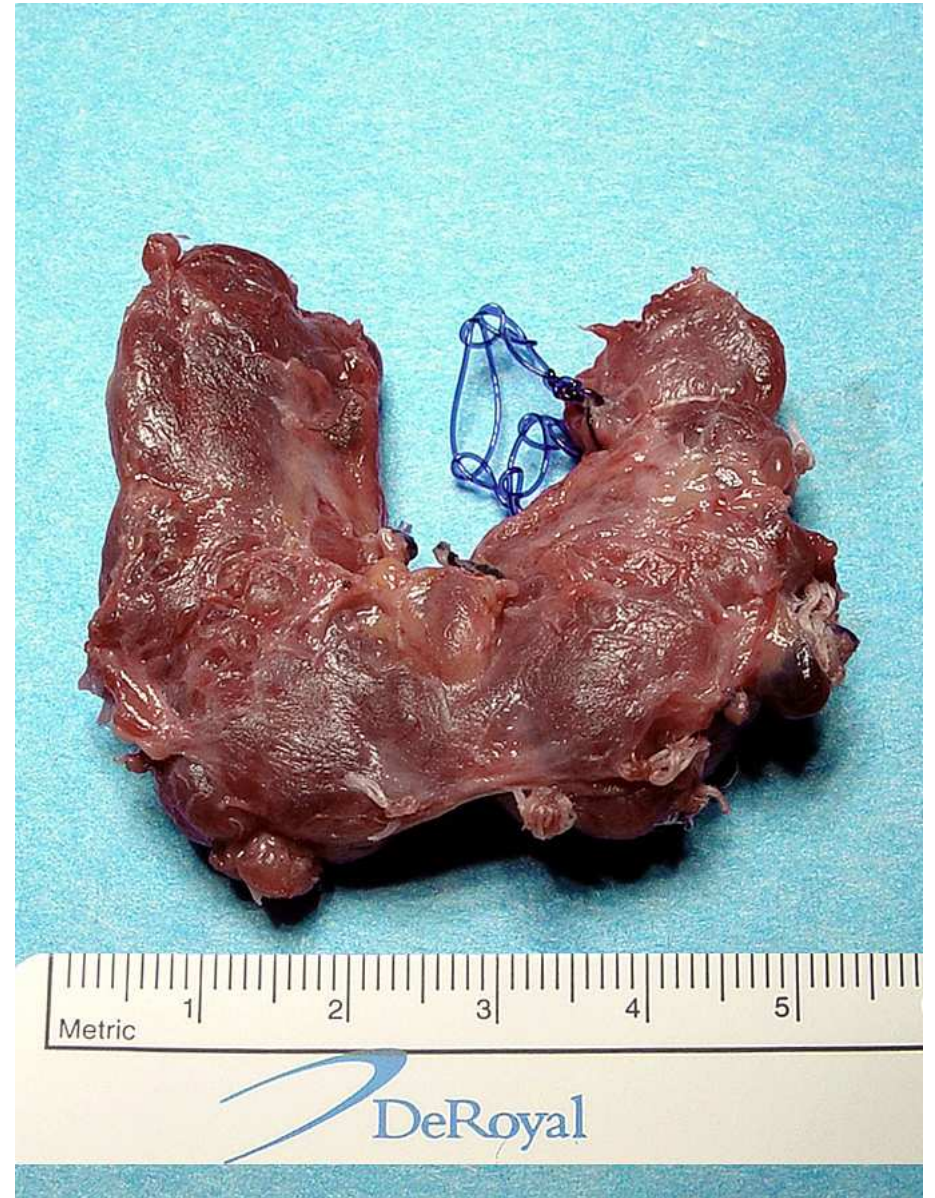Tiroidectomia totale extracapsulare per tiroidite cronica in gozzo plurinodulare



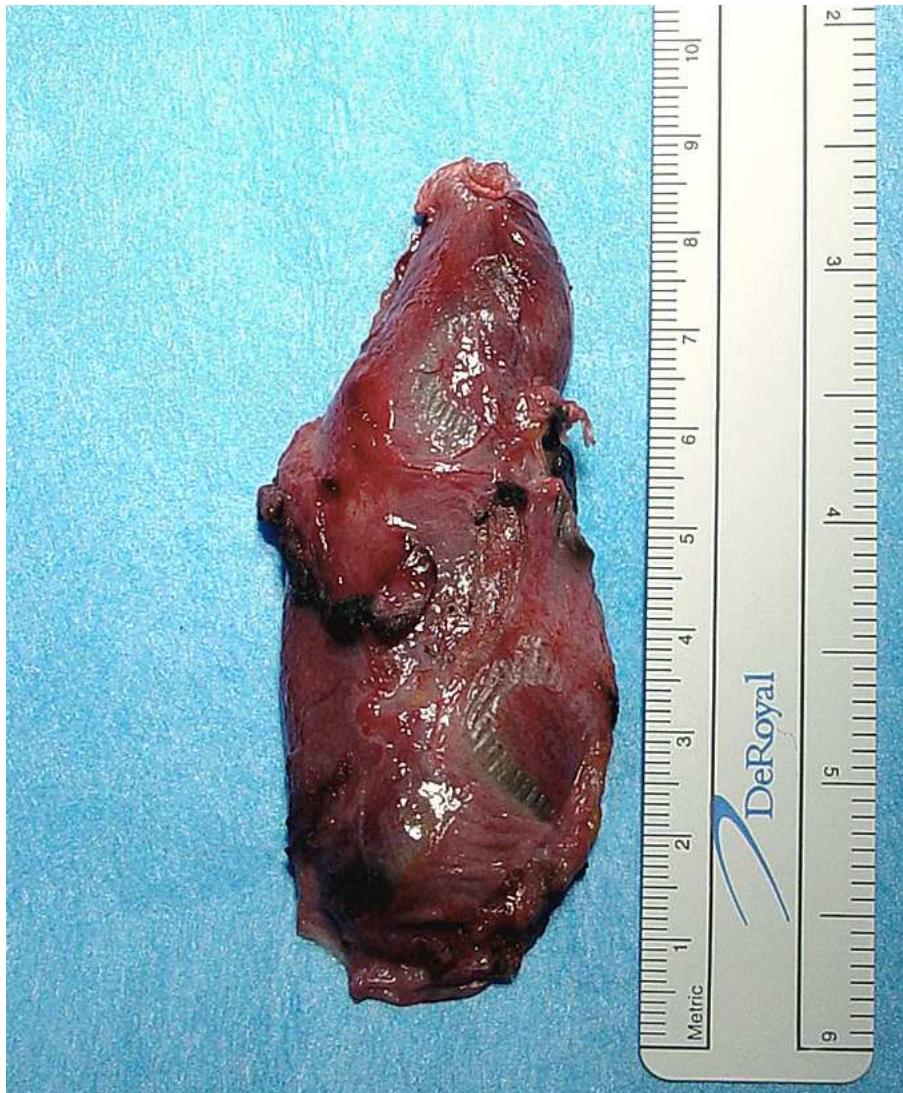Isolamento dei nervi laringei inferiori (ricorrenti)



Lobo destro - Istmo - Lobo sinistro (superficie anteriore)

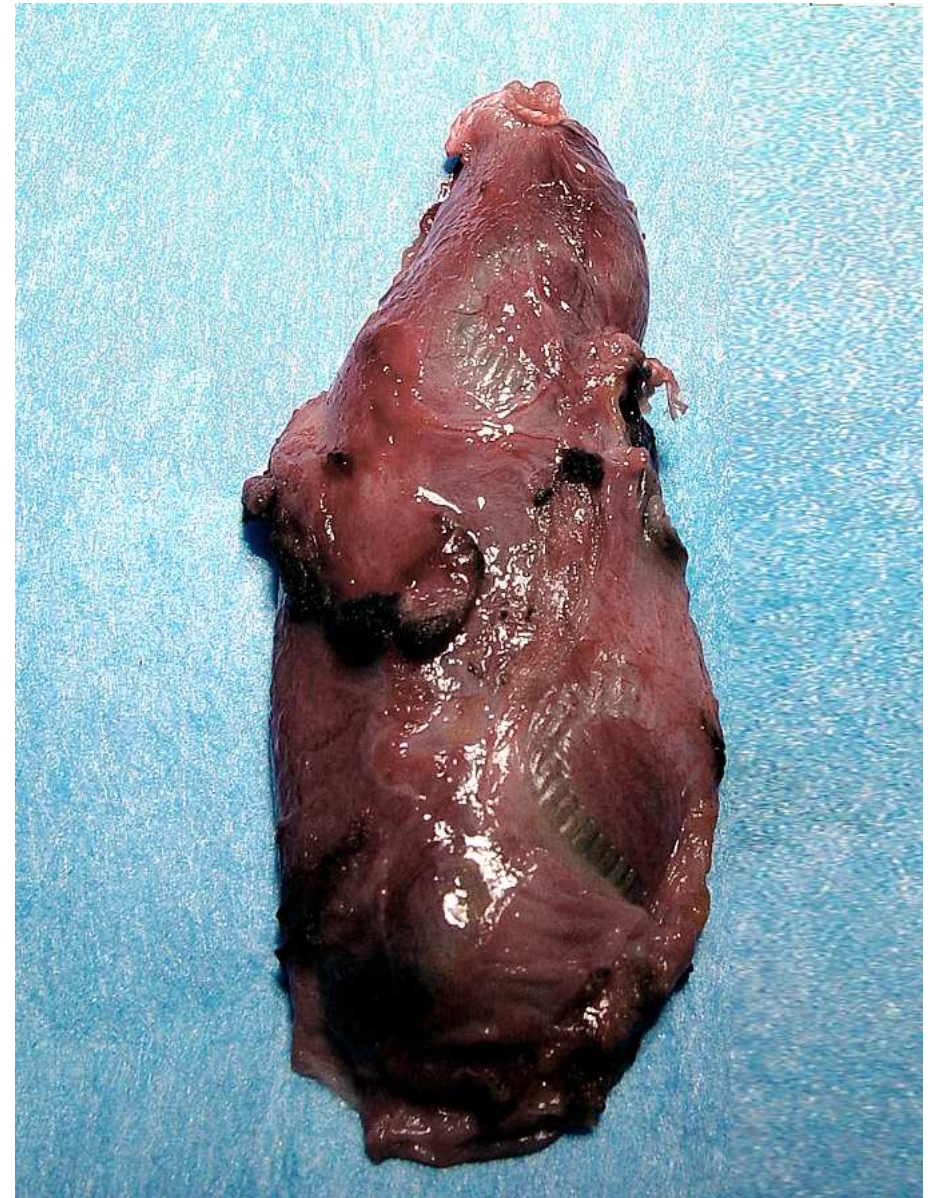


Lobo sinistro - Istmo - Lobo destro (superficie posteriore)

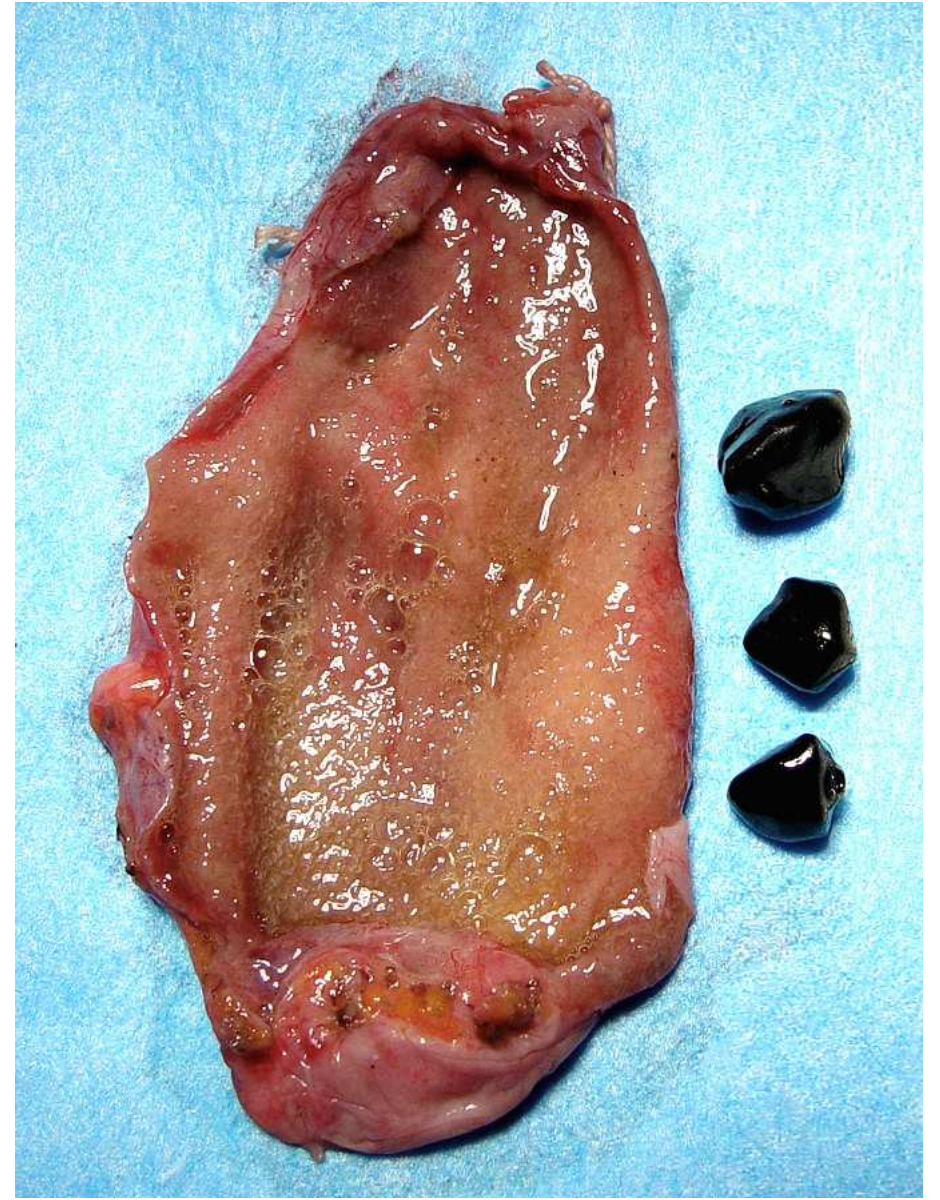
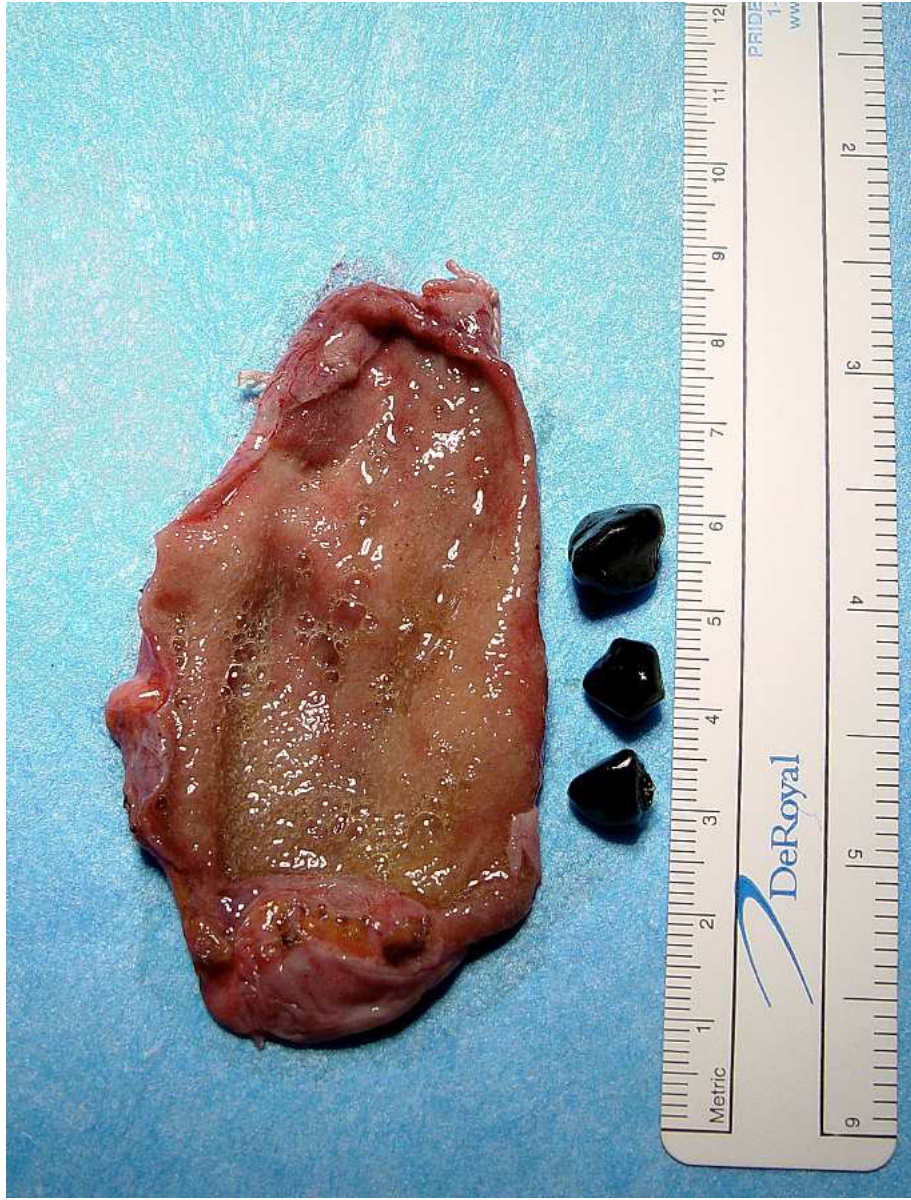
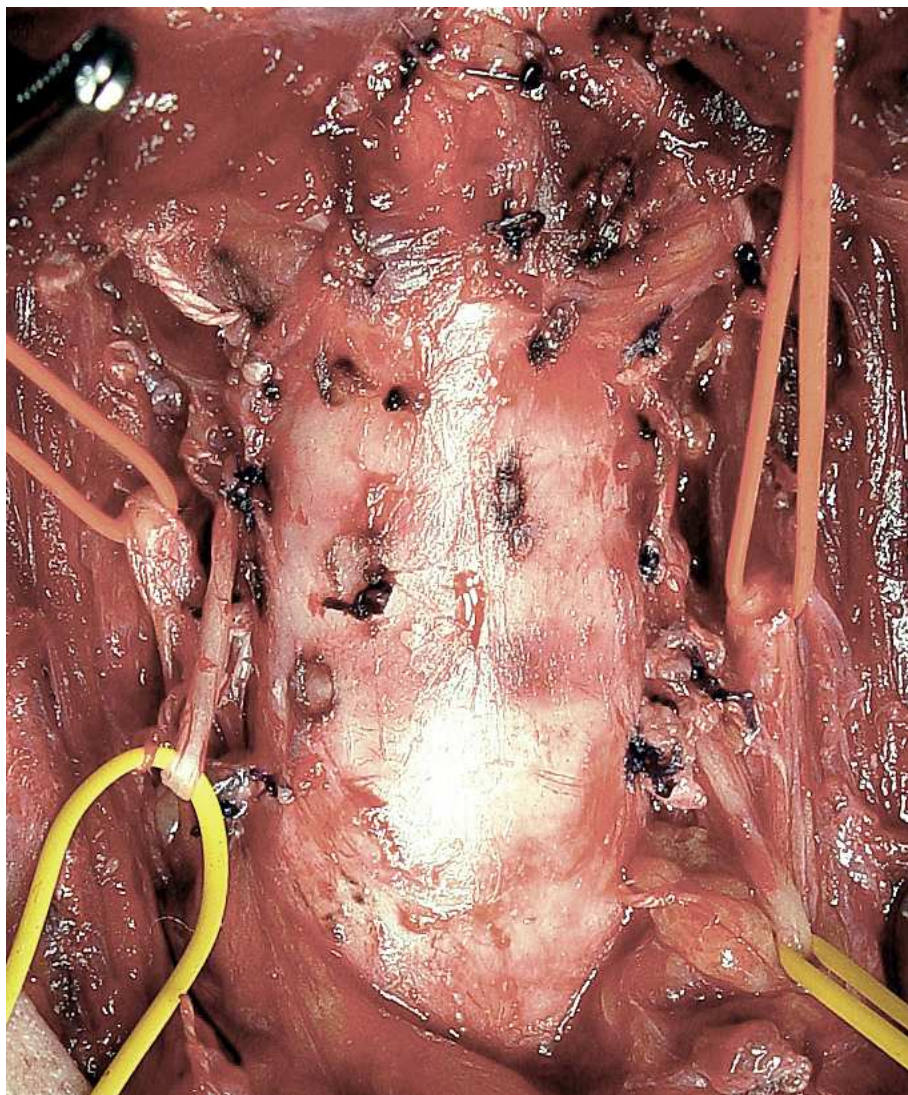
D.M.C. • Anni: 71 - F • Record: 45 • 17-06-2002

Colecistectomia retrograda per litiasi in recente ittero colostatico trattato con ERCP e PST



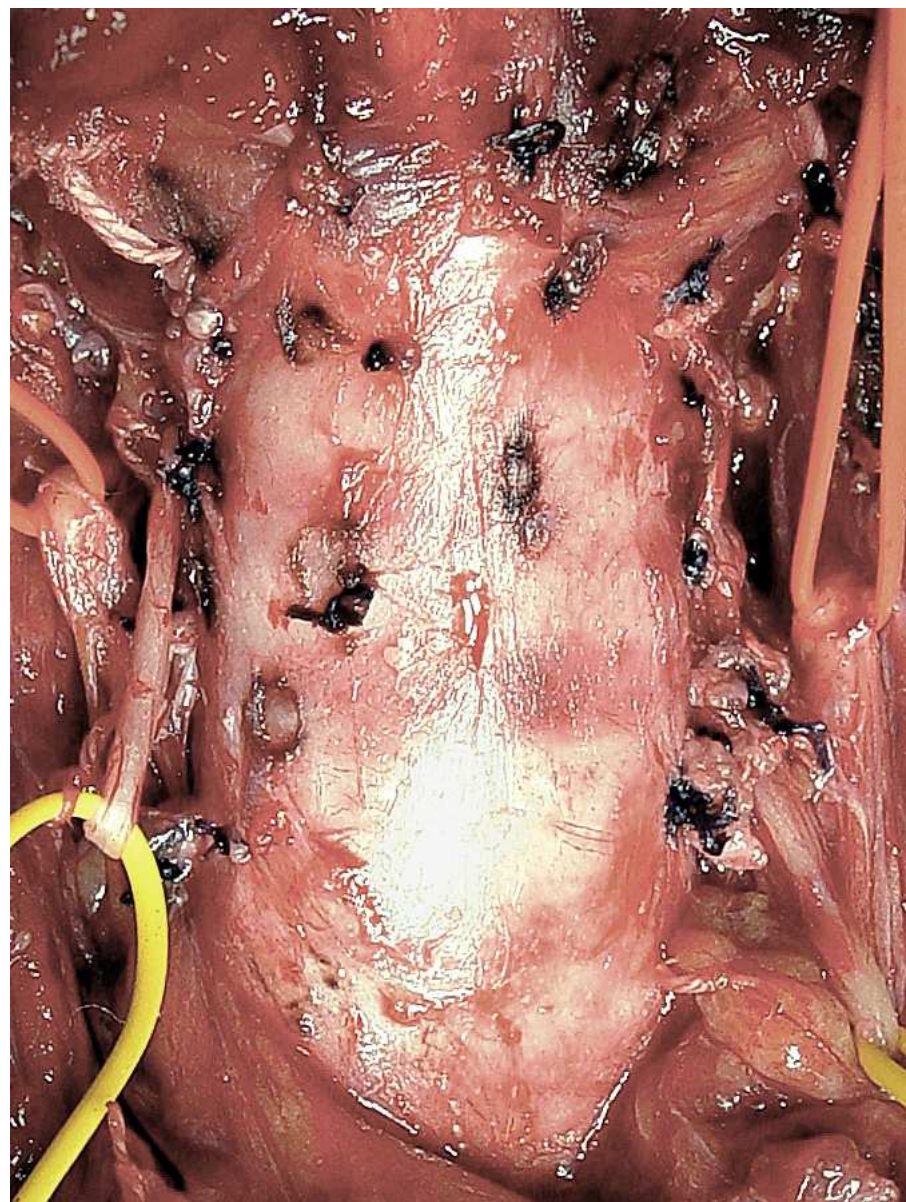




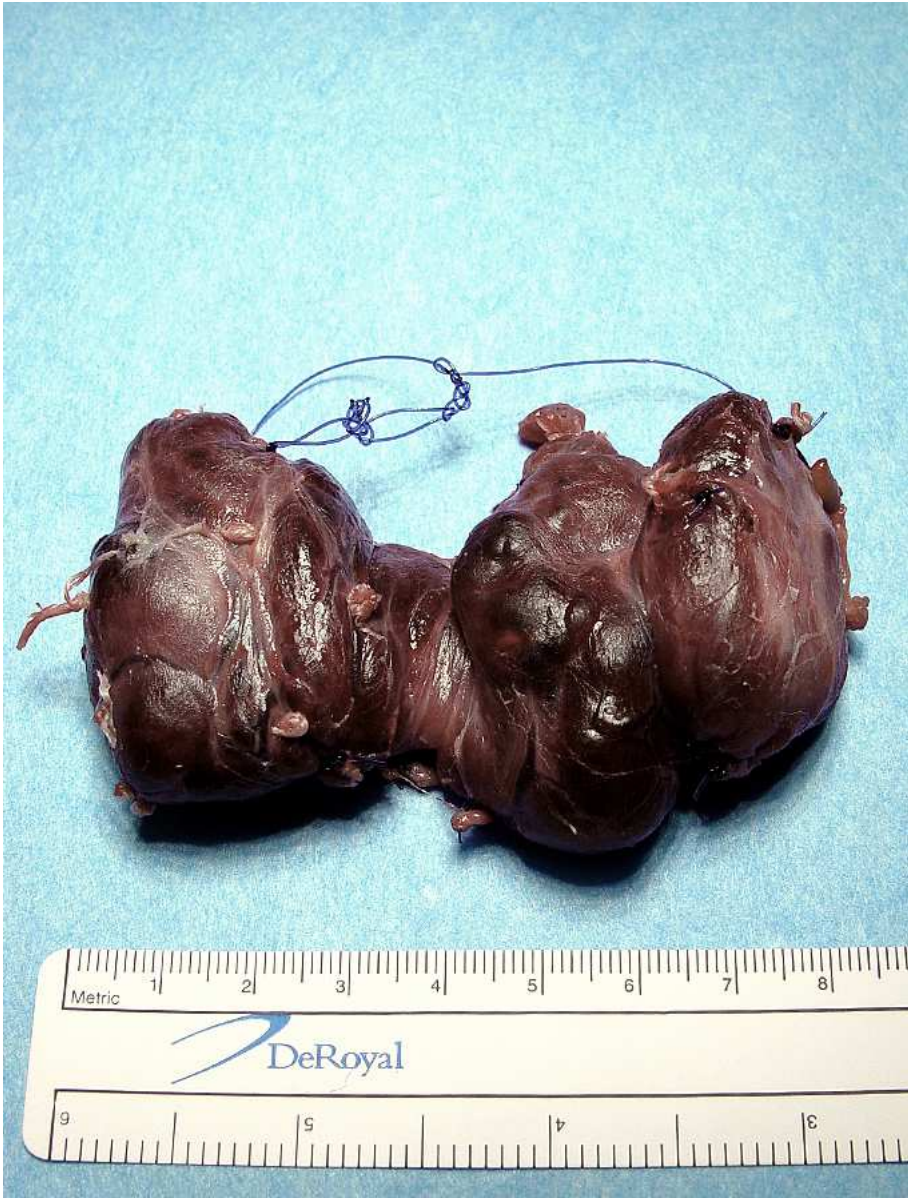

M.A. • Anni: 51 - F • Record: 46 • 19-06-2002

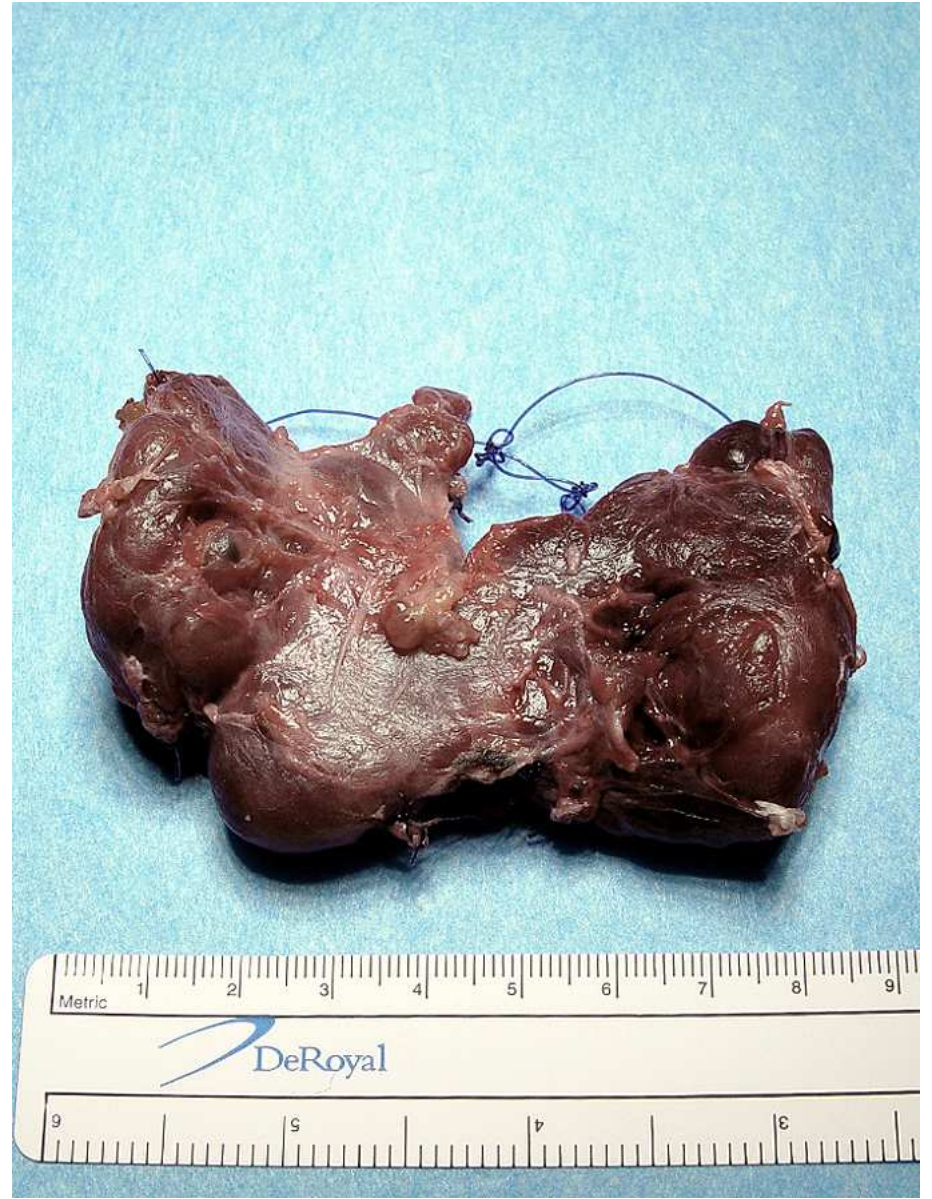Tiroidectomia totale extracapsulare per microcarcinoma papillifero del lobo dx in gozzo plurinodulare



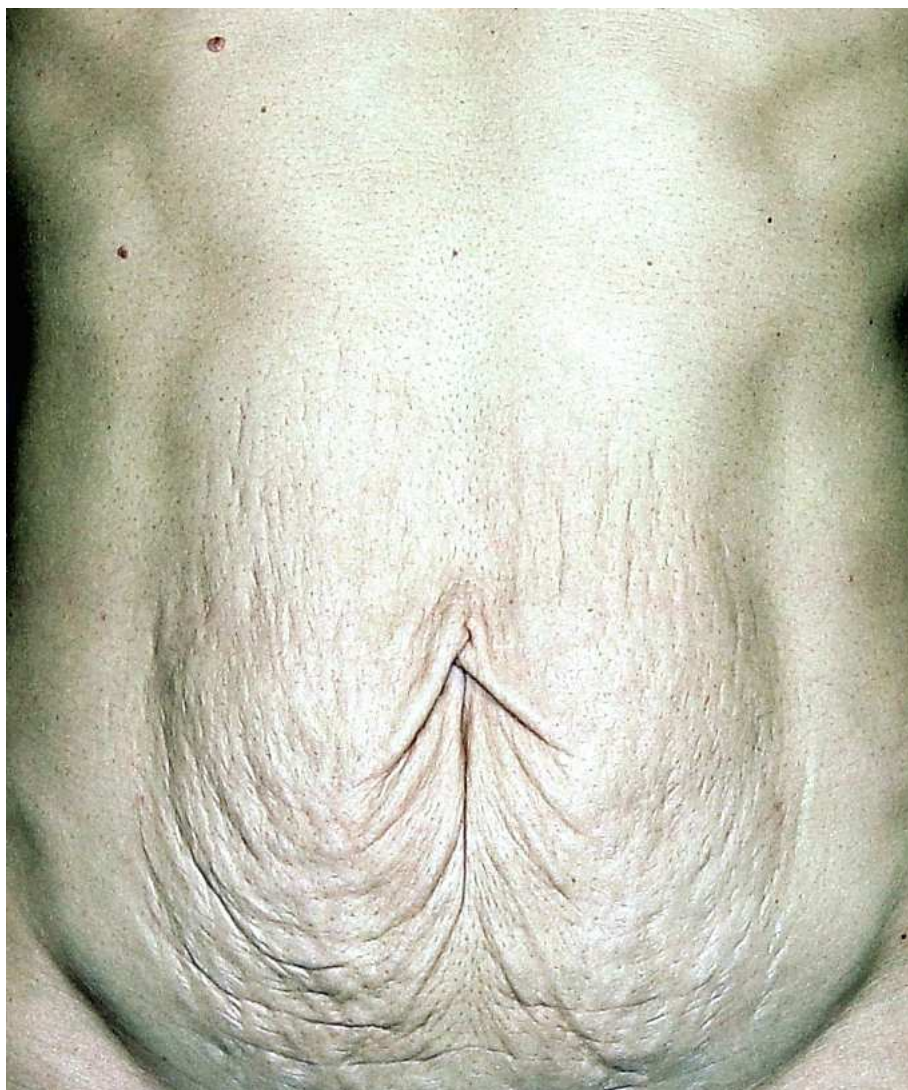Isolamento delle arterie tiroidee inferiori e dei nervi laringei inferiori (ricorrenti)



Lobo destro - Istmo - Lobo sinistro (superficie anteriore)

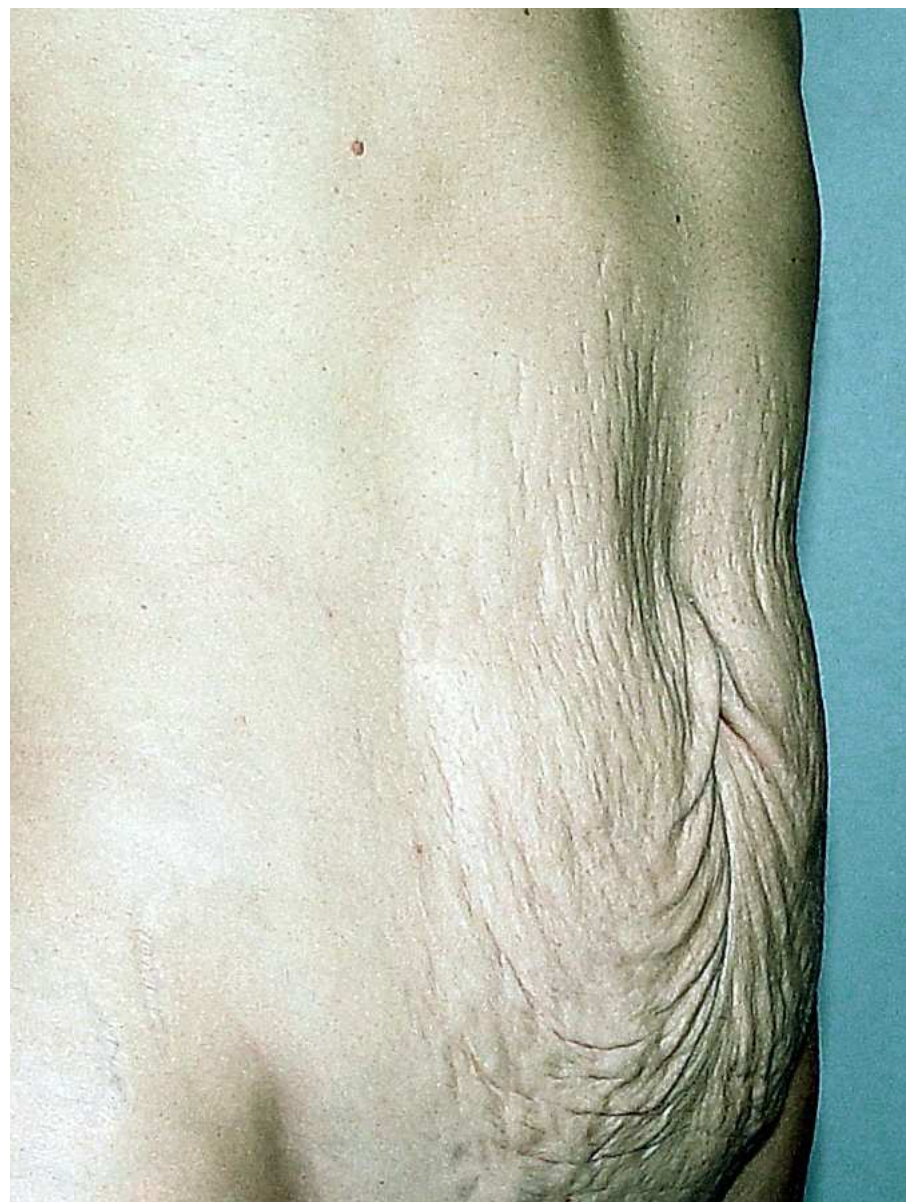

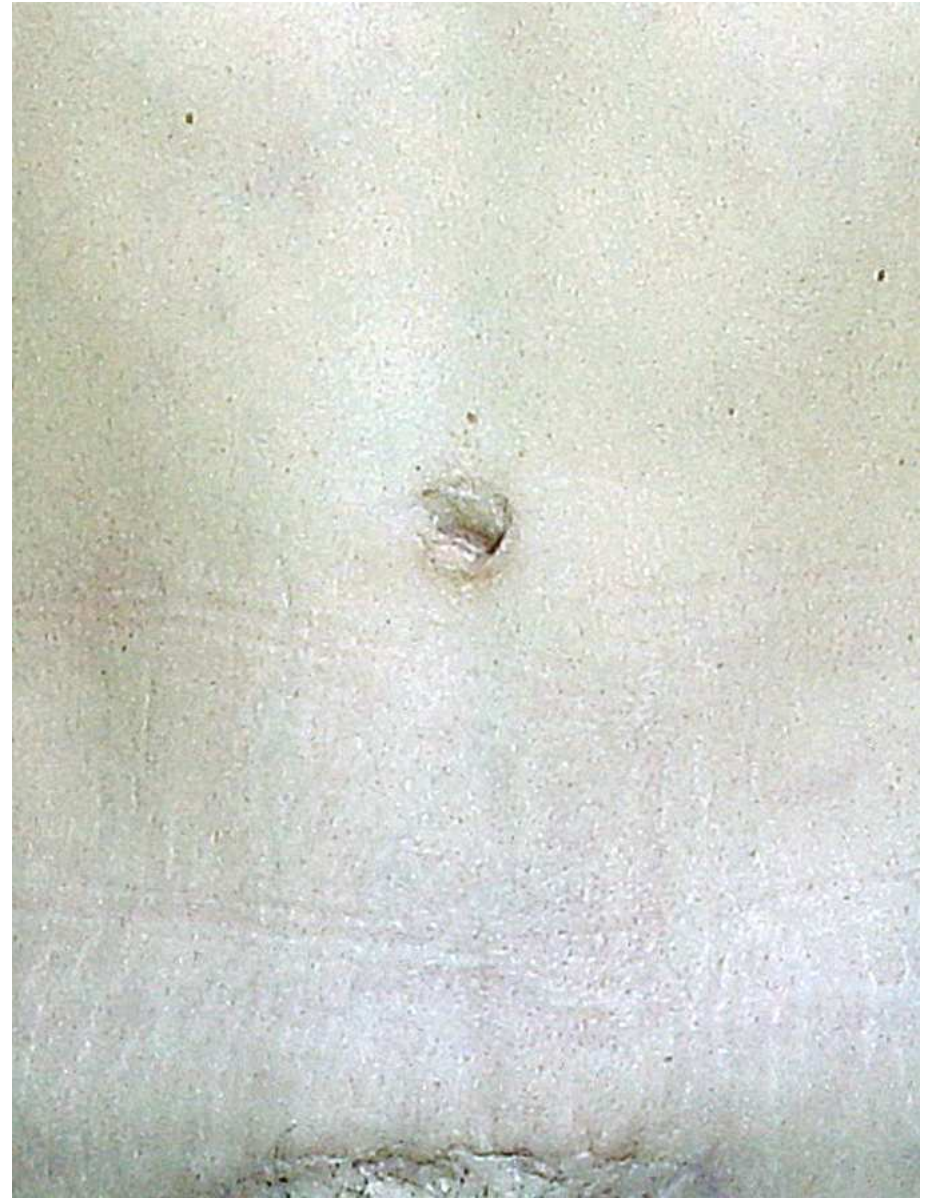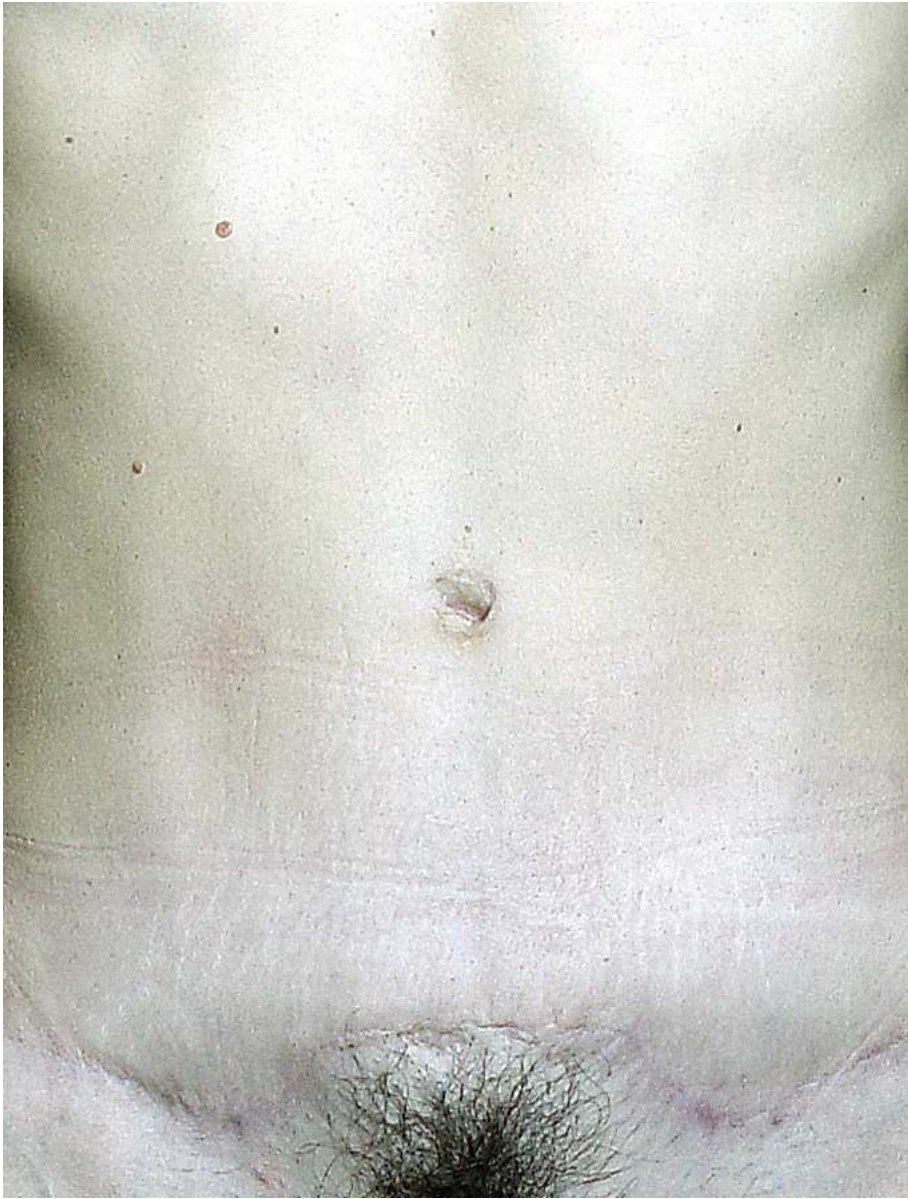Lobo sinistro - Istmo - Lobo destro (superficie posteriore)

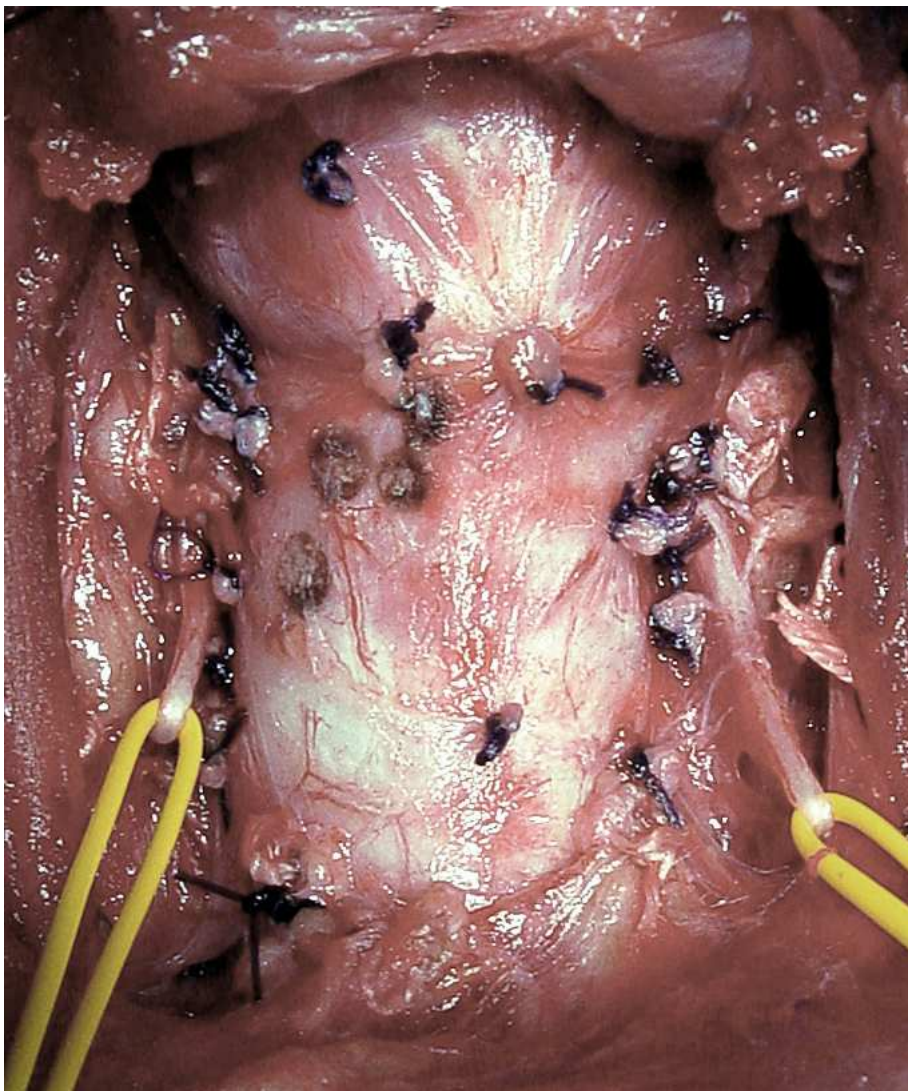


P.G. • Anni: 37 - F • Record: 47 • 22-06-2002

Addominoplastica sec. Serson mod. per addome pendulo

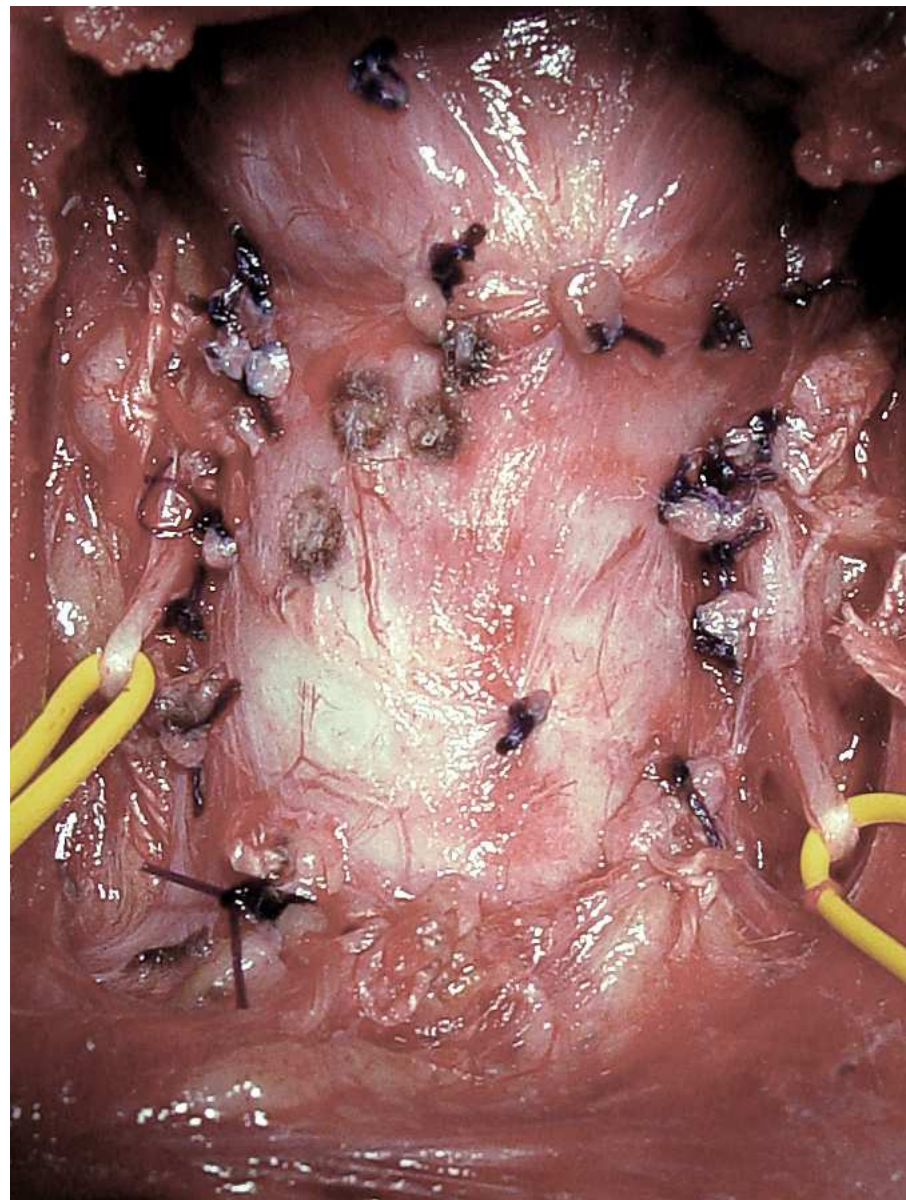




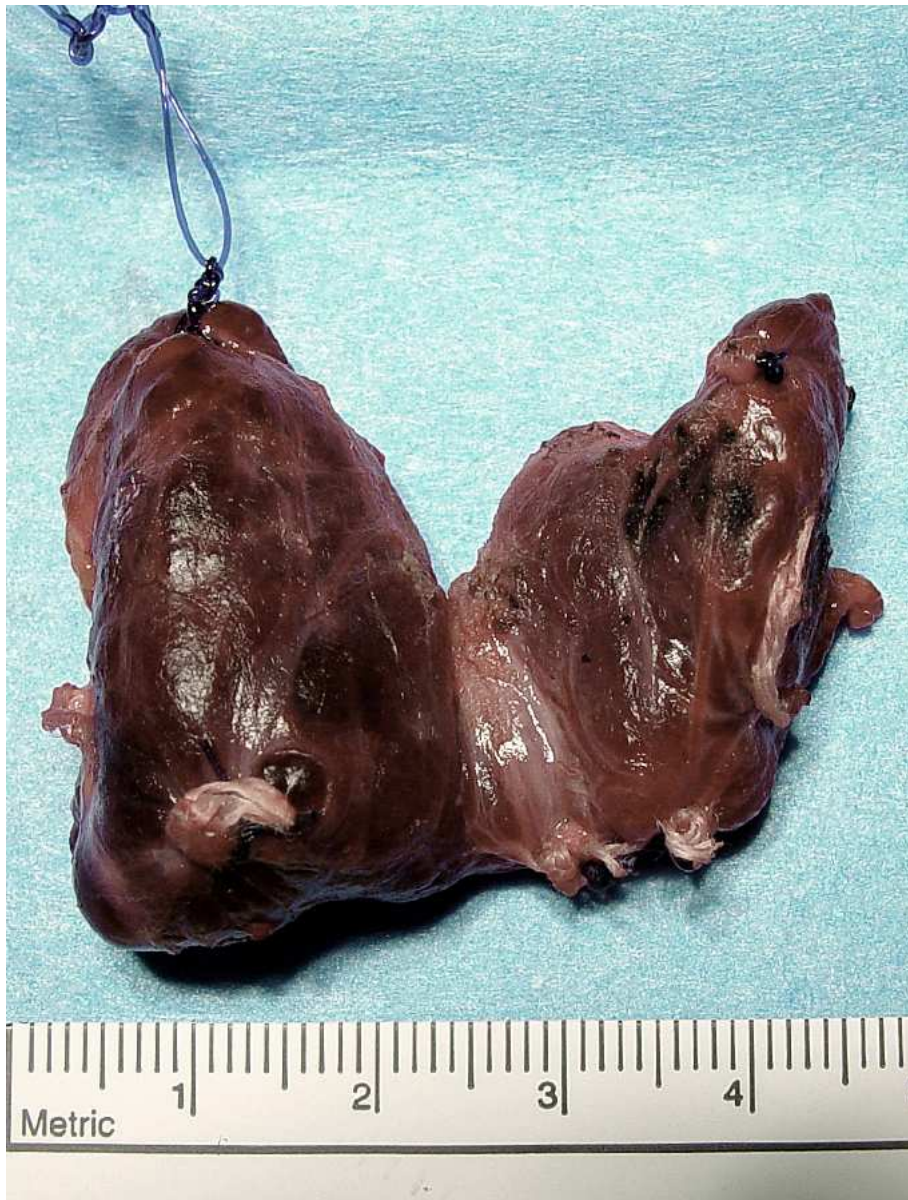

C.L. · Anni: 15 - F · Record: 48 · 10-07-2002

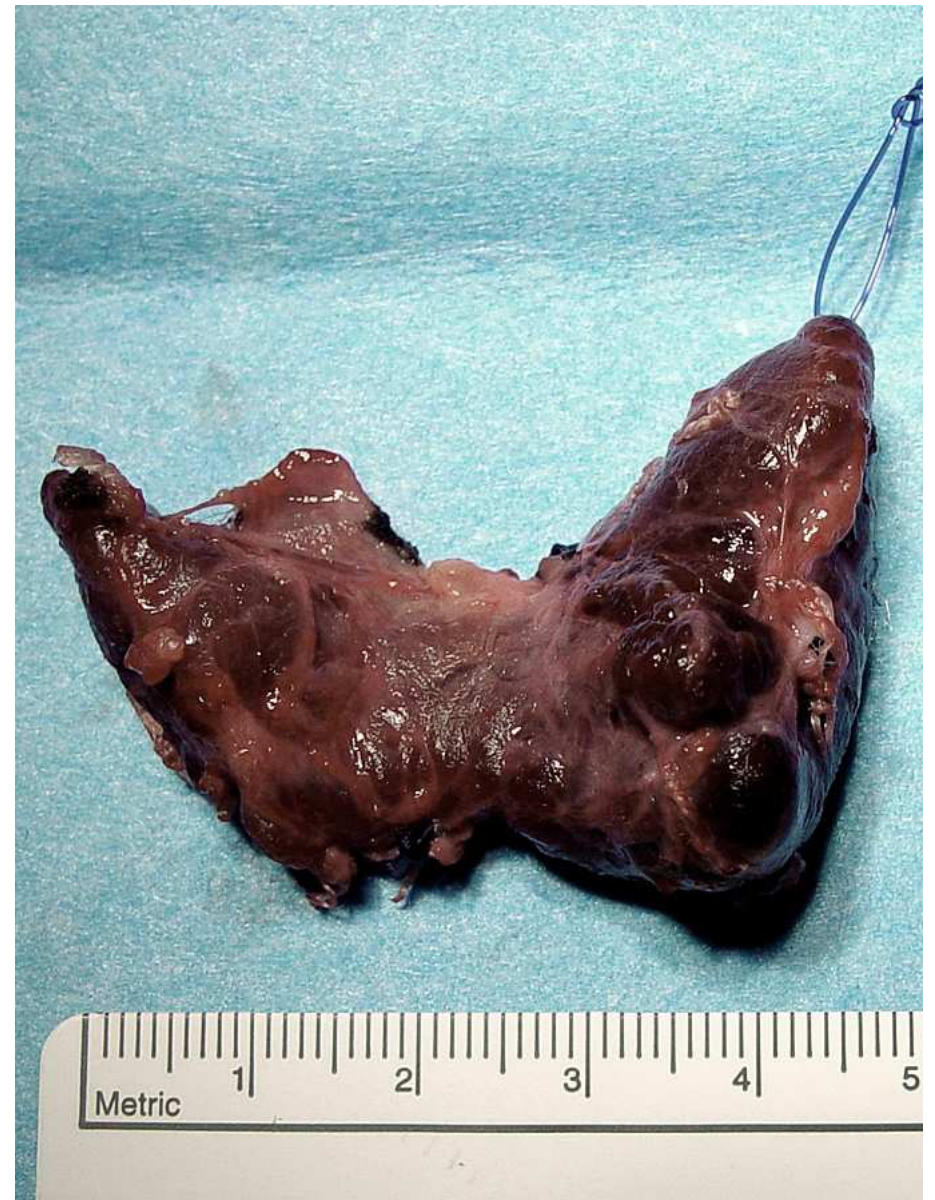Tiroidectomia totale extracapsulare per microcarcinoma papillifero del lobo dx in gozzo plurinodulare



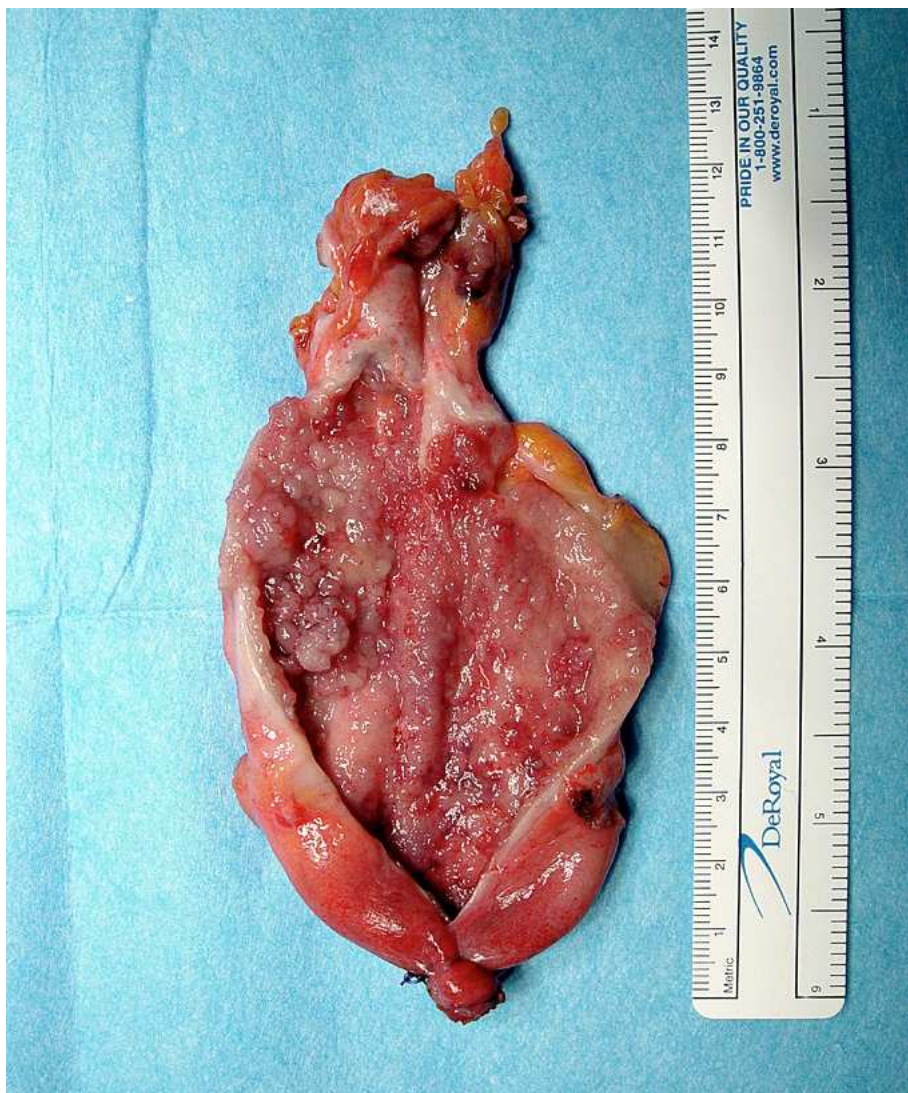
Isolamento dei nervi laringei inferiori (ricorrenti)



Lobo destro - Istmo - Lobo sinistro (superficie anteriore)



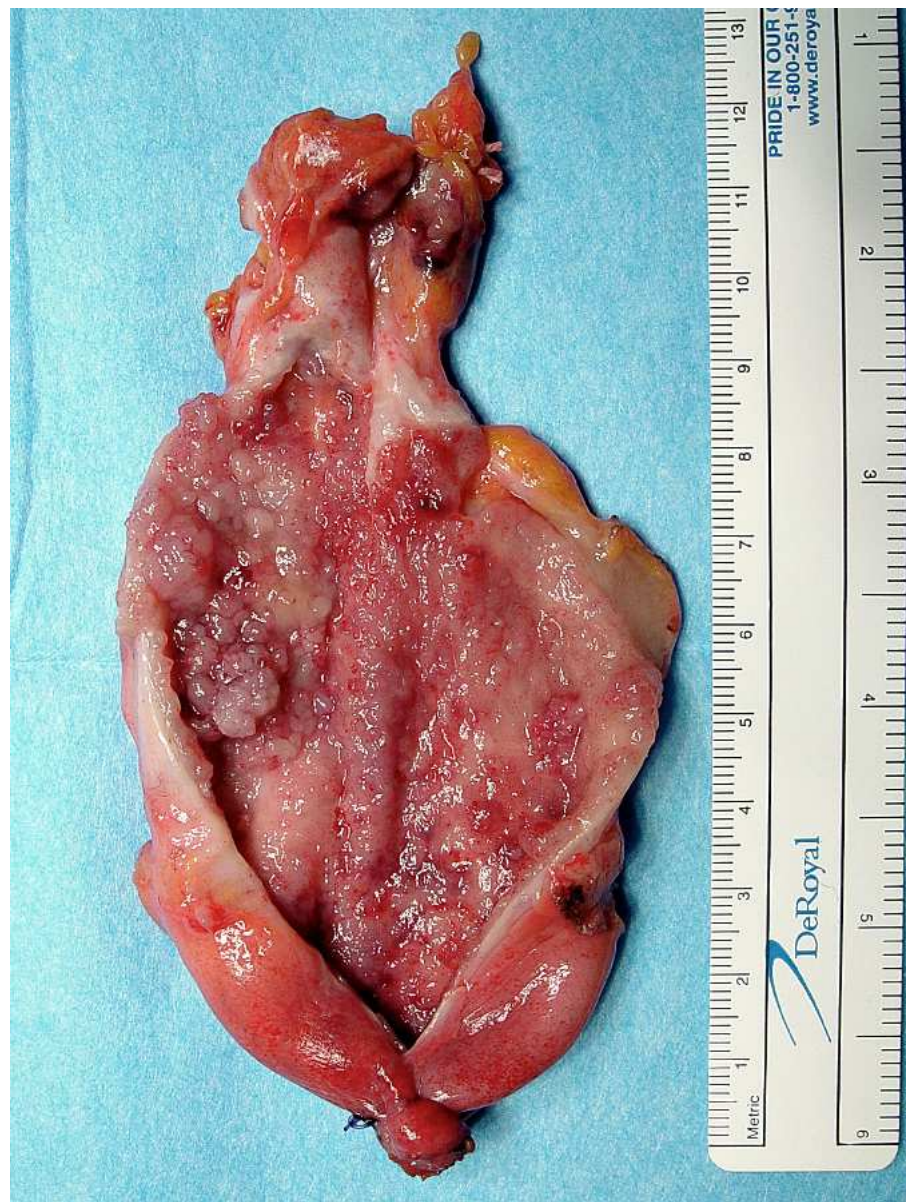Lobo sinistro - Istmo - Lobo destro (superficie posteriore)



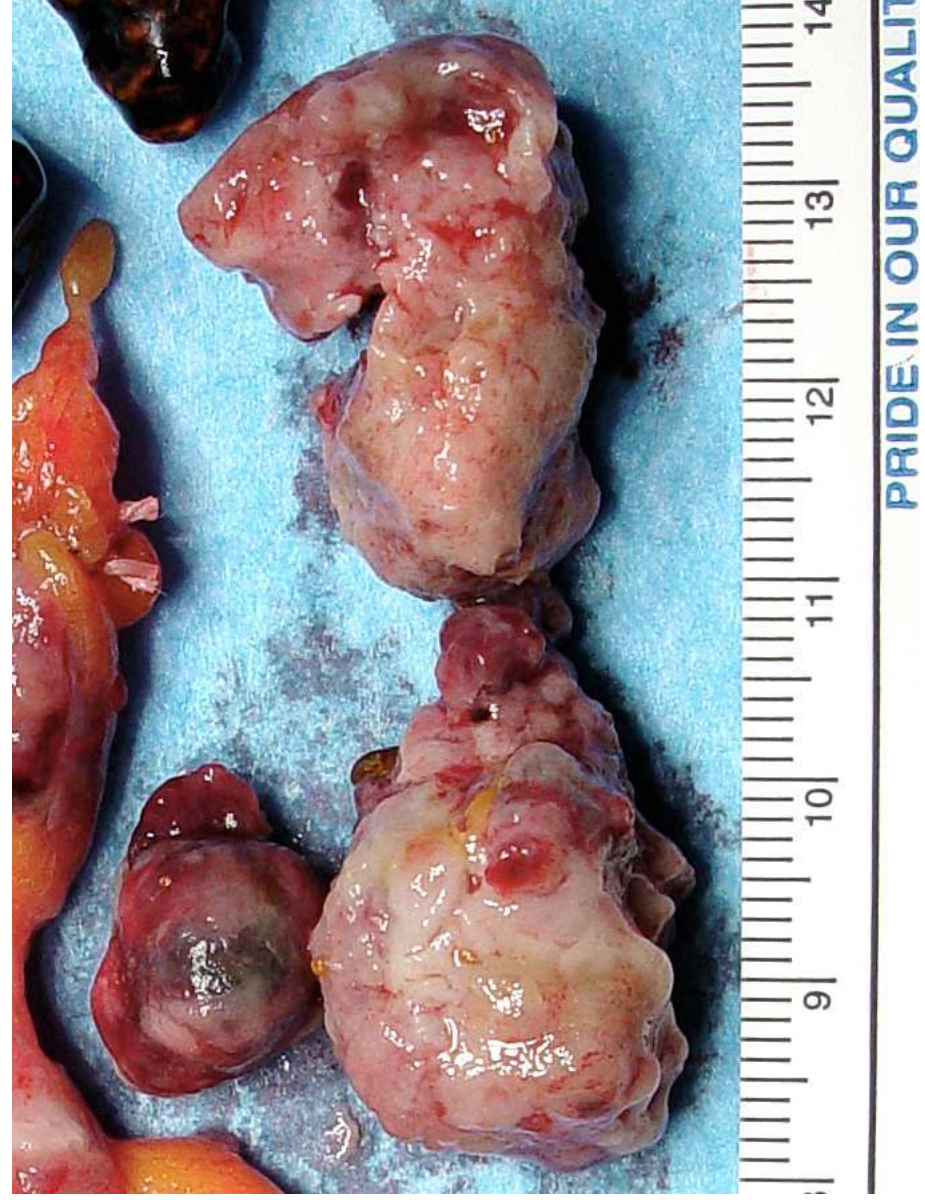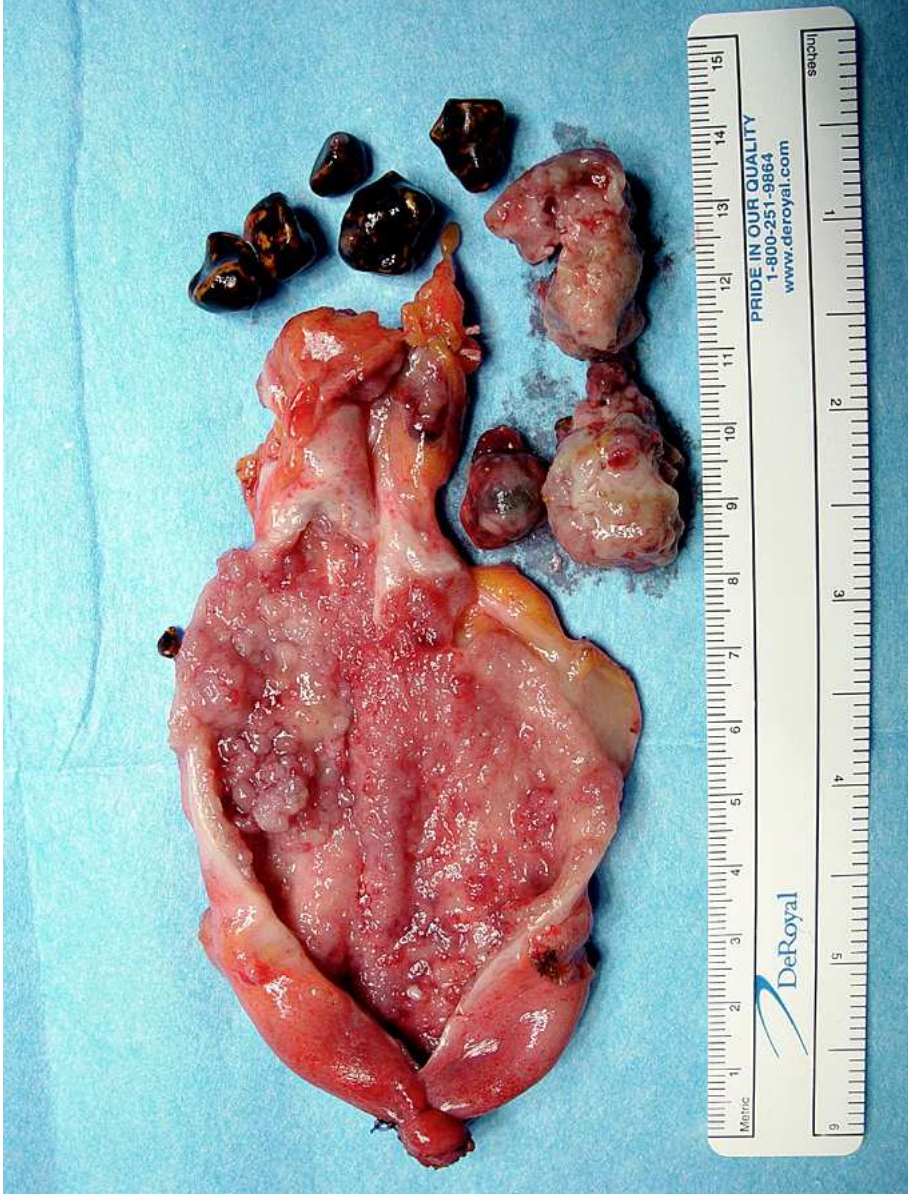B.V. · Anni: 76 - F · Record: 49 · 10-07-2002

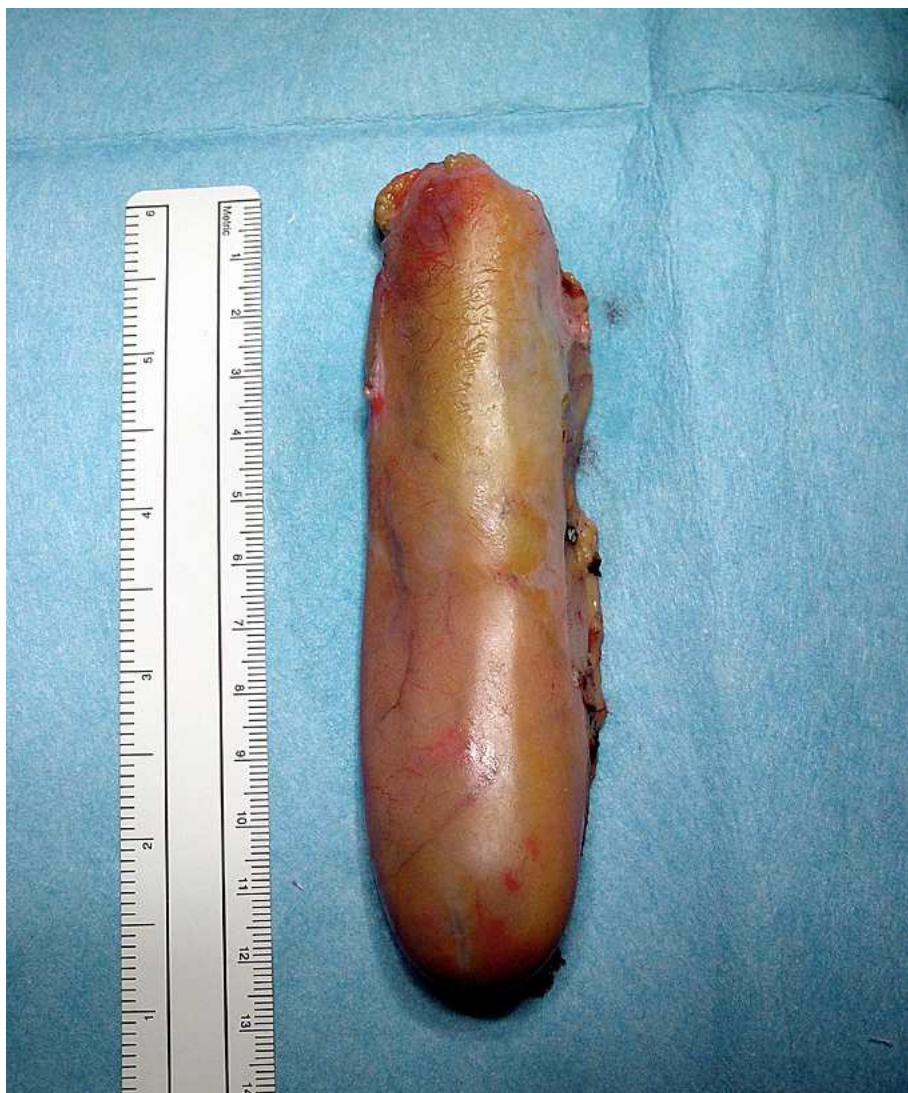Colecistectomia retrograda per adenocarcinoma in recente PST perendoscopica per litiasi della VBP

DIGITAL IMAGING



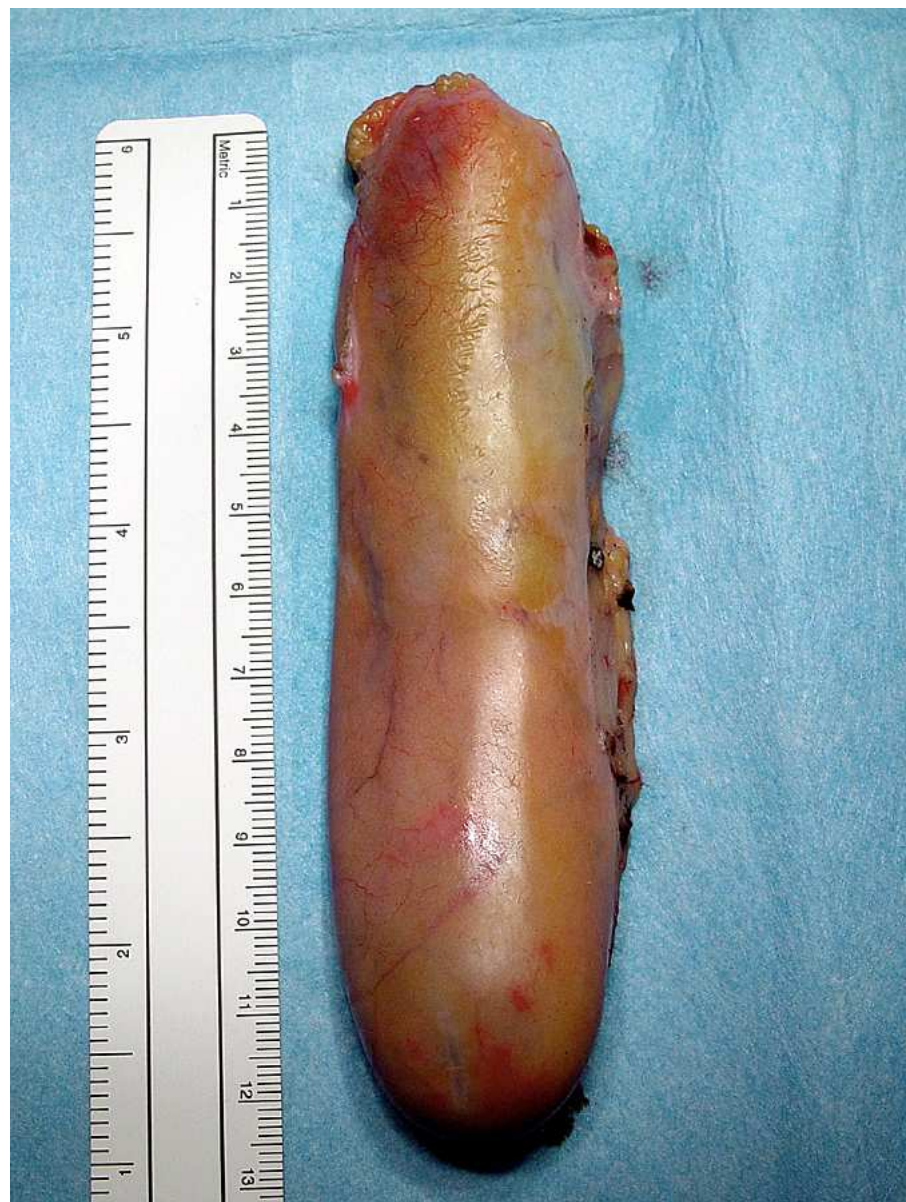

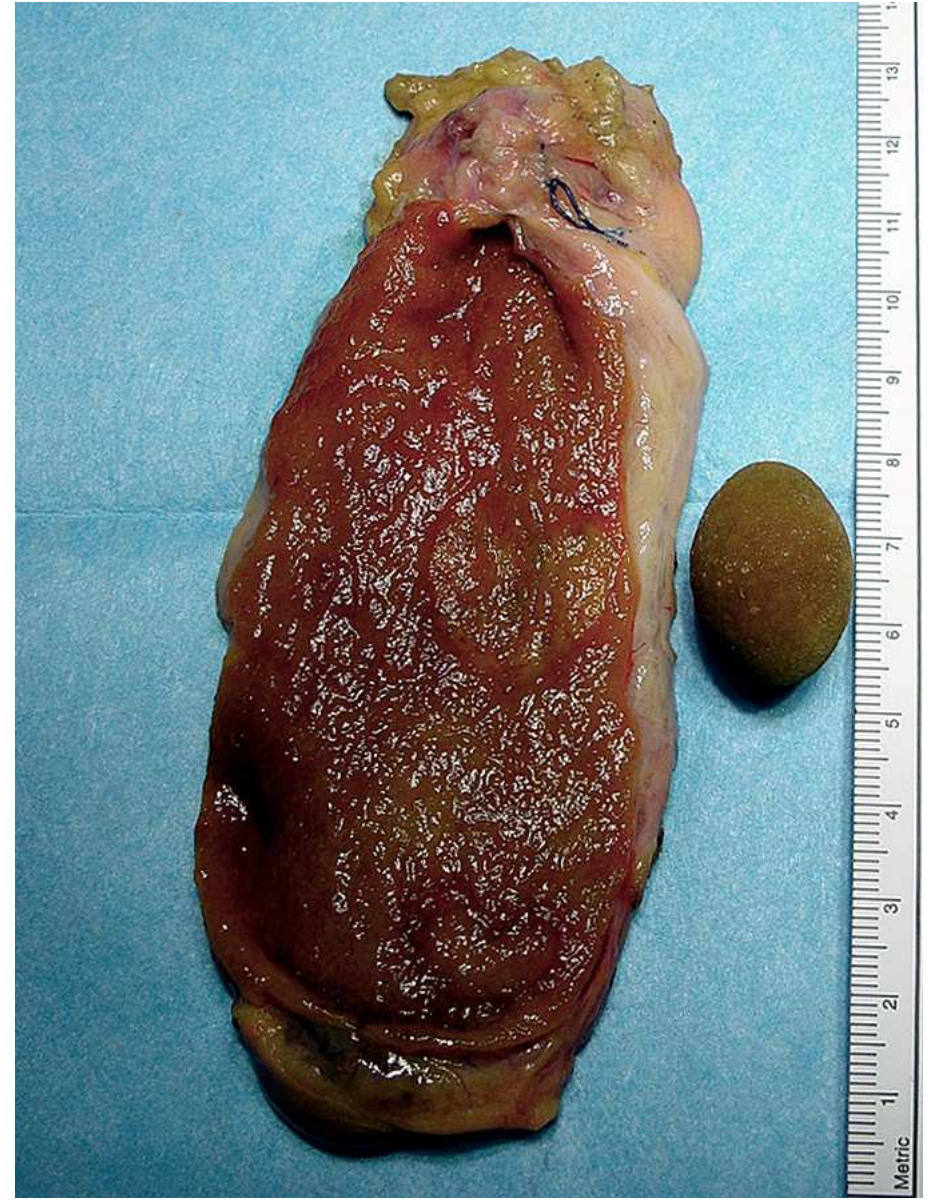

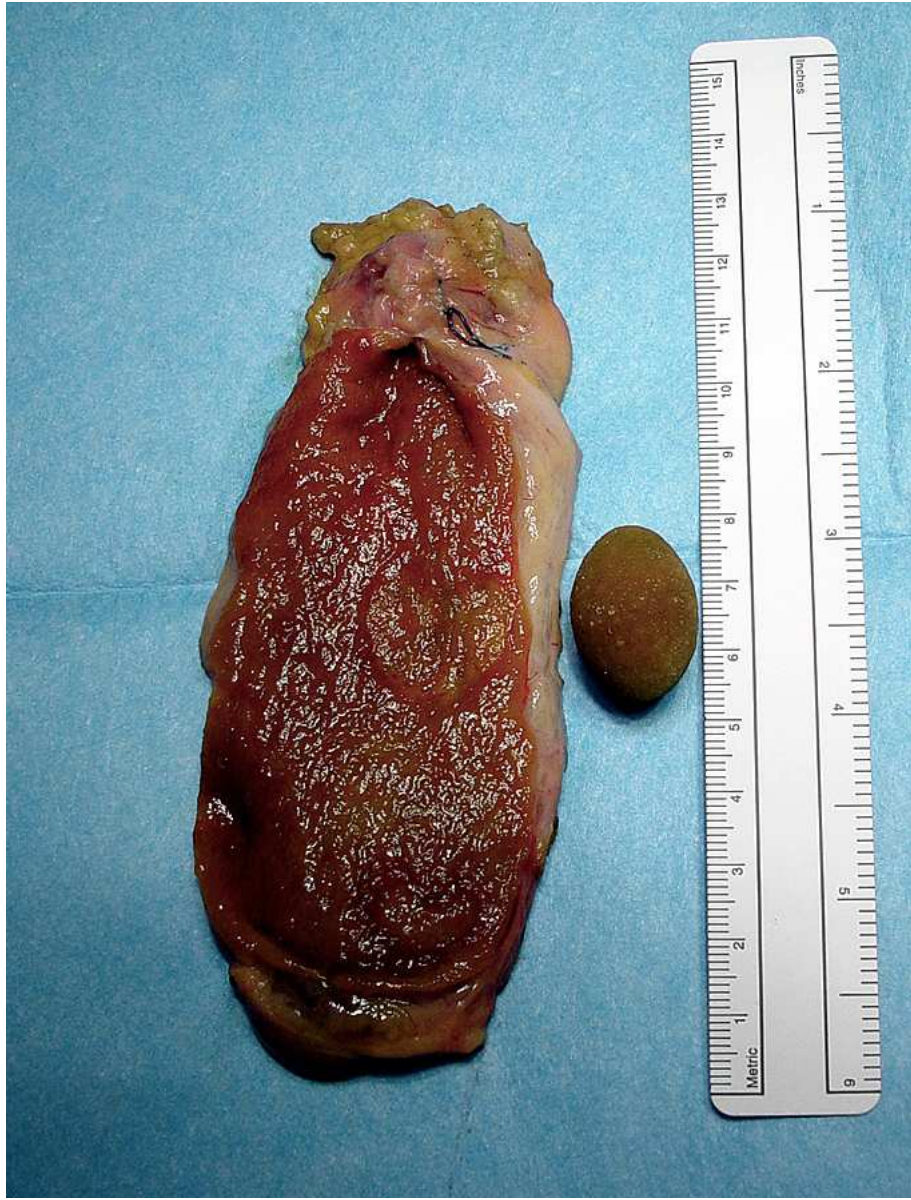
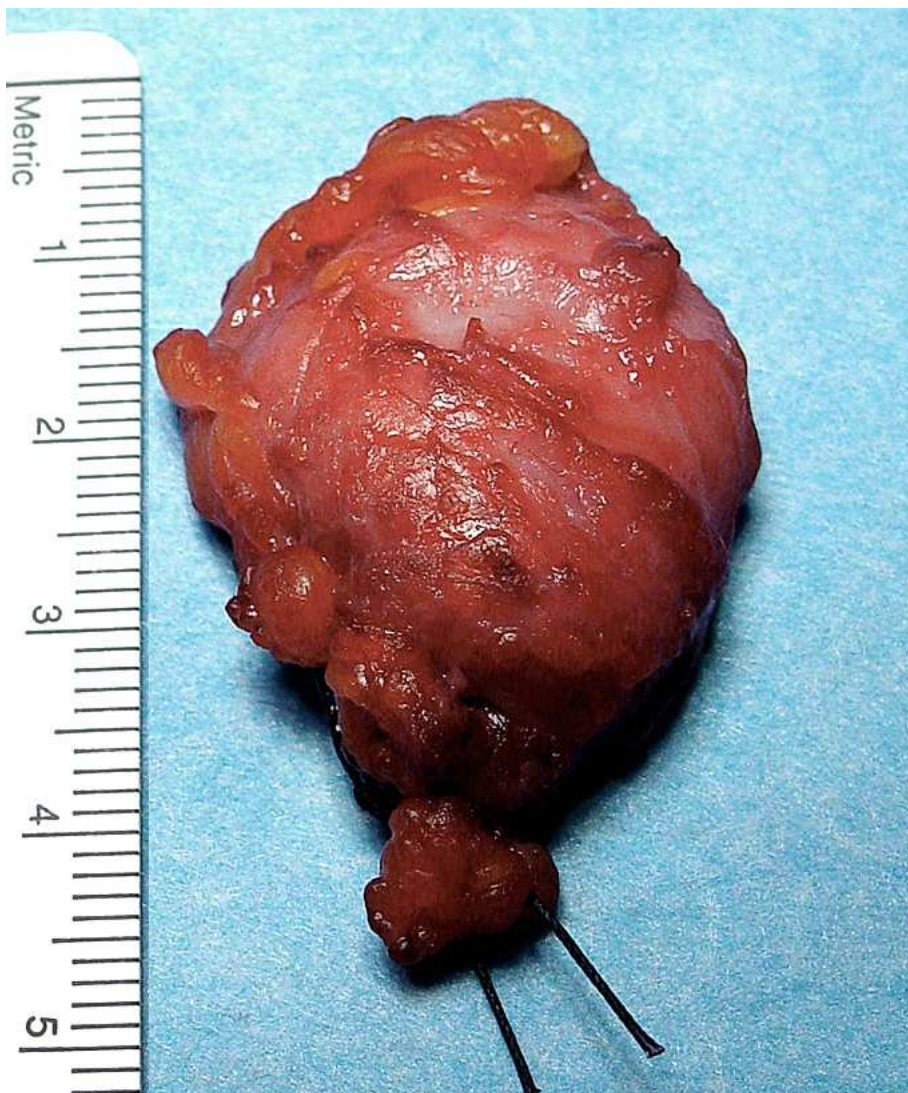


G.P. · Anni: 36 - M · Record: 50 · 26-07-2002

Colecistectomia retrograda per litiasi

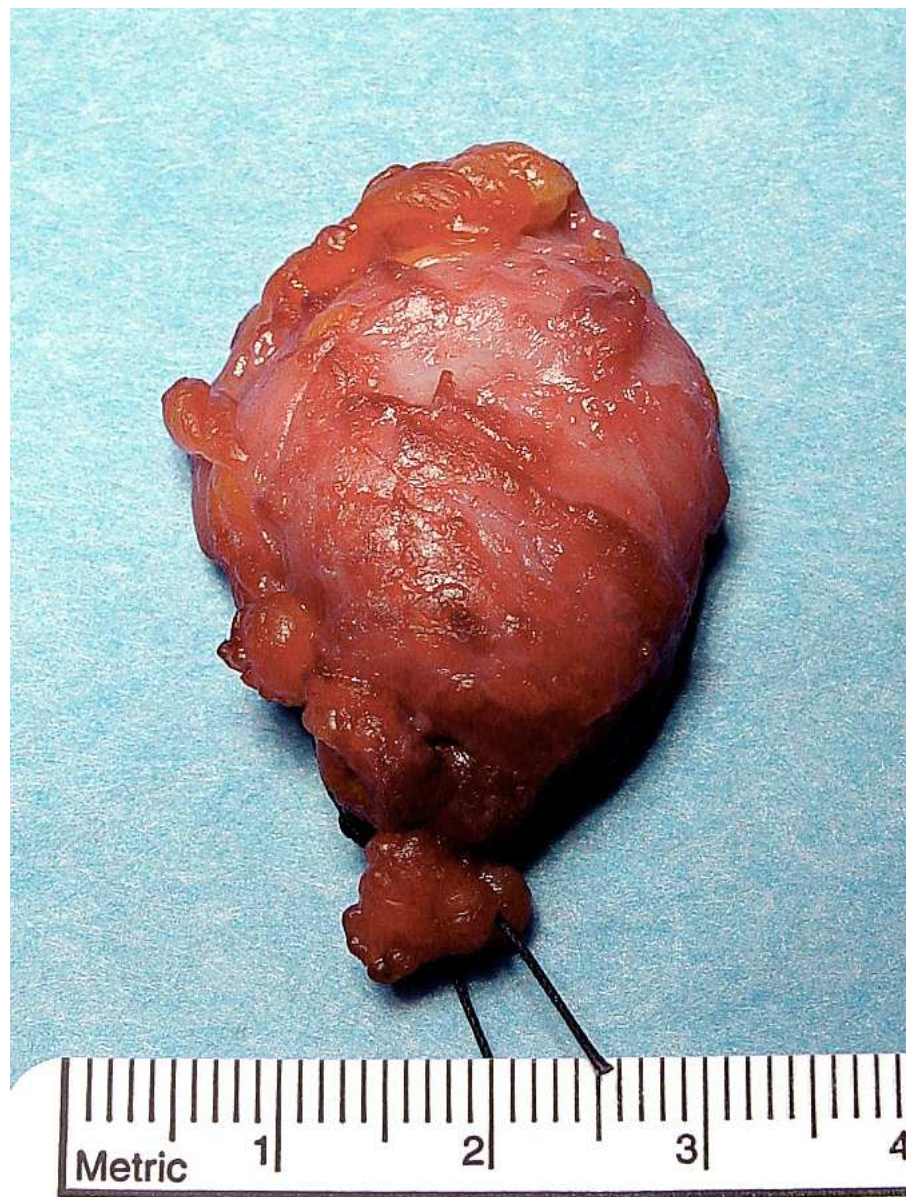


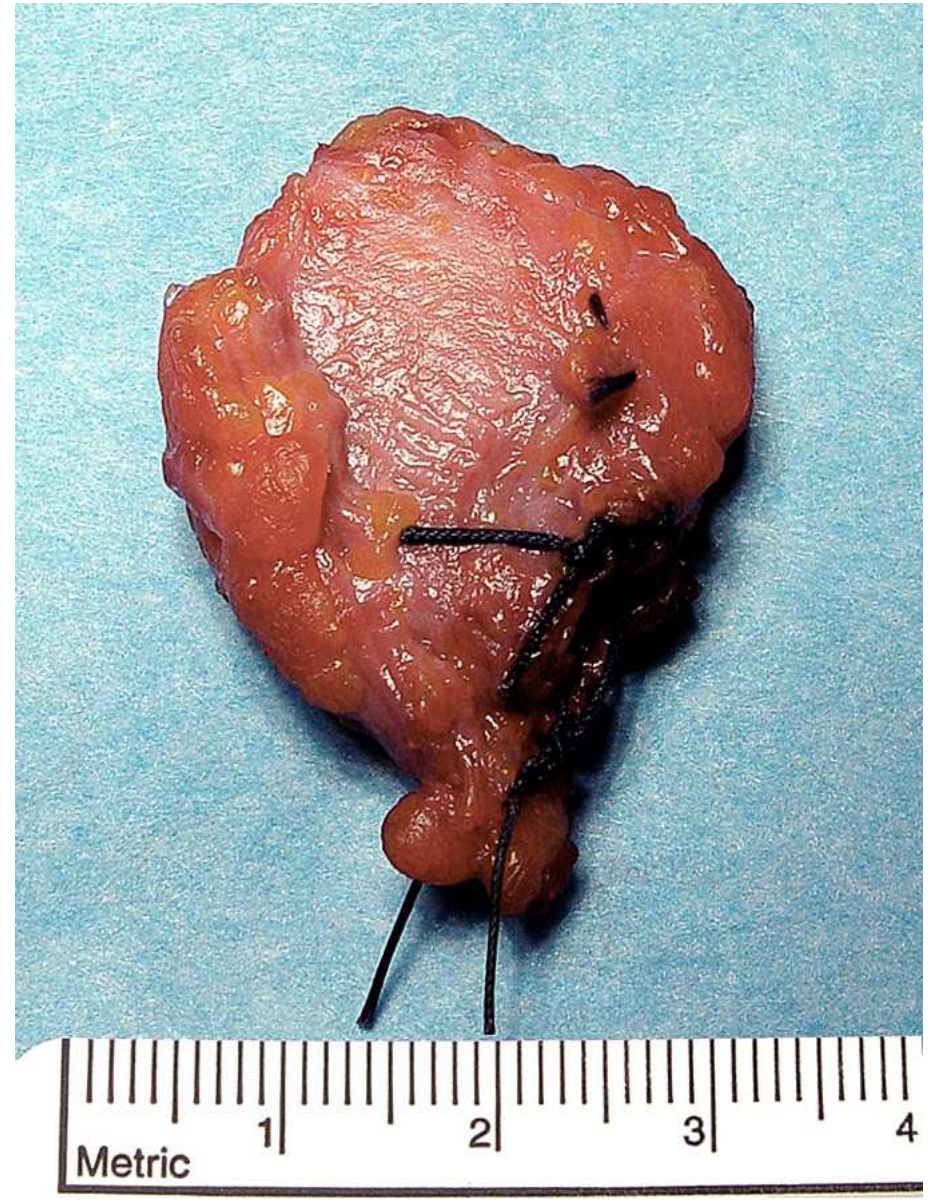
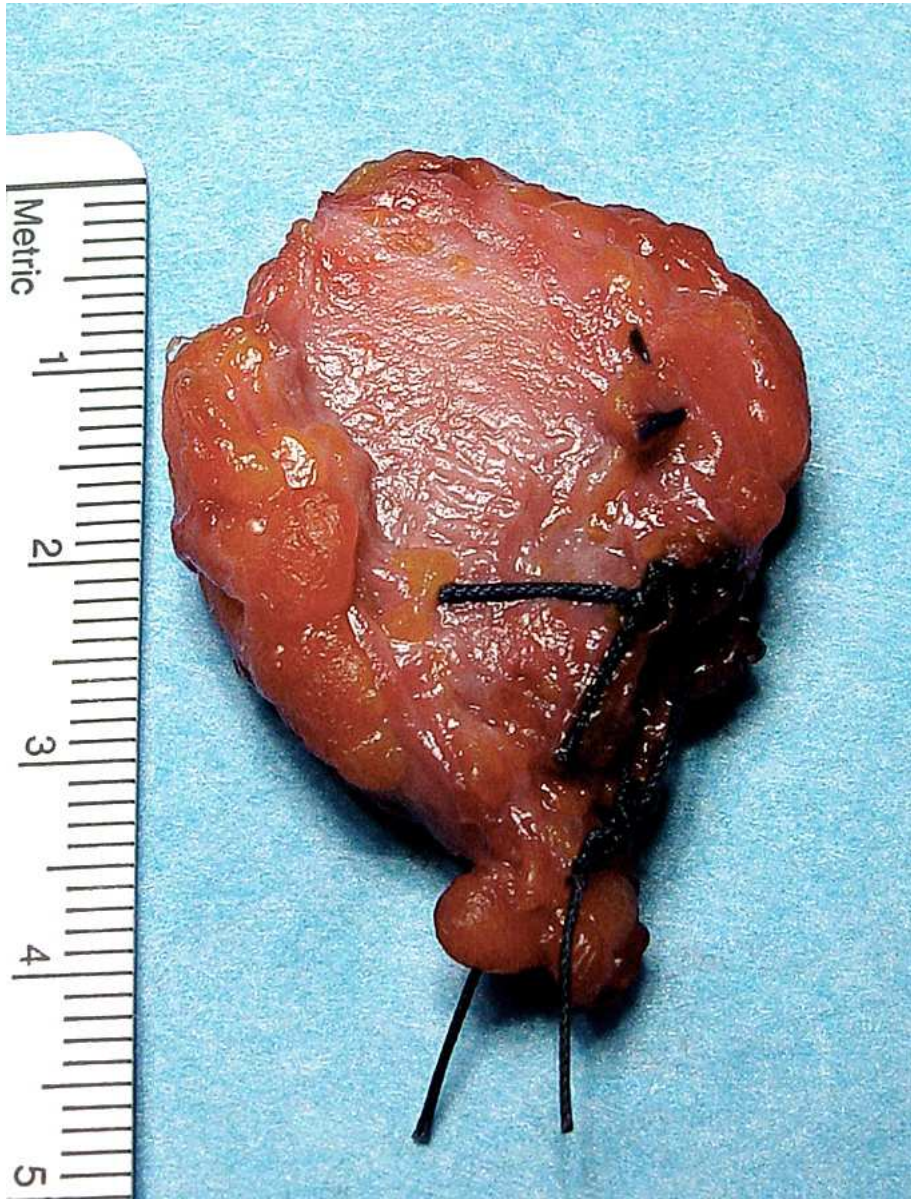


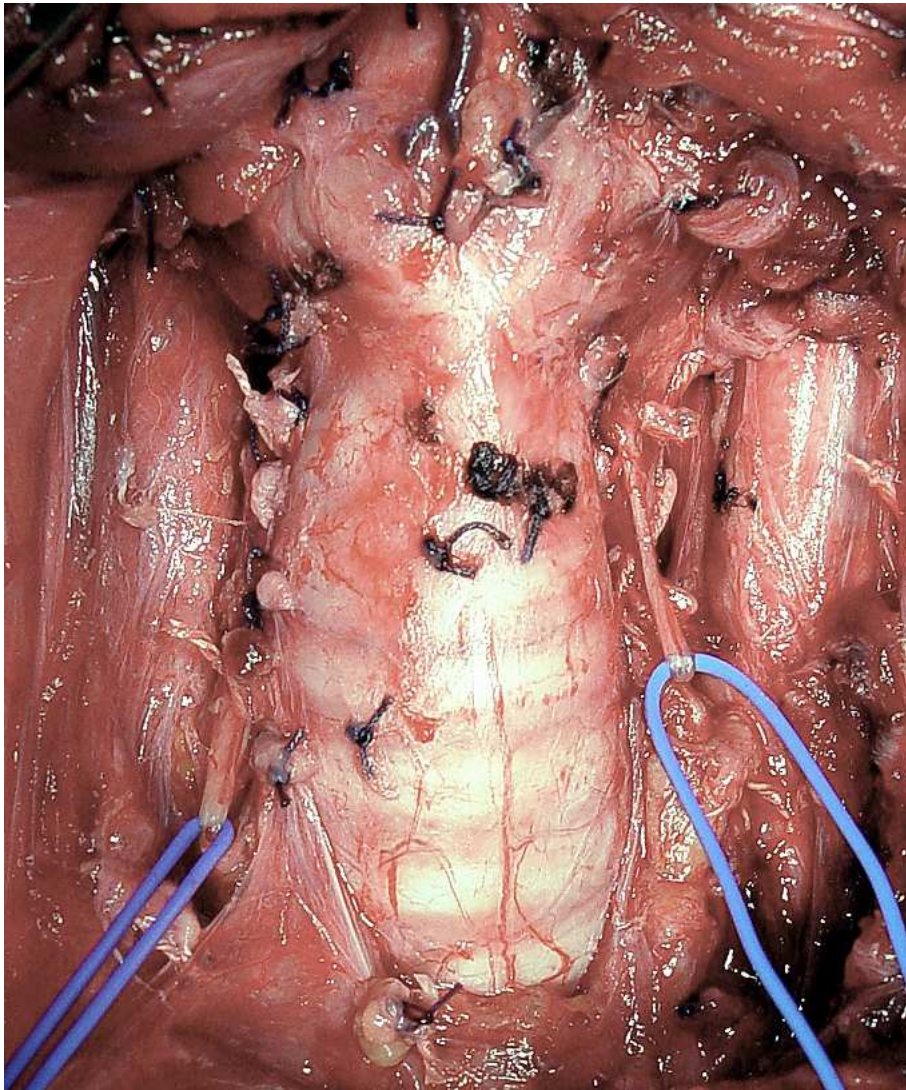


D.N. • Anni: 12 - M • Record: 51 • 25-09-2002

Mastectomia sottocutanea (adenomammectomia) a dx per ginecomastia

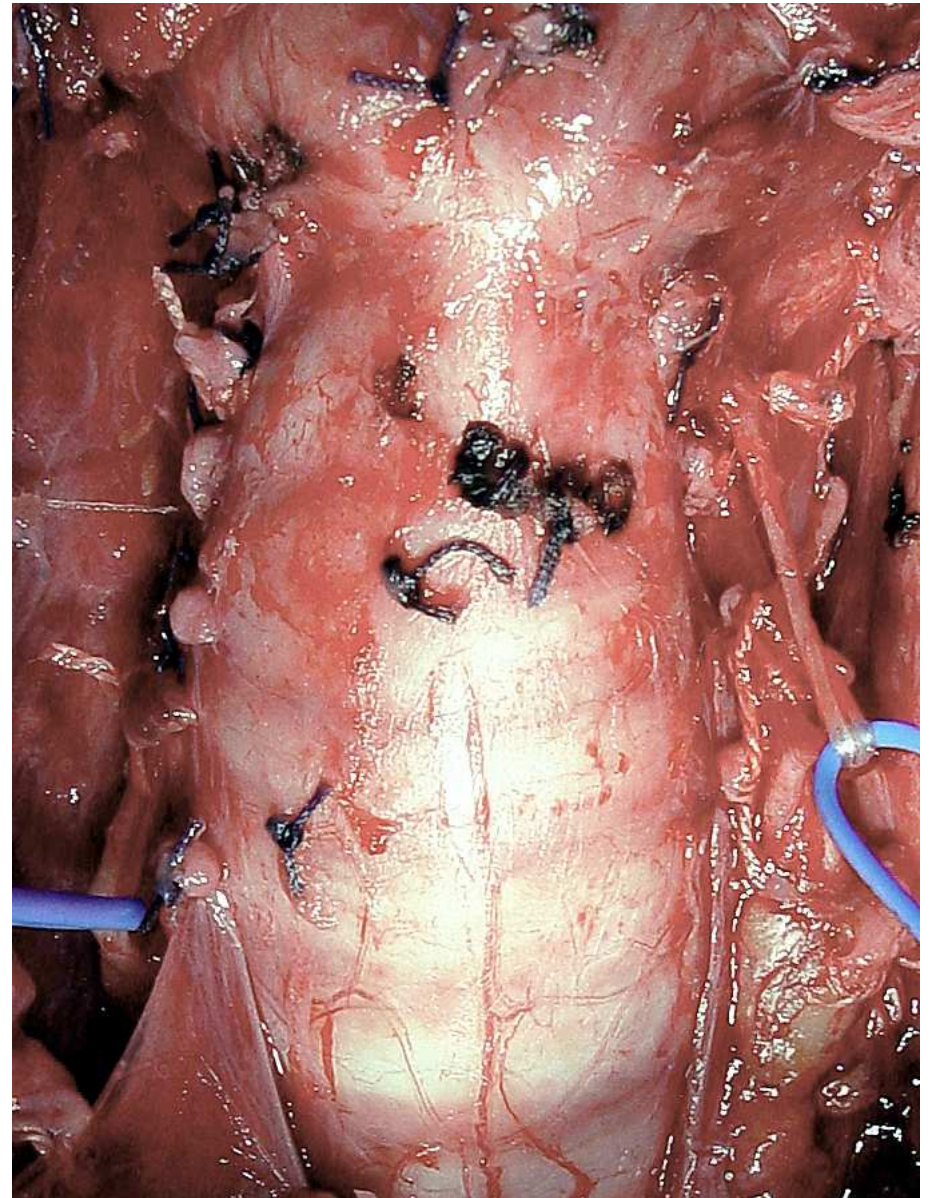




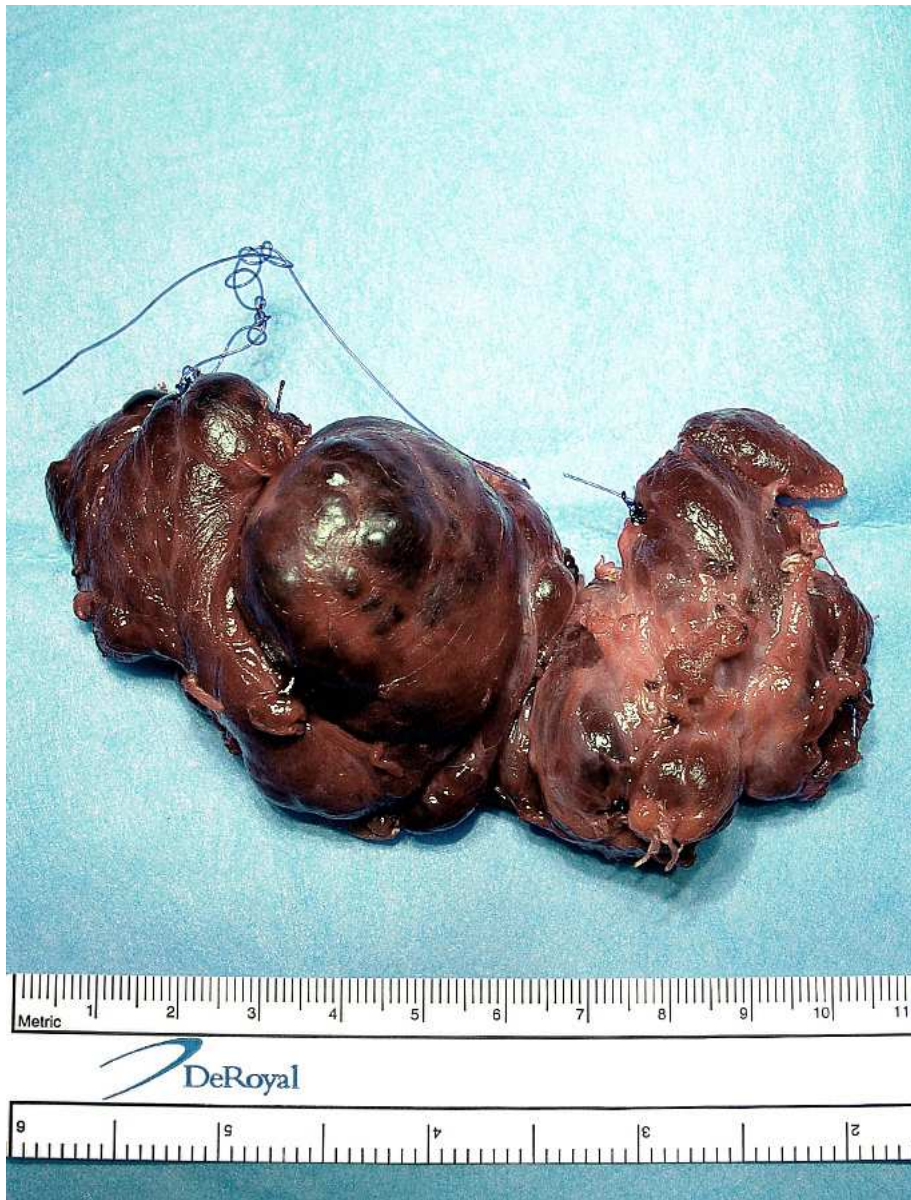

M.G. • Anni: 46 - F • Record: 52 • 25-09-2002

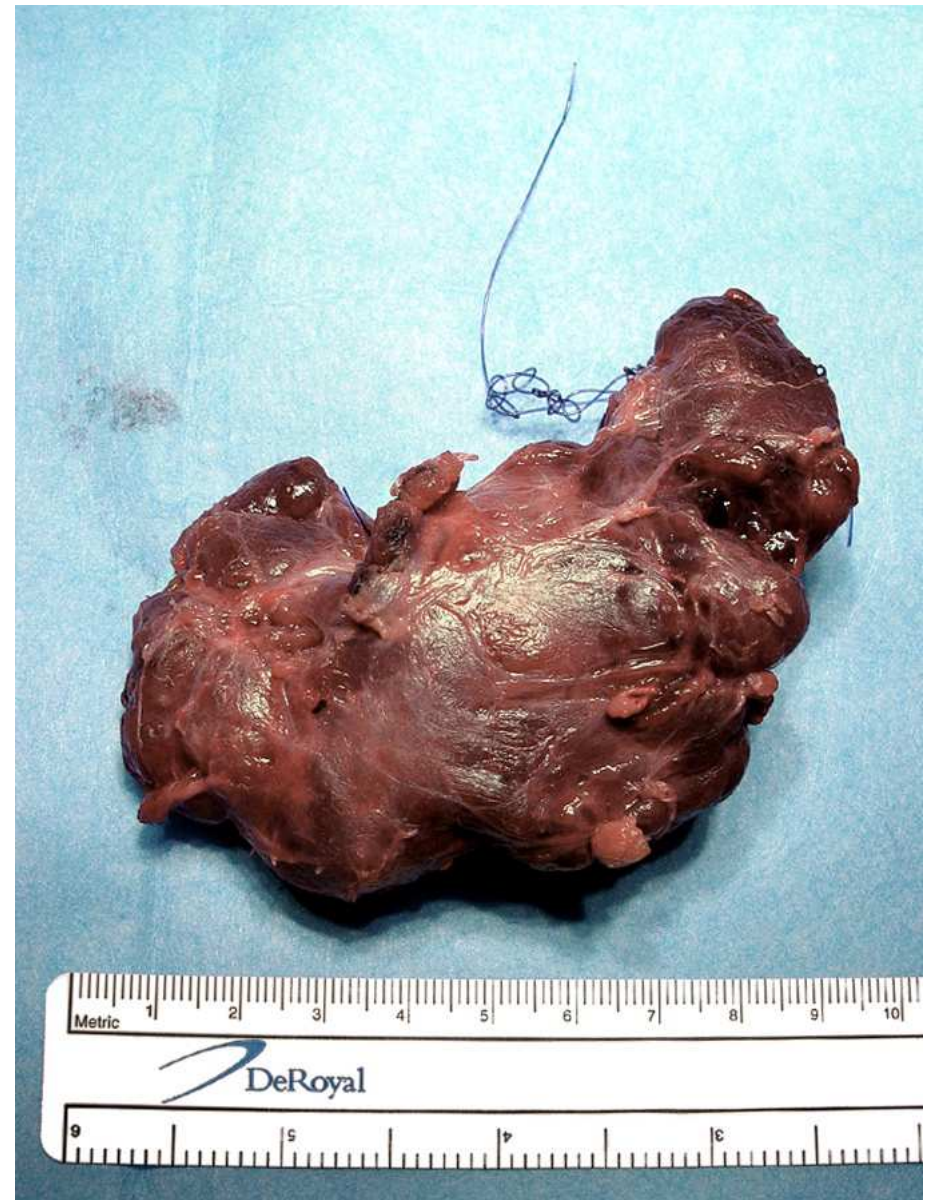Tiroidectomia totale extracapsulare per gozzo plurinodulare recidivo in lobectomizzata a sn



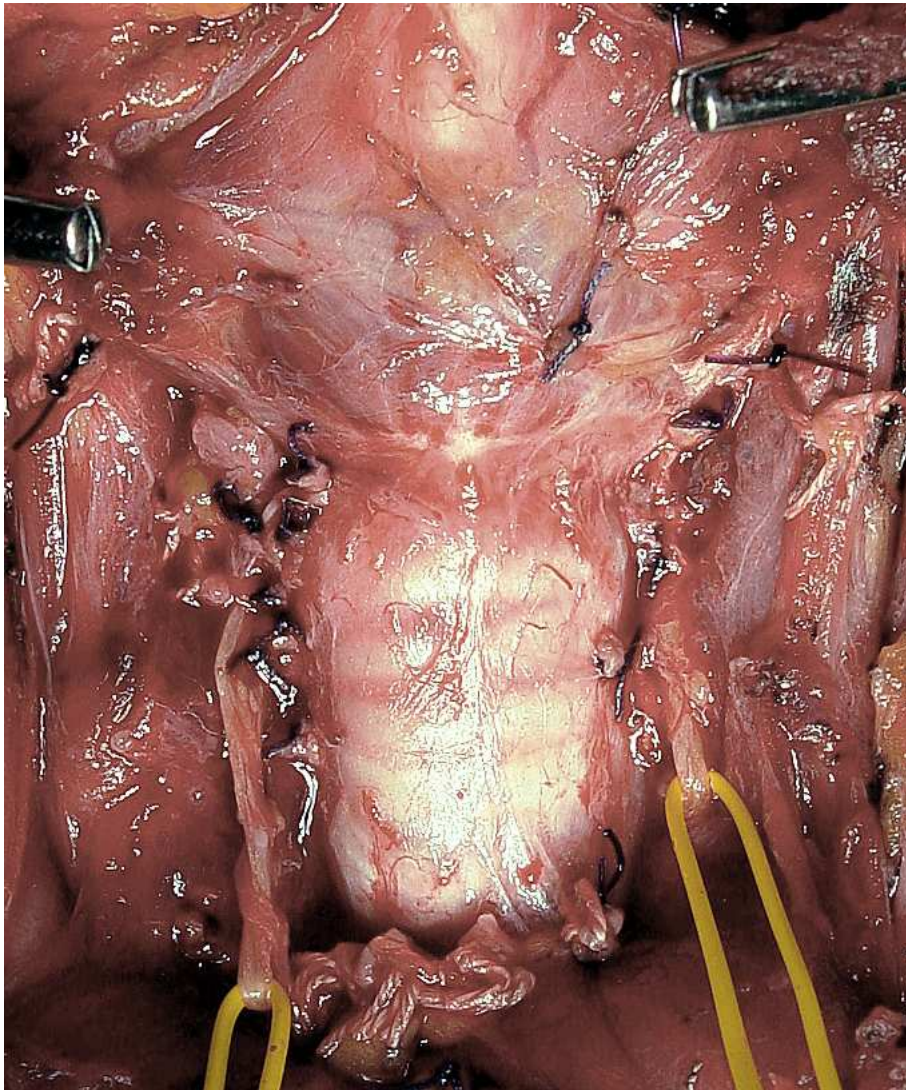
Isolamento dei nervi laringei inferiori (ricorrenti)



Lobo destro - Istmo - Residuo del lobo sinistro (superficie posteriore)

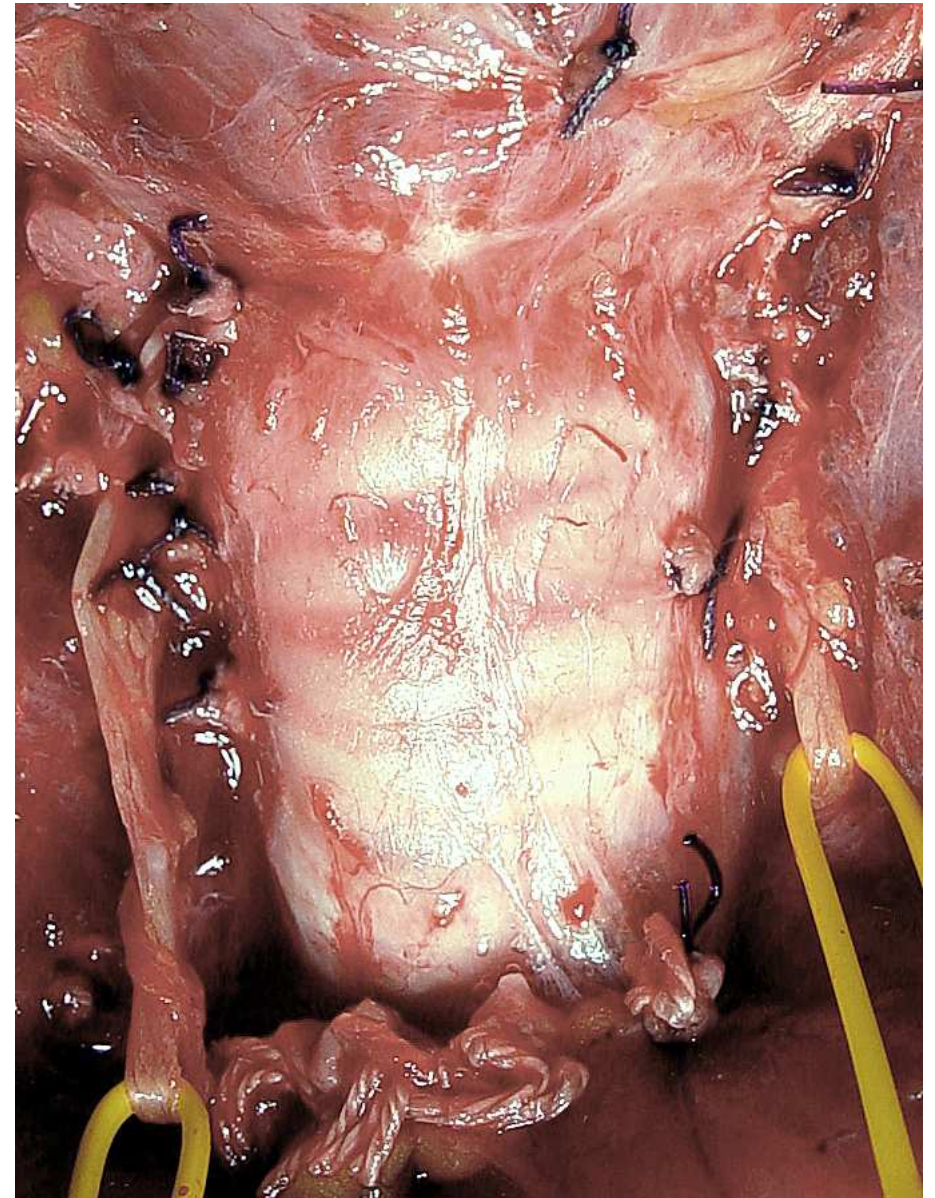


Residuo del lobo sinistro - Istmo - Lobo destro (superficie posteriore)



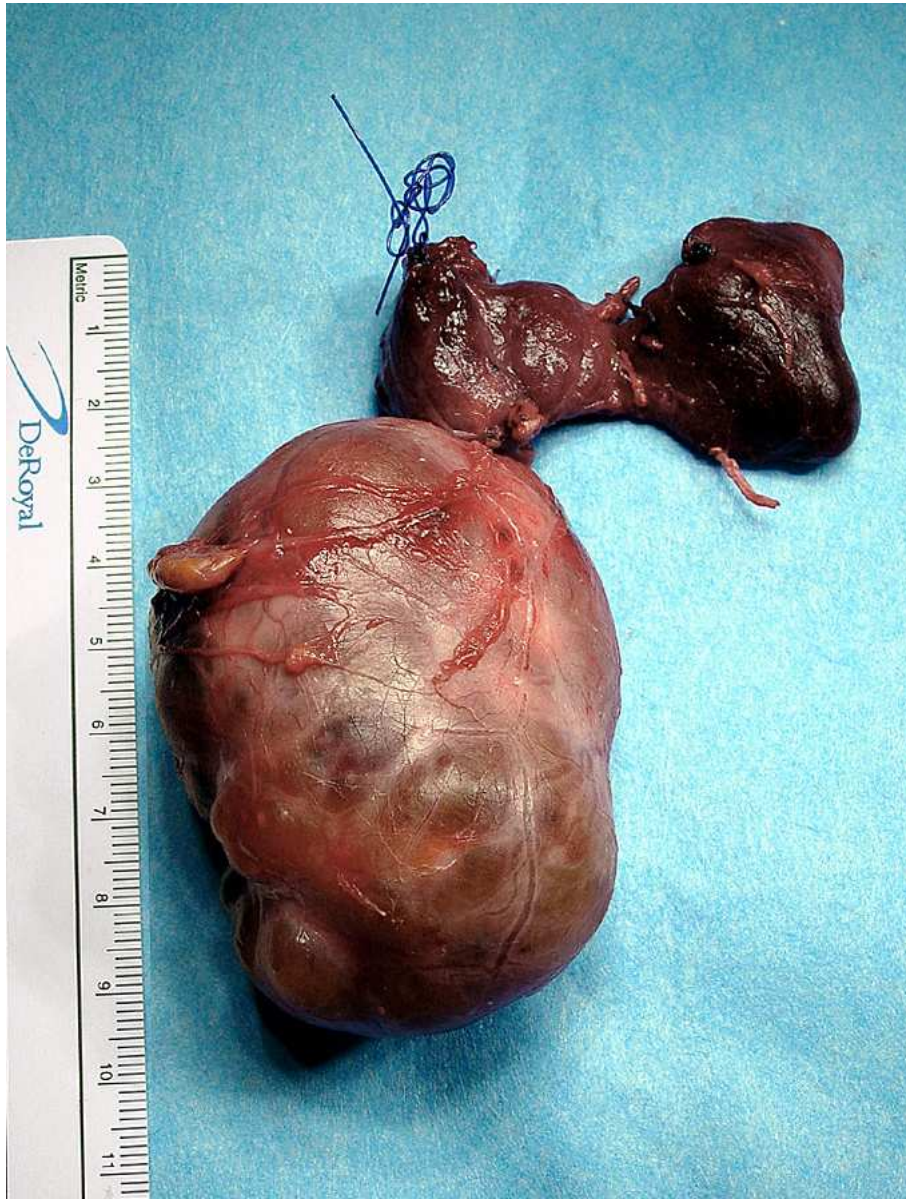S.R. • Anni: 53 - F • Record: 53 • 30-10-2002

Tiroidectomia totale extracapsulare per gozzo plurinodulare pretossico plongeant a dx

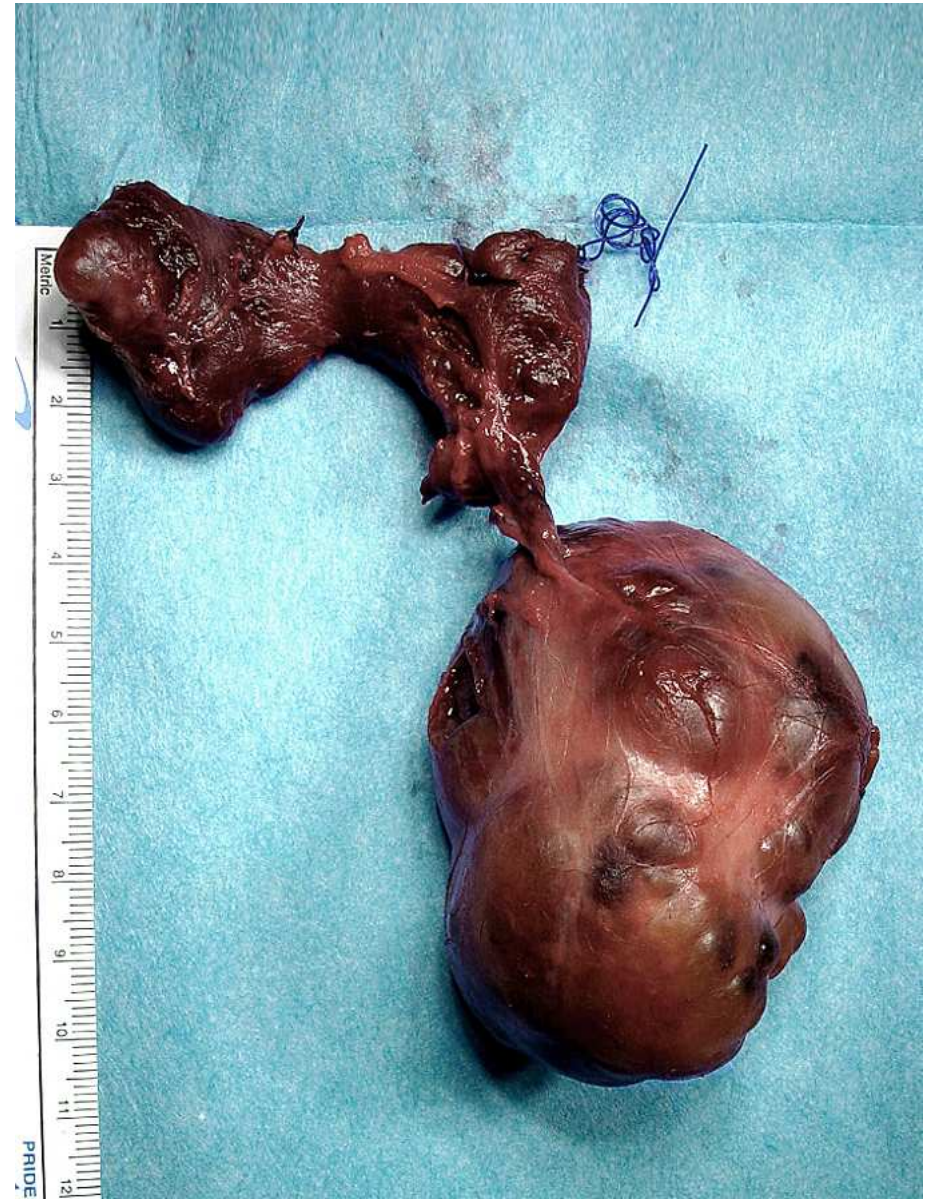

Isolamento dei nervi laringei inferiori (ricorrenti)

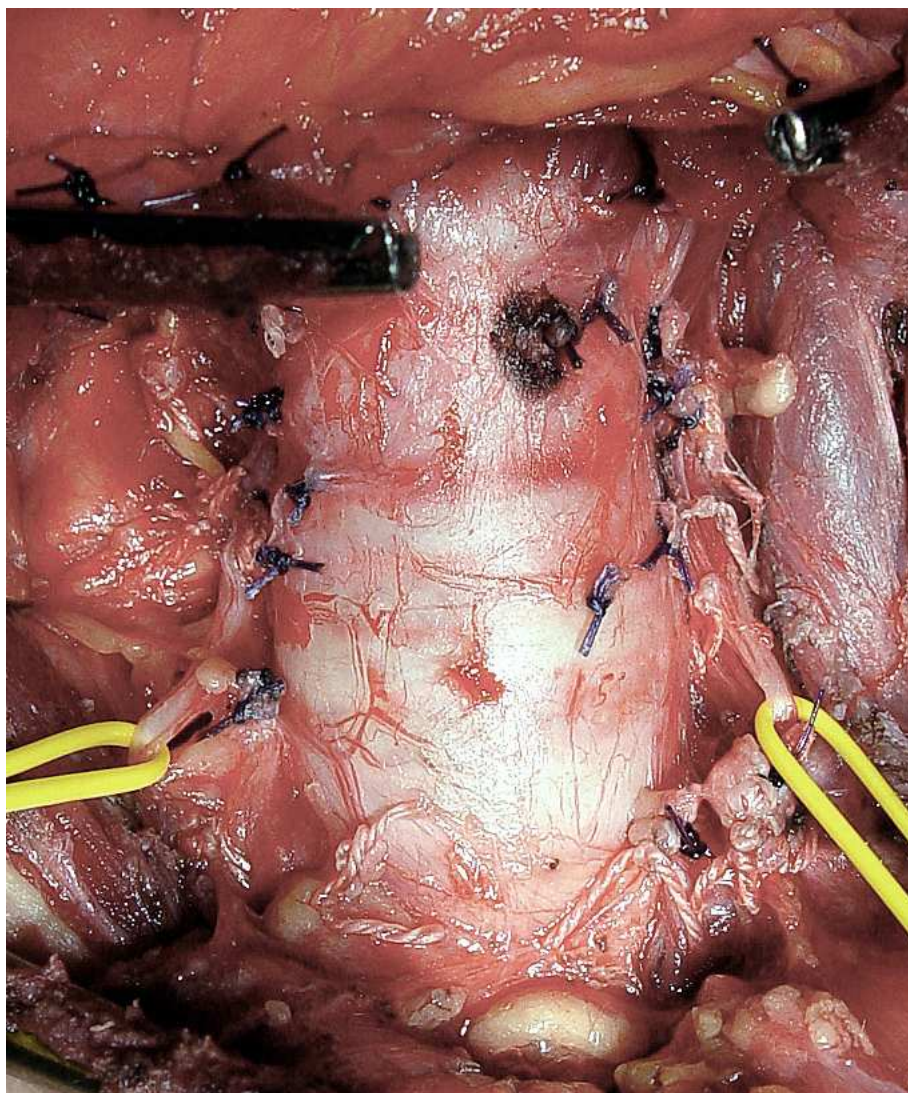




Lobo destro - Istmo - Lobo sinistro (superficie anteriore)

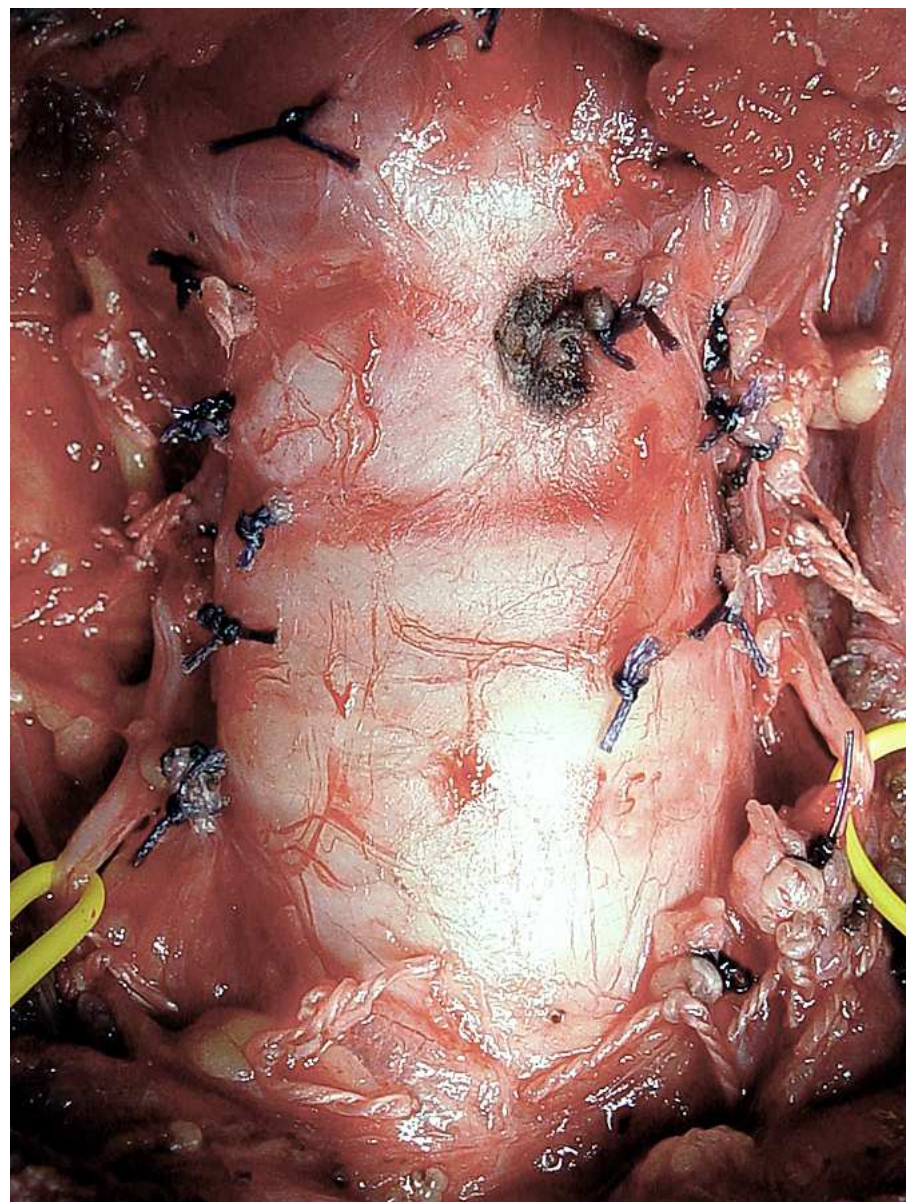


Lobo sinistro - Istmo - Lobo destro (superficie posteriore)

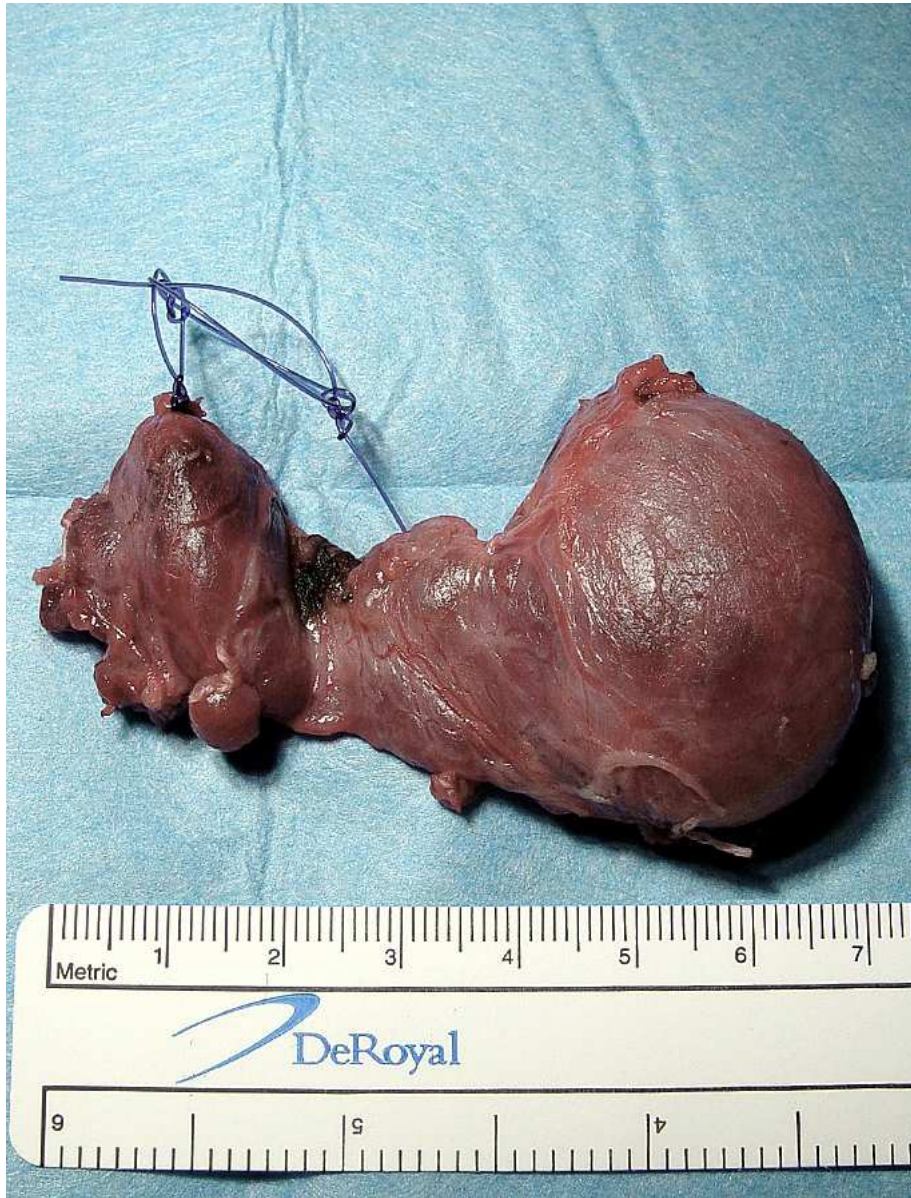

P.C. • Anni: 42 - F • Record: 54 • 06-11-2002

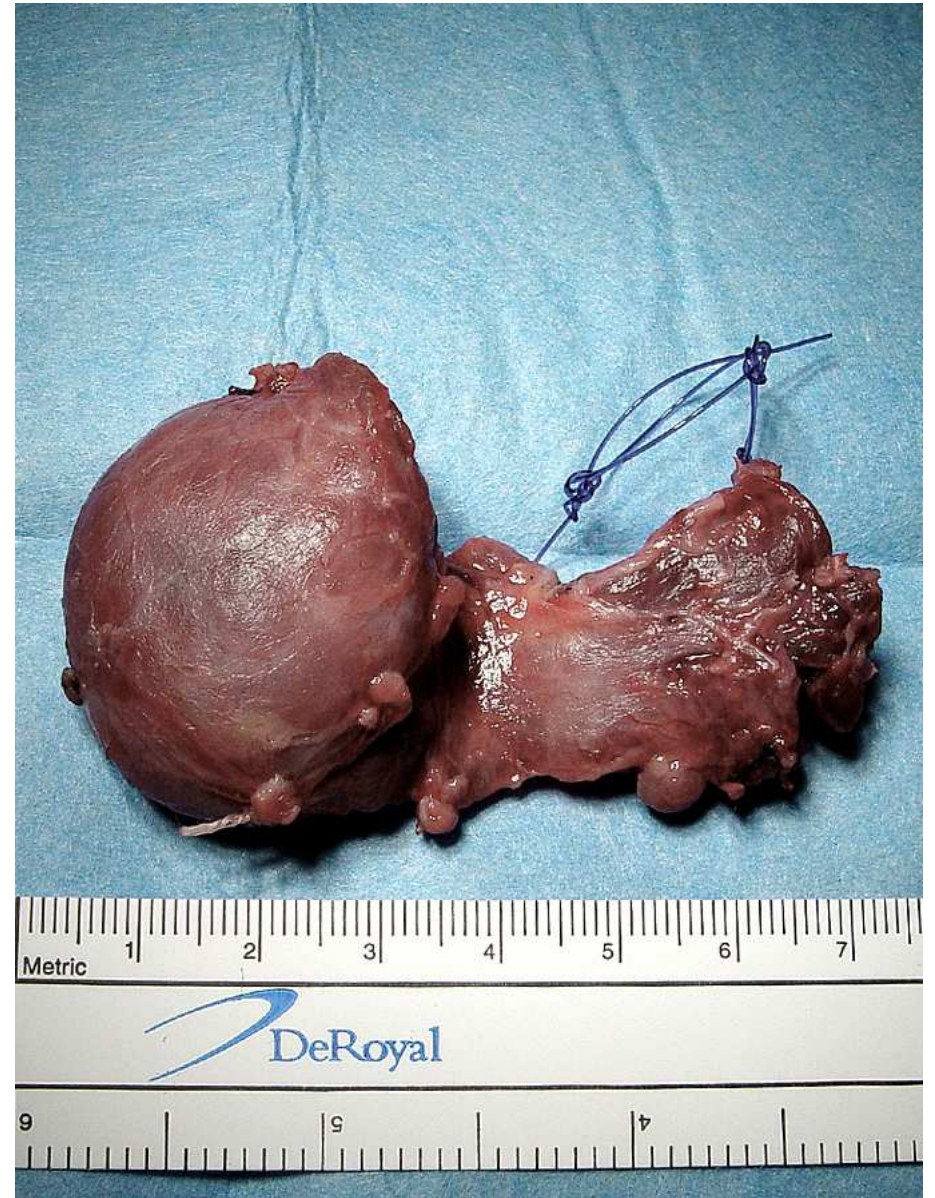
Tiroidectomia totale extracapsulare per gozzo plurinodulare pretossico plongeant a sn



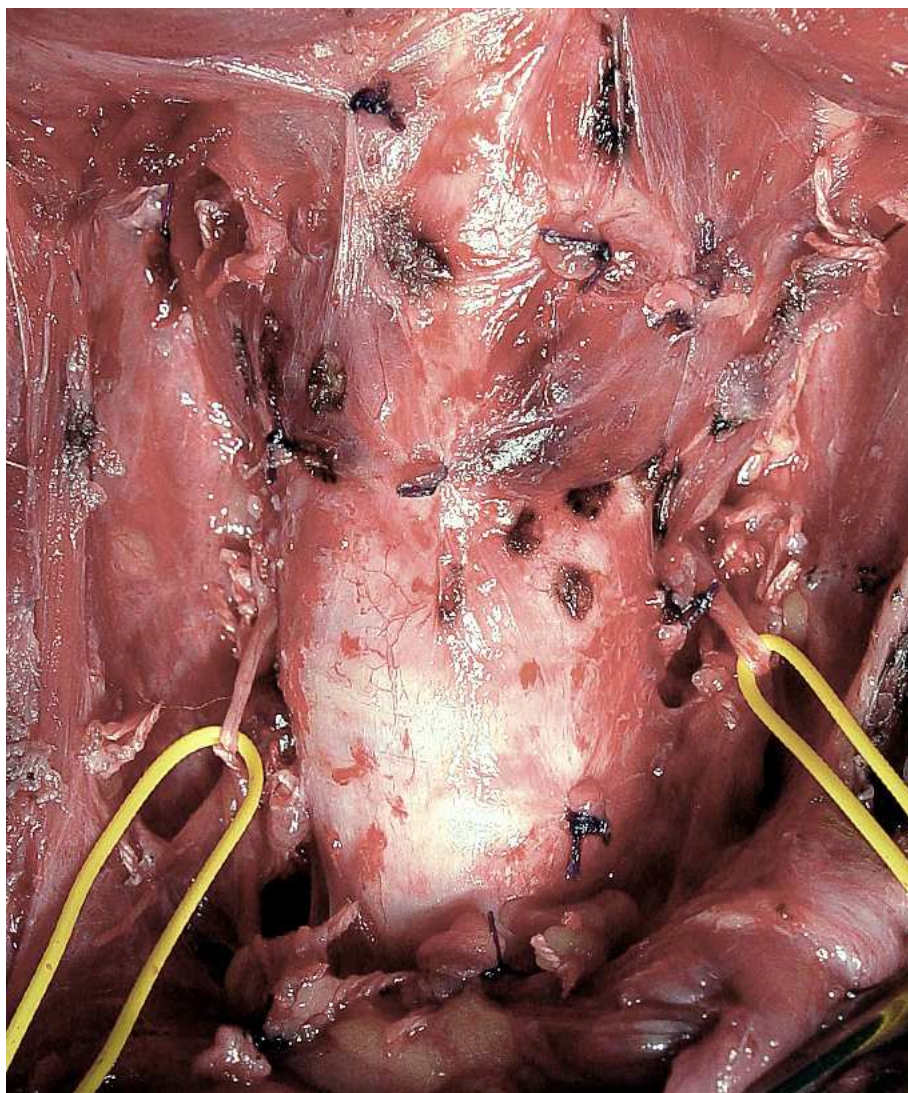
Isolamento dei nervi laringei inferiori (ricorrenti)



Lobo destro - Istmo - Lobo sinistro (superficie anteriore)

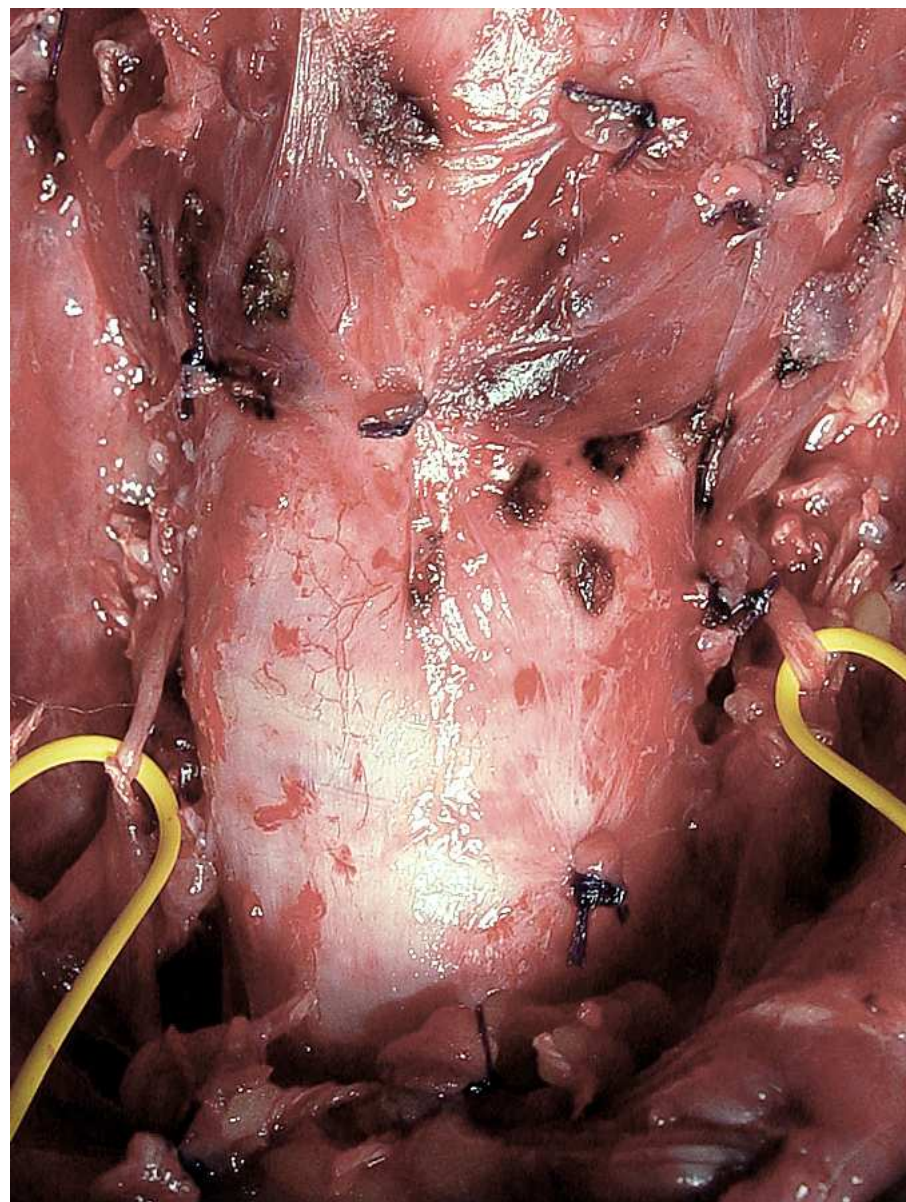


Lobo sinistro - Istmo - Lobo destro (superficie posteriore)

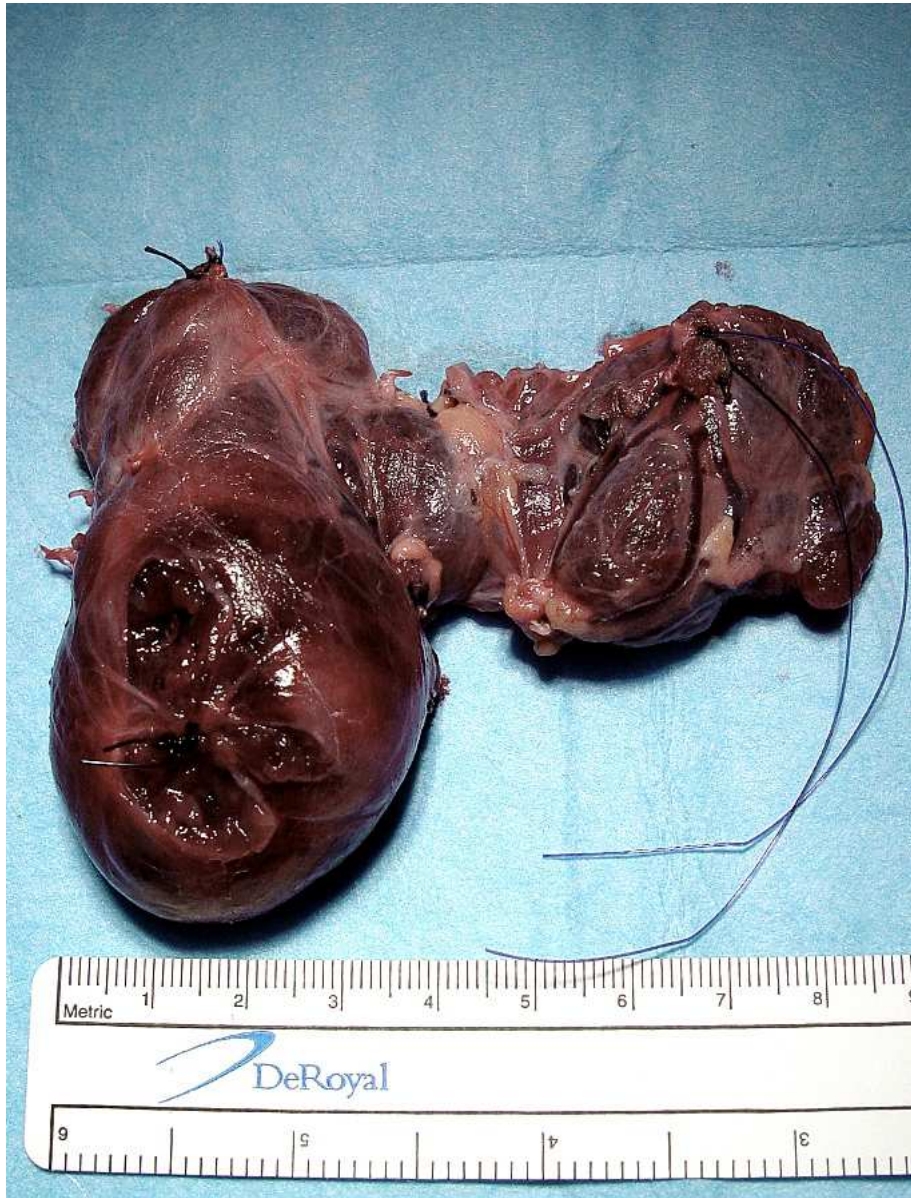


L.P. · Anni: 36 - M · Record: 55 · 15-11-2002

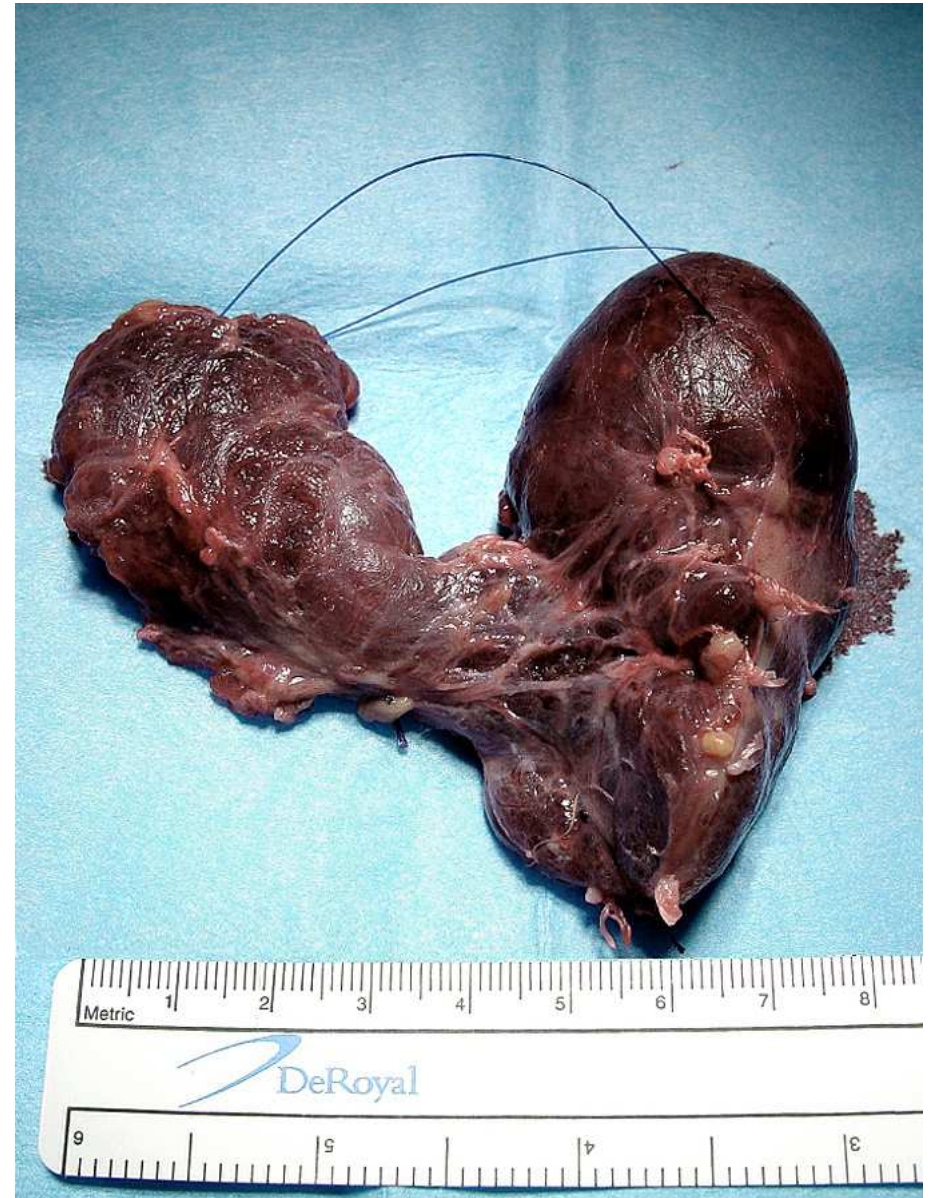Tiroidectomia totale extracapsulare per gozzo plurinodulare plongeant a dx



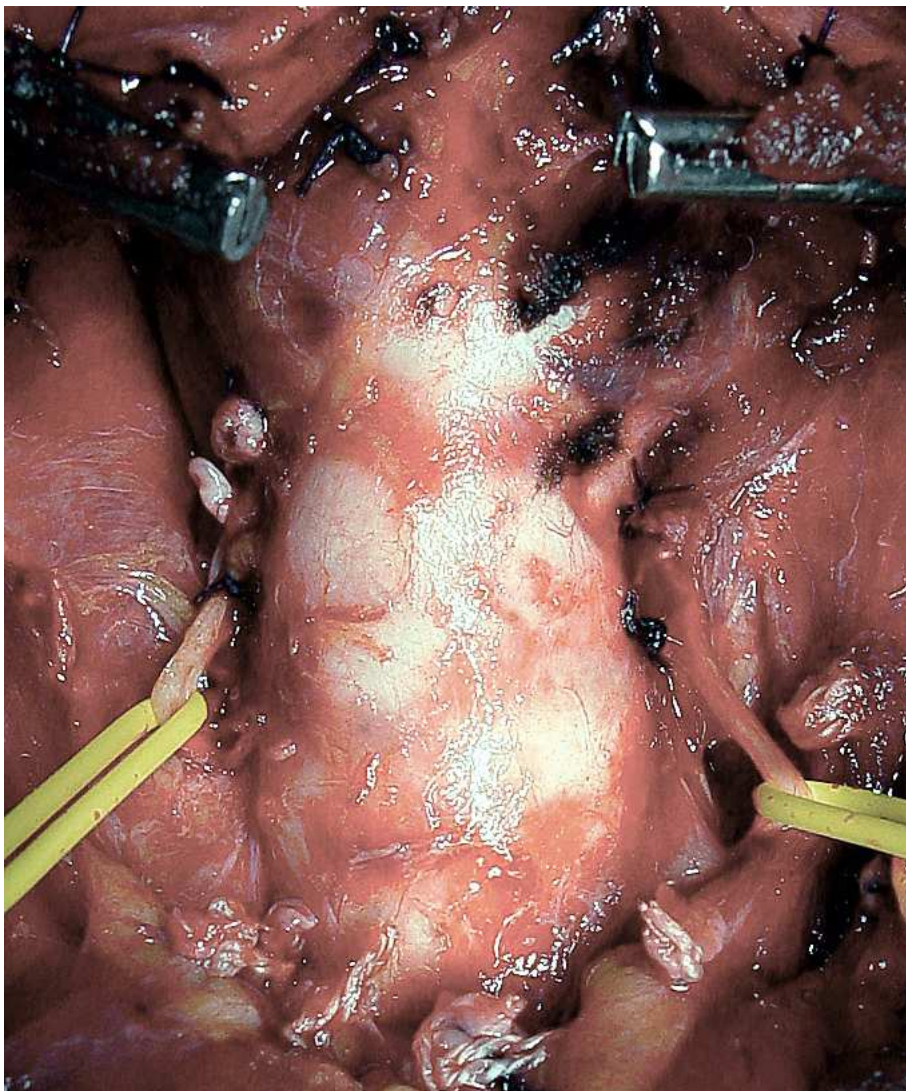
Isolamento dei nervi laringei inferiori (ricorrenti)



Lobo destro - Istmo - Lobo sinistro (superficie anteriore)

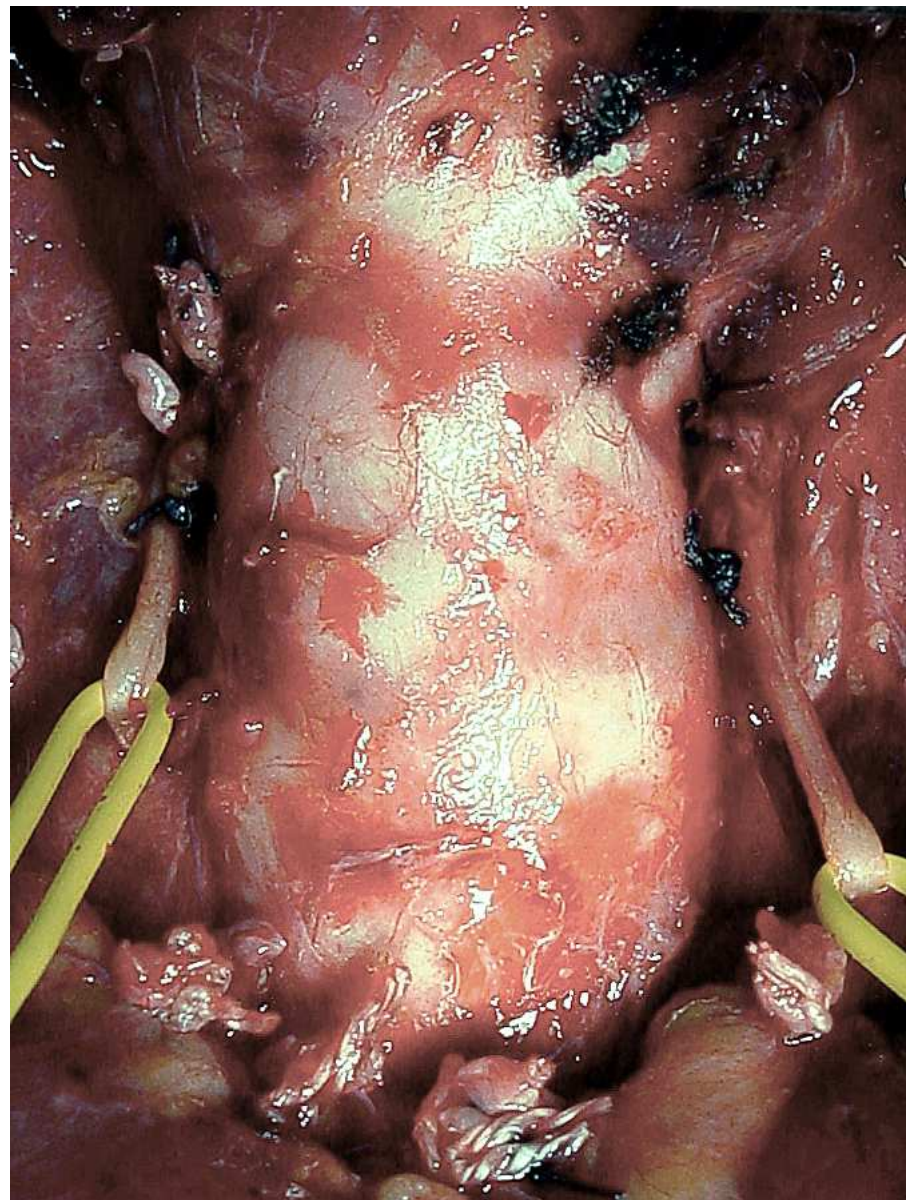


Lobo sinistro - Istmo - Lobo destro (superficie posteriore)

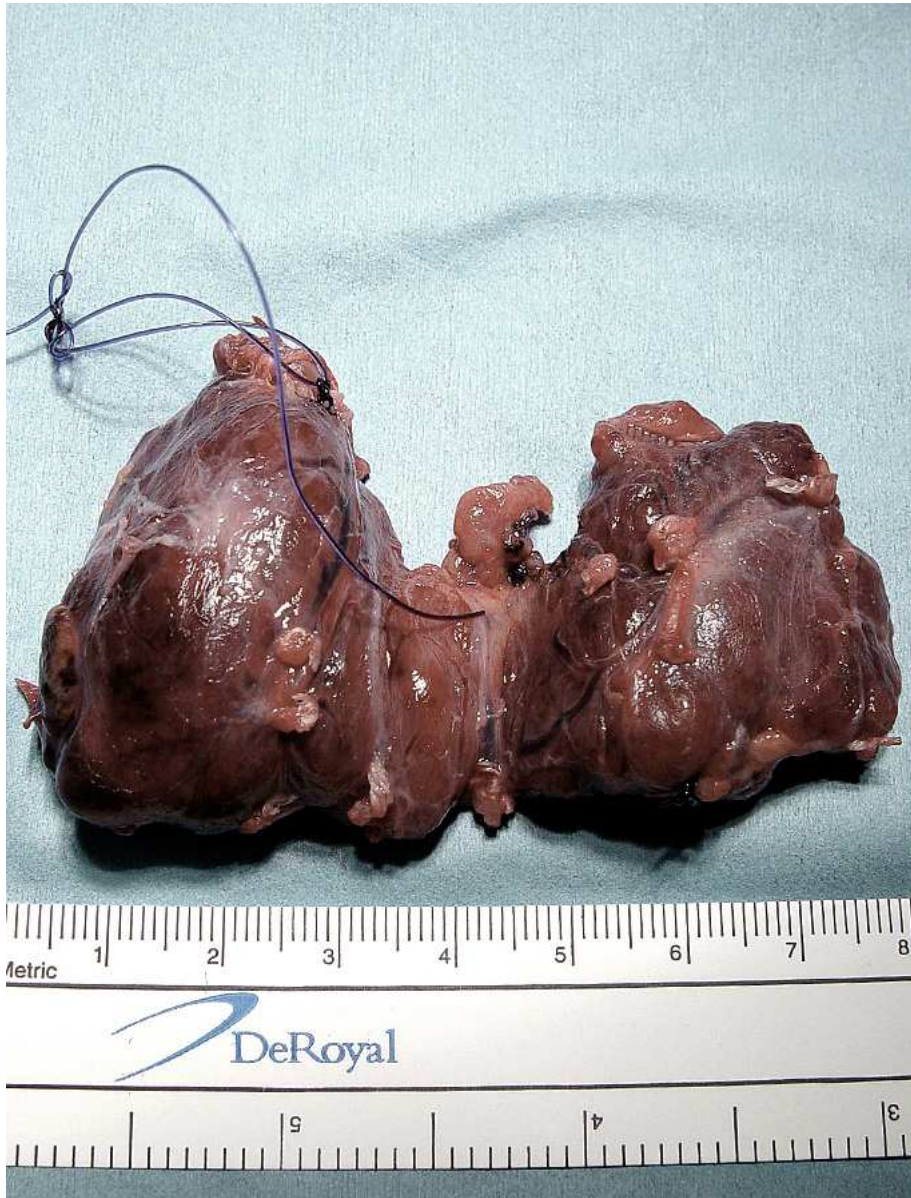


D.G. • Anni: 60 - F • Record: 56 • 13-12-2002

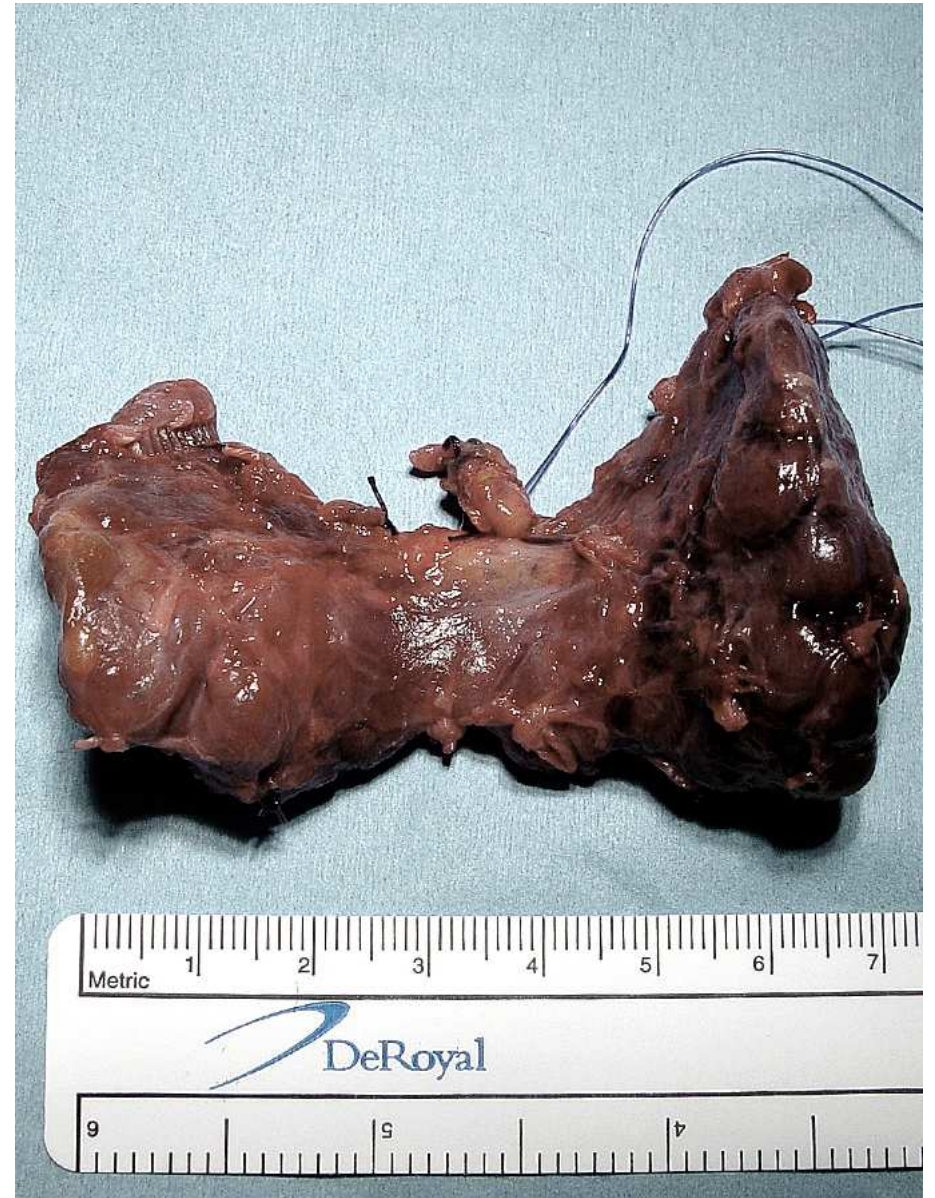Tiroidectomia totale extracapsulare per gozzo plurinodulare tossico



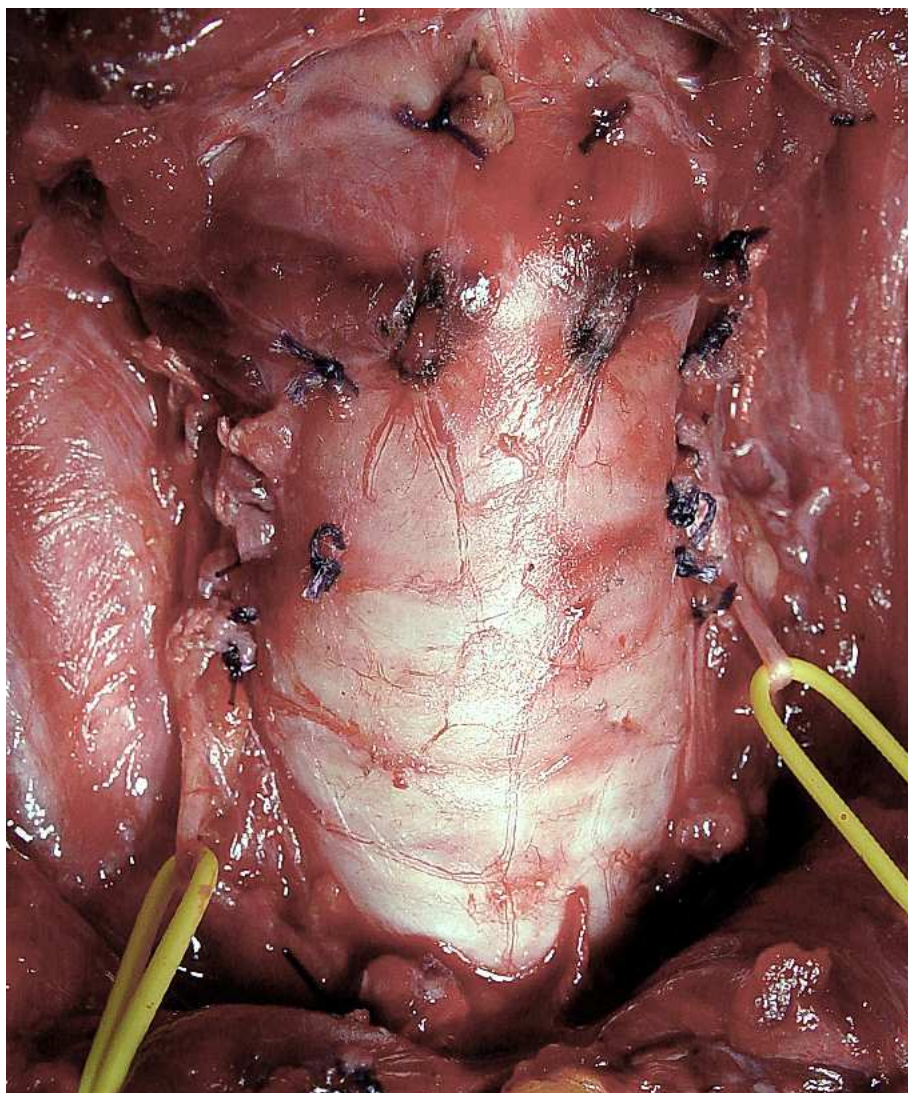
Isolamento dei nervi laringei inferiori (ricorrenti)



Lobo destro - Istmo - Lobo sinistro (superficie anteriore)

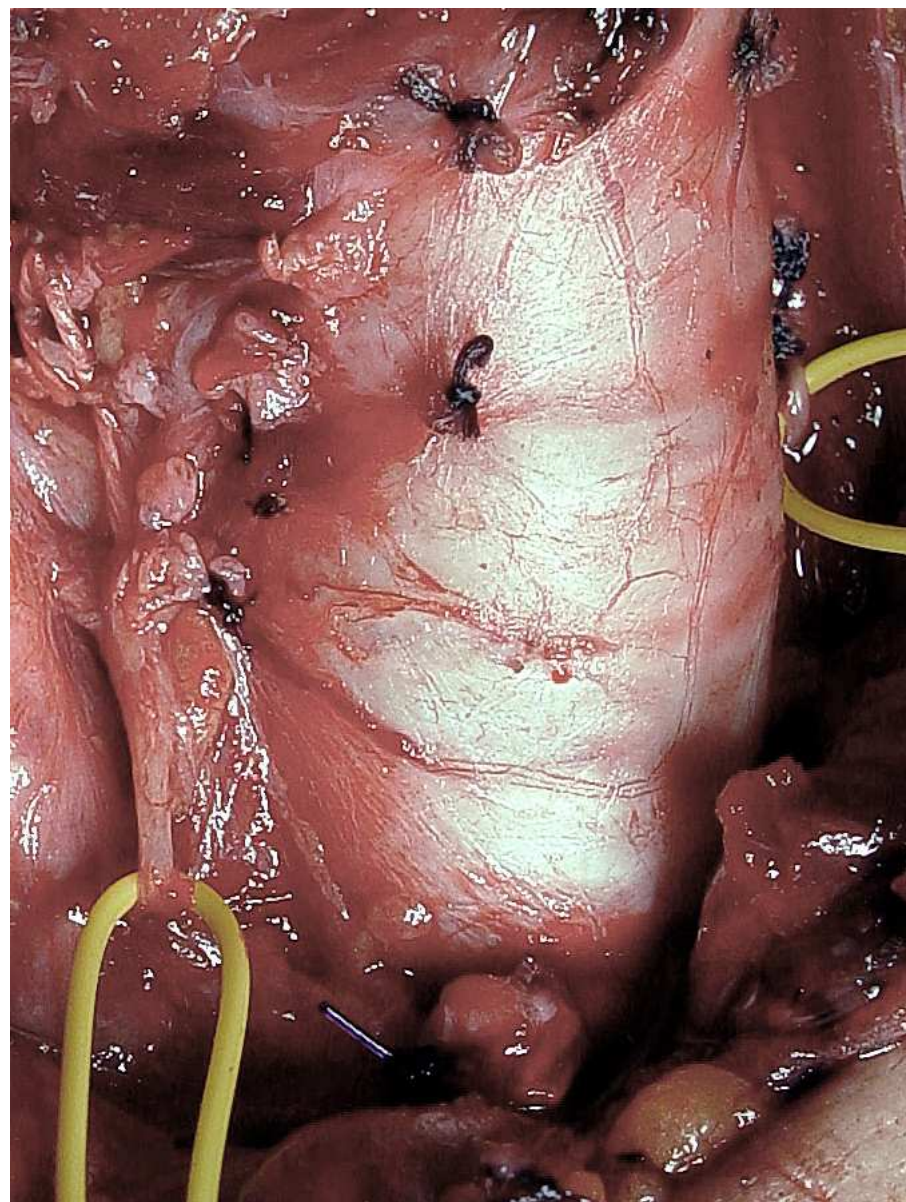


Lobo sinistro - Istmo - Lobo destro (superficie posteriore)



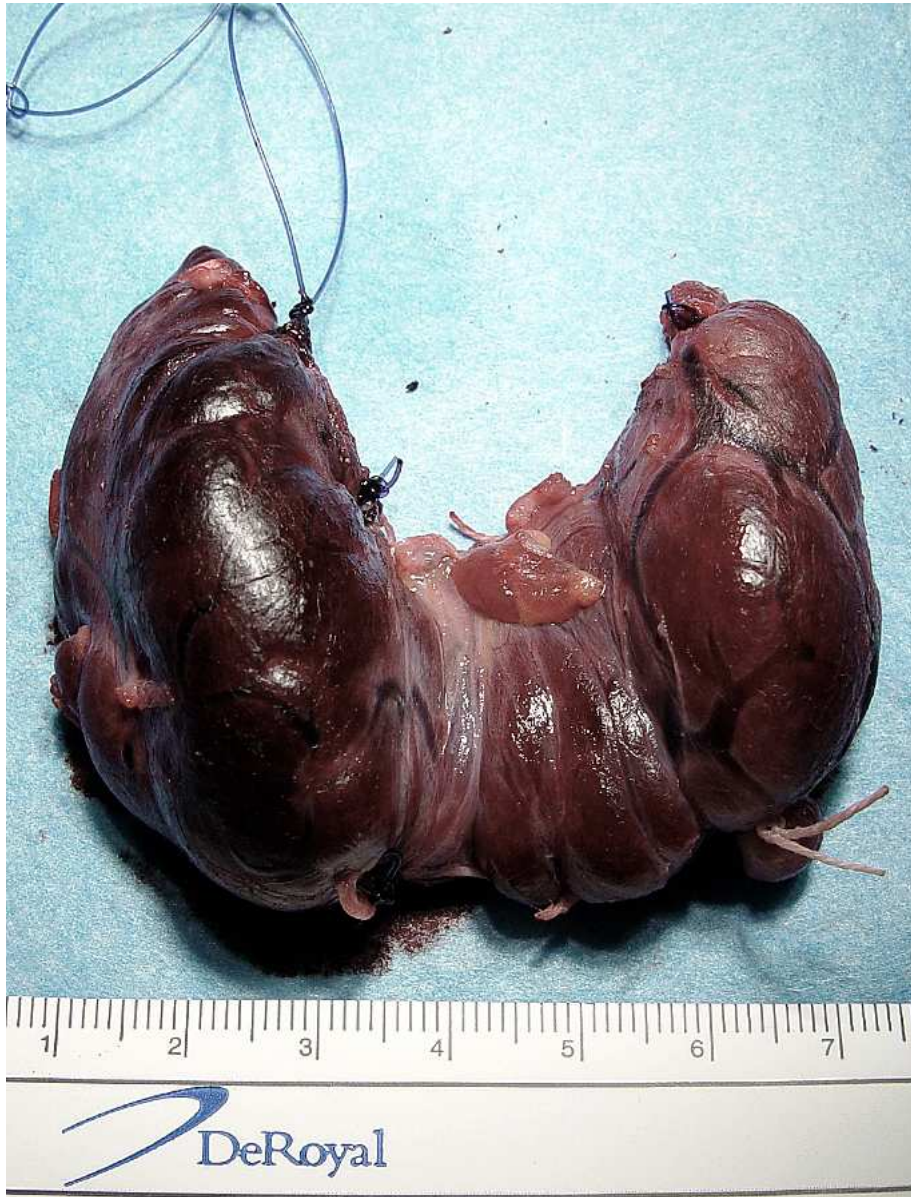E.M. • Anni: 38 - F • Record: 57 • 19-03-2003

Tiroidectomia totale extracapsulare per gozzo plurinodulare

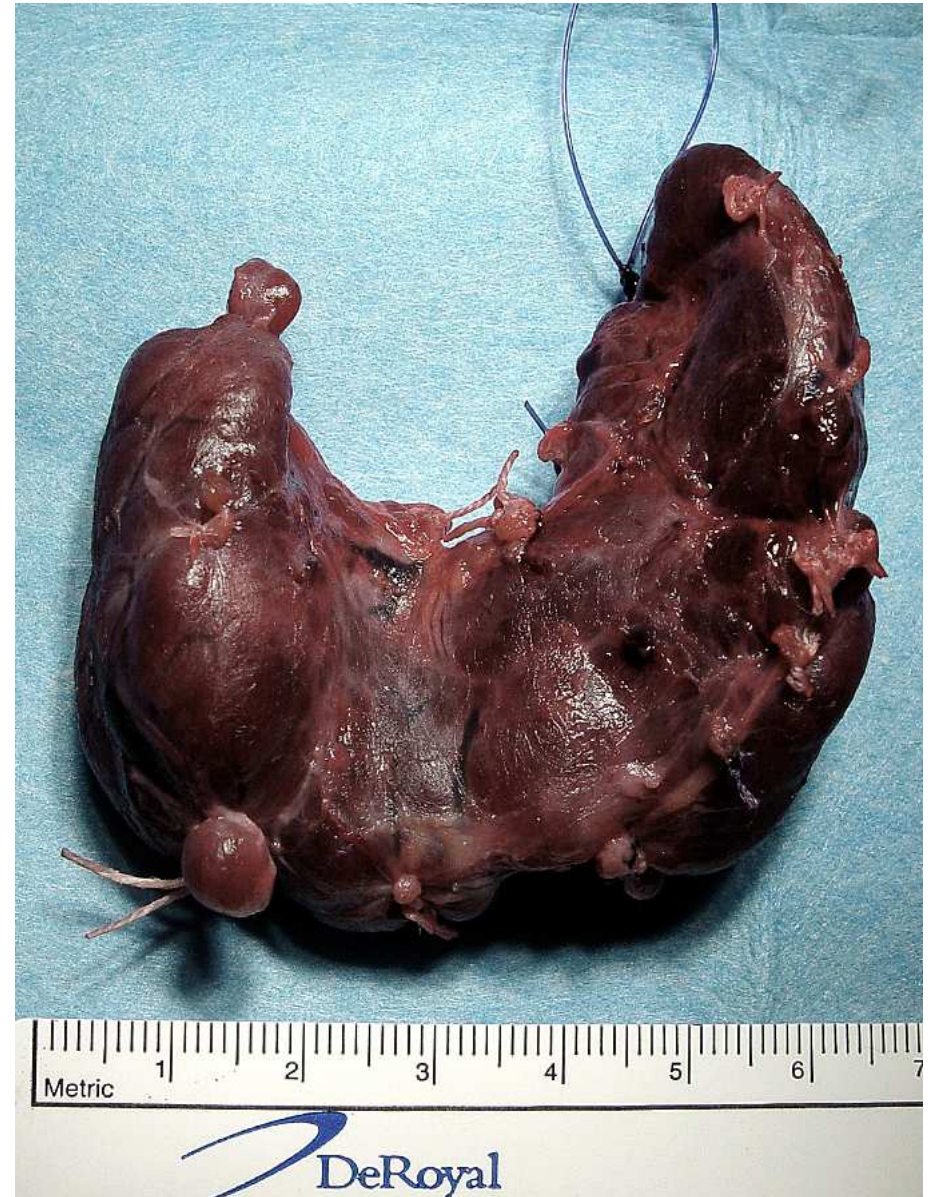

Isolamento dei nervi laringei inferiori (ricorrenti)

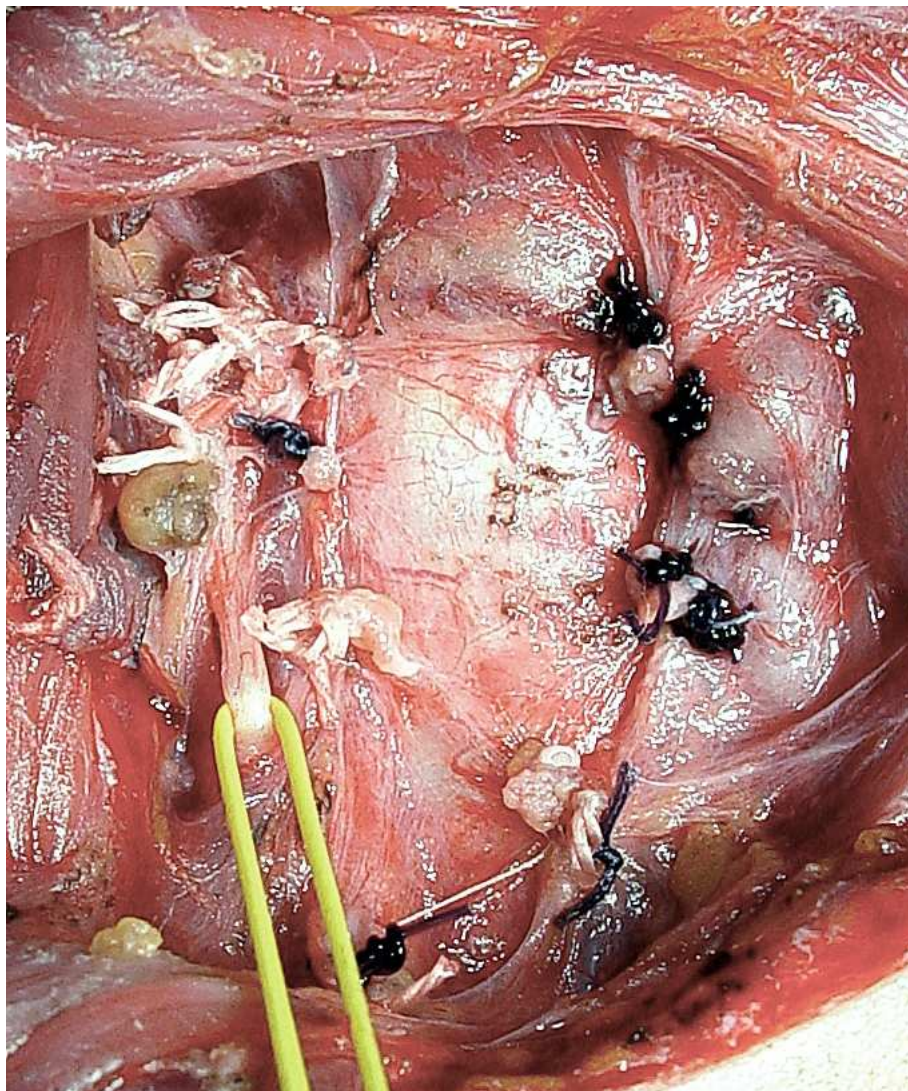




Lobo destro - Istmo - Lobo sinistro (superficie anteriore)

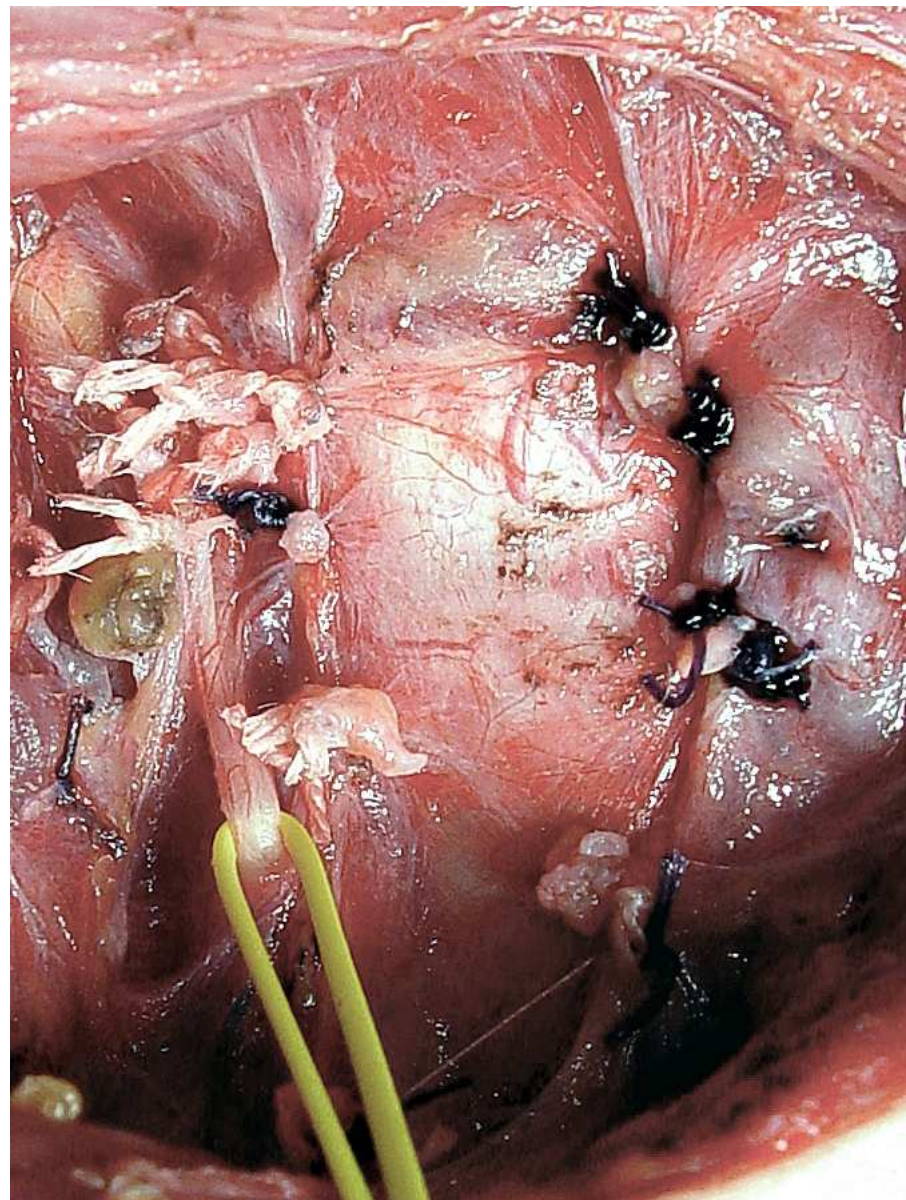


Lobo sinistro - Istmo - Lobo destro (superficie posteriore)

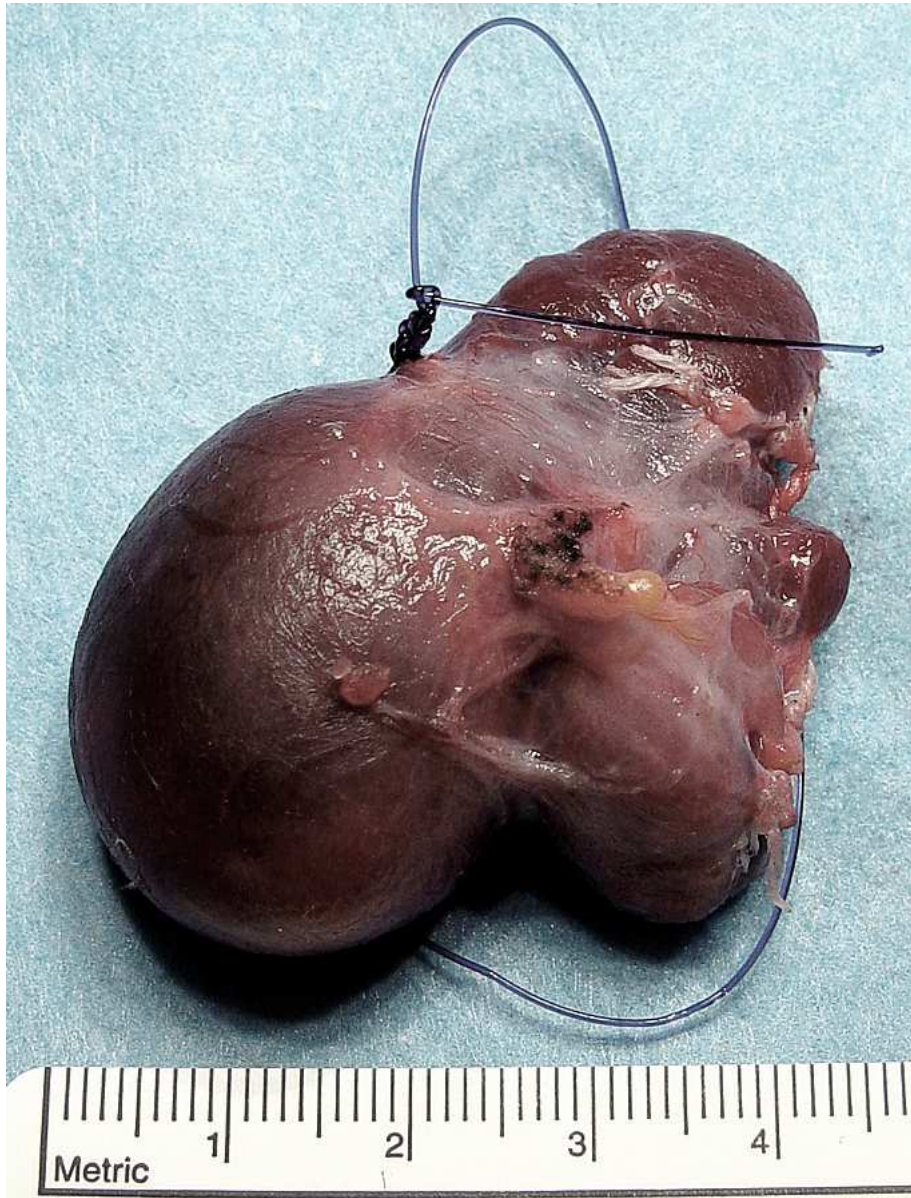


F.B. · Anni: 20 - F · Record: 58 · 26-03-2003

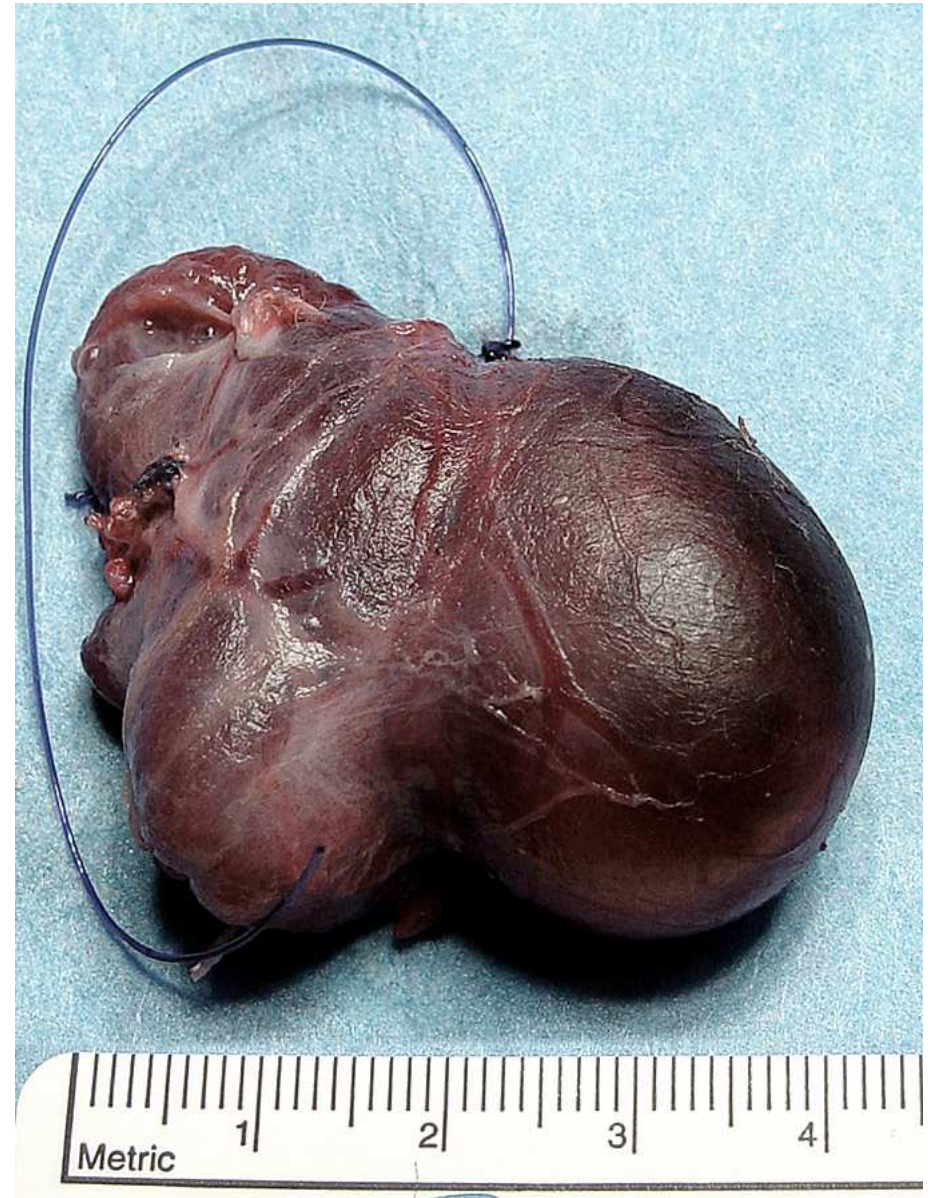
Emitiroidectomia destra per adenoma follicolare



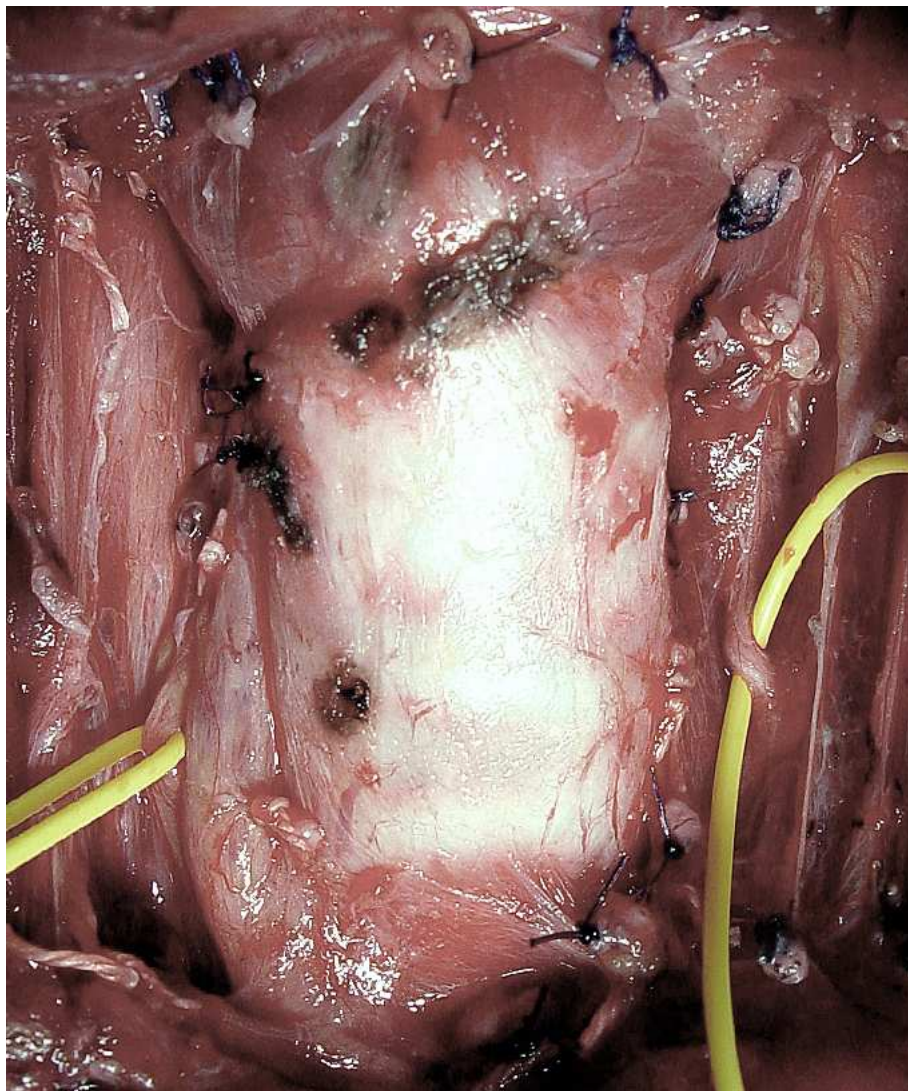
Isolamento del nervo laringeo inferiore destro (ricorrente)



Lobo destro - Istmo (superficie anteriore)

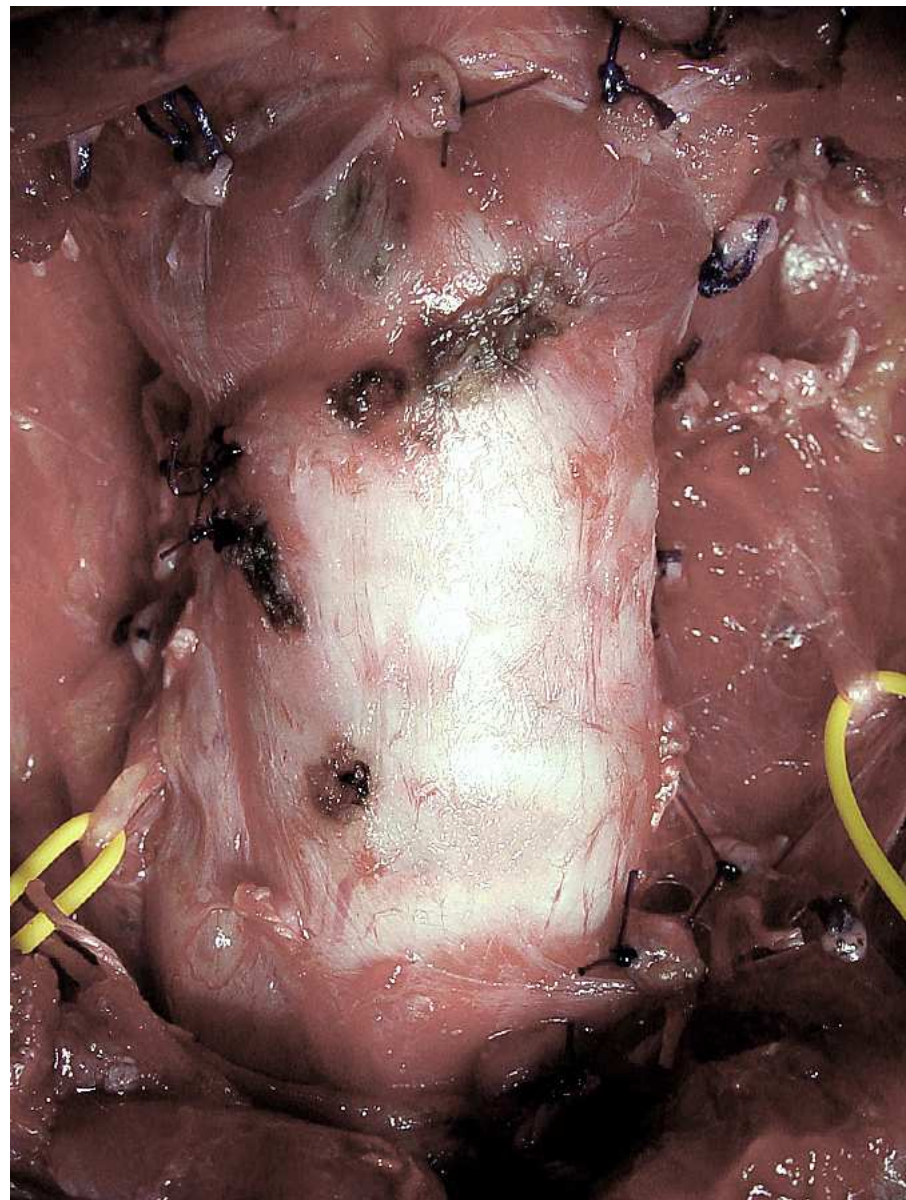


Istmo - Lobo destro (superficie posteriore)

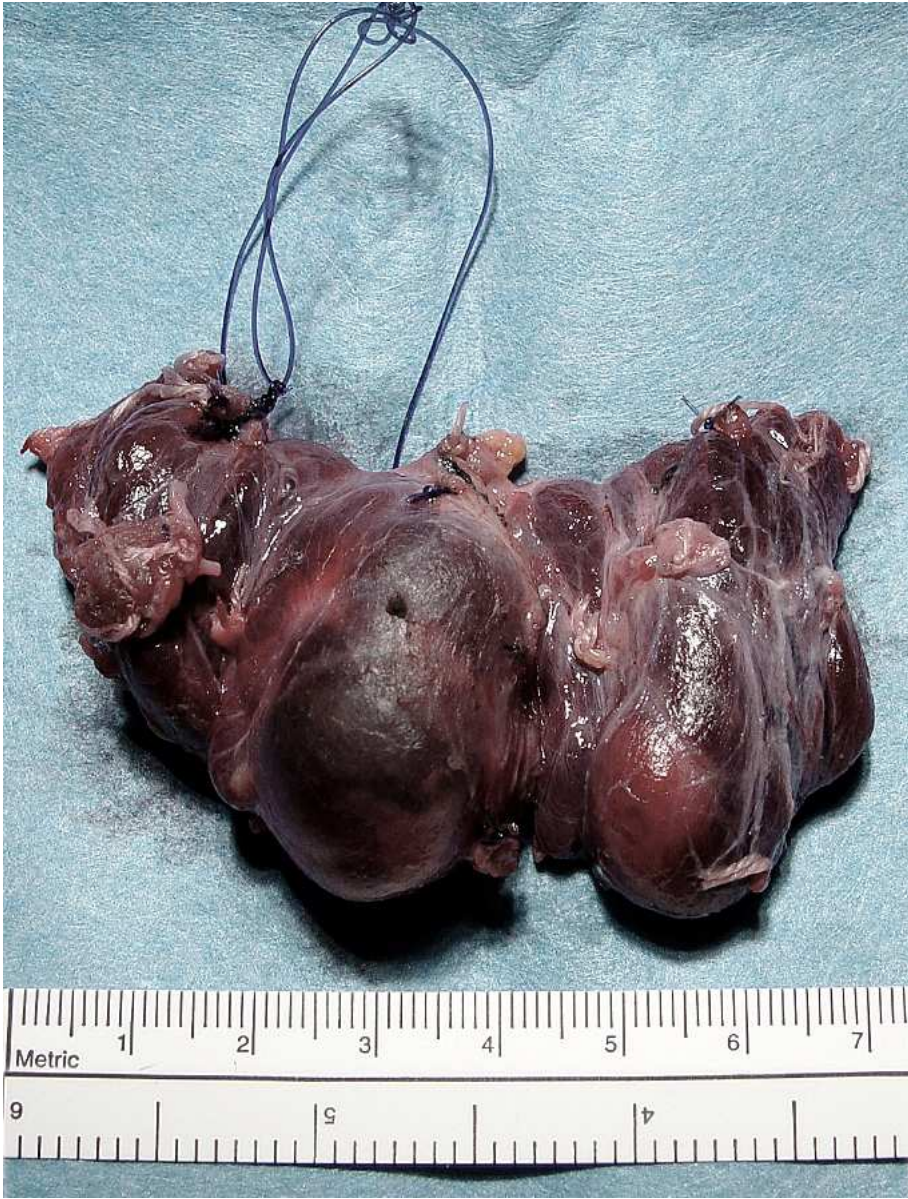

P.A. • Anni: 38 - F • Record: 59 • 02-04-2003

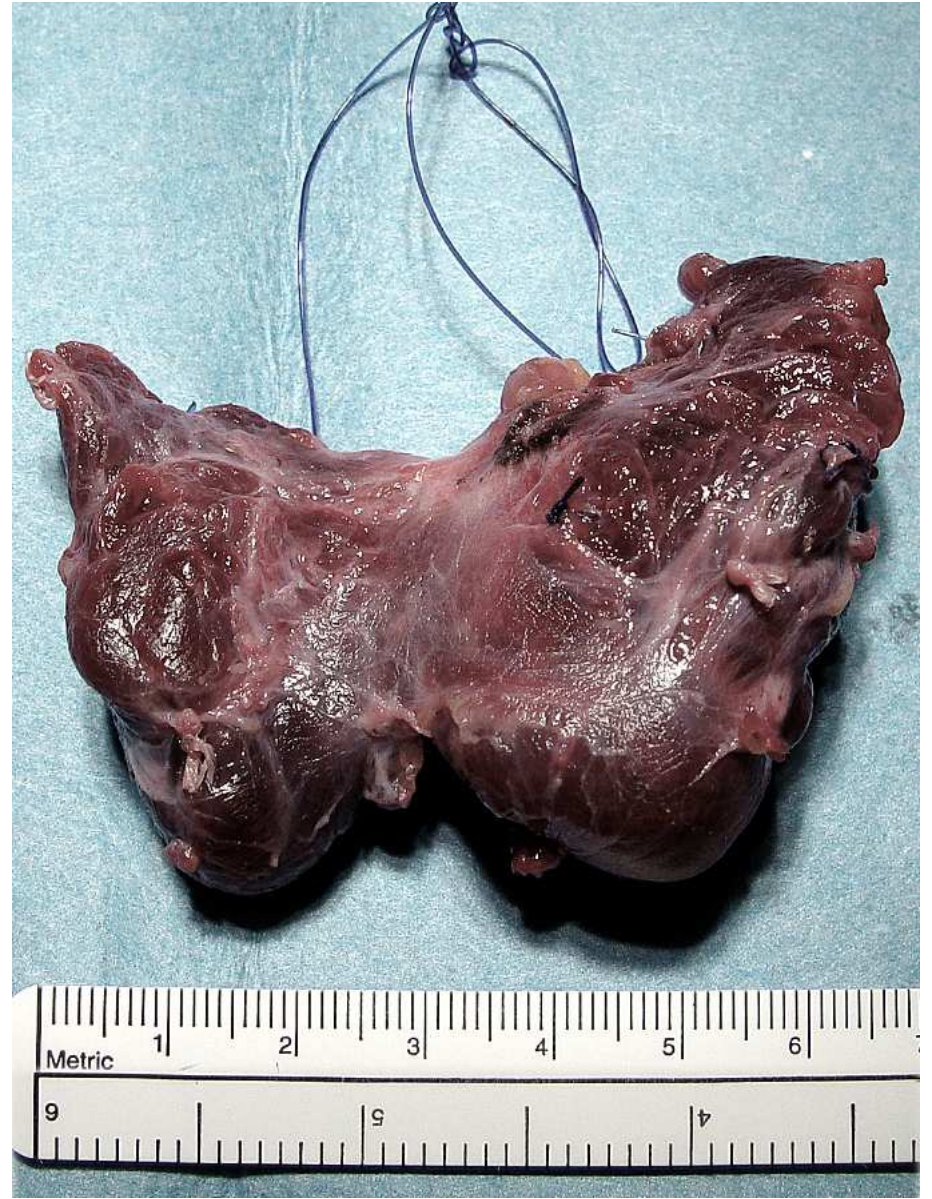Tiroidectomia totale extracapsulare per carcinoma papillifero multifocale (pT2b G2)



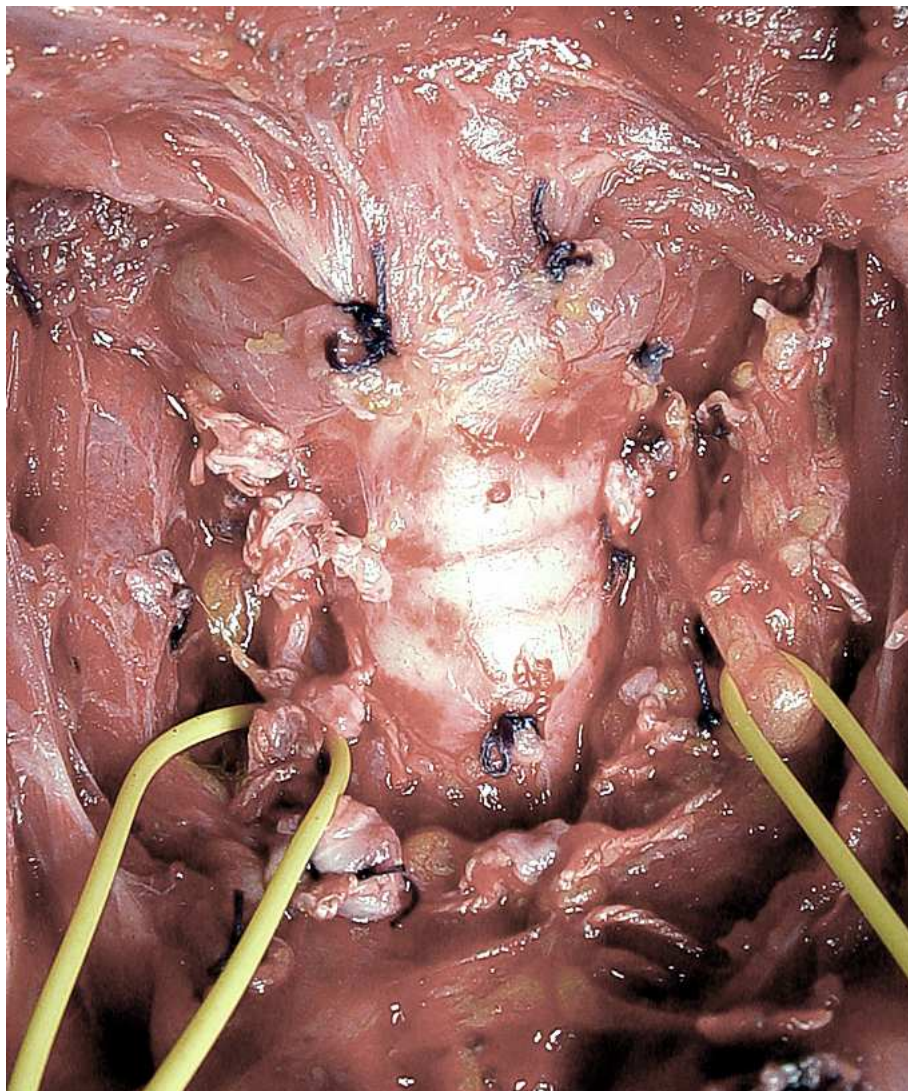
Isolamento dei nervi laringei inferiori (ricorrenti)



Lobo destro - Istmo - Lobo sinistro (superficie anteriore)

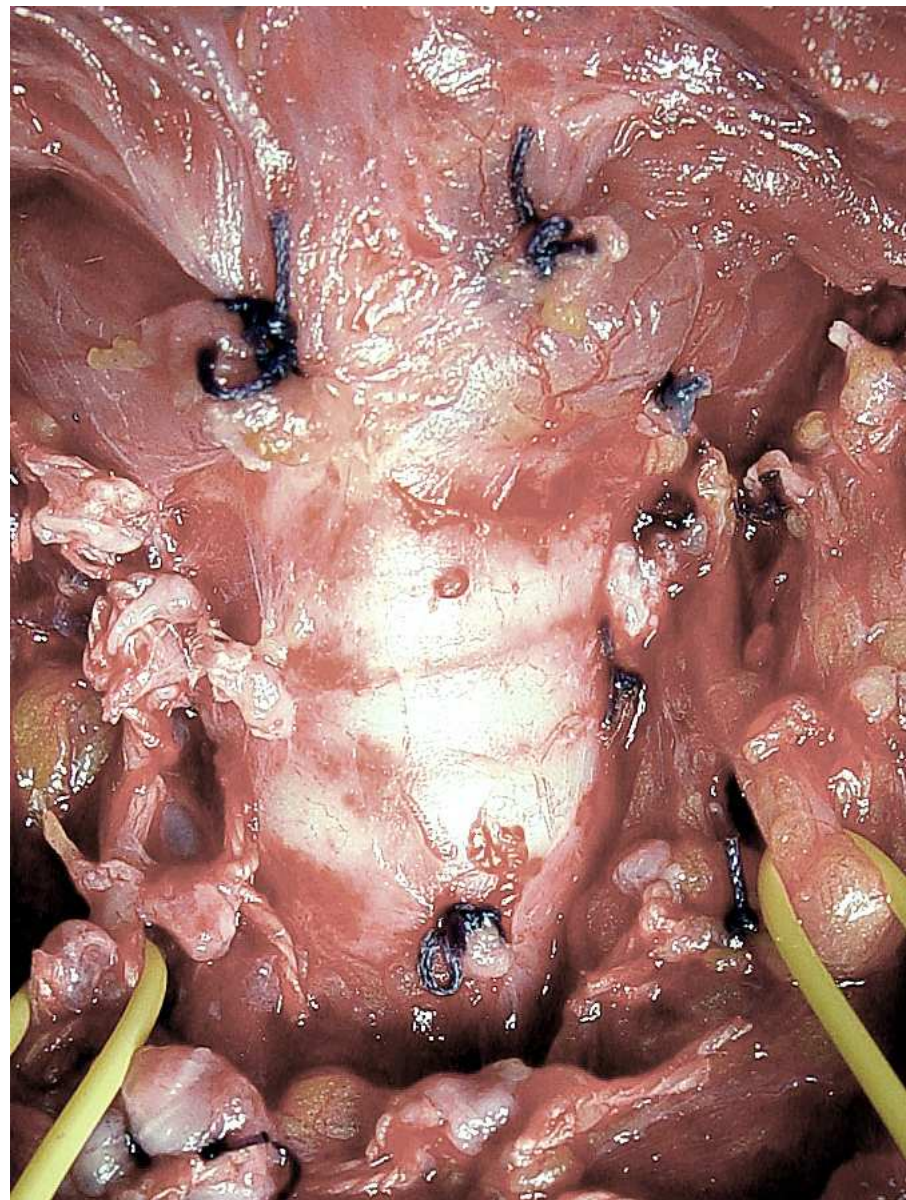


Lobo sinistro - Istmo - Lobo destro (superficie posteriore)

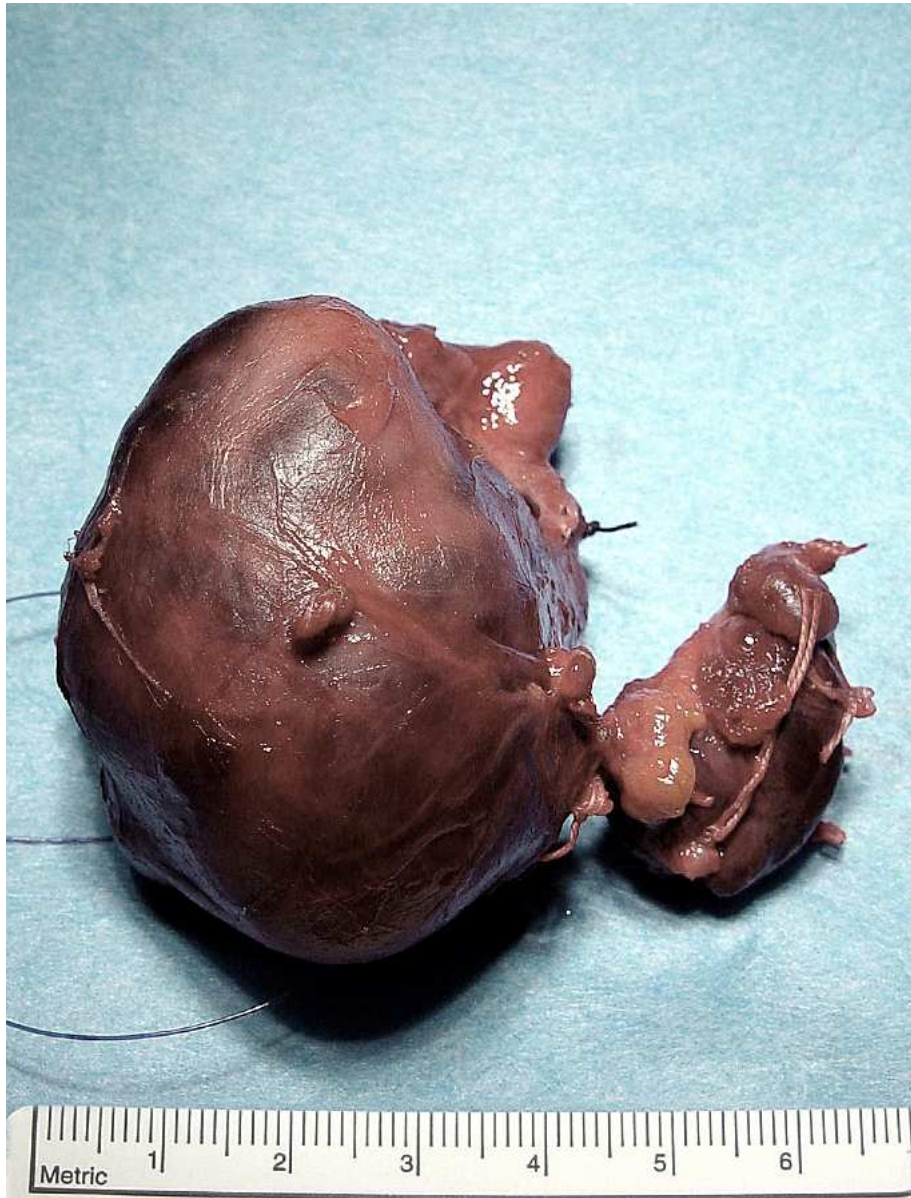


C.A. · Anni: 49 - F · Record: 60 · 09-04-2003

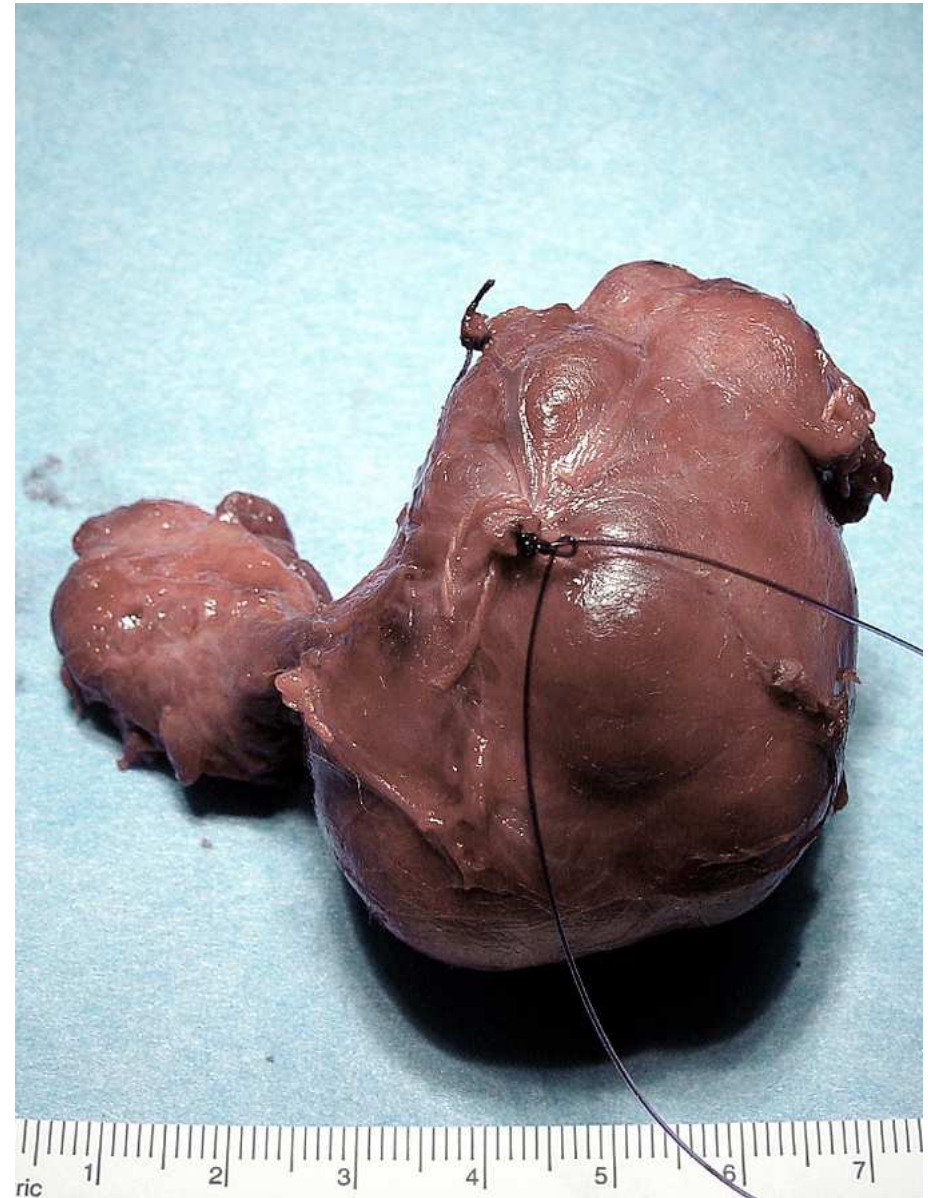
Tiroidectomia totale extracapsulare per carcinoma papillifero multifocale (pT4b G1)



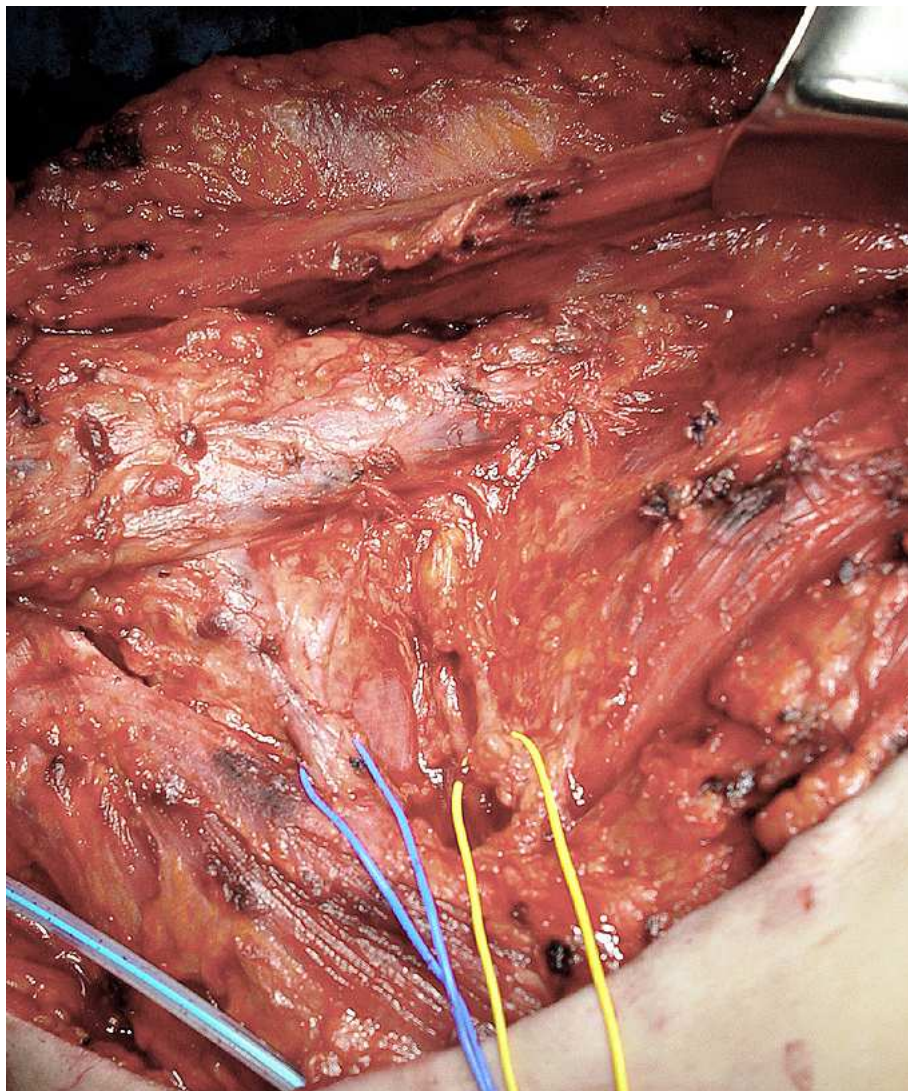
Isolamento dei nervi laringei inferiori (ricorrenti)



Lobo destro - Istmo - Lobo sinistro (superficie anteriore)

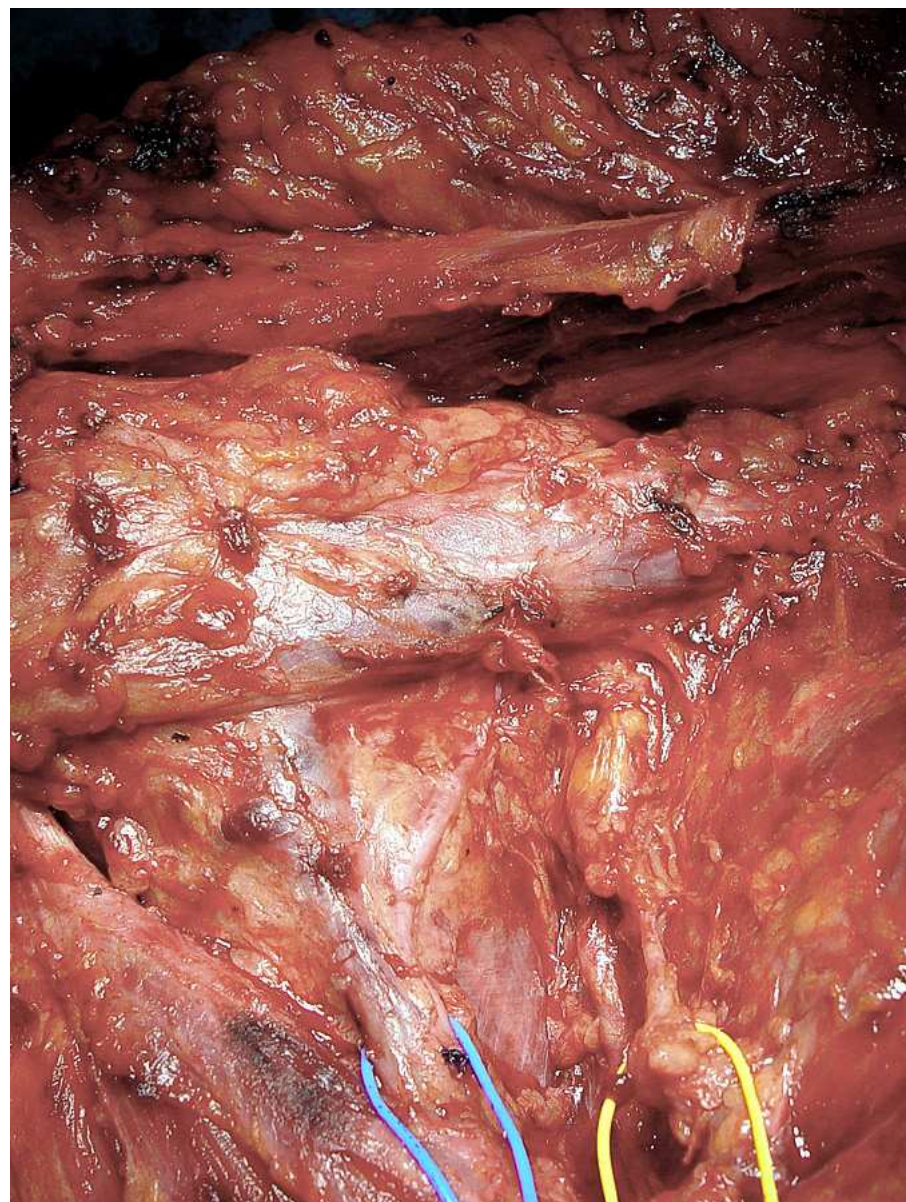

Lobo sinistro - Istmo - Lobo destro (superficie posteriore)

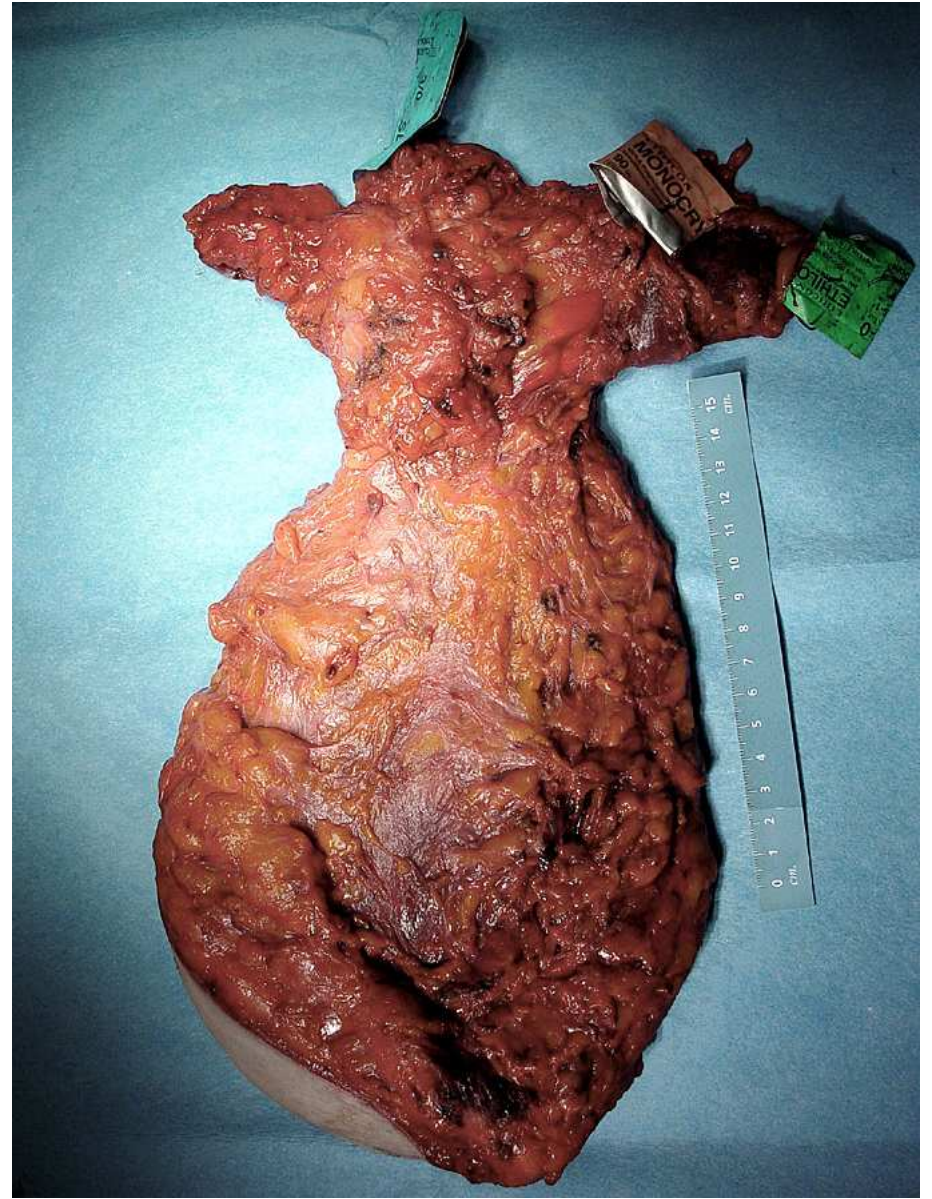
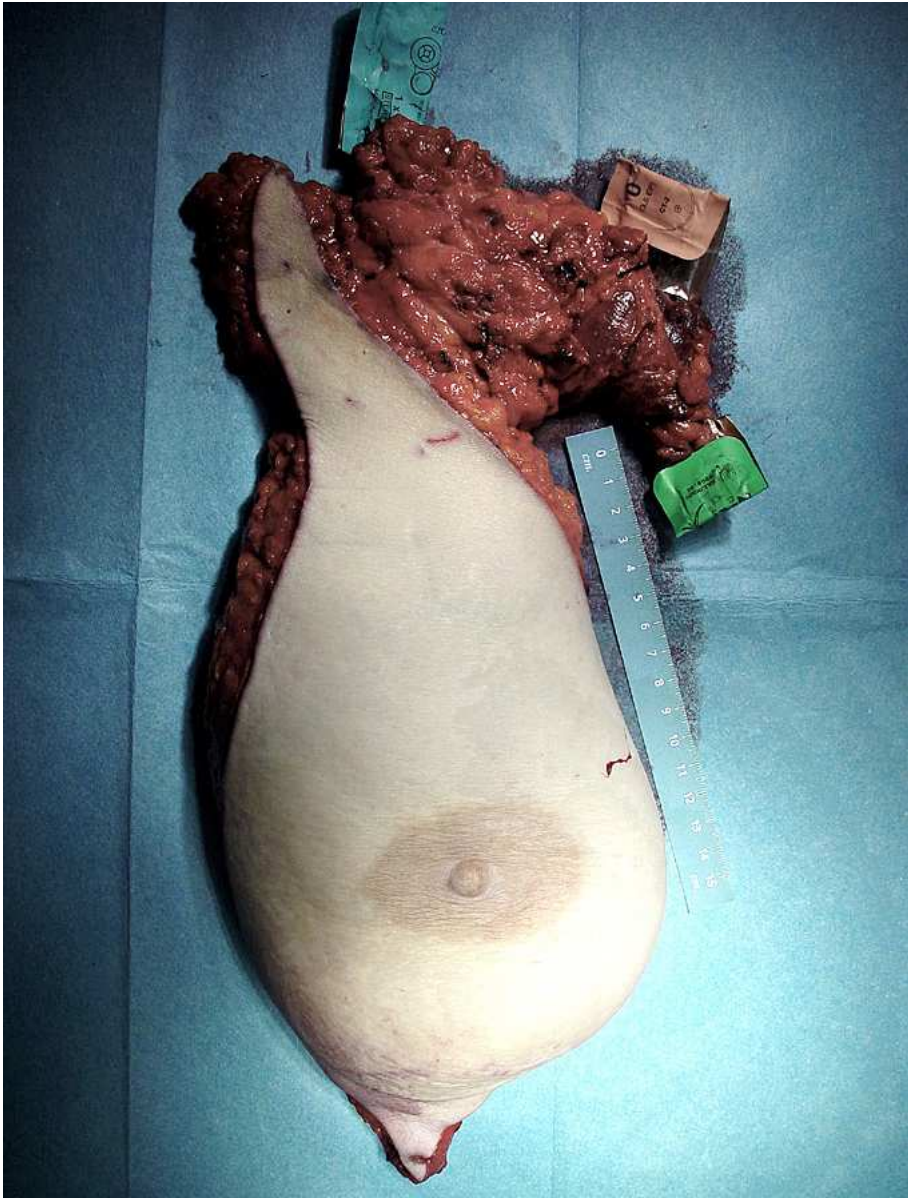

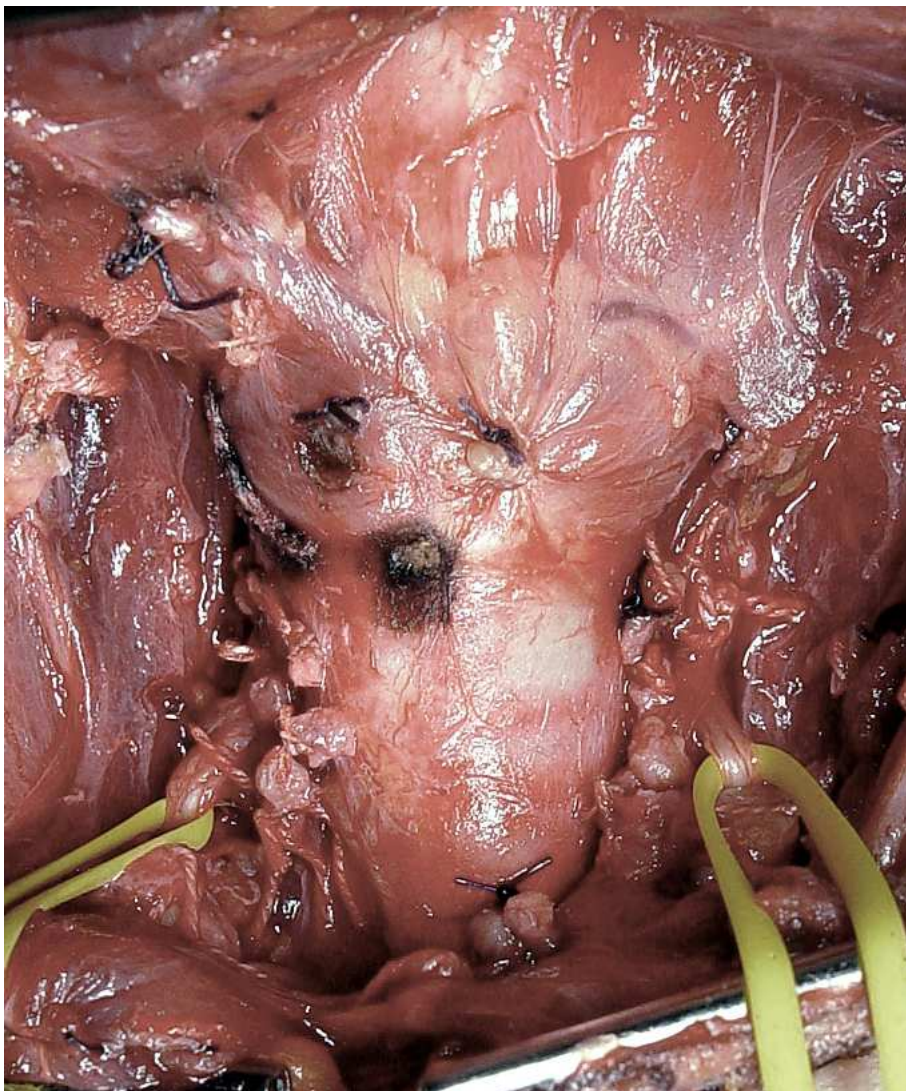
D.L. · Anni: 69 - F · Record: 61 · 12-04-2003

Mastectomia radicale modificata sec. Patey con svuotamento ascellare in continuit  per carcinoma lobulare infiltrante QII dx (T2N0M0)



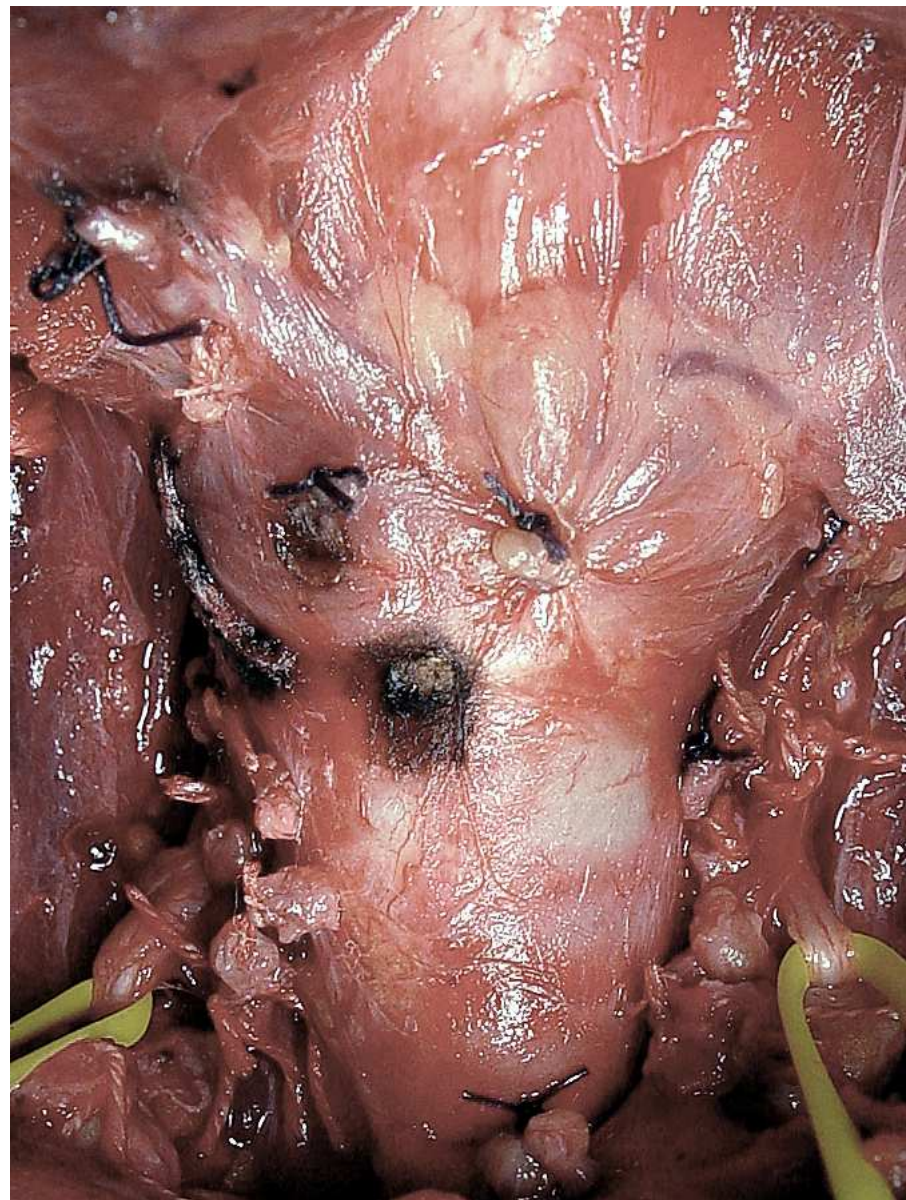




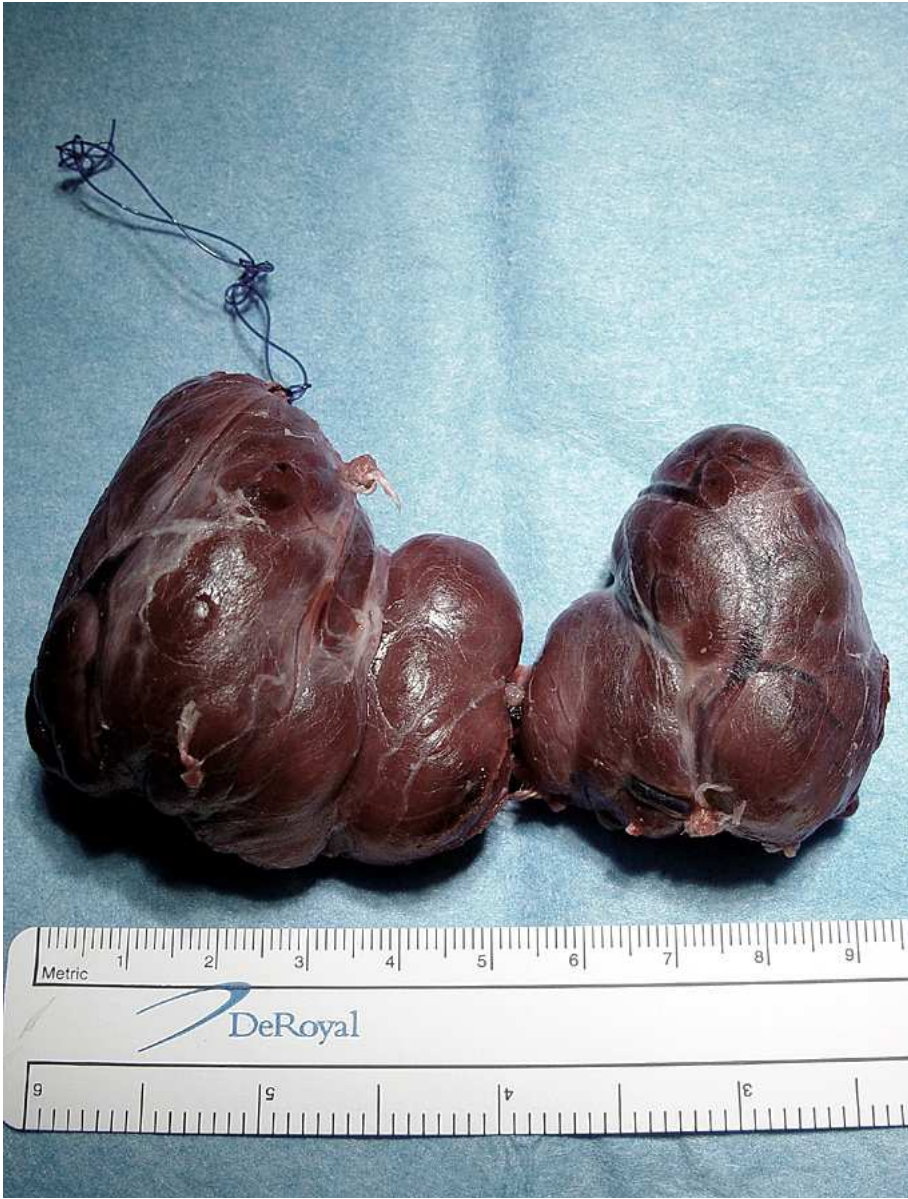

C.S. · Anni: 48 - F · Record: 62 · 14-05-2003

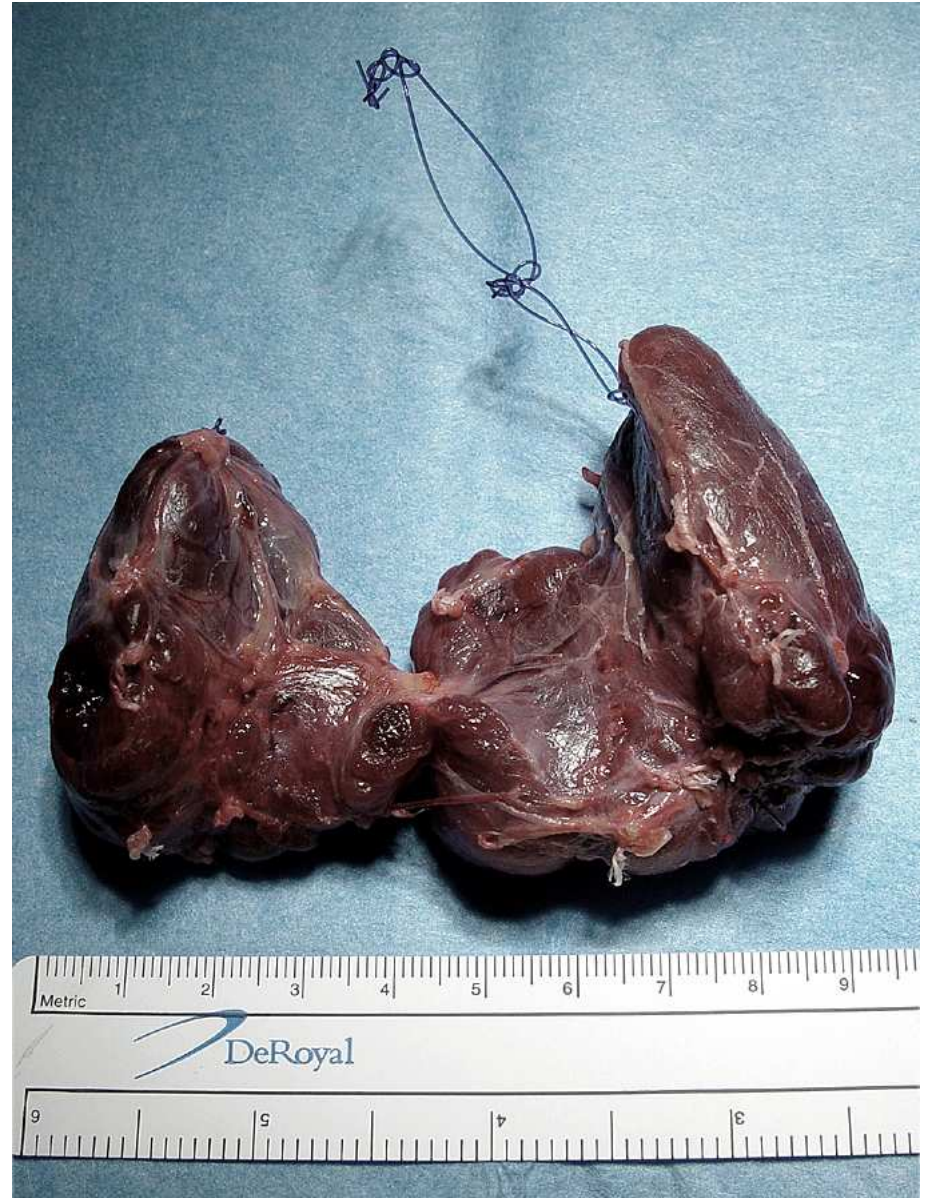Tiroidectomia totale extracapsulare per gozzo plurinodulare tossico



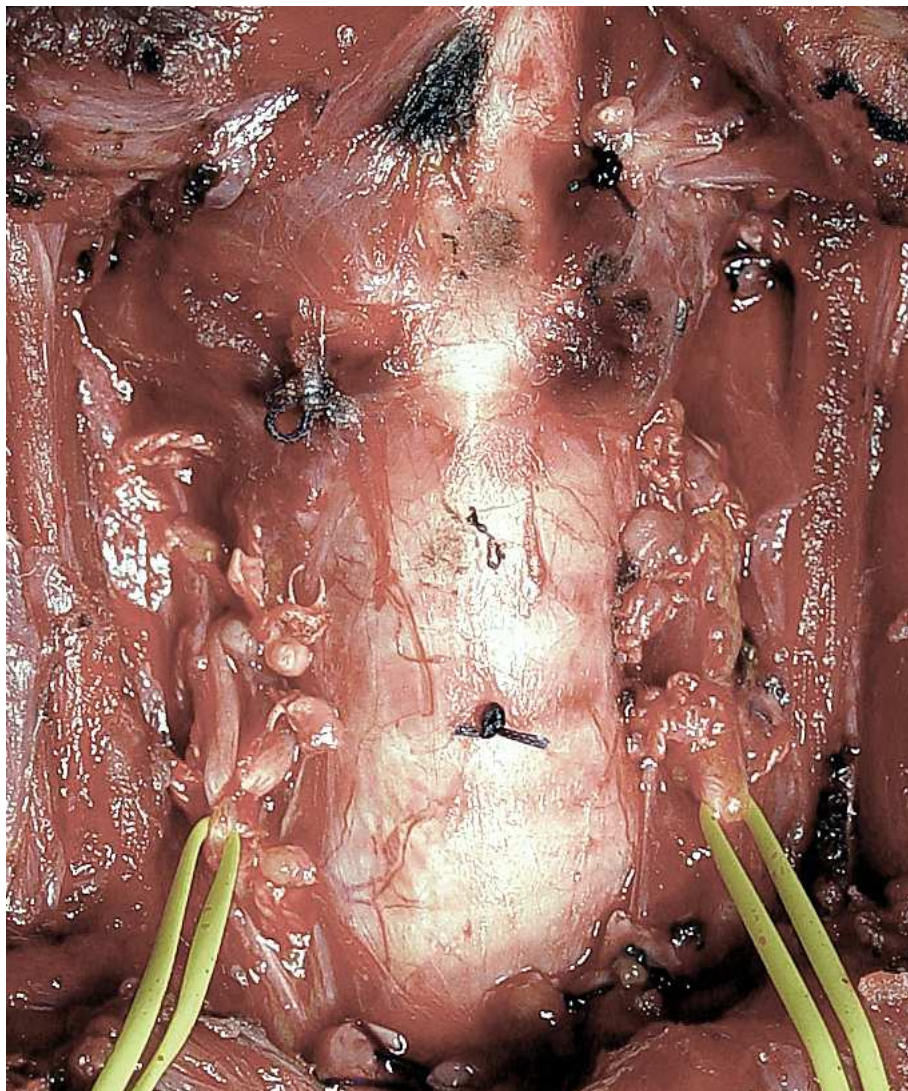
Isolamento dei nervi laringei inferiori (ricorrenti)



Lobo destro - Istmo - Lobo sinistro (superficie anteriore)

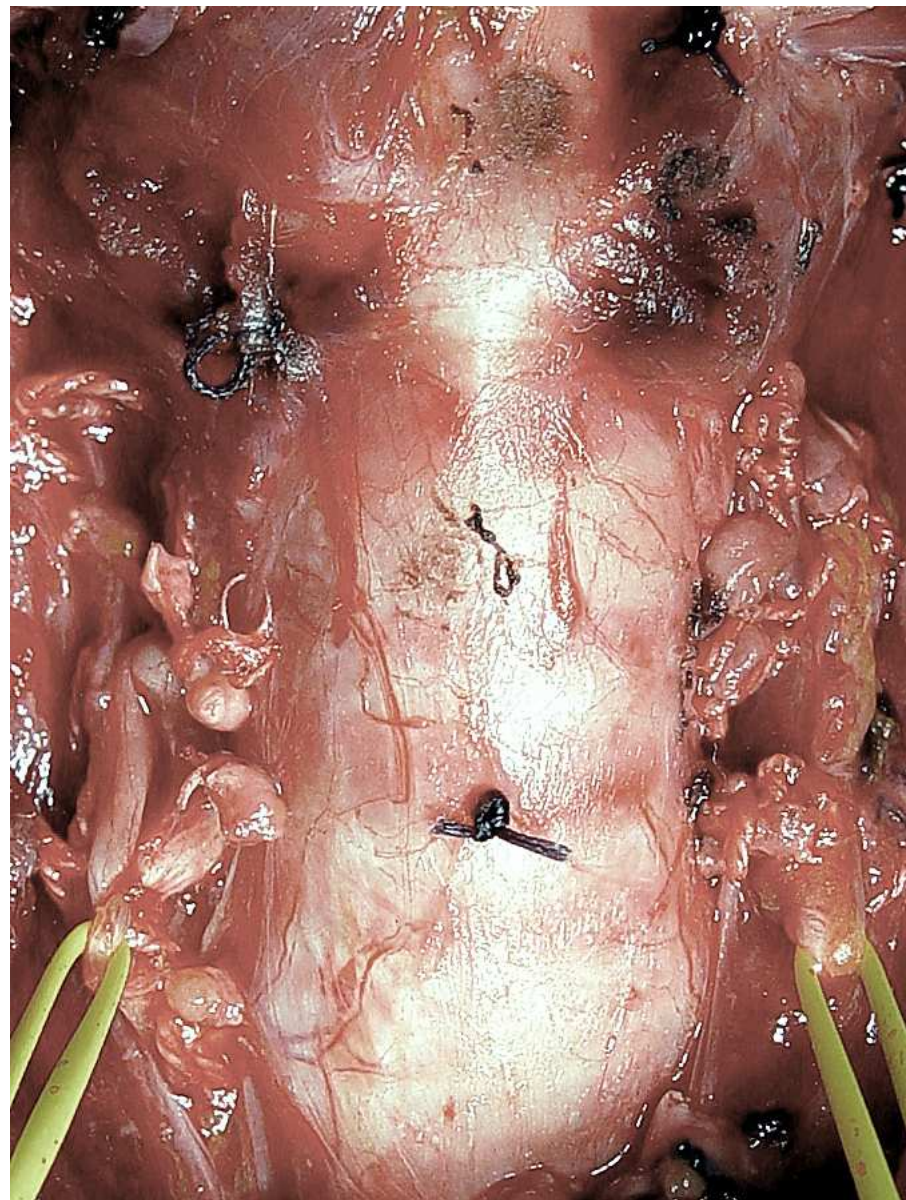

Lobo sinistro - Istmo - Lobo destro (superficie posteriore)

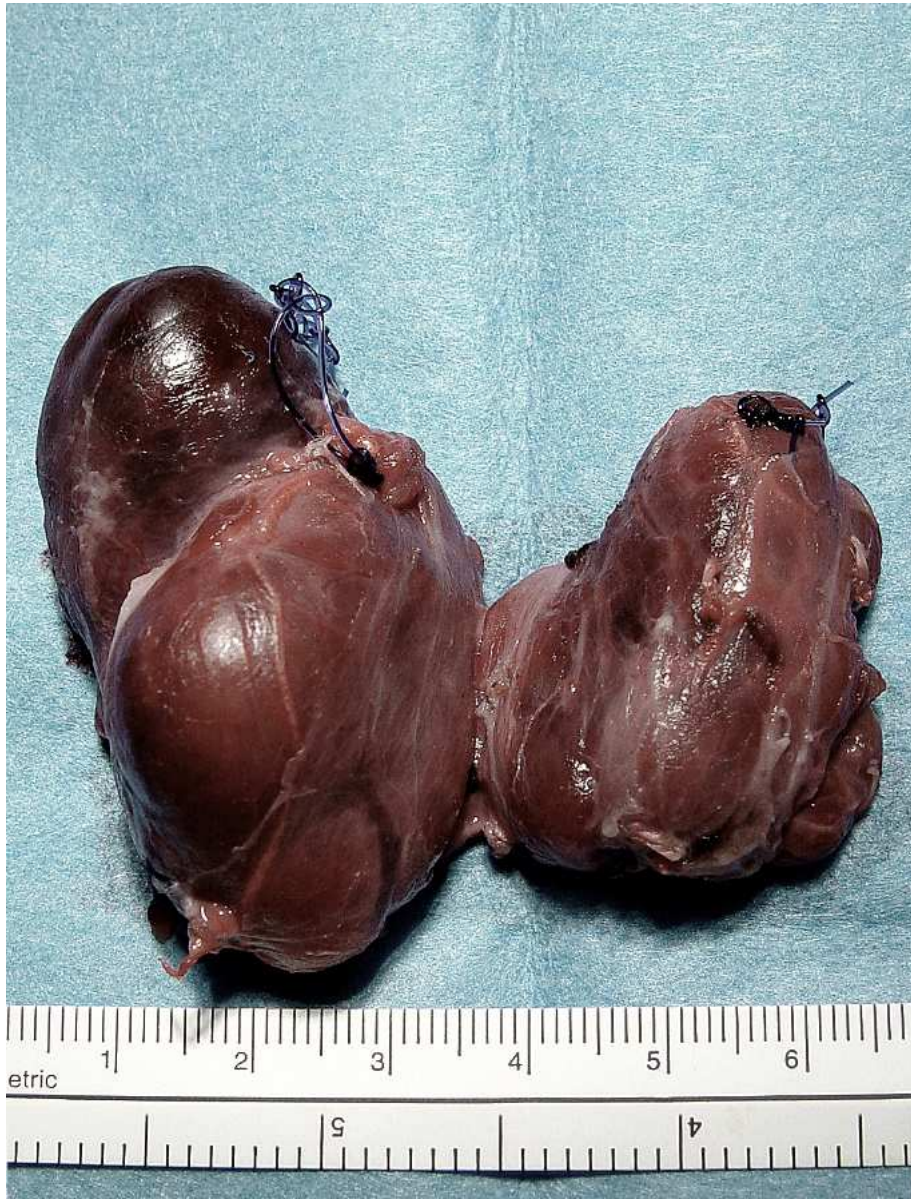

T.M. · Anni: 49 - F · Record: 63 · 16-05-2003

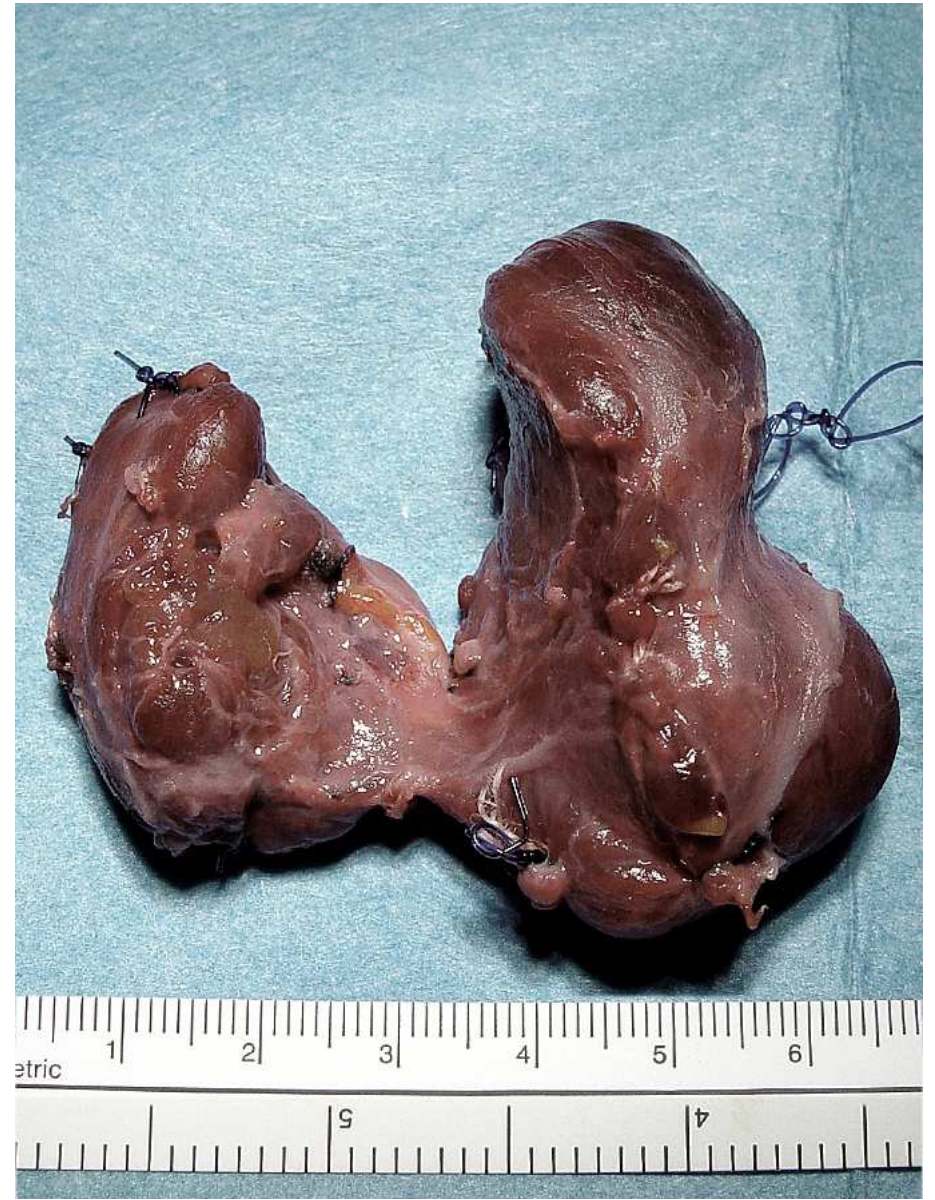Tiroidectomia totale extracapsulare per gozzo plurinodulare



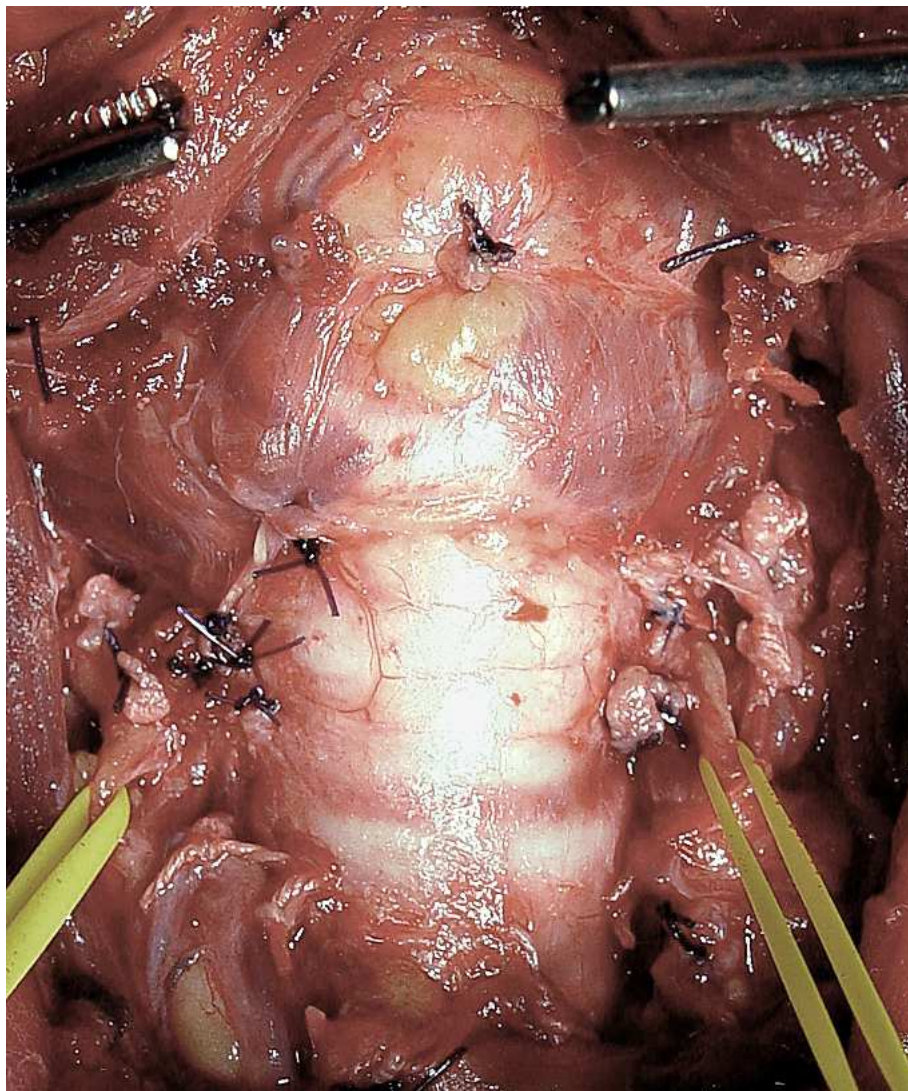
Isolamento dei nervi laringei inferiori (ricorrenti)



Lobo destro - Istmo - Lobo sinistro (superficie anteriore)

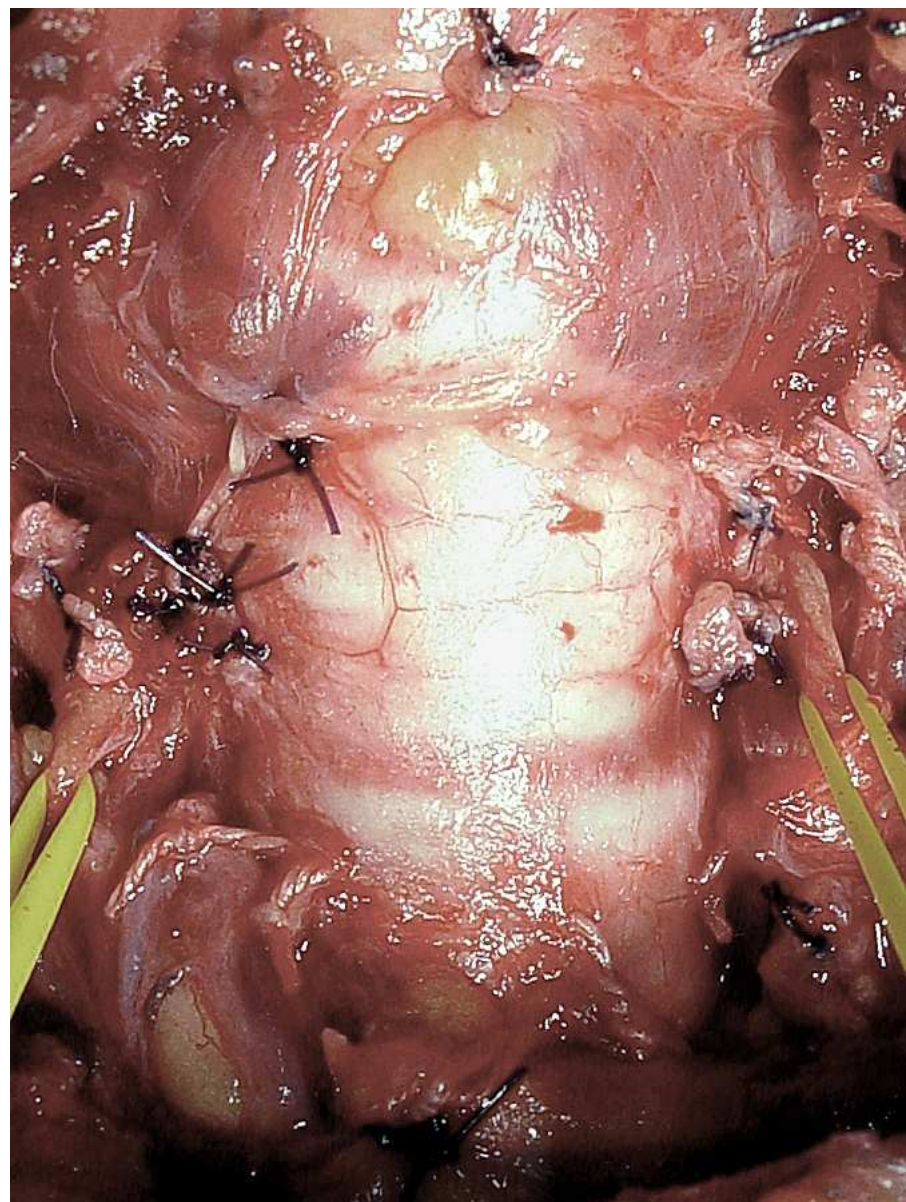


Lobo sinistro - Istmo - Lobo destro (superficie posteriore)

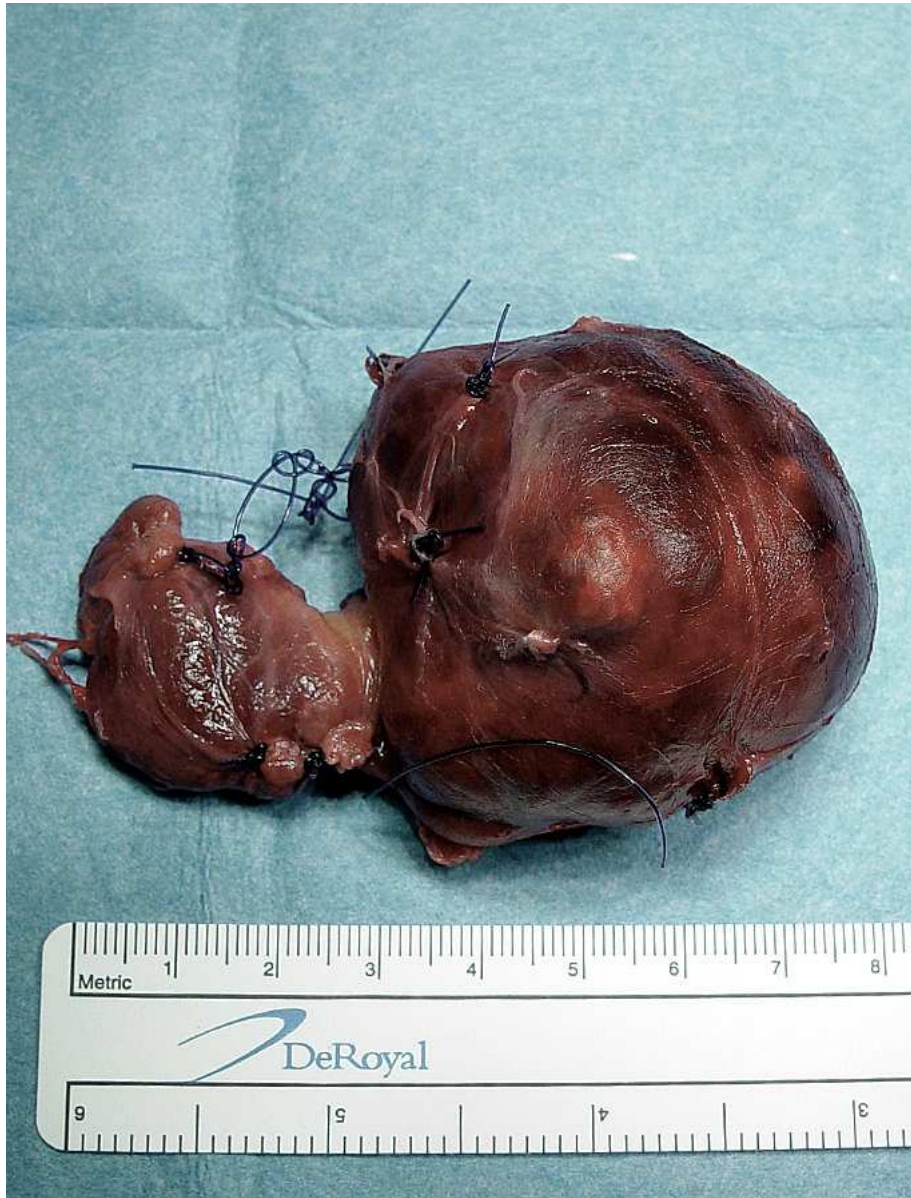

D.F.R. • Anni: 69 - M • Record: 64 • 03-06-2003

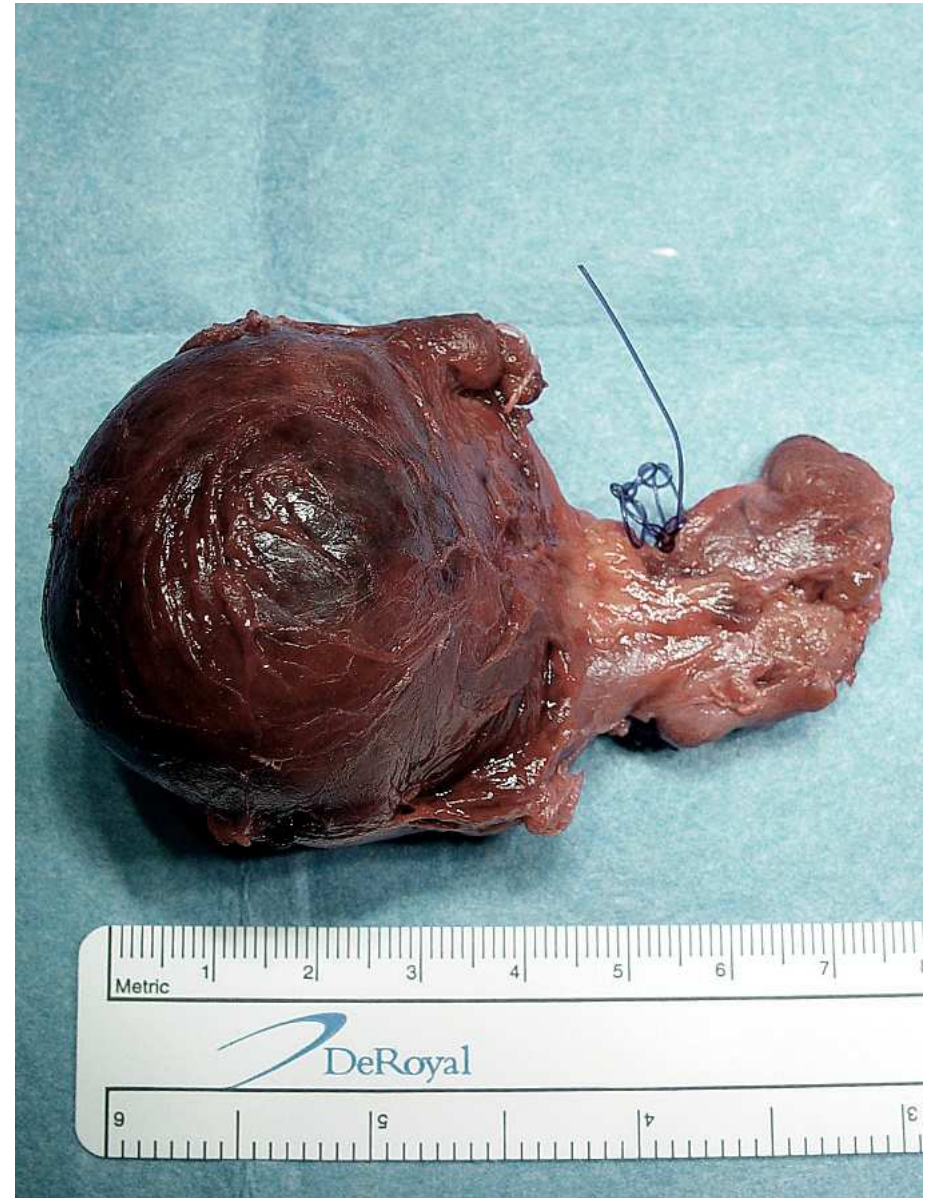Tiroidectomia totale extracapsulare per gozzo plurinodulare tossico



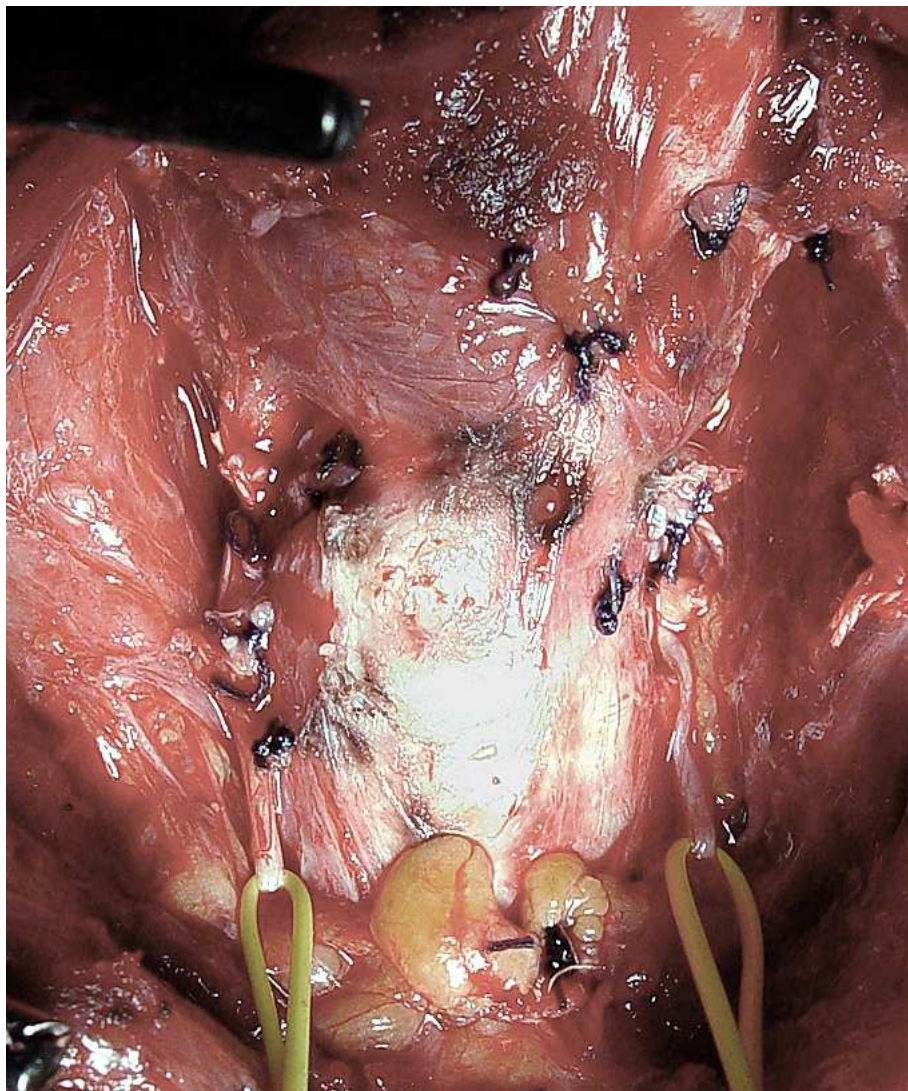
Isolamento dei nervi laringei inferiori (ricorrenti)



Lobo destro - Istmo - Lobo sinistro (superficie anteriore)

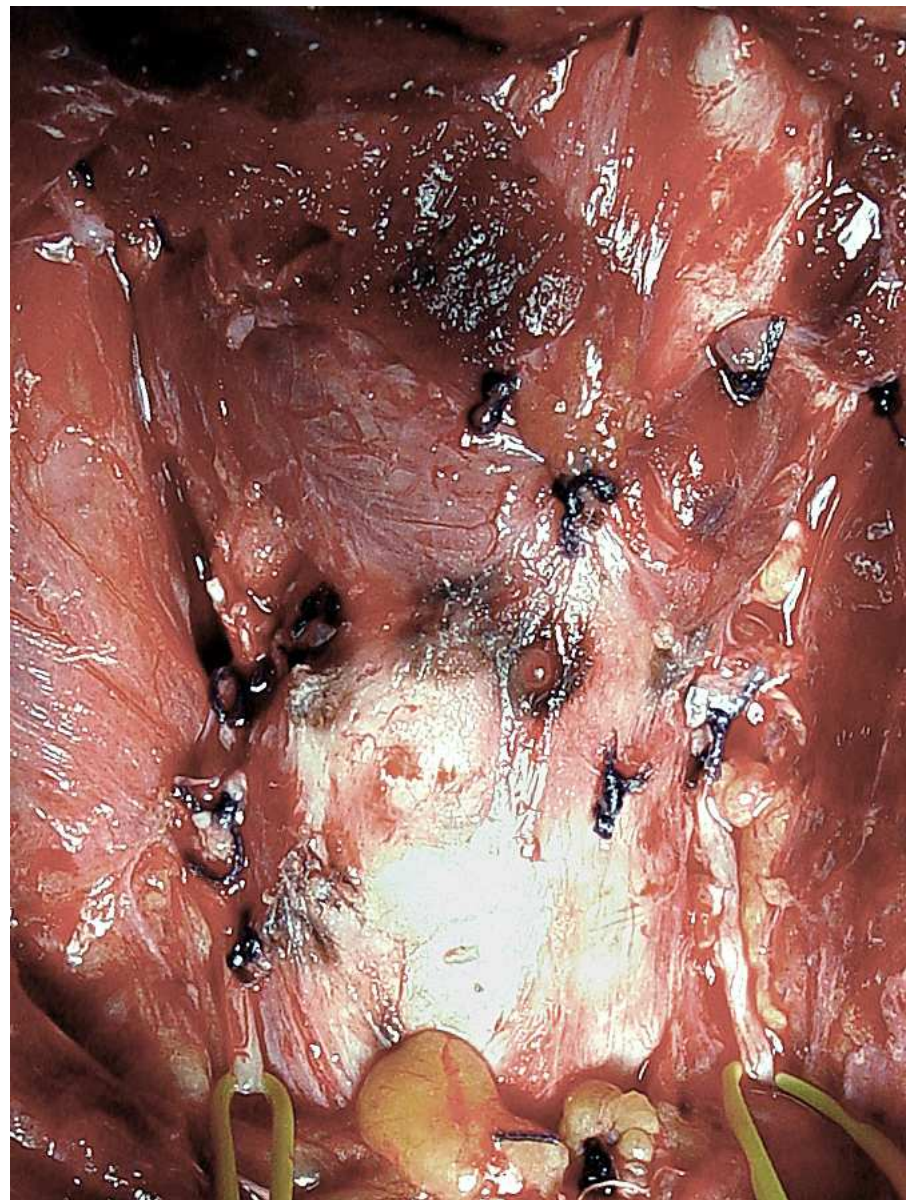


Lobo sinistro - Istmo - Lobo destro (superficie posteriore)



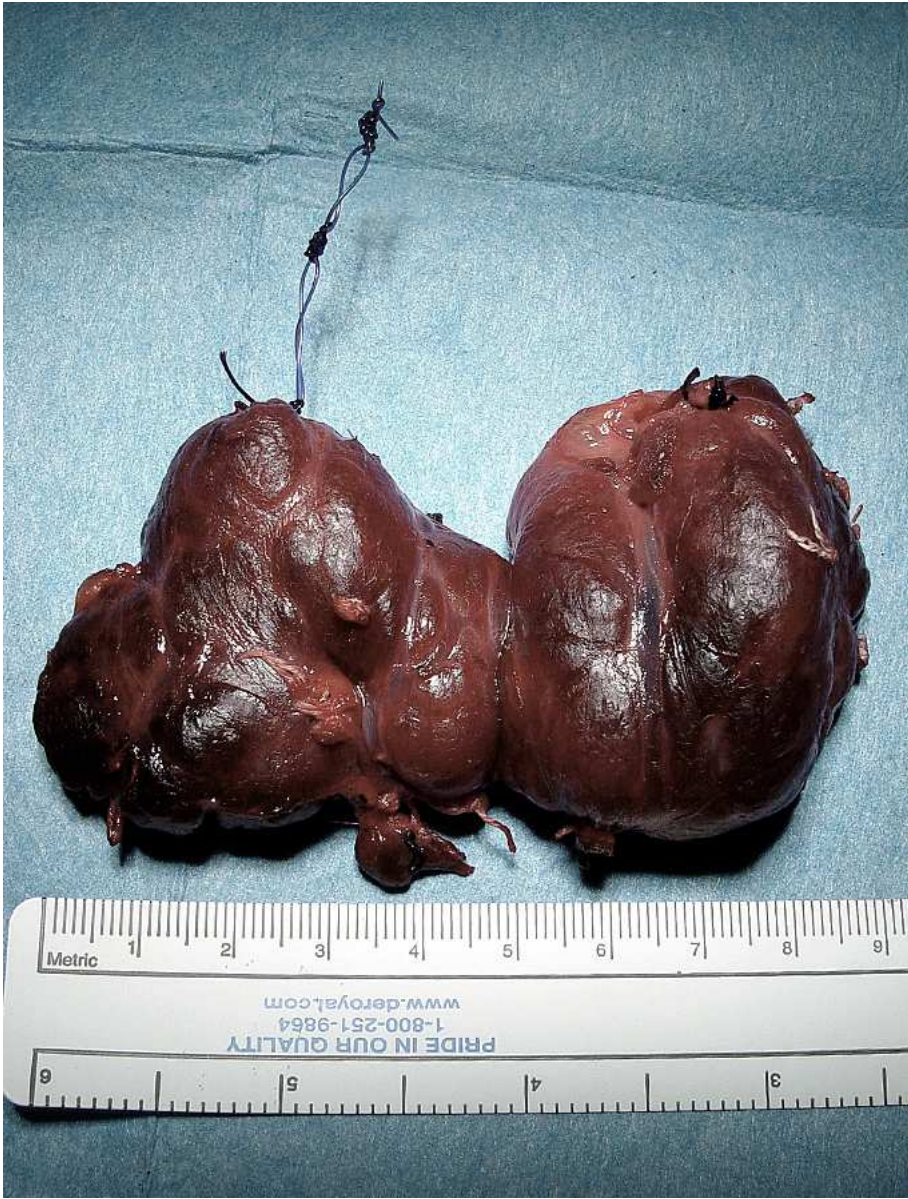B.P. • Anni: 41 - F • Record: 65 • 16-06-2003

Tiroidectomia totale extracapsulare per gozzo plurinodulare

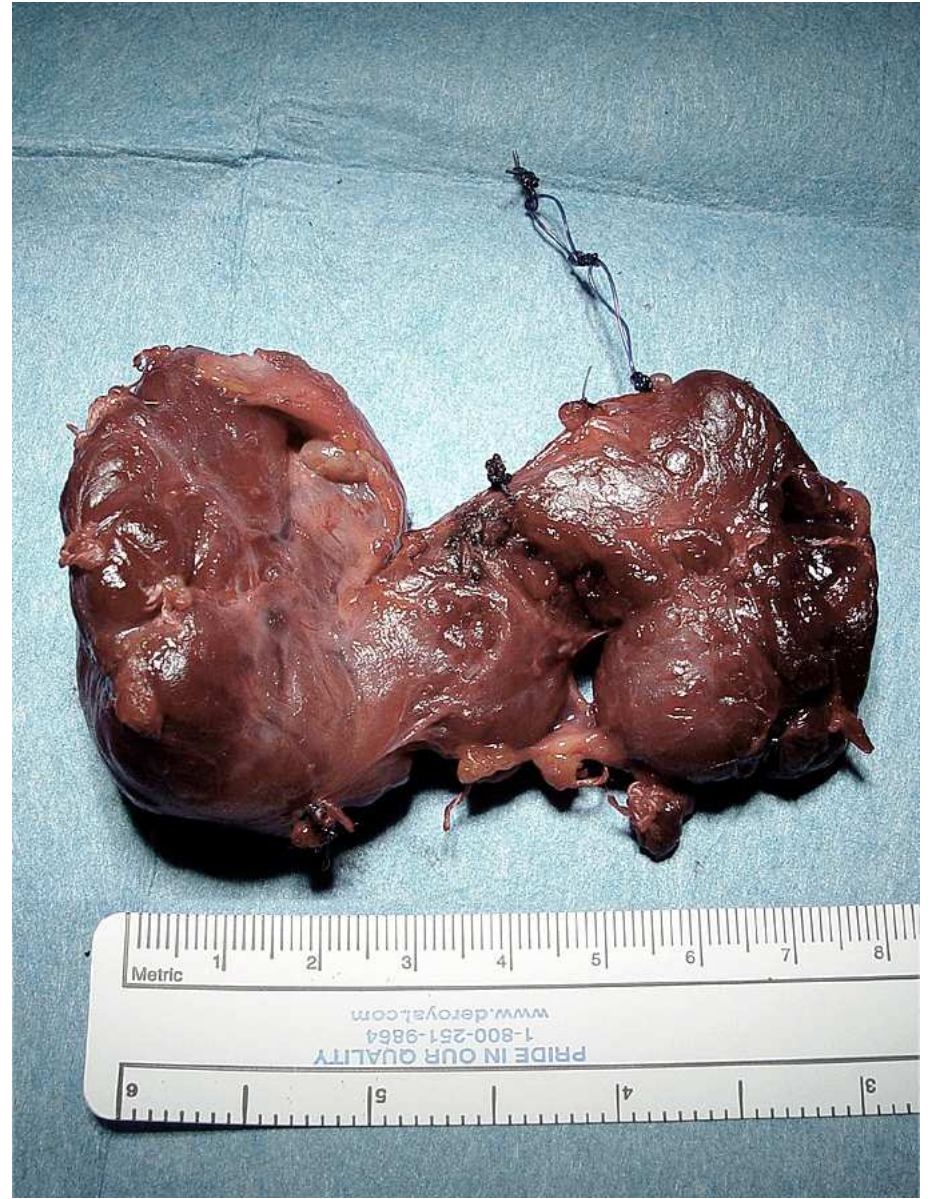


Isolamento dei nervi laringei inferiori (ricorrenti)

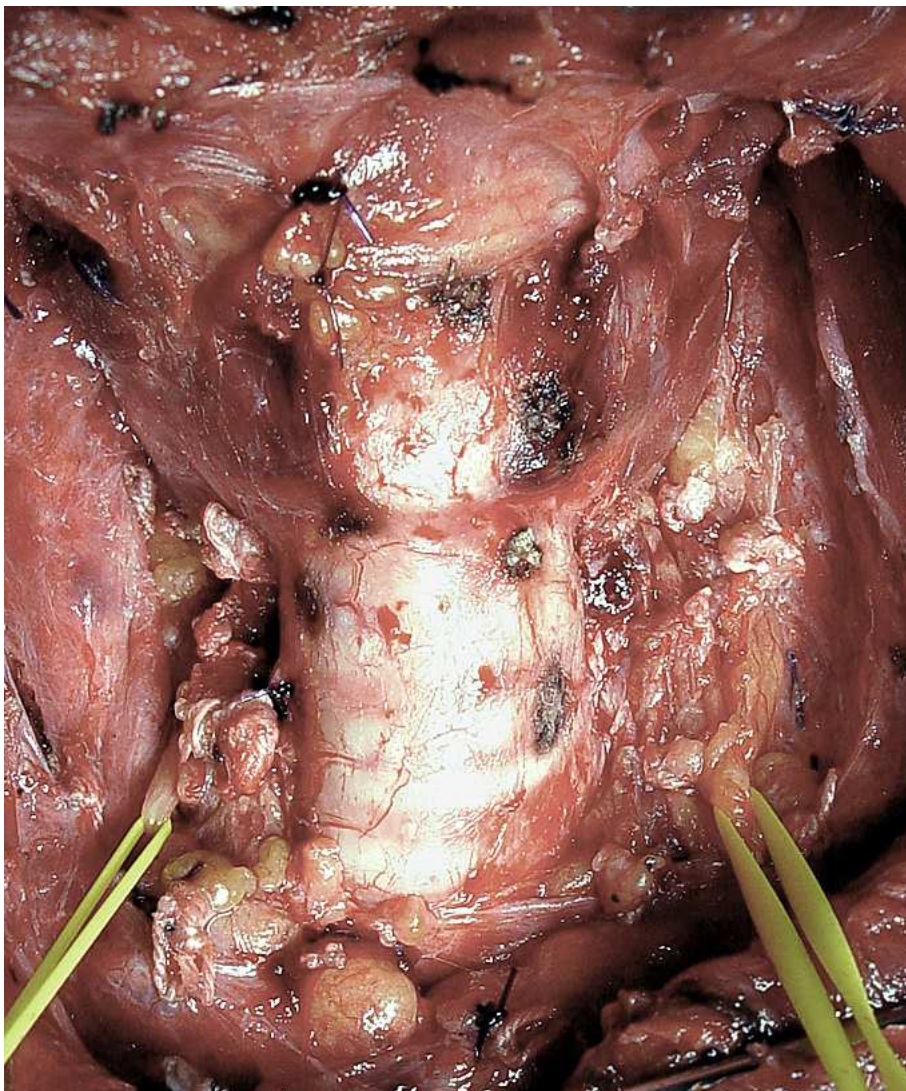




Lobo destro - Istmo - Lobo sinistro (superficie anteriore)

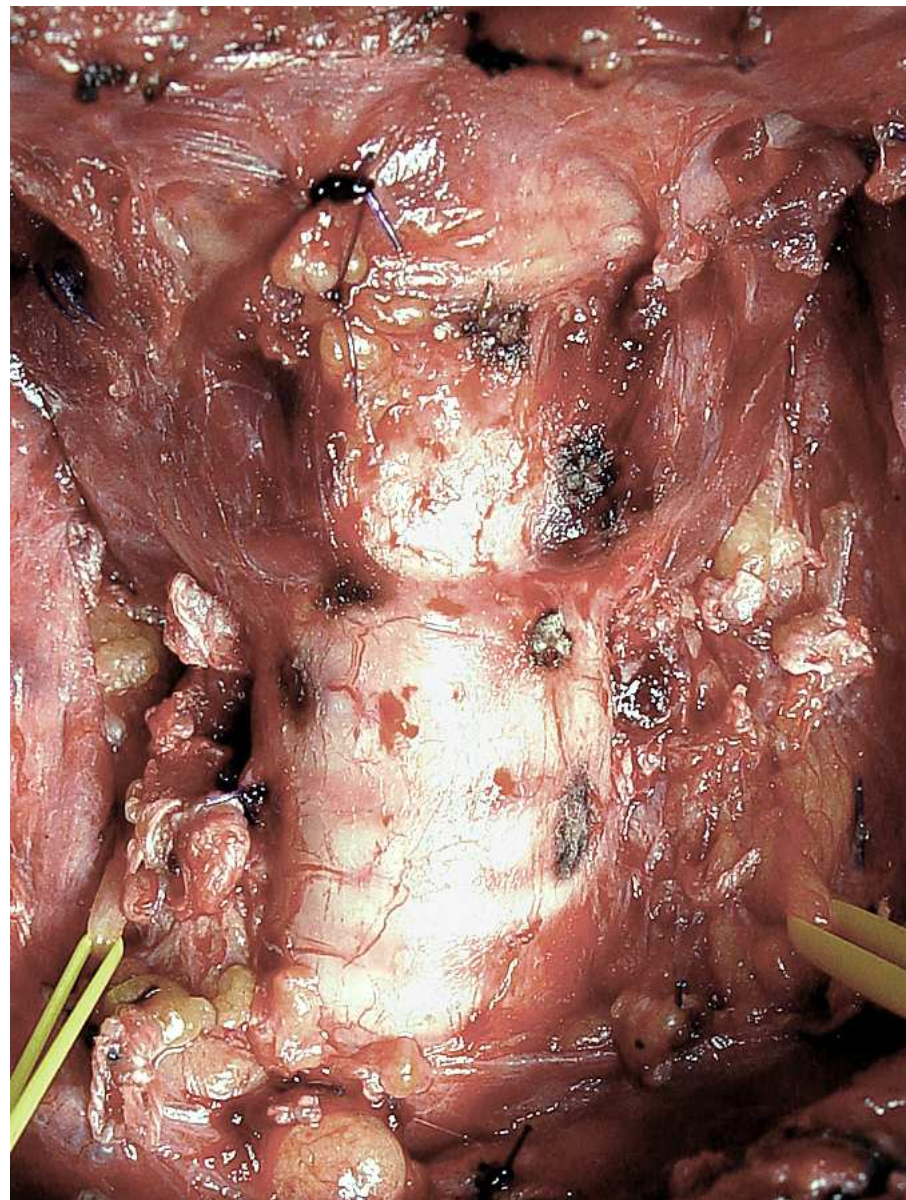


Lobo sinistro - Istmo - Lobo destro (superficie posteriore)

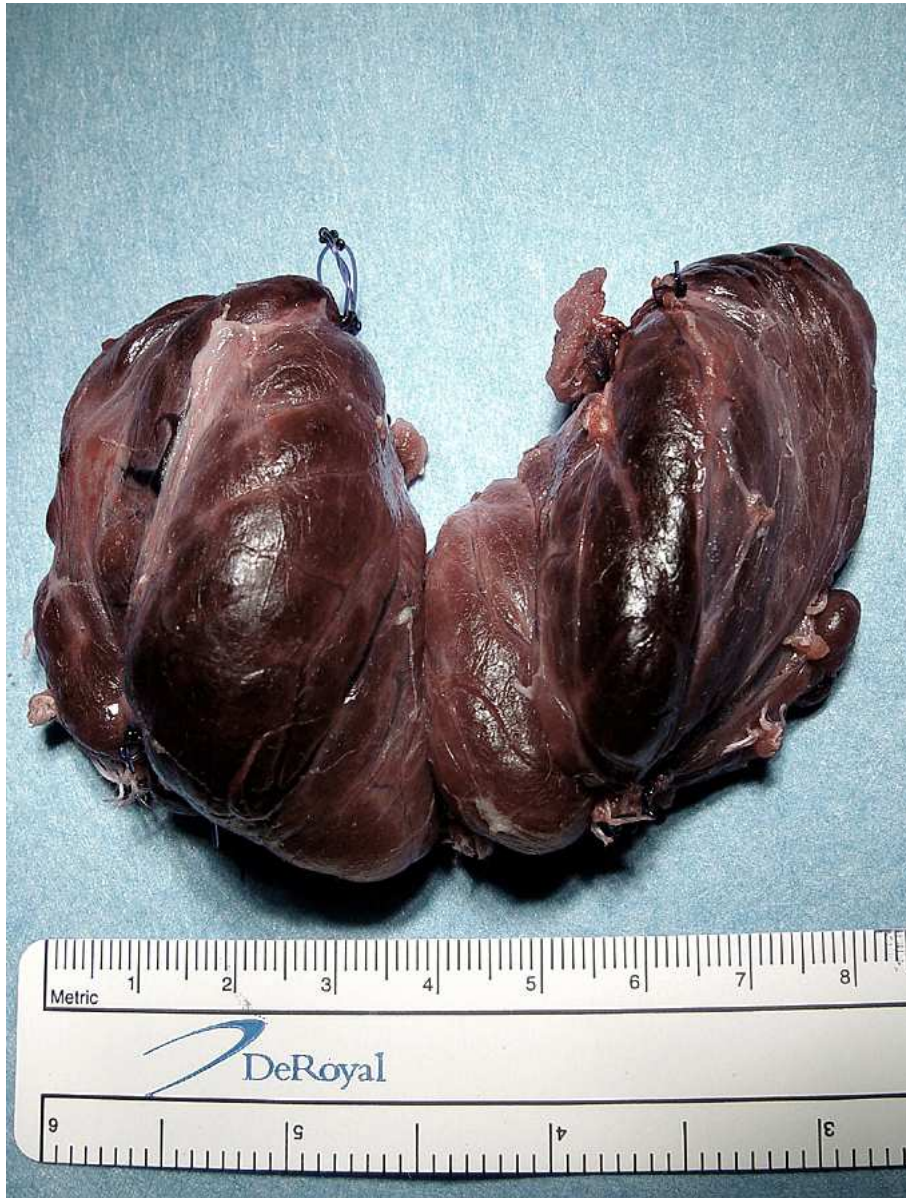

D.G. · Anni: 56 - M · Record: 66 · 21-06-2003

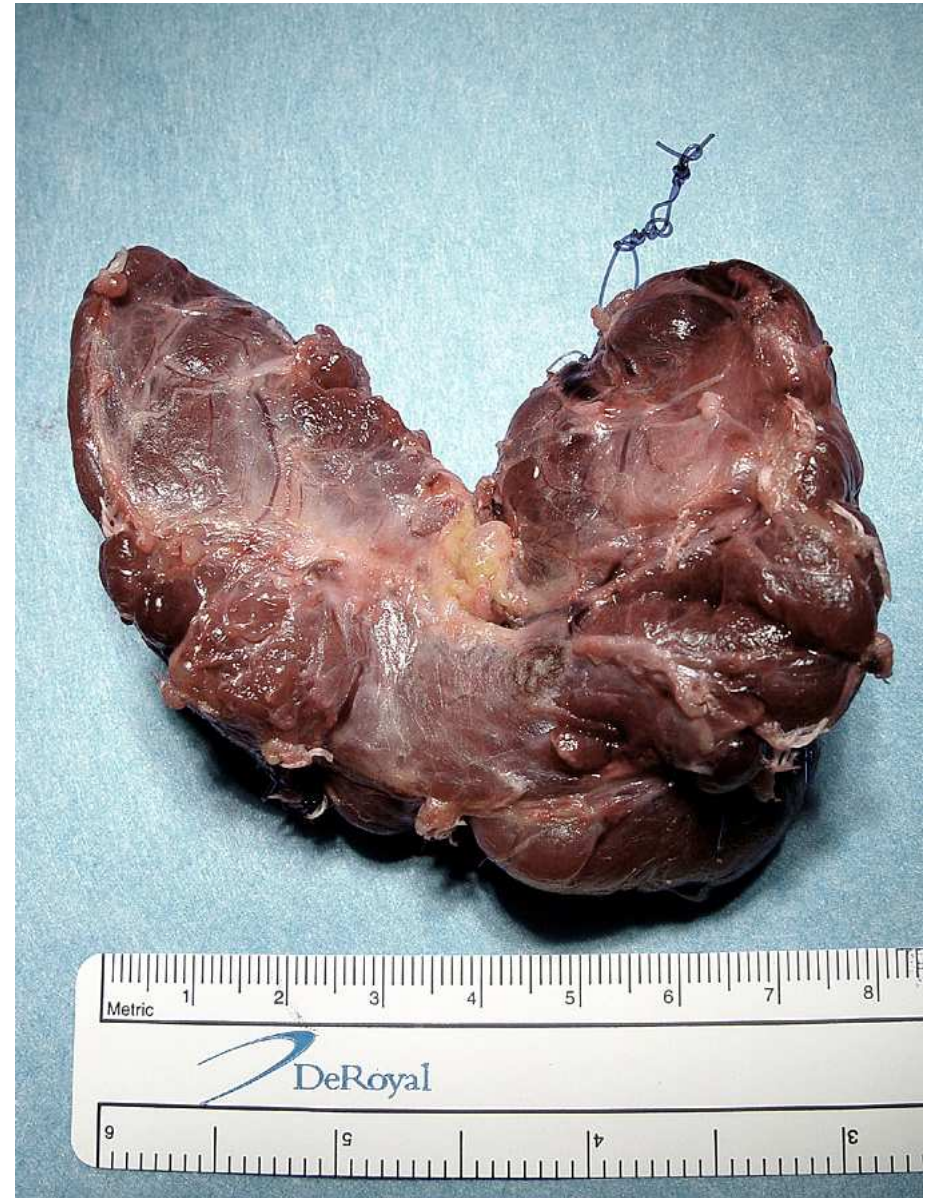
Tiroidectomia totale extracapsulare per carcinoma papillifero del lobo dx (T2 N0 G1)



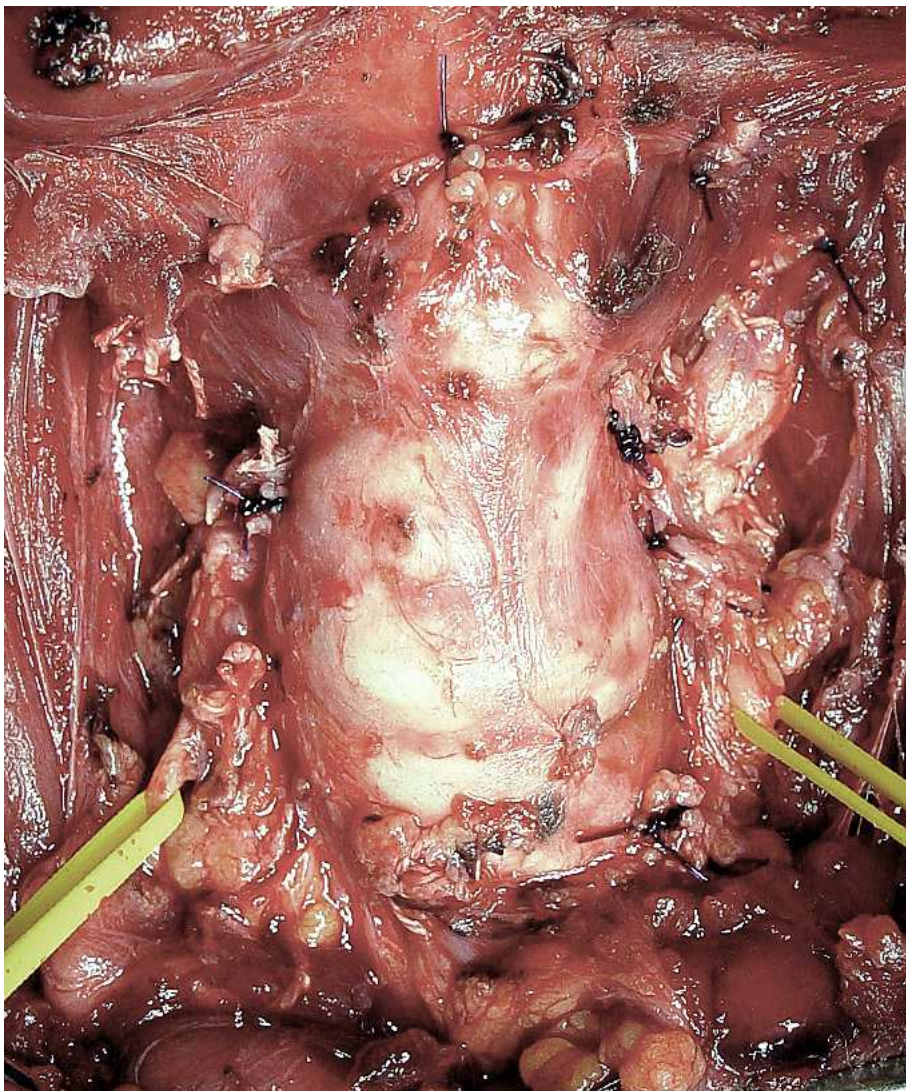
Isolamento dei nervi laringei inferiori (ricorrenti)



Lobo destro - Istmo - Lobo sinistro (superficie anteriore)

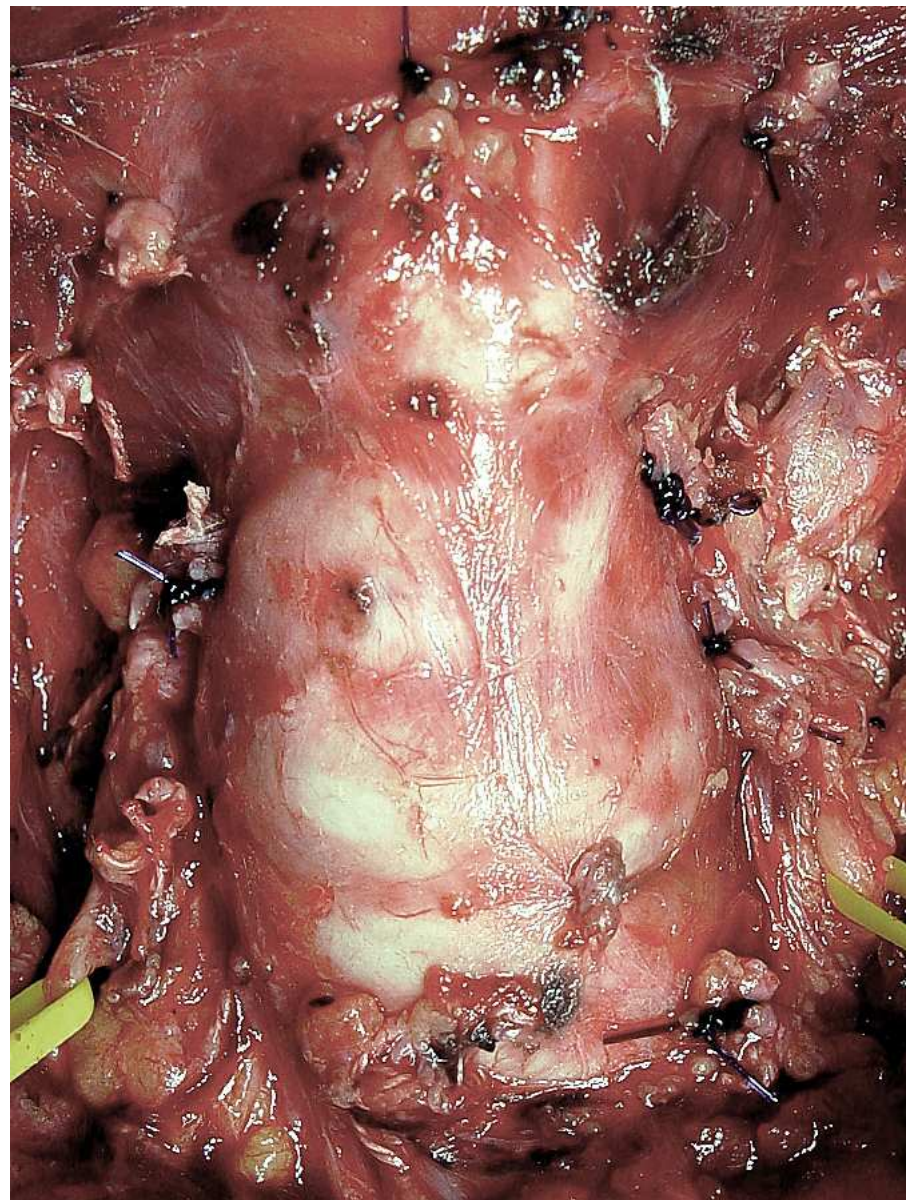


Lobo sinistro - Istmo - Lobo destro (superficie posteriore)

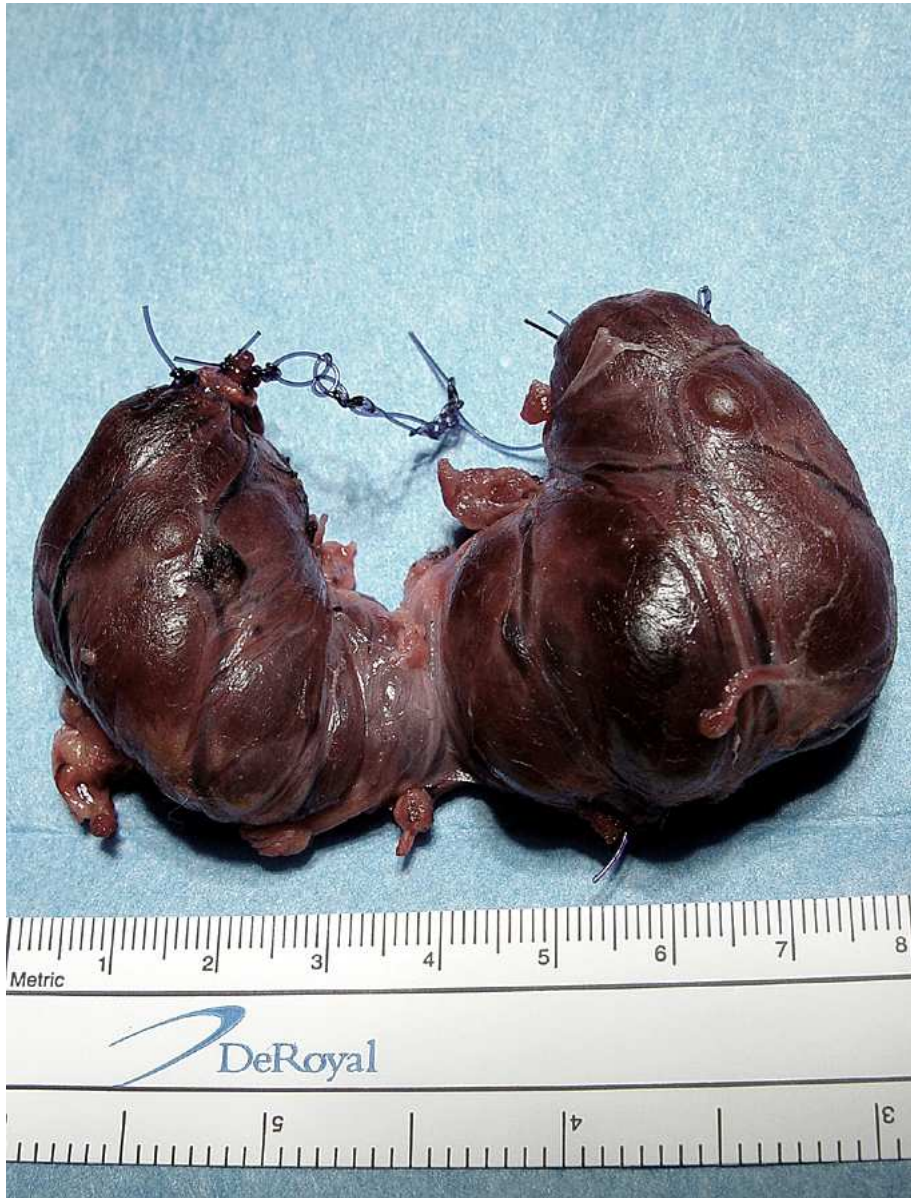

D.G. • Anni: 52 - M • Record: 67 • 09-07-2003

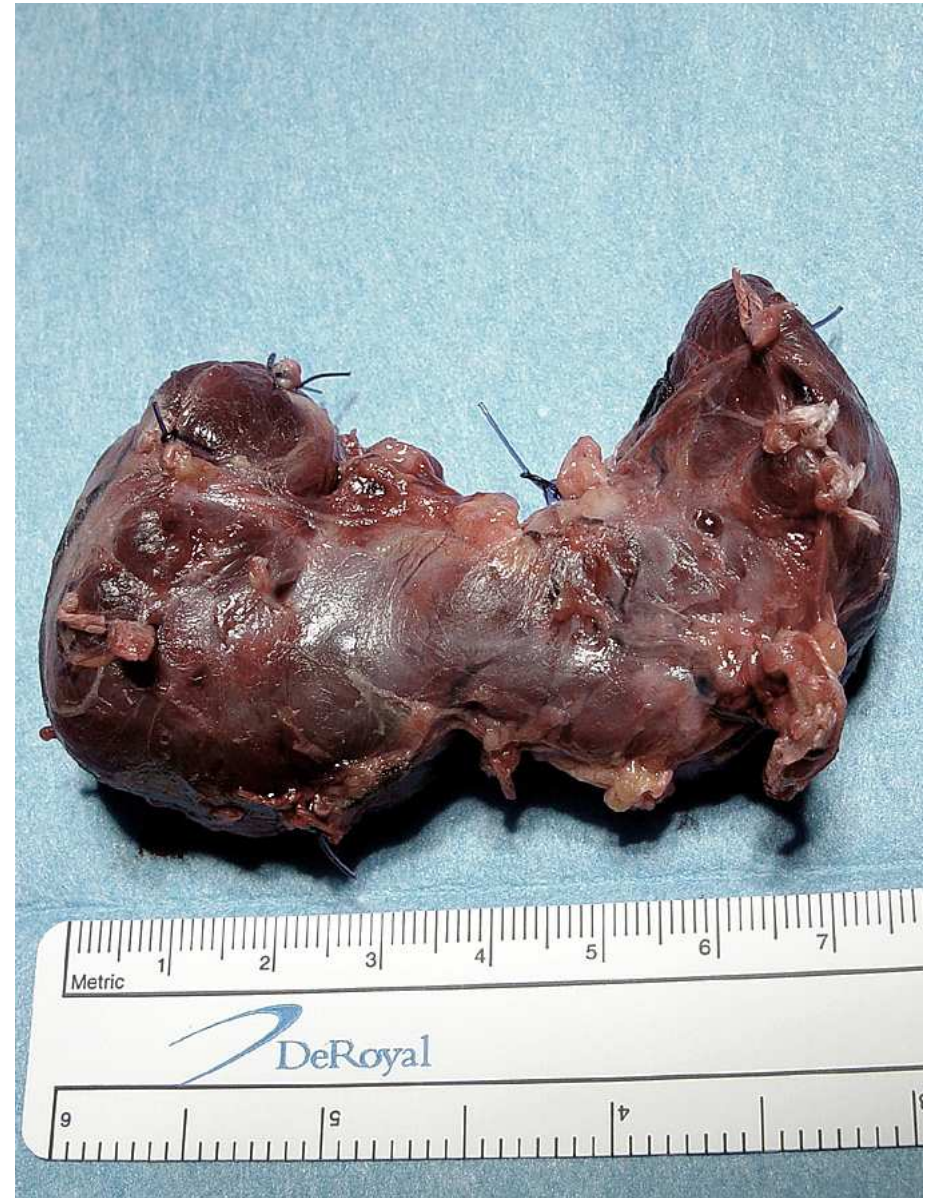Tiroidectomia totale extracapsulare per gozzo plurinodulare pretossico



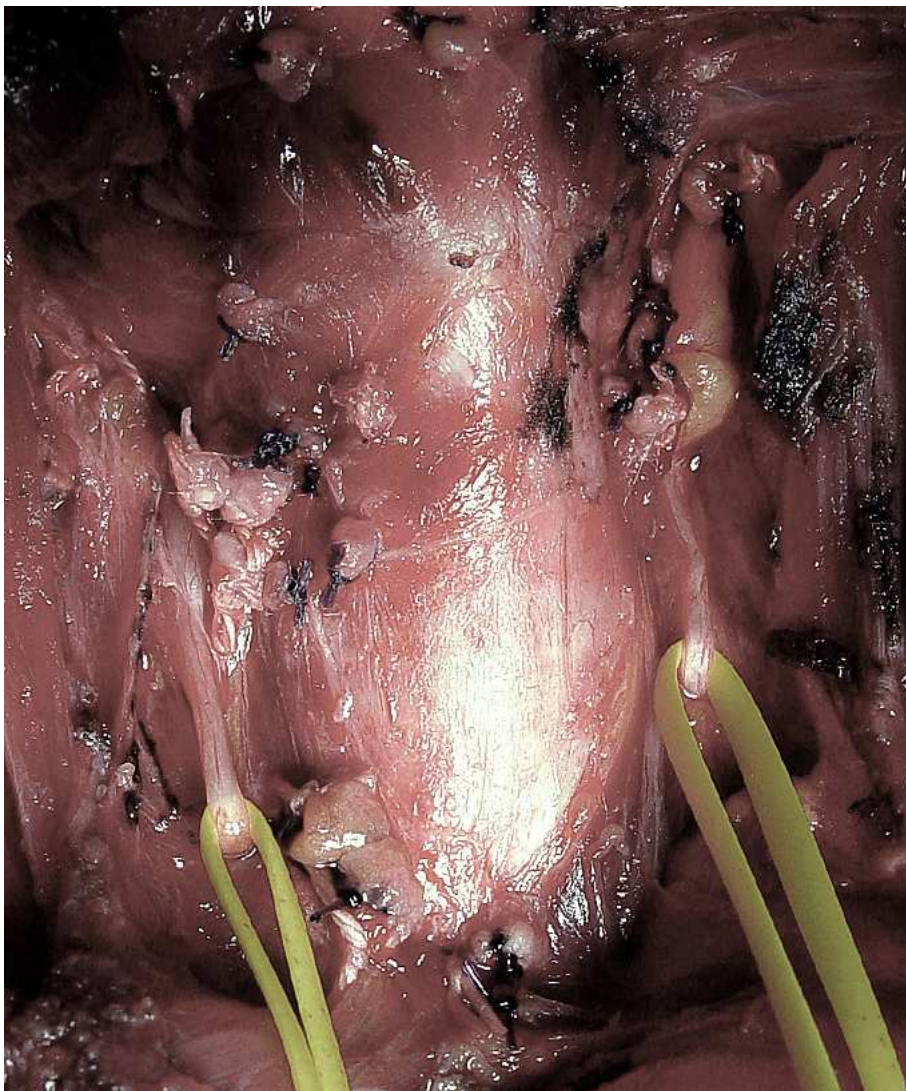
Isolamento dei nervi laringei inferiori (ricorrenti)



Lobo destro - Istmo - Lobo sinistro (superficie anteriore)

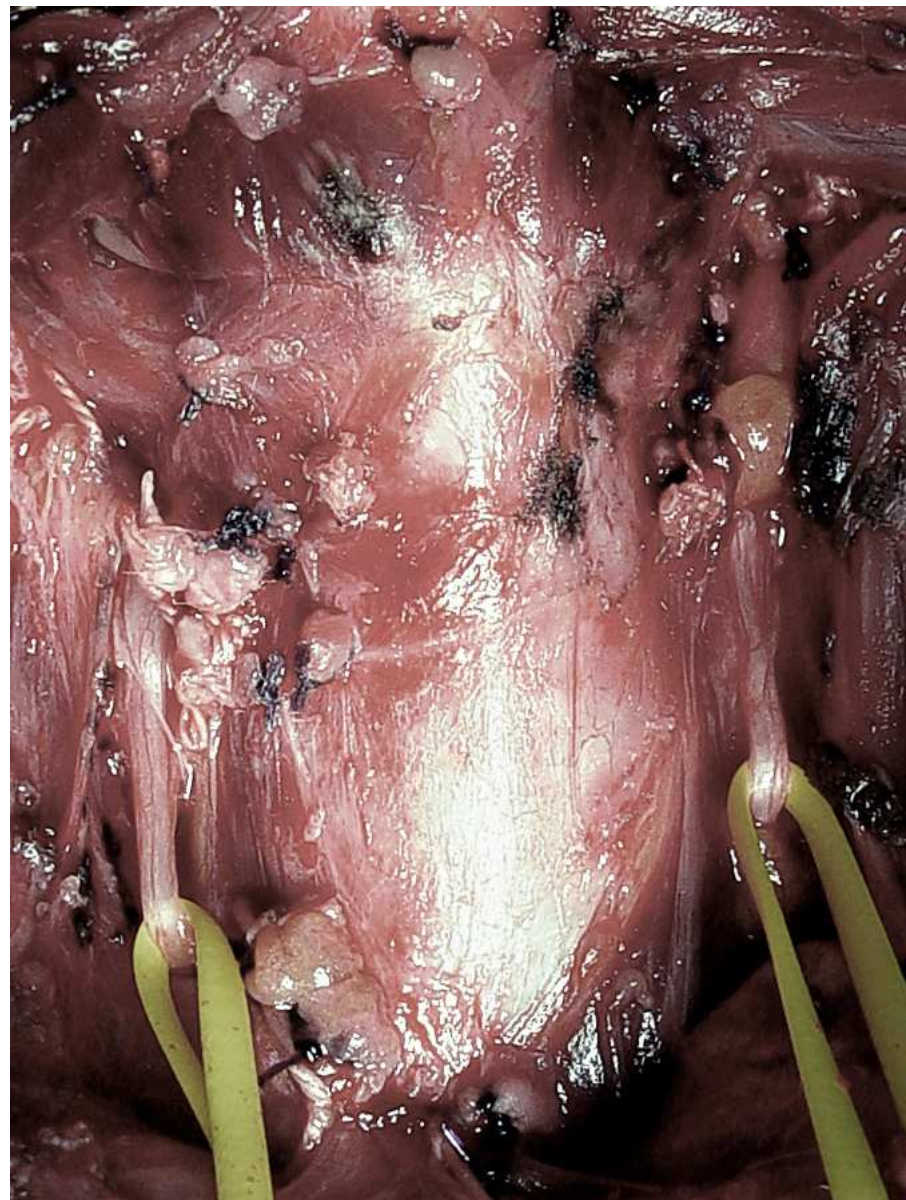


Lobo sinistro - Istmo - Lobo destro (superficie posteriore)

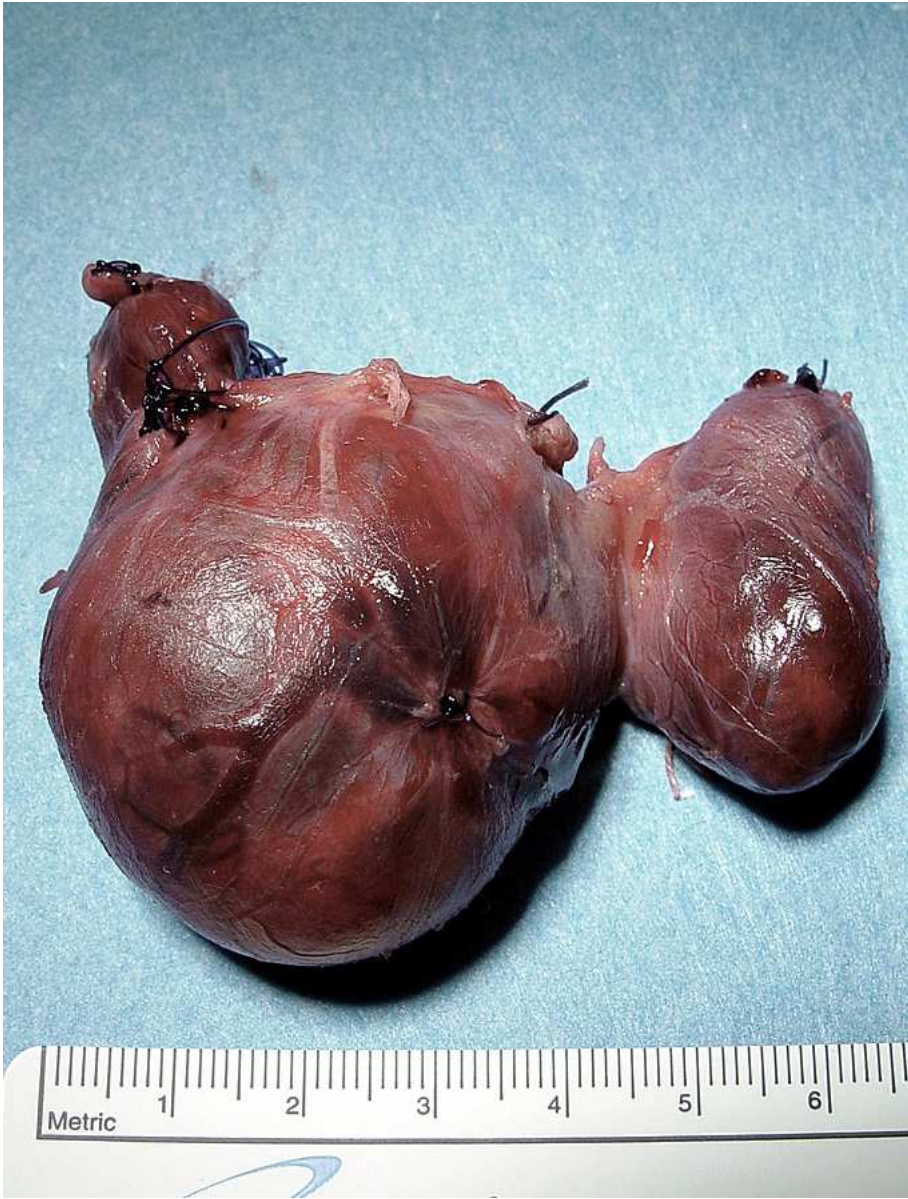


D.G.C. · Anni: 38 - F · Record: 68 · 11-07-2003

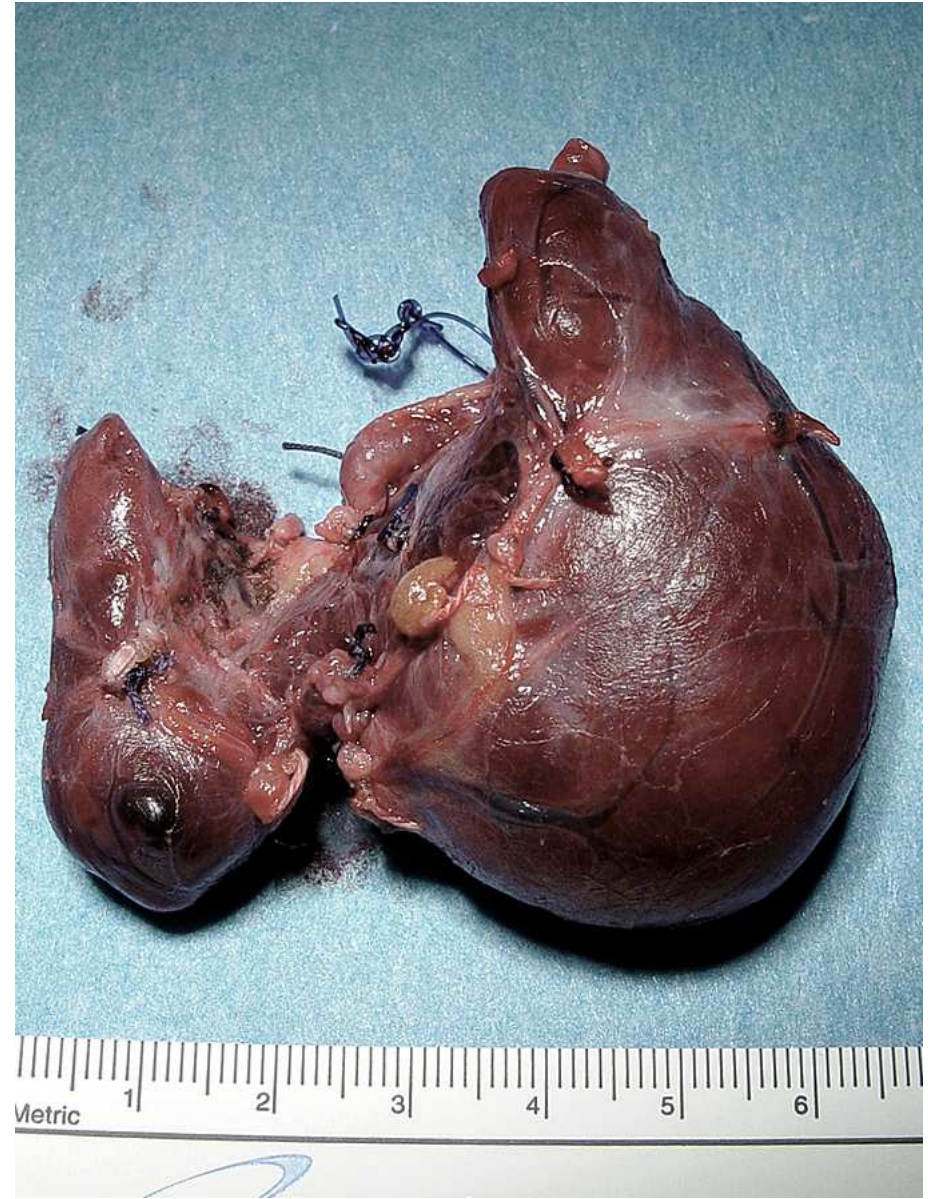
Tiroidectomia totale extracapsulare per microcarcinoma papillifero del lobo dx in gozzo plurinodulare plongeant (pT1a)



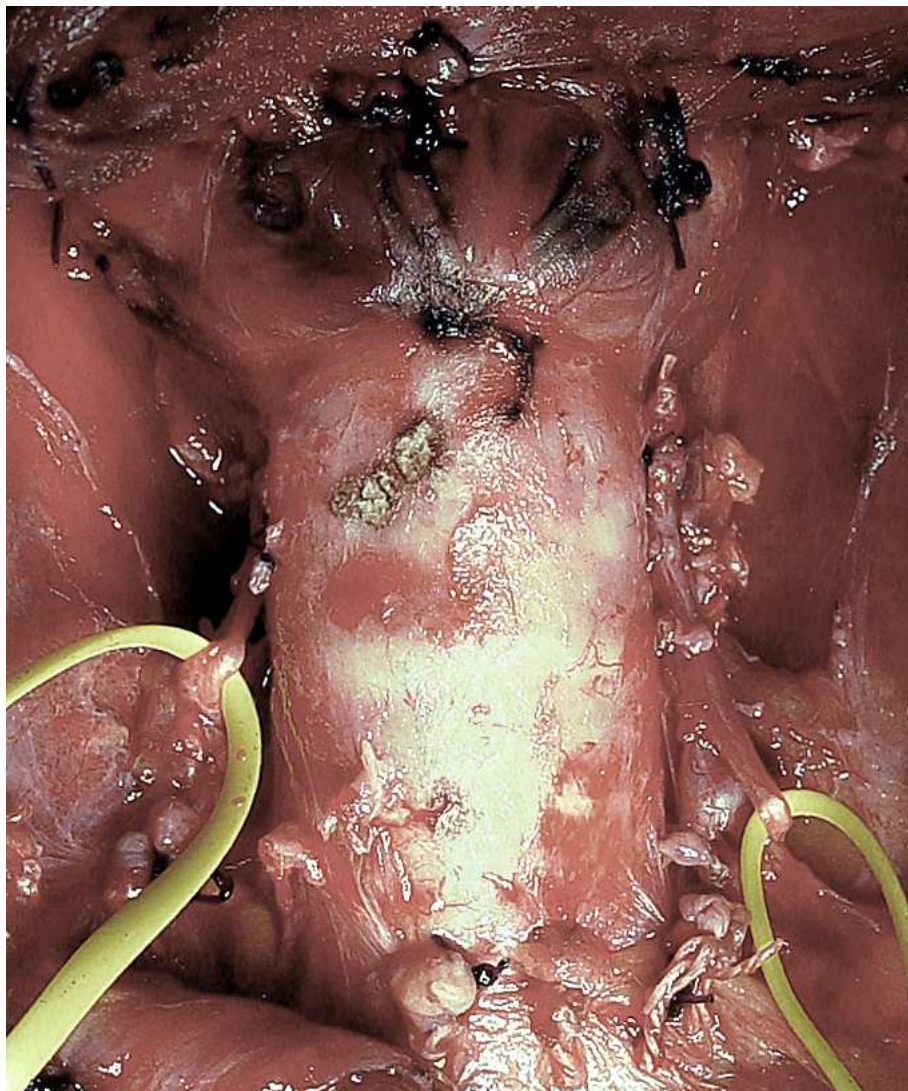
Isolamento dei nervi laringei inferiori (ricorrenti)



Lobo destro - Istmo - Lobo sinistro (superficie anteriore)

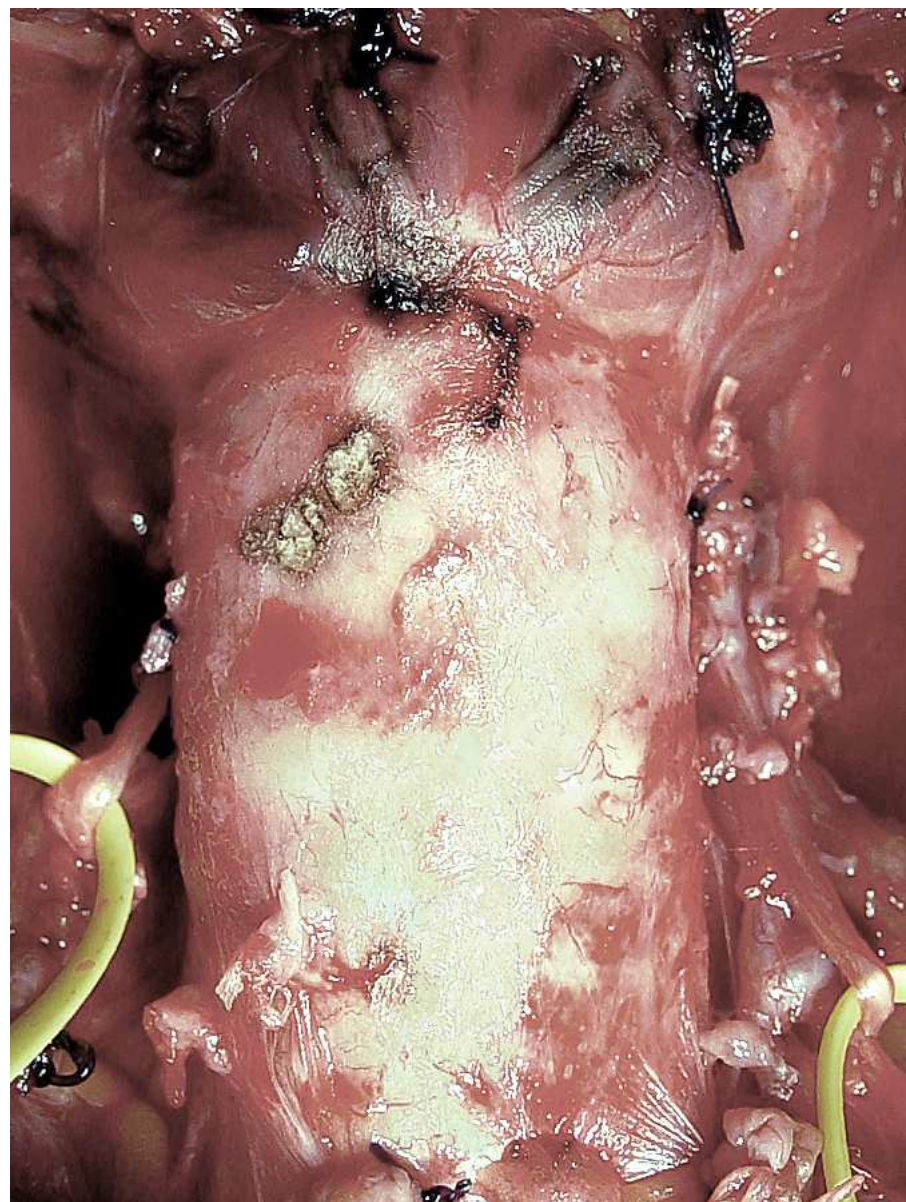


Lobo sinistro - Istmo - Lobo destro (superficie posteriore)



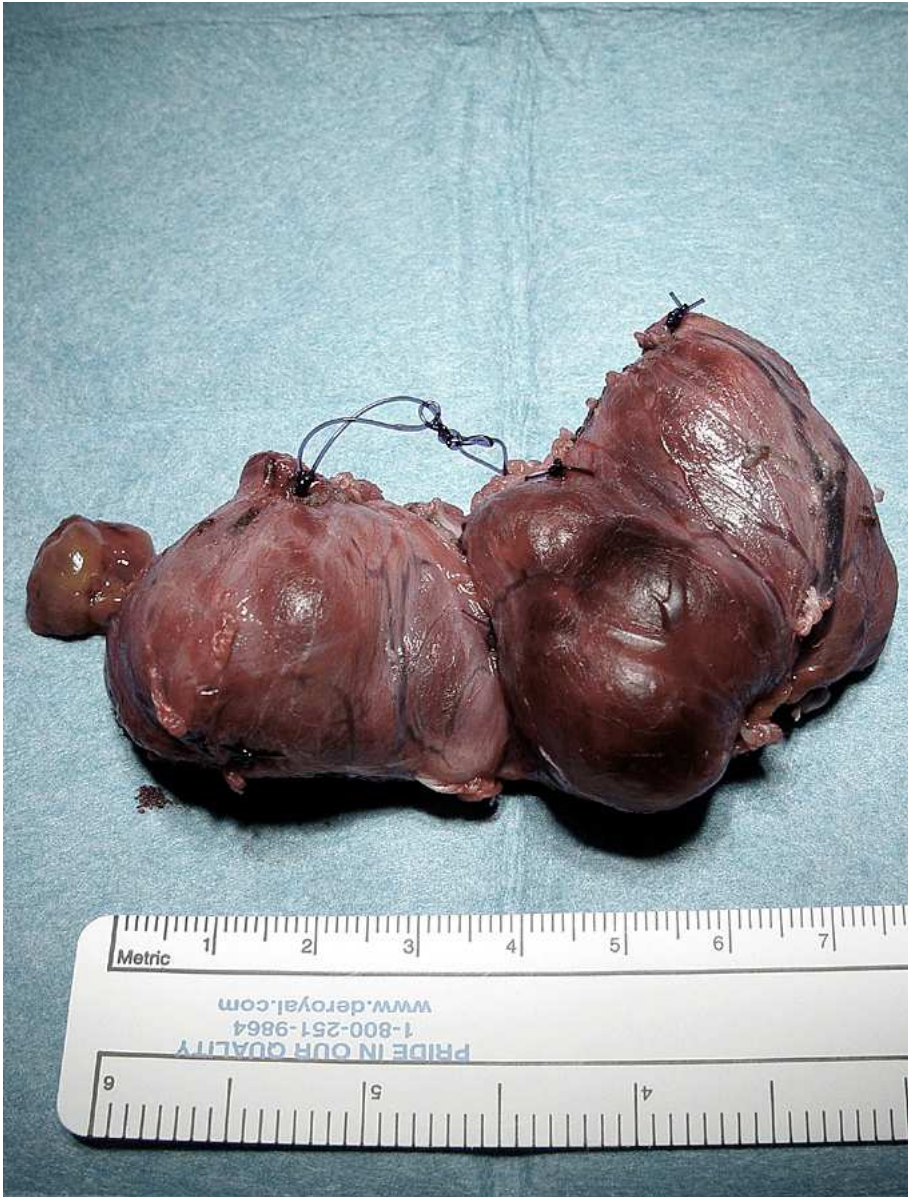L.N. • Anni: 38 - F • Record: 69 • 16-07-2003

Tiroidectomia totale extracapsulare per gozzo plurinodulare e paratiroidectomia superiore destra per adenoma

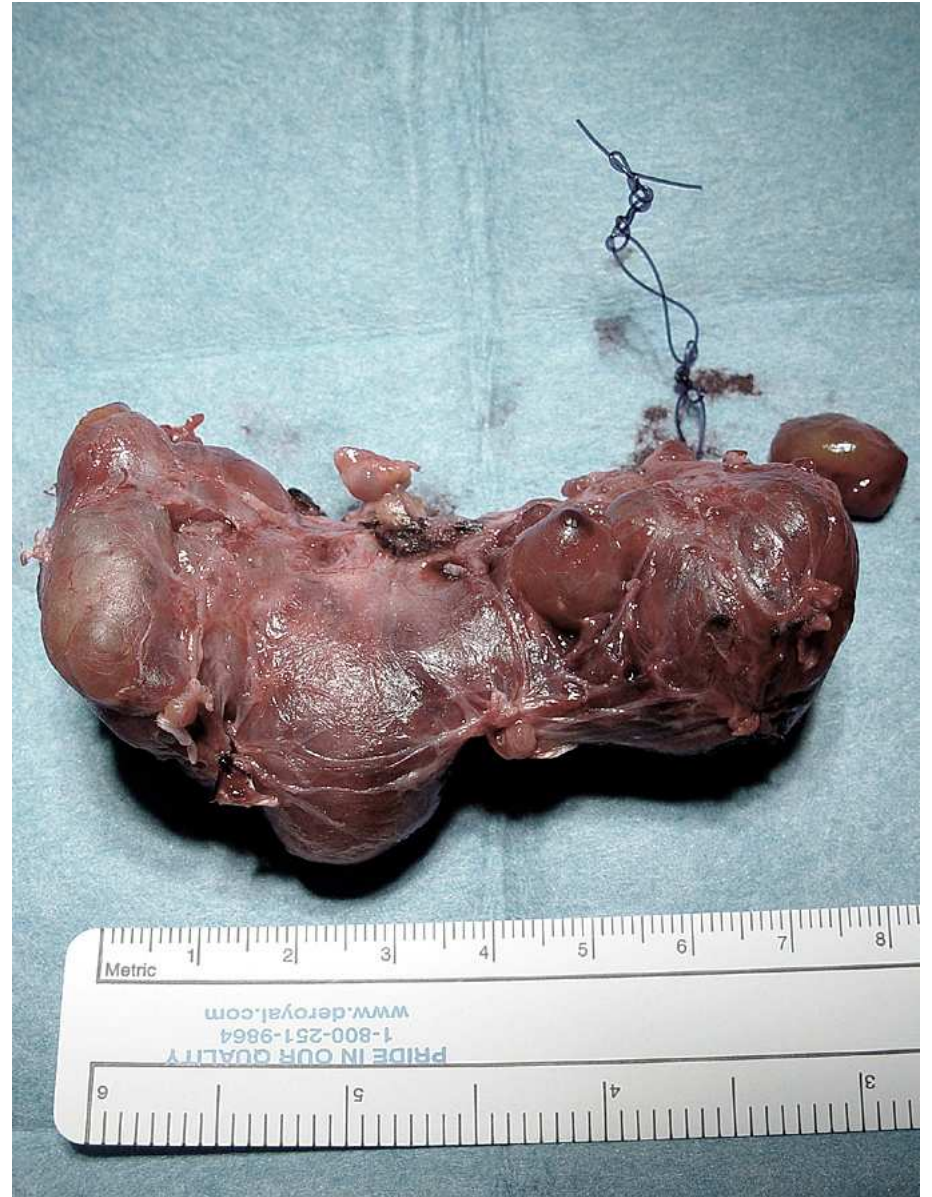

Isolamento dei nervi laringei inferiori (ricorrenti)

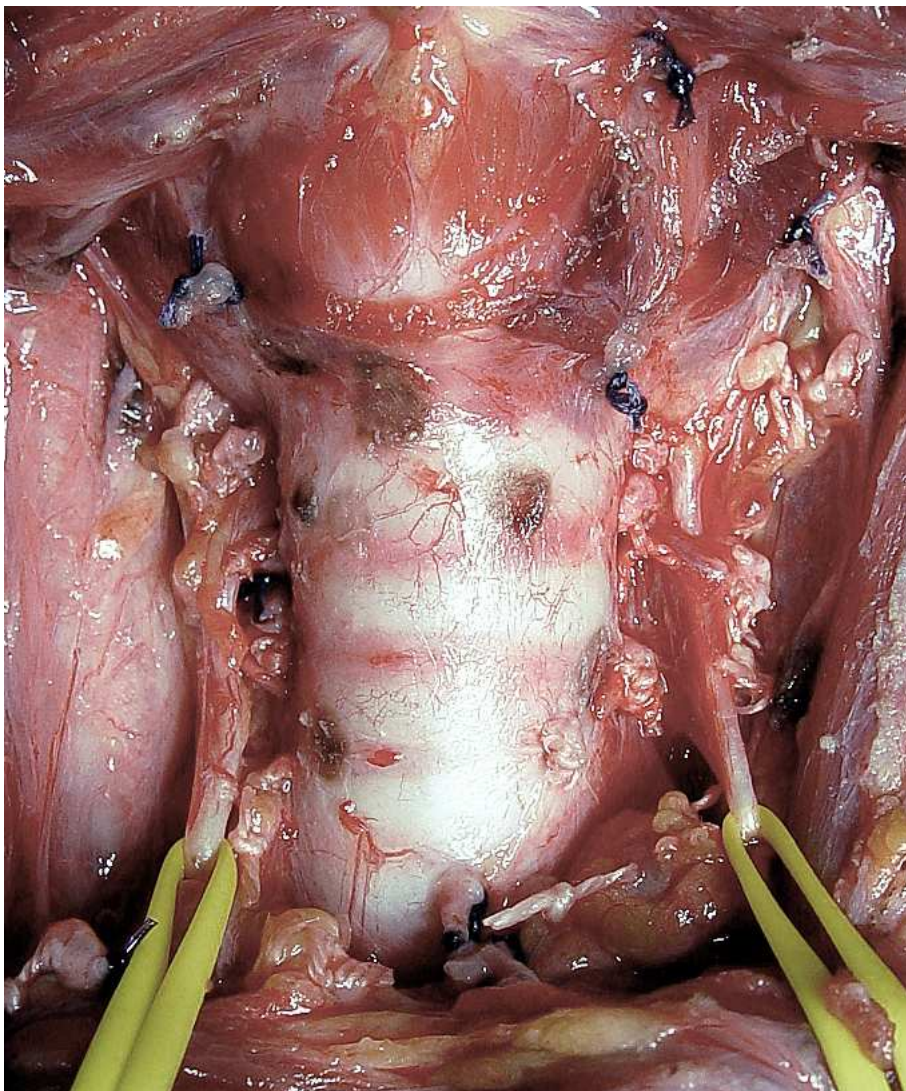




Lobo destro - Istmo - Lobo sinistro (superficie anteriore)

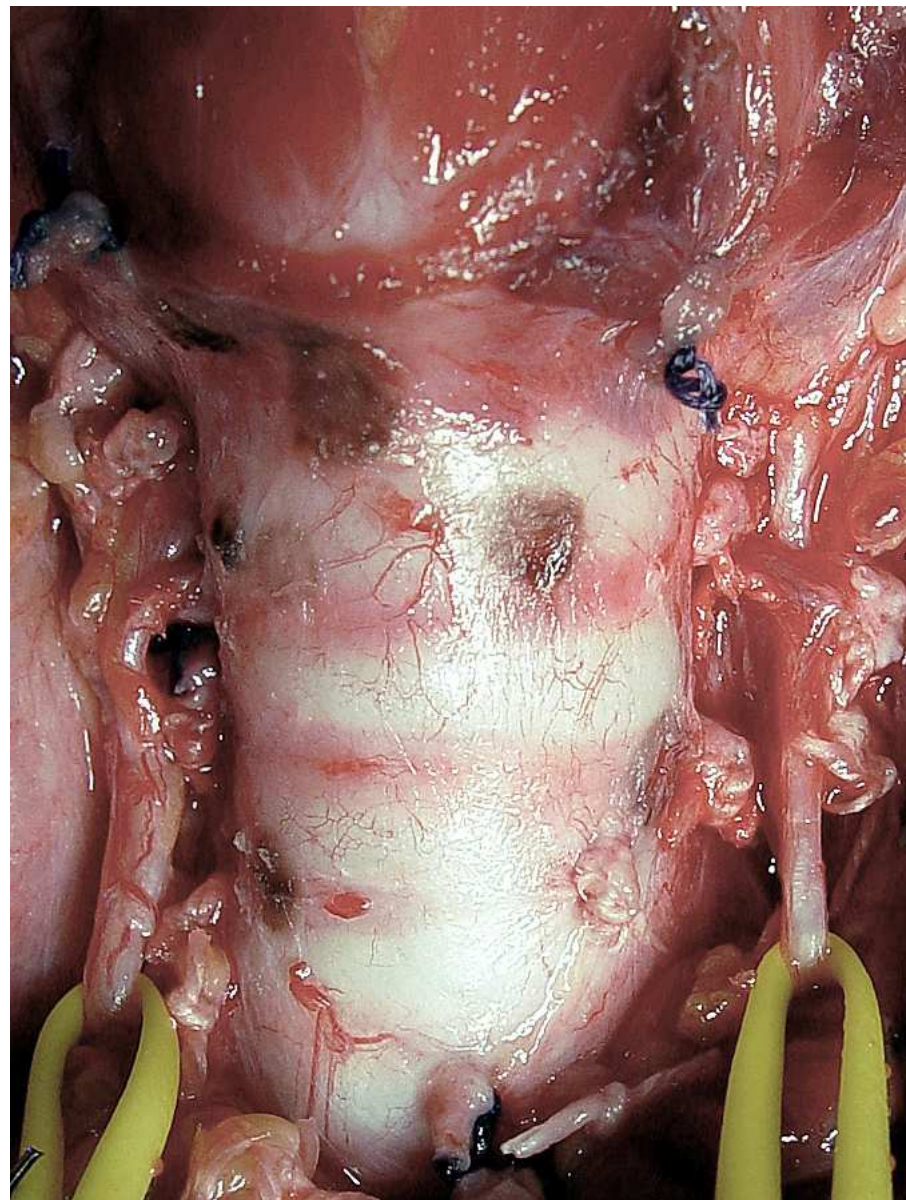


Lobo sinistro, Istmo e Lobo destro della tiroide - Paratiroide (superficie posteriore)

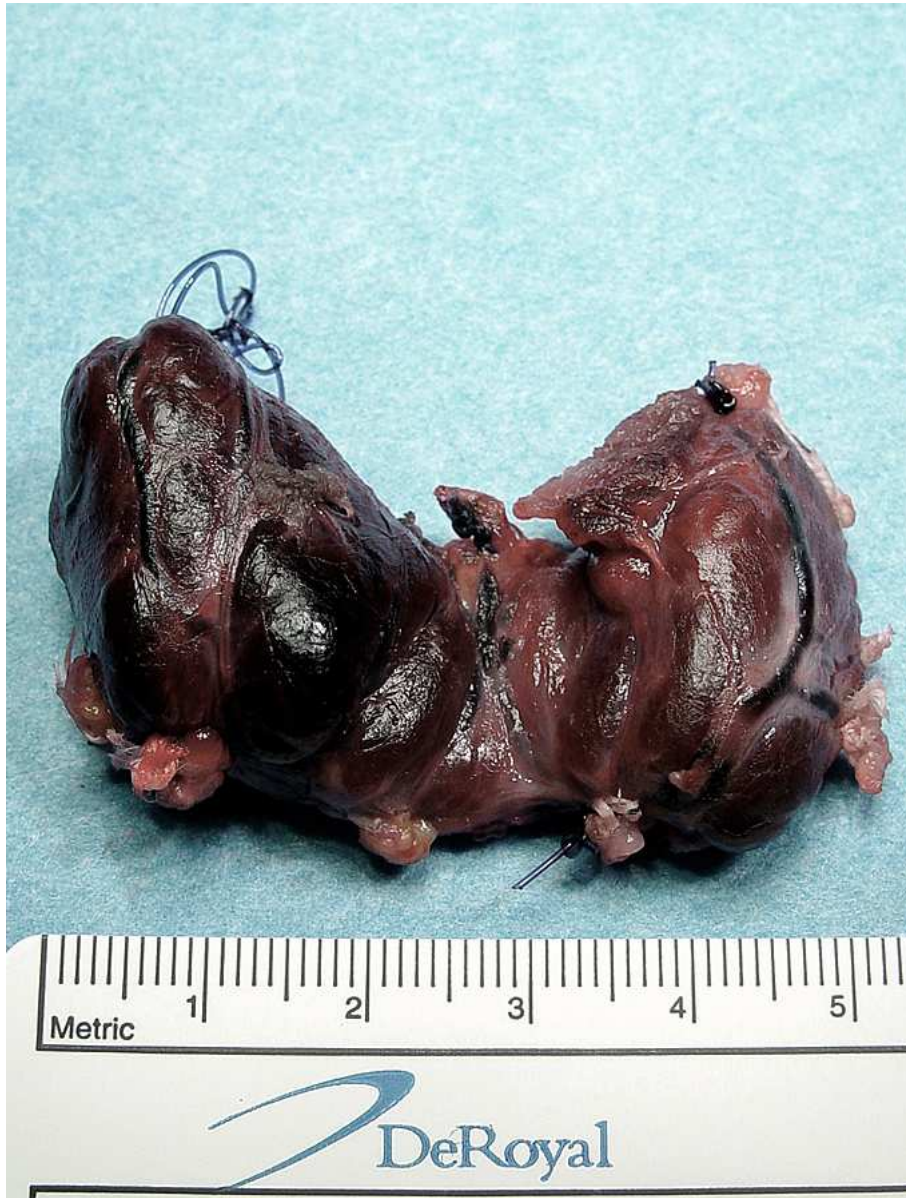

R.S. · Anni: 35 - F · Record: 70 · 31-07-2003

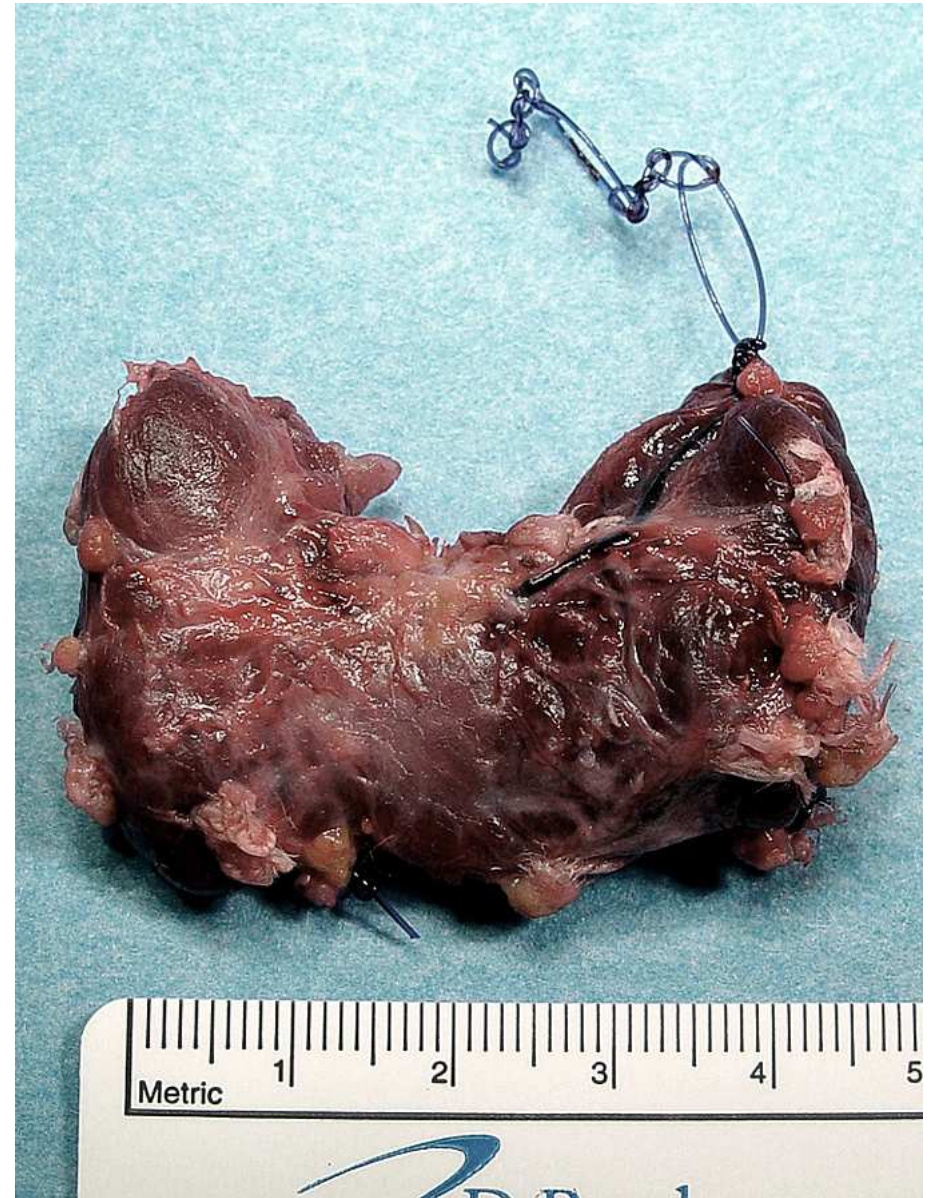
Tiroidectomia totale extracapsulare per carcinoma papillare variante follicolare multifocale del lobo sinistro in gozzo adenomatoso e tiroidite linfocitaria



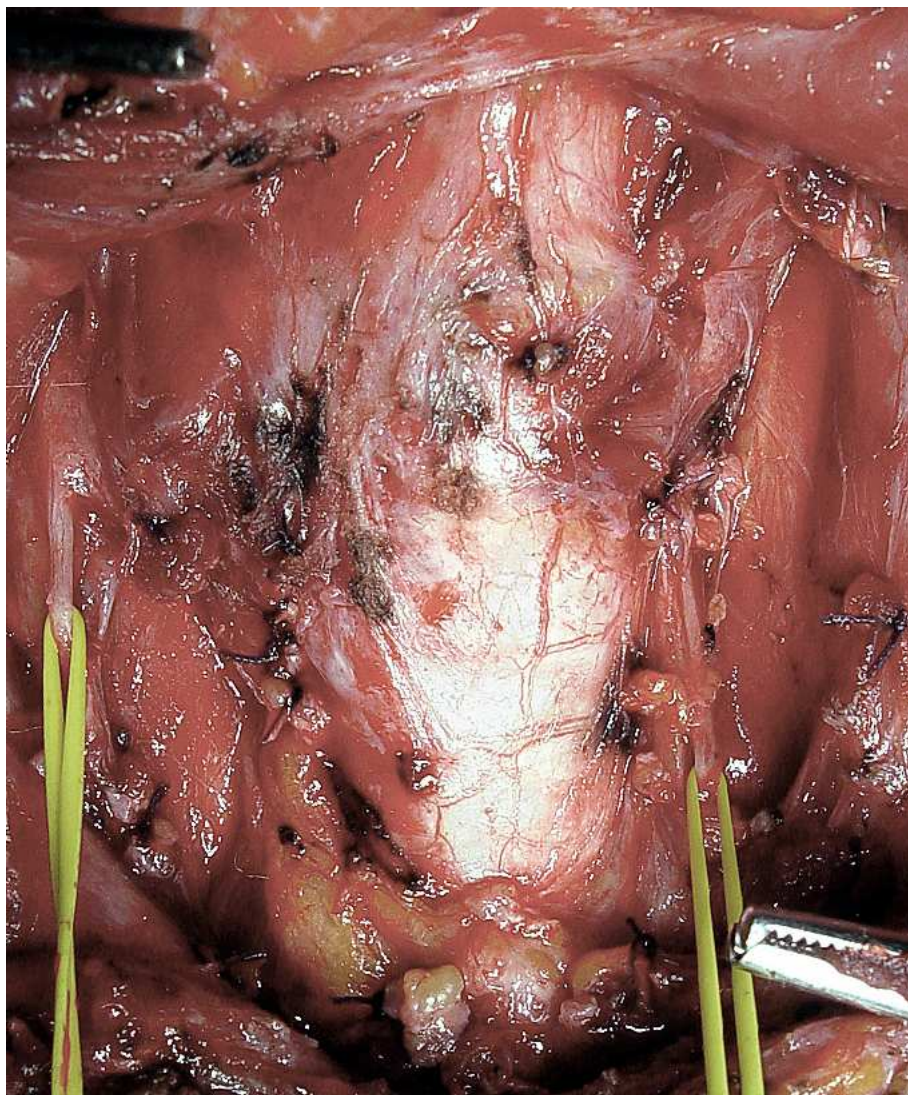
Isolamento dei nervi laringei inferiori (ricorrenti)



Lobo sinistro - Istmo - Lobo destro (superficie anteriore)

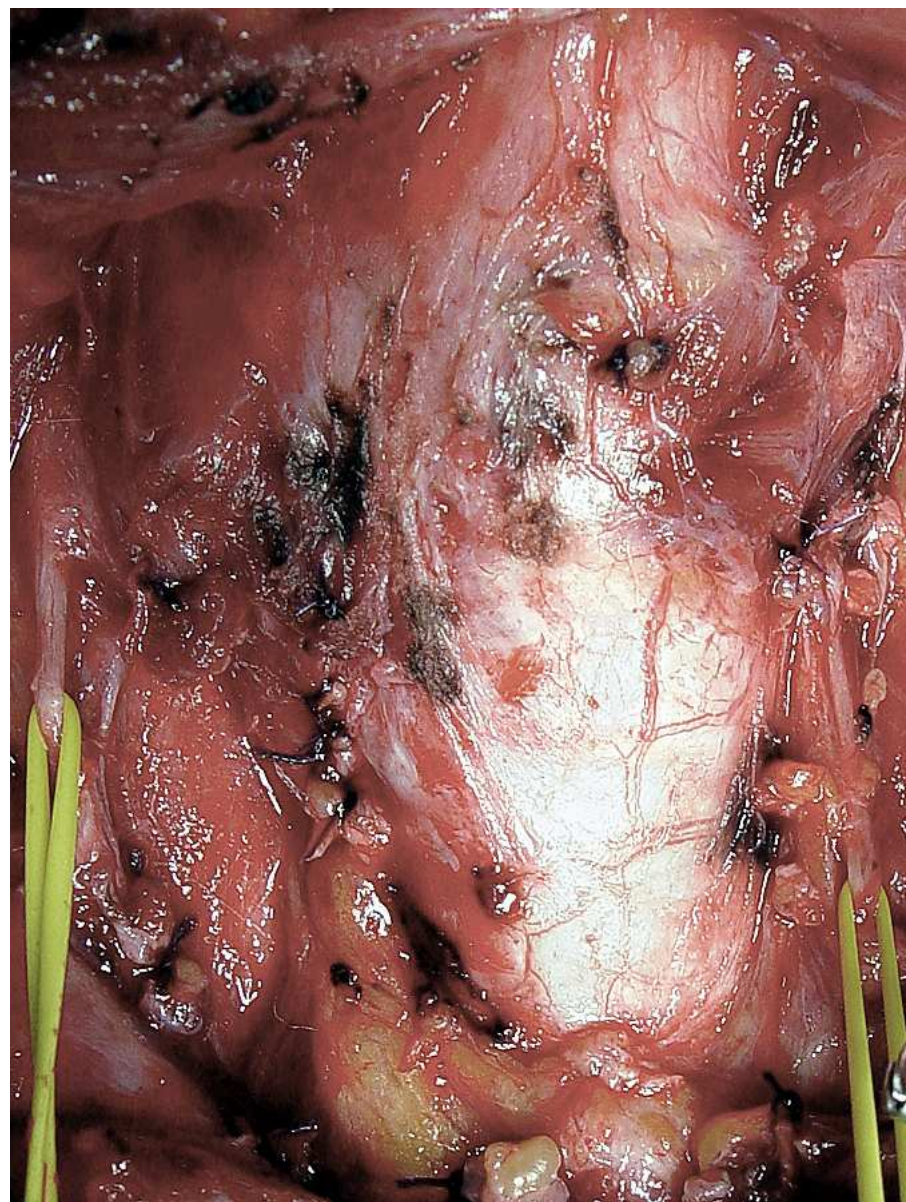

Lobo sinistro - Istmo - Lobo destro (superficie posteriore)

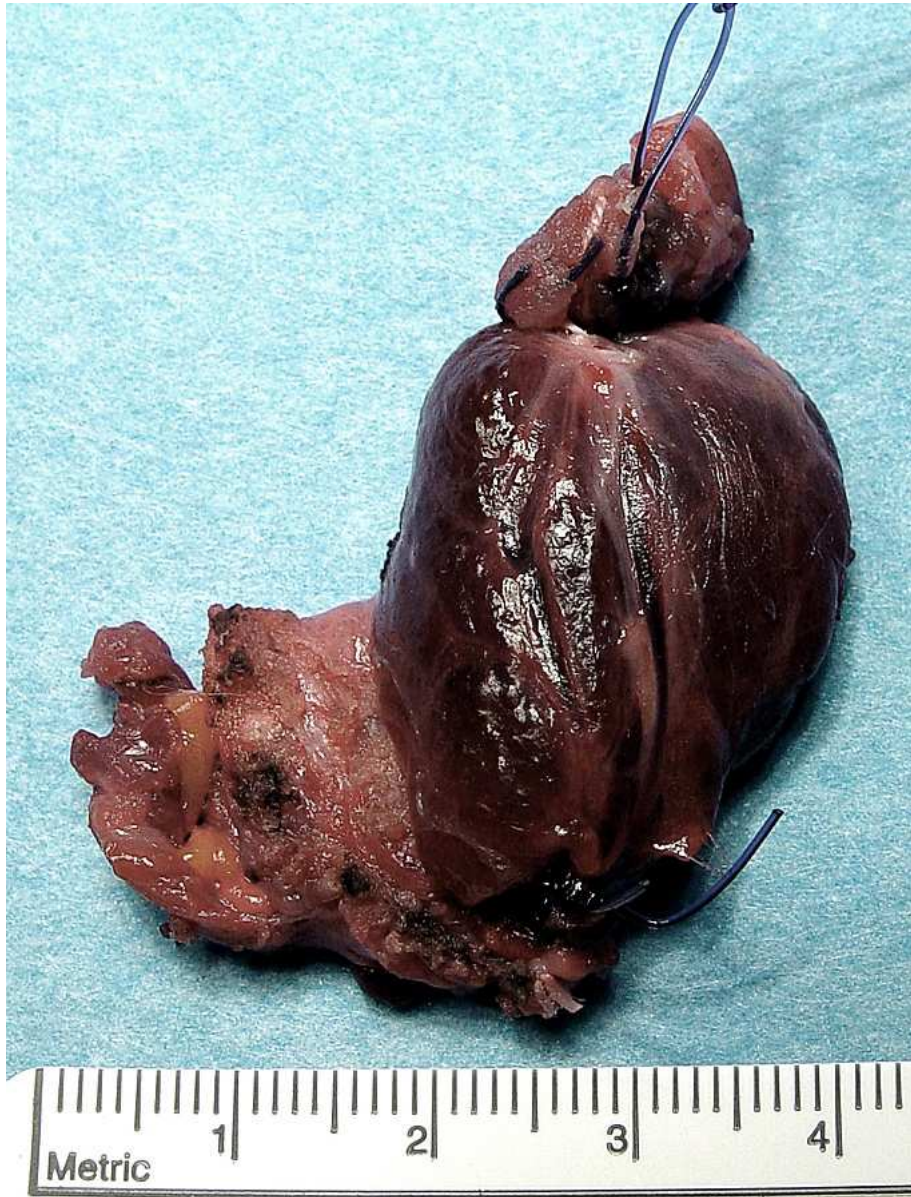

P.M. · Anni: 39 - F · Record: 71 · 24-09-2003

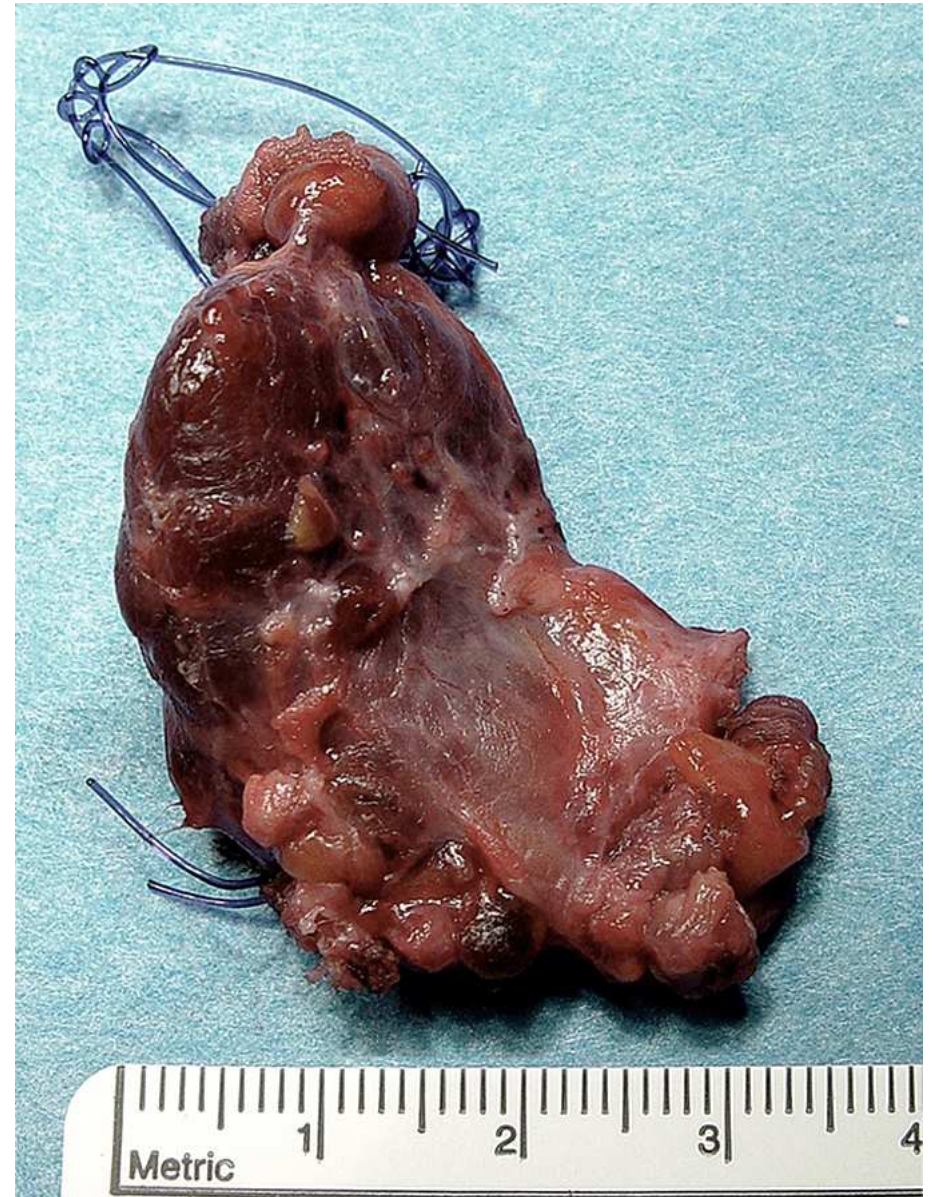
Radicalizzazione tiroidea per tiroidite linfocitaria post-lobectomia dx per neoplasia follicolare a cellule di Hürthle



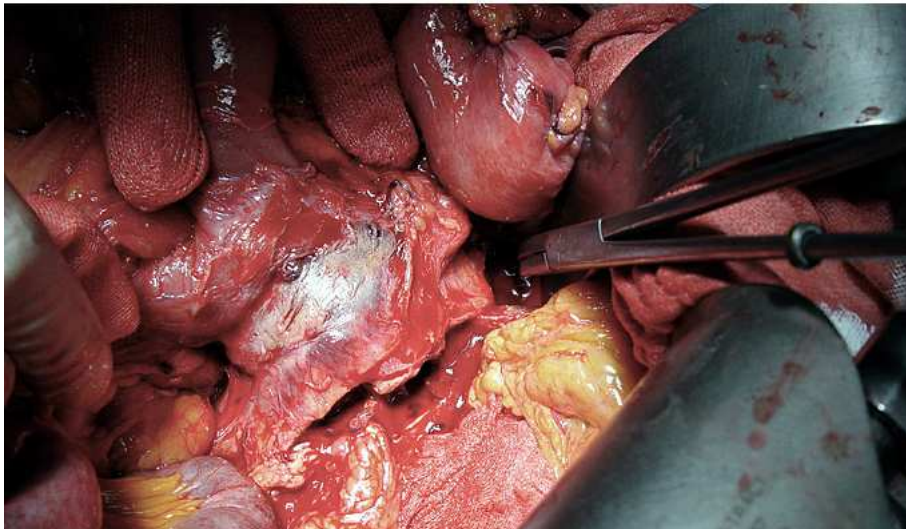
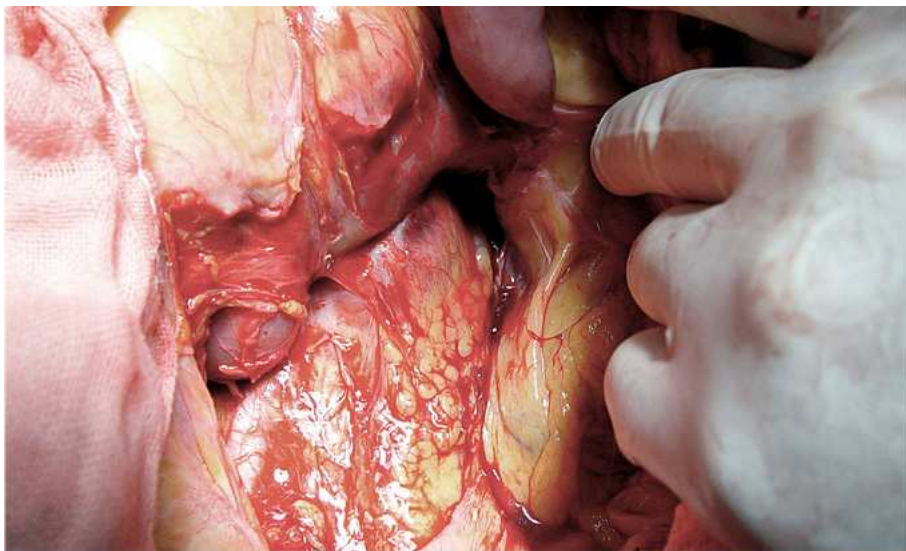
Isolamento dei nervi laringei inferiori (ricorrenti)



Istmo - Lobo sinistro (superficie anteriore)

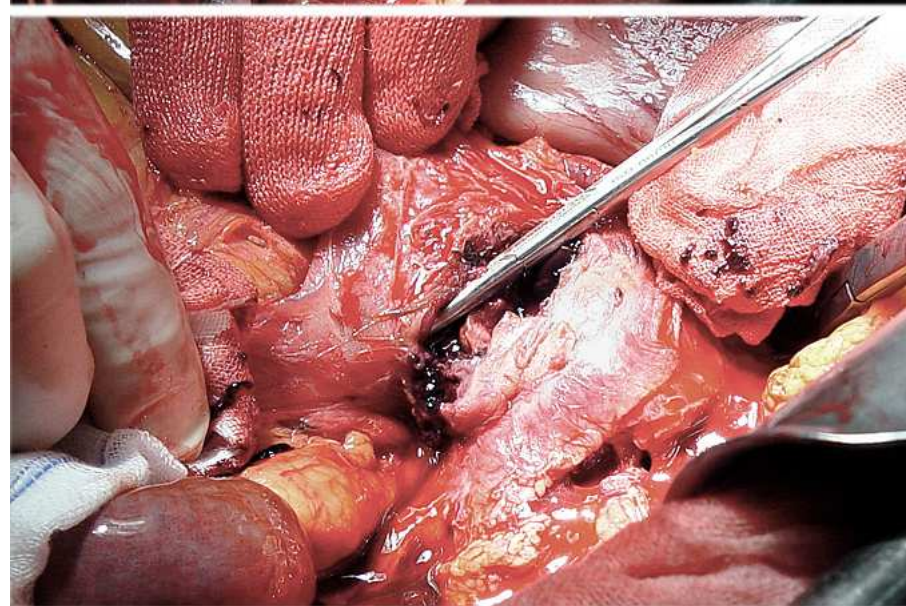
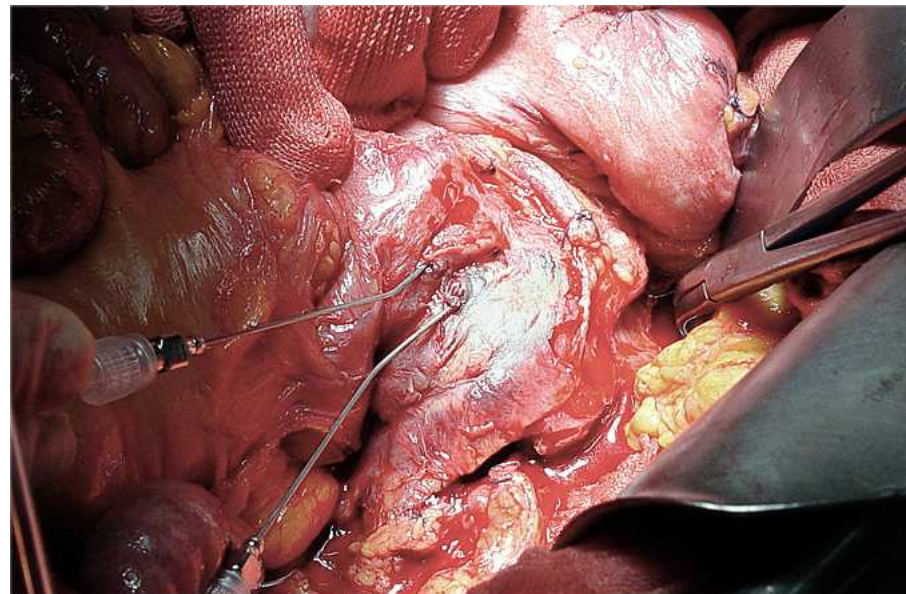


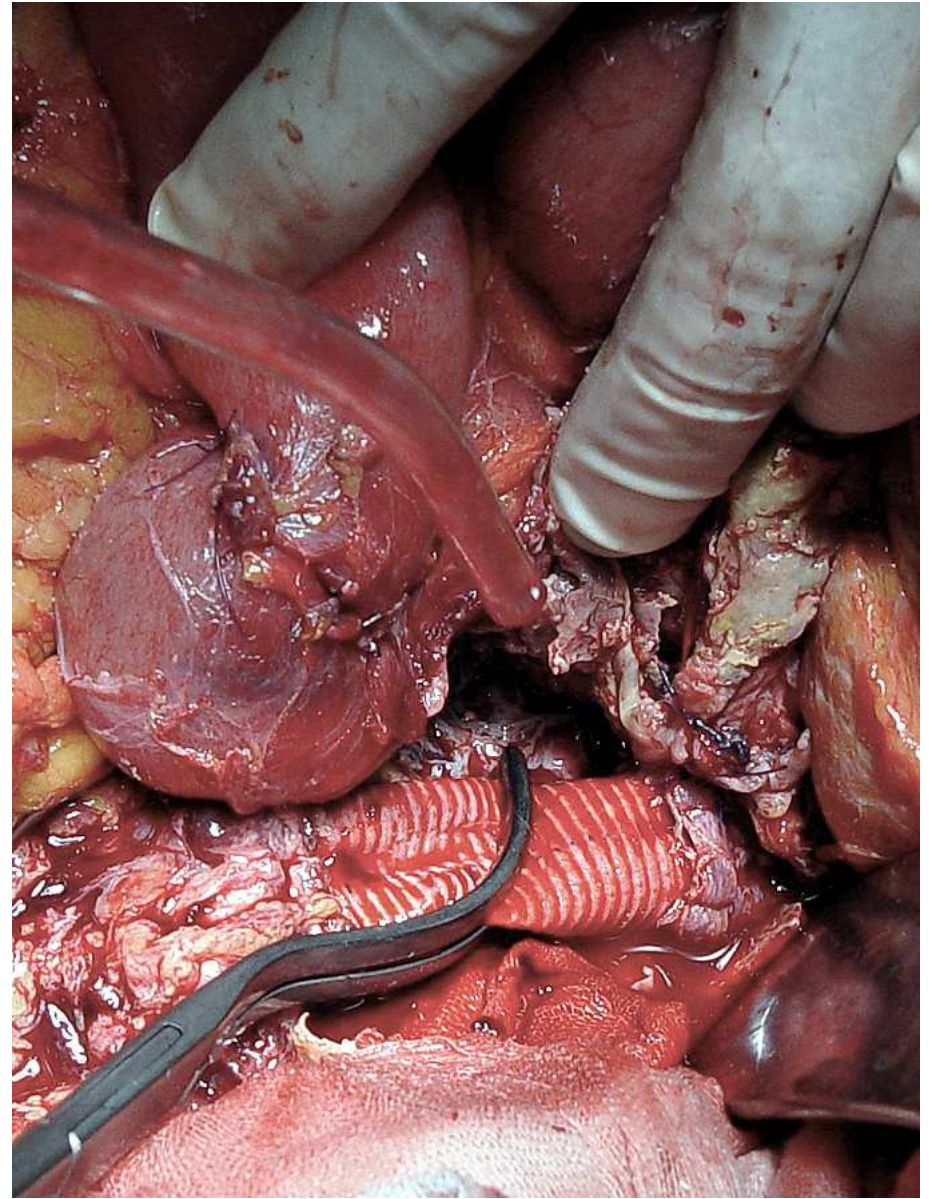
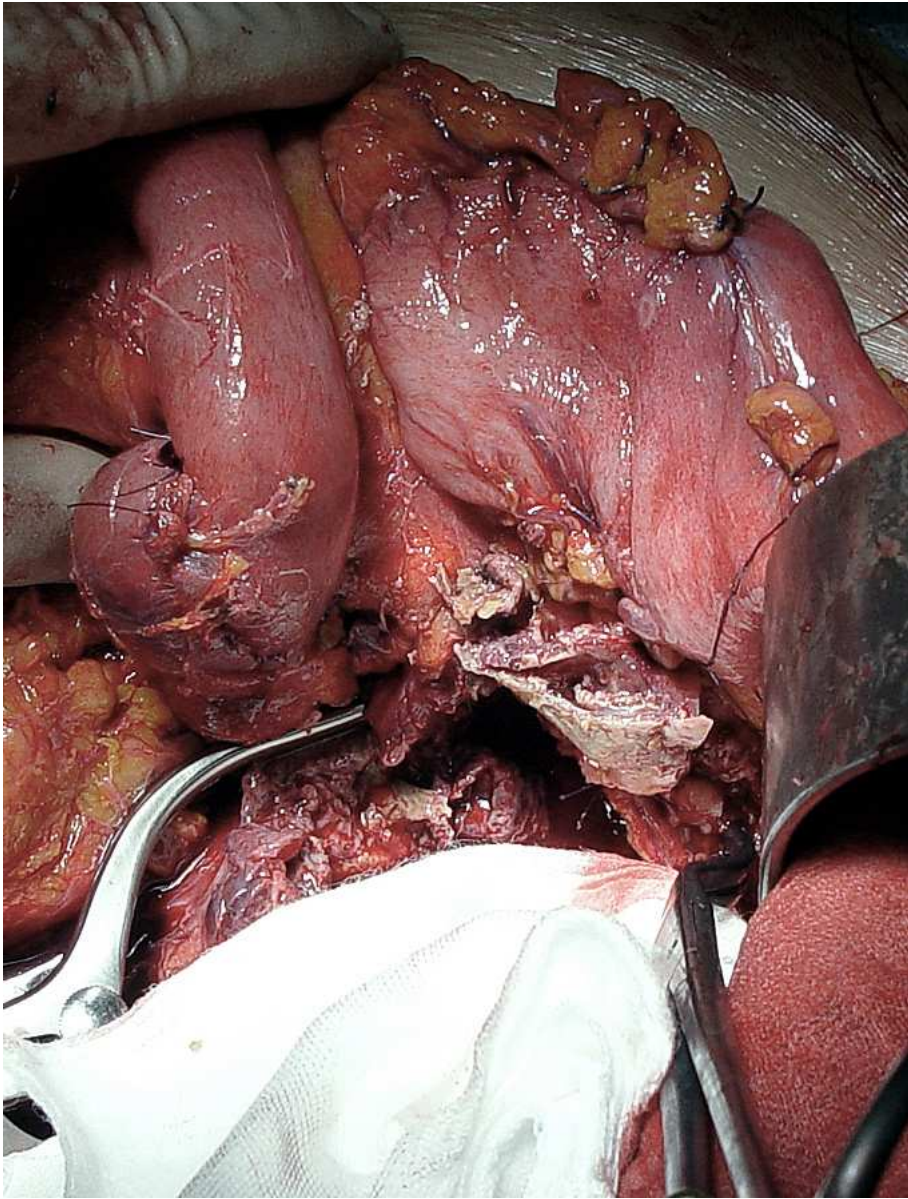
Lobo sinistro - Istmo (superficie posteriore)

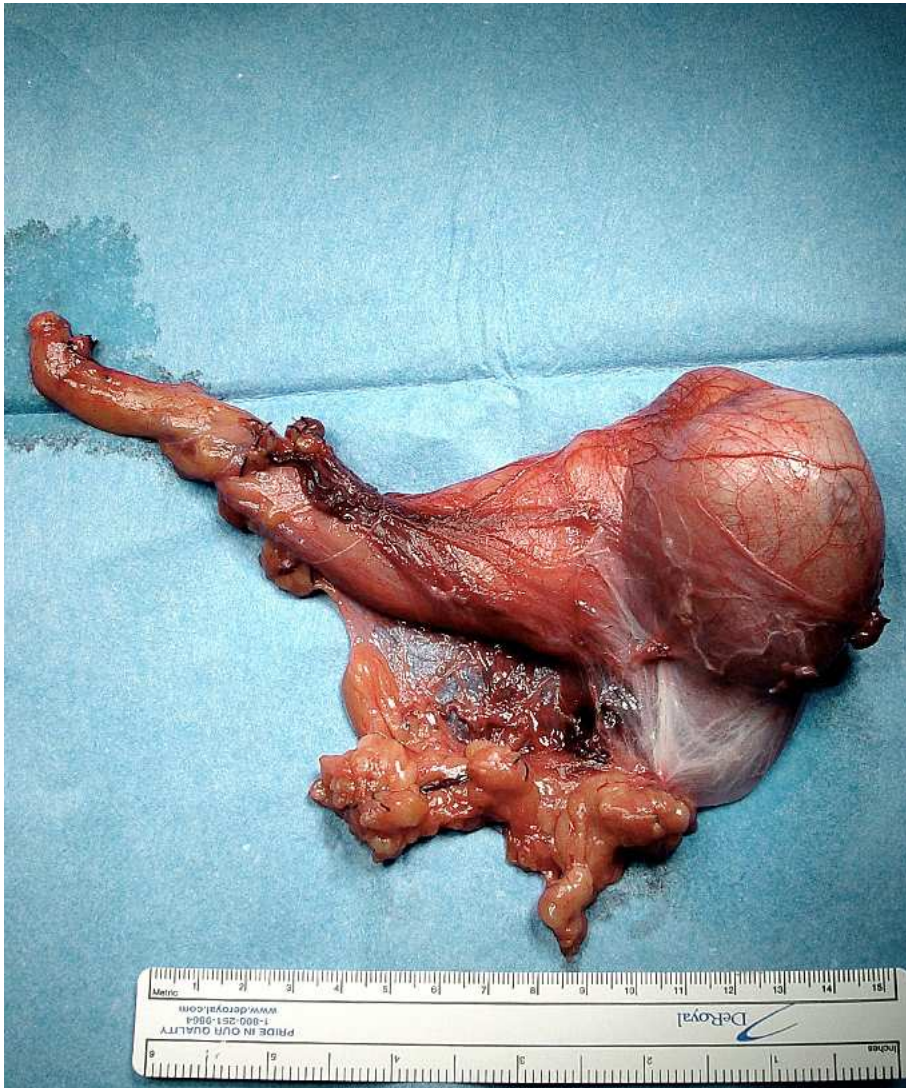

G.A.L. · Anni: 75 - F  Record: 72 · 06-10-2003

Duodenorrafia in corso di innesto aorto-aortico per grave stato di shock emorragico da fistola aorto-enterica

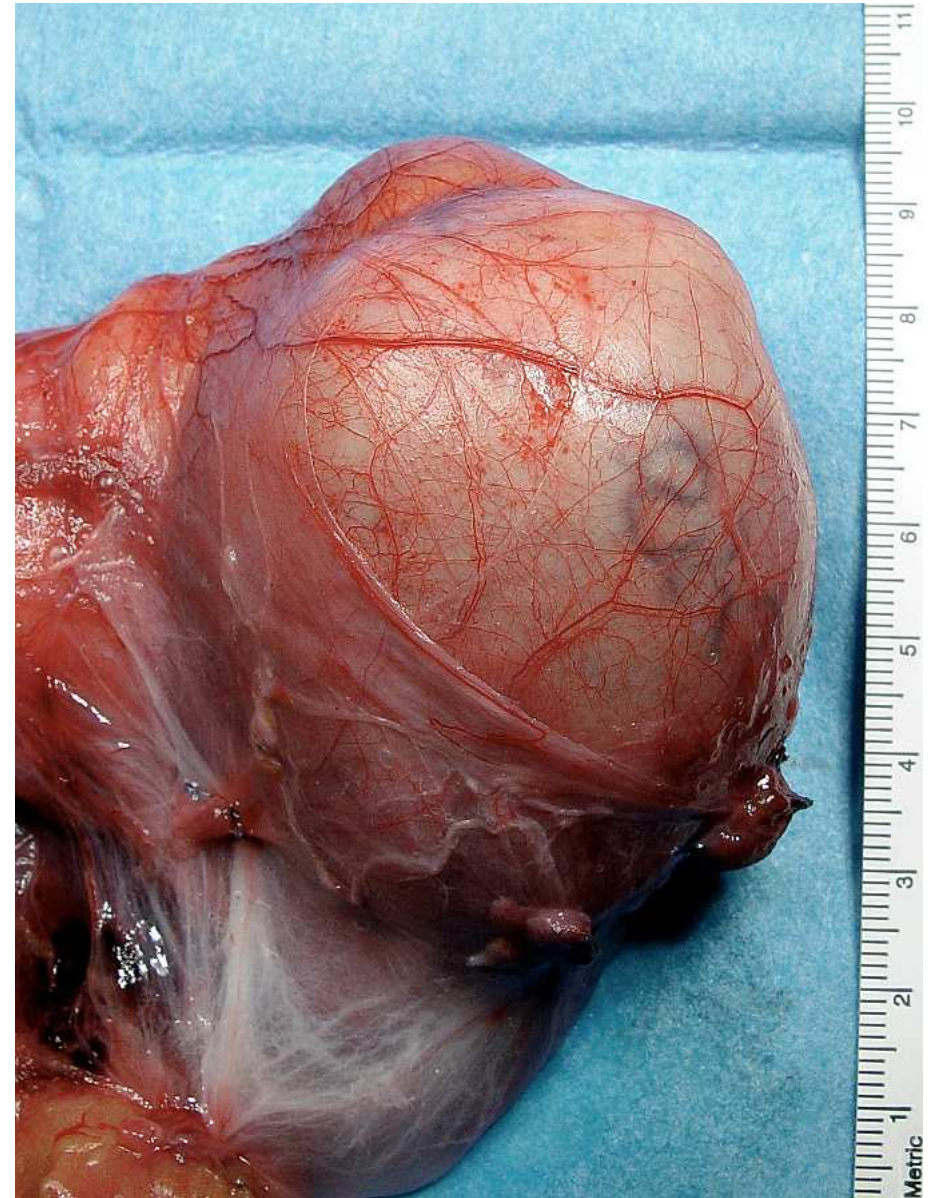




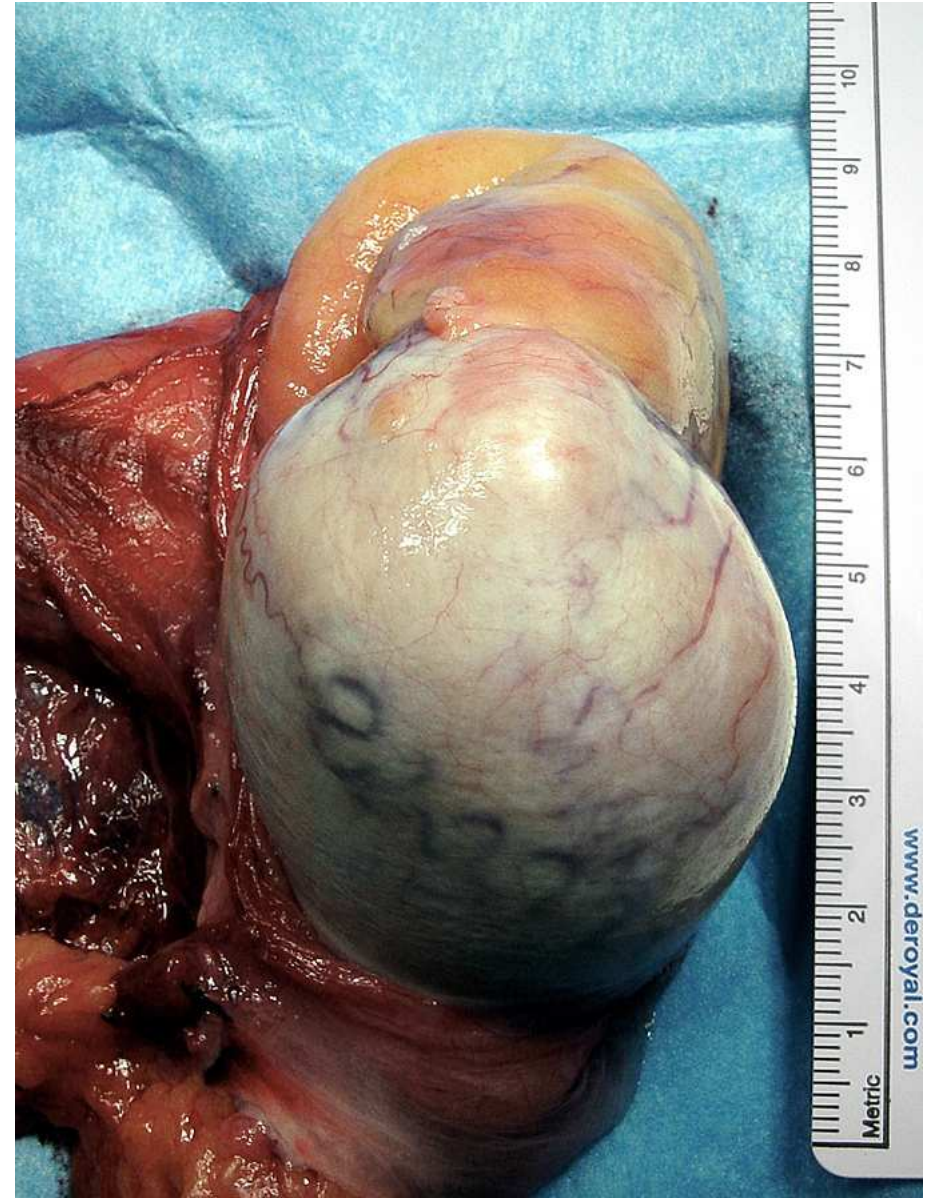
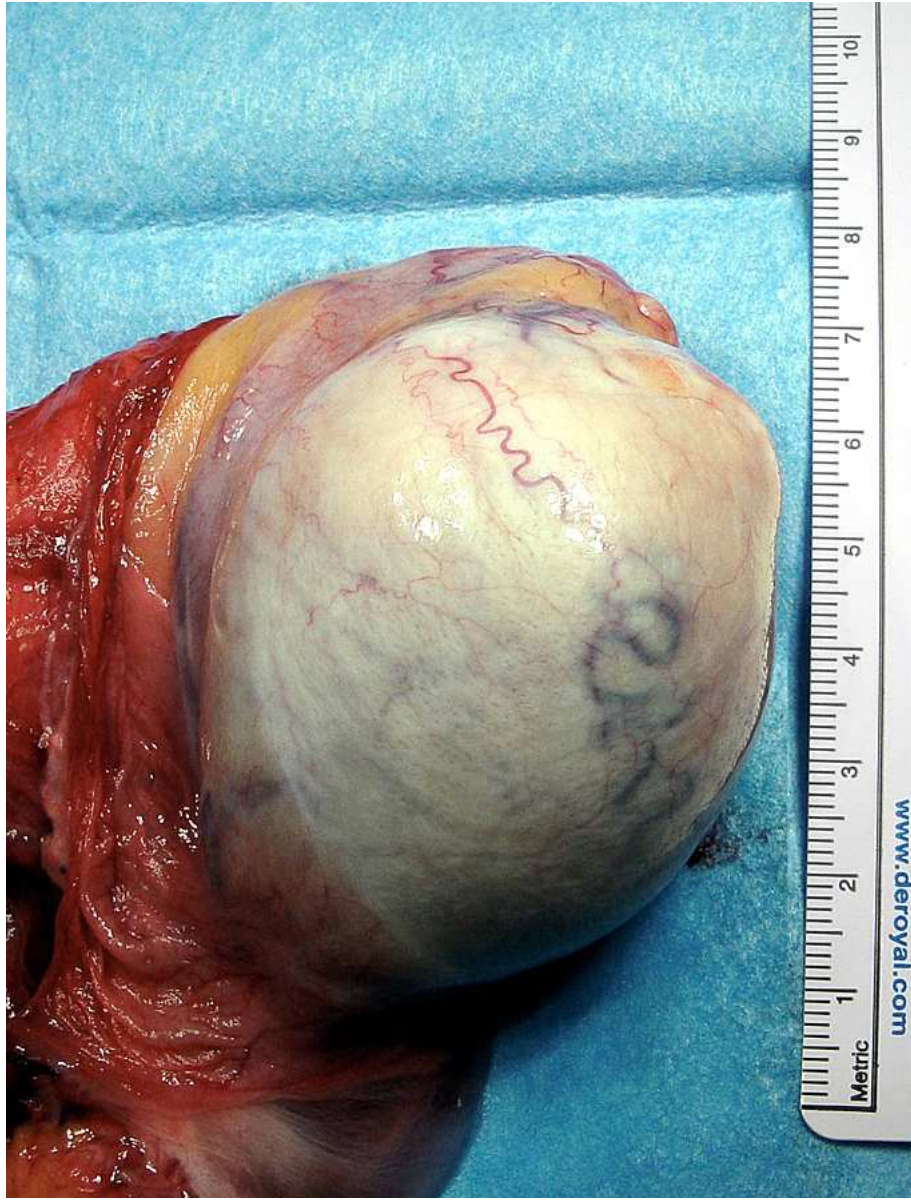

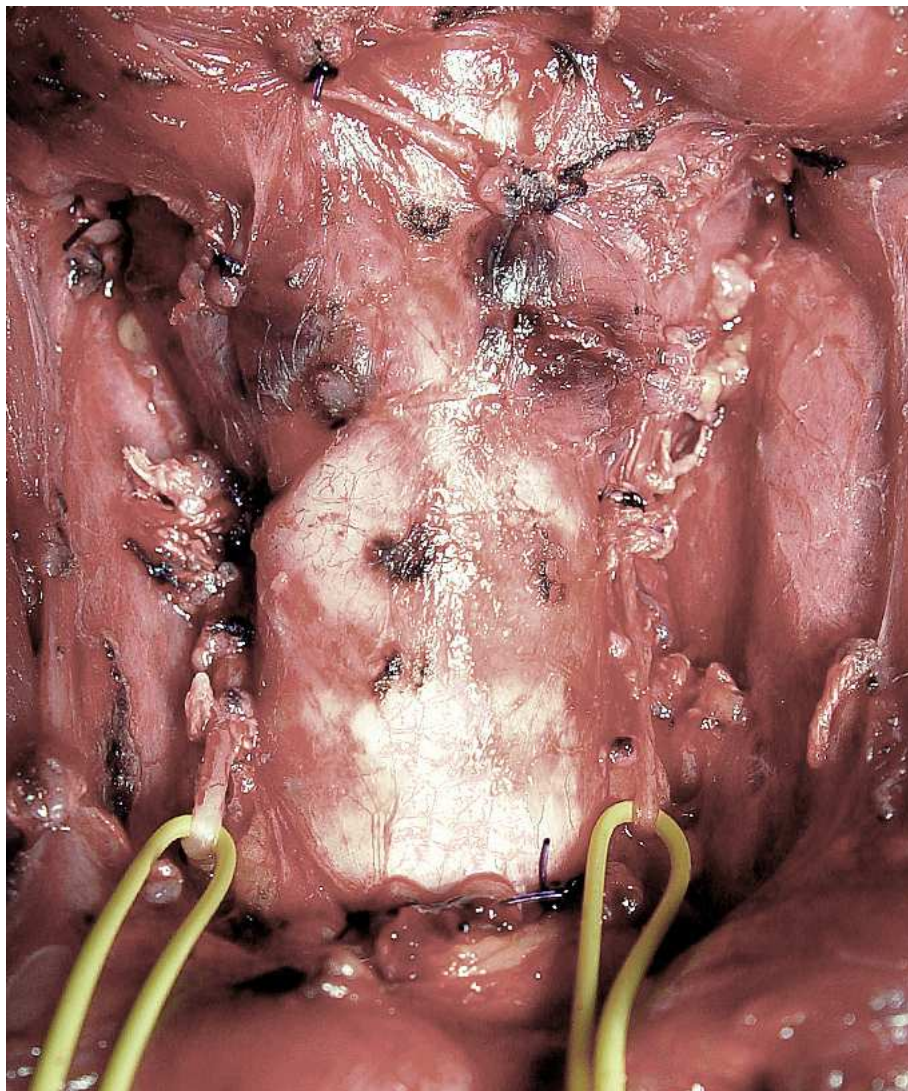
S.S. · Anni: 29 - M · Record: 73 · 15-10-2003

Orchifunicelectomia e plastica inguinale sec. Bassini a dx per miofibroma del testicolo



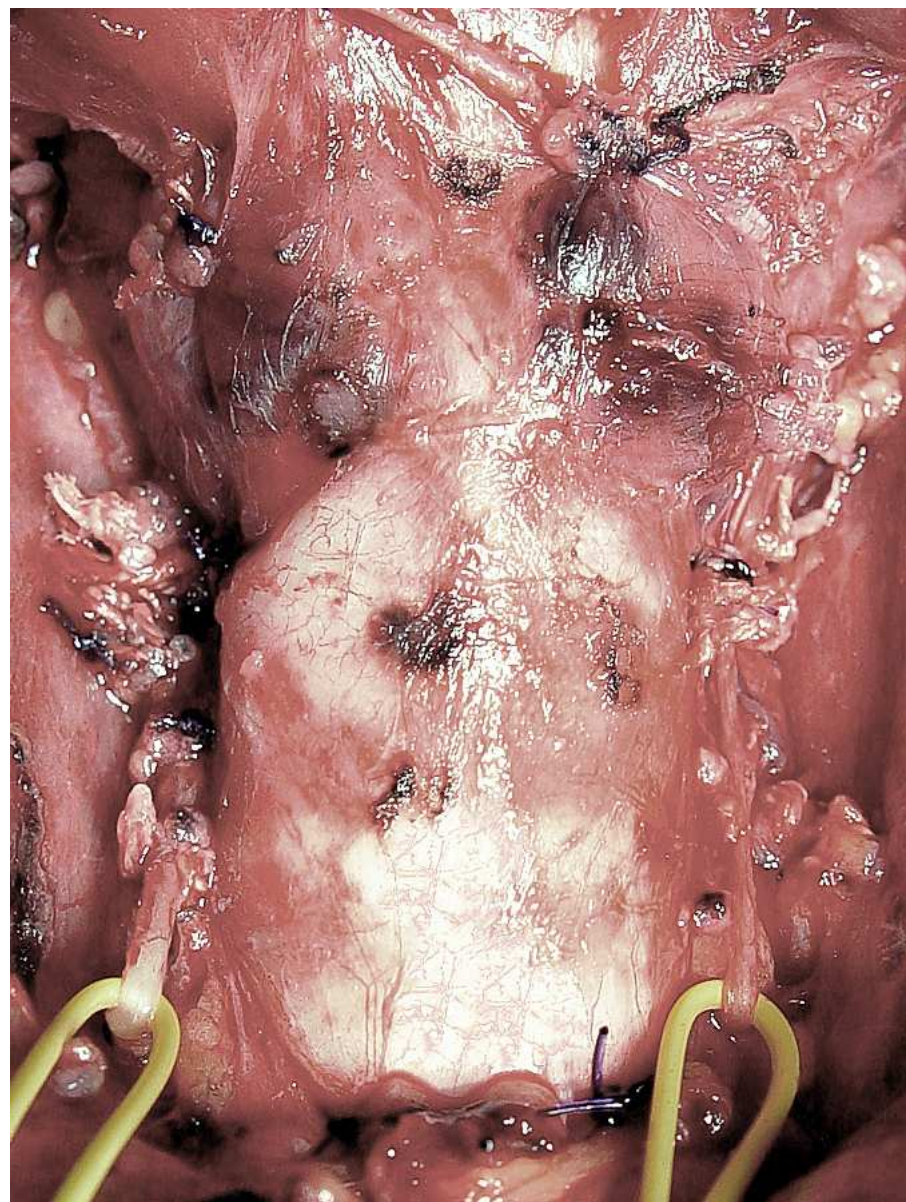




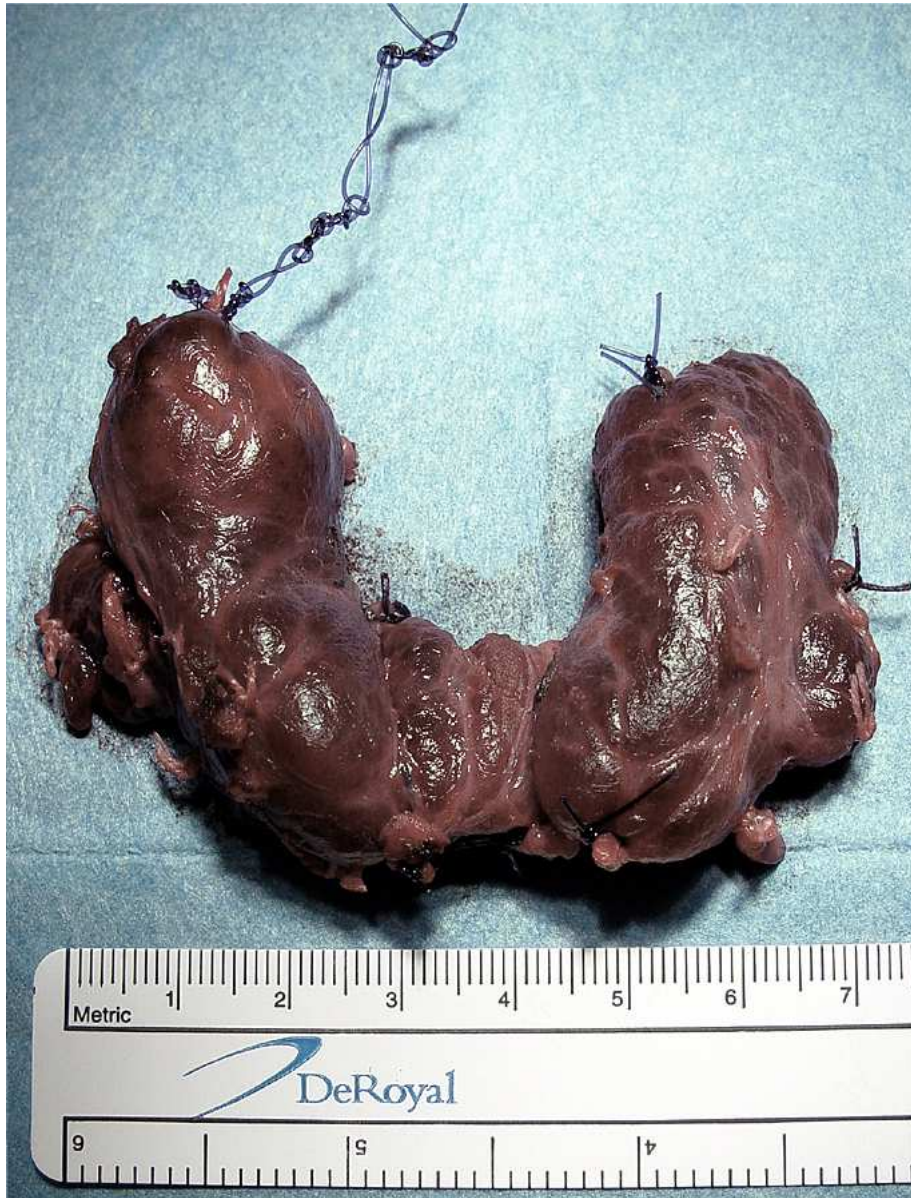

N.M.R. · Anni: 34 - F · Record: 74 · 23-10-2003

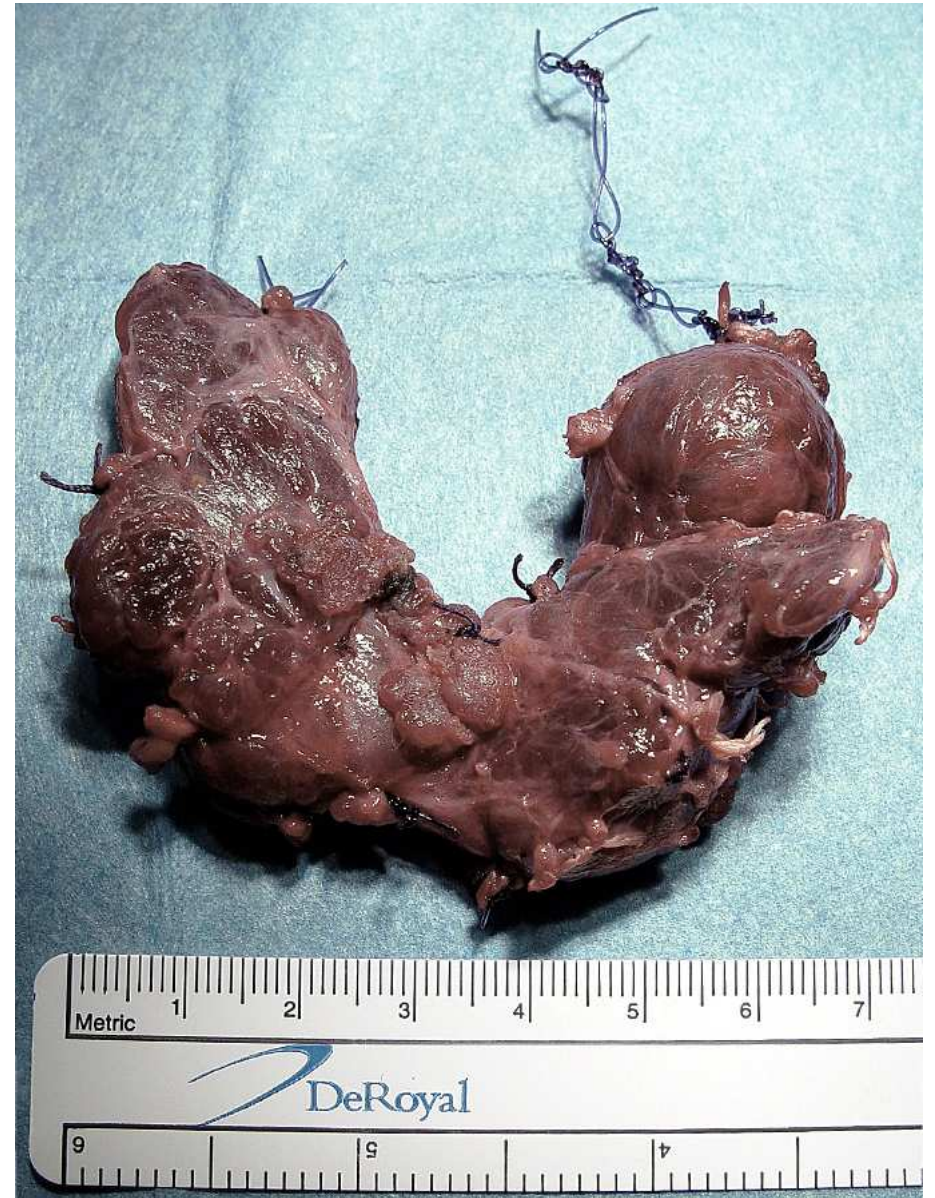Tiroidectomia totale extracapsulare per adenoma follicolare del lobo destro in gozzo plurinodulare



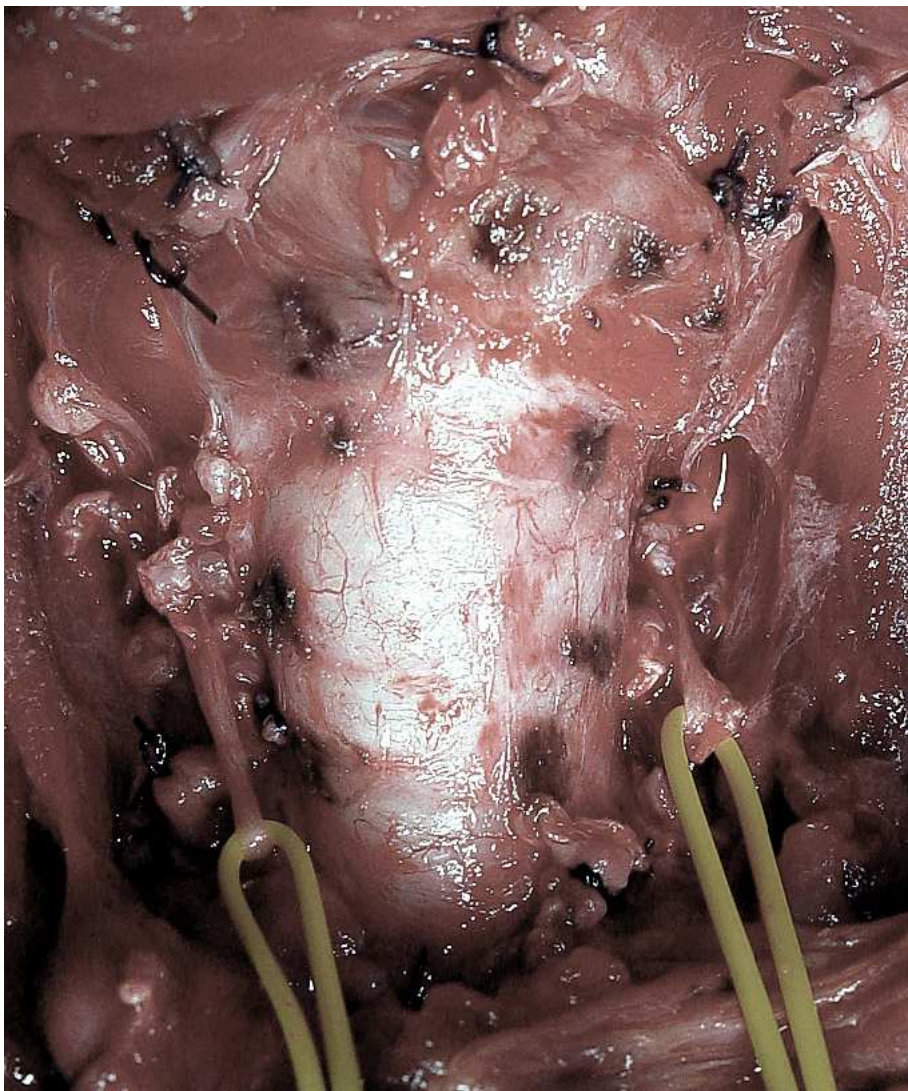
Isolamento dei nervi laringei inferiori (ricorrenti)



Lobo destro - Istmo - Lobo sinistro (superficie anteriore)

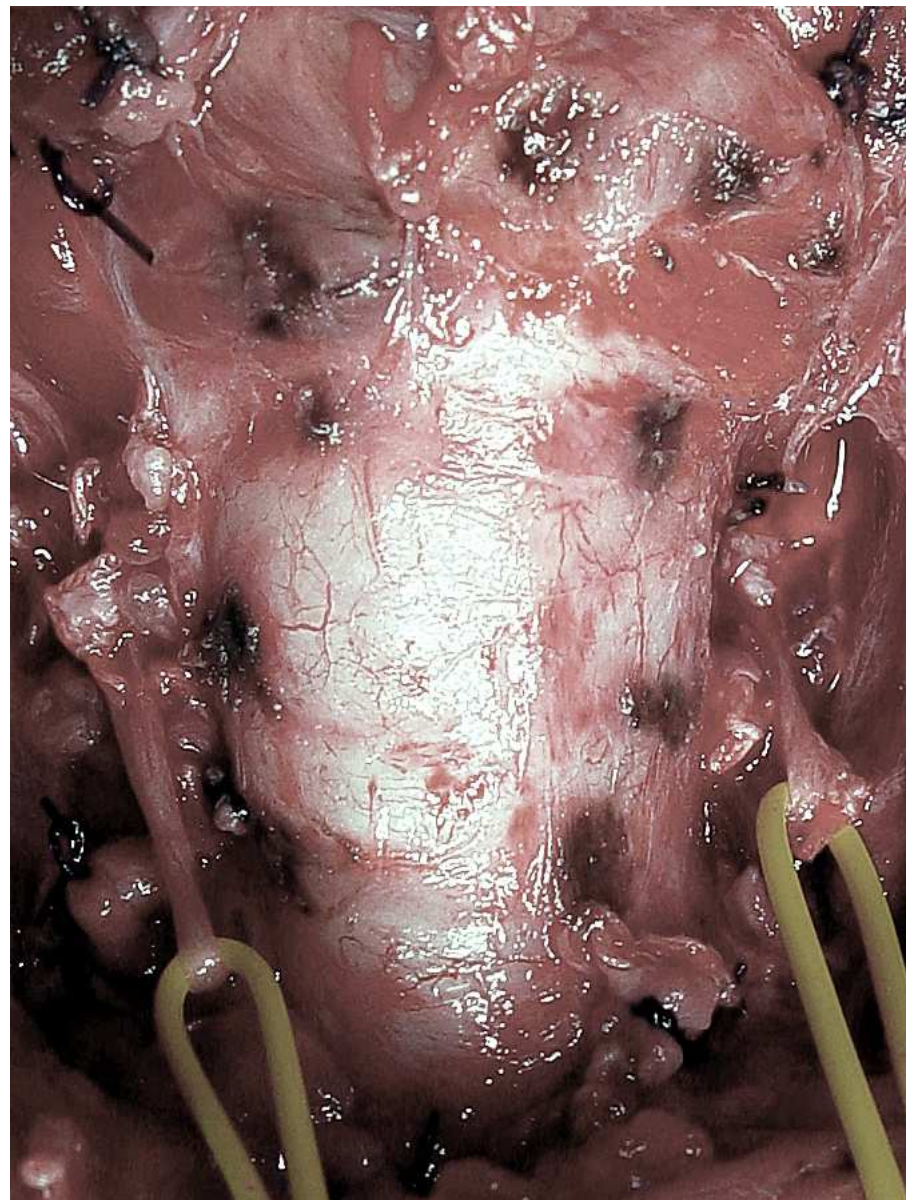


Lobo sinistro - Istmo - Lobo destro (superficie posteriore)

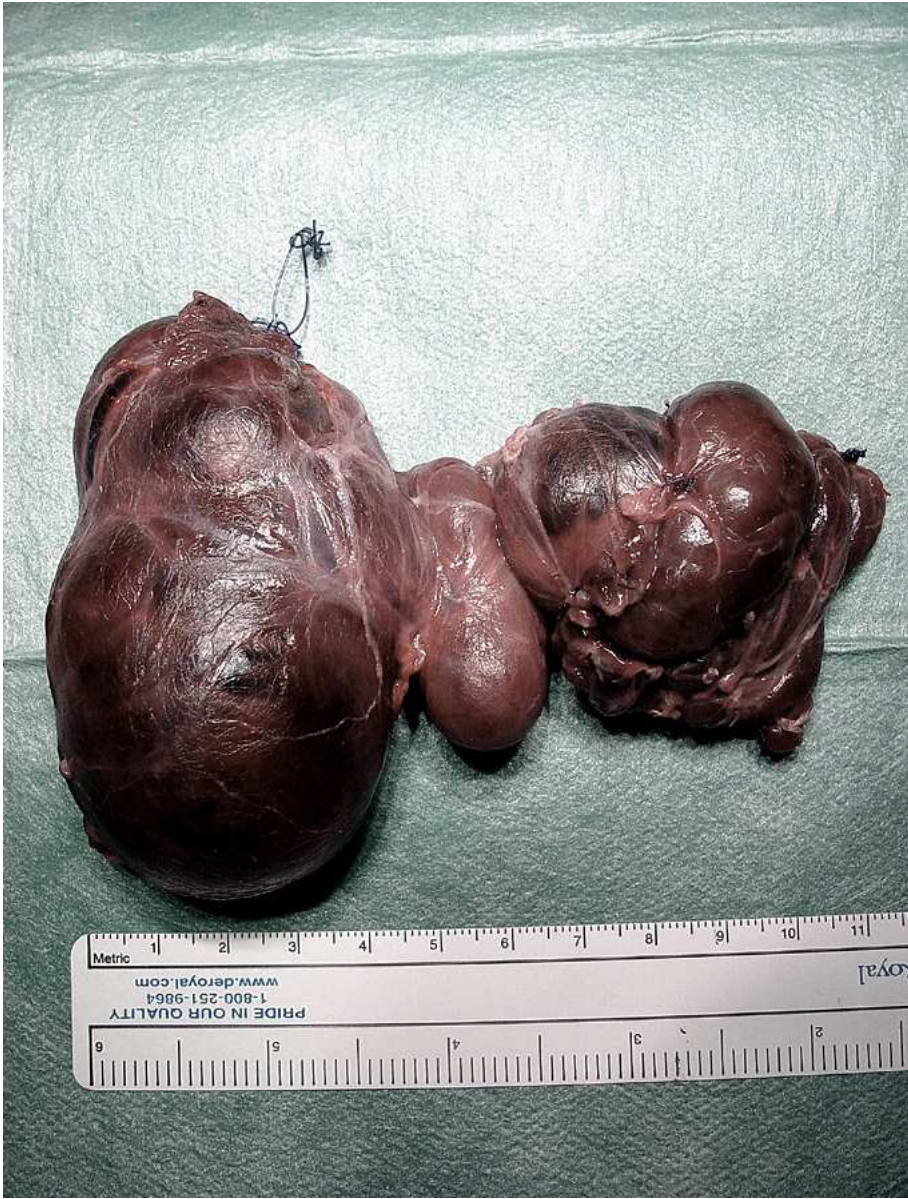

M.A. · Anni: 42 - F · Record: 75 · 21-02-2004

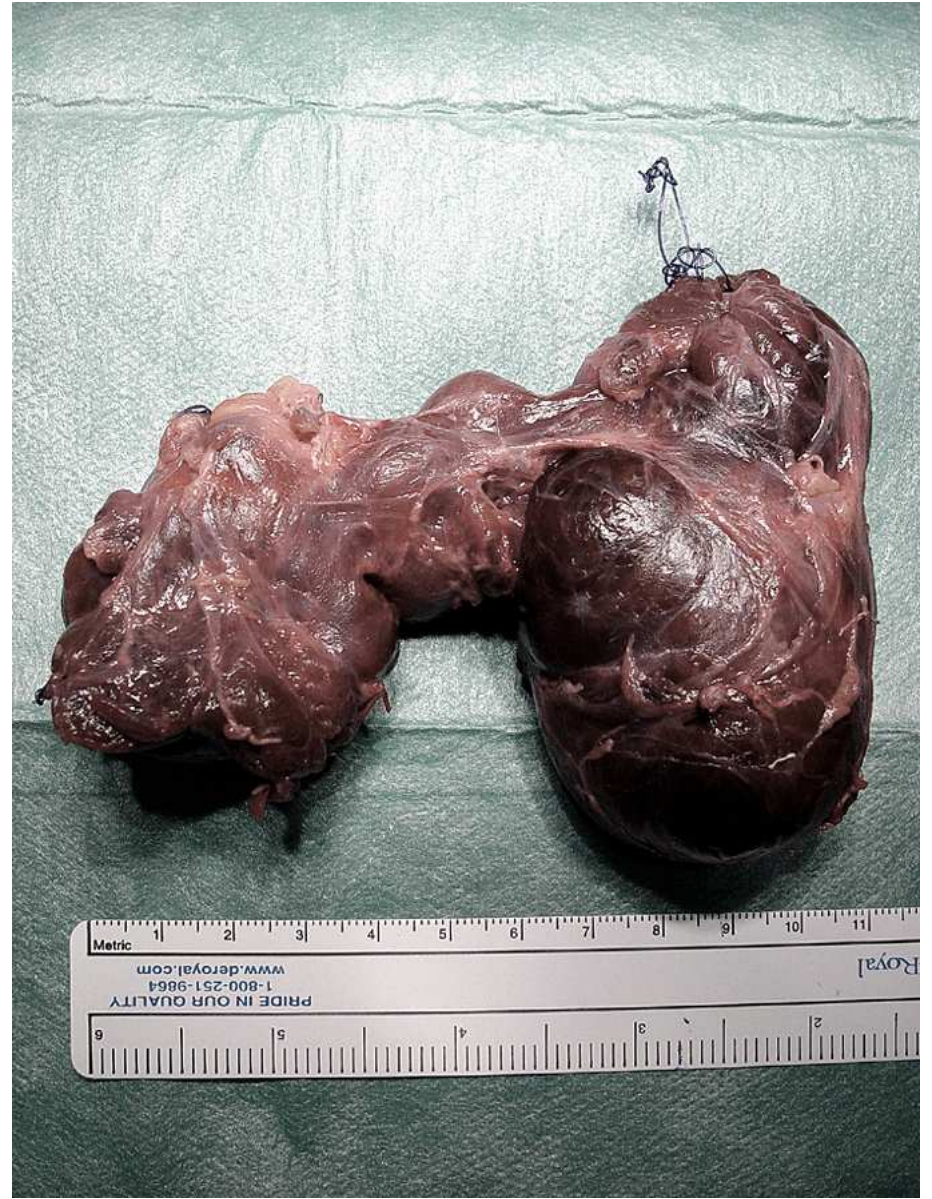Tiroidectomia totale extracapsulare per gozzo plurinodulare tossico plongeant



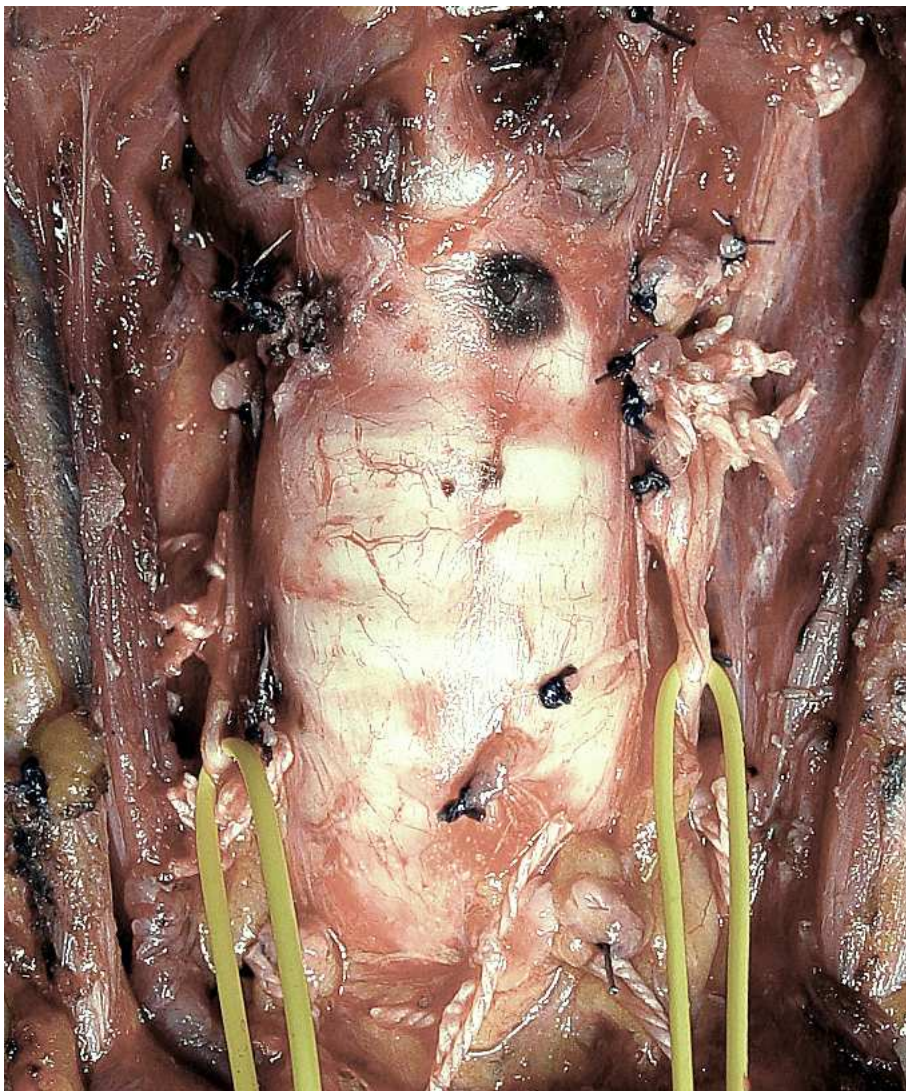
Isolamento dei nervi laringei inferiori (ricorrenti)



Lobo destro - Istmo - Lobo sinistro (superficie anteriore)

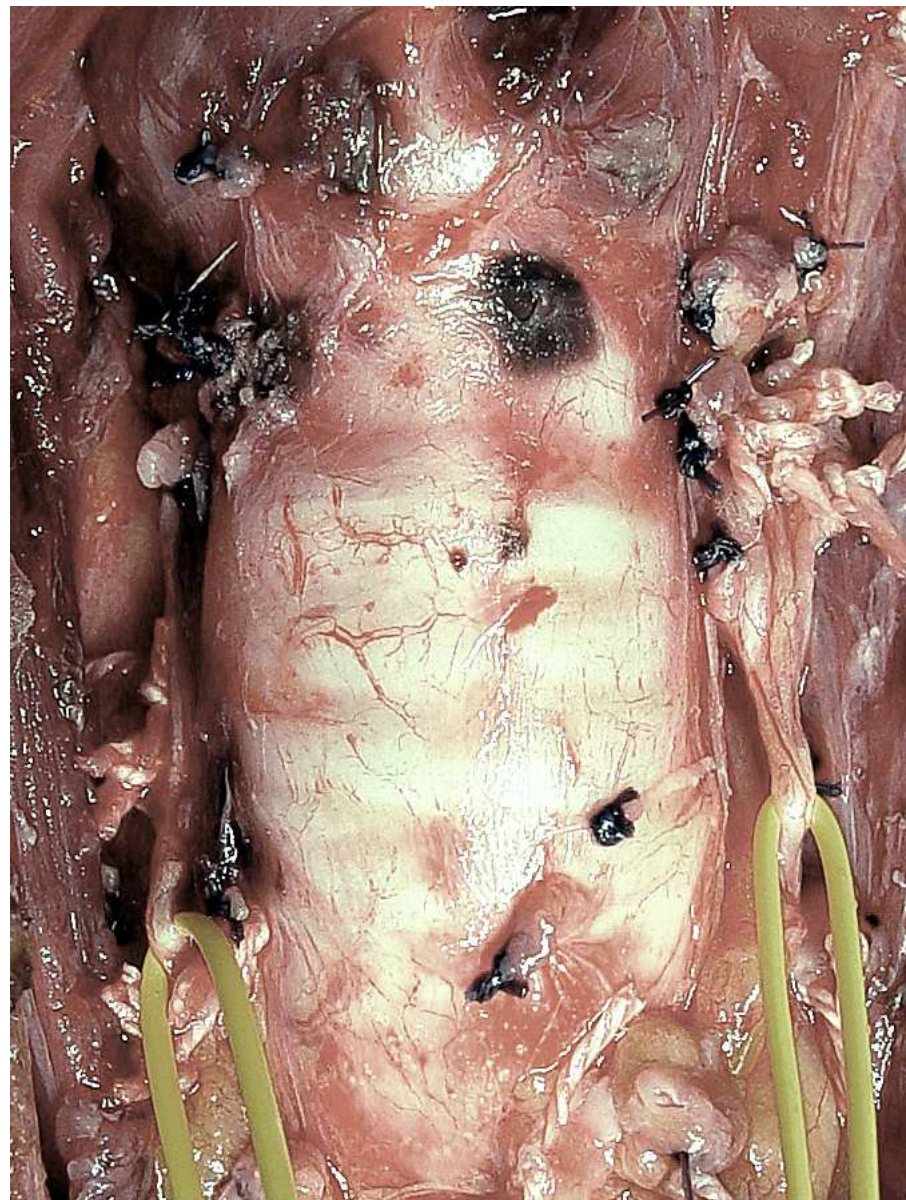


Lobo sinistro - Istmo - Lobo destro (superficie posteriore)

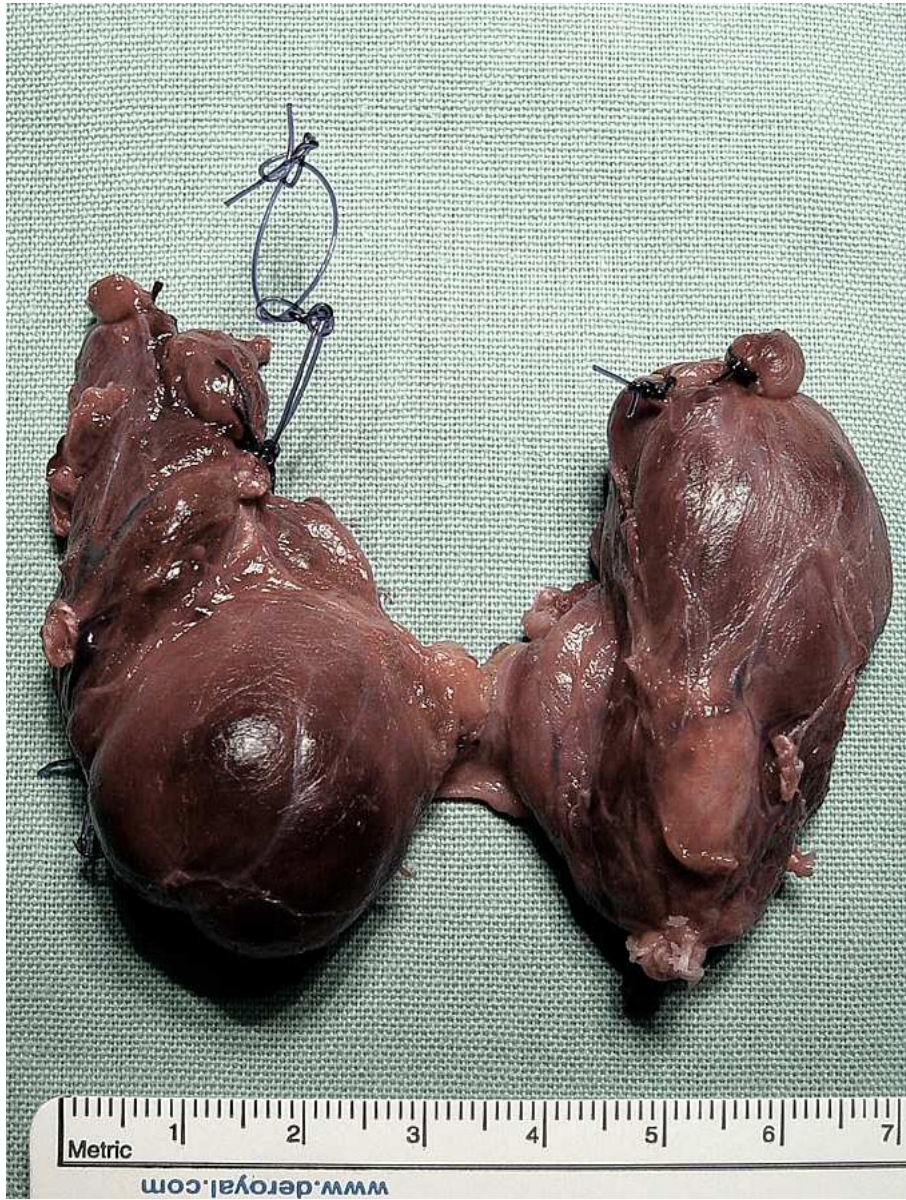


B.A. • Anni: 54 - F • Record: 76 • 26-02-2004

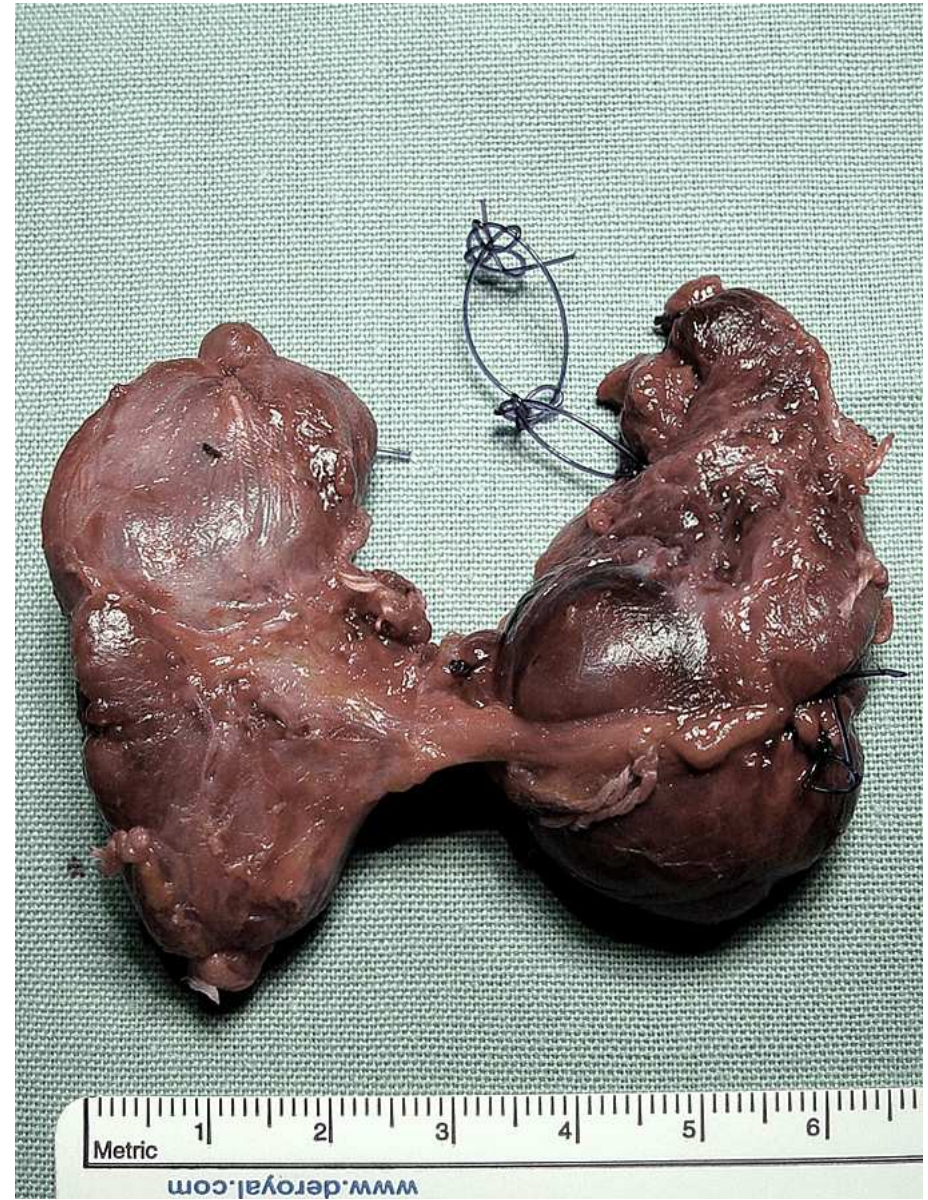
Tiroidectomia totale extracapsulare per gozzo plurinodulare



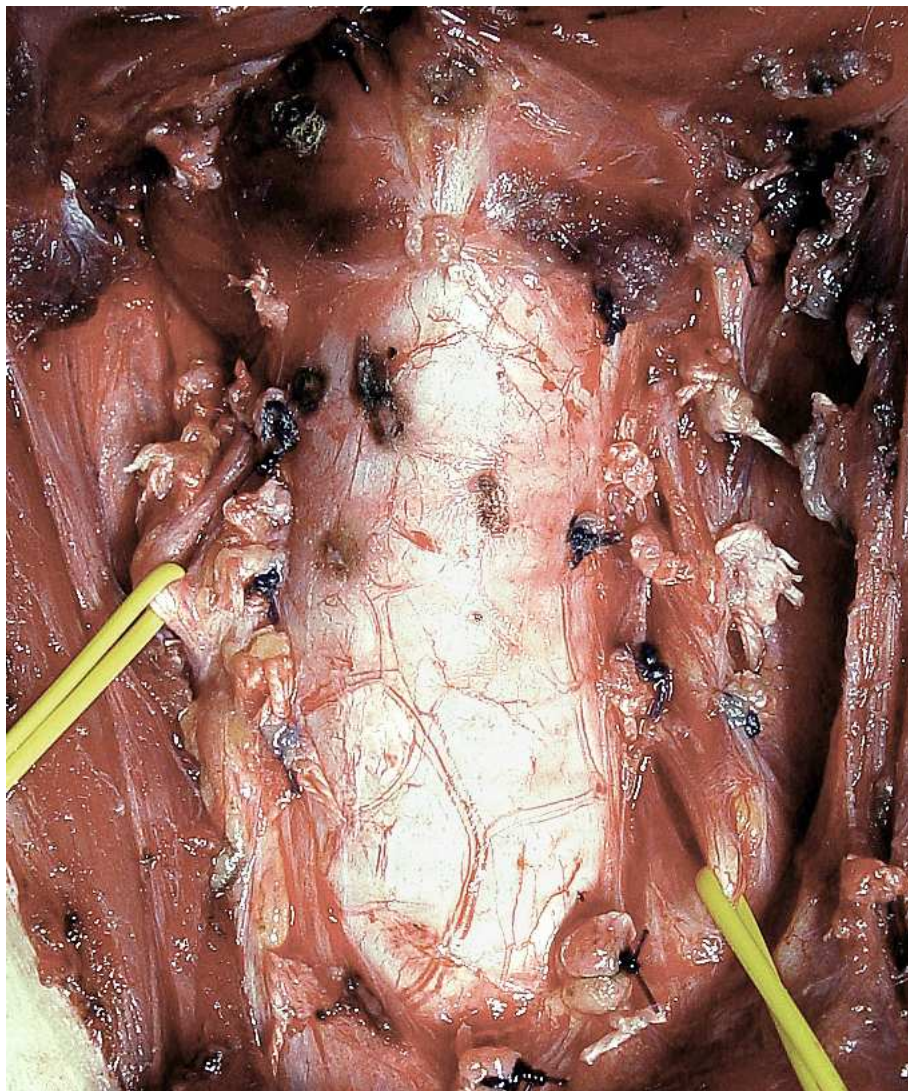
Isolamento dei nervi laringei inferiori (ricorrenti)



Lobo destro - Istmo - Lobo sinistro (superficie anteriore)

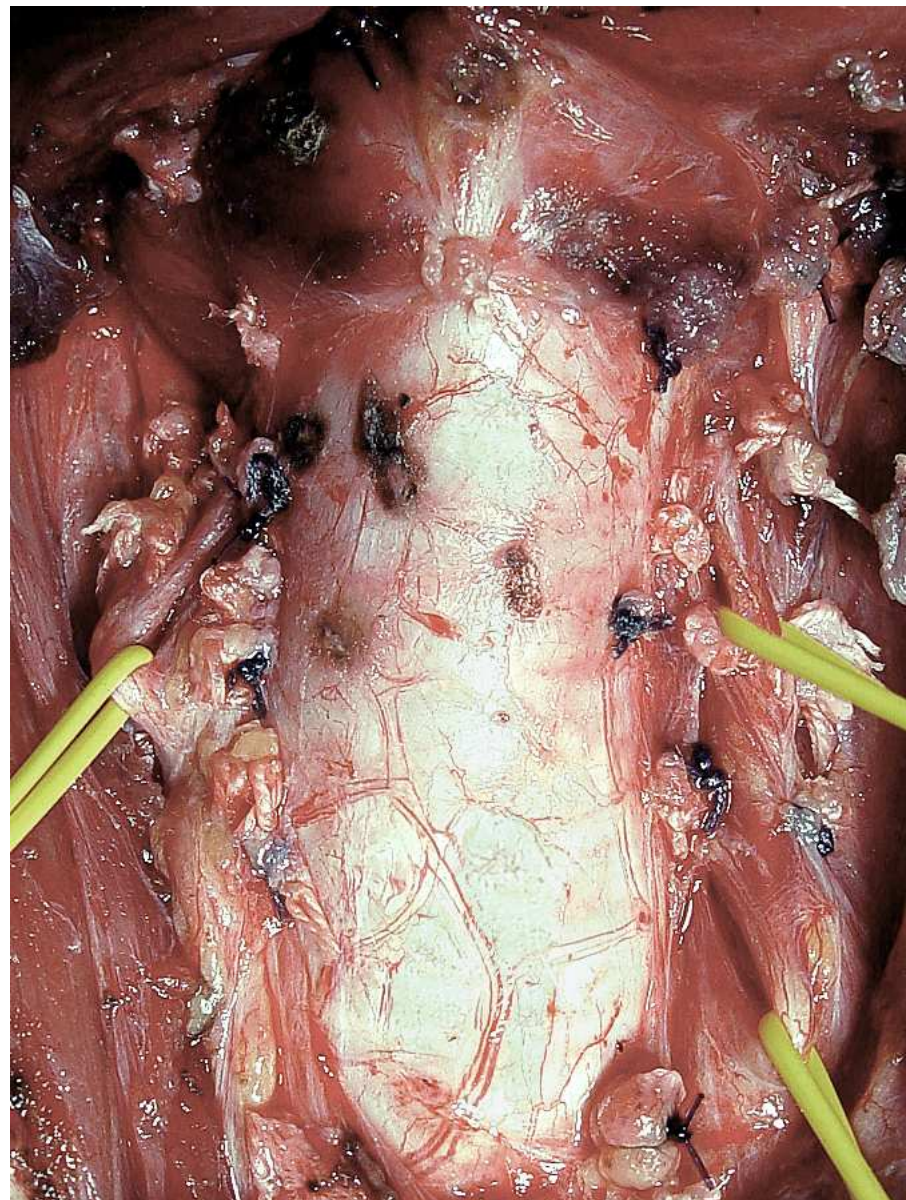


Lobo sinistro - Istmo - Lobo destro (superficie posteriore)



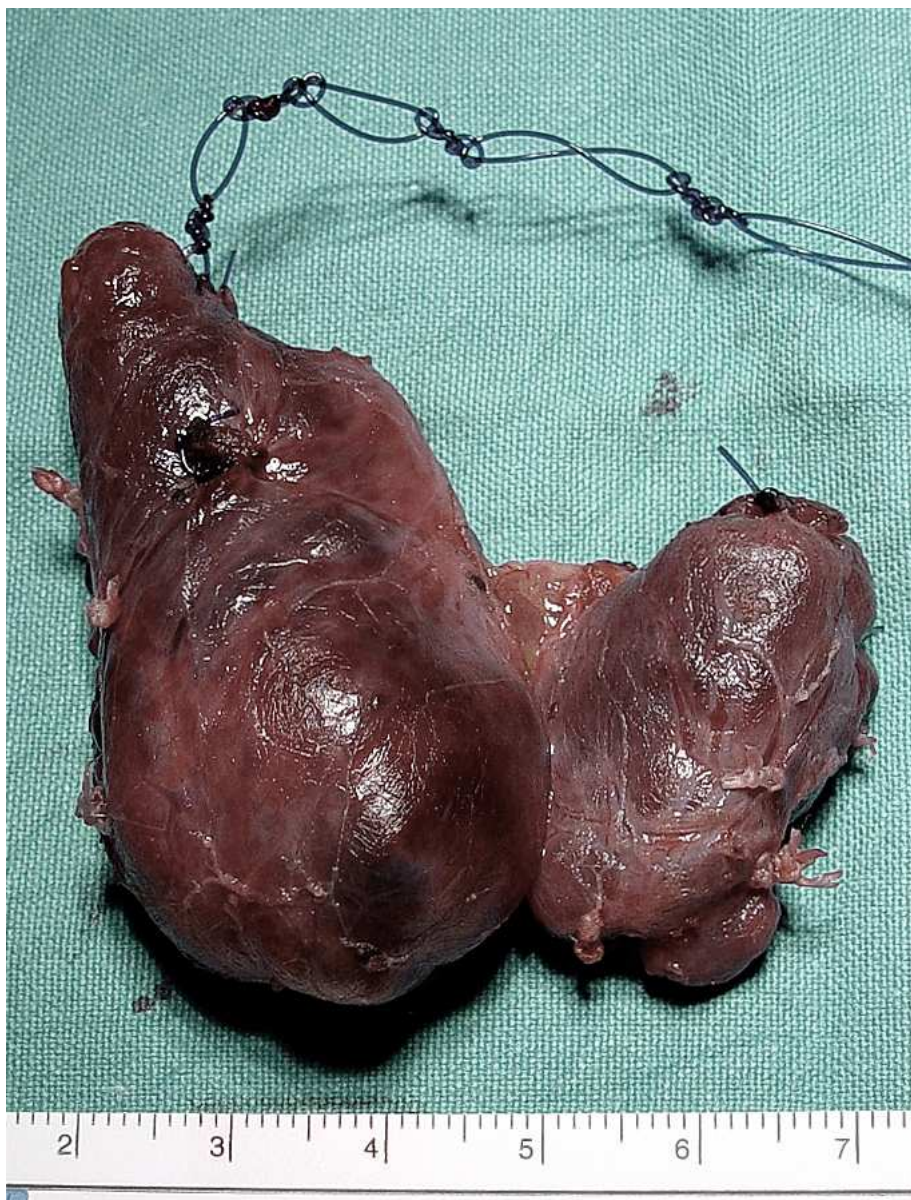
P.R. · Anni: 27 - F · Record: 77 · 28-02-2004

Tiroidectomia totale extracapsulare per gozzo plurinodulare

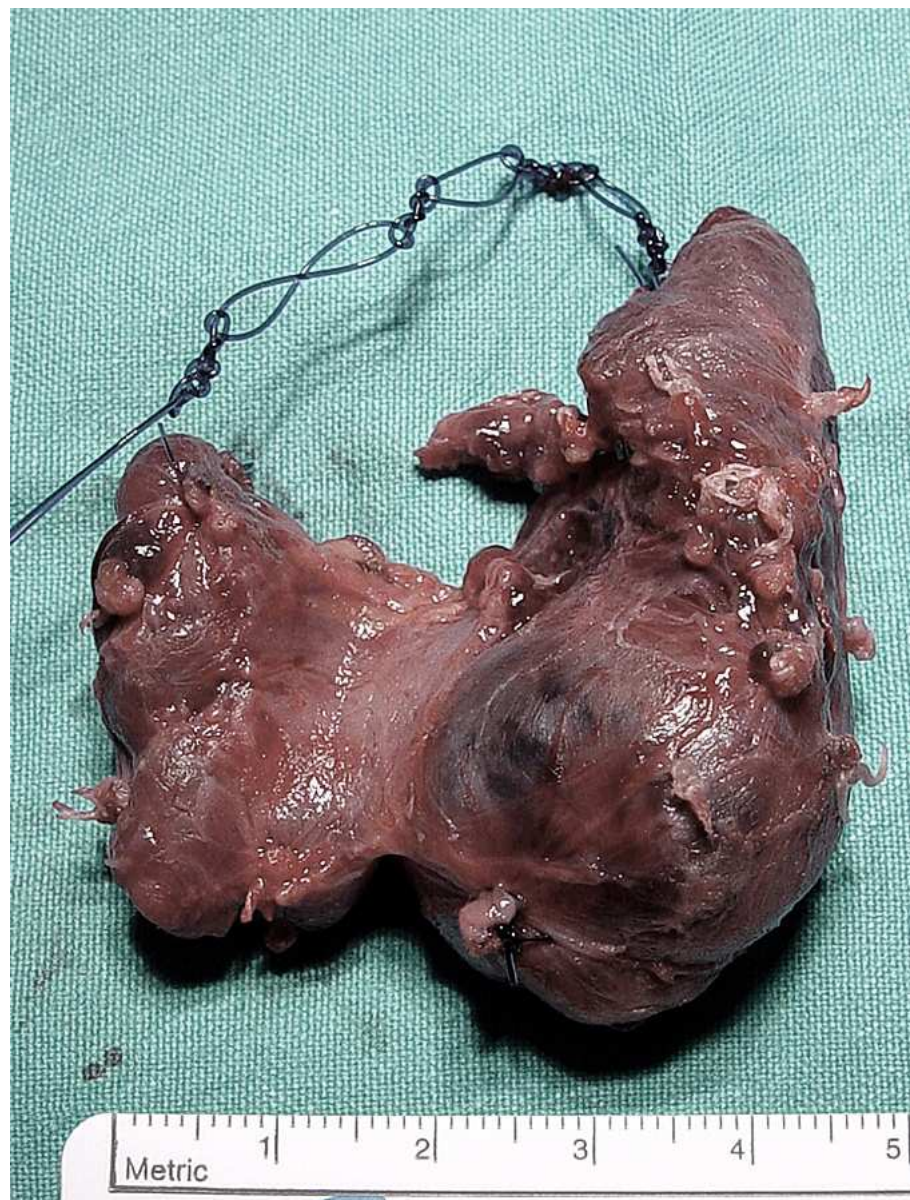


Isolamento dei nervi laringei inferiori (ricorrenti)

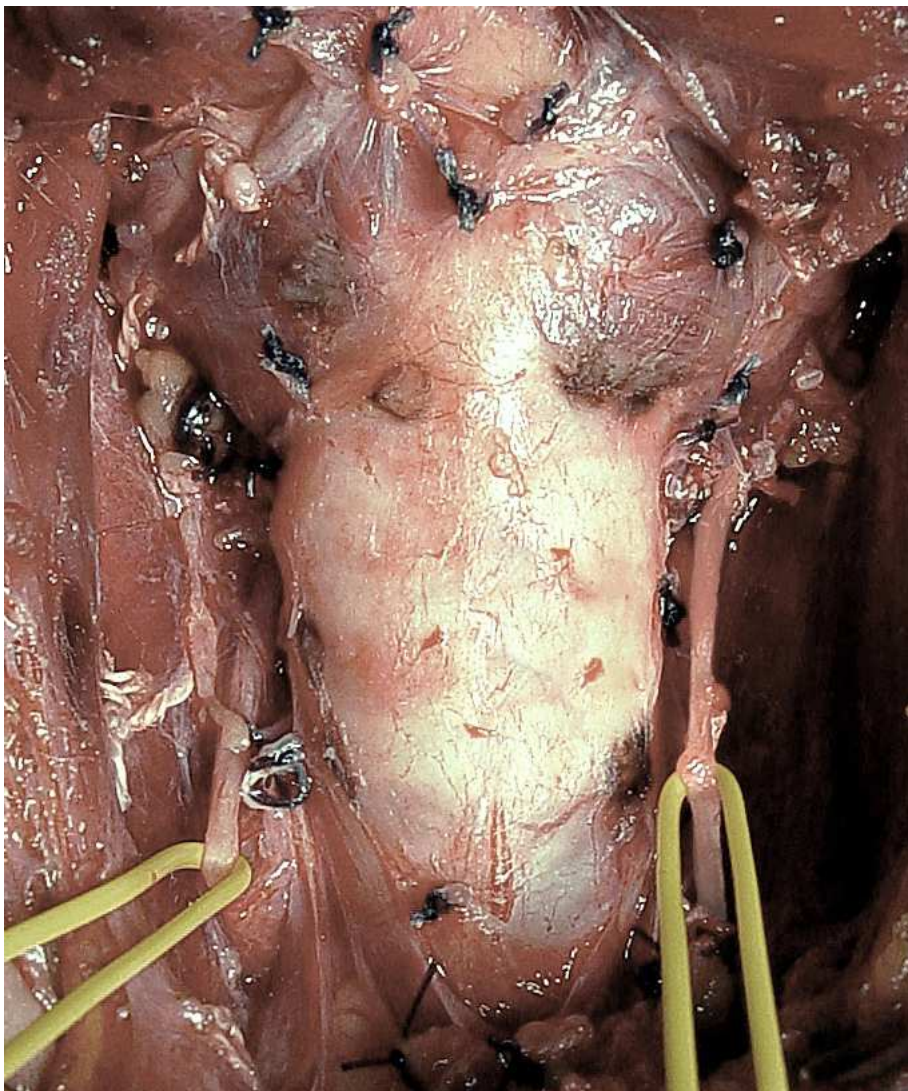




Lobo destro - Istmo - Lobo sinistro (superficie anteriore)

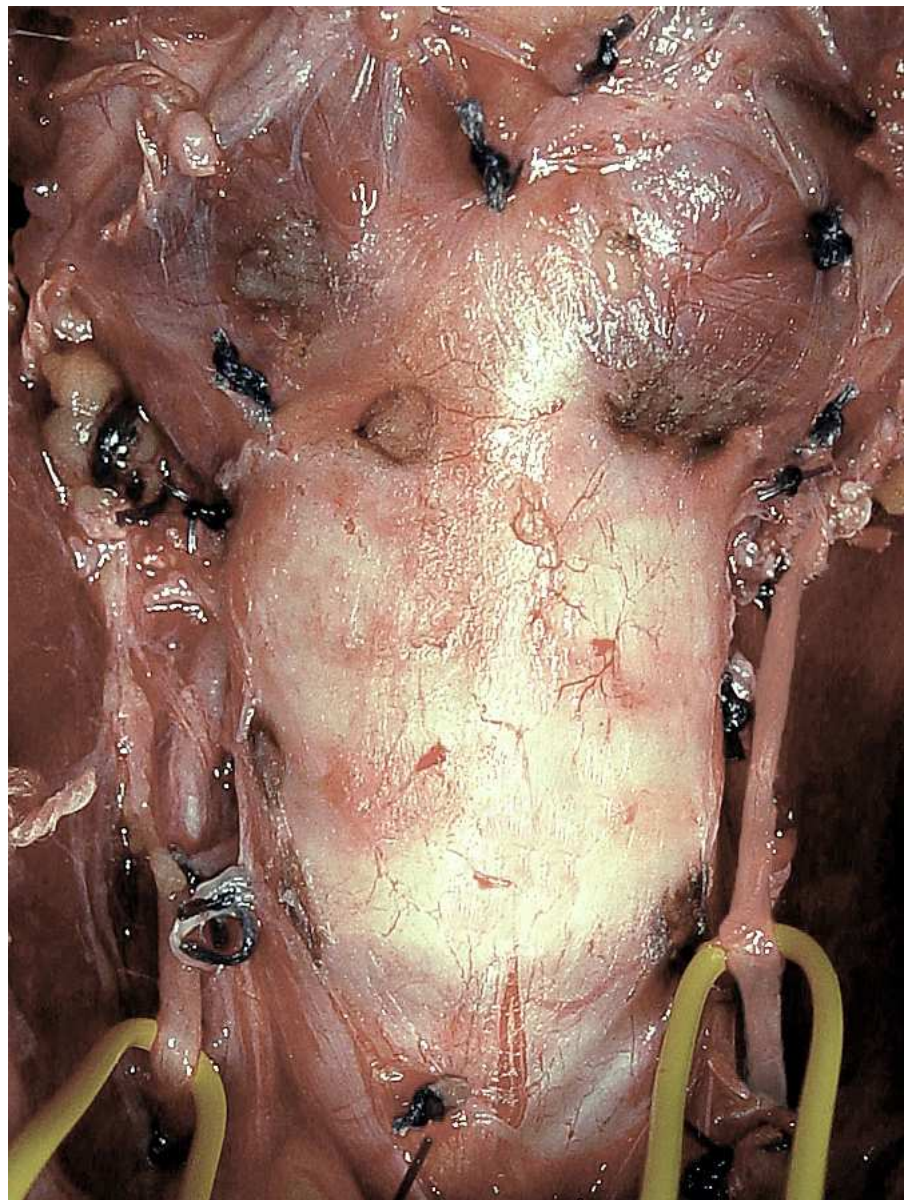


Lobo sinistro - Istmo - Lobo destro (superficie posteriore)

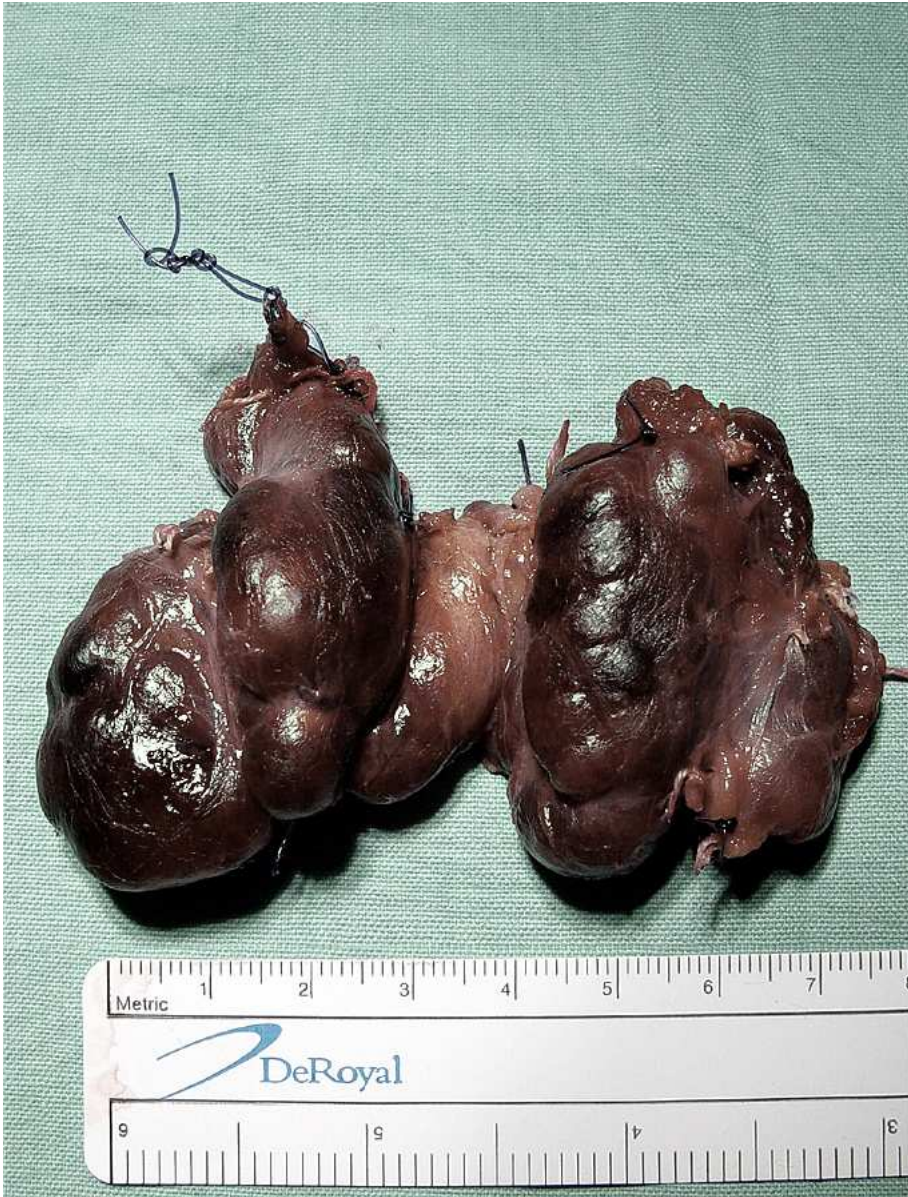

S.F. · Anni: 40 - F · Record: 78 · 25-03-2004

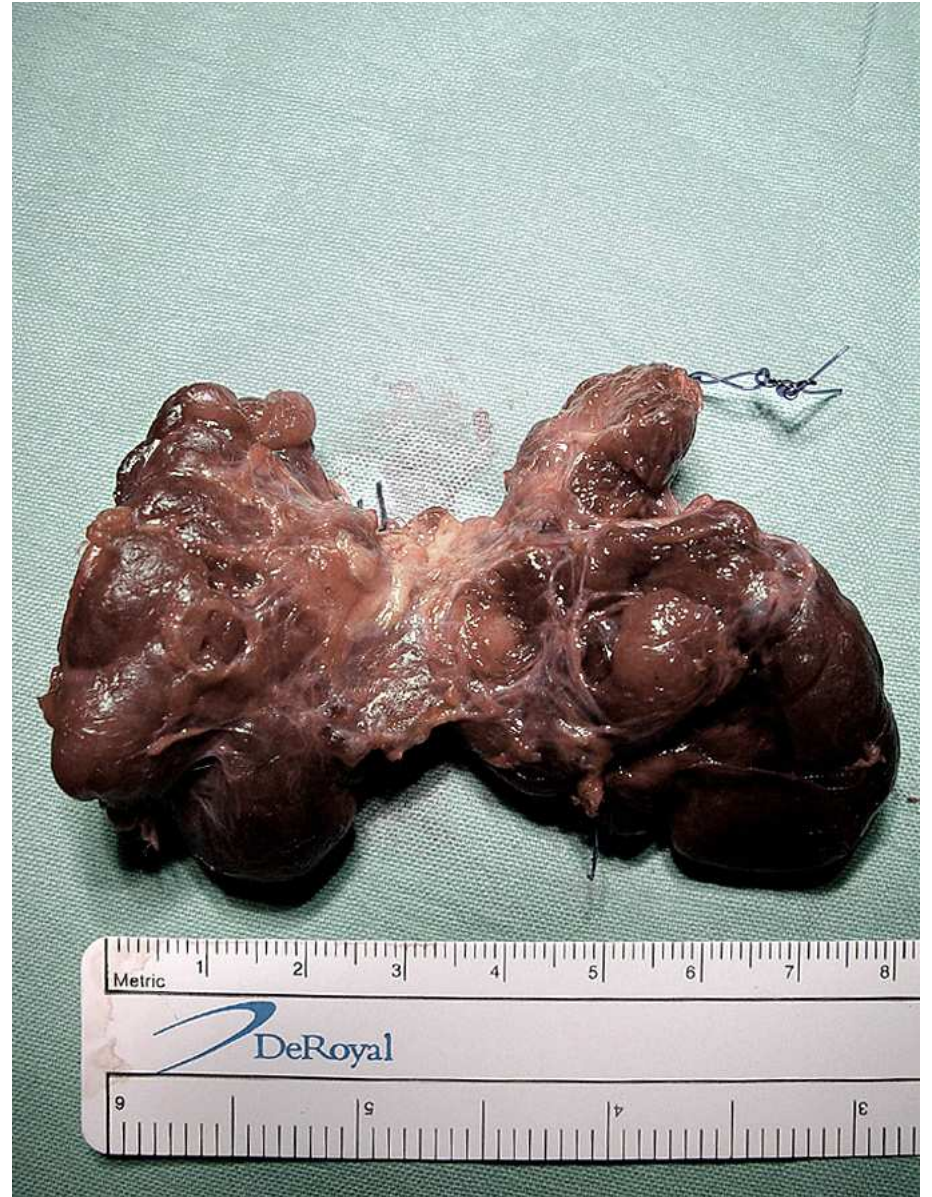Tiroidectomia totale extracapsulare per gozzo plurinodulare pretossico



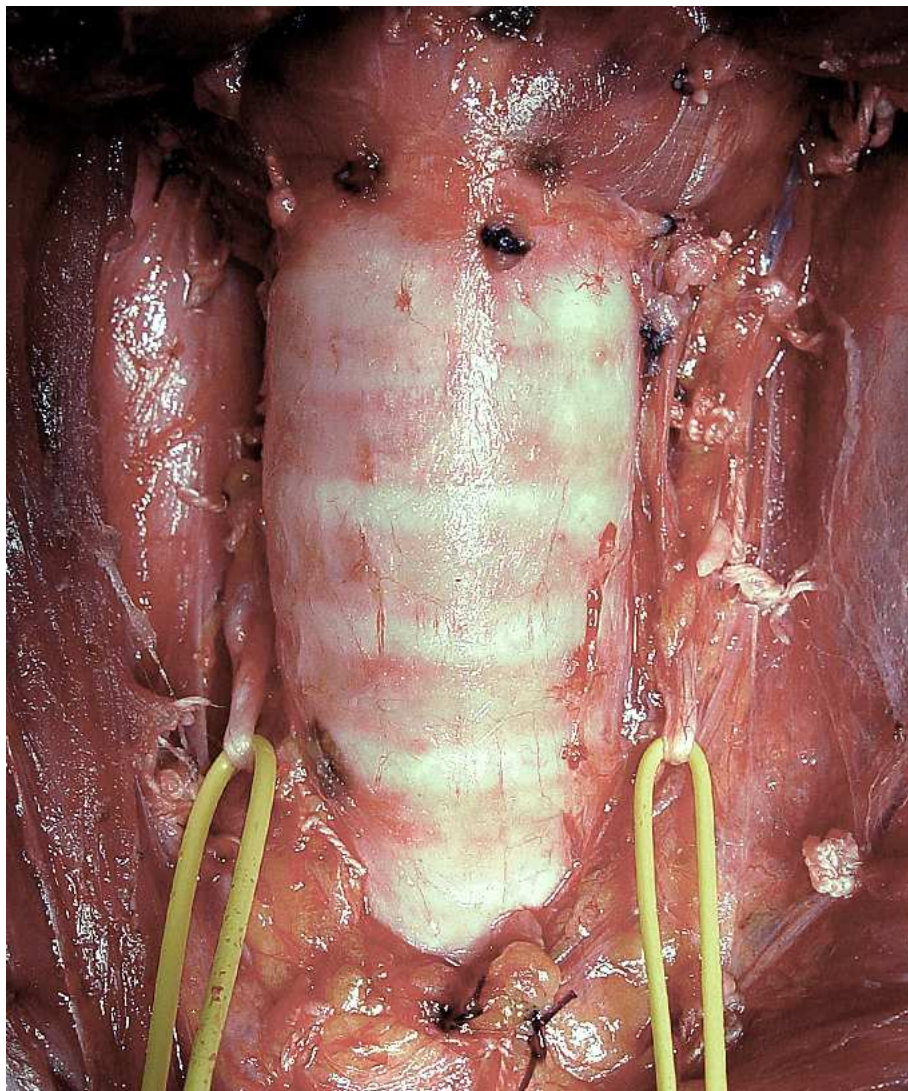
Isolamento dei nervi laringei inferiori (ricorrenti)



Lobo destro - Istmo - Lobo sinistro (superficie anteriore)

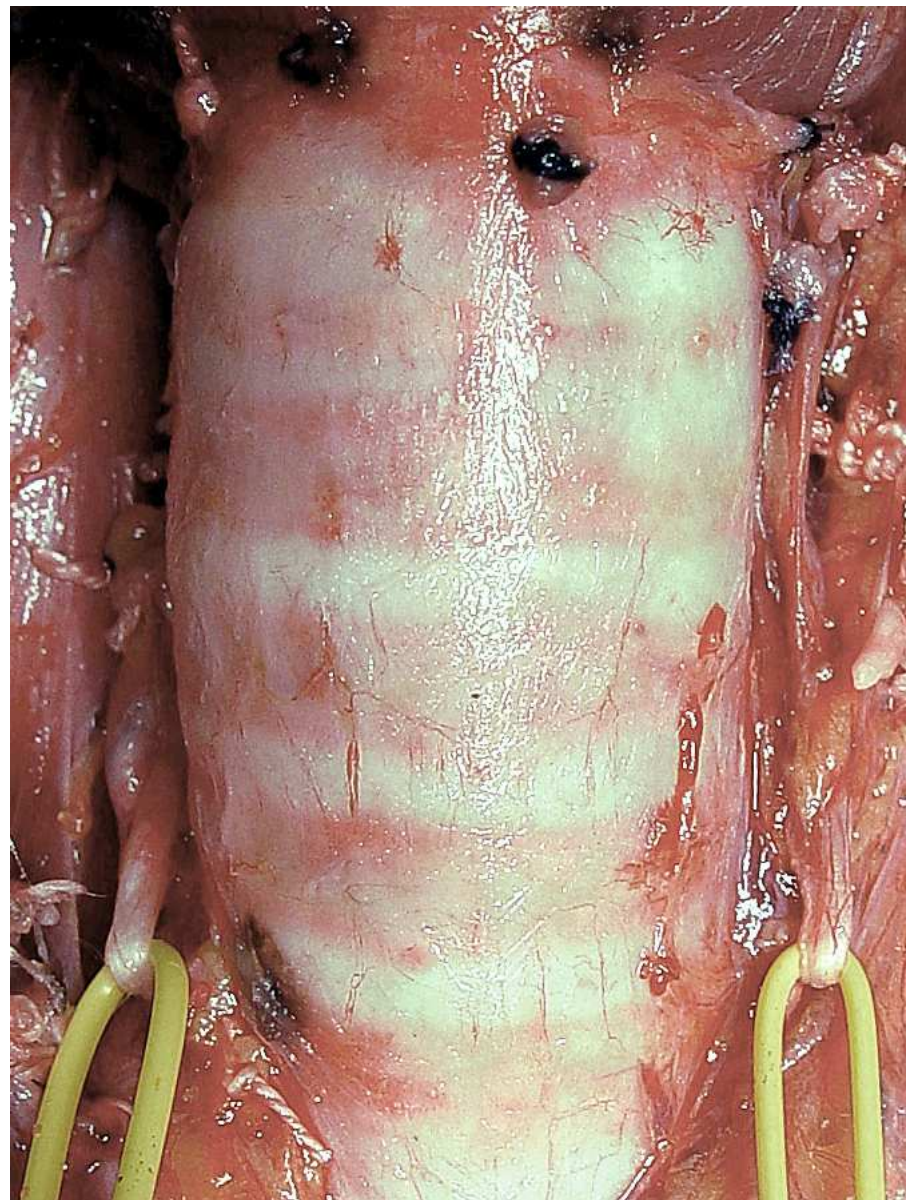


Lobo sinistro - Istmo - Lobo destro (superficie posteriore)

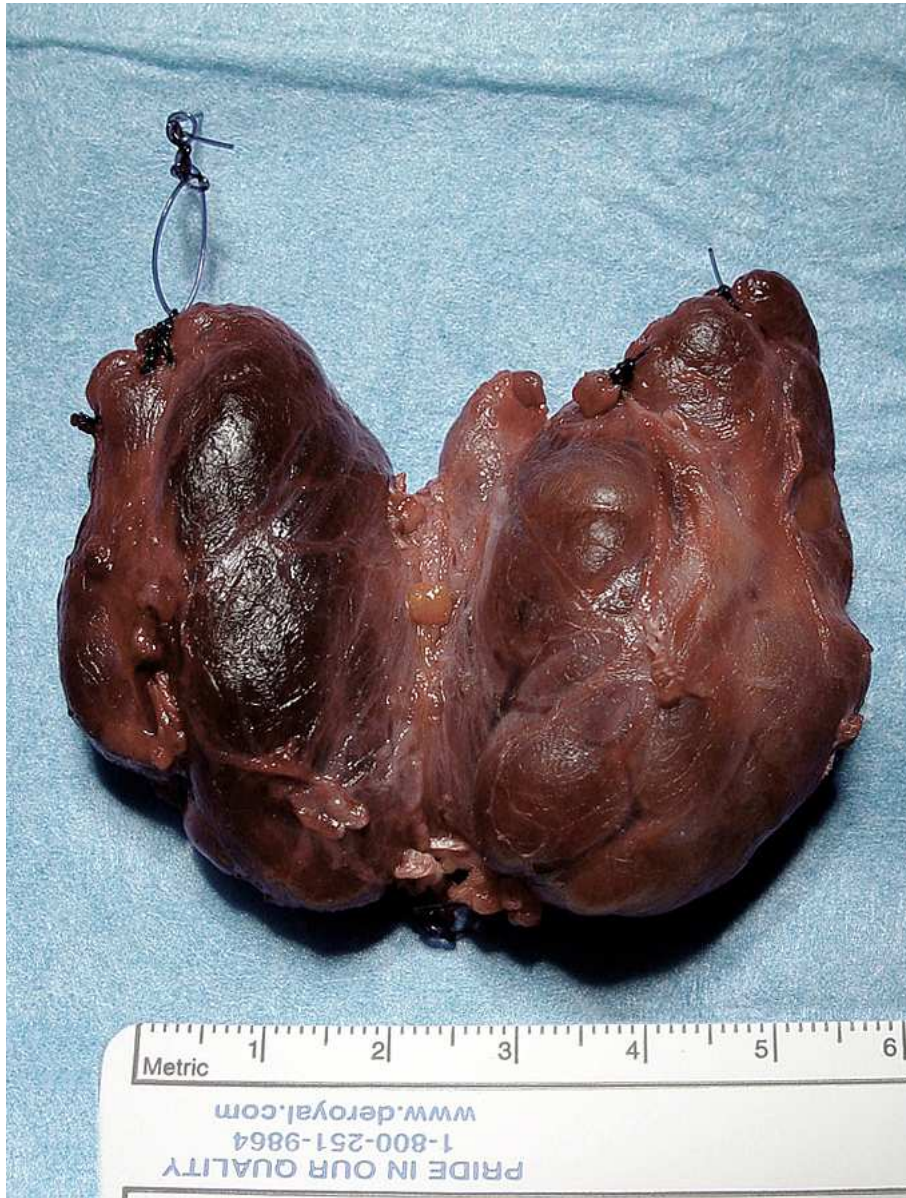

D.P.M. • Anni: 46 - F • Record: 79 • 09-05-2004

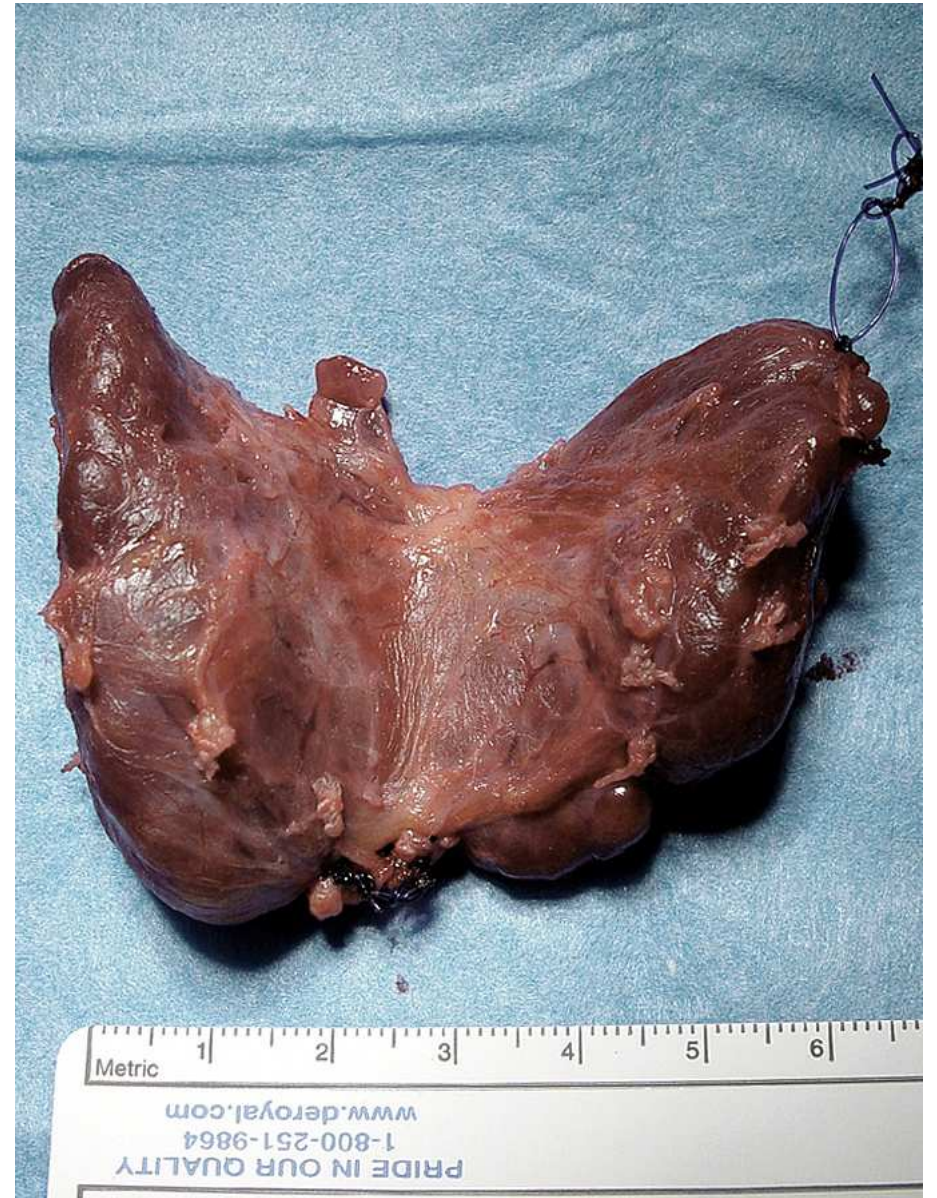Tiroidectomia totale extracapsulare per microcarcinoma papillifero del lobo sn in gozzo plurinodulare con tiroidite linfocitaria



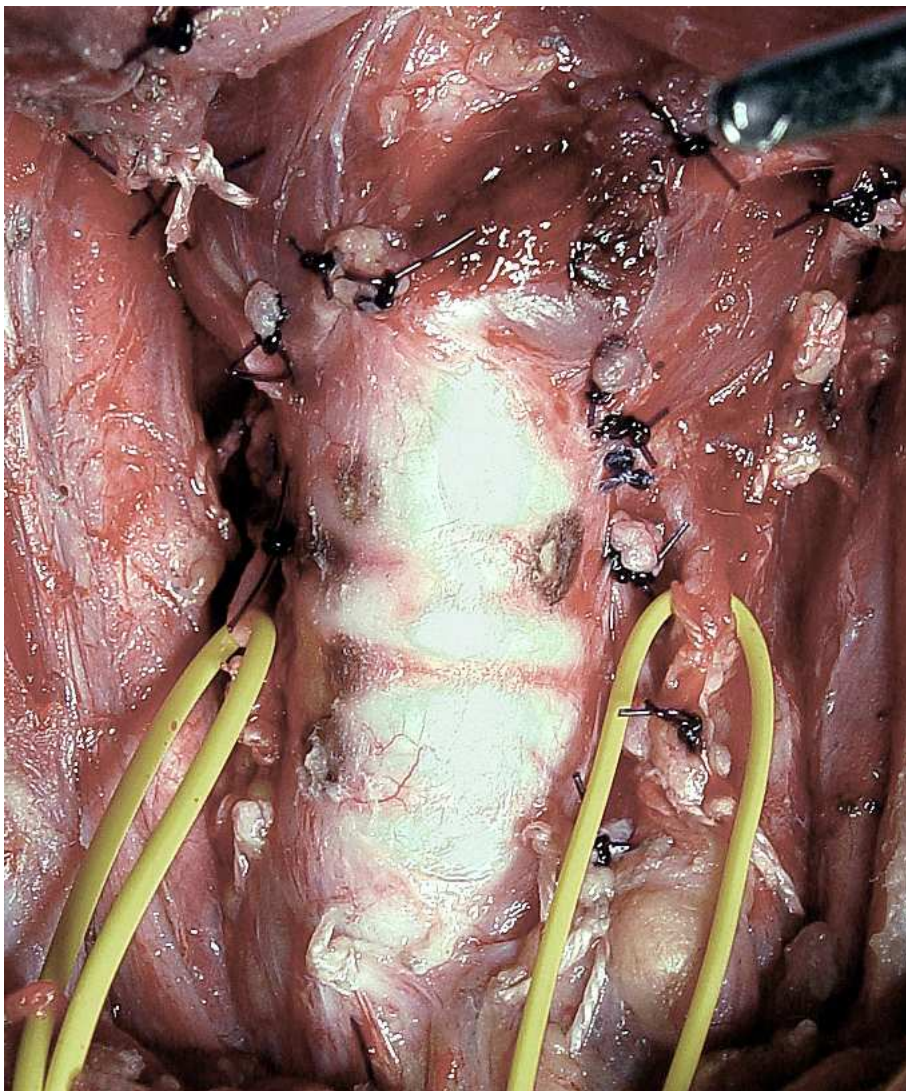
Isolamento dei nervi laringei inferiori (ricorrenti)



Lobo destro - Istmo - Lobo sinistro (superficie anteriore)

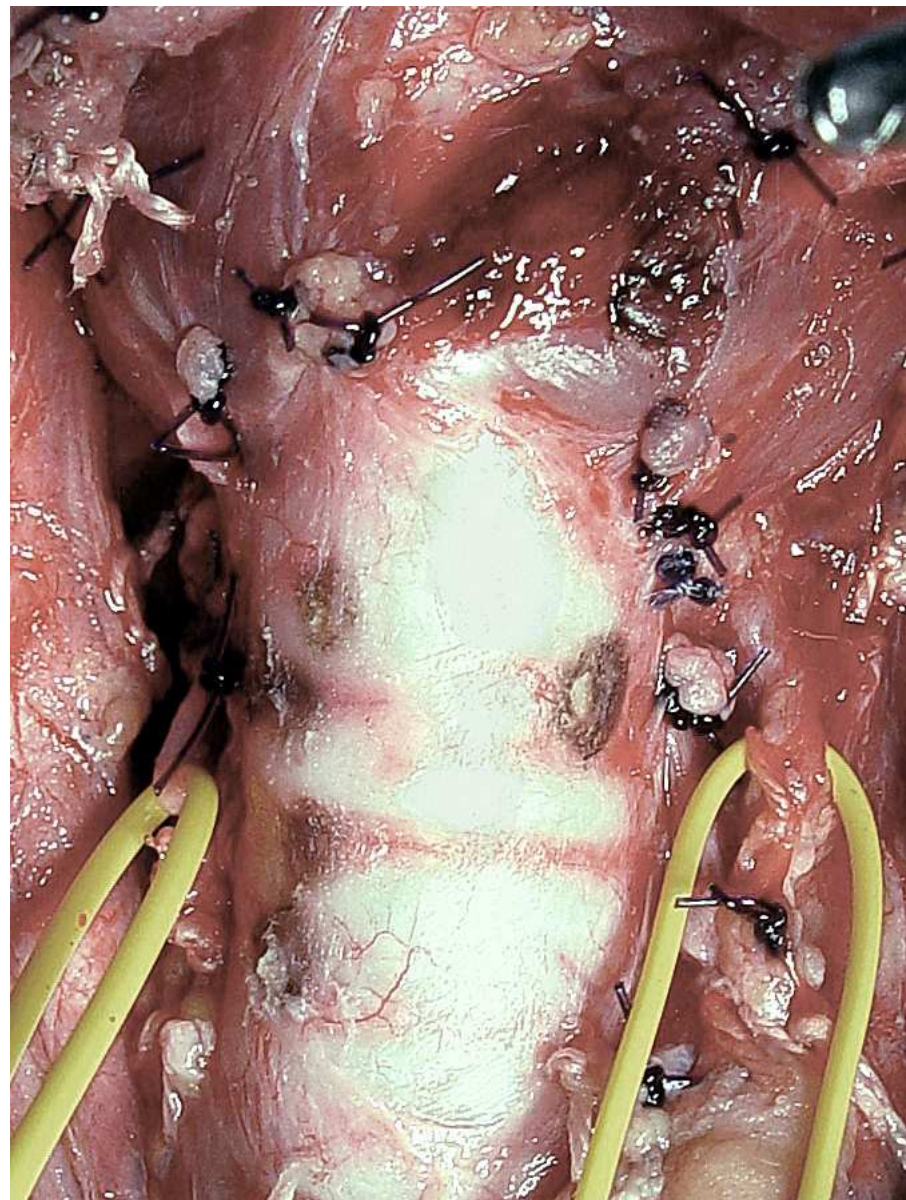


Lobo sinistro - Istmo - Lobo destro (superficie posteriore)

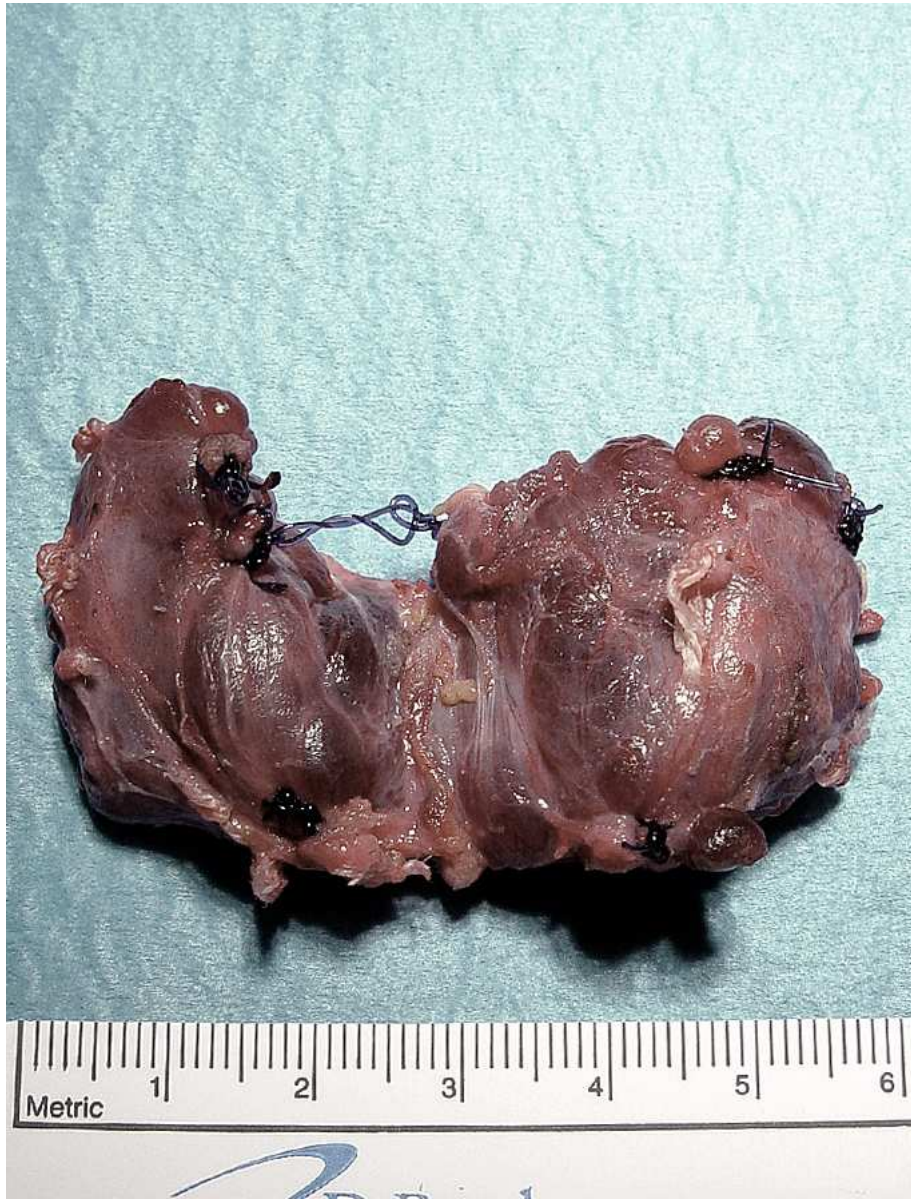

M.G. • Anni: 34 - F • Record: 80 • 24-07-2004

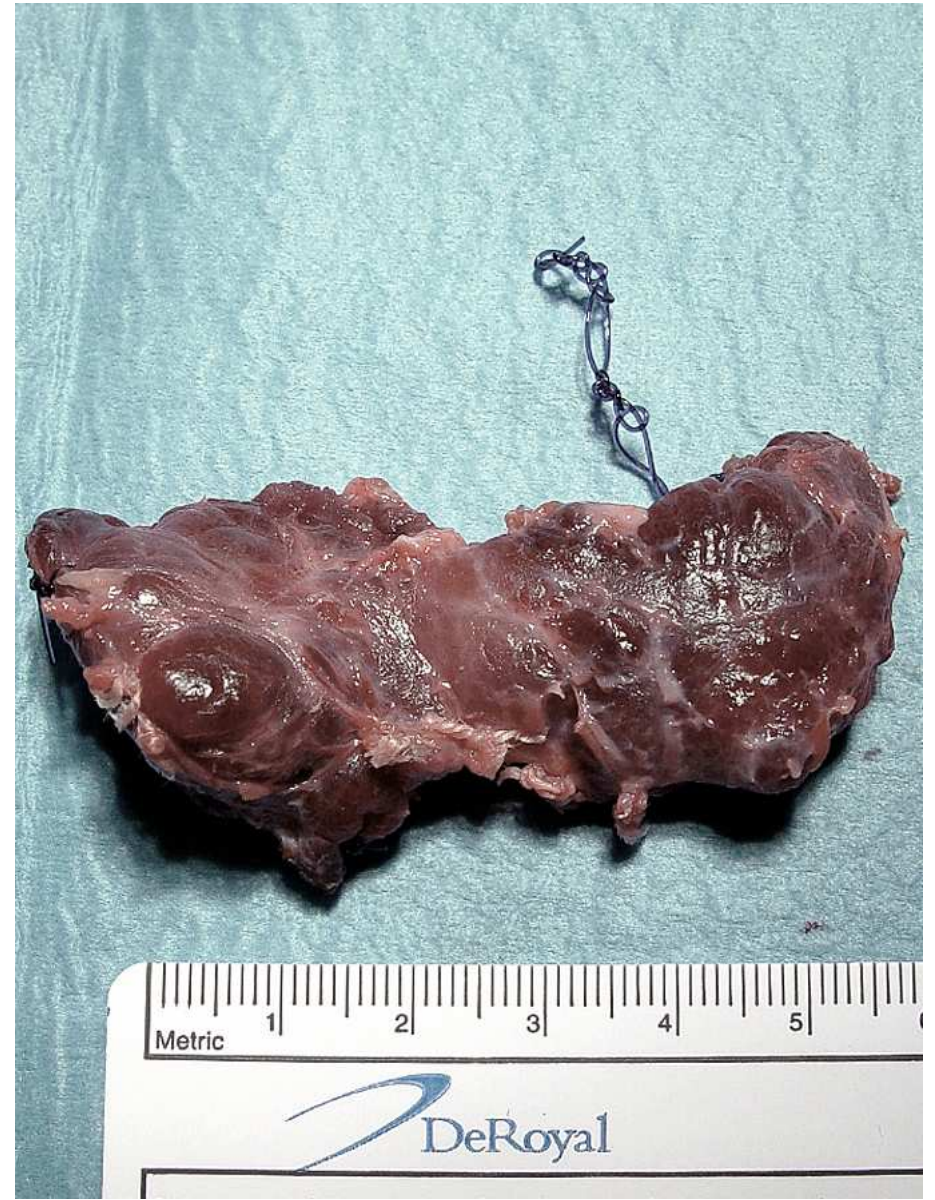Tiroidectomia totale extracapsulare per carcinoma papillifero del lobo sn (T1bN0G2)



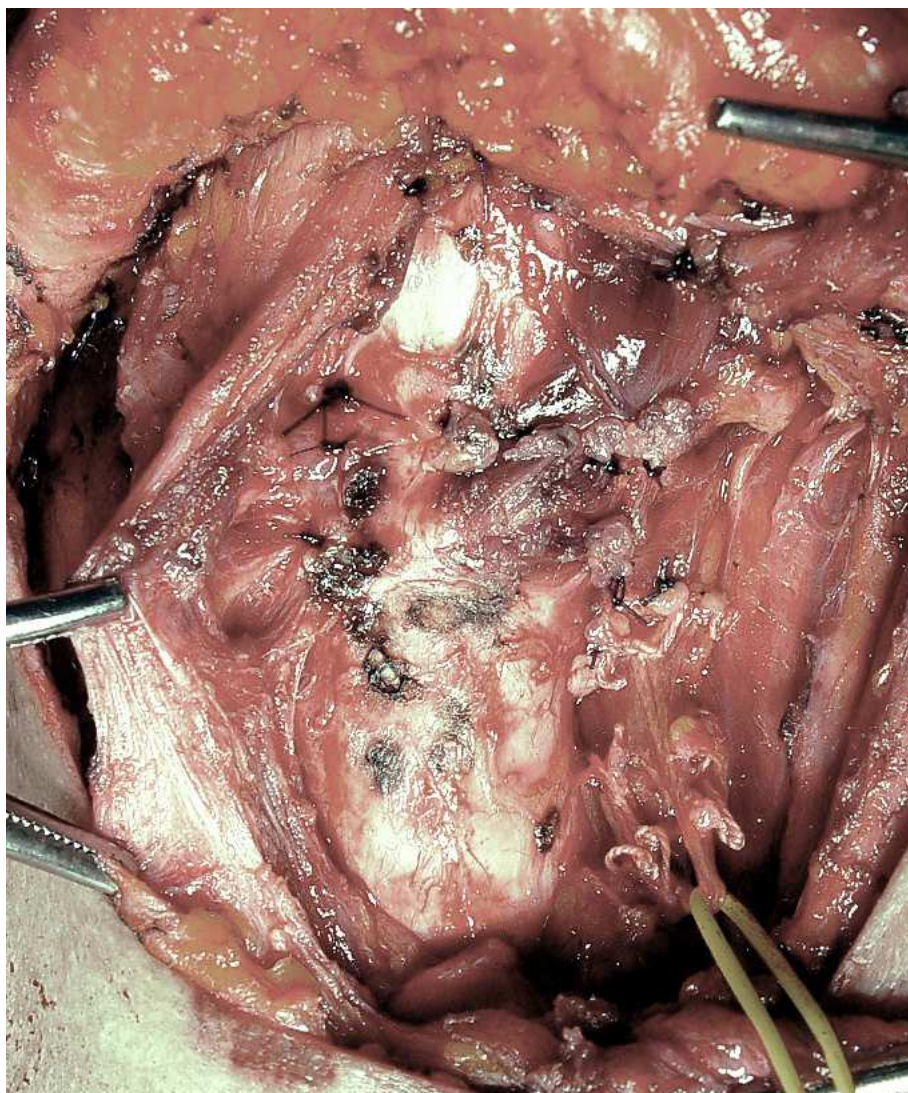
Isolamento dei nervi laringei inferiori (ricorrenti)



Lobo destro - Istmo - Lobo sinistro (superficie anteriore)

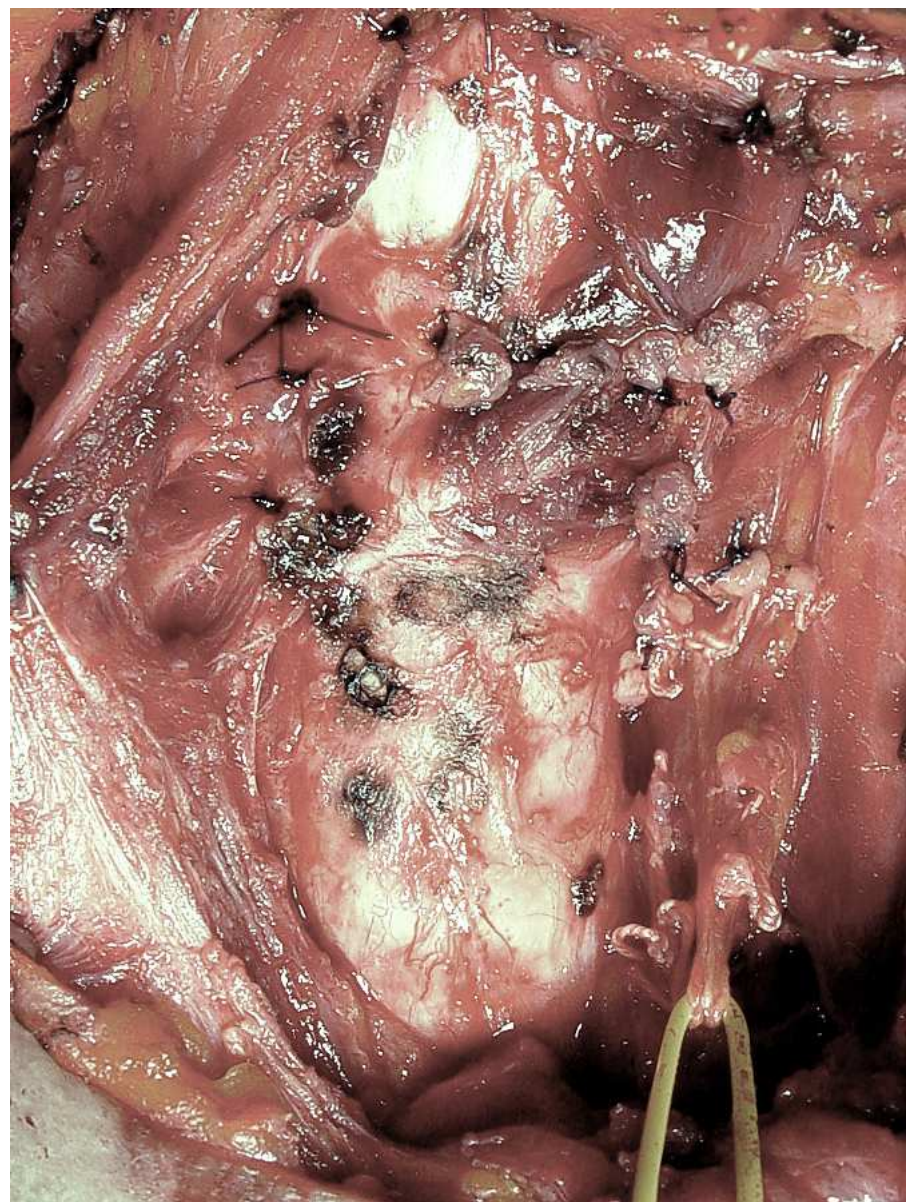

Lobo sinistro - Istmo - Lobo destro (superficie posteriore)

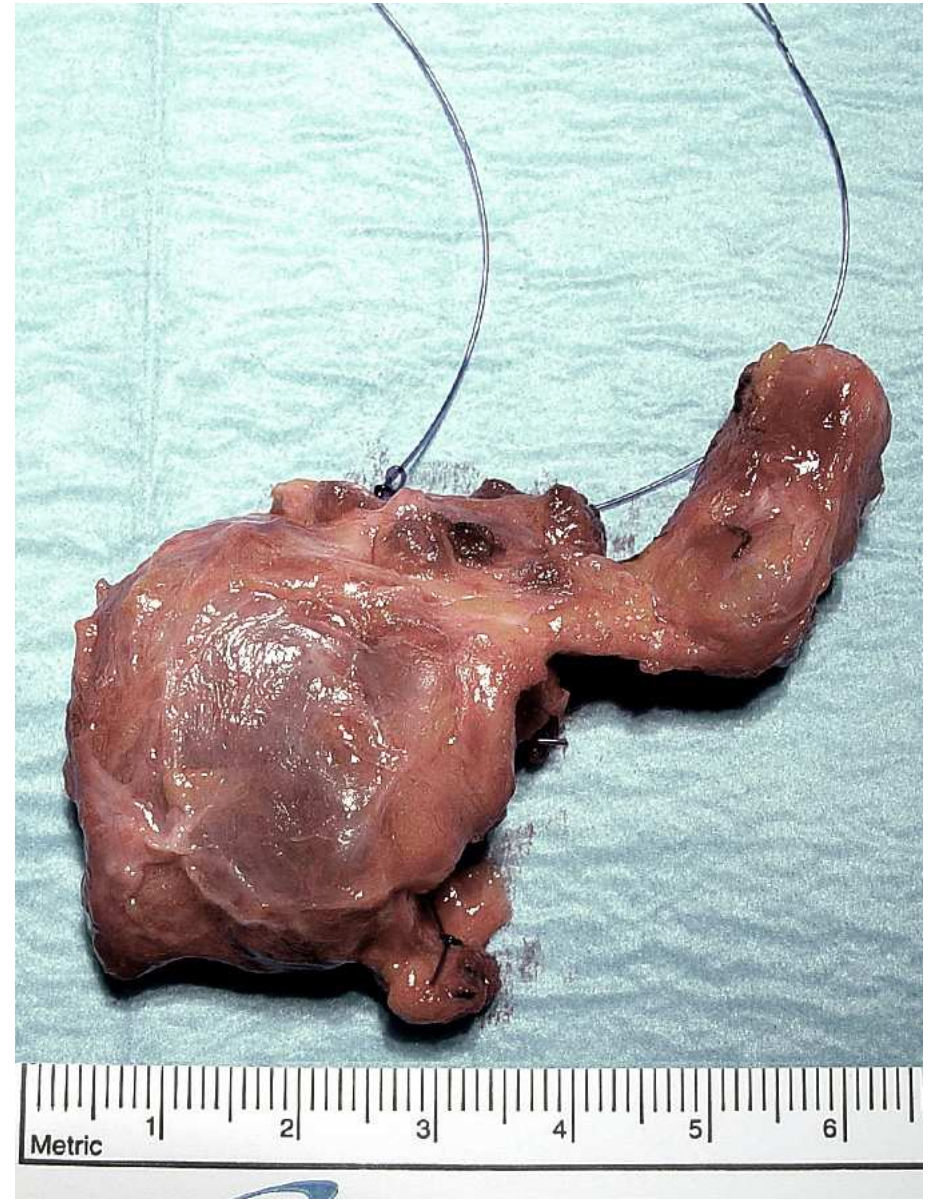
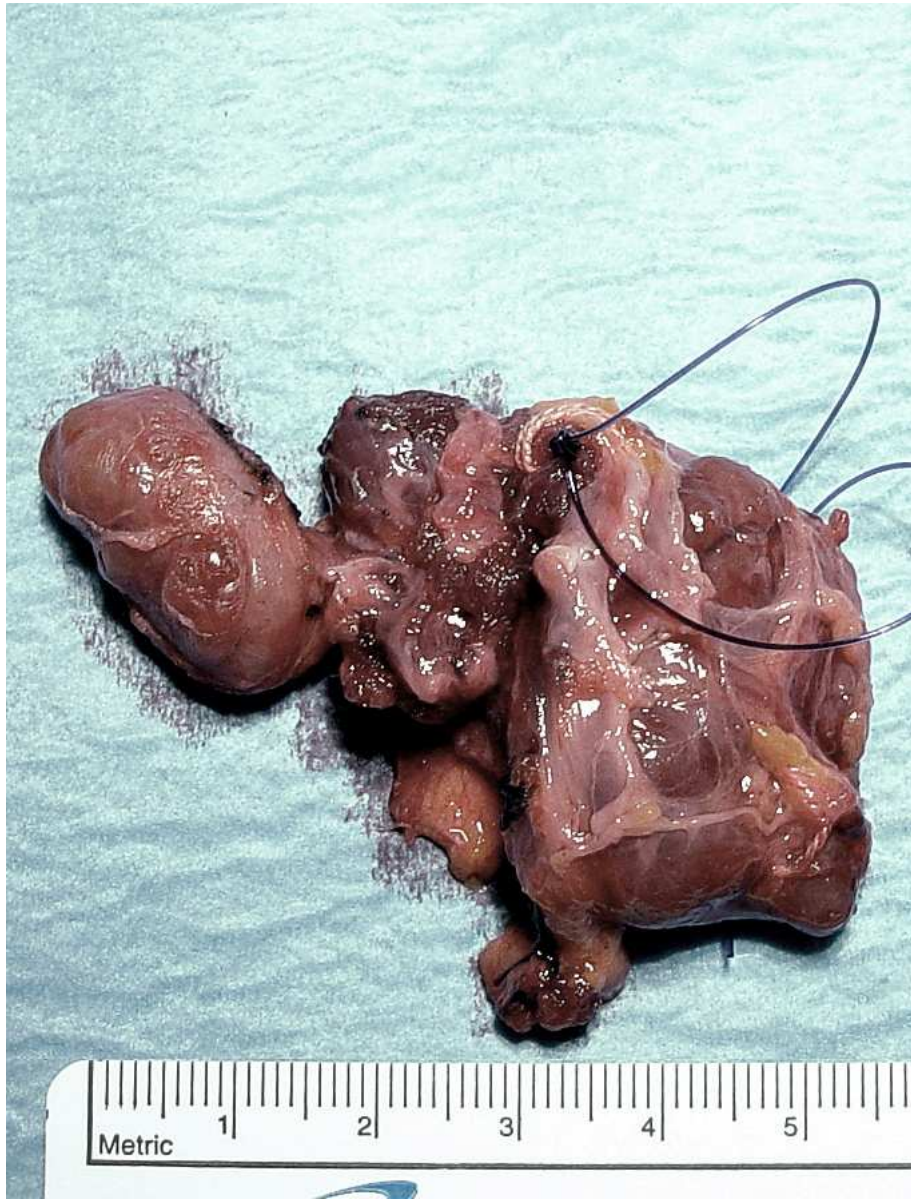


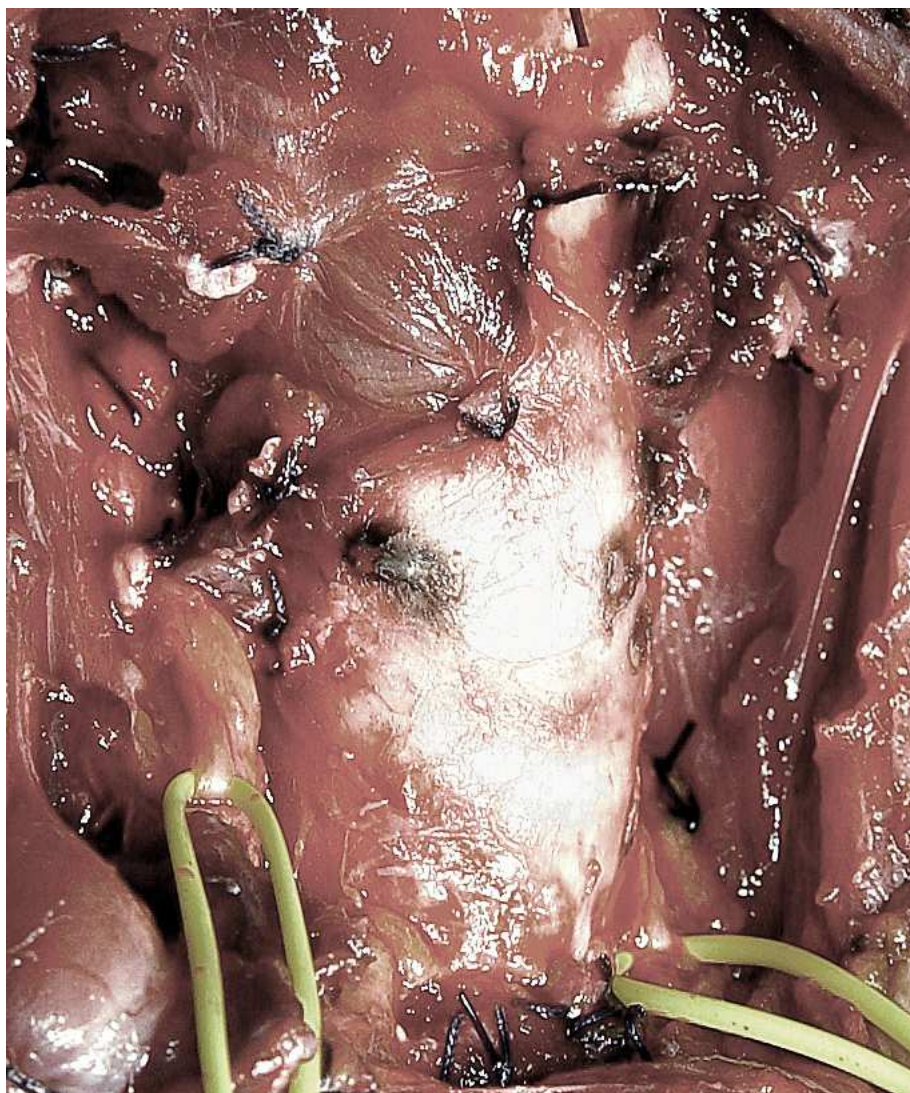
S.A. · Anni: 58 - F · Record: 81 · 07-12-2004

Lobectomia totale extracapsulare a sn, istmectomia ed asportazione del residuo lobare a dx "en bloc" per gozzo plurinodulare tossico recidivo in lobectomizzata a dx



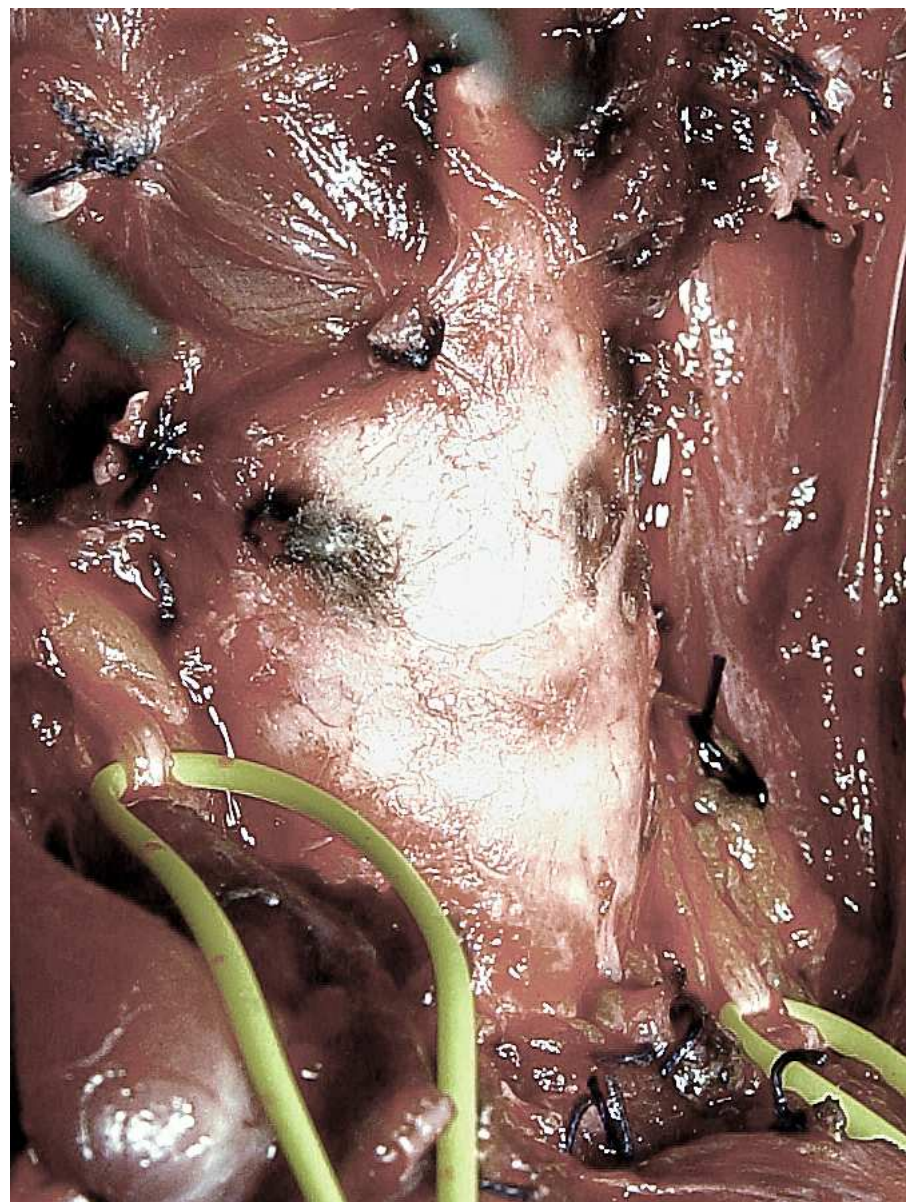




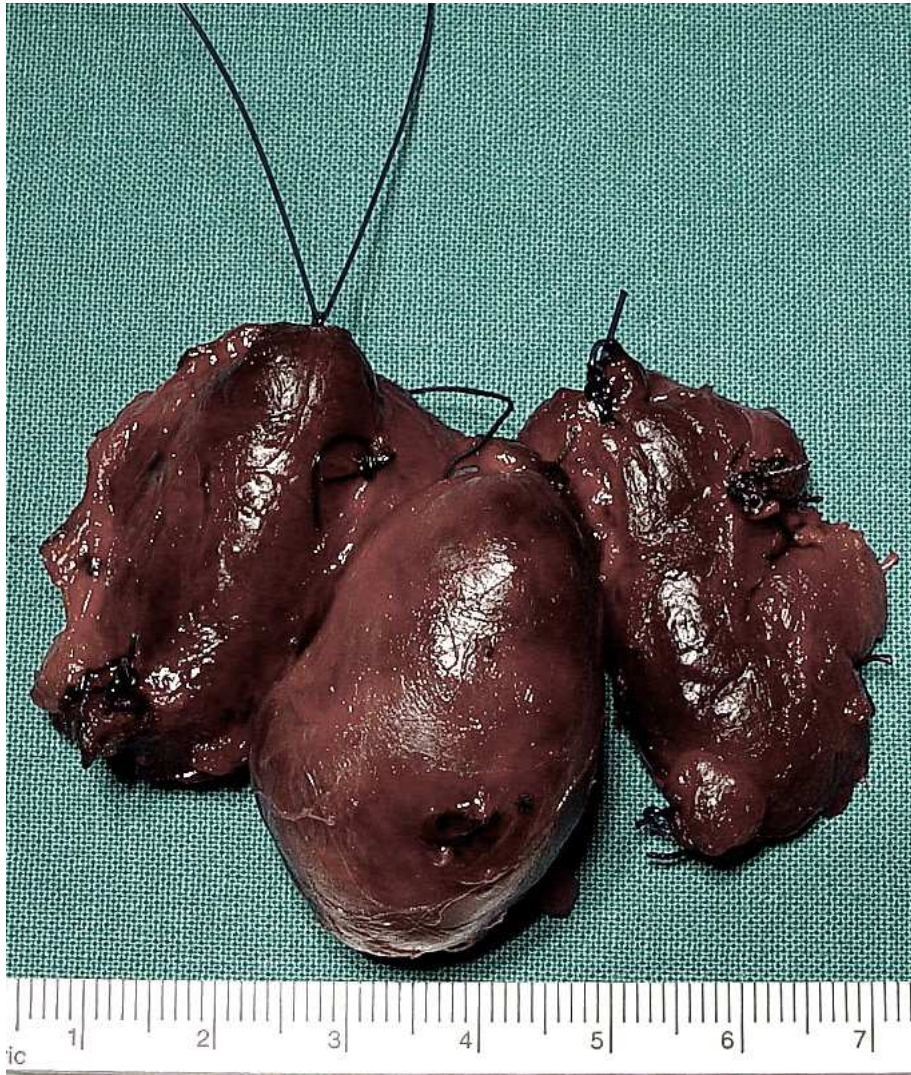


A.M. • Anni: 51 - F • Record: 82 • 21-09-2005

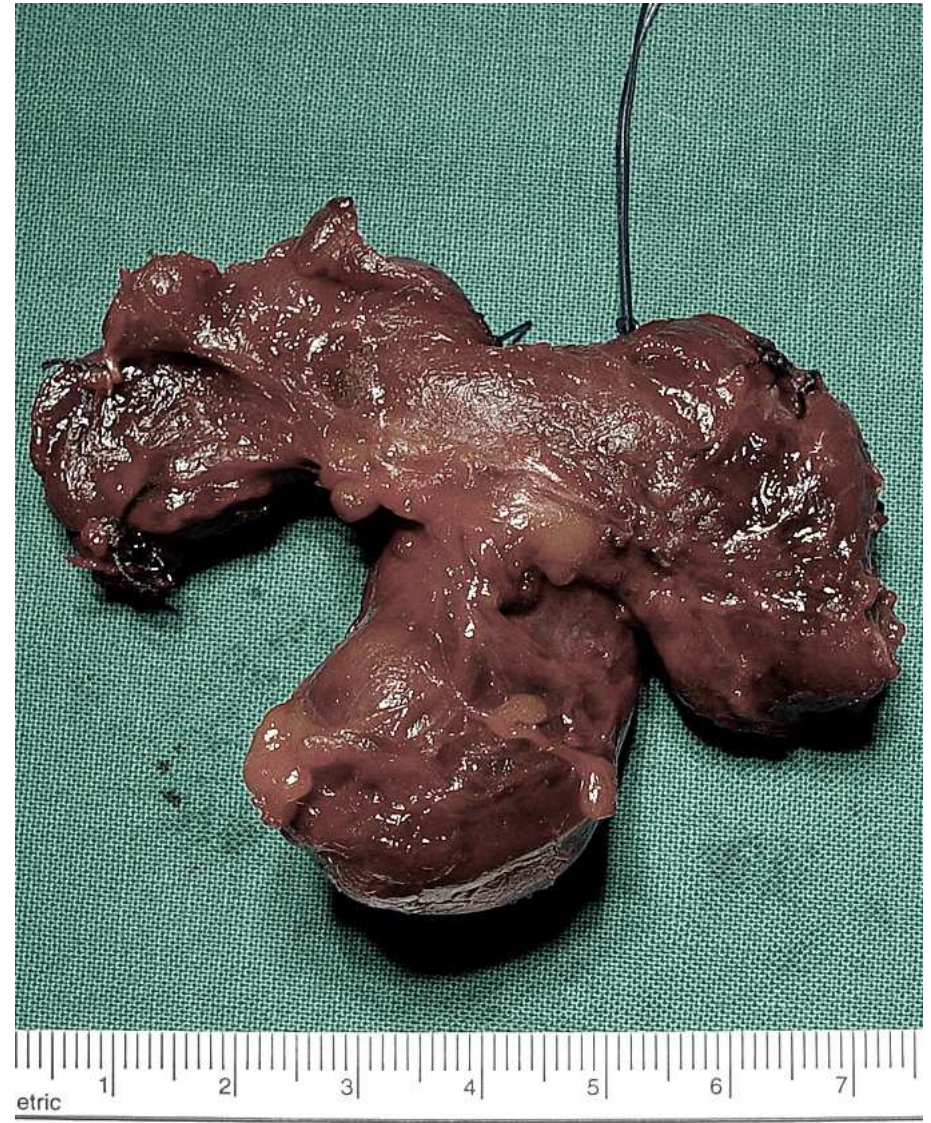
Tiroidectomia totale extracapsulare per gozzo plurinodulare adenomatoso e tiroidite di Hashimoto



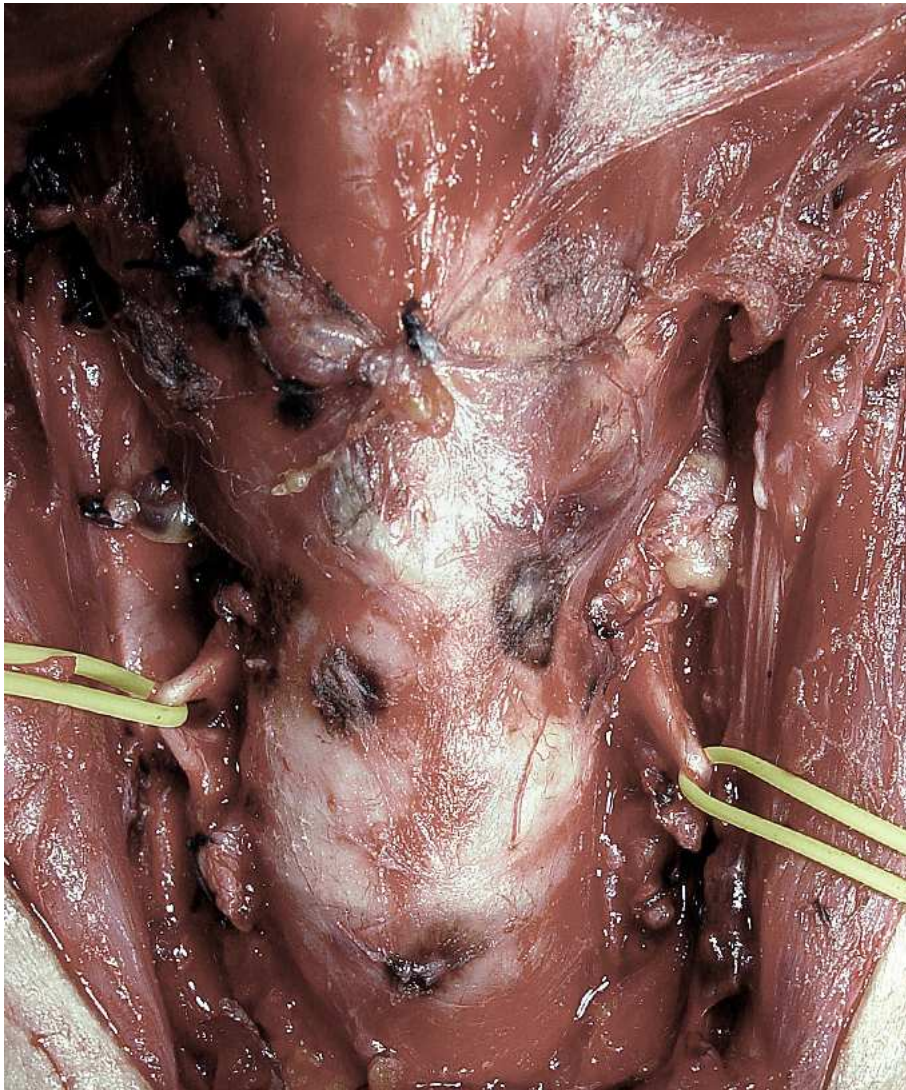
Isolamento dei nervi laringei inferiori (ricorrenti)



Lobo destro - Istmo - Lobo sinistro (superficie anteriore)

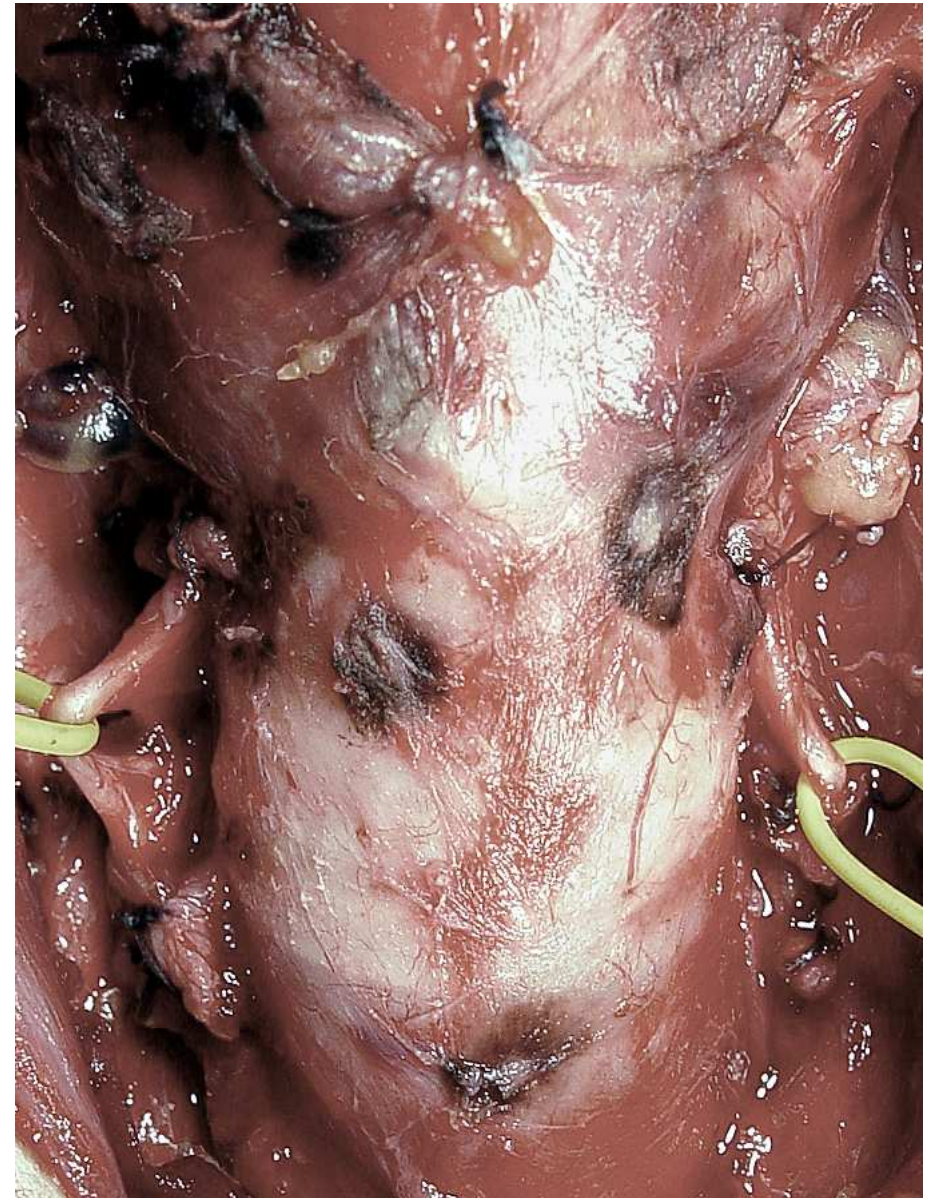


Lobo sinistro - Istmo - Lobo destro (superficie posteriore)

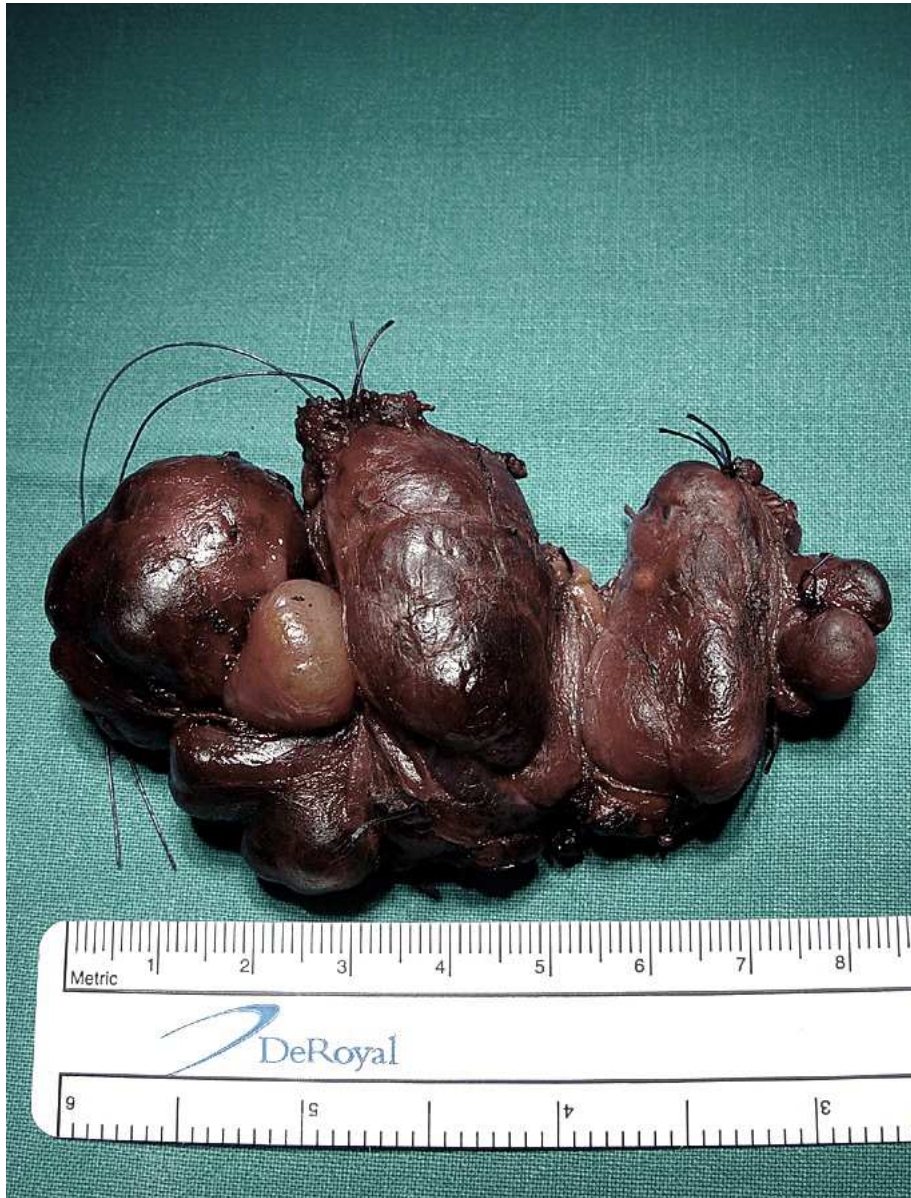

P.M.A. • Anni: 56 - F • Record: 83 • 28-09-2005

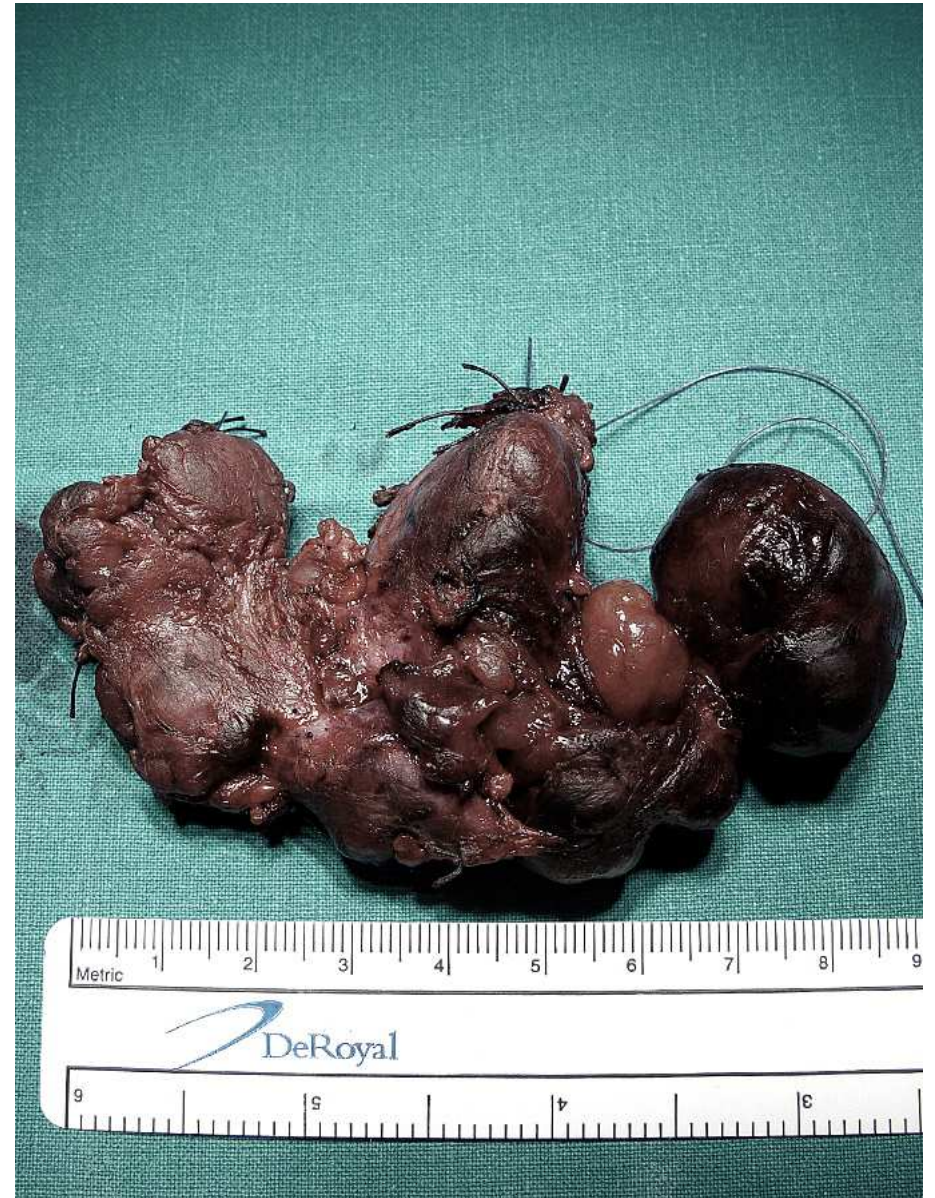Tiroidectomia totale extracapsulare per gozzo plurinodulare pretossico



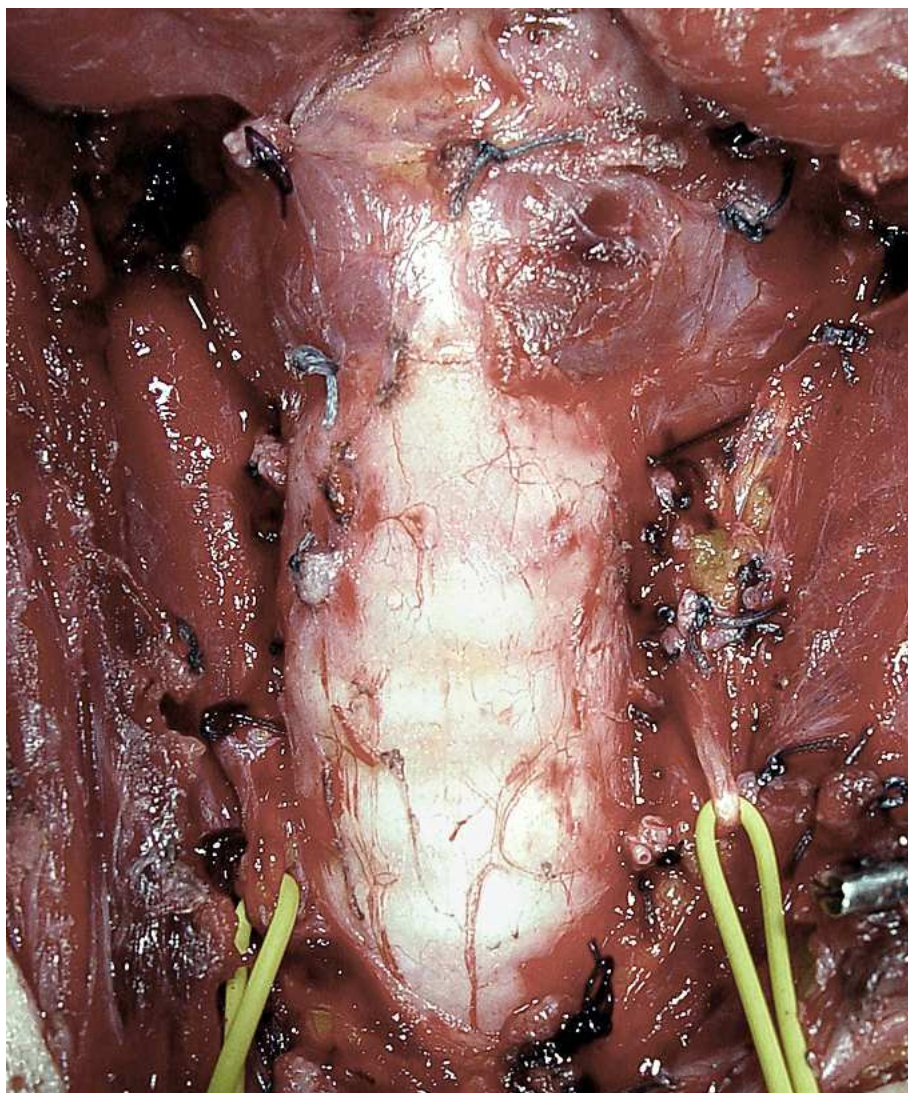
Isolamento dei nervi laringei inferiori (ricorrenti)



Lobo destro - Istmo - Lobo sinistro (superficie anteriore)

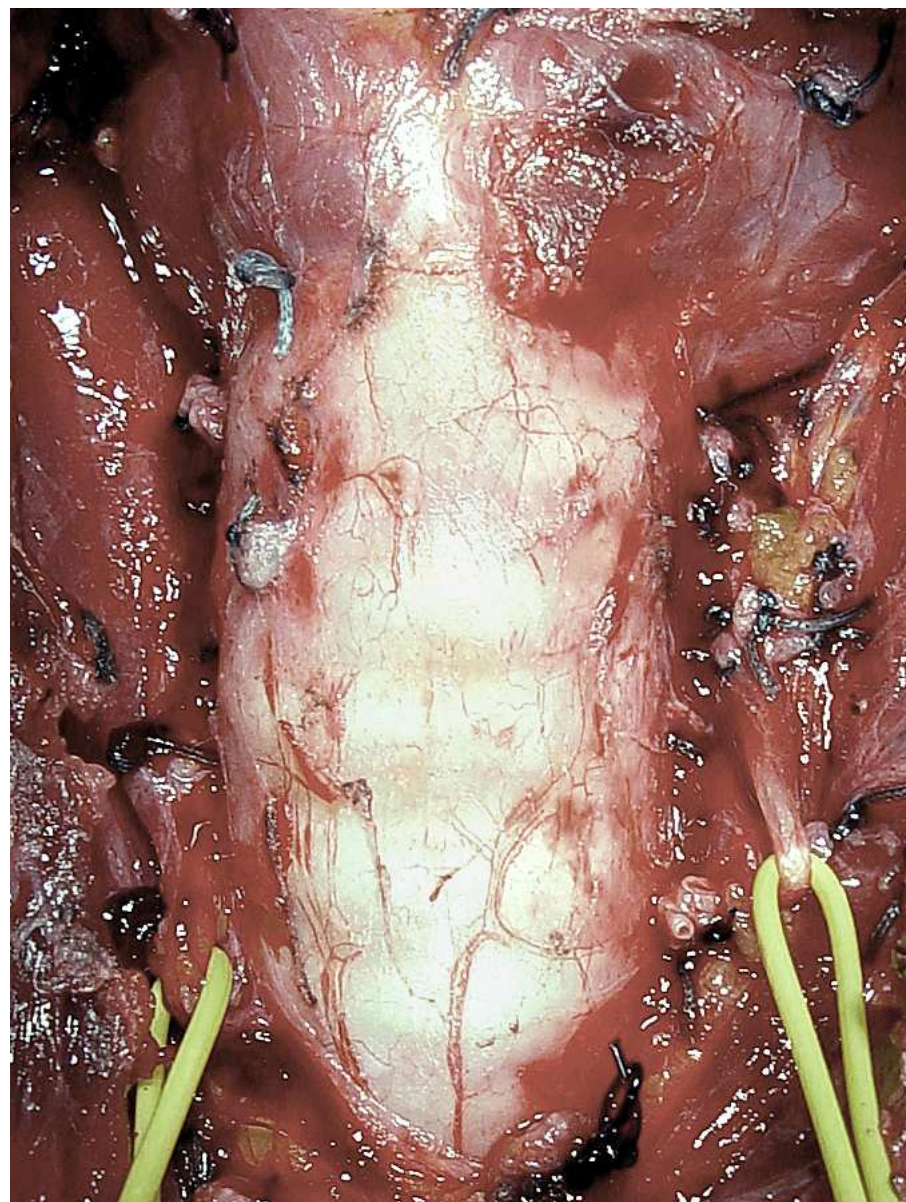


Lobo sinistro - Istmo - Lobo destro (superficie posteriore)

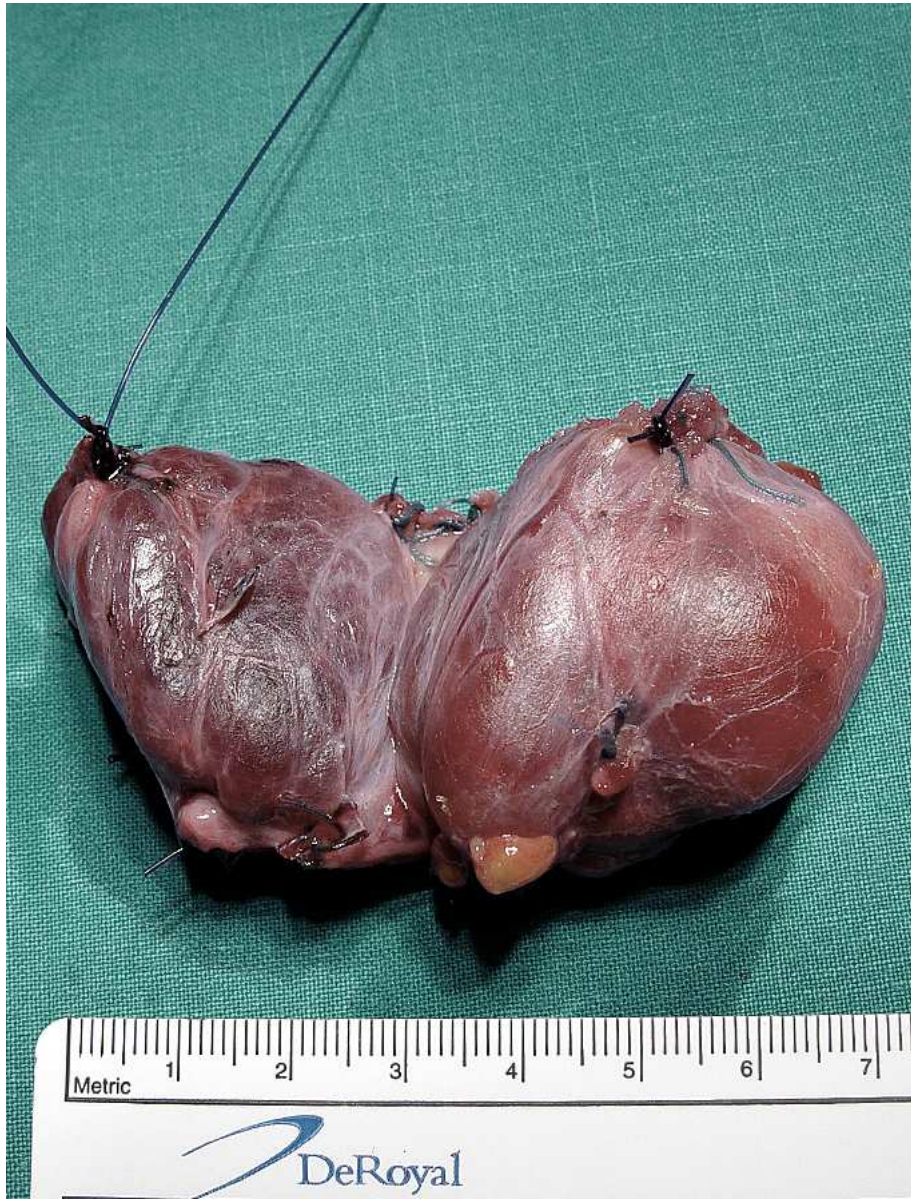


S.V. • Anni: 42 - F • Record: 84 • 05-10-2005

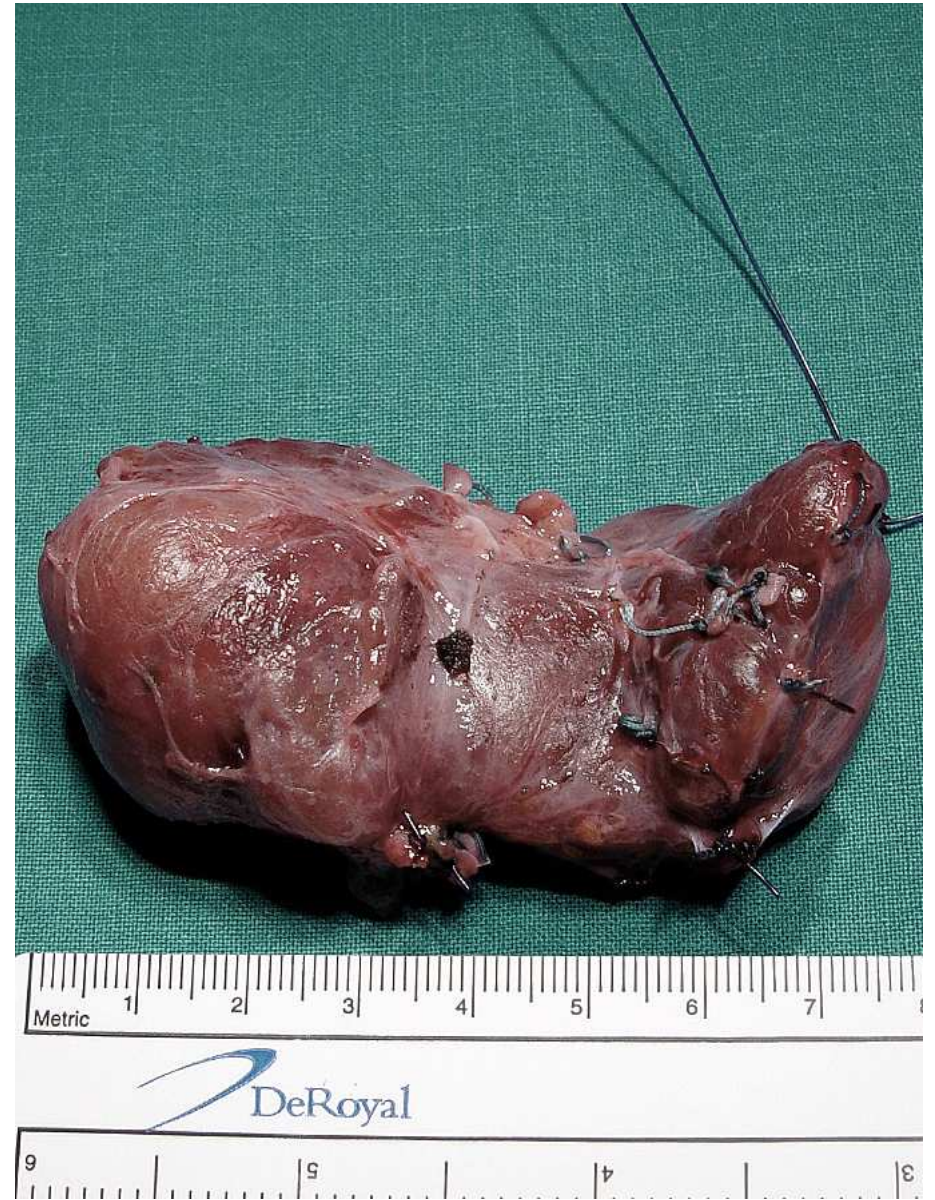
Tiroidectomia totale extracapsulare per adenoma follicolare del lobo sinistro in gozzo plurinodulare



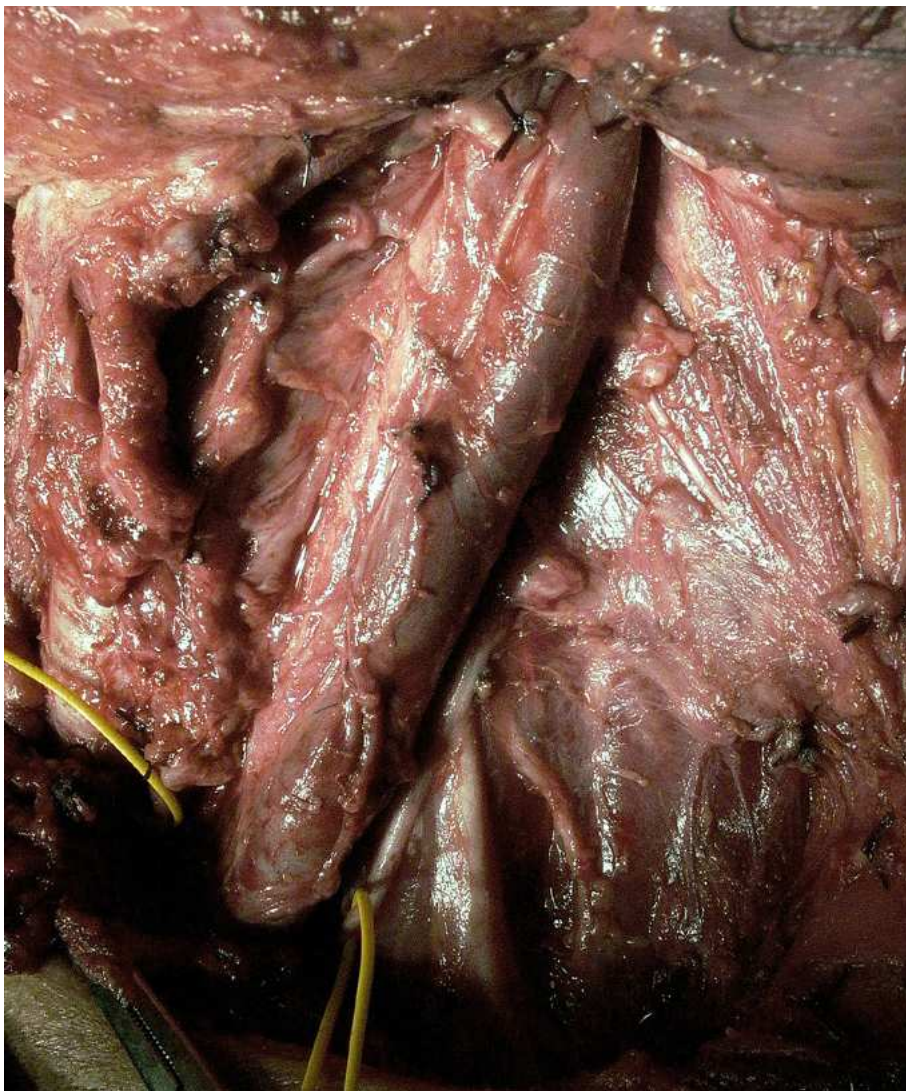
Isolamento dei nervi laringei inferiori (ricorrenti)



Lobo destro - Istmo - Lobo sinistro (superficie anteriore)

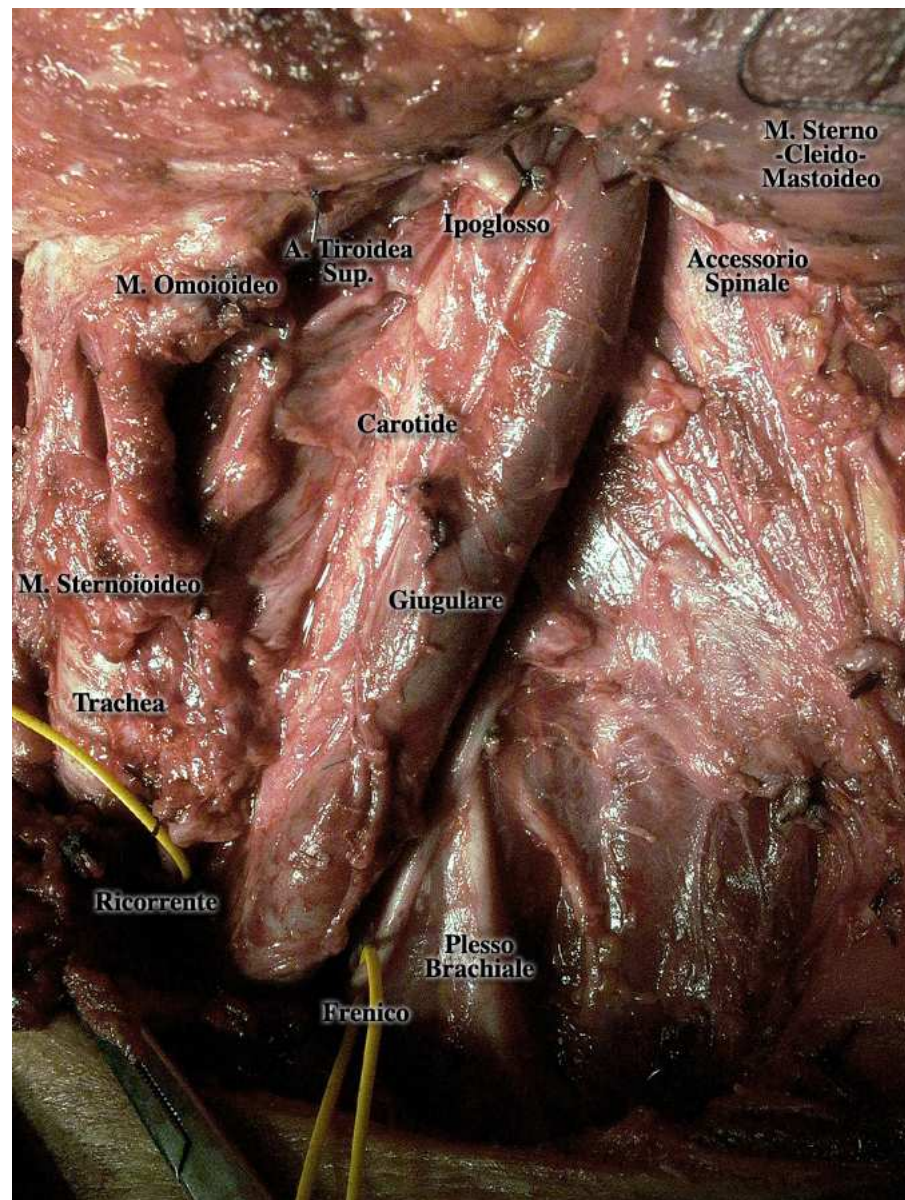


Lobo sinistro - Istmo - Lobo destro (superficie posteriore)

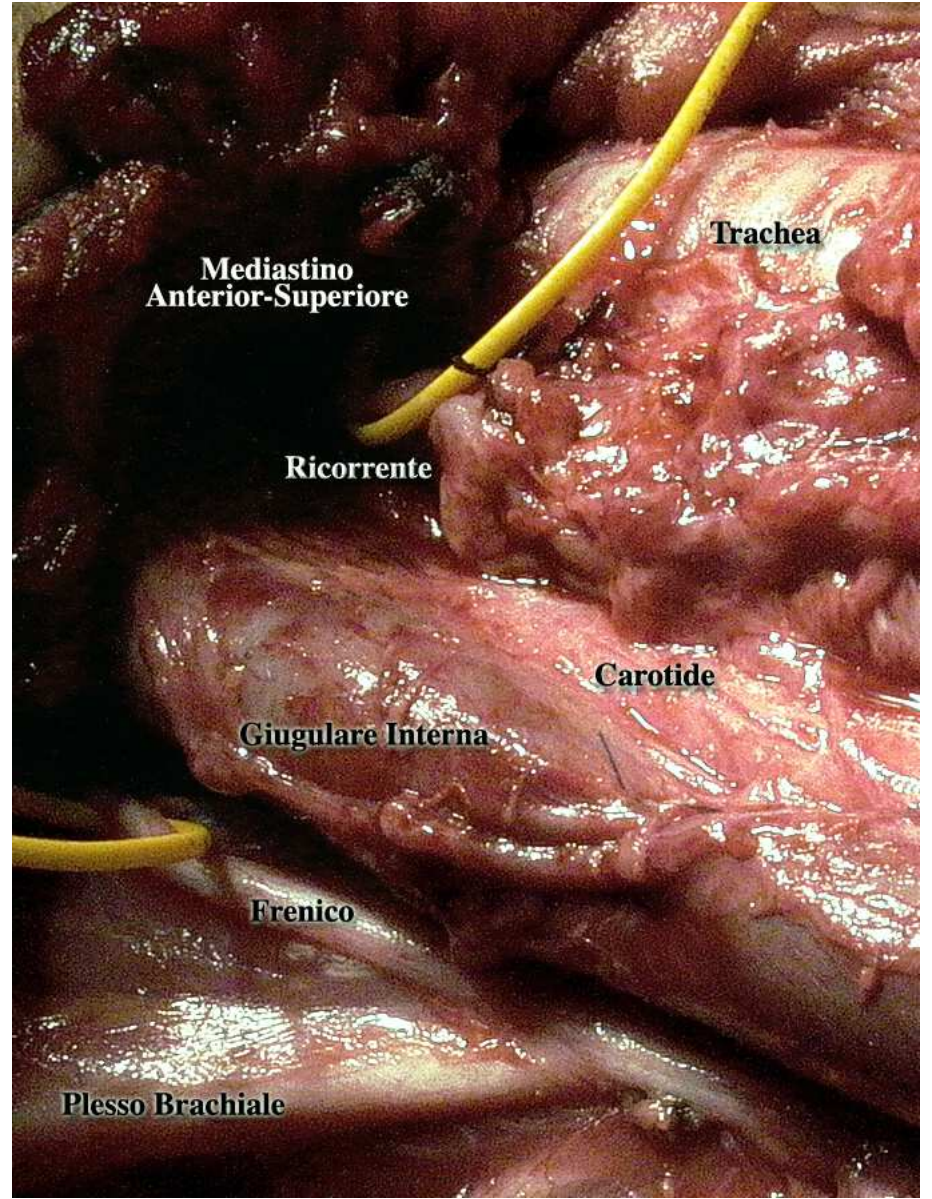
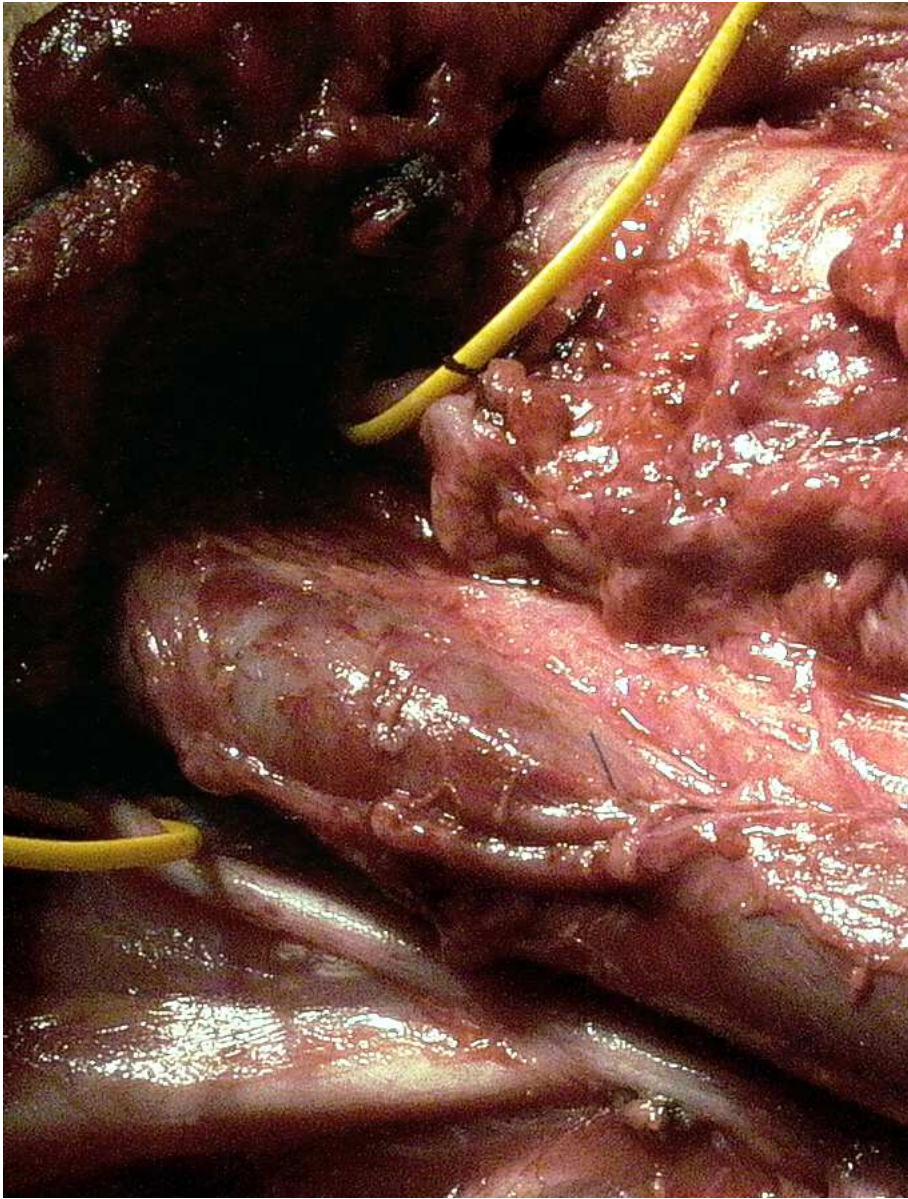


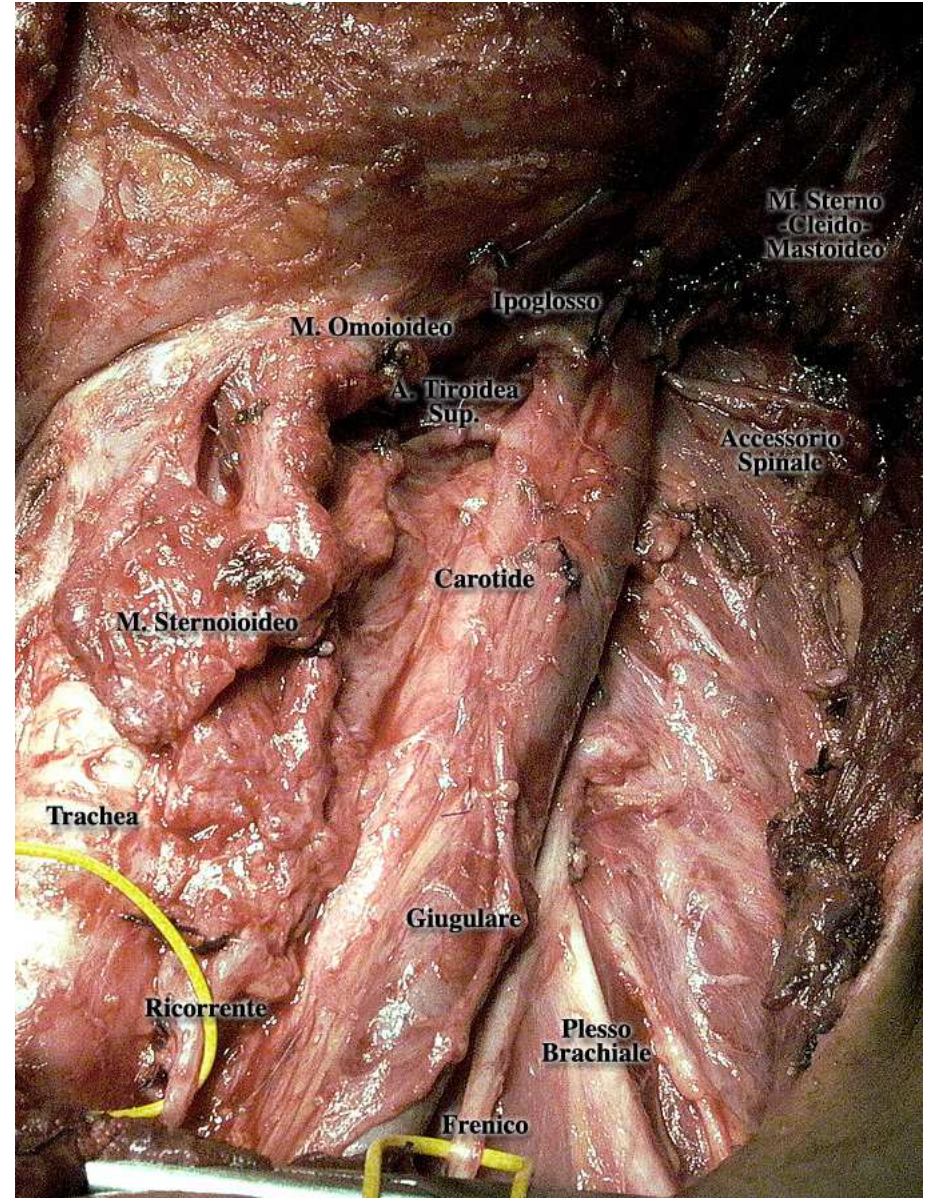
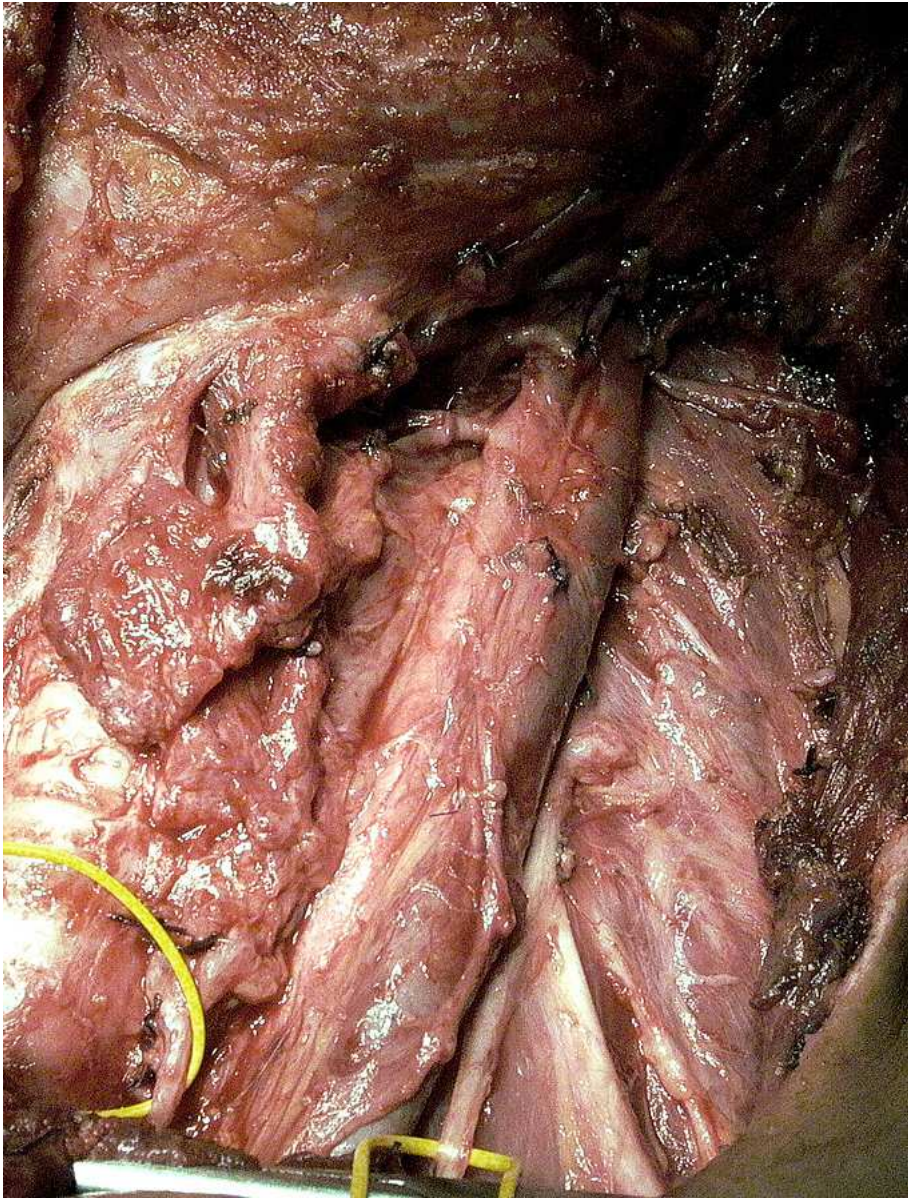
M.G. • Anni: 35 - F • Record: 85 • 12-10-2005

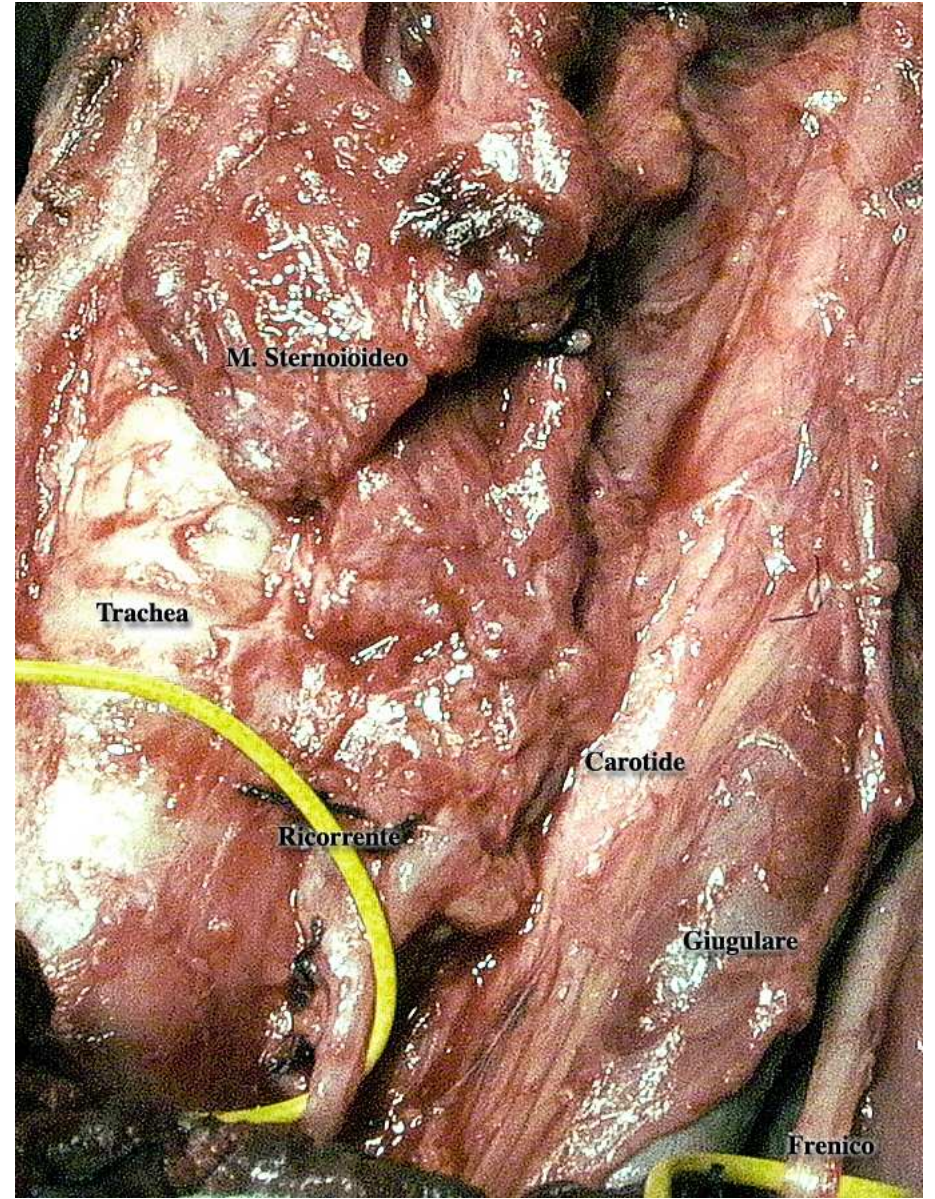
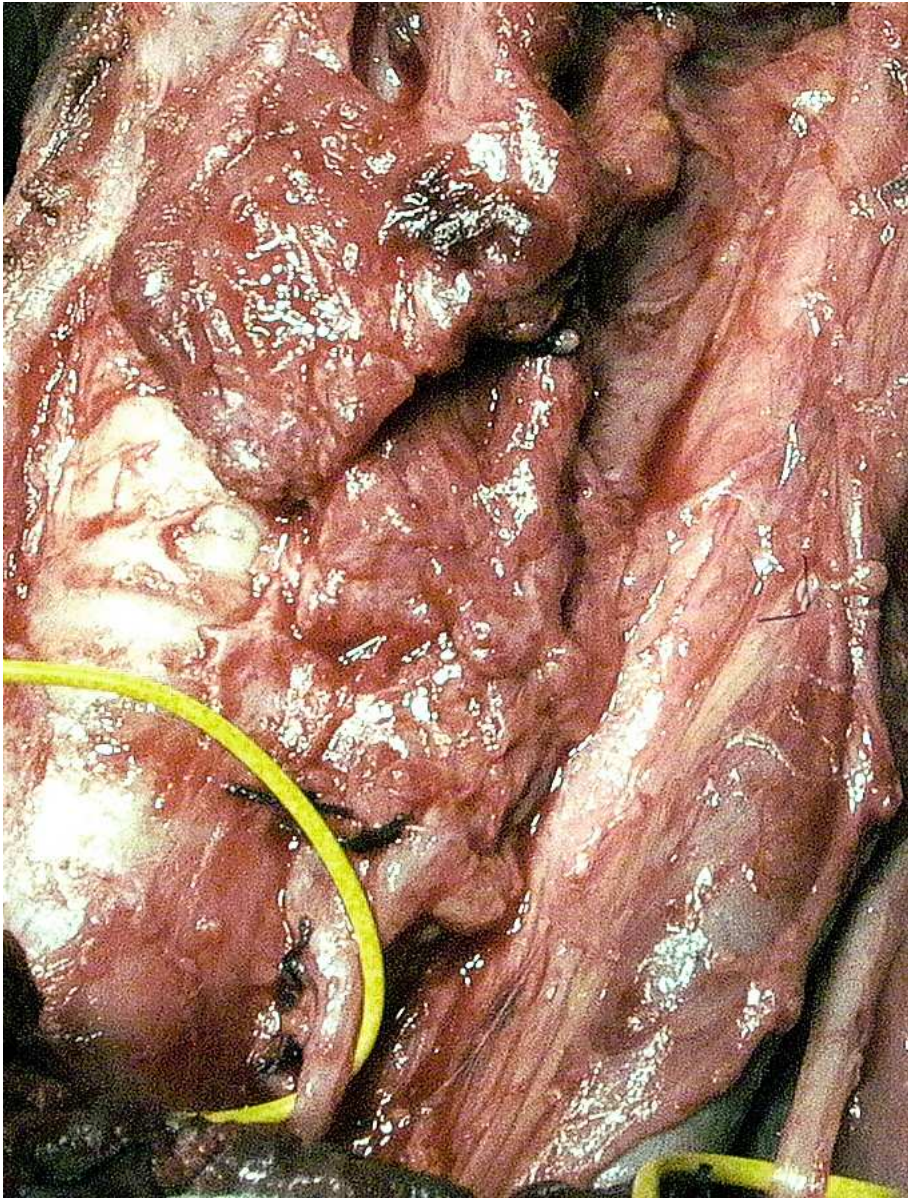
Linfectomia cervico-mediastinica sn per metastasi linfonodali LC in operata per carcinoma papillifero del lobo sn della tiroide

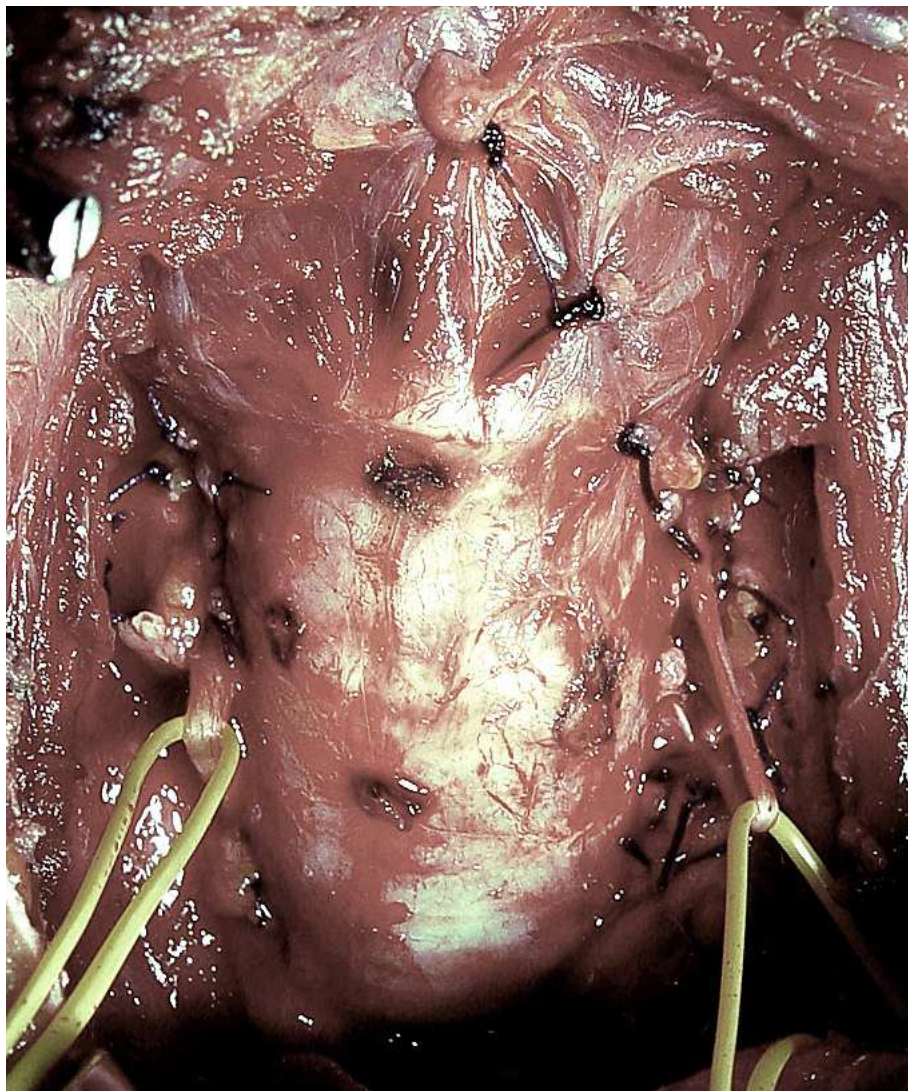






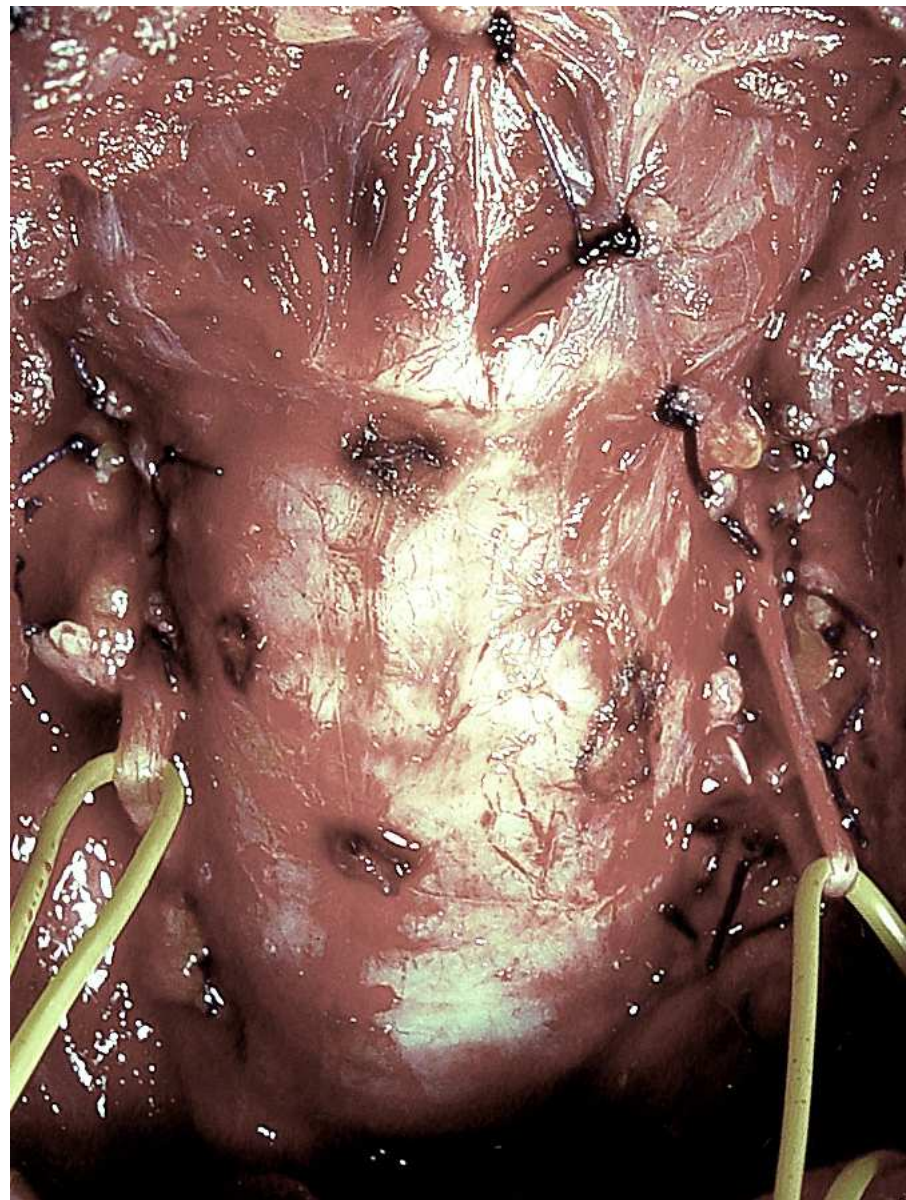




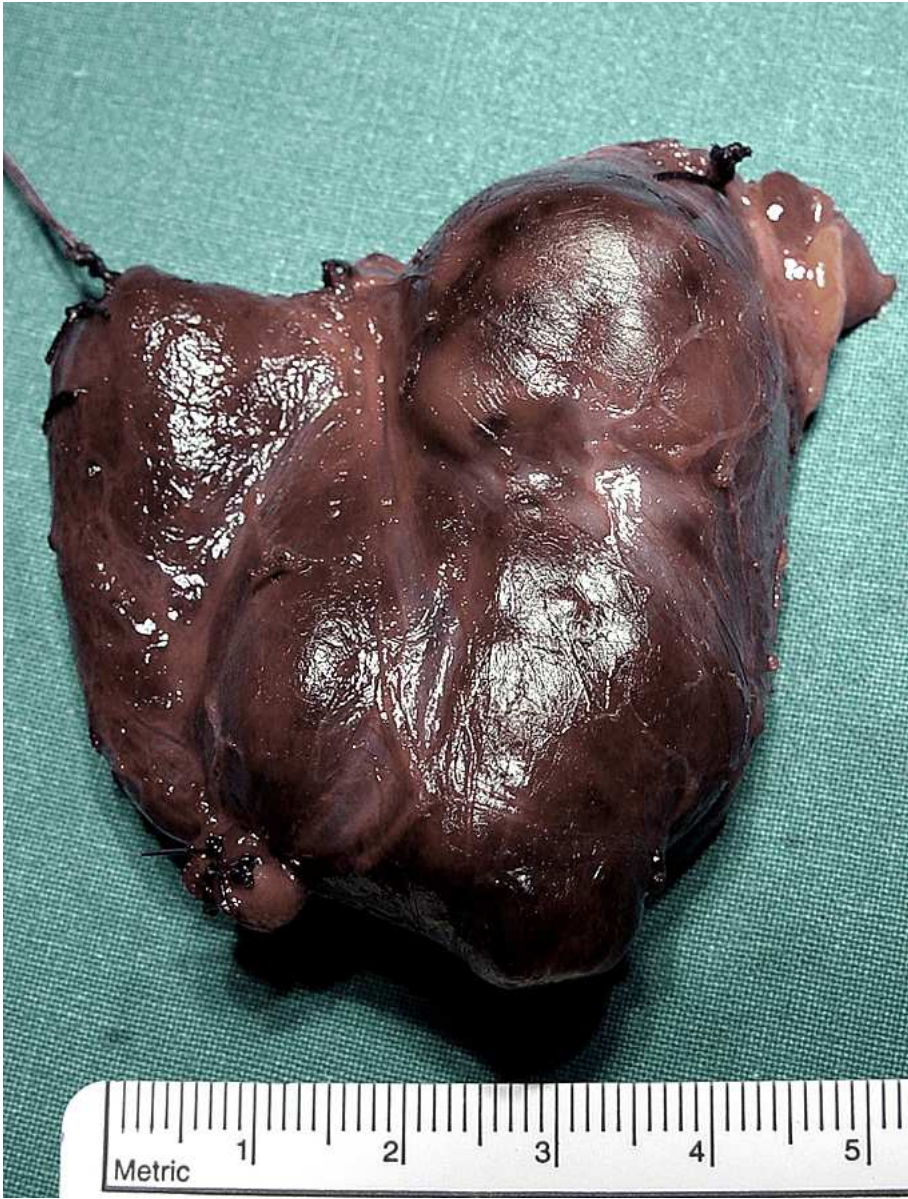


V.A. • Anni: 43 - F • Record: 86 • 19-10-2005

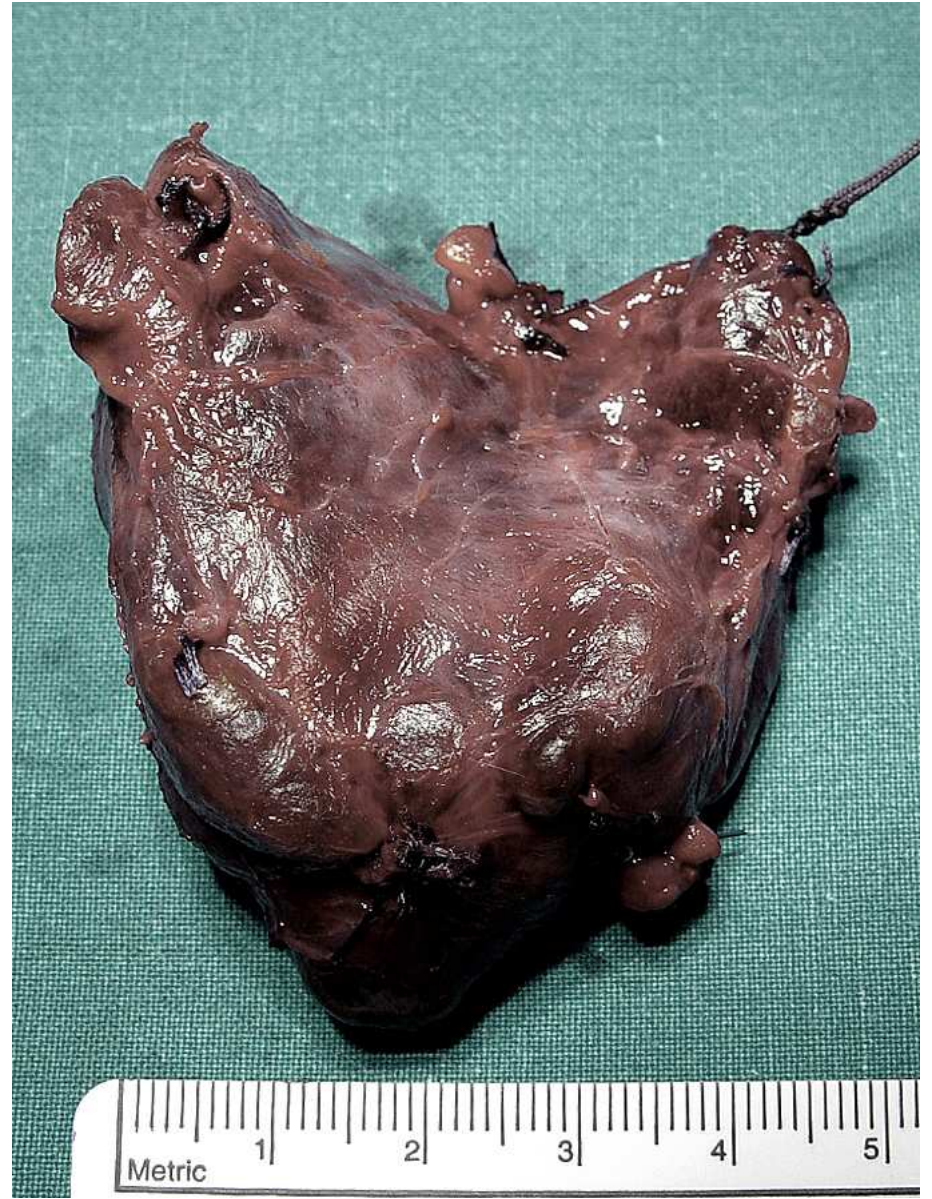
Tiroidectomia totale extracapsulare per gozzo plurinodulare pretossico plongeant



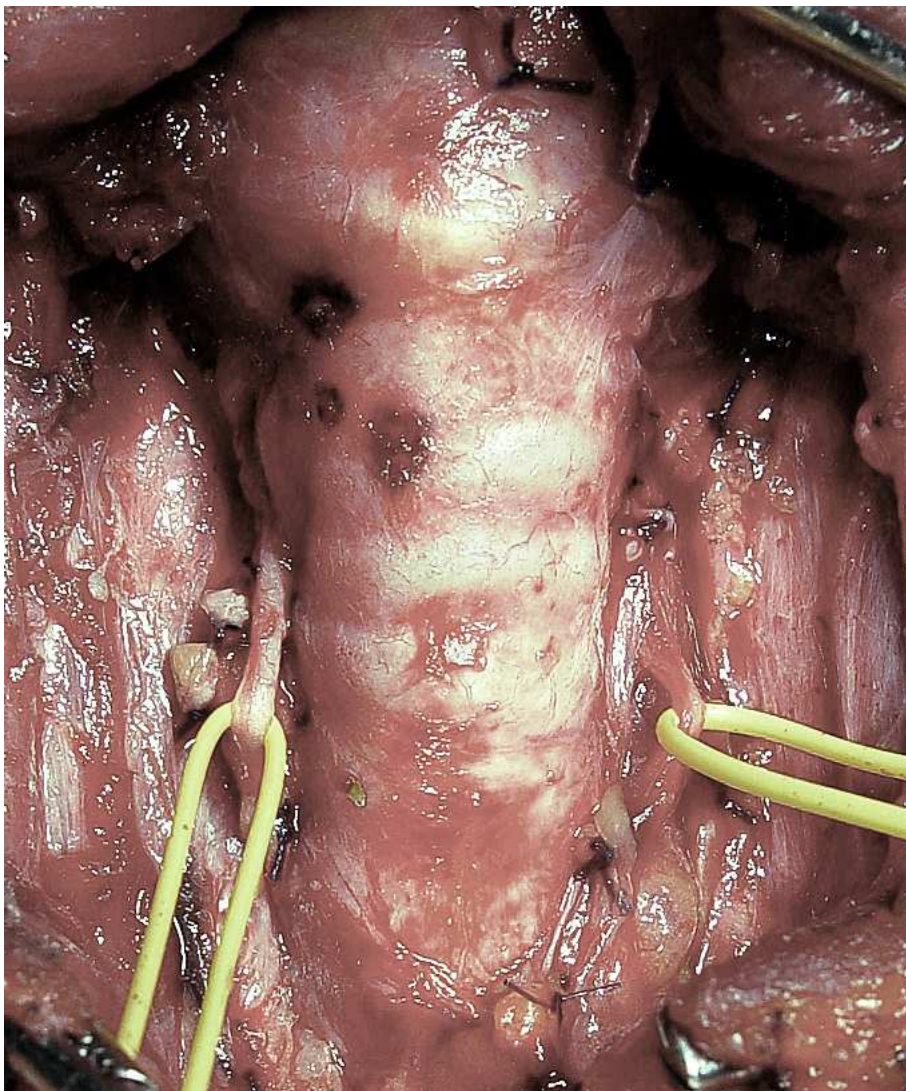
Isolamento dei nervi laringei inferiori (ricorrenti)



Lobo destro - Istmo - Lobo sinistro (superficie anteriore)

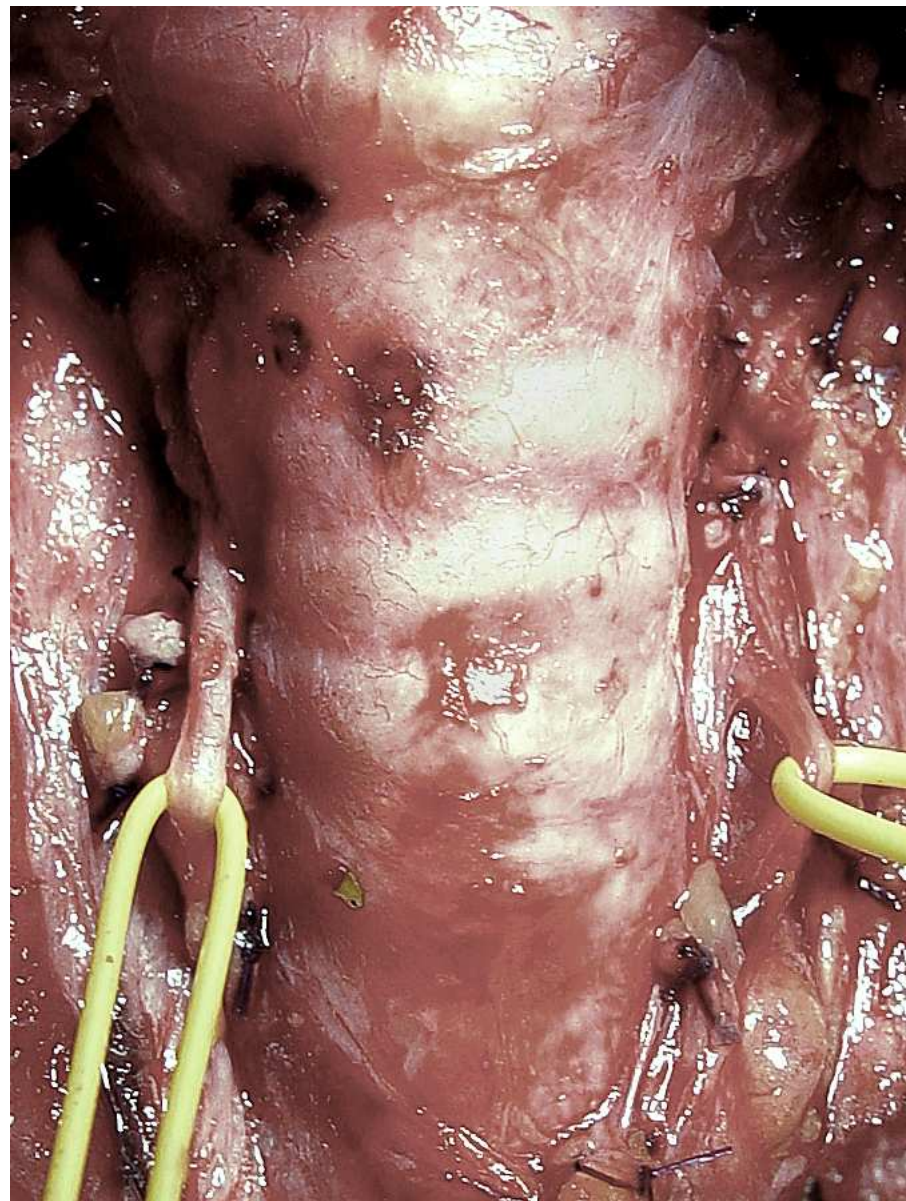


Lobo sinistro - Istmo - Lobo destro (superficie posteriore)

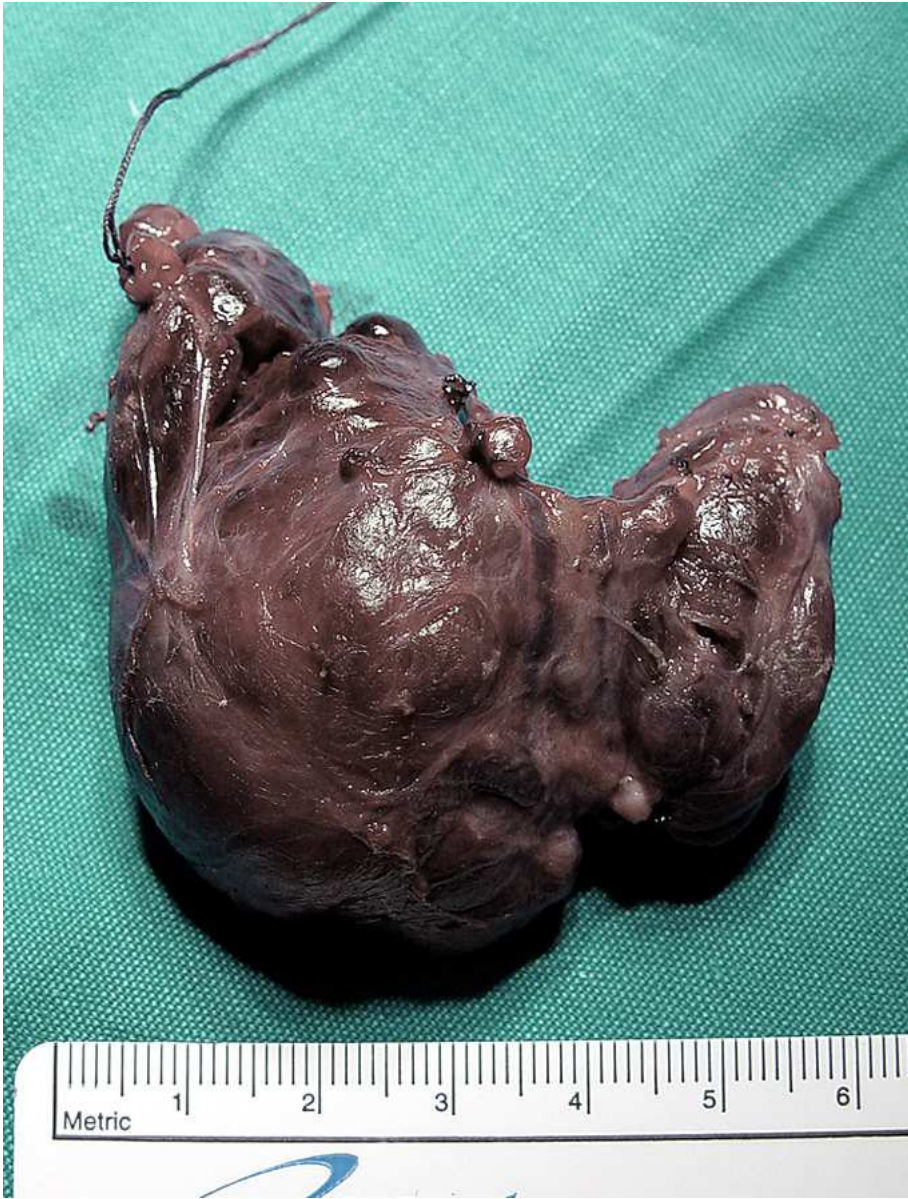

C.T. • Anni: 35 - F • Record: 87 • 09-11-2005

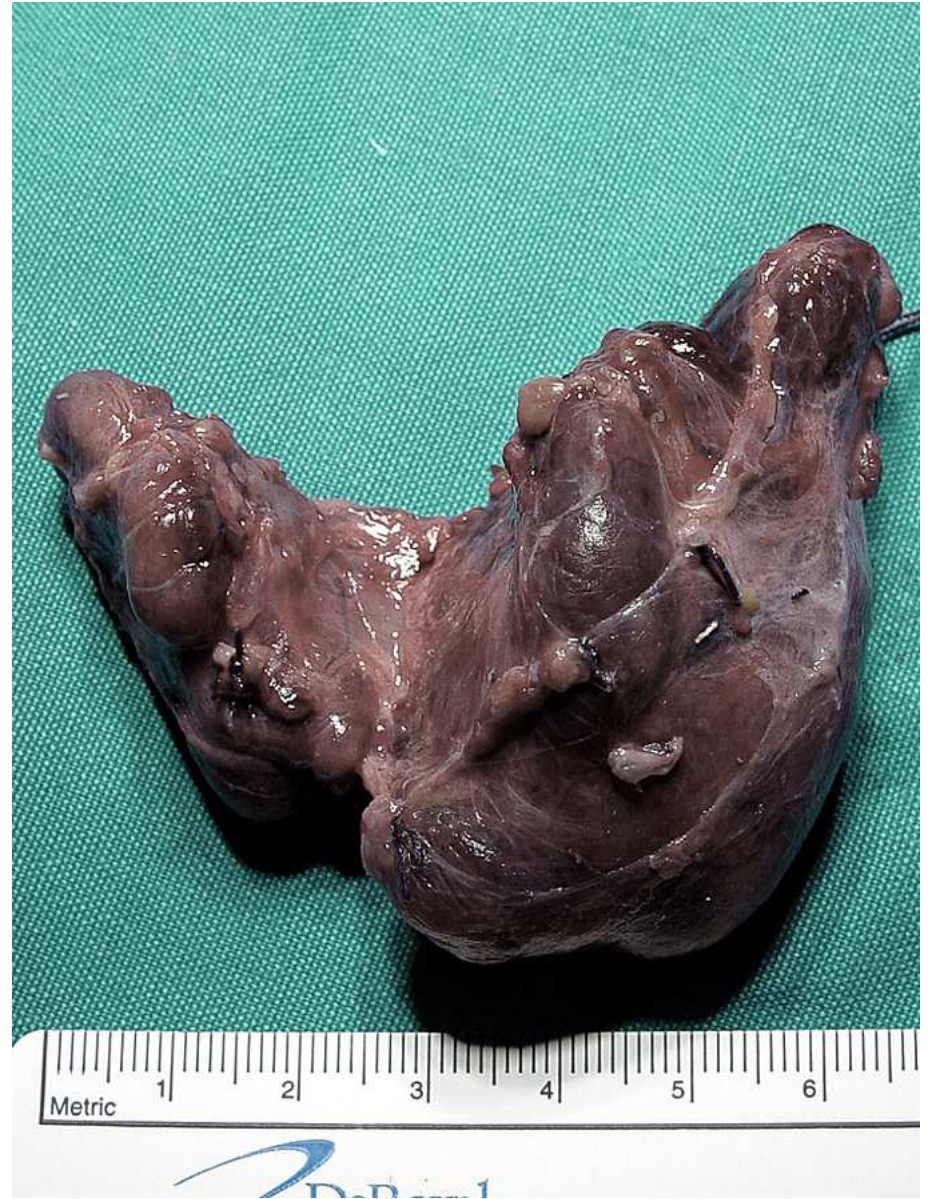Tiroidectomia totale extracapsulare per gozzo plurinodulare



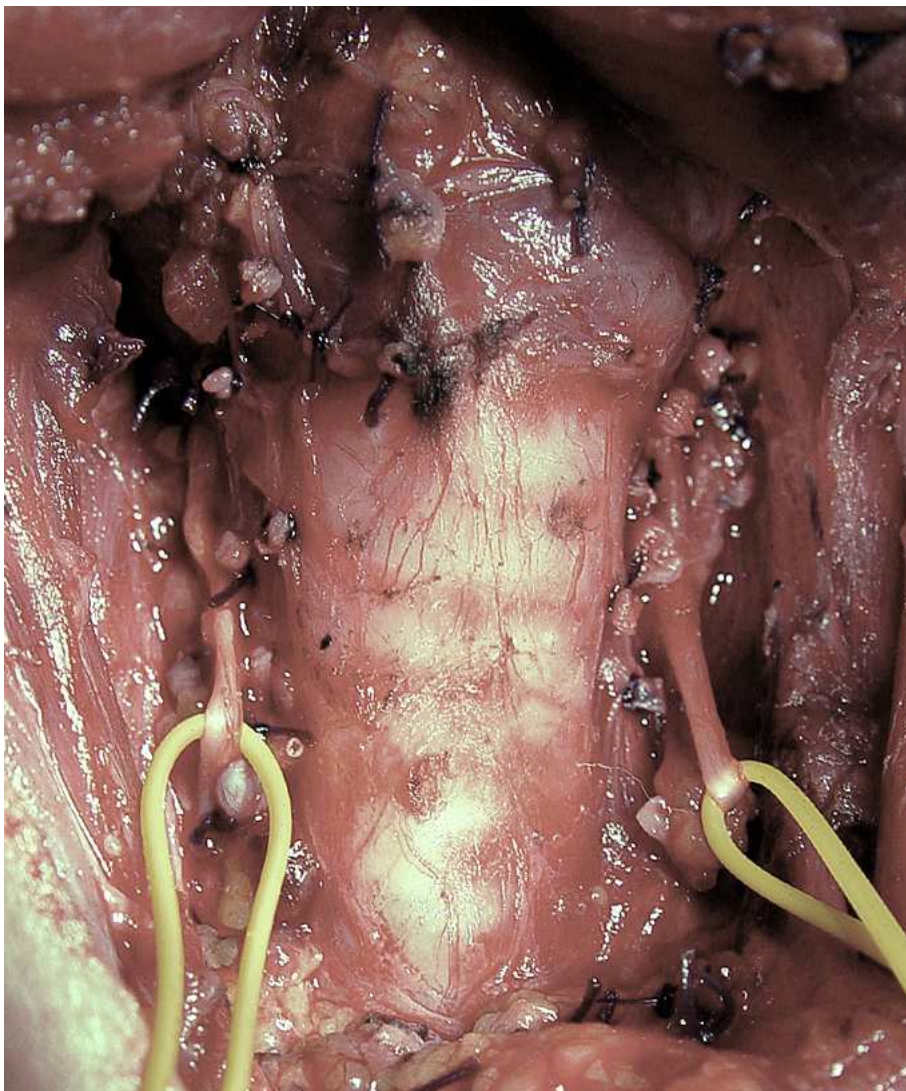
Isolamento dei nervi laringei inferiori (ricorrenti)



Lobo destro - Istmio - Lobo sinistro (superficie anteriore)

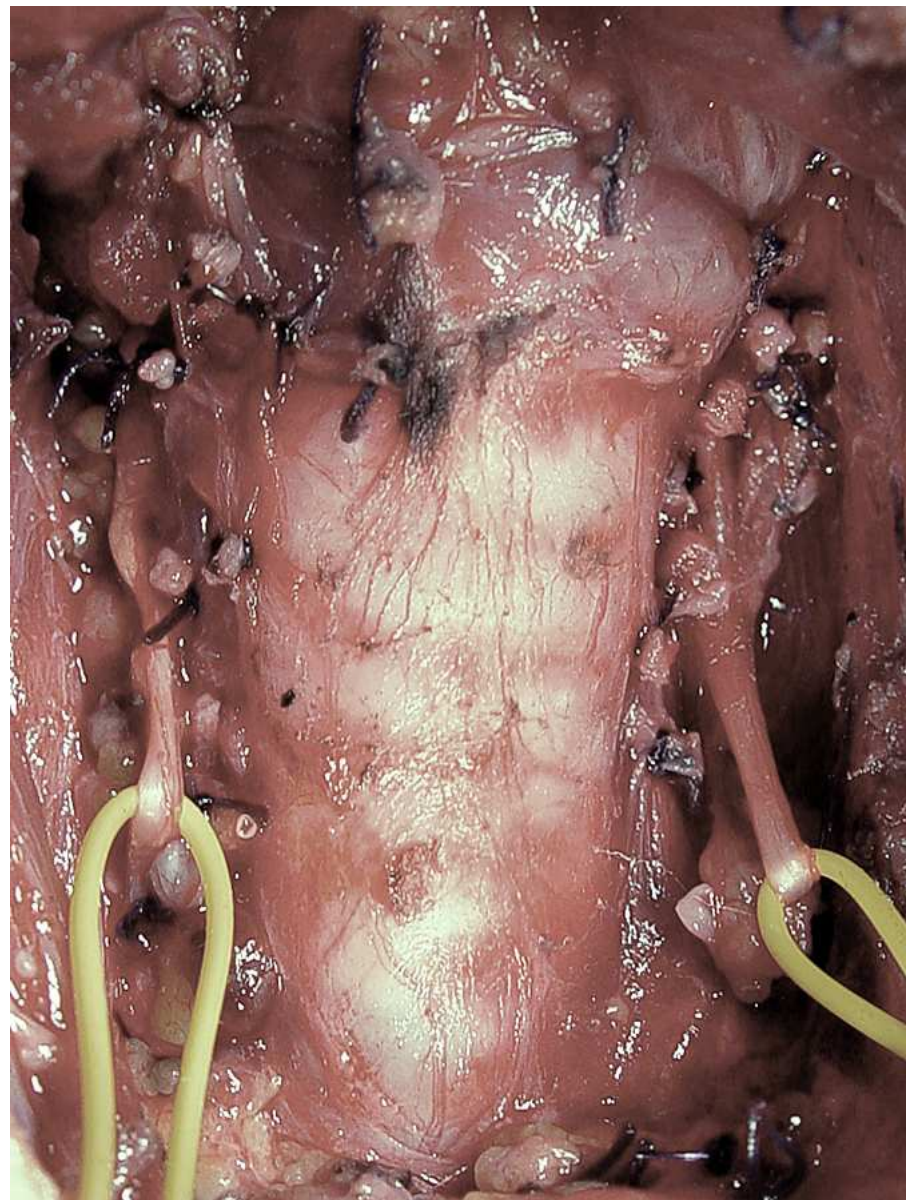


Lobo sinistro - Istmio - Lobo destro (superficie posteriore)



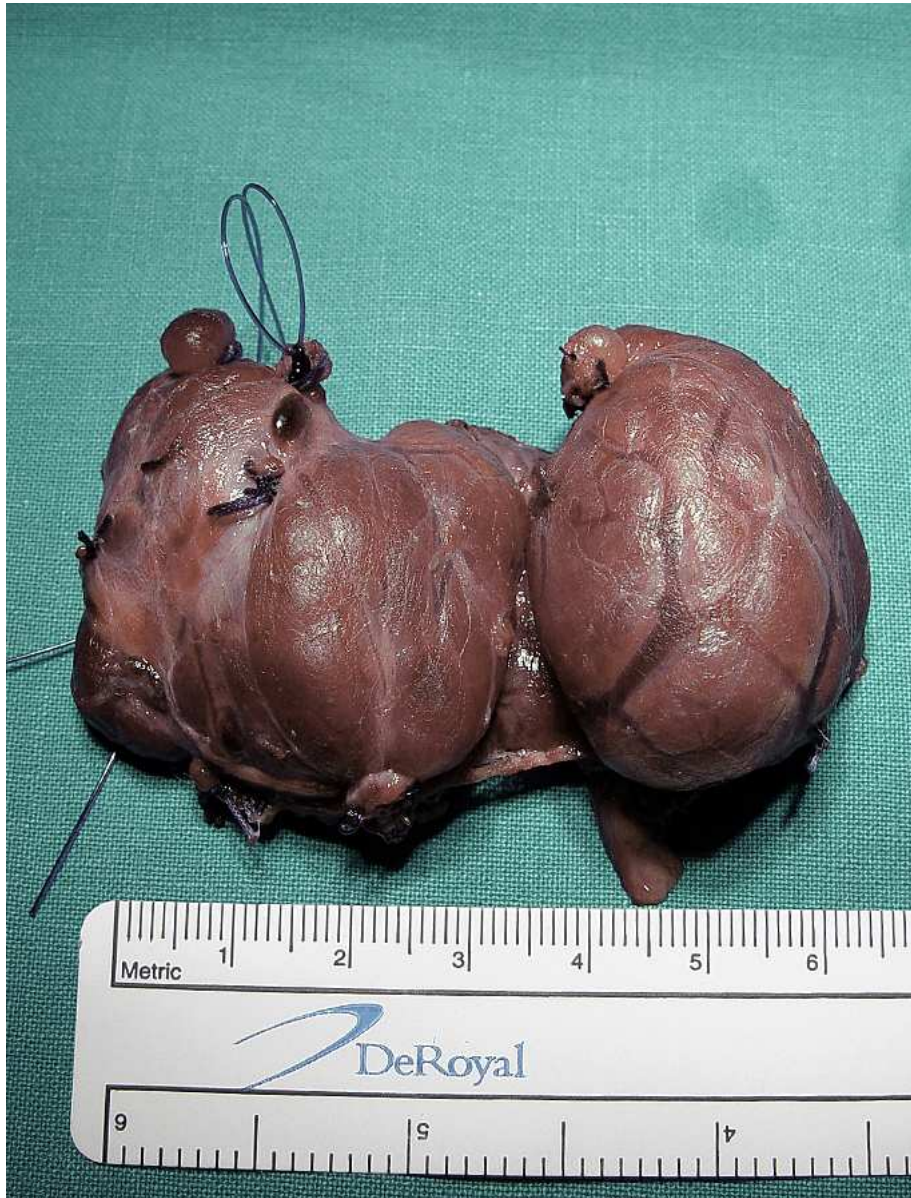V.V. • Anni: 19 - F • Record: 88 • 23-11-2005

Tiroidectomia totale extracapsulare per gozzo plurinodulare adenomatoso tossico e tiroidite linfocitaria

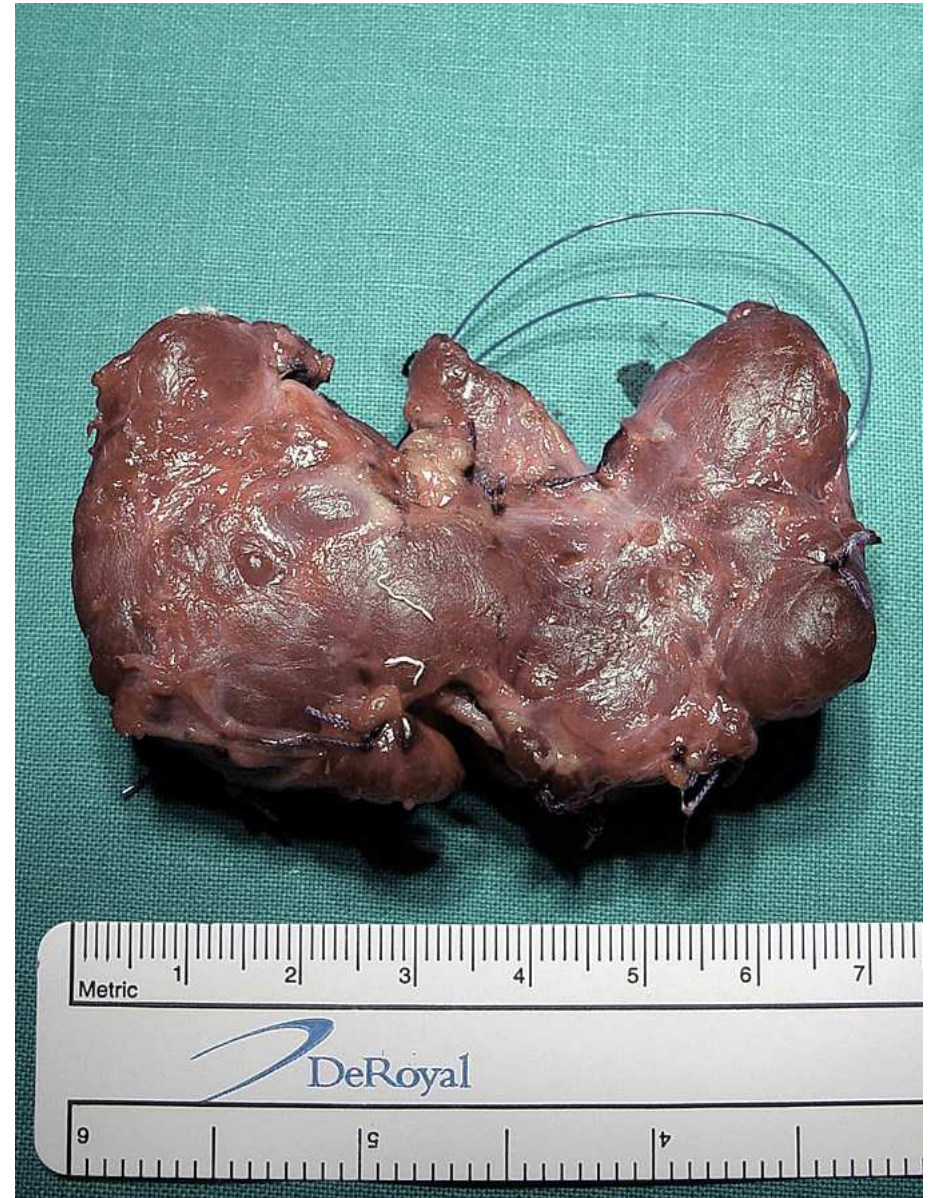

Isolamento dei nervi laringei inferiori (ricorrenti)

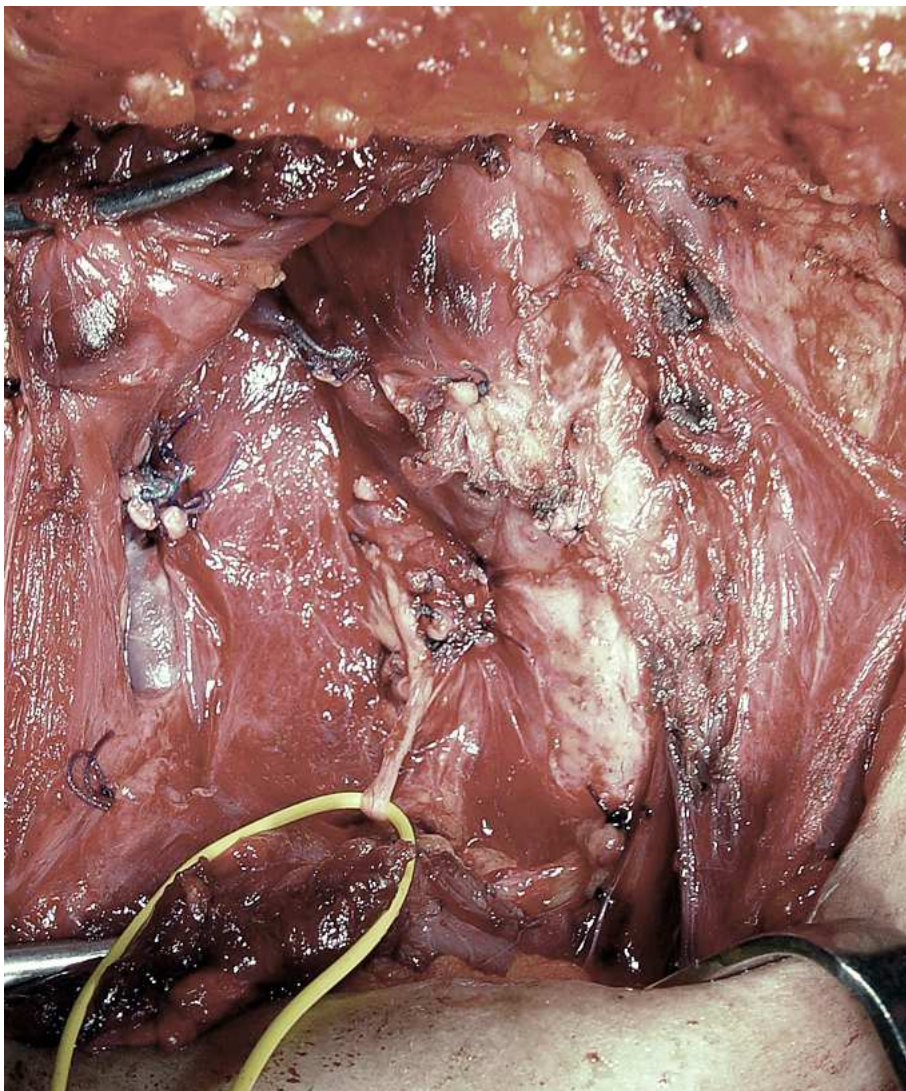




Lobo destro - Istmo - Lobo sinistro (superficie anteriore)

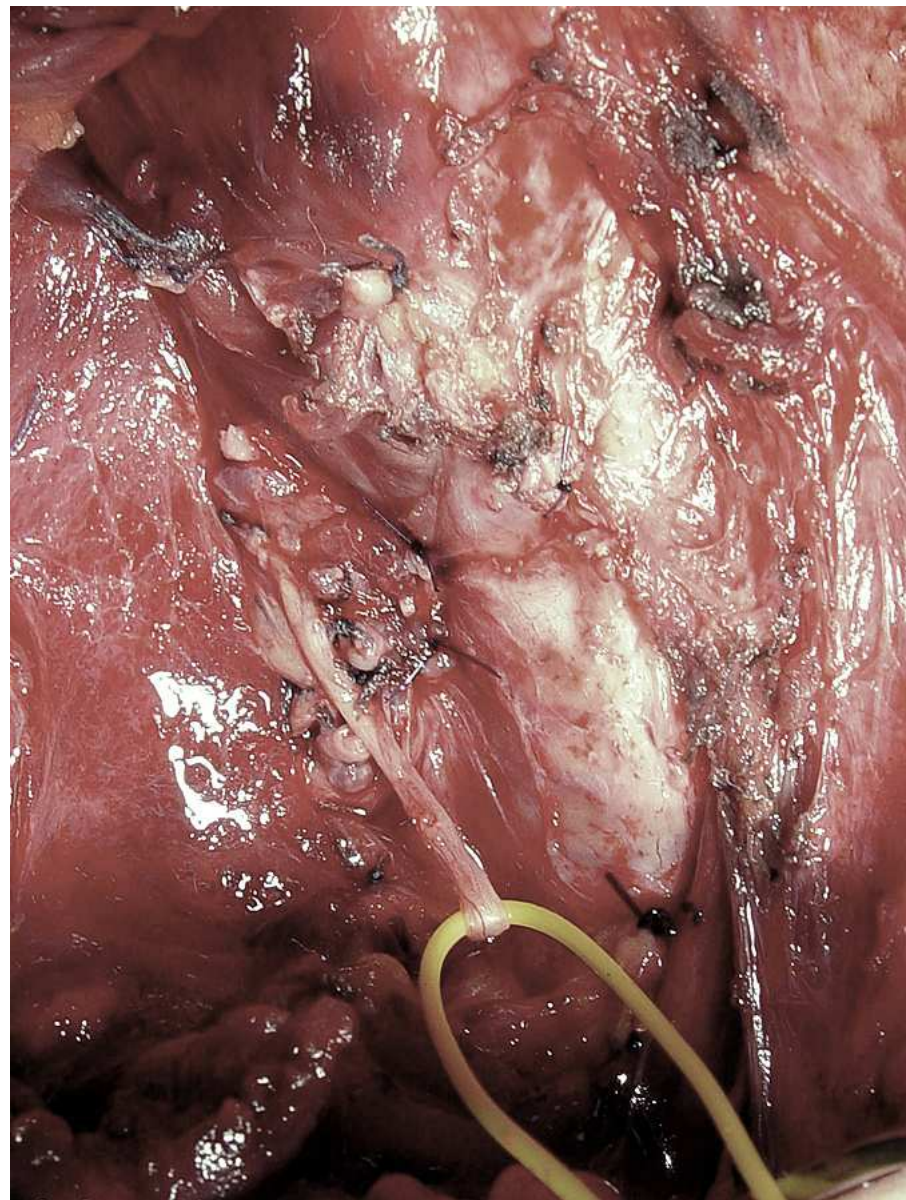


Lobo sinistro - Istmo - Lobo destro (superficie posteriore)

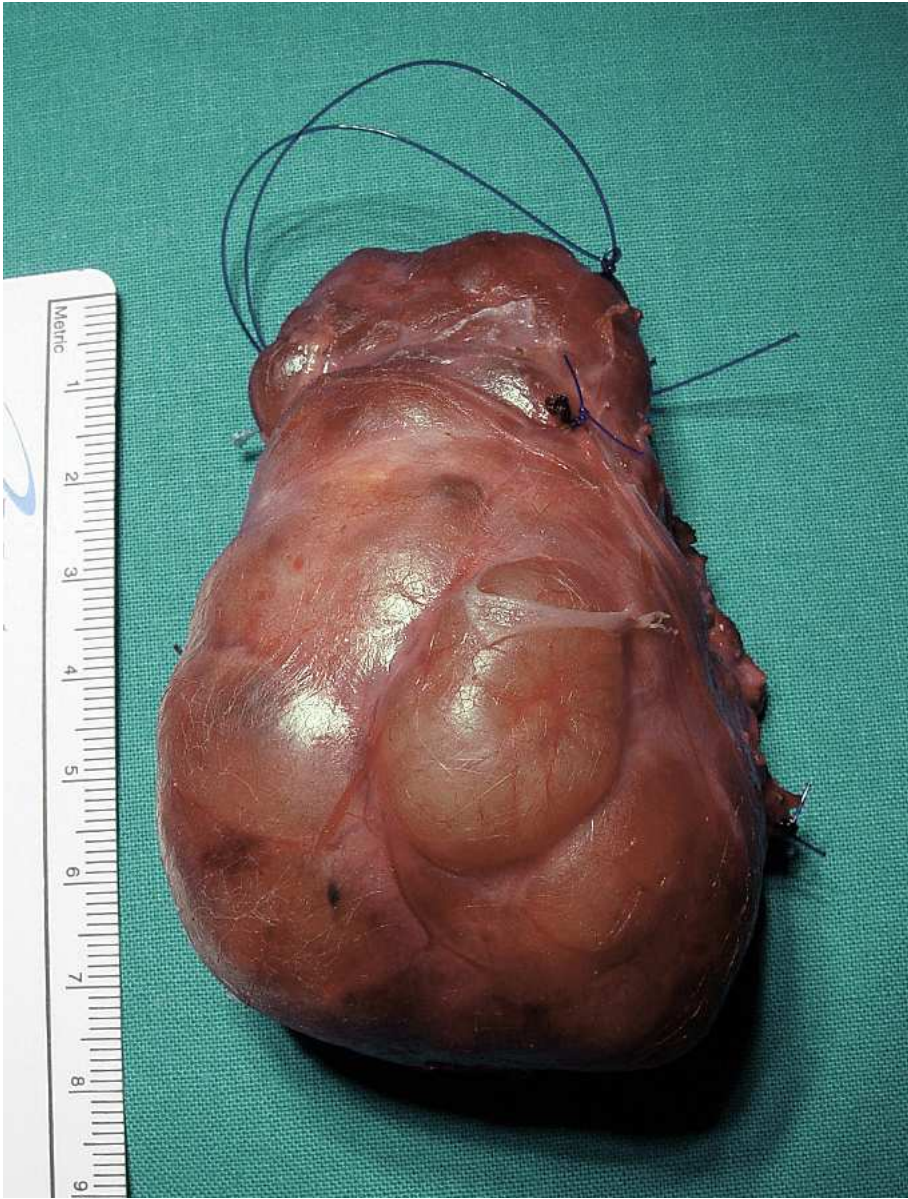


B.G. • Anni: 57 - F • Record: 89 • 23-11-2005

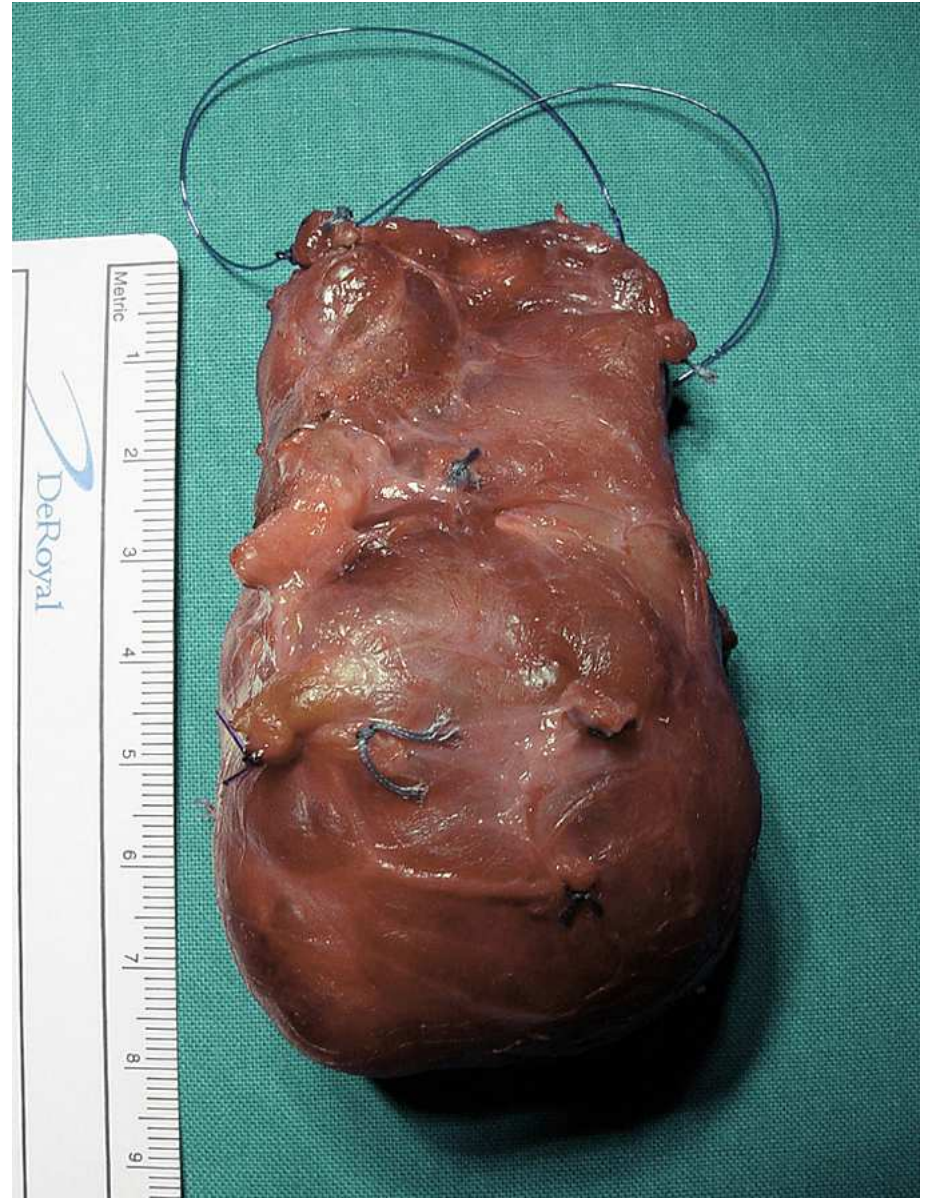
Istmo-lobectomia dx totale extracapsulare per gozzo plurinodulare plongeant recidivo in lobectomizzata a sn



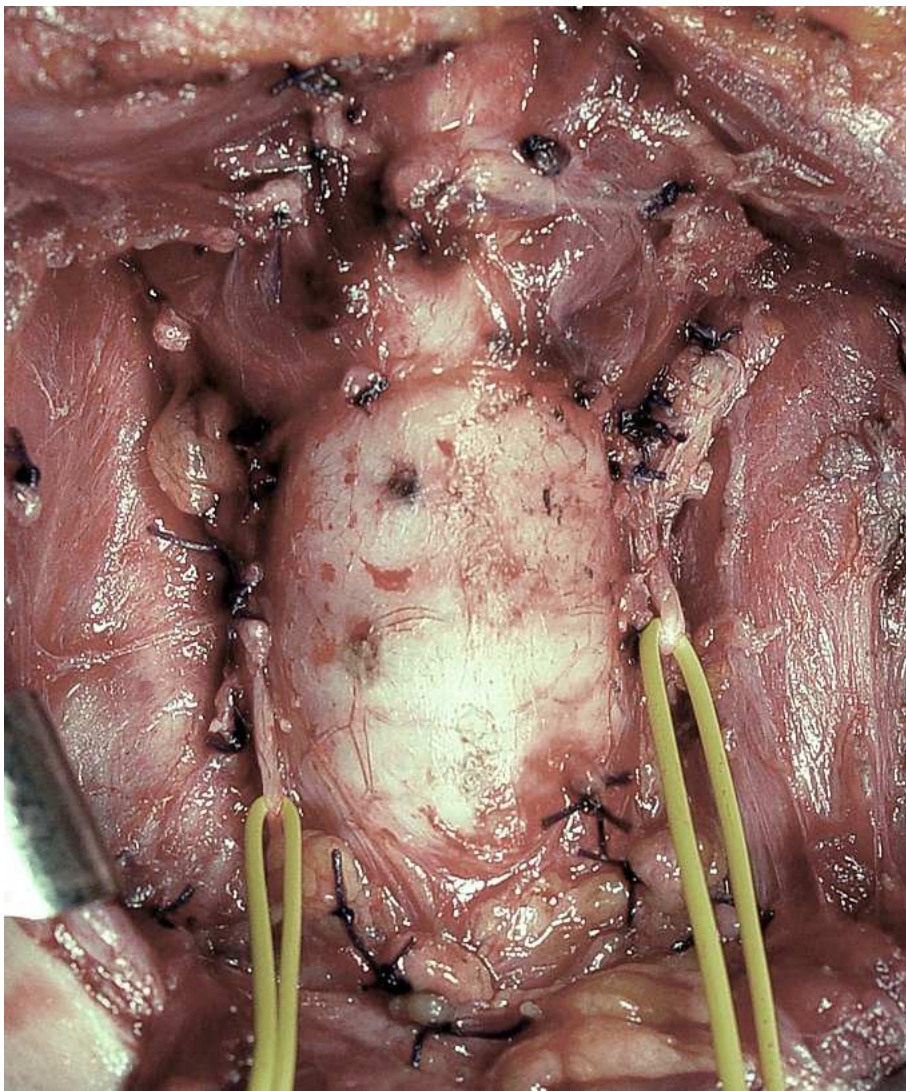
Isolamento del nervo laringeo inferiore destro (ricorrente)



Lobo destro - Istmo (superficie anteriore)

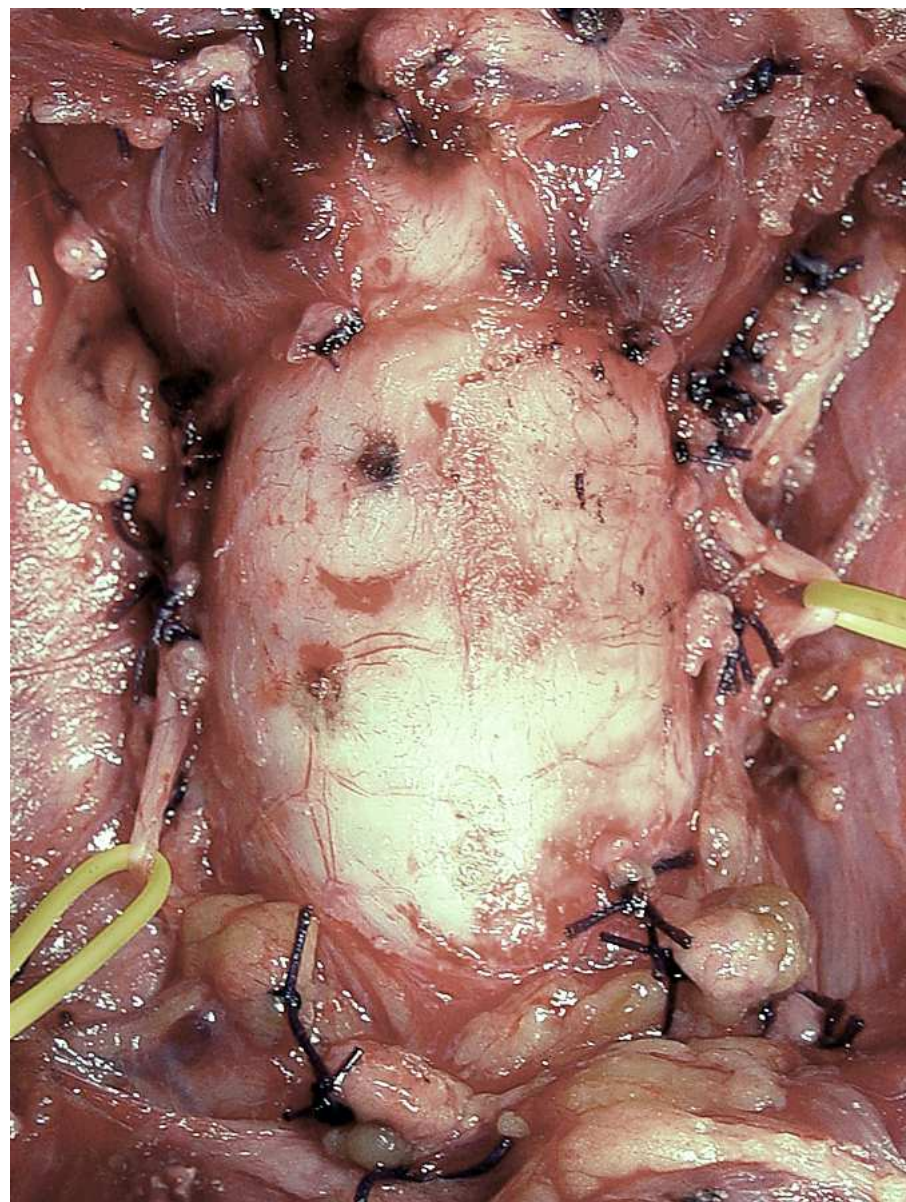


Istmo - Lobo destro (superficie posteriore)

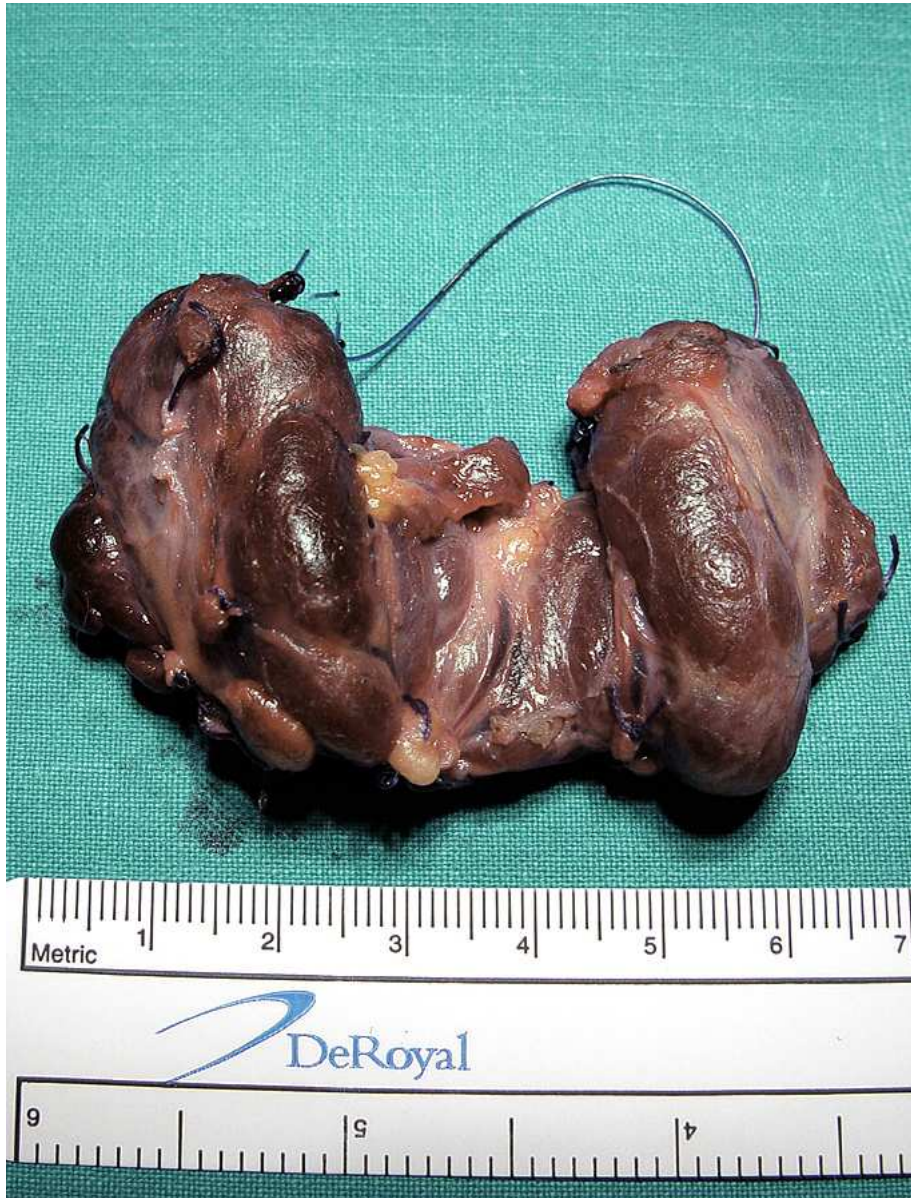

L.A. • Anni: 45 - F • Record: 90 • 25-11-2005

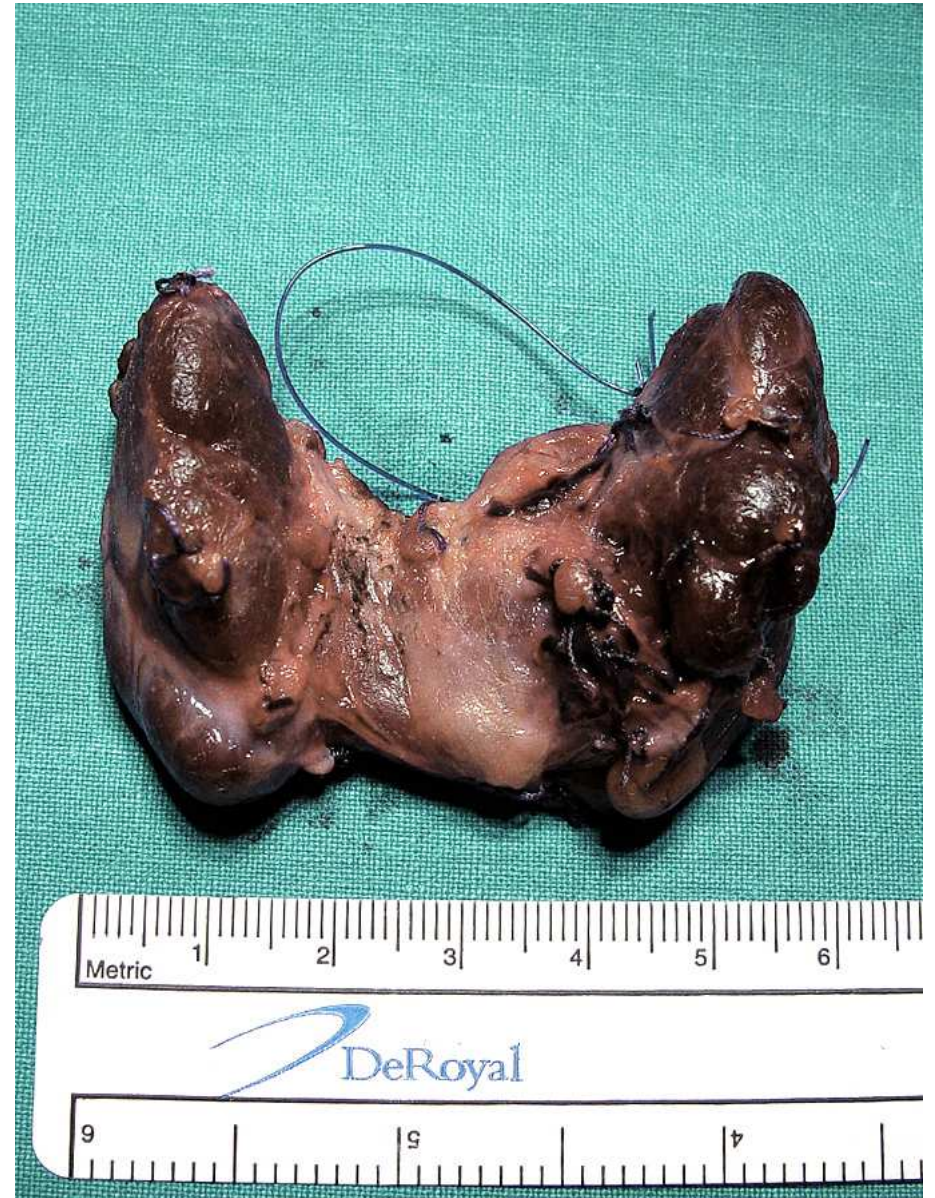Tiroidectomia totale extracapsulare per gozzo plurinodulare adenomatoso



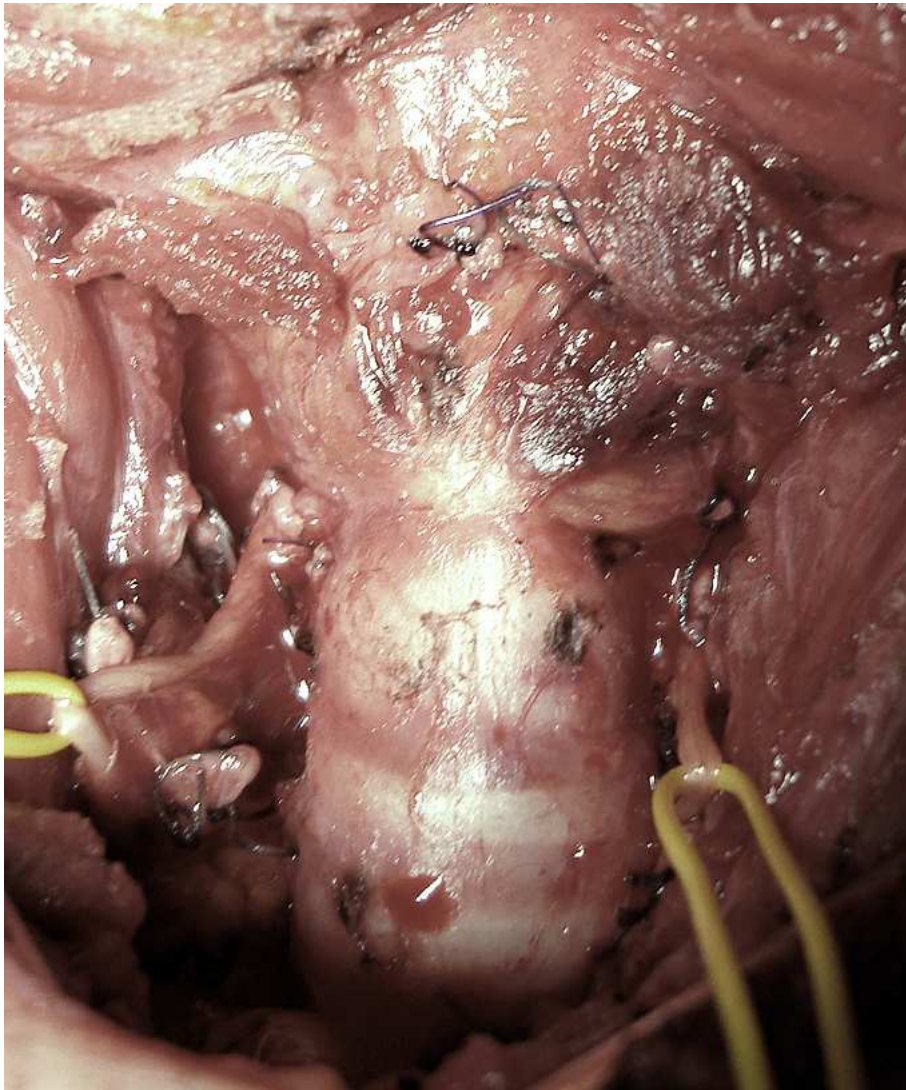
Isolamento dei nervi laringei inferiori (ricorrenti)



Lobo destro - Istmo - Lobo sinistro (superficie anteriore)

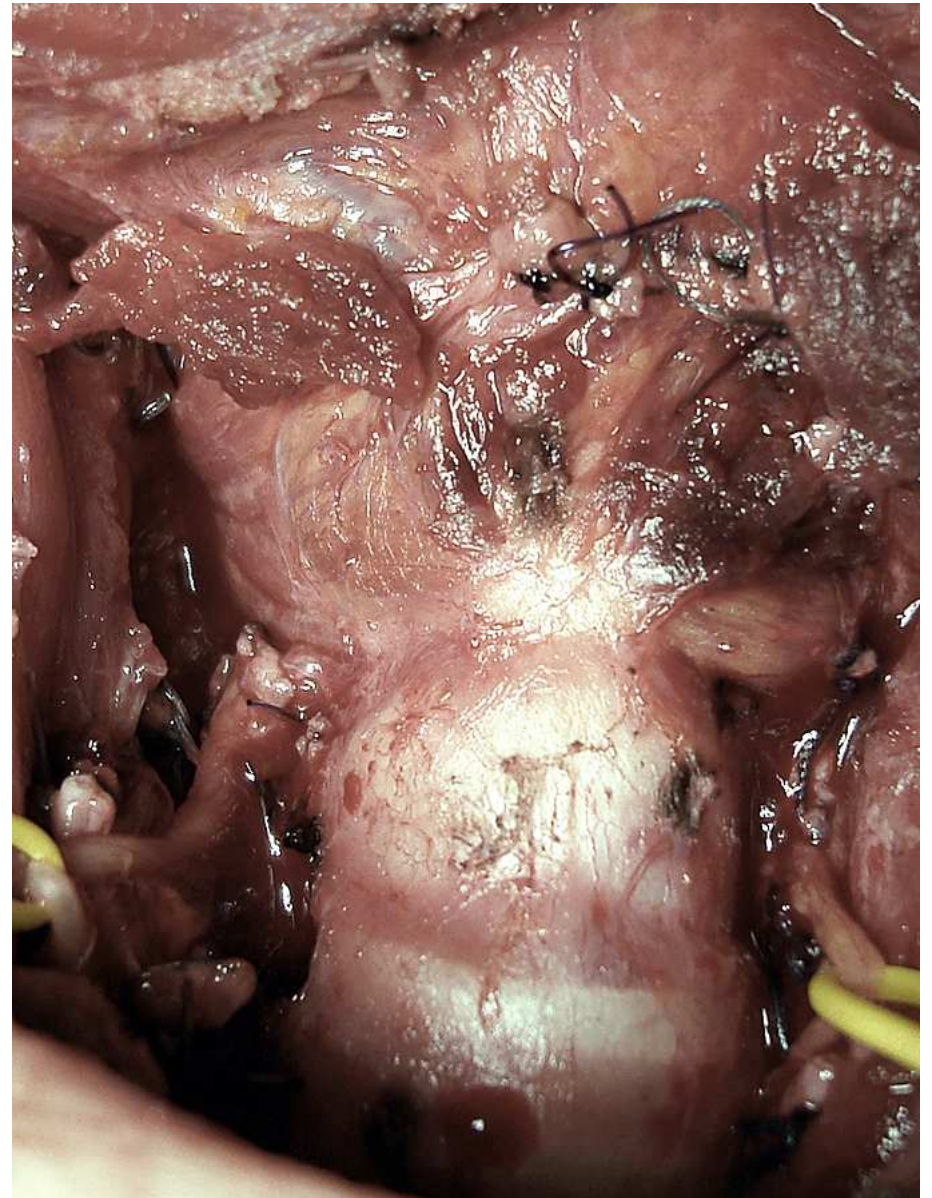


Lobo sinistro - Istmo - Lobo destro (superficie posteriore)

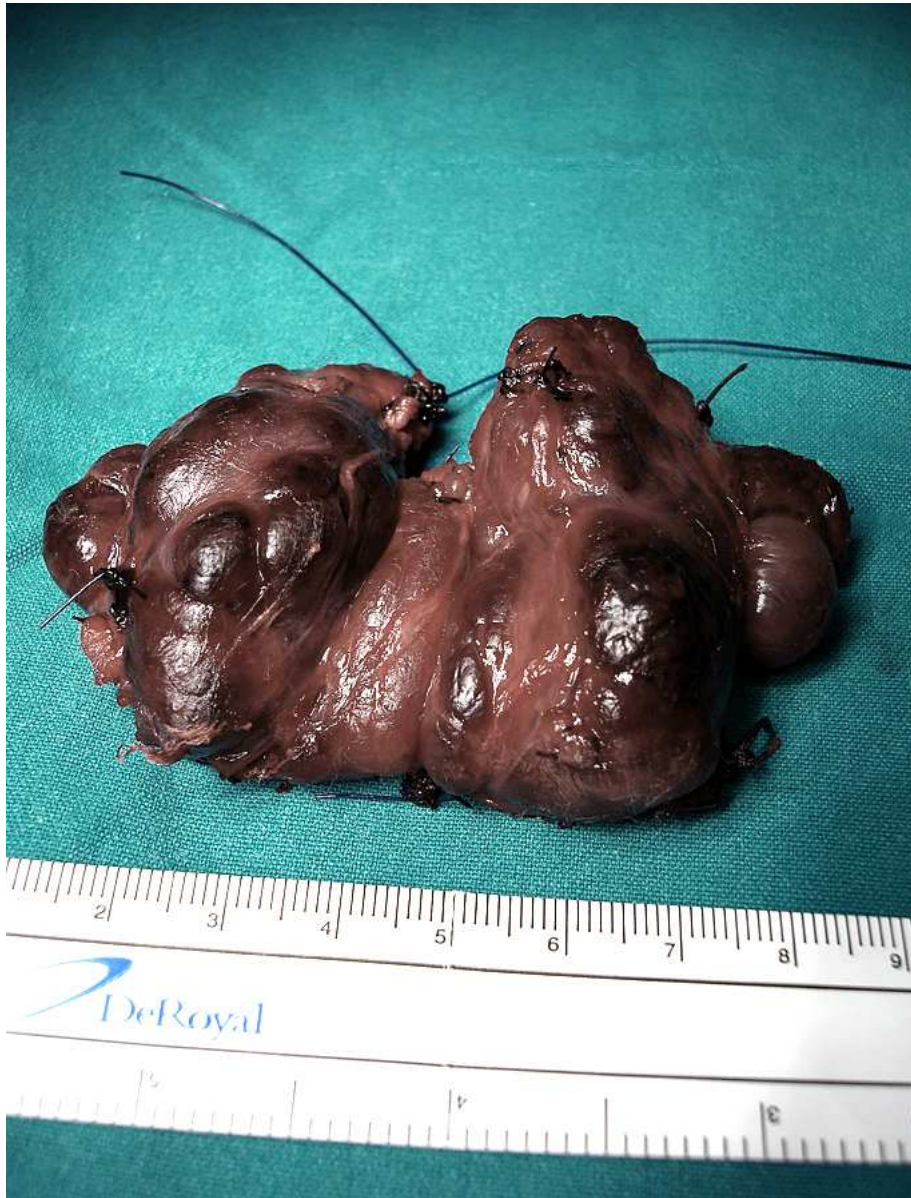

M.A.M. • Anni: 63 - F • Record: 91 • 13-03-2006

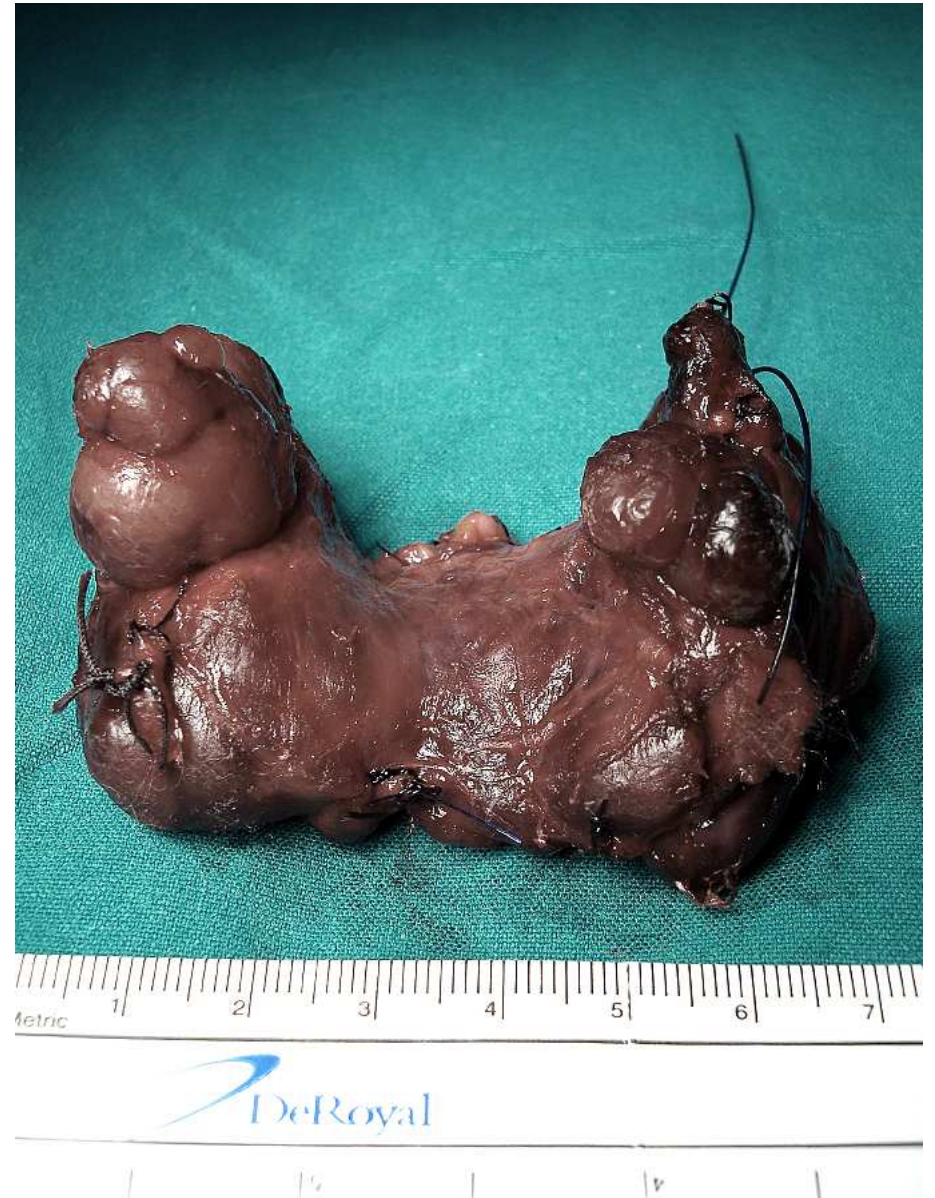Tiroidectomia totale extracapsulare per gozzo plurinodulare plongeant



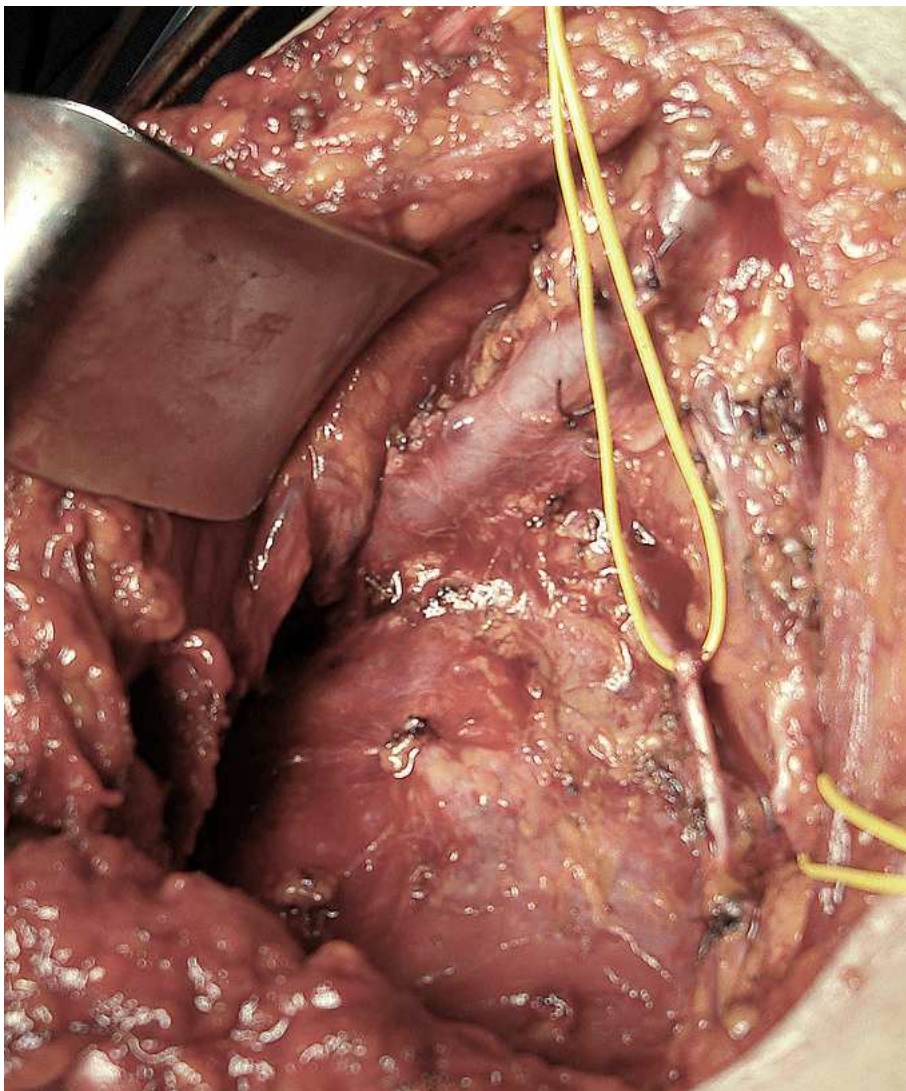Isolamento dei nervi laringei inferiori (ricorrenti)



Lobo destro - Istmo - Lobo sinistro (superficie anteriore)

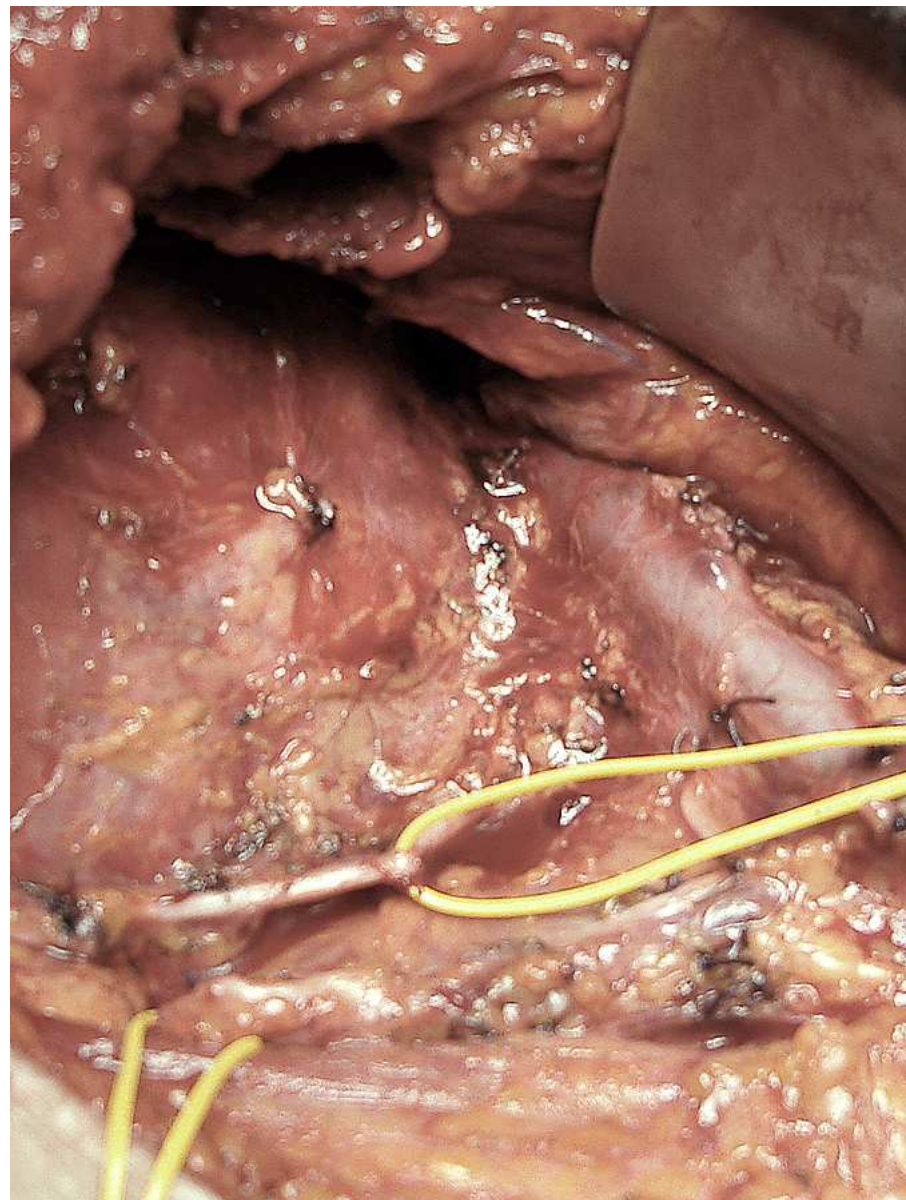


Lobo sinistro - Istmo - Lobo destro (superficie posteriore)

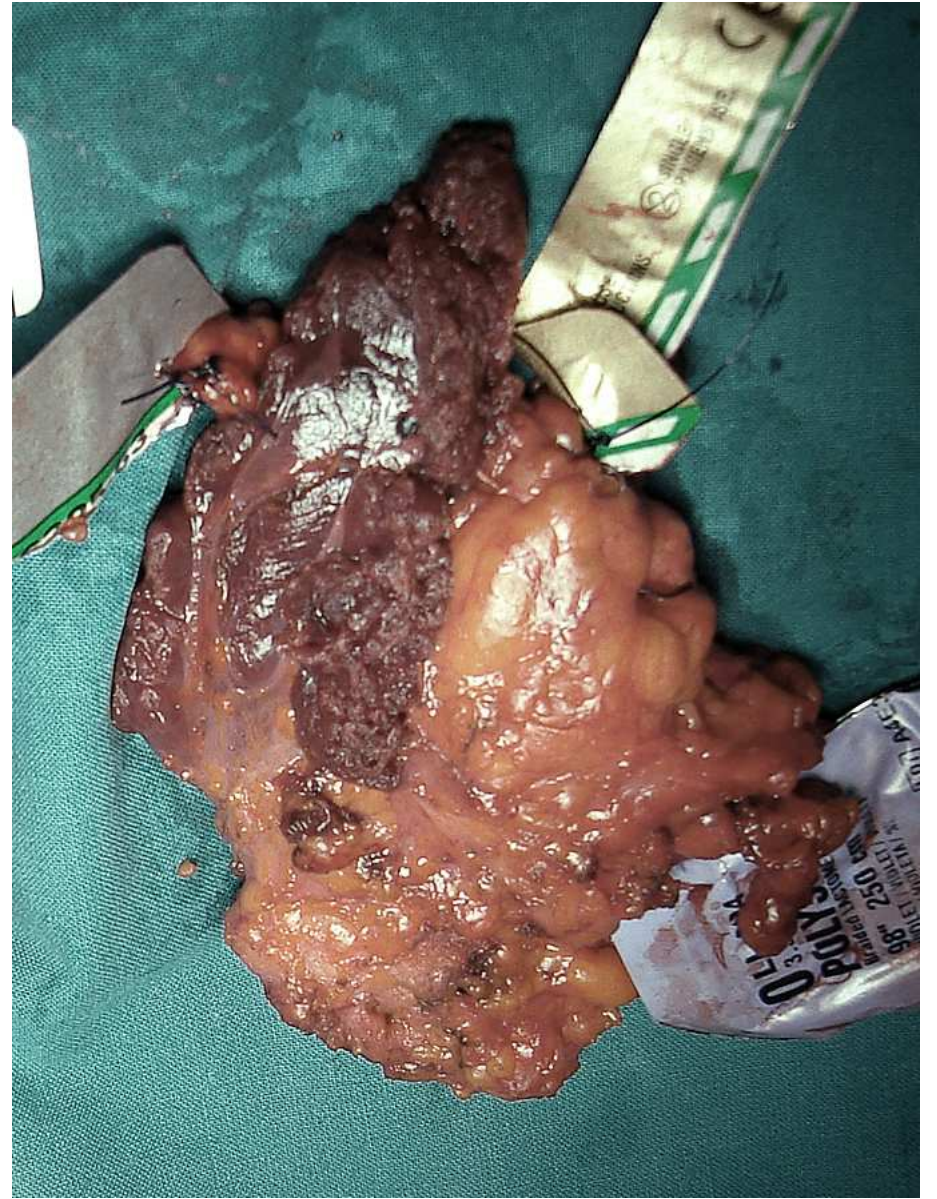
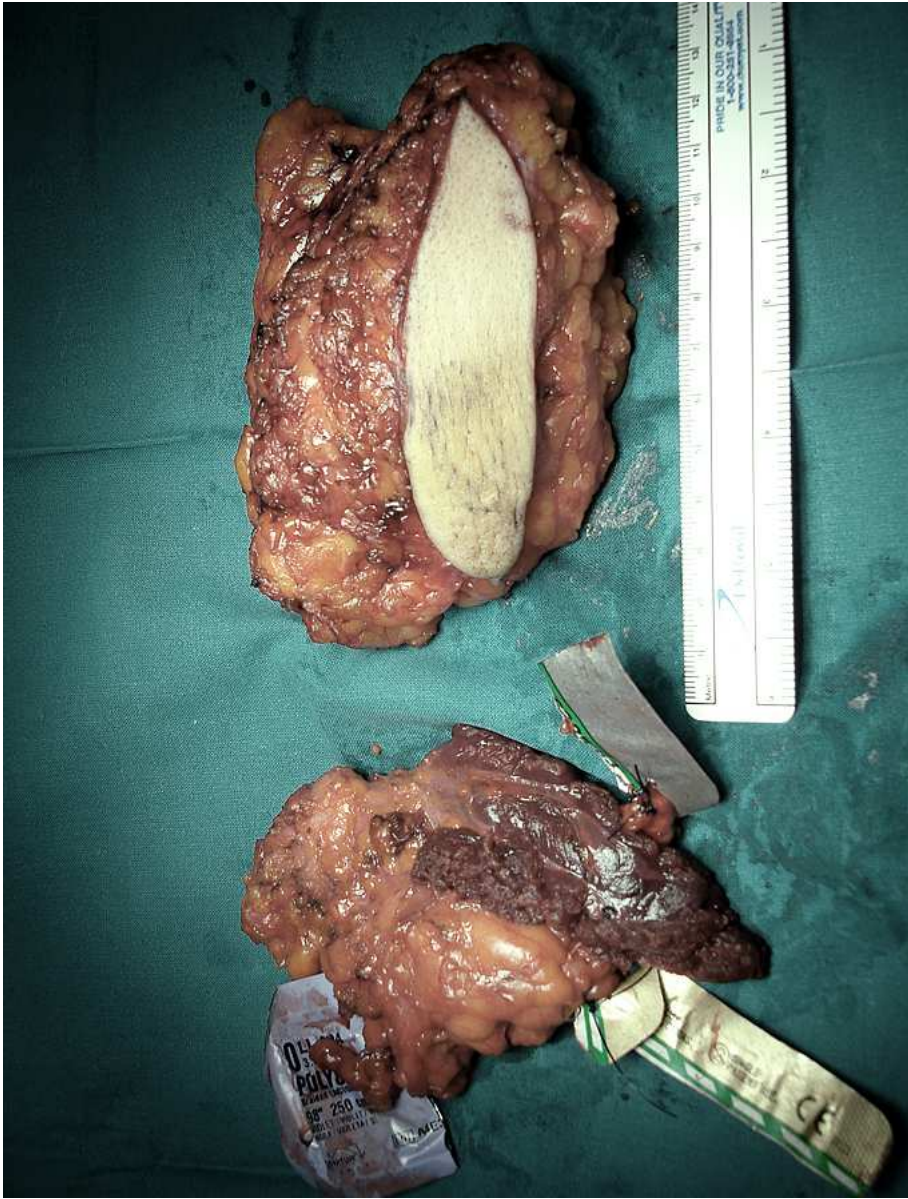
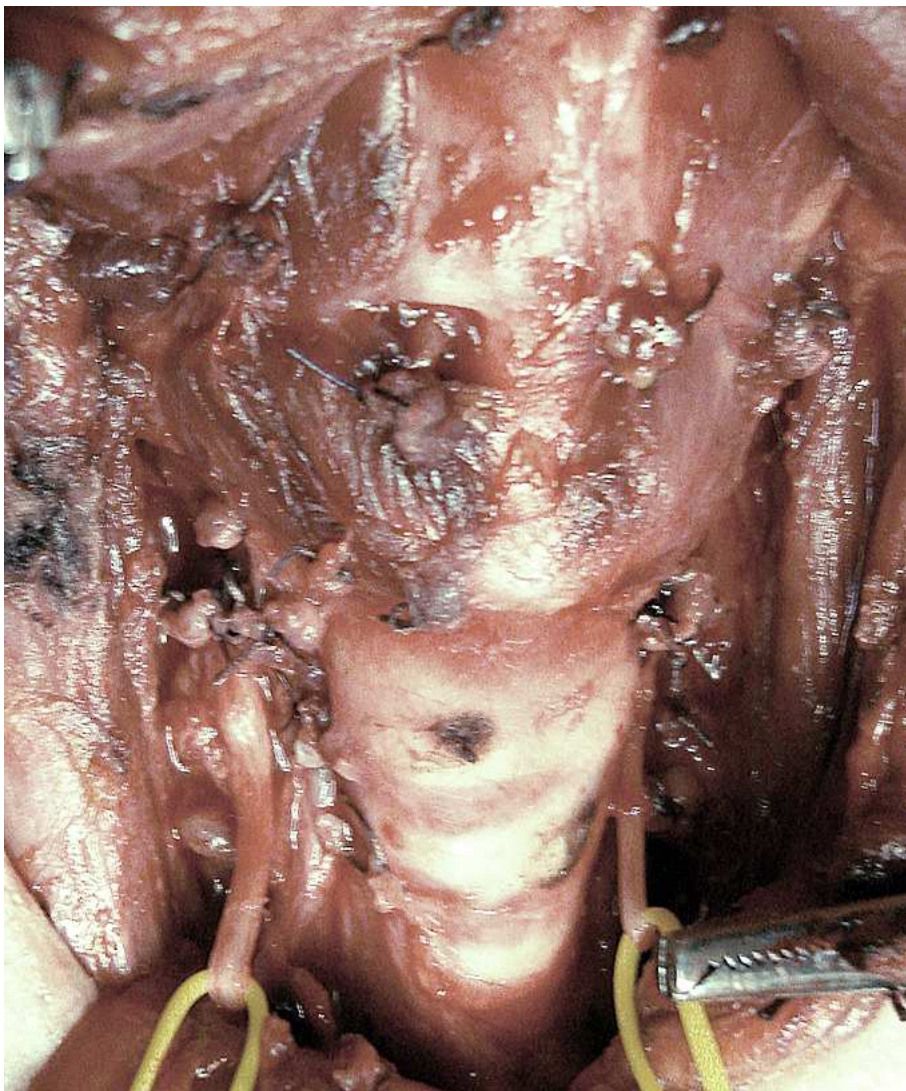F.A. • Anni: 39 - F • Record: 92 • 14-03-2006

Quadrantectomia supero-interna mammella sn con svuotamento ascellare per carcinoma infiltrante con aspetti misti di tipo lobulare e duttale del QSI



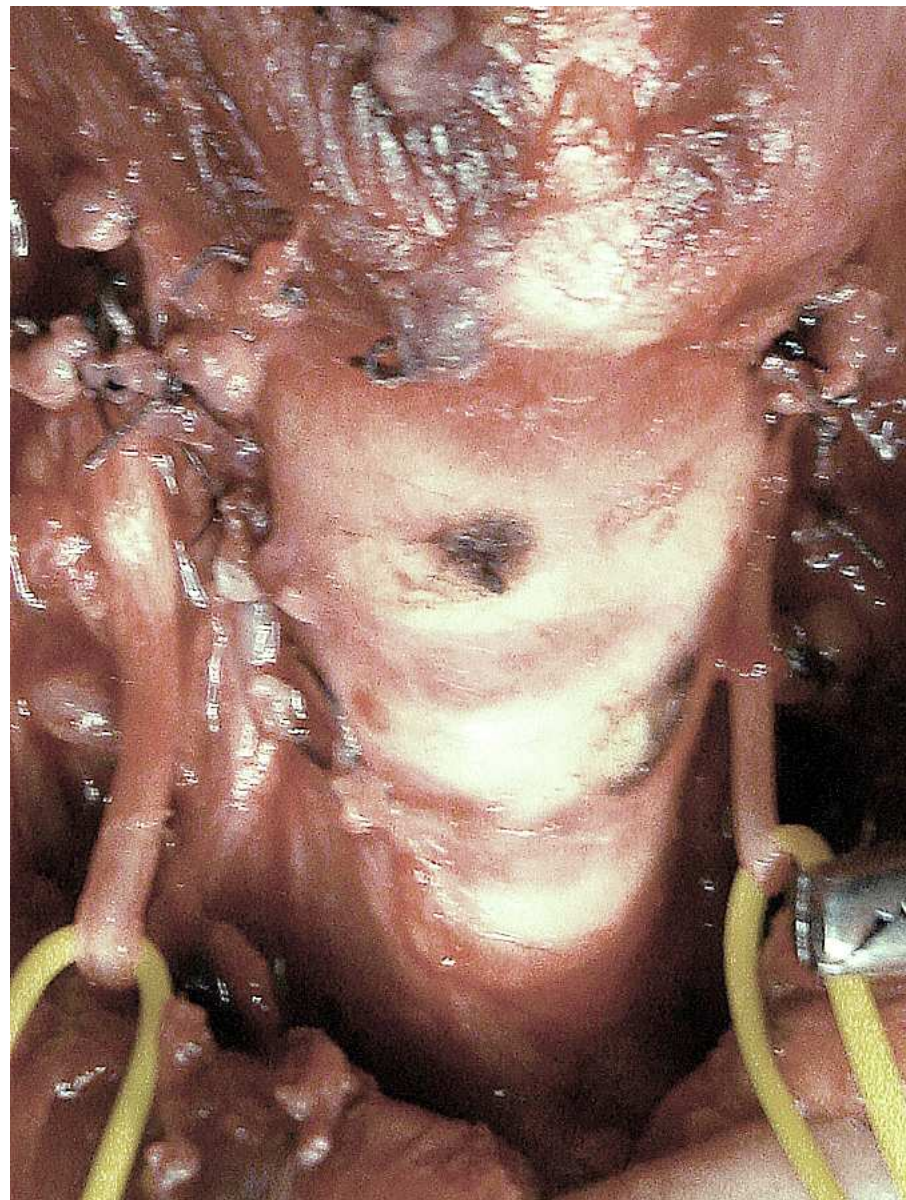




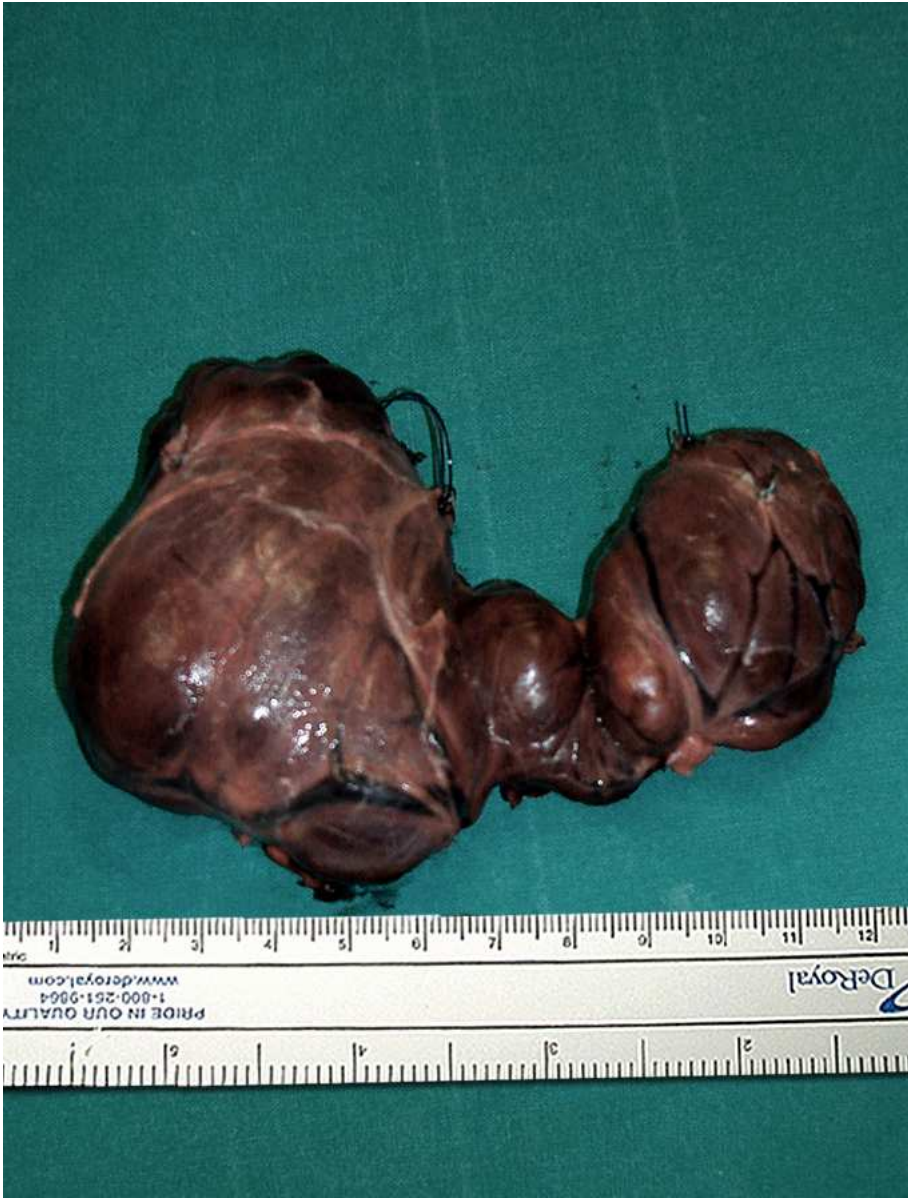
I.R. • Anni: 51 - F • Record: 93 • 21-03-2006

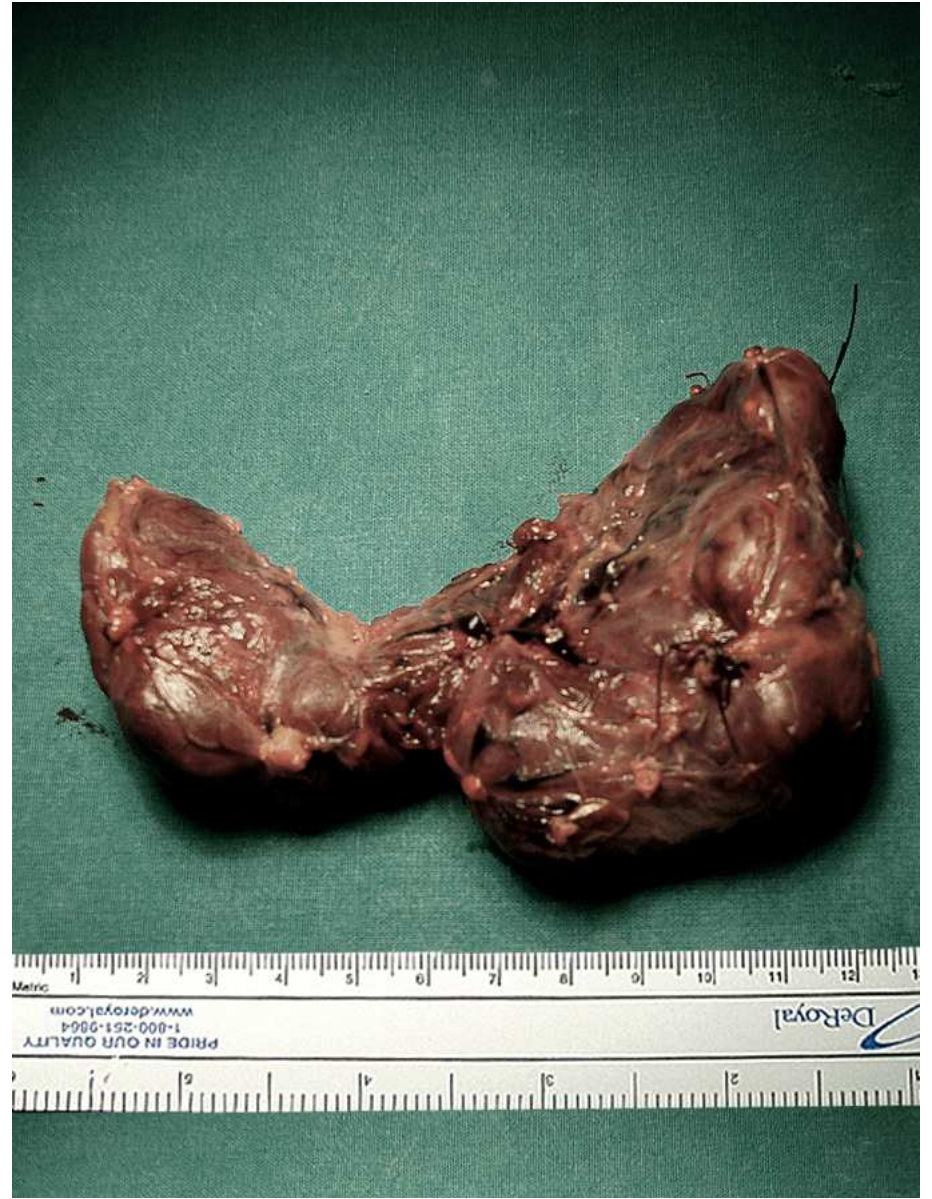
Tiroidectomia totale extracapsulare per gozzo plurinodulare tossico plongeant



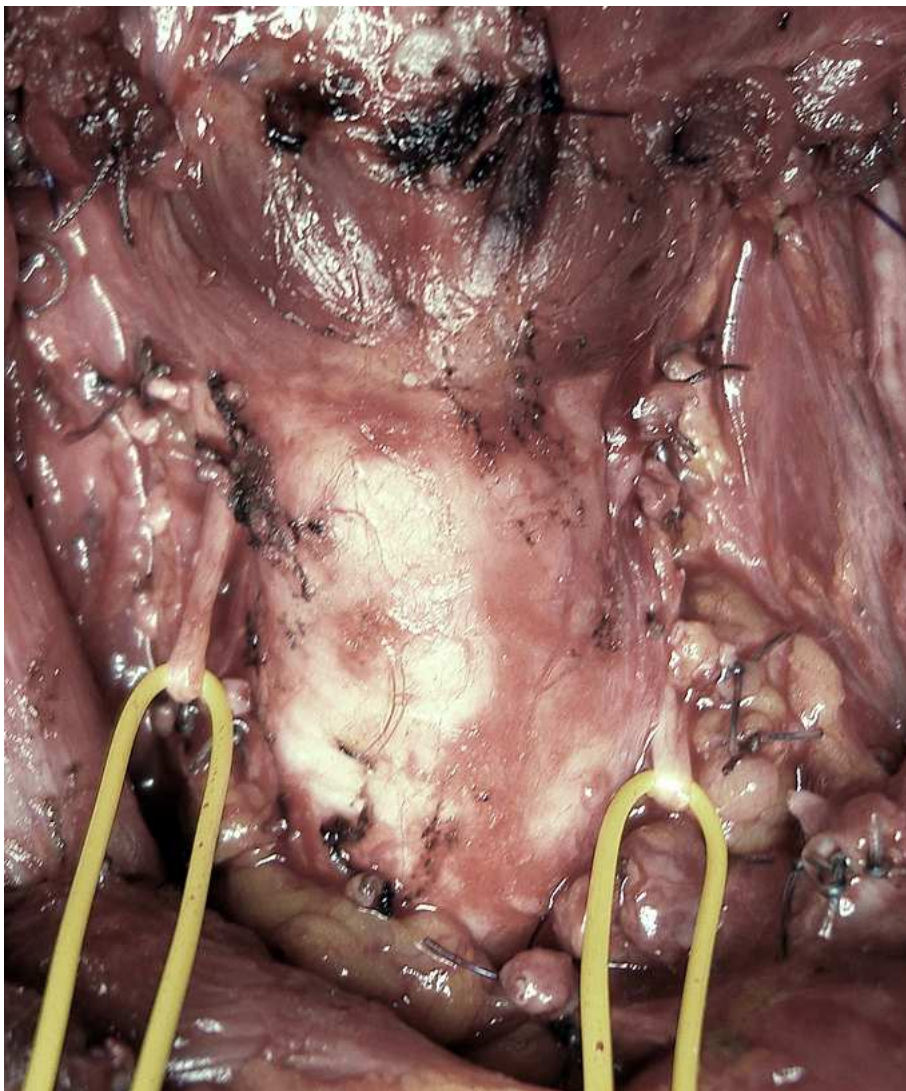
Isolamento dei nervi laringei inferiori (ricorrenti)



Lobo destro - Istmo - Lobo sinistro (superficie anteriore)

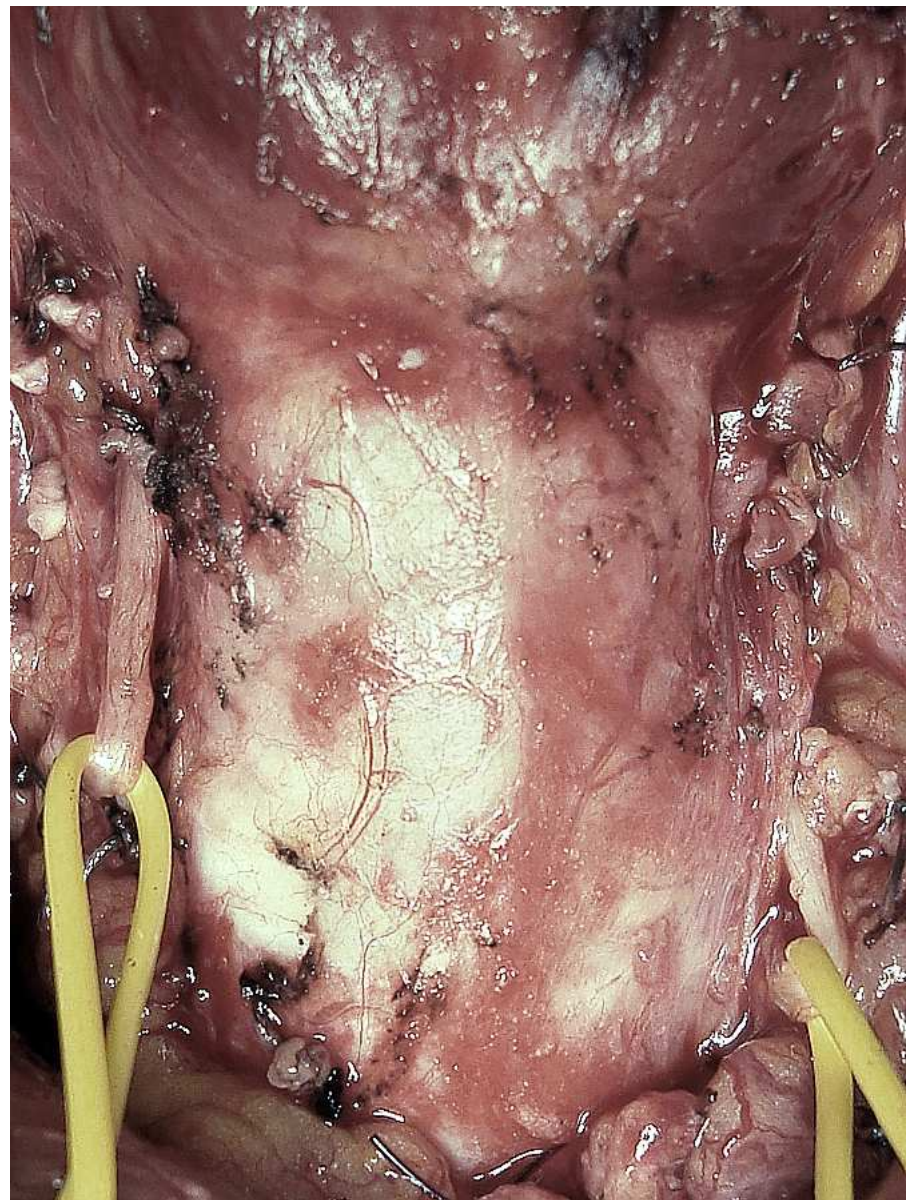


Lobo sinistro - Istmo - Lobo destro (superficie posteriore)

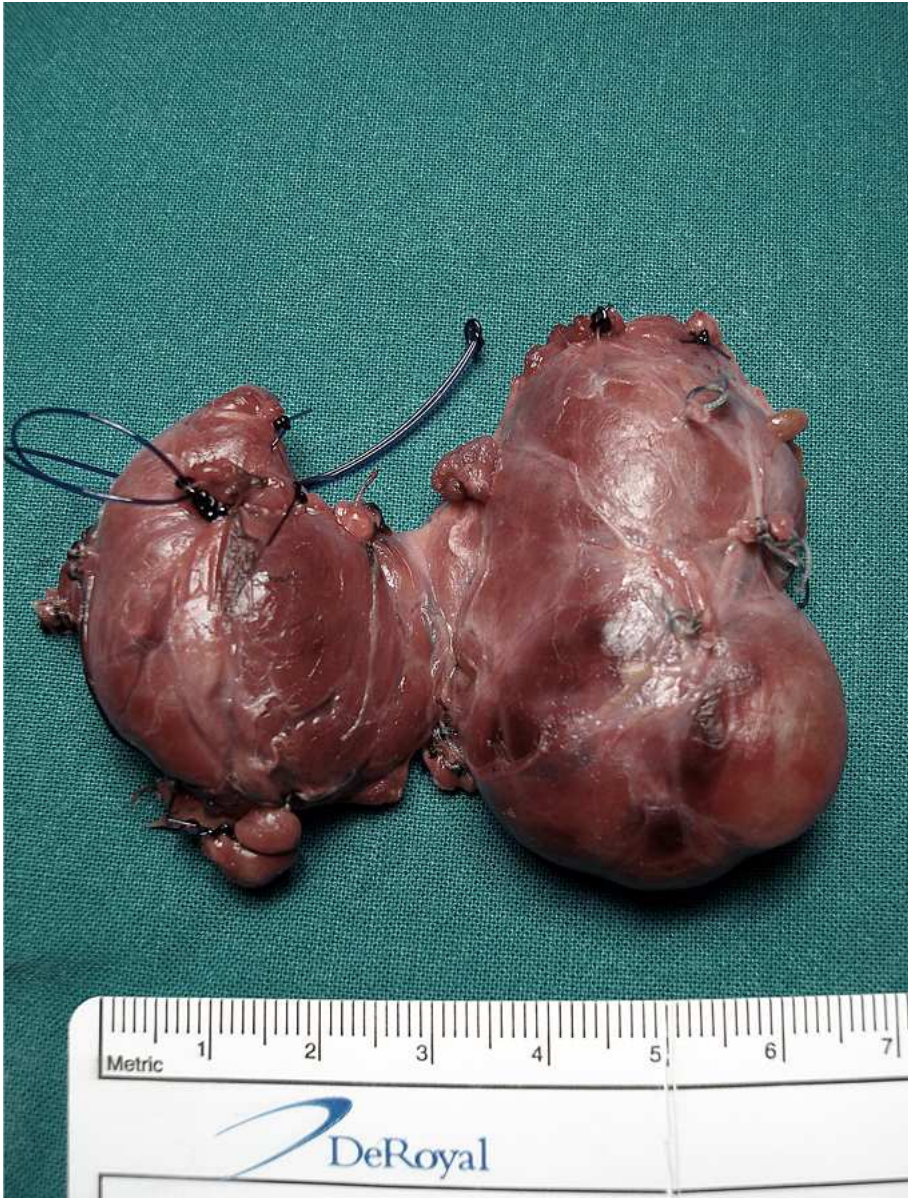

D.A. • Anni: 55 - F • Record: 94 • 11-04-2006

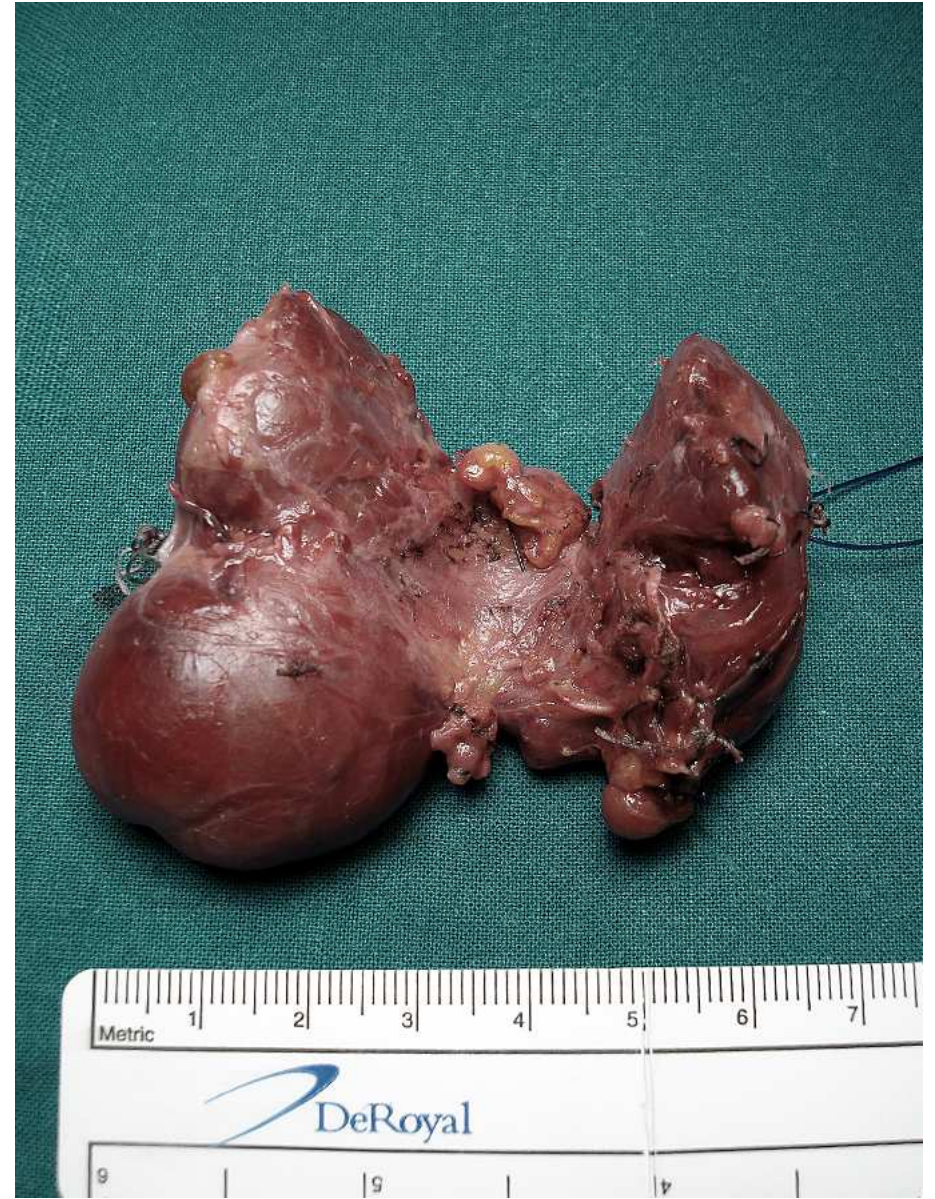
Tiroidectomia totale extracapsulare per gozzo plurinodulare plongeant a sn



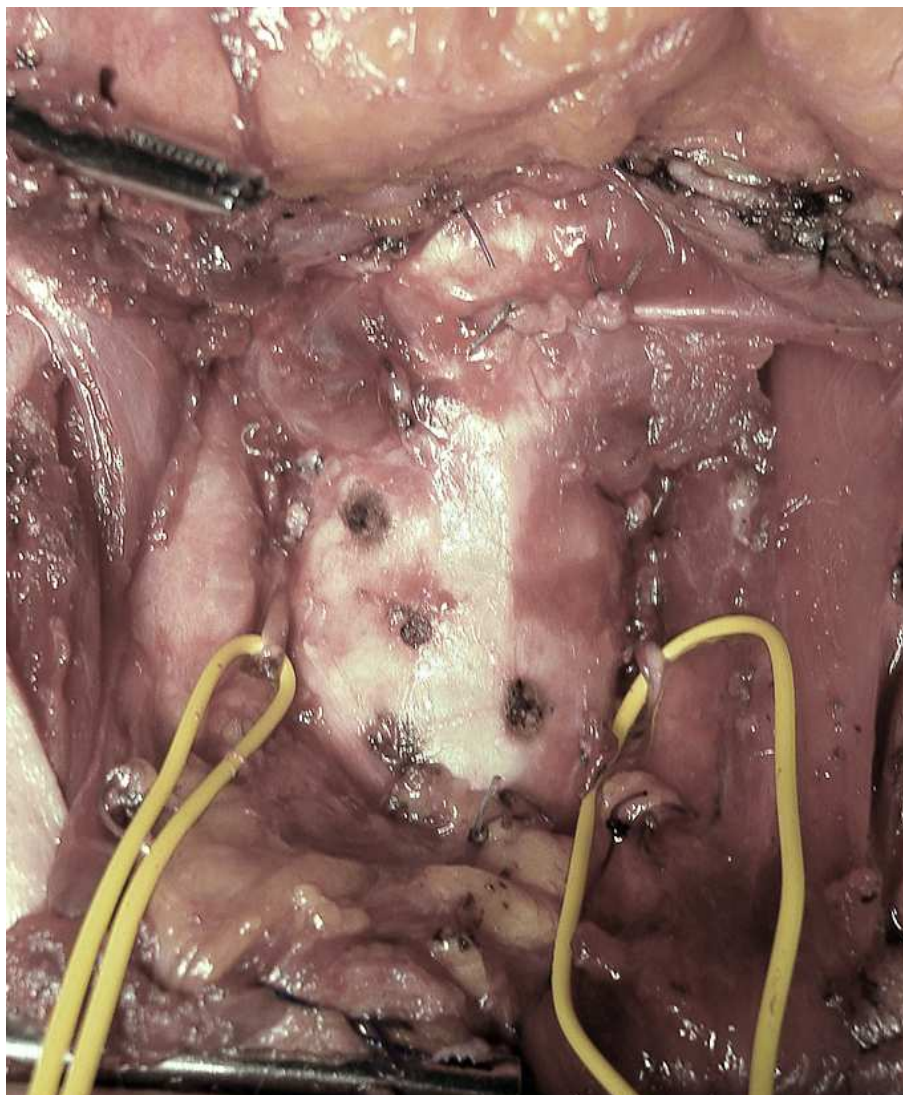
Isolamento dei nervi laringei inferiori (ricorrenti)



Lobo destro - Istmo - Lobo sinistro (superficie anteriore)

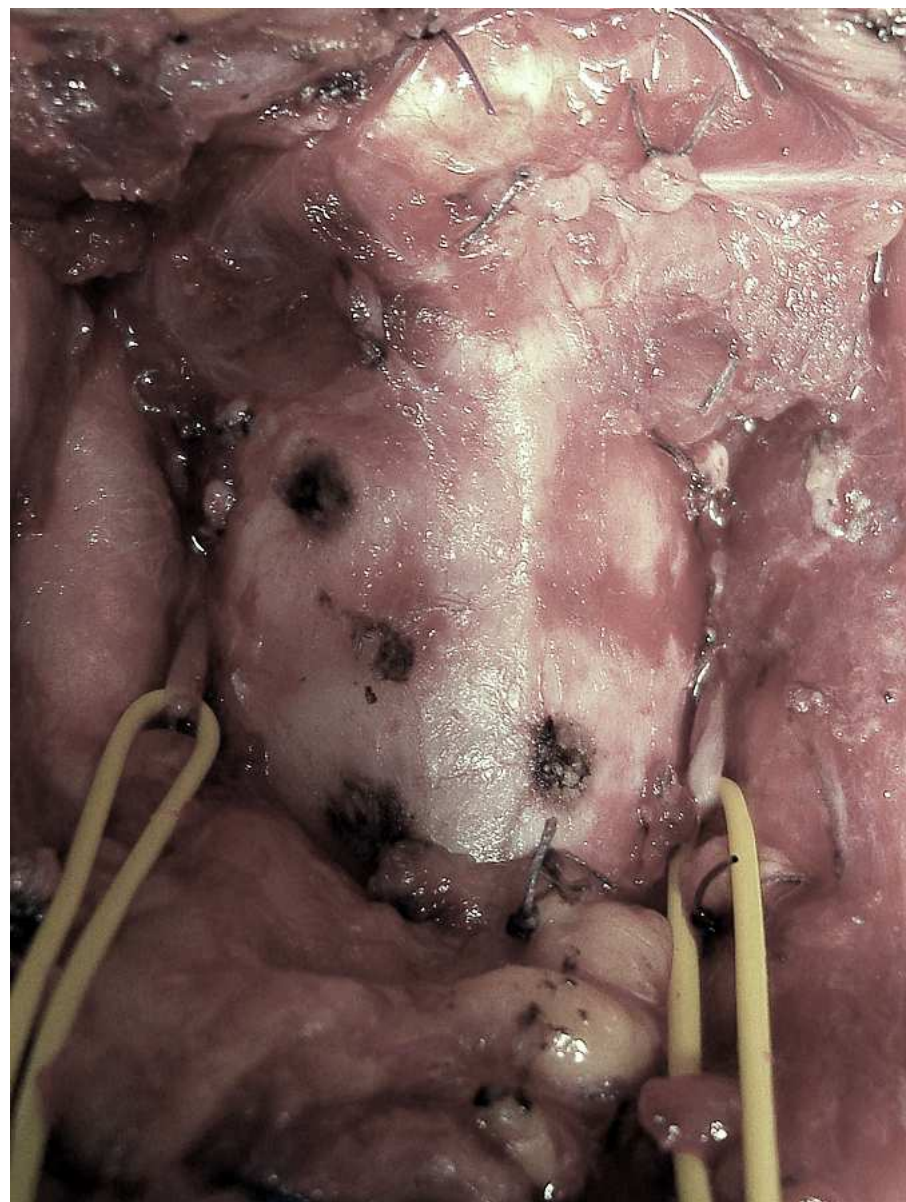


Lobo sinistro - Istmo - Lobo destro (superficie posteriore)

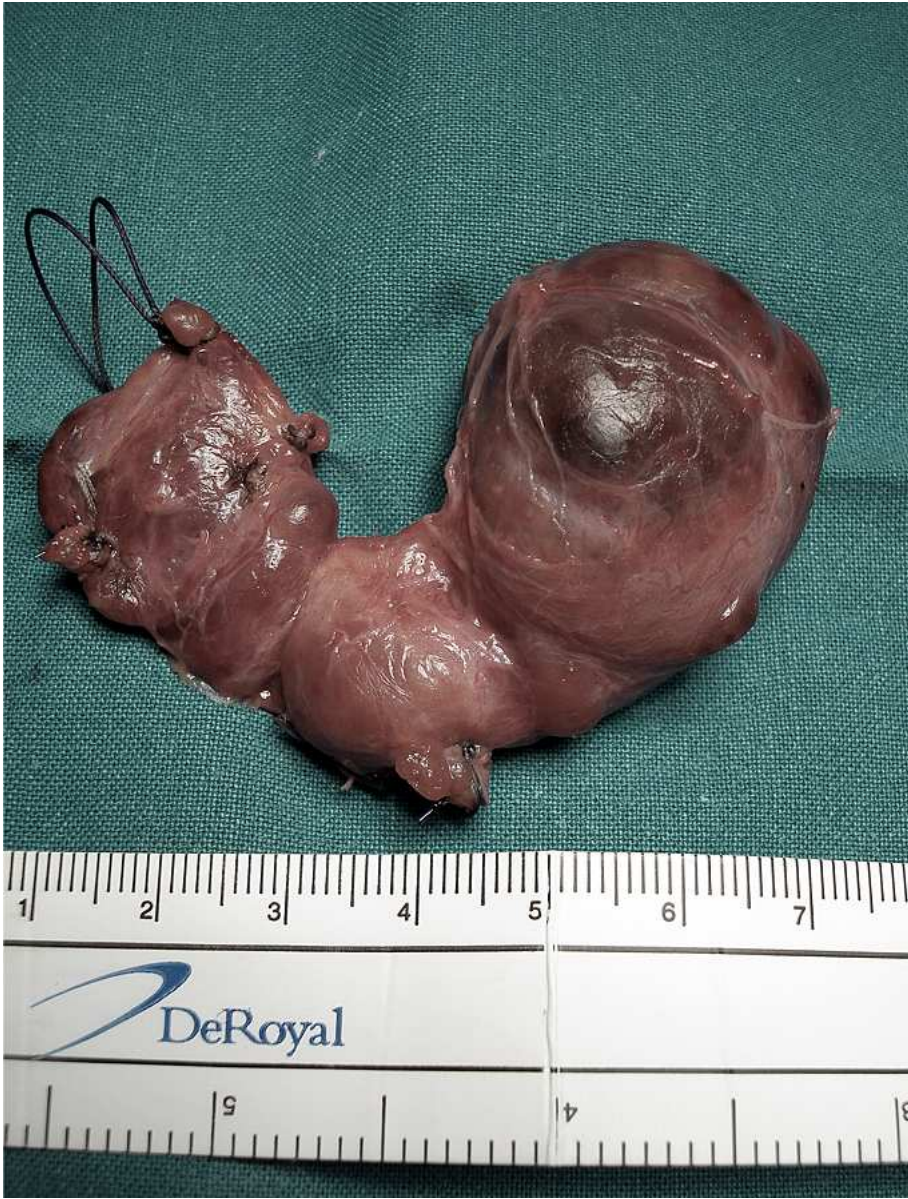

G.G. • Anni: 68 - F • Record: 95 • 19-05-2006

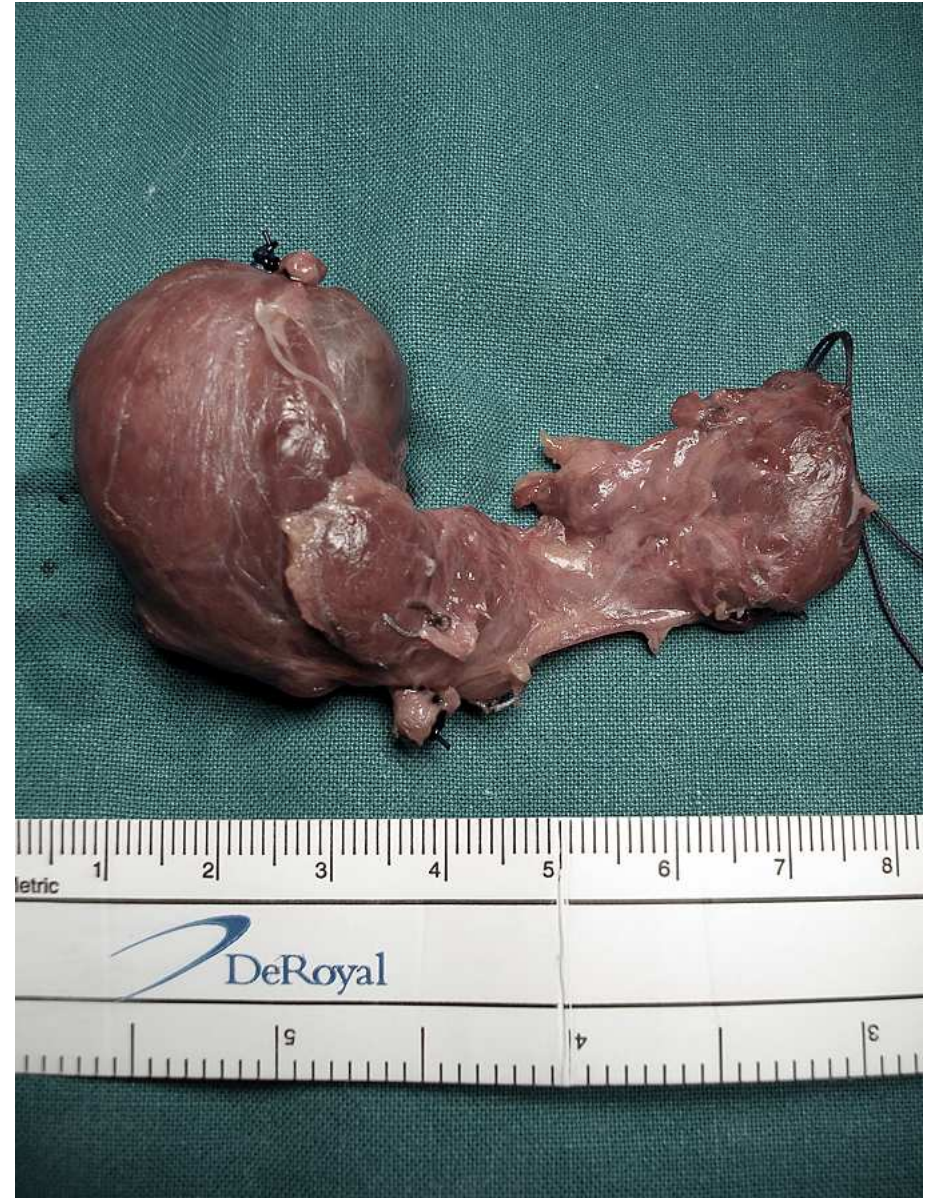Tiroidectomia totale extracapsulare per gozzo nodulare



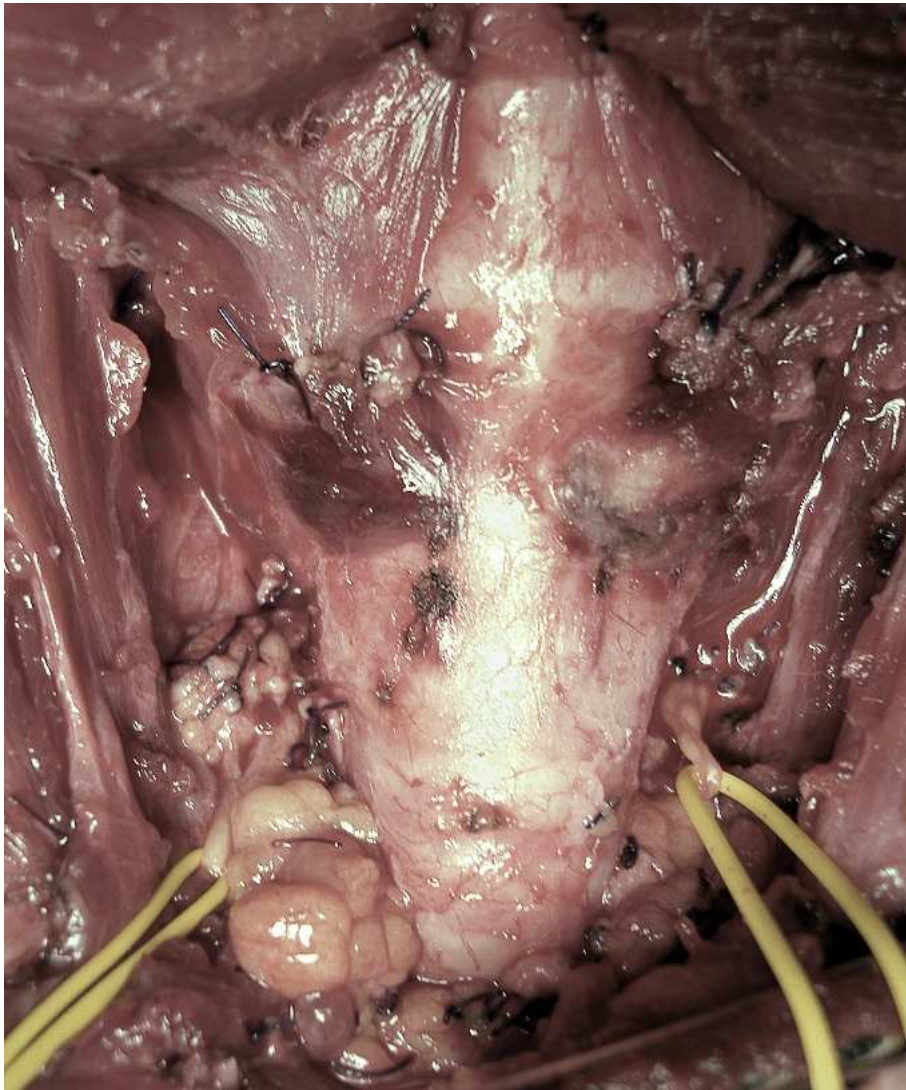
Isolamento dei nervi laringei inferiori (ricorrenti)



Lobo destro - Istmo - Lobo sinistro (superficie anteriore)

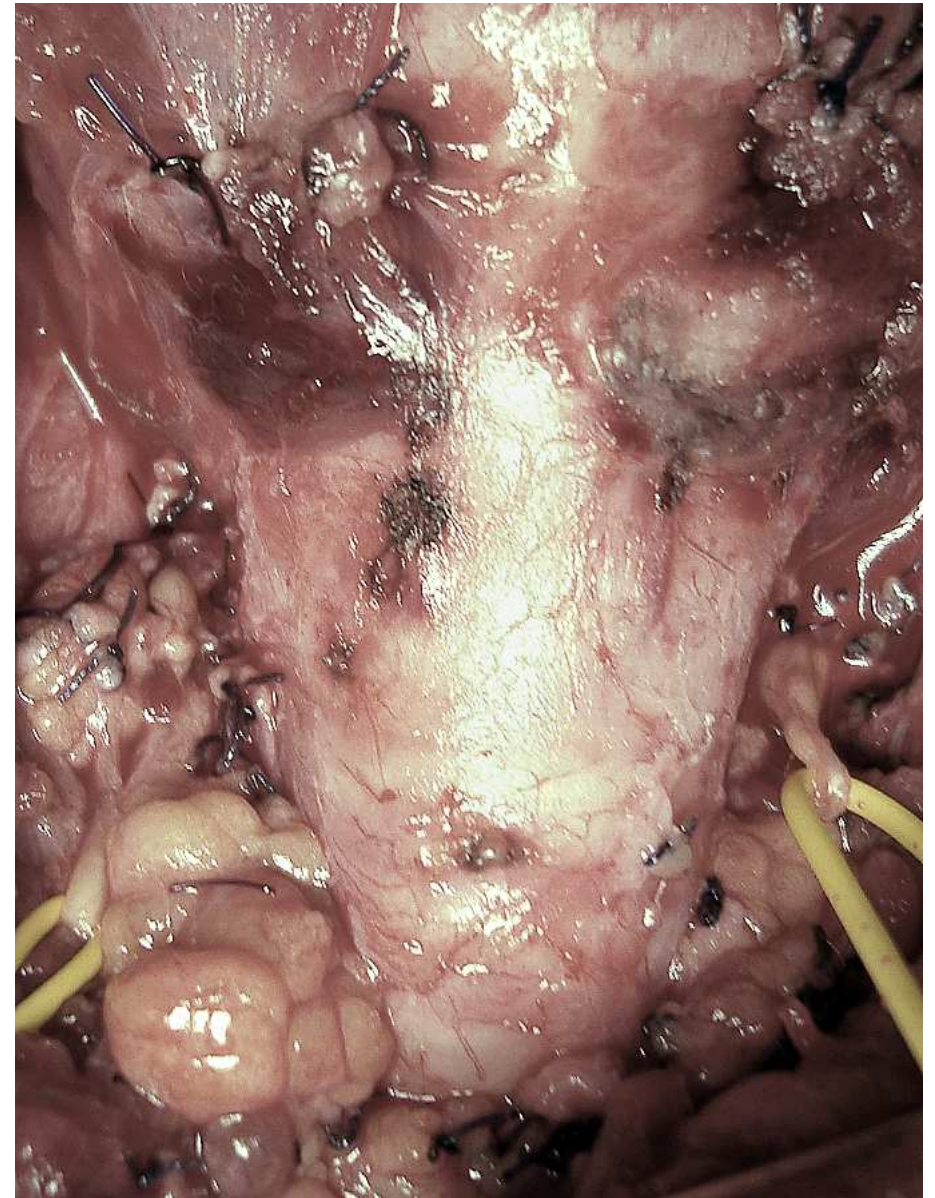


Lobo sinistro - Istmo - Lobo destro (superficie posteriore)



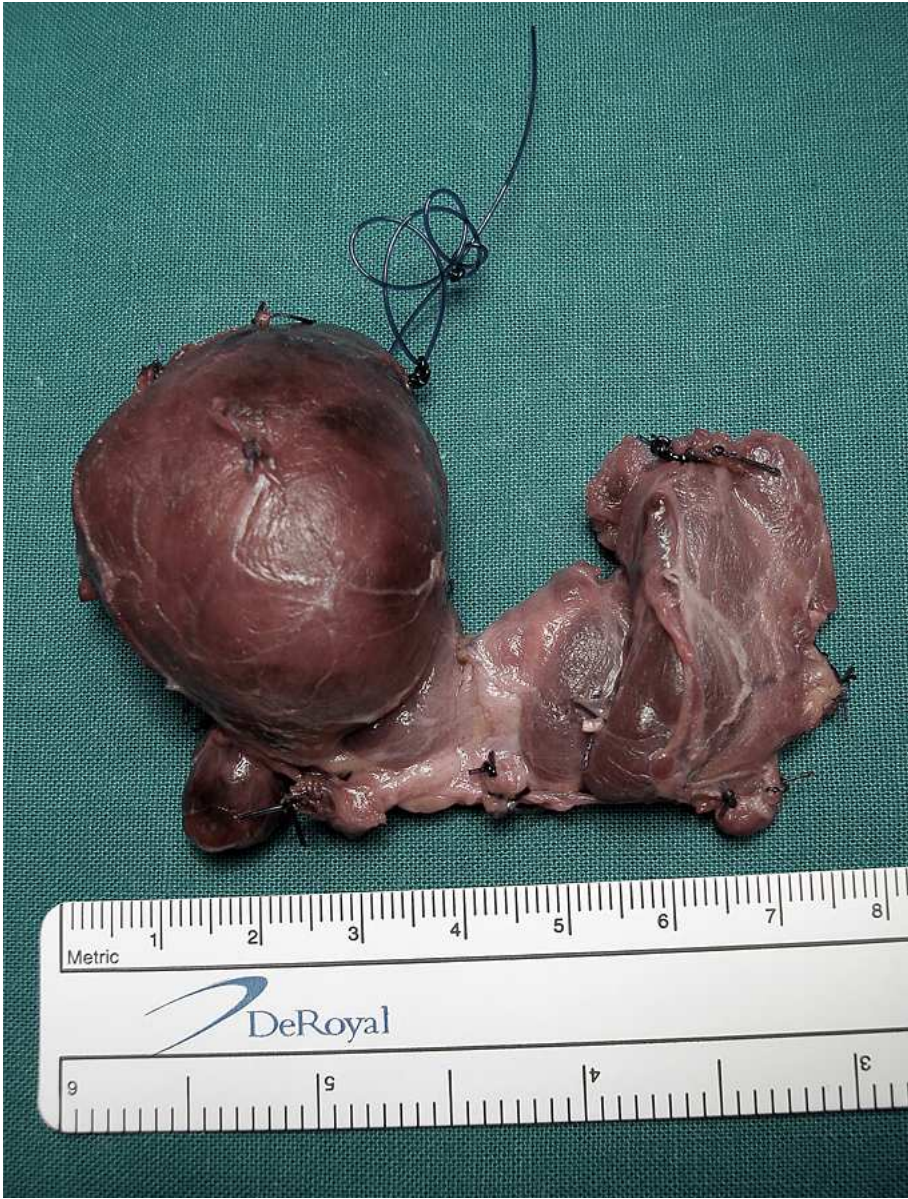M.A. • Anni: 43 - M • Record: 96 • 22-05-2006

Tiroidectomia totale extracapsulare per gozzo nodulare

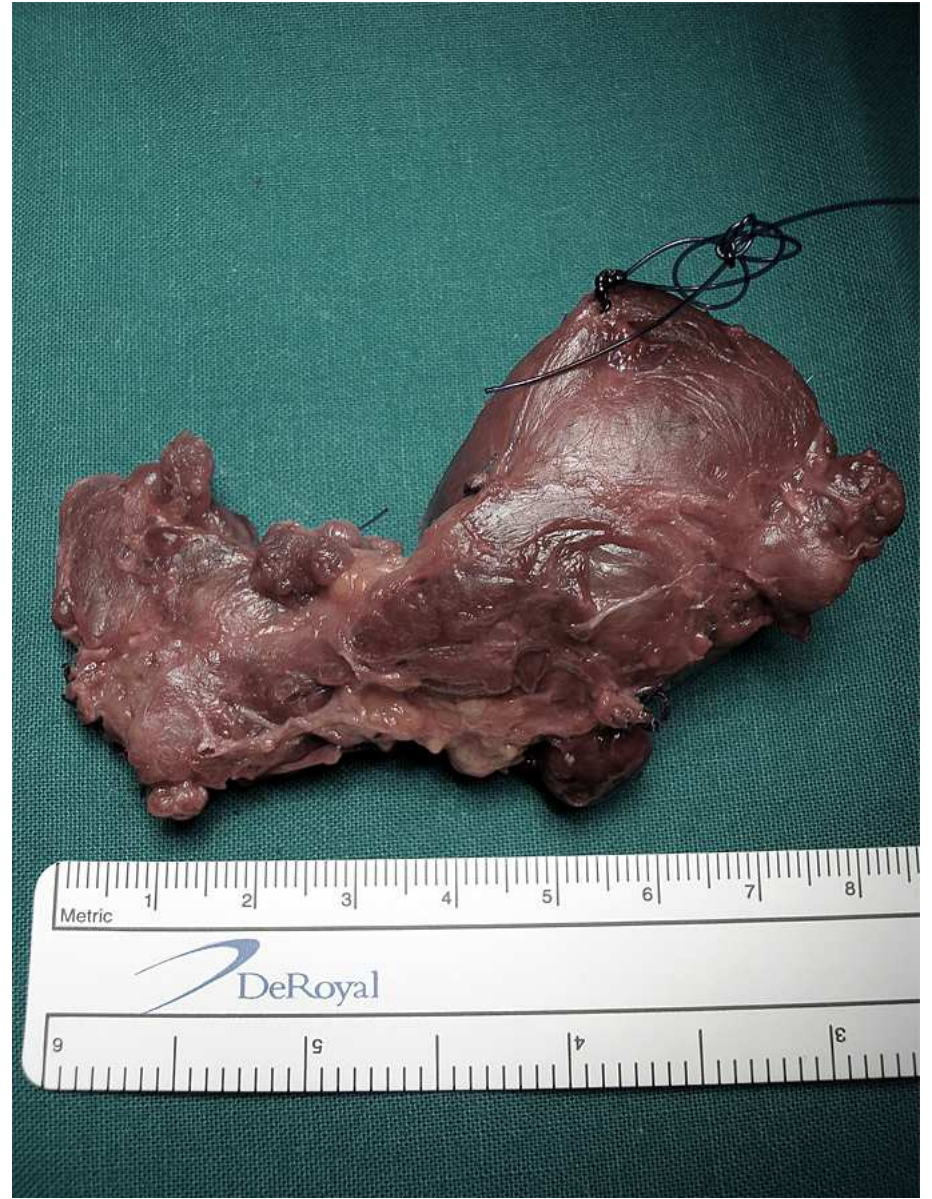

Isolamento dei nervi laringei inferiori (ricorrenti)

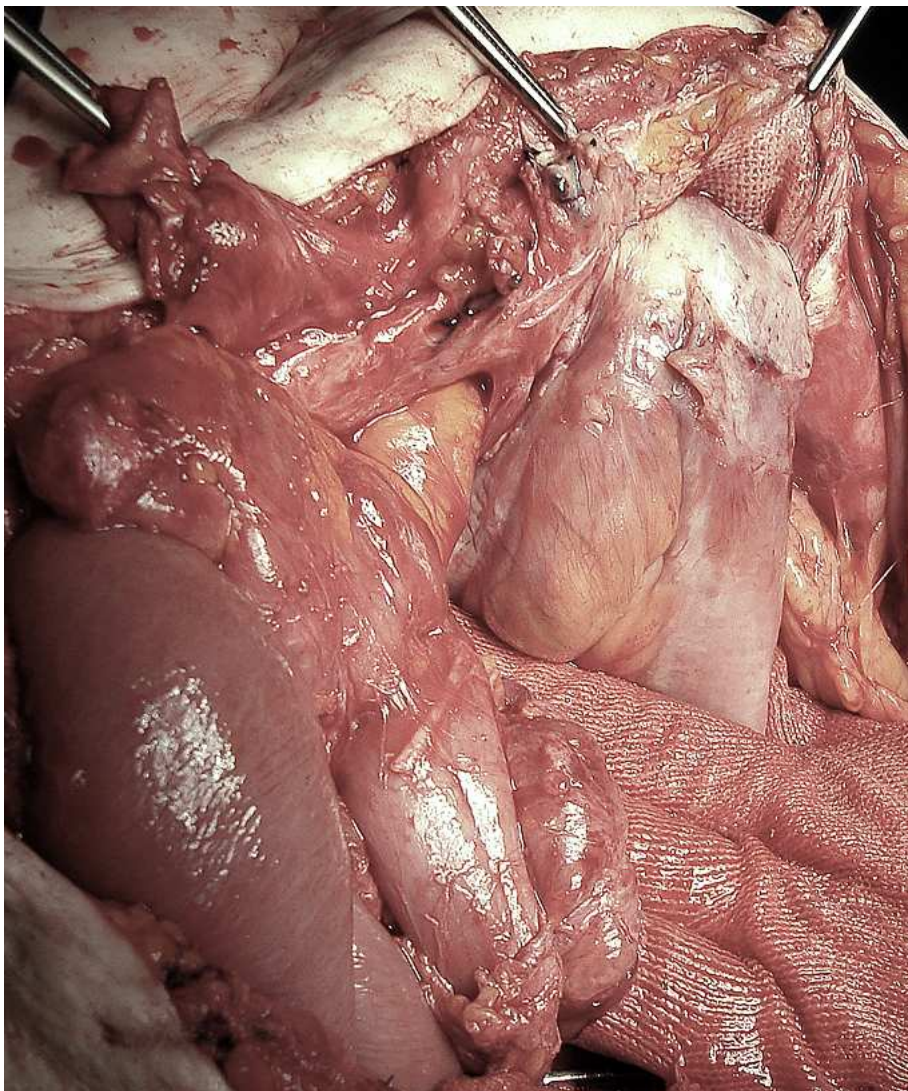




Lobo destro - Istmo - Lobo sinistro (superficie anteriore)

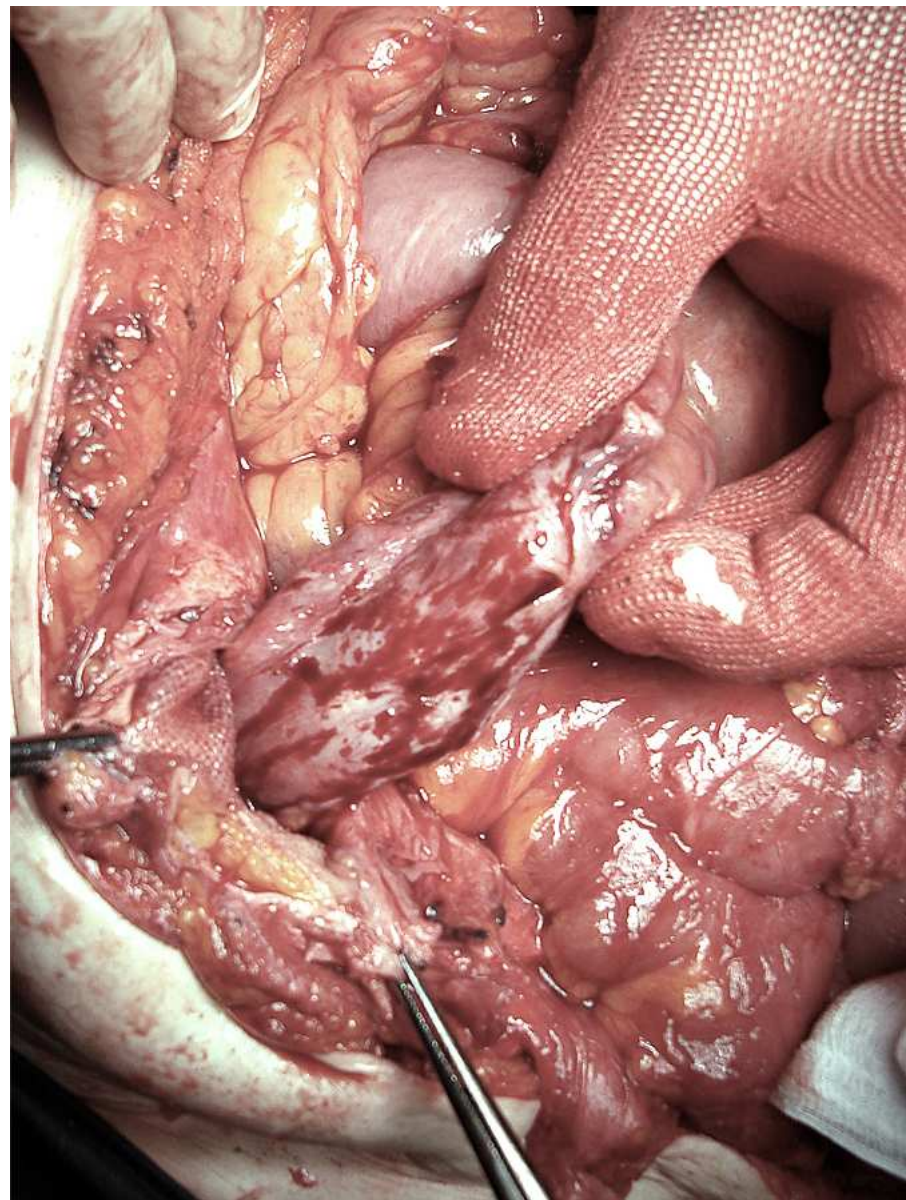


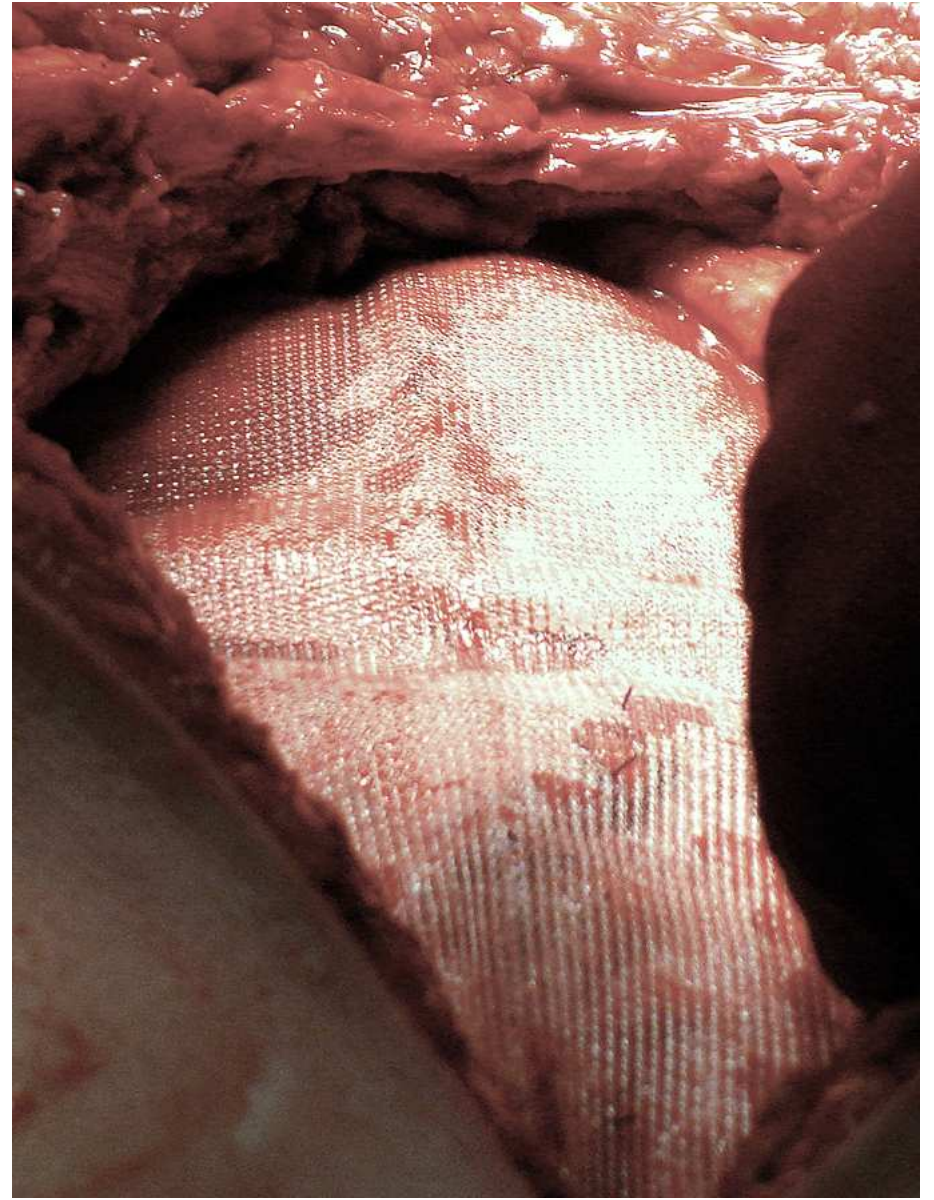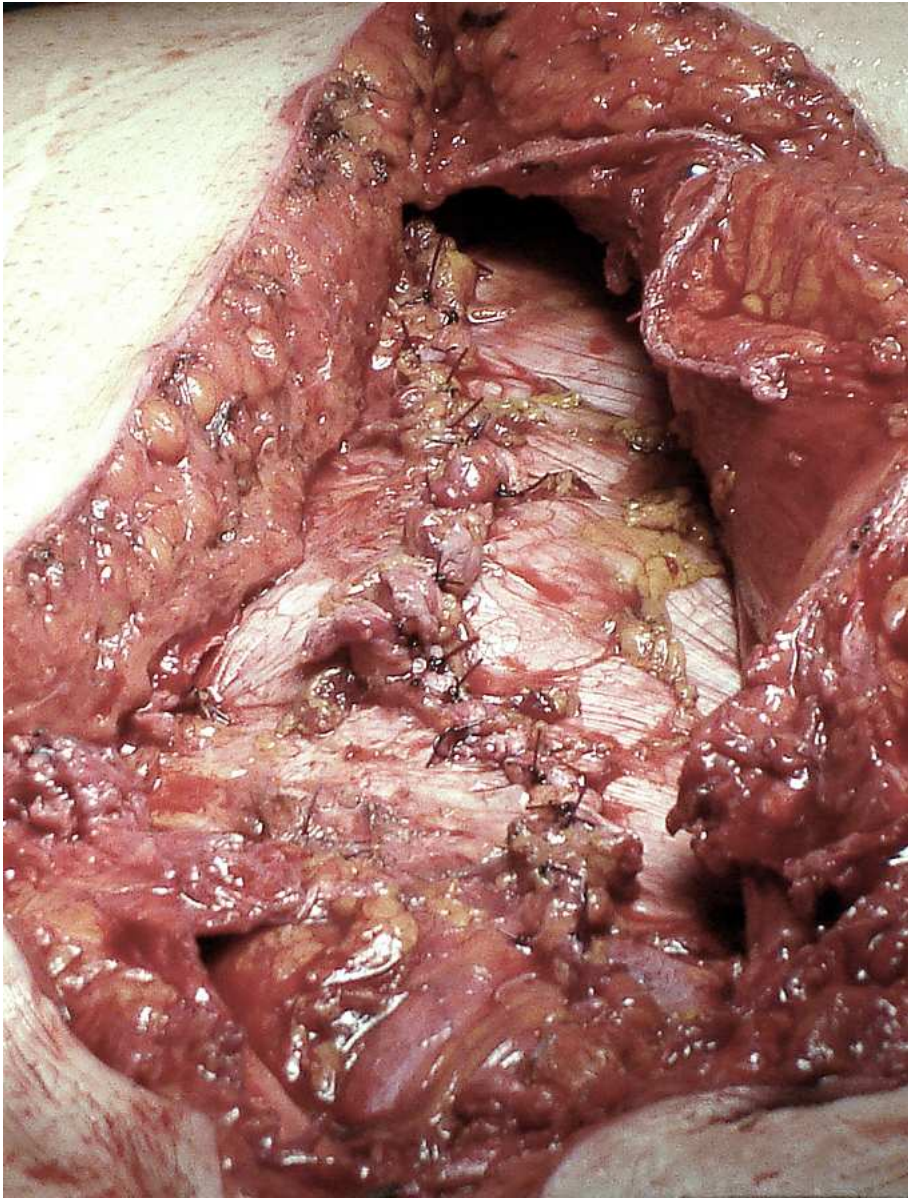
Lobo sinistro - Istmo - Lobo destro (superficie posteriore)

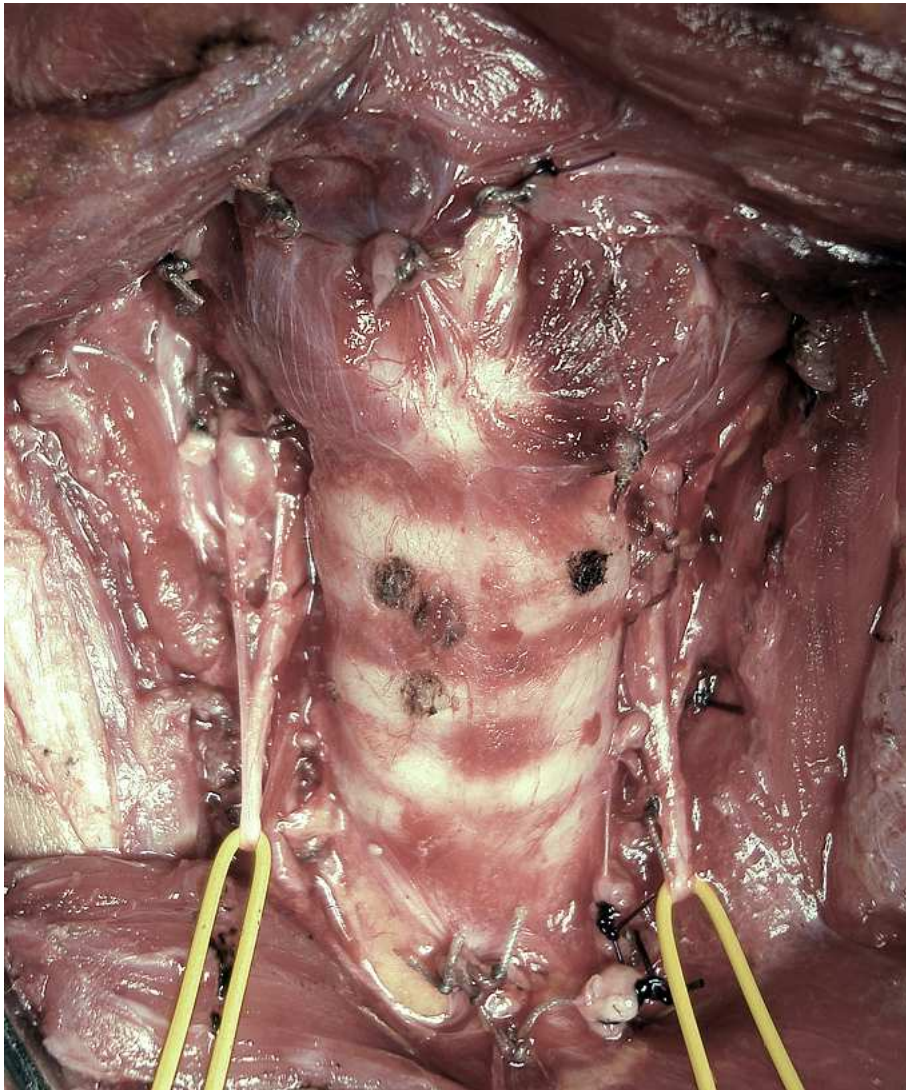


D.G. • Anni: 57 - F • Record: 97 • 24-05-2006

Resezione ileale e laparoalloplastica sec. Rives per occlusione intestinale da laparocèle mediano plurirecidivo strozzato

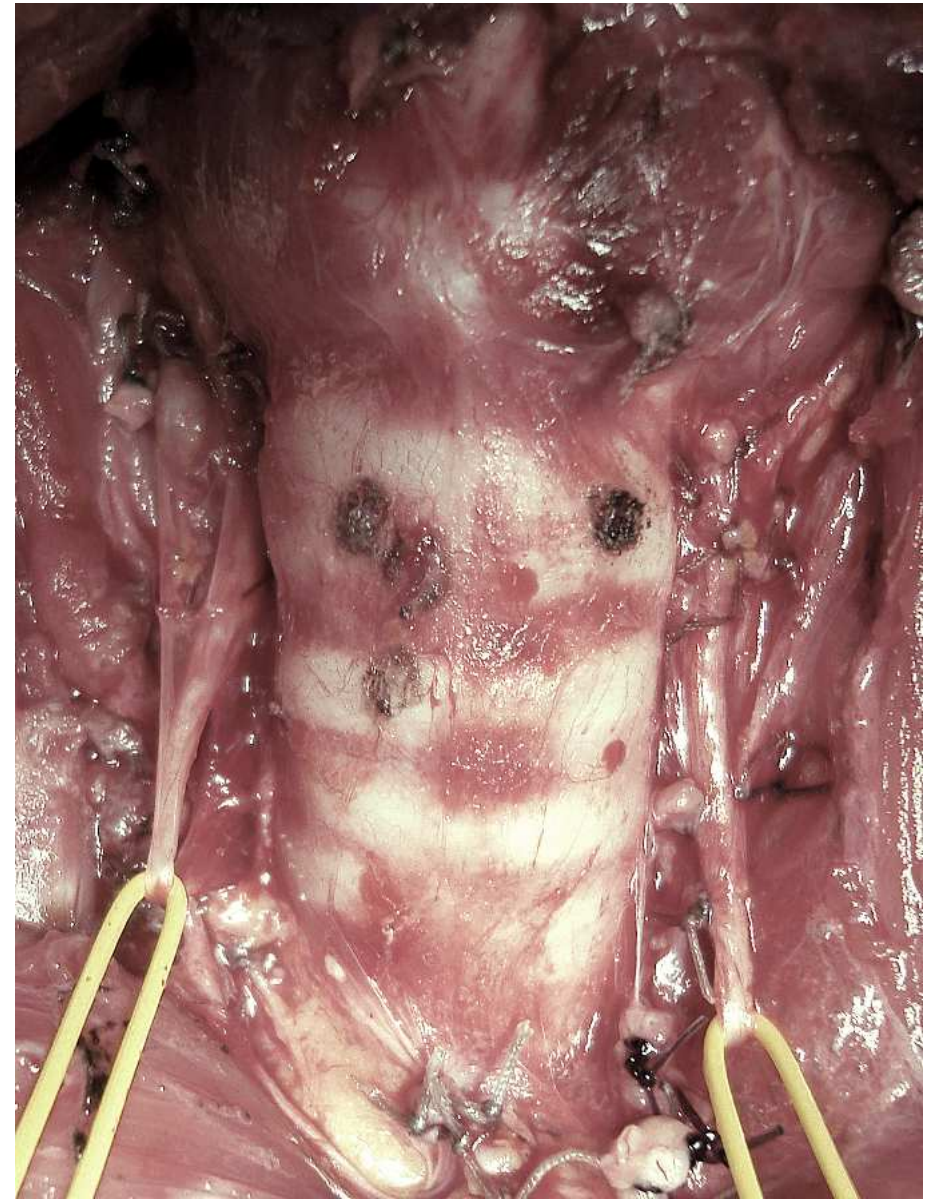




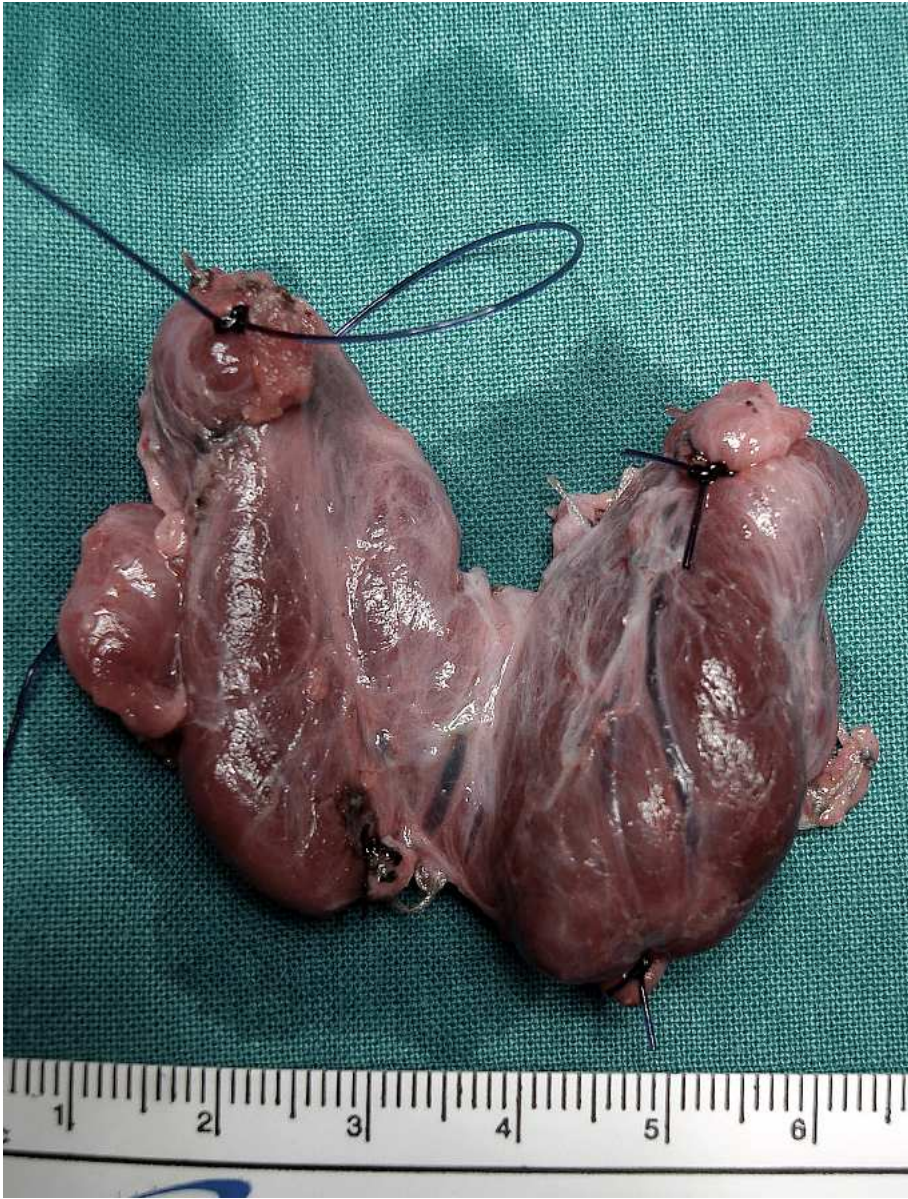


D.L. • Anni: 47 - F • Record: 98 • 06-09-2006

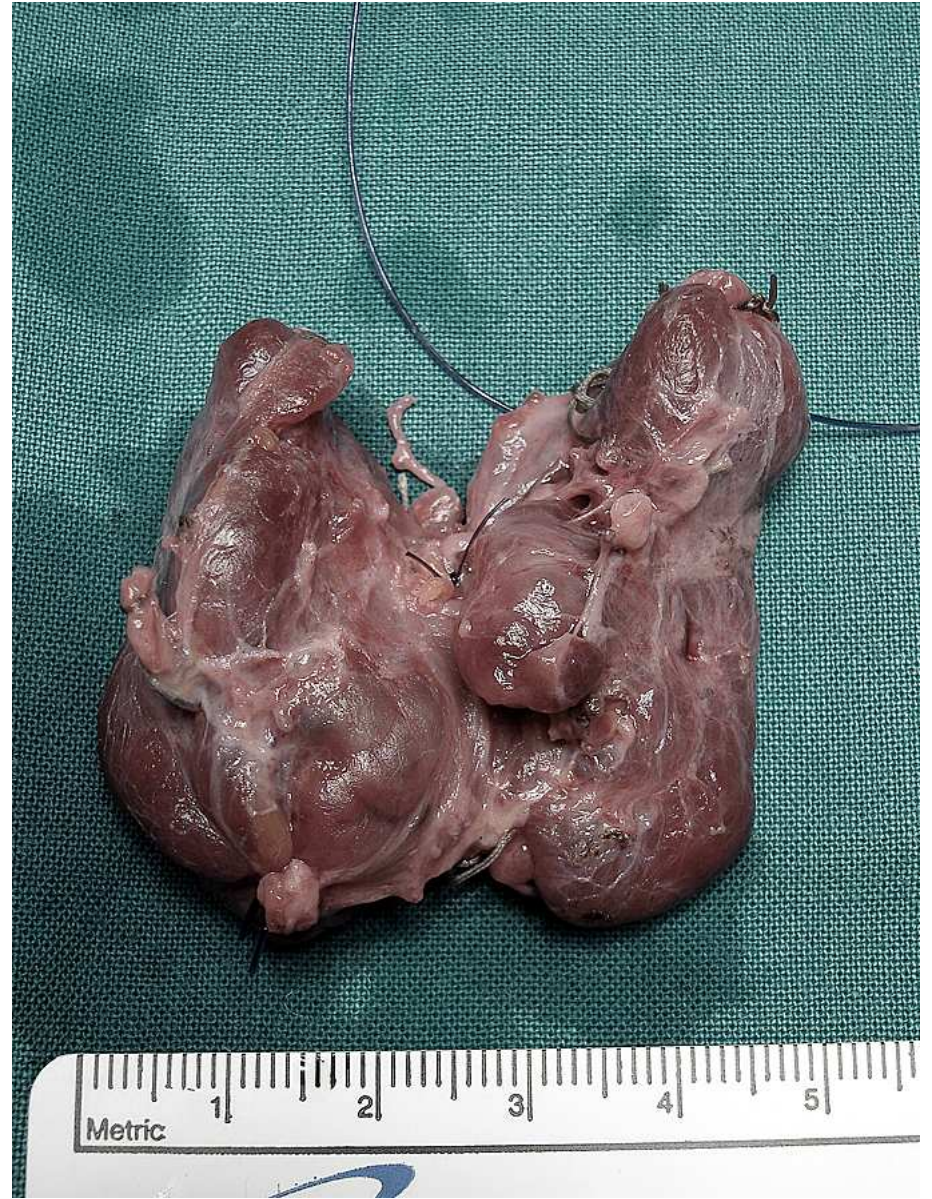
Tiroidectomia totale extracapsulare per adenoma follicolare del lobo sn in gozzo multinodulare



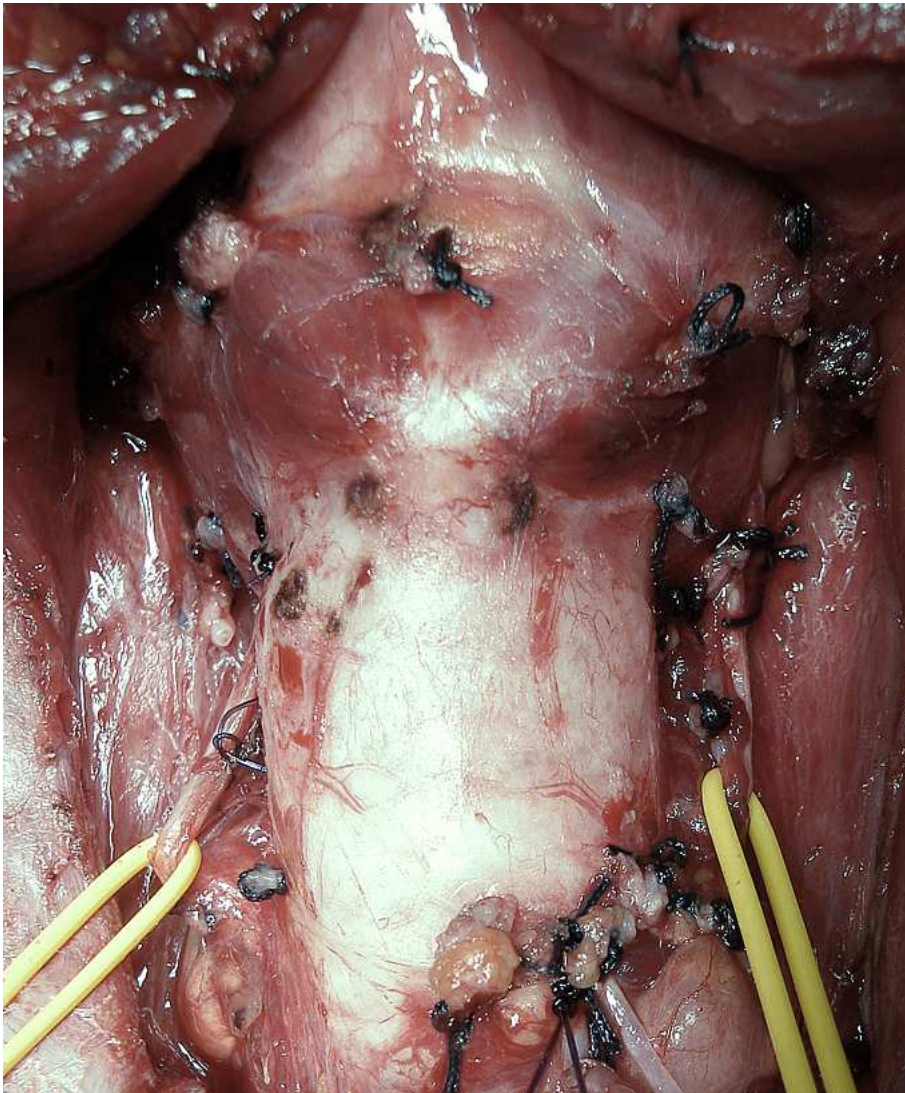
Isolamento dei nervi laringei inferiori (ricorrenti)



Lobo destro - Istmo - Lobo sinistro (superficie anteriore)

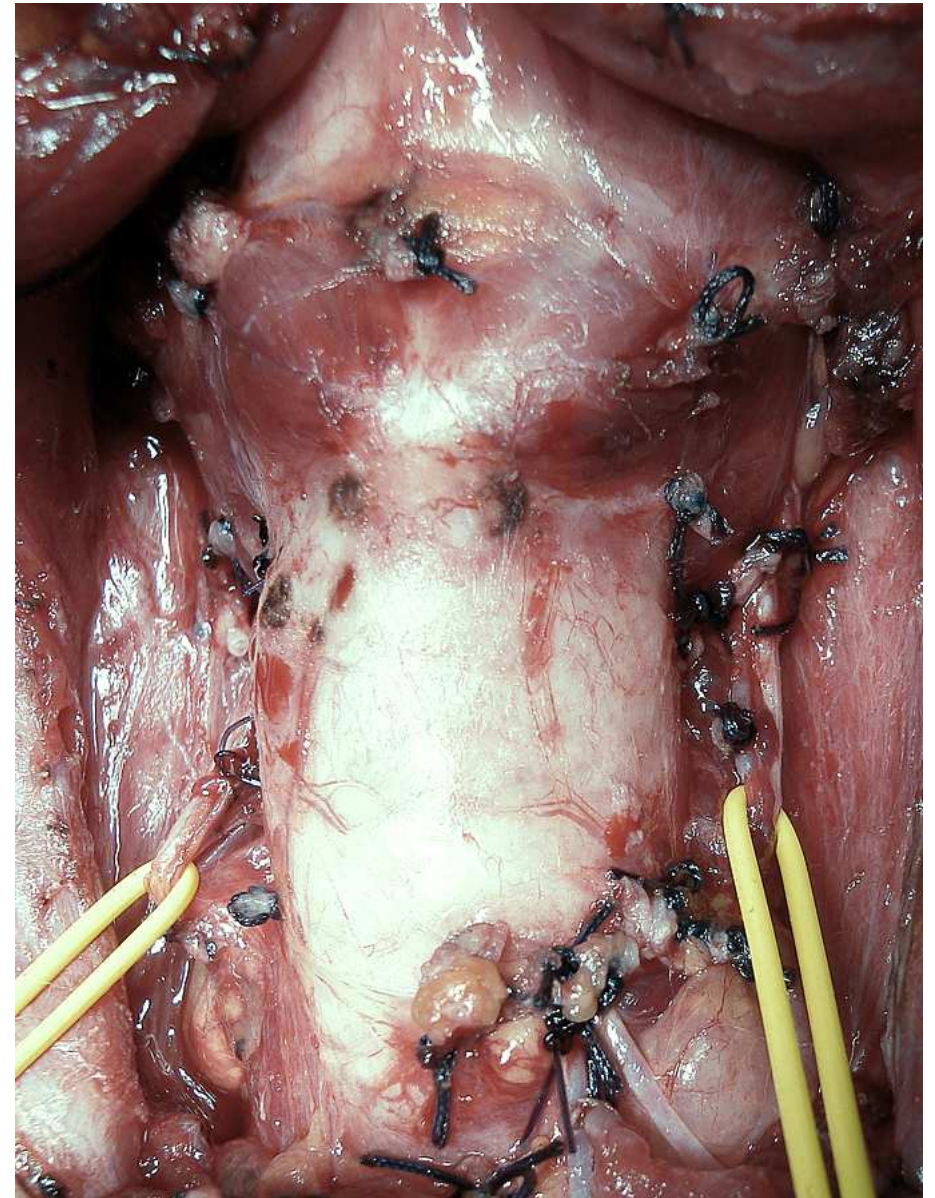


Lobo sinistro - Istmo - Lobo destro (superficie posteriore)

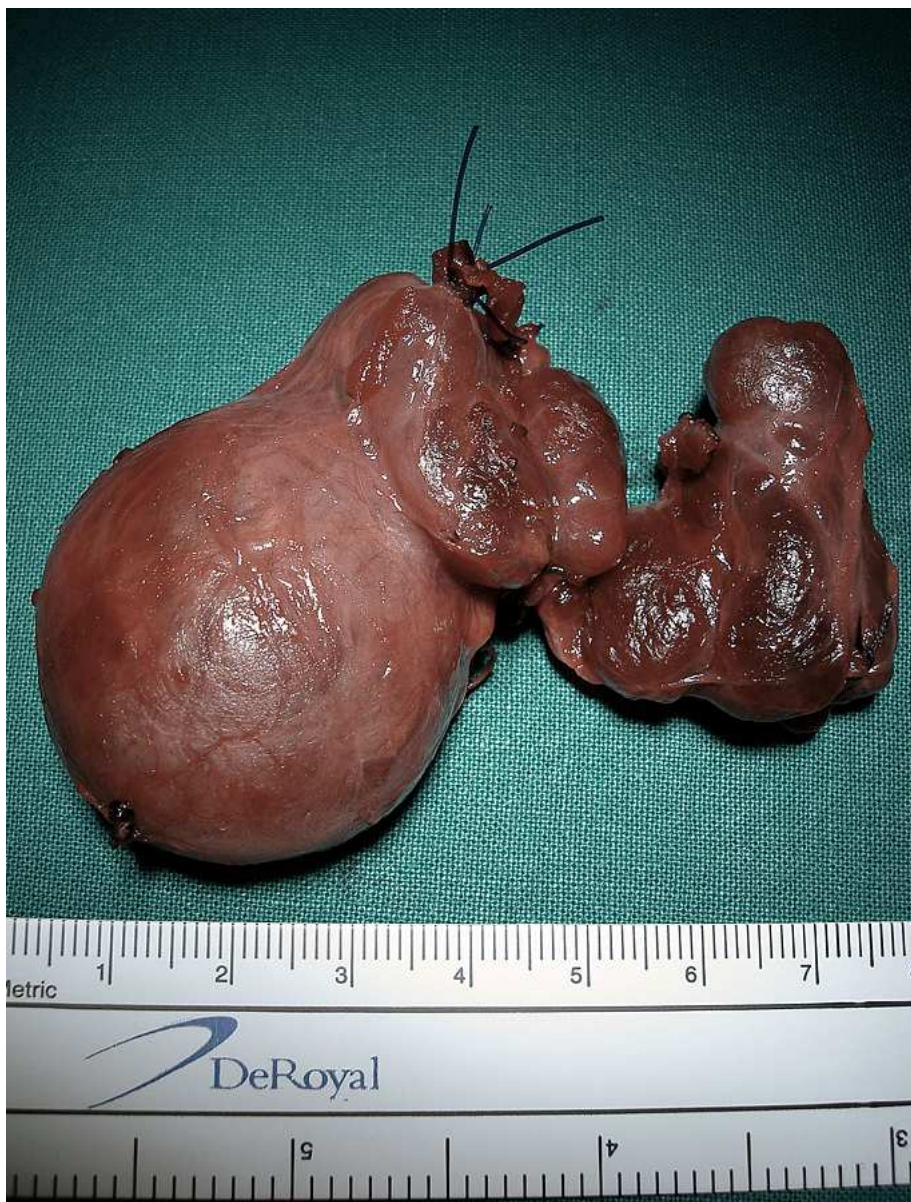


L.A. • Anni: 24 - F • Record: 1 • 05-10-2006

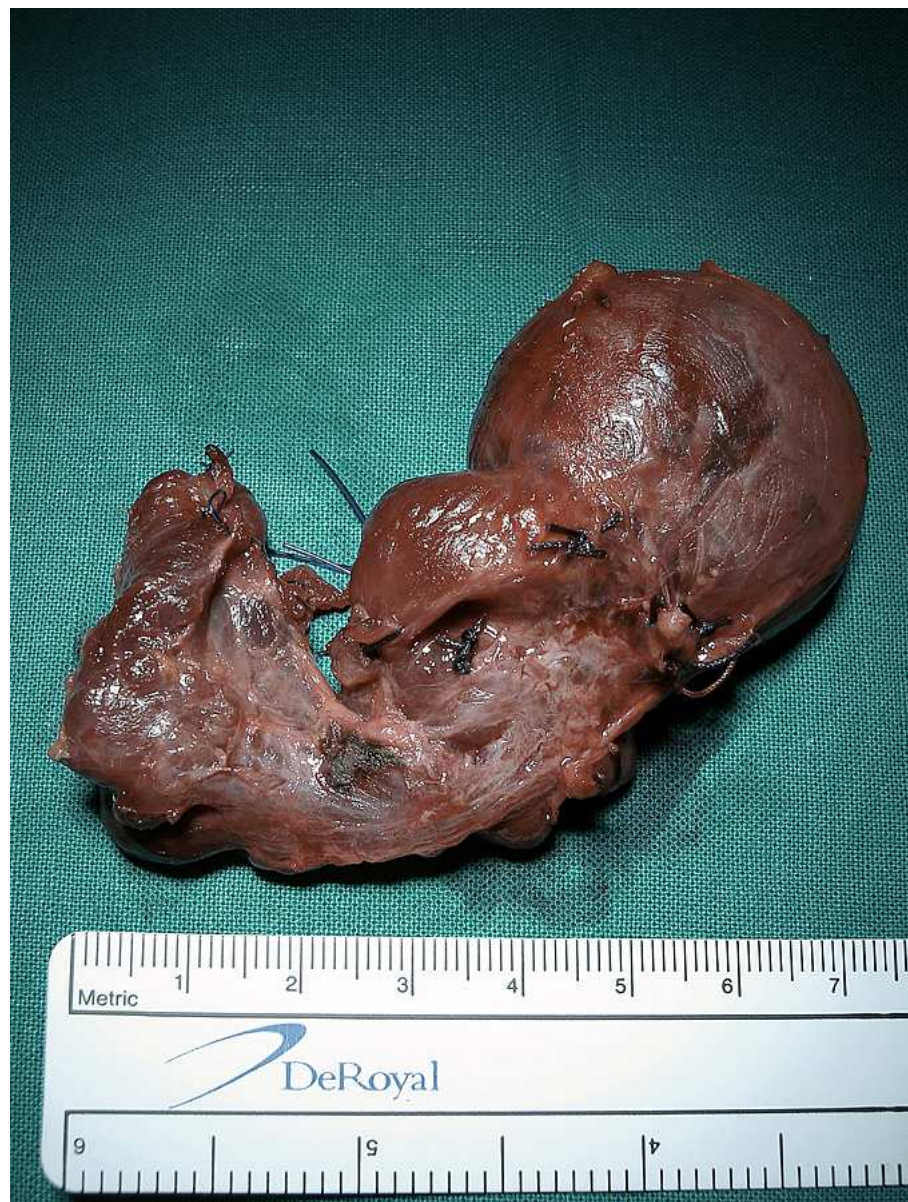Tiroidectomia totale extracapsulare per adenoma follicolare in gozzo plurinodulare con sezione dei muscoli pretiroidei



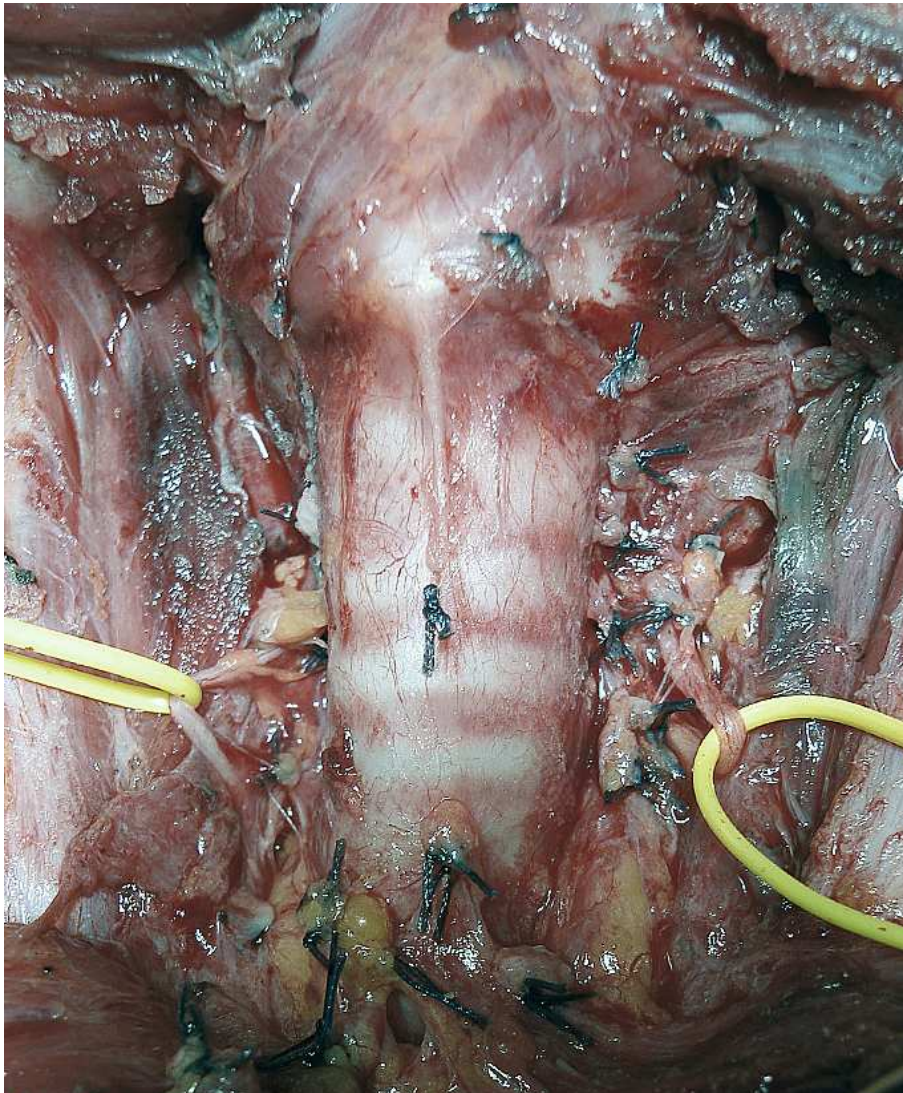
Isolamento dei nervi laringei inferiori (ricorrenti)



Lobo destro - Istmo - Lobo sinistro (superficie anteriore)

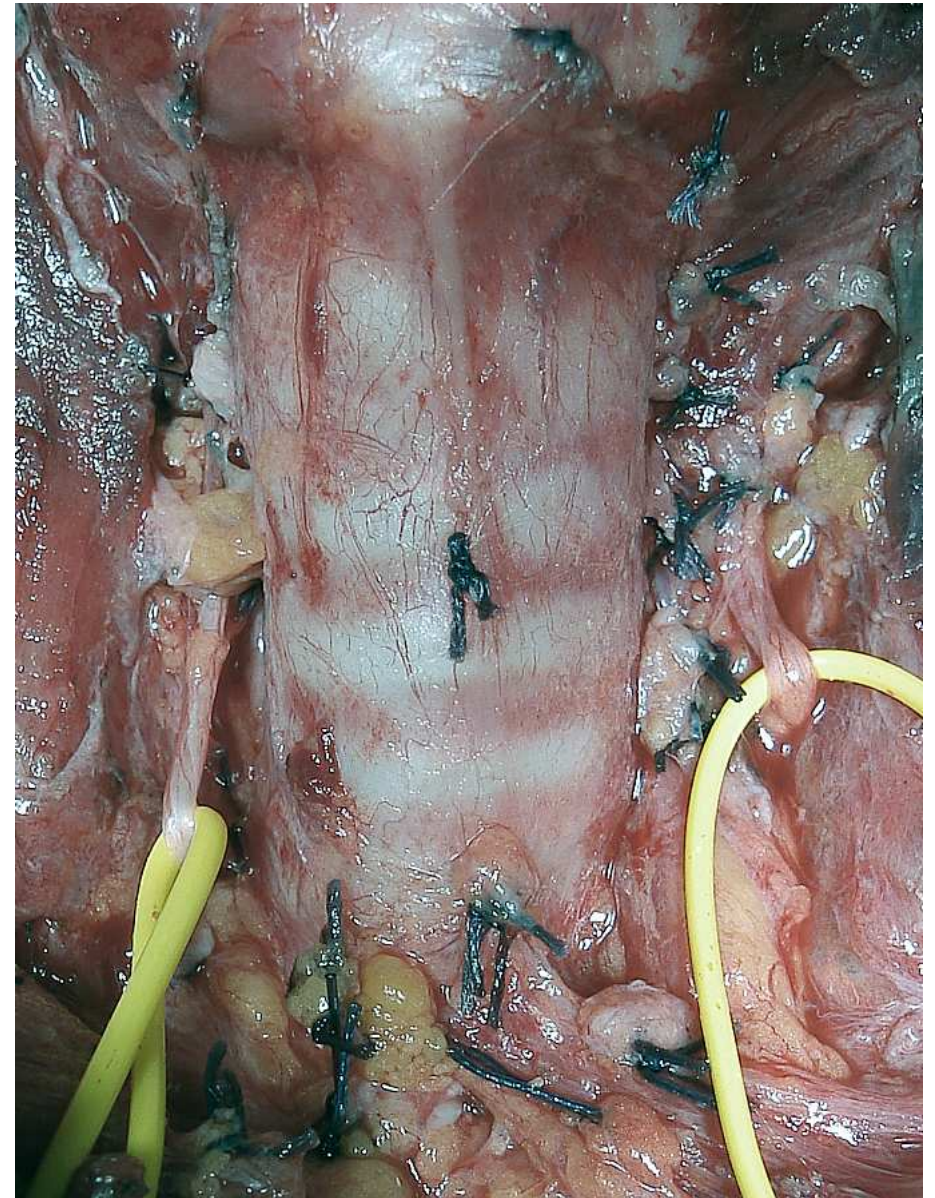


Lobo sinistro - Istmo - Lobo destro (superficie posteriore)



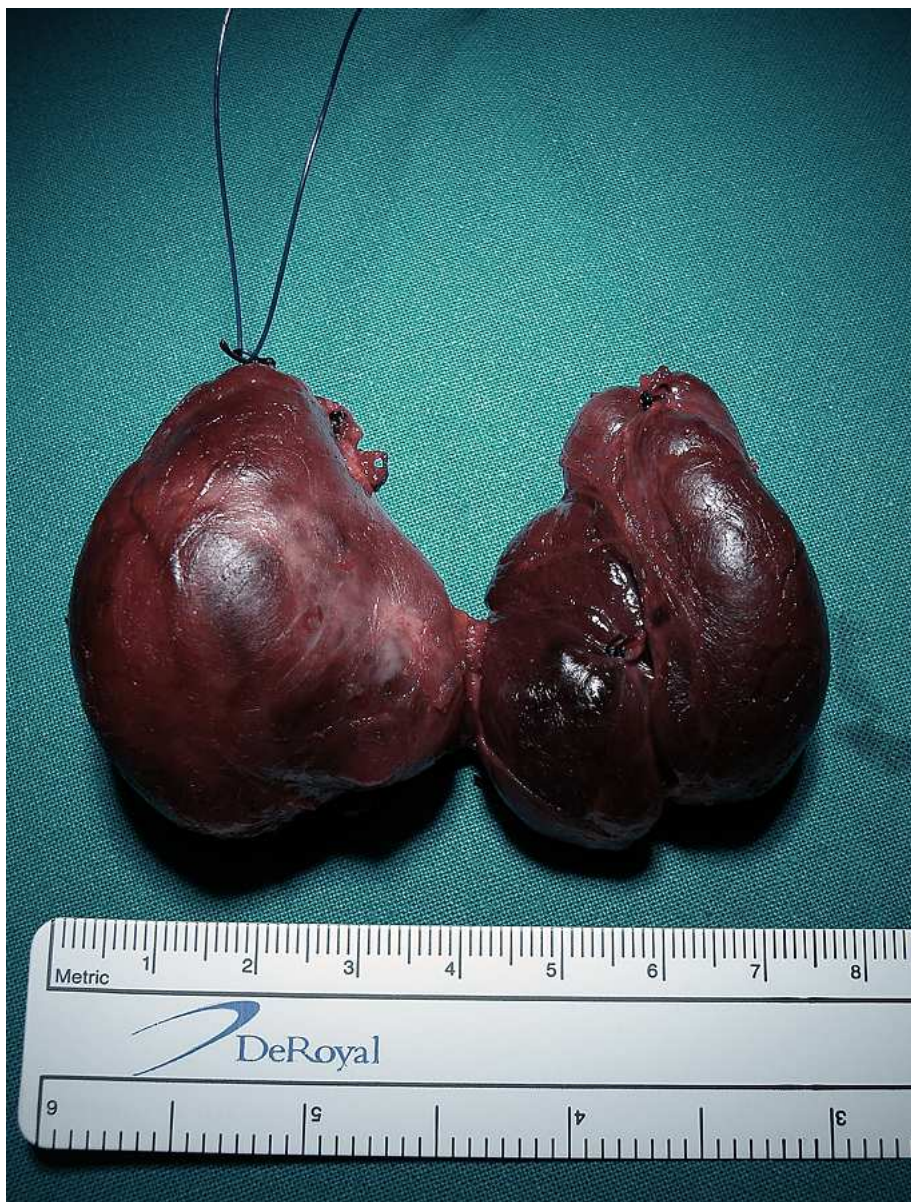
I.A. • Anni: 35 - F • Record: 2 • 05-10-2006

Tiroidectomia totale extracapsulare per gozzo plurinodulare con sezione dei muscoli pretiroidei

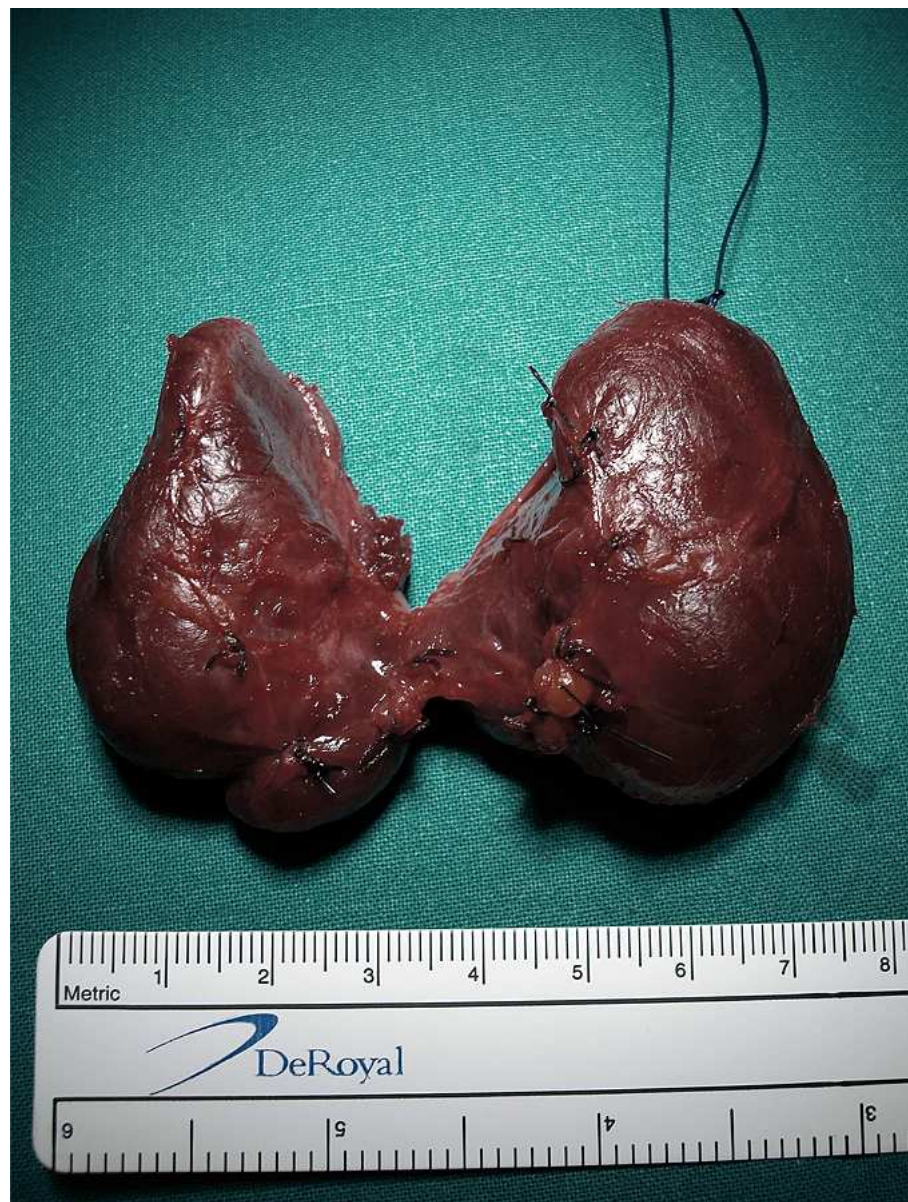


Isolamento dei nervi laringei inferiori (ricorrenti)

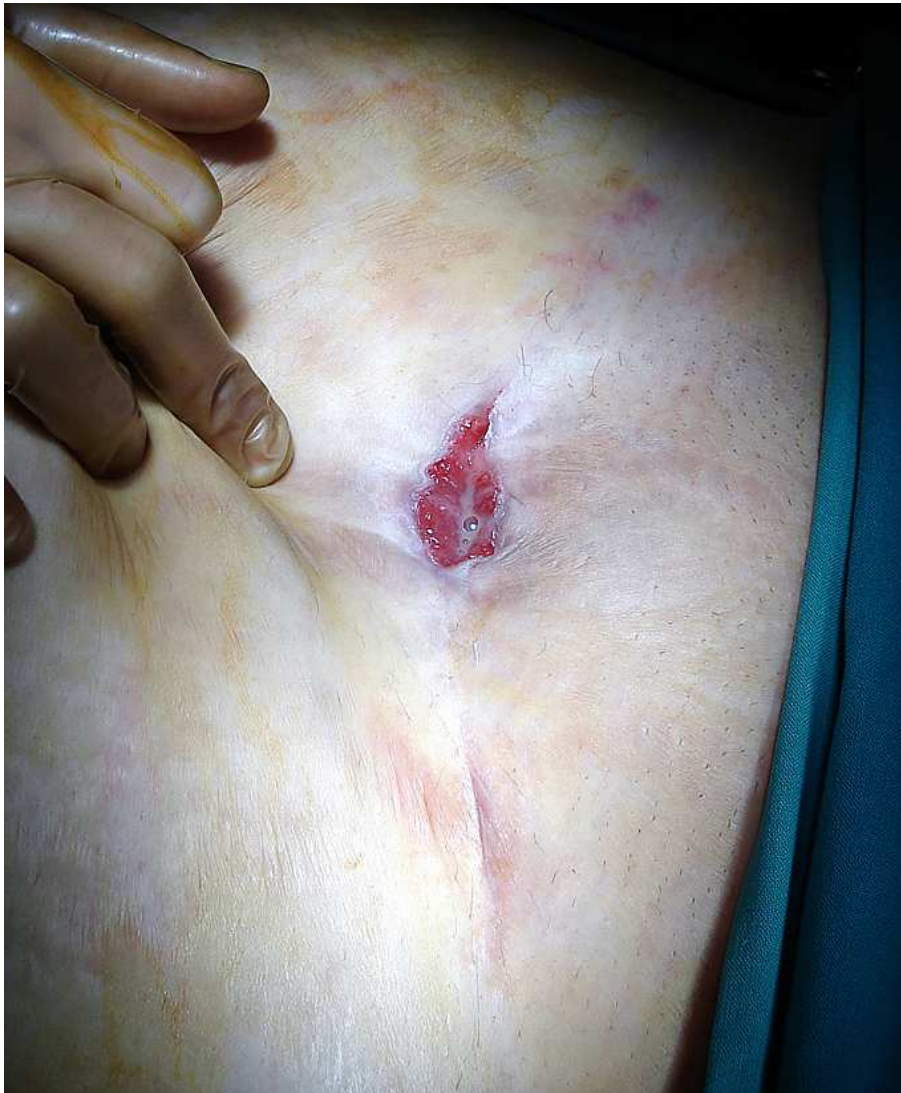



Lobo destro - Istmo - Lobo sinistro (superficie anteriore)

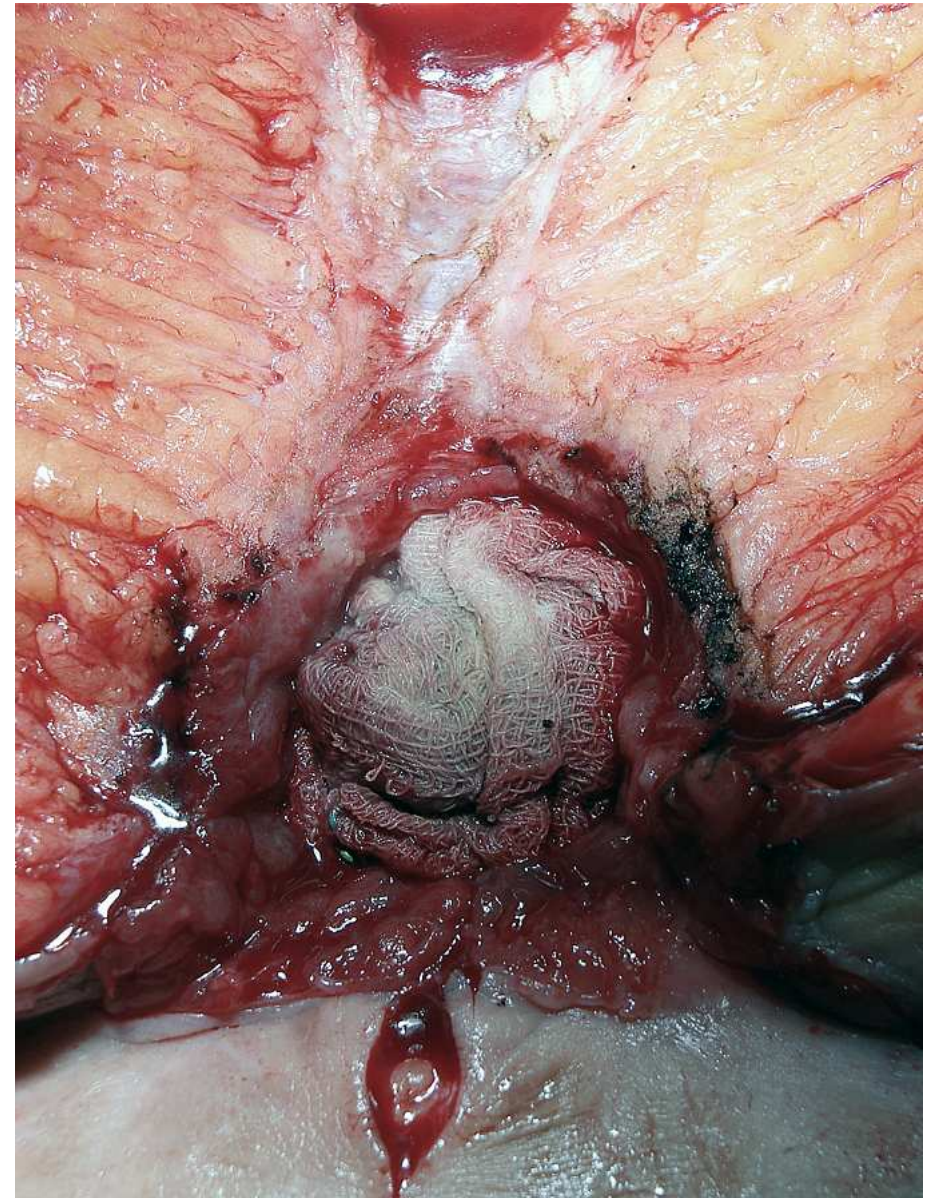


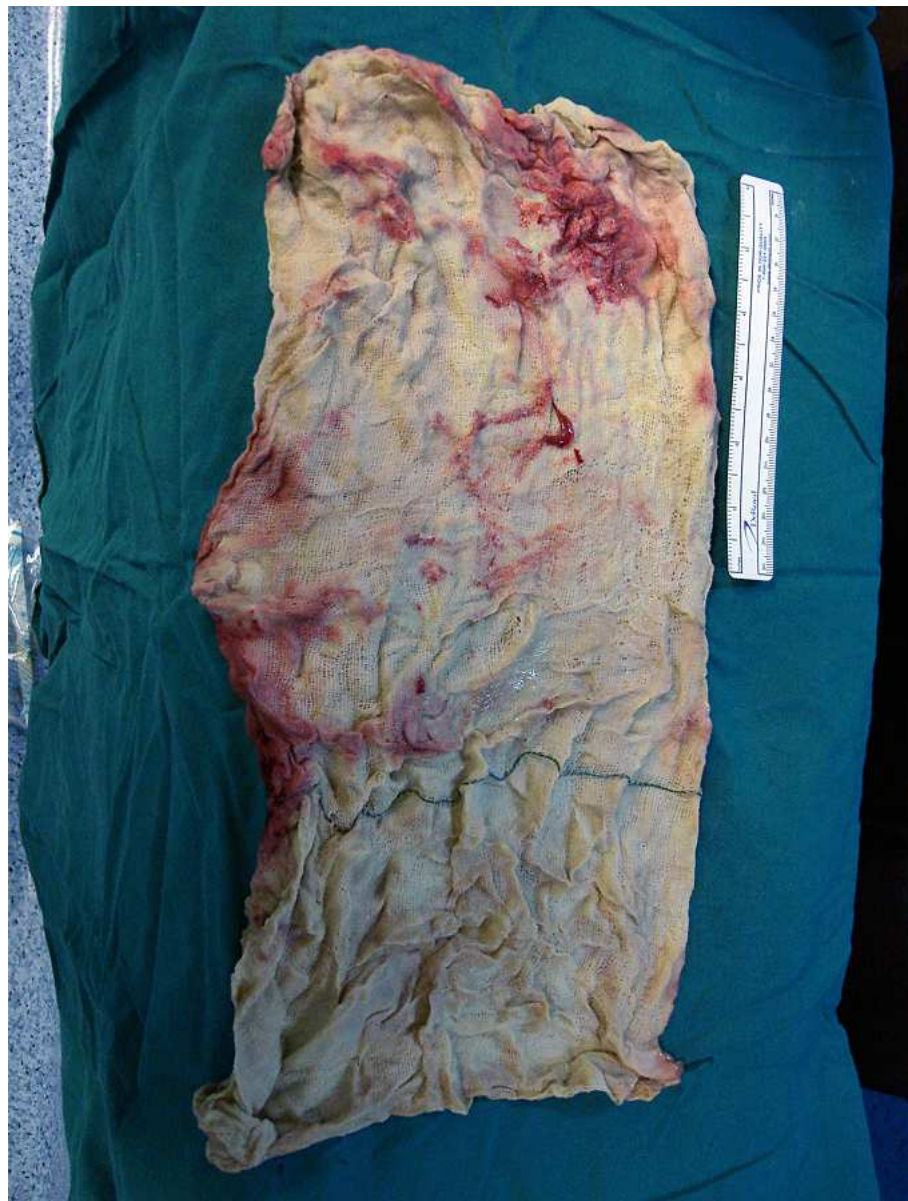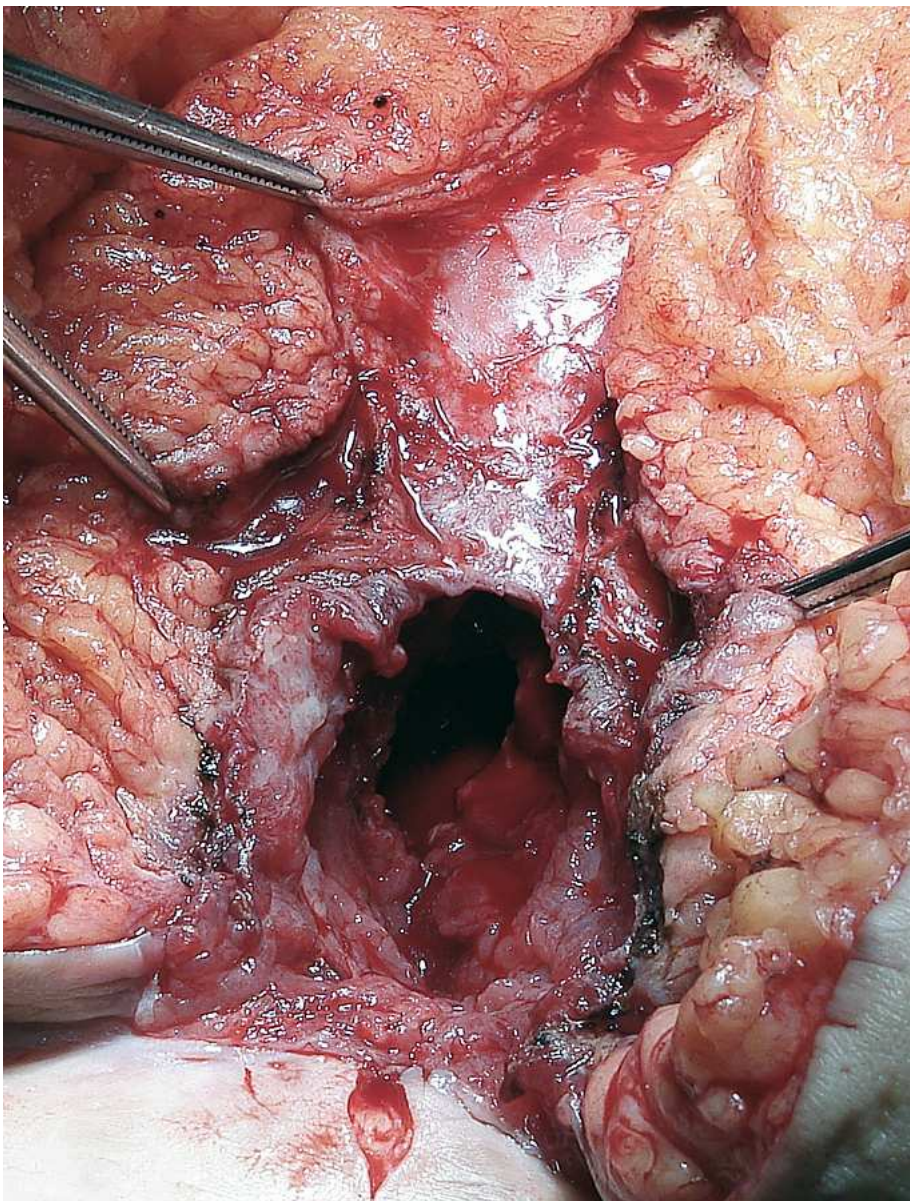
Lobo sinistro - Istmo - Lobo destro (superficie posteriore)

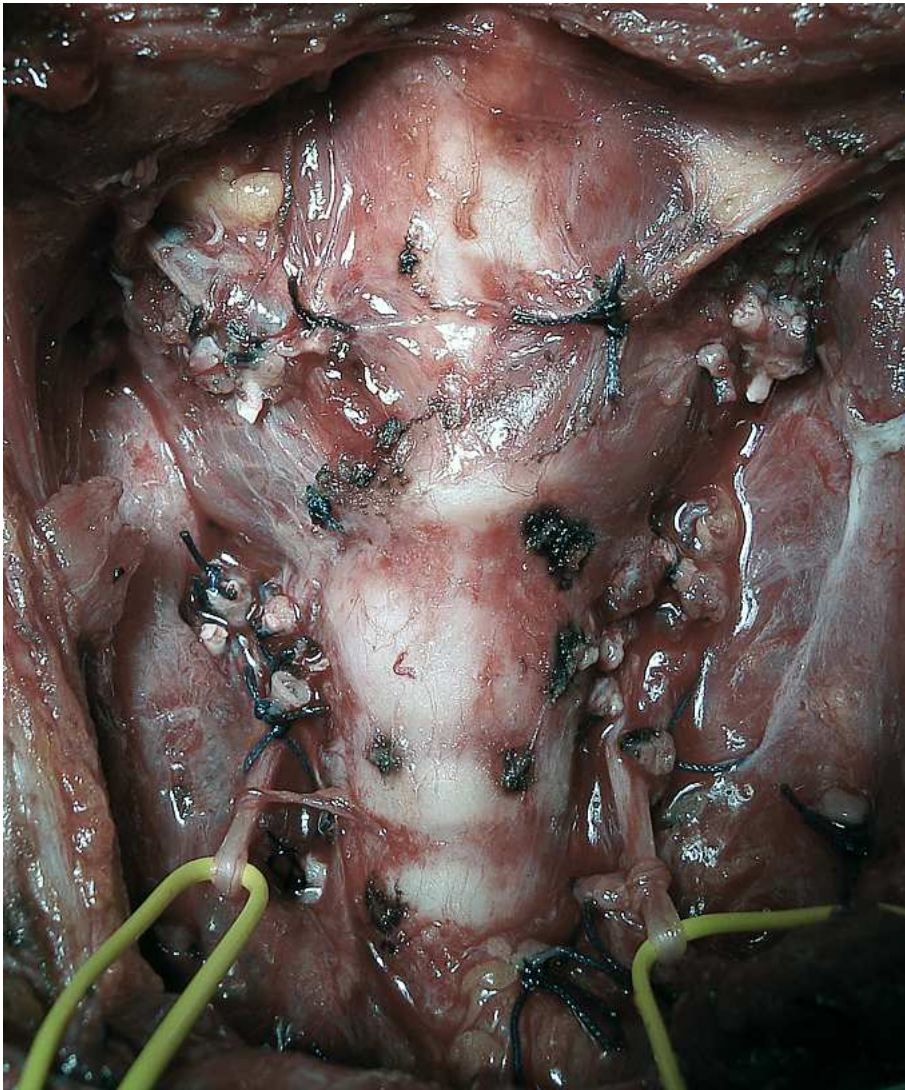

G.E. • Anni: 48 - F • Record: 3 • 19-10-2006

Rimozione di corpo estraneo (garza) ritenuto in cavita' ascessuale sottofasciale ipogastrica in recente isterectomizzata

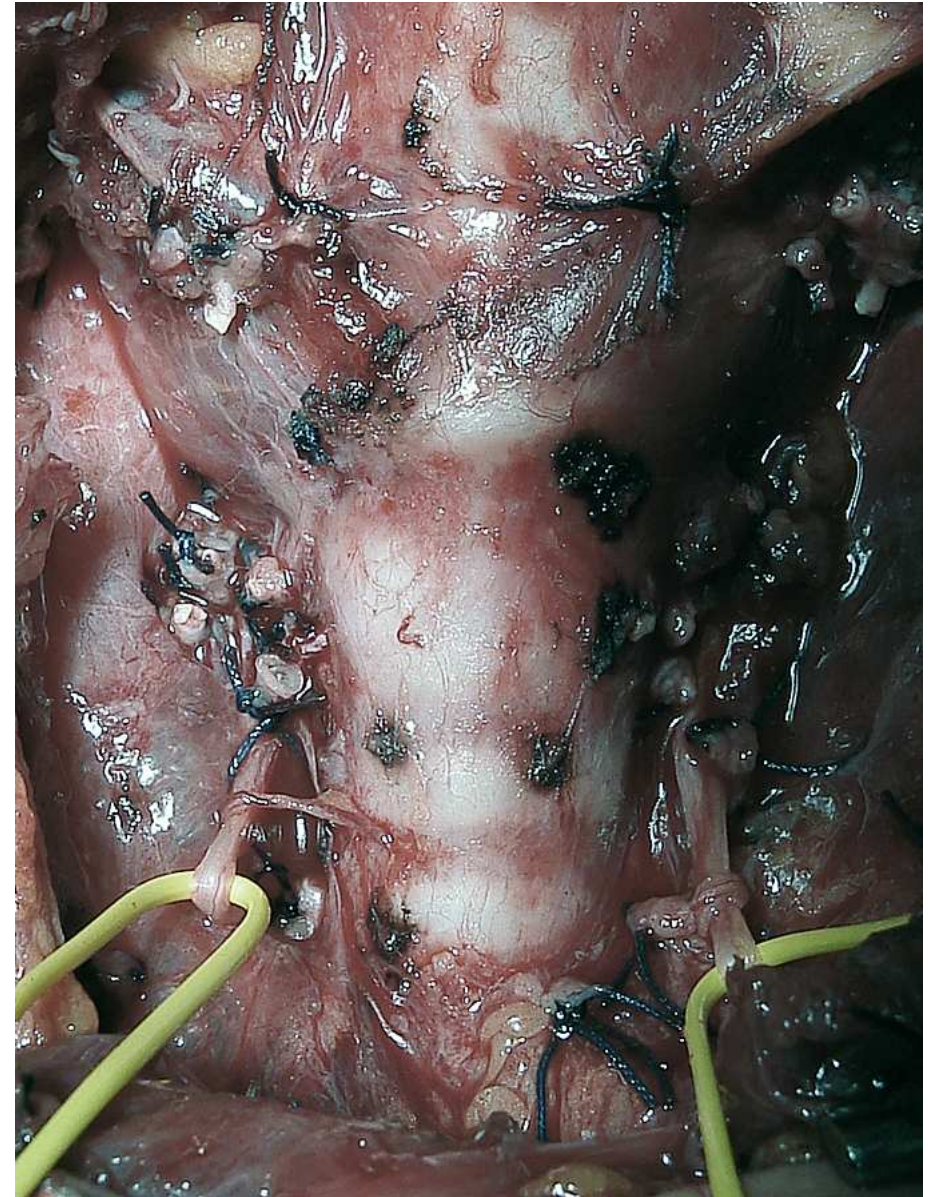




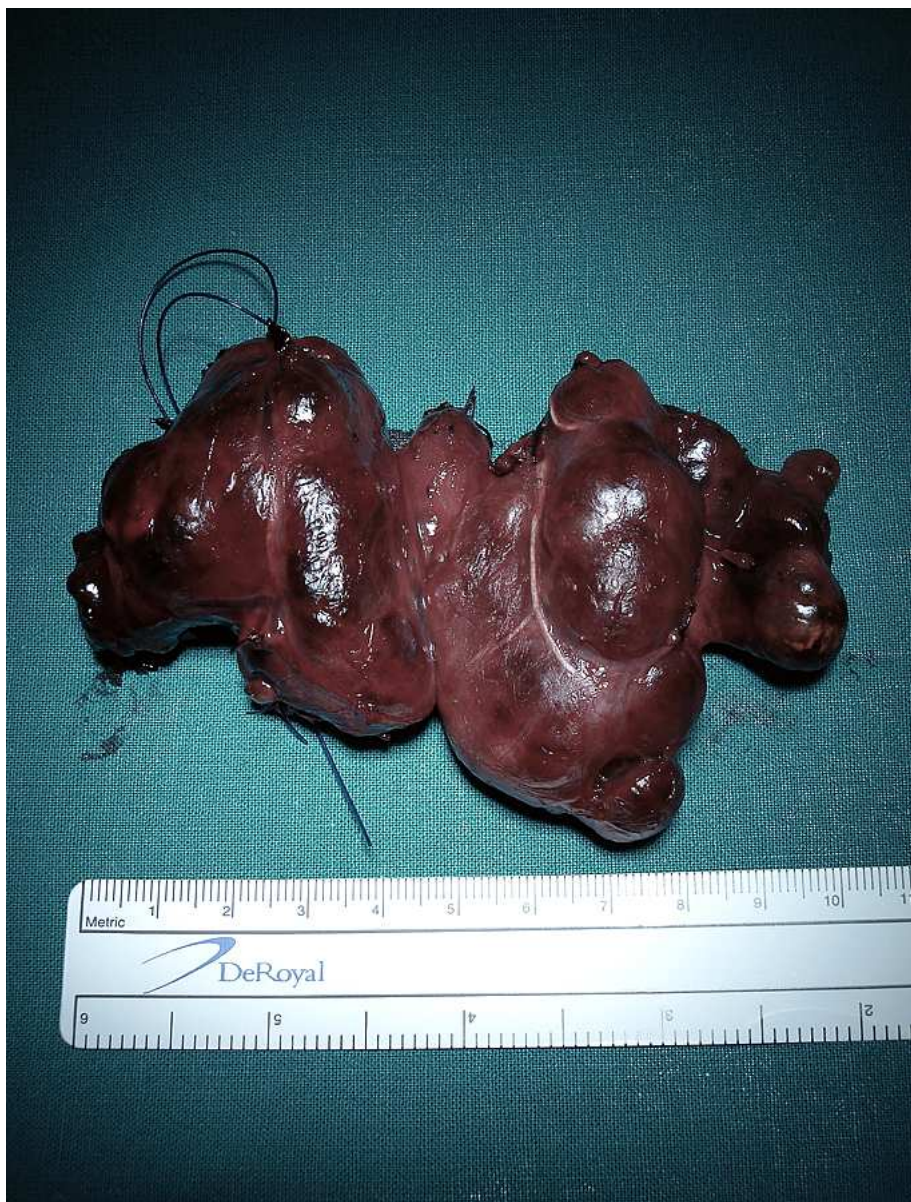

A.S.C. • Anni: 68 - F • Record: 4 • 30-10-2006

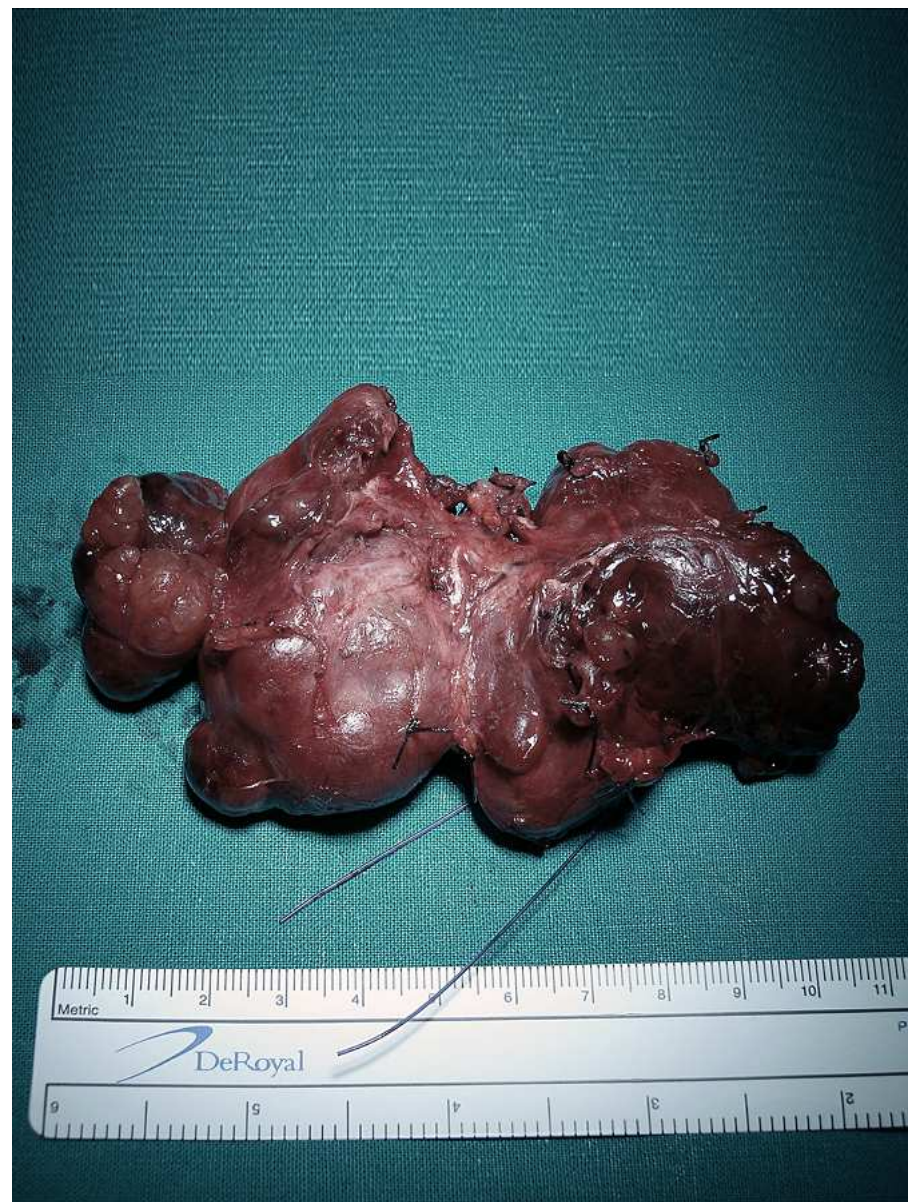Tiroidectomia totale extracapsulare per gozzo plurinodulare con sezione dei muscoli pretiroidei



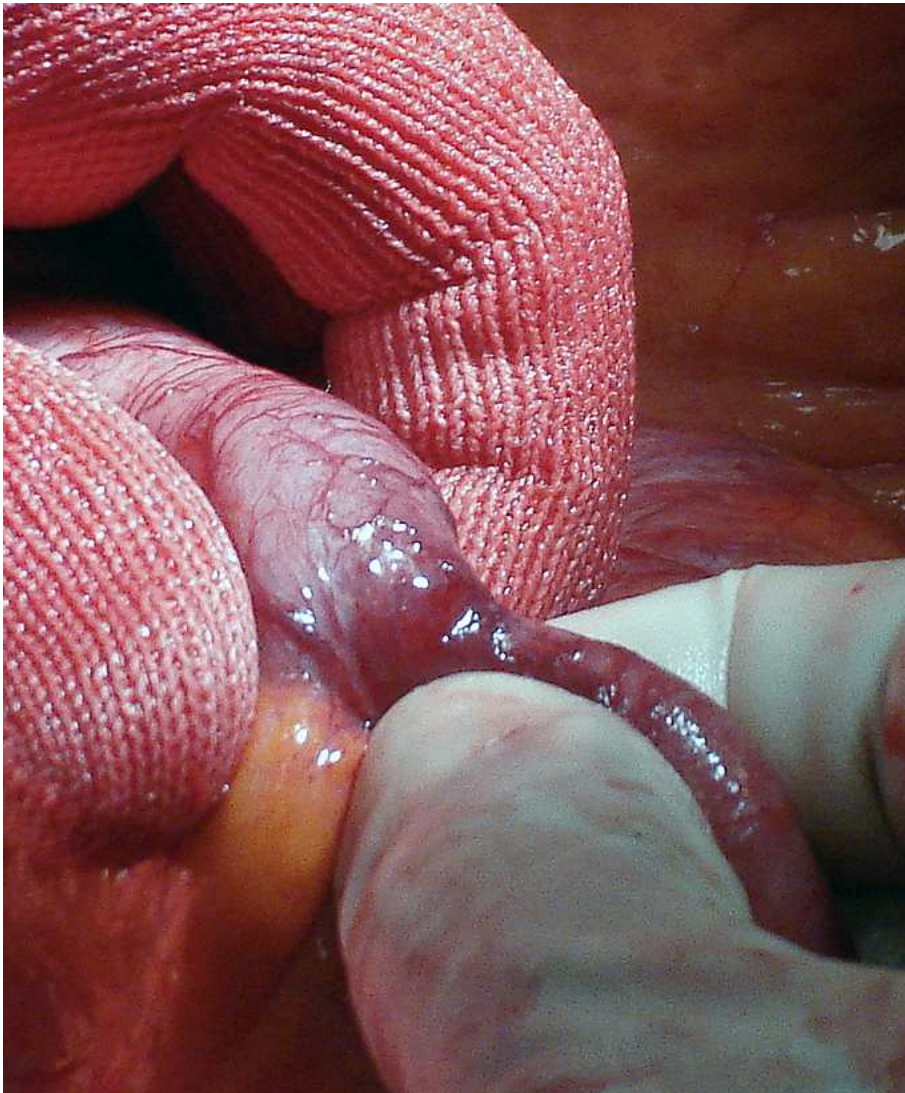
Isolamento dei nervi laringei inferiori (ricorrenti)



Lobo destro - Istmo - Lobo sinistro (v. ant.)

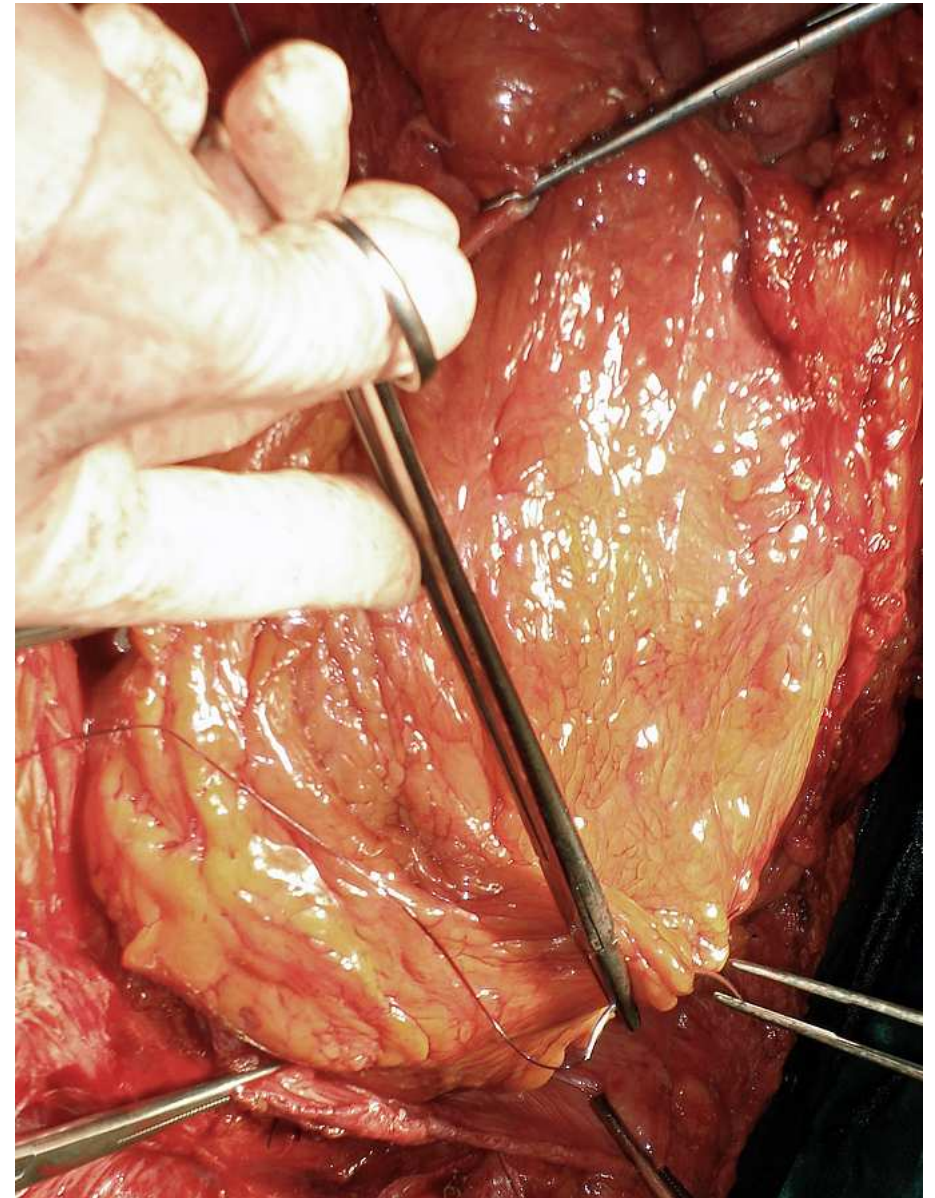


Lobo sinistro - Istmo - Lobo destro (superficie posteriore)

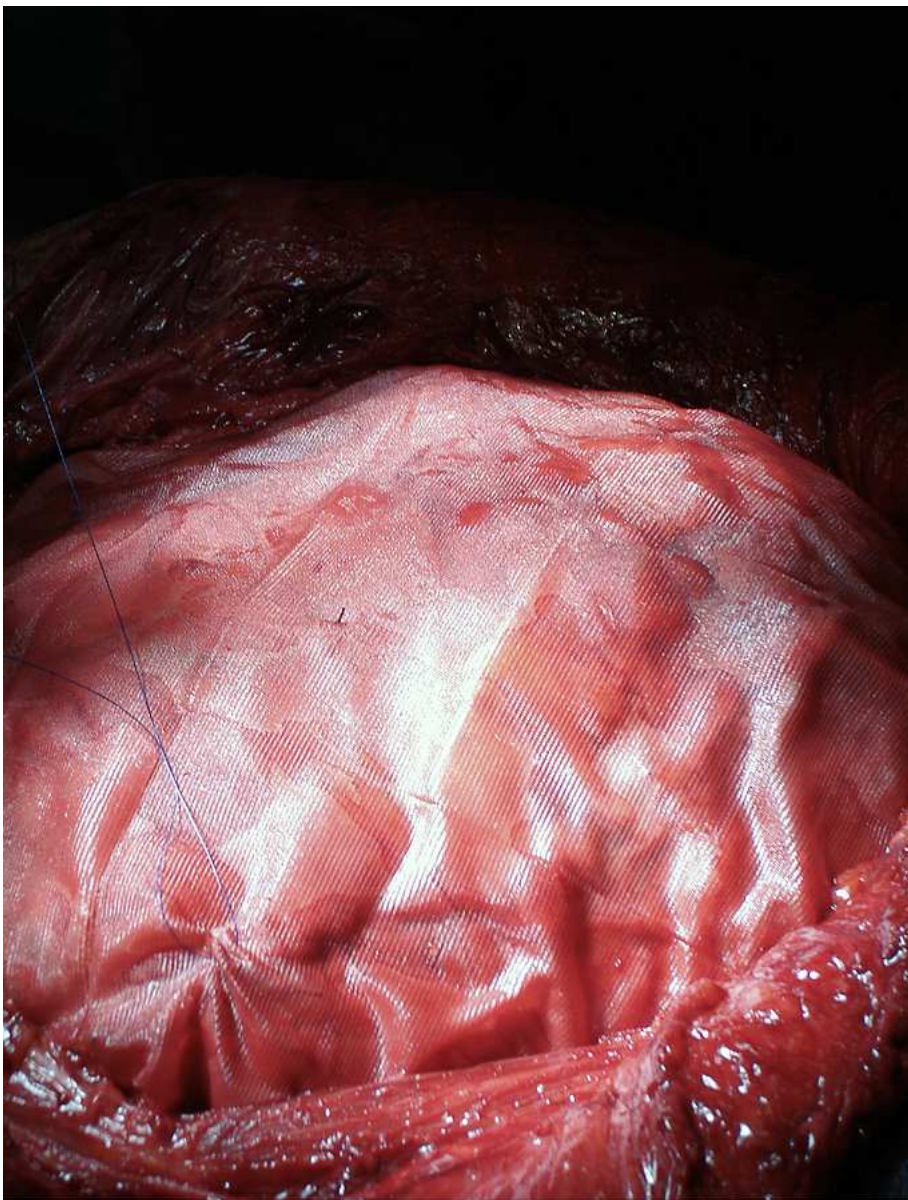


M.R. • Anni: 62 - F • Record: 5 • 03-11-2006

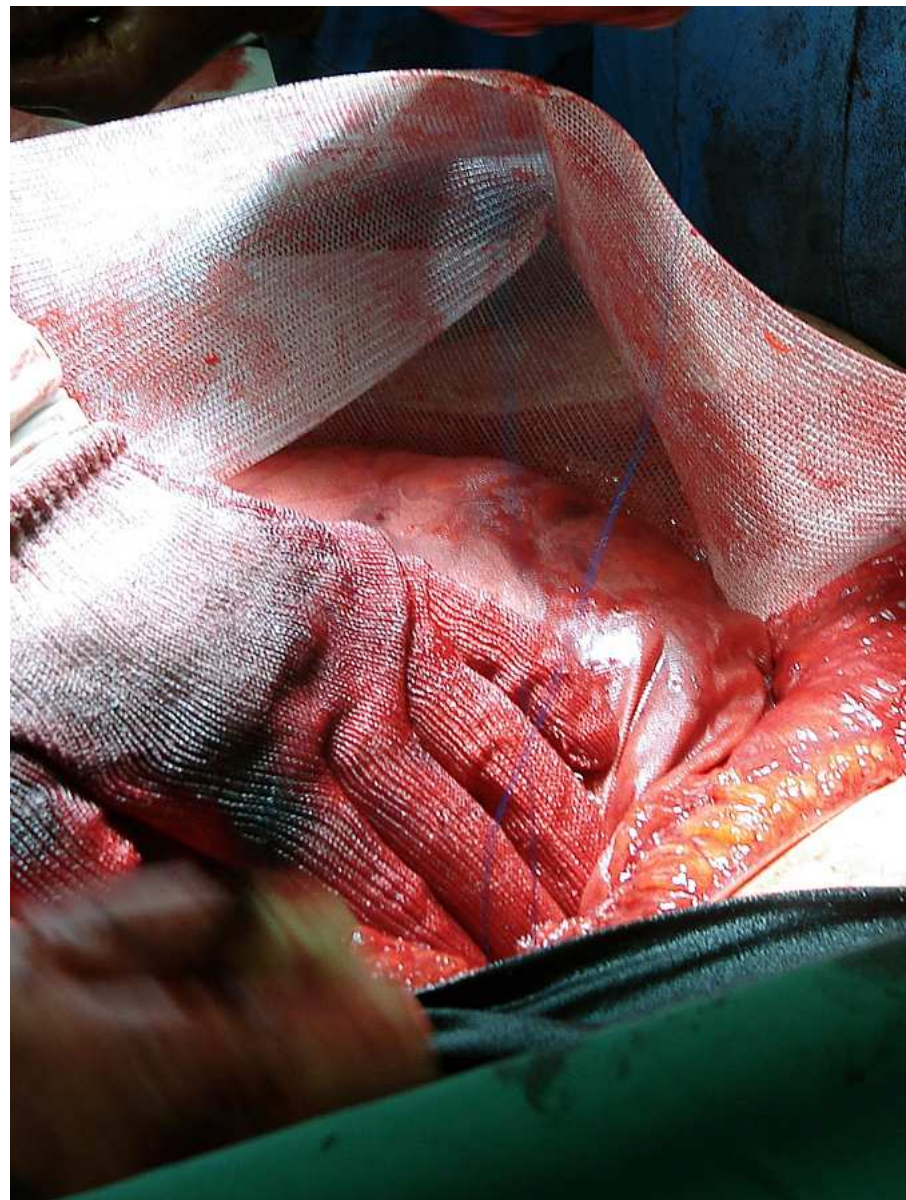Resezione ileale ed alloplastica mediana con sbarramento epiploico e posizionamento di doppia protesi (Vicryl e prolene) per laparocoele strozzato



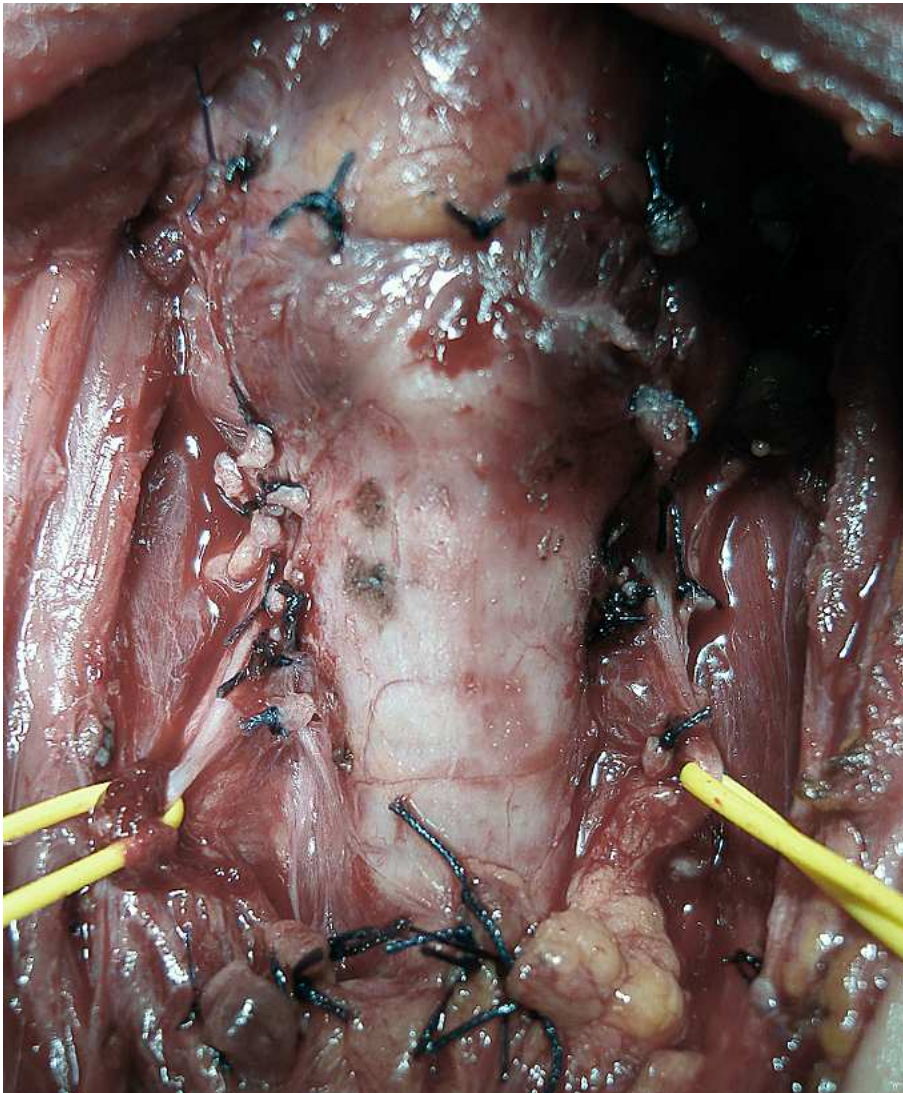
Sbarramento epiploico



Alloplastica con rete di Vicryl

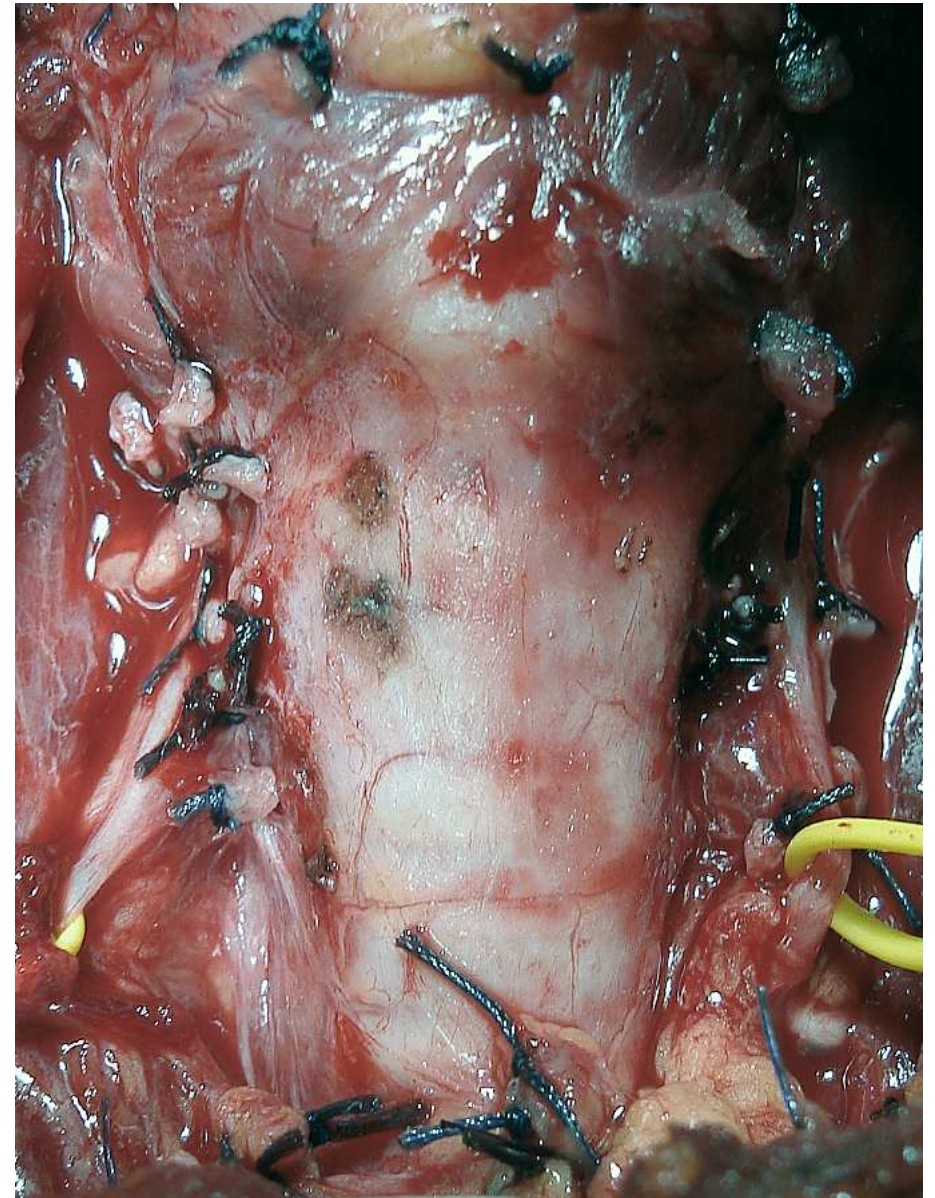


Alloplastica con rete di Prolene



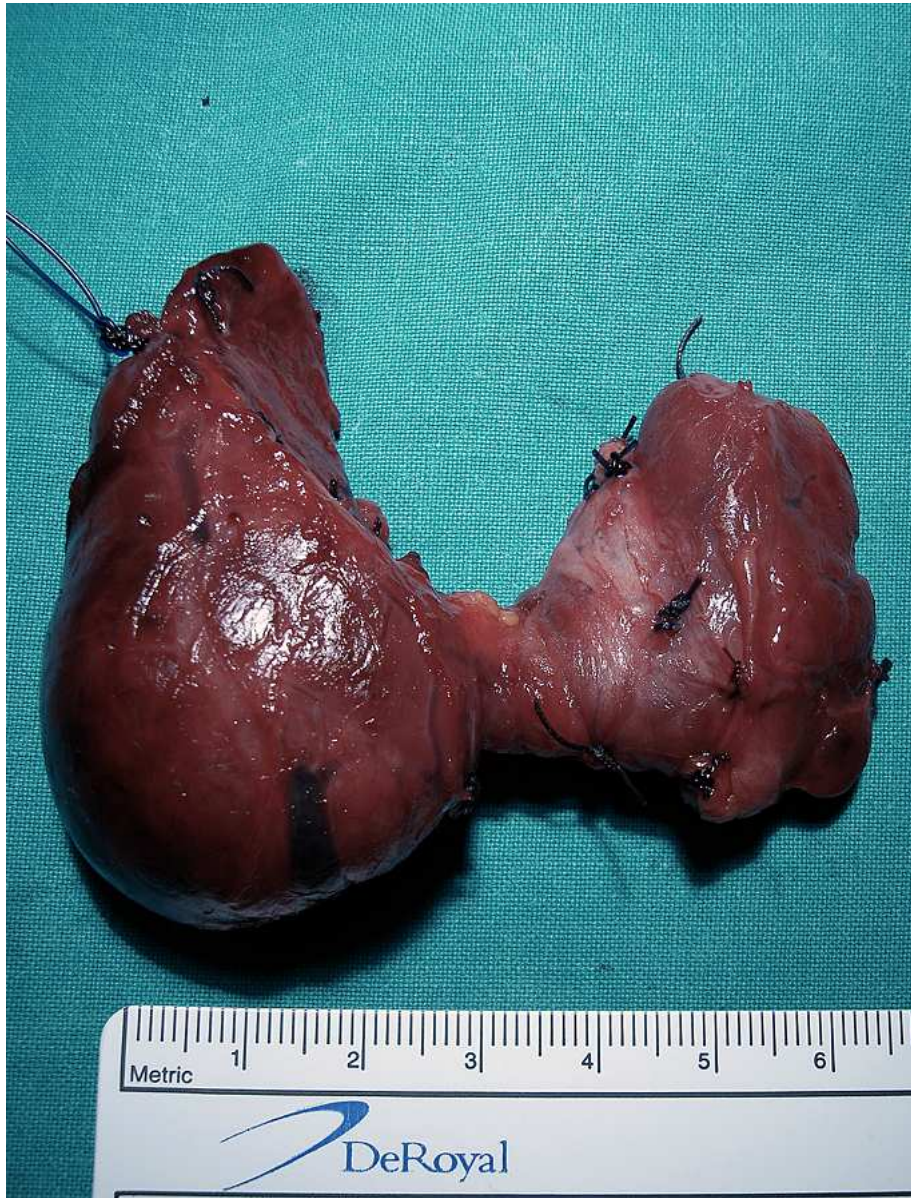O.A.M. • Anni: 53 - F • Record: 6 • 06-11-2006

Tiroidectomia totale extracapsulare per lesione follicolare ad incerto potenziale di malignita' (FI-ump) del lobo dx con sezione dei muscoli pretiroidei

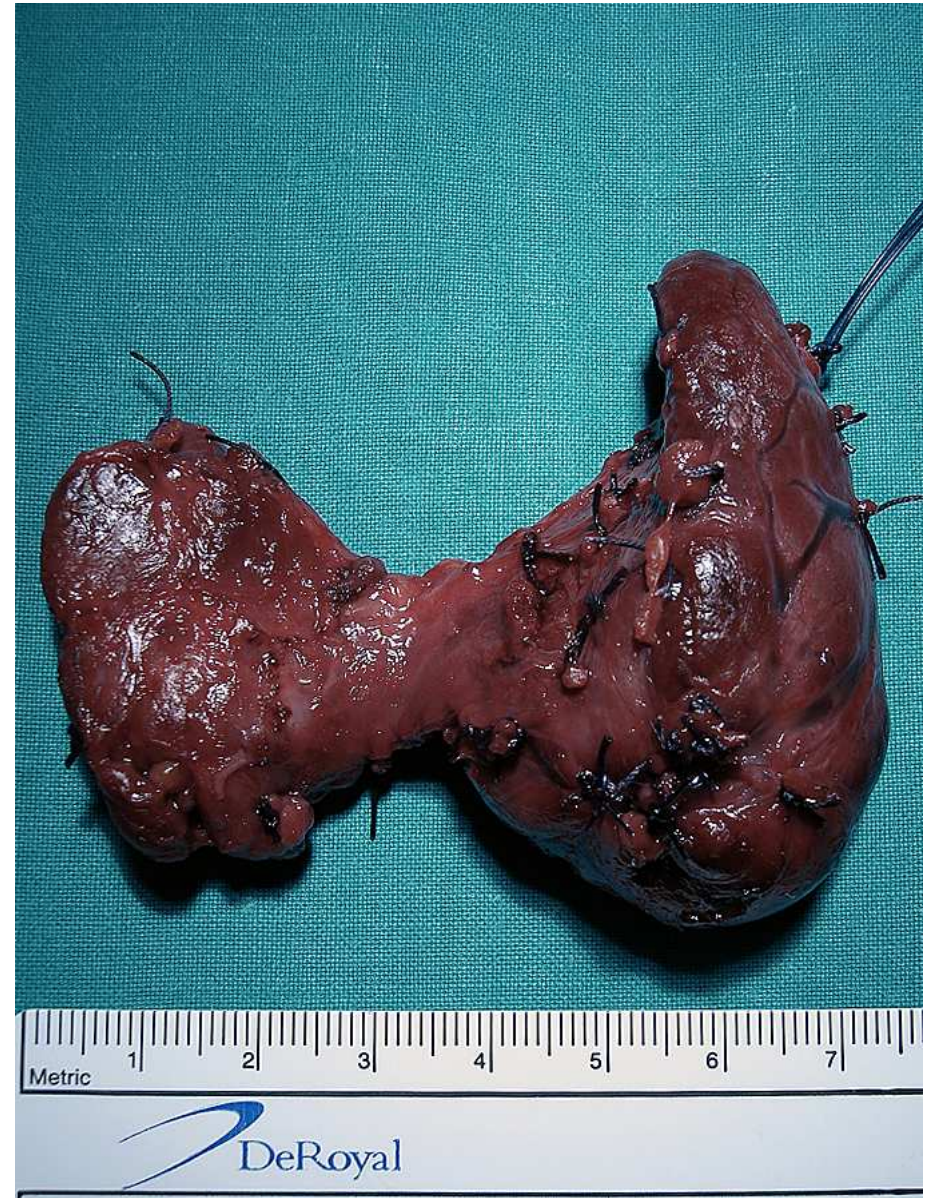


Isolamento dei nervi laringei inferiori (ricorrenti)

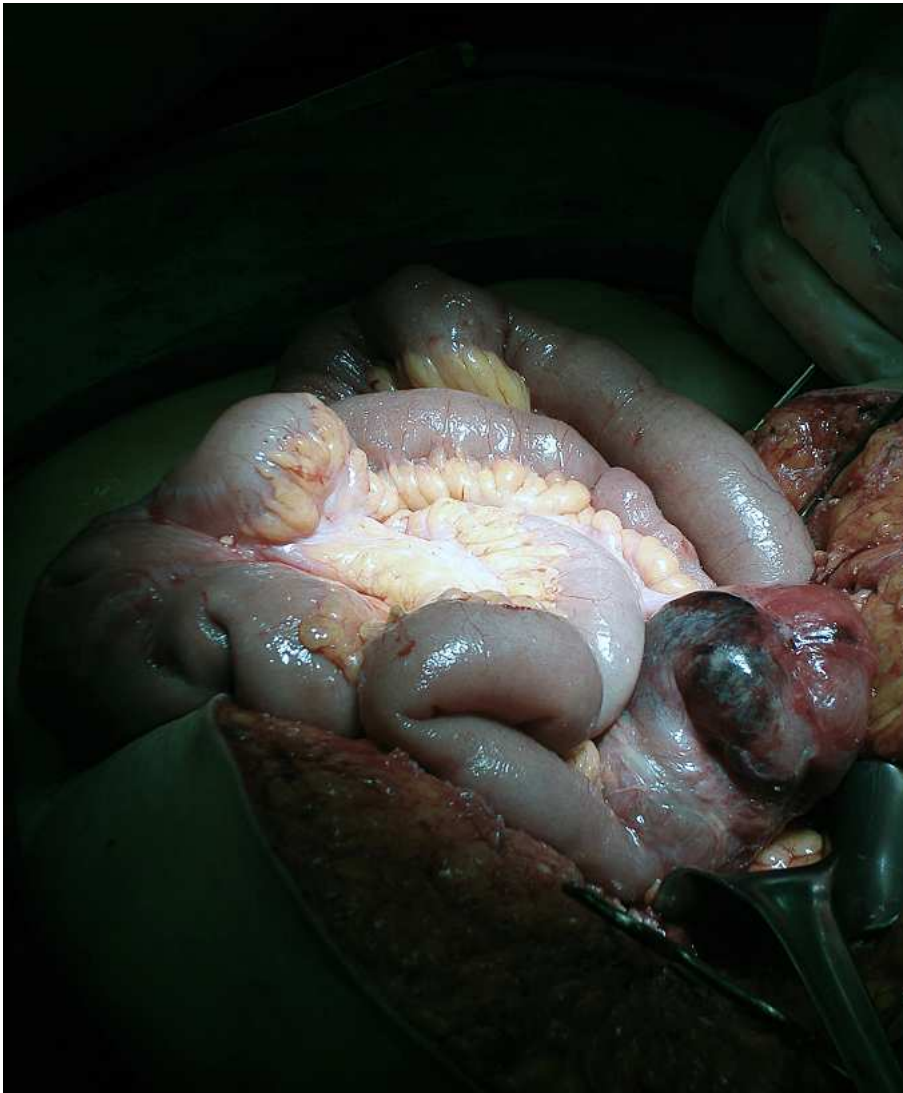



Lobo destro - Istmo - Lobo sinistro (v. ant.)

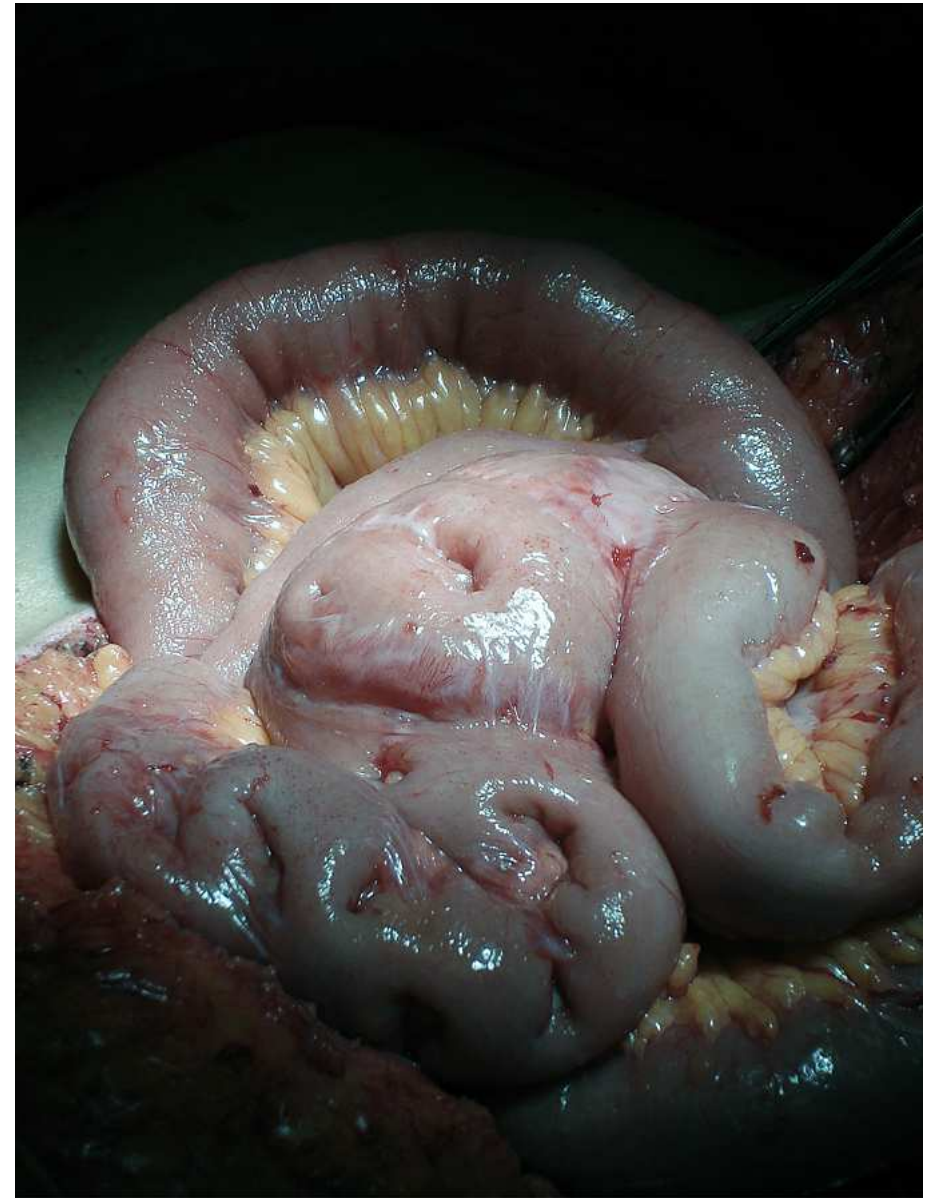

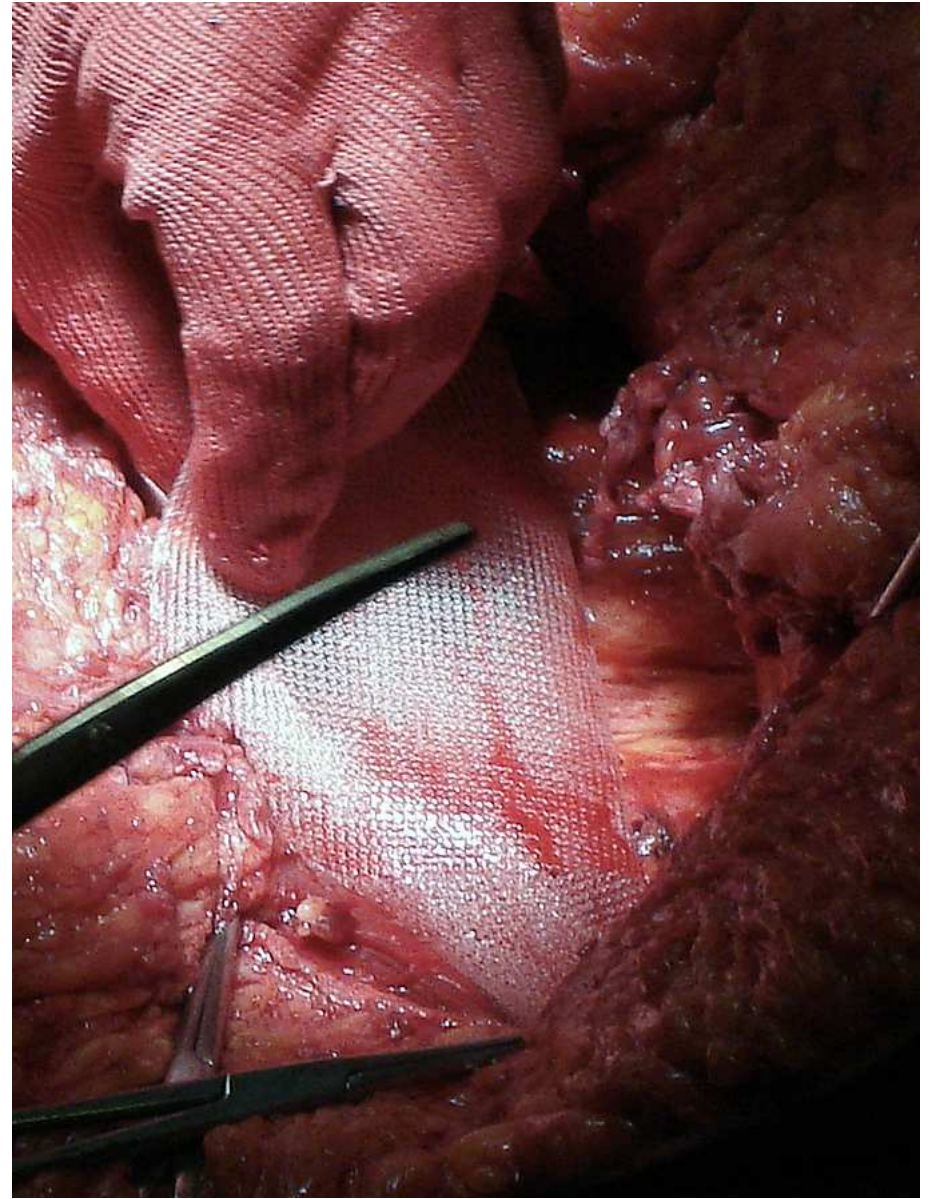
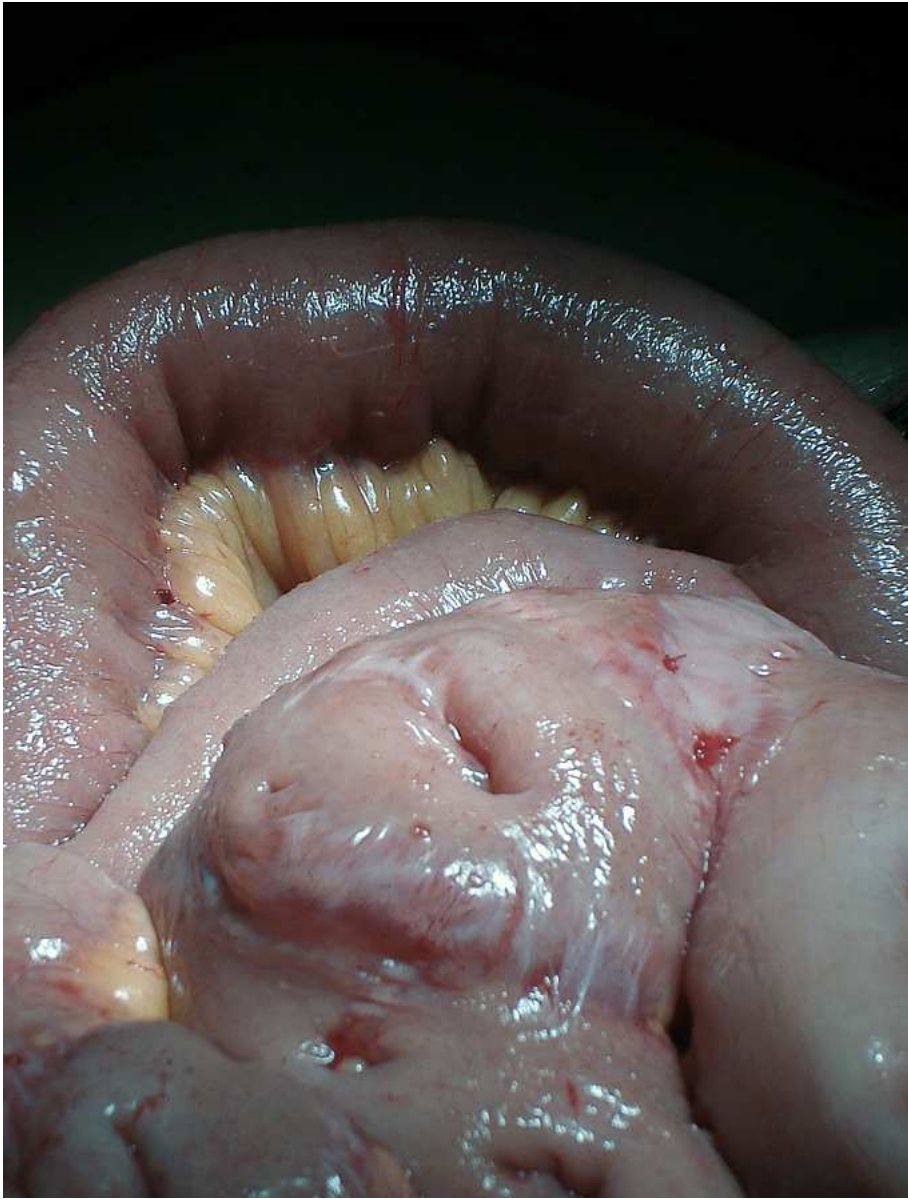
Lobo sinistro - Istmo - Lobo destro (superficie posteriore)

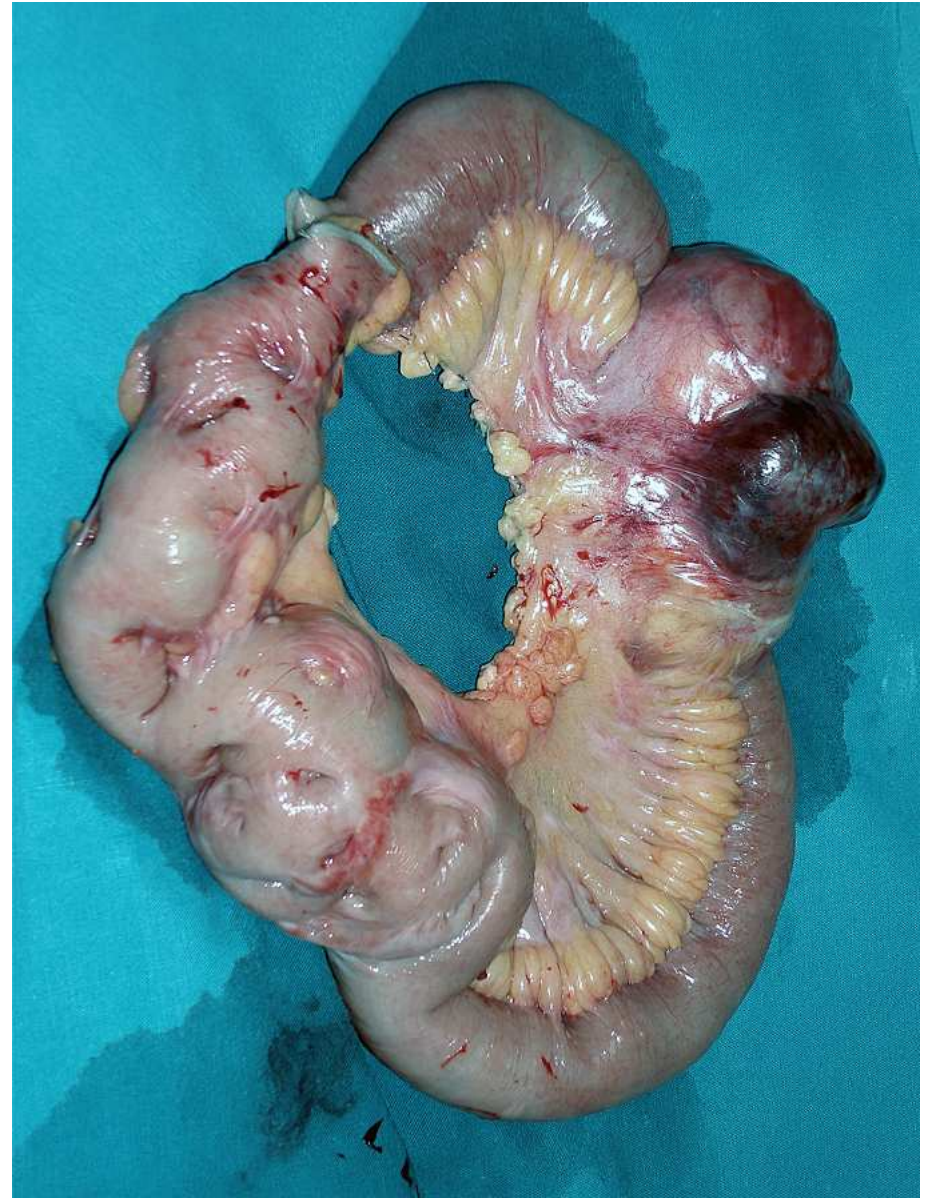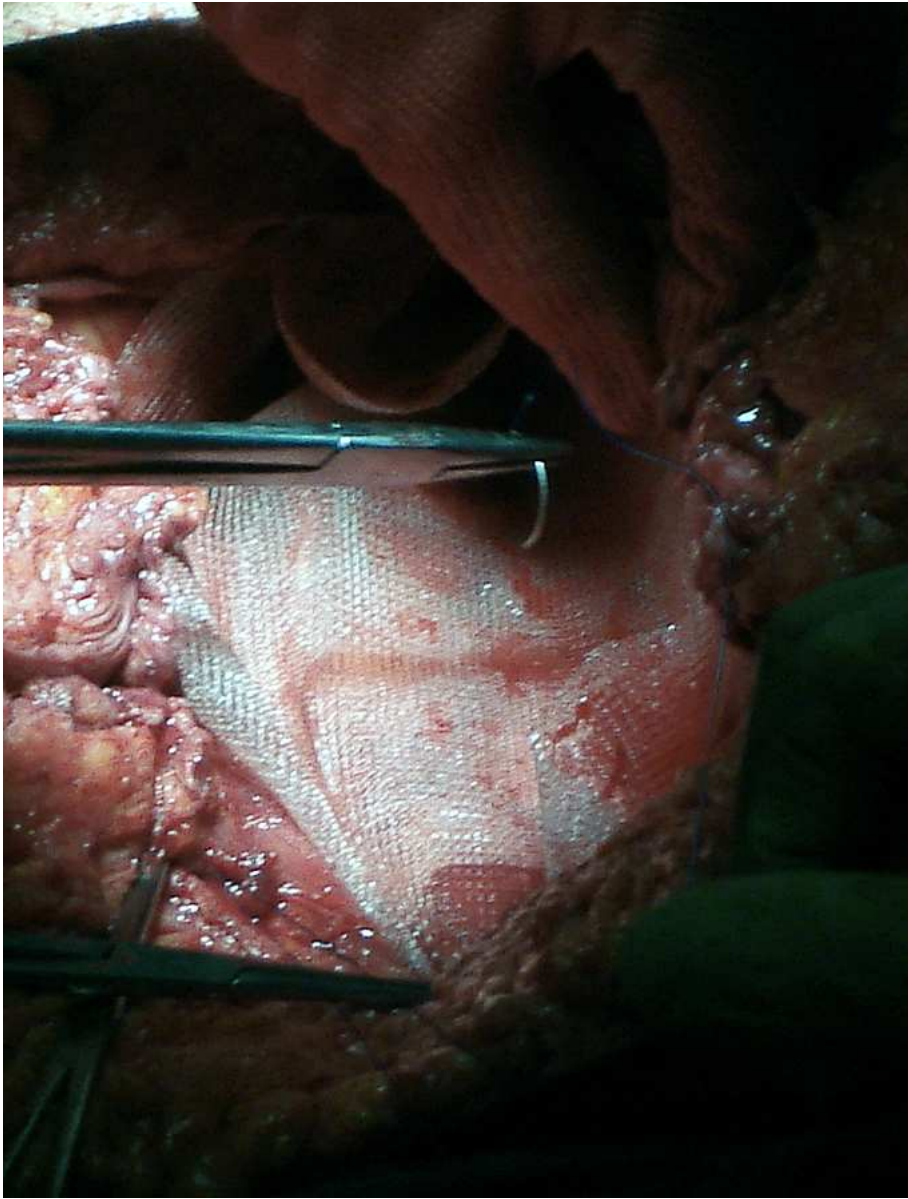


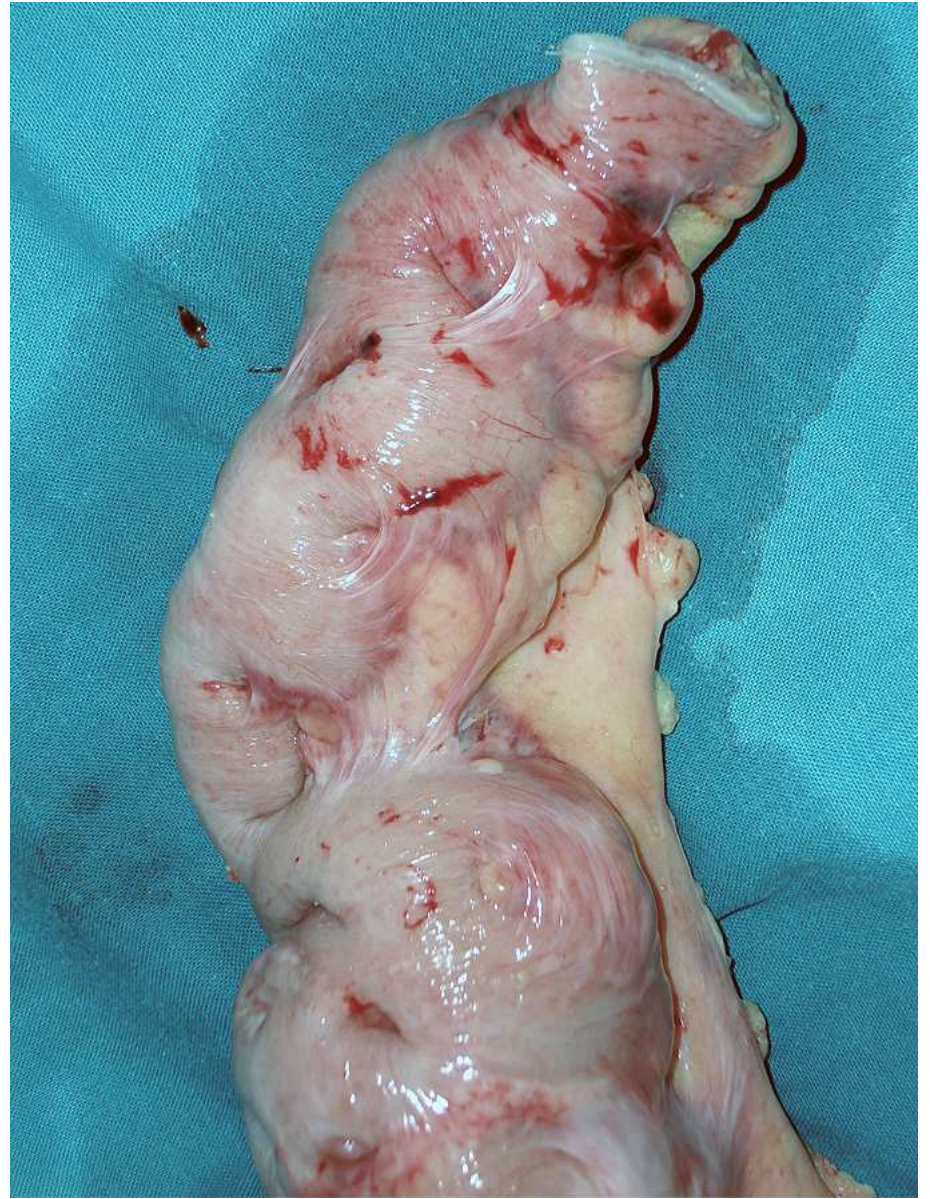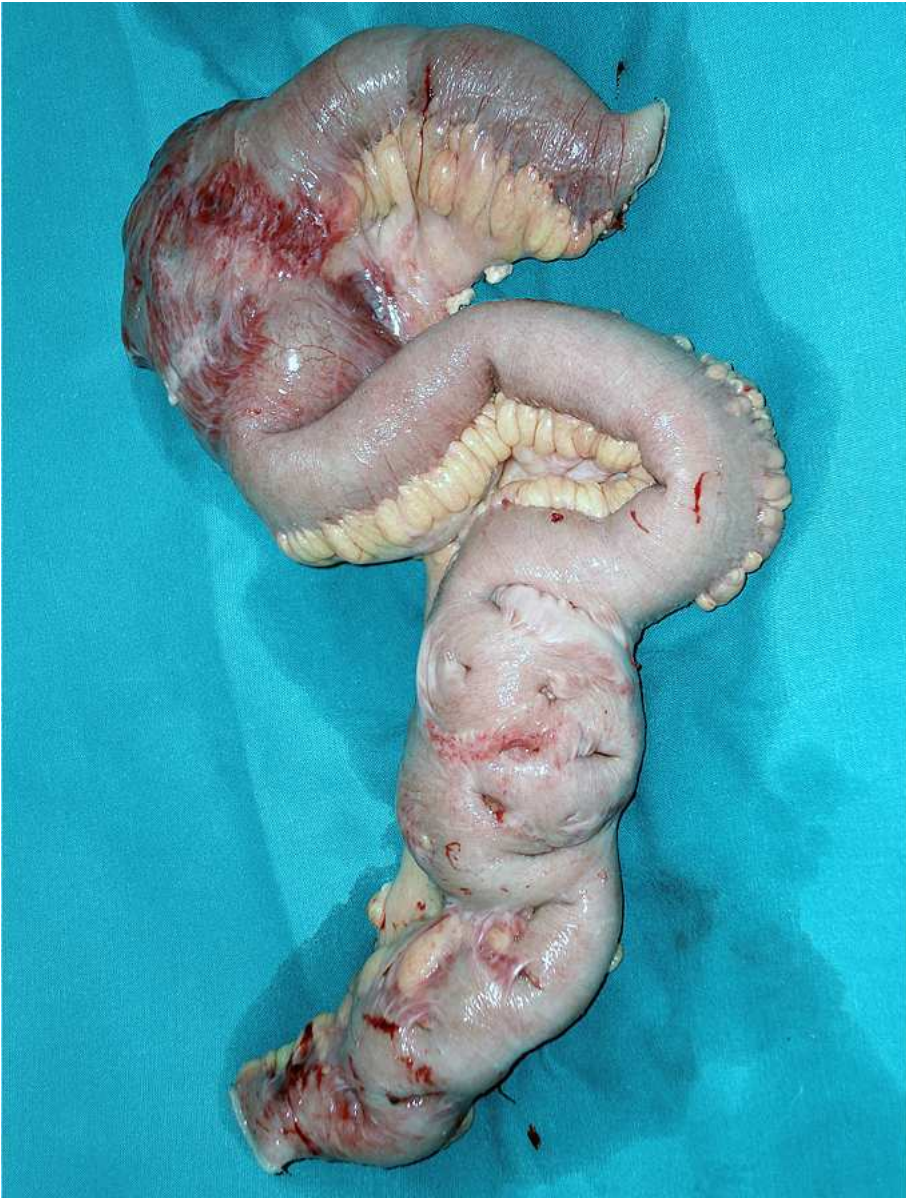J.V. • Anni: 51 - F • Record: 7 • 17-11-2006

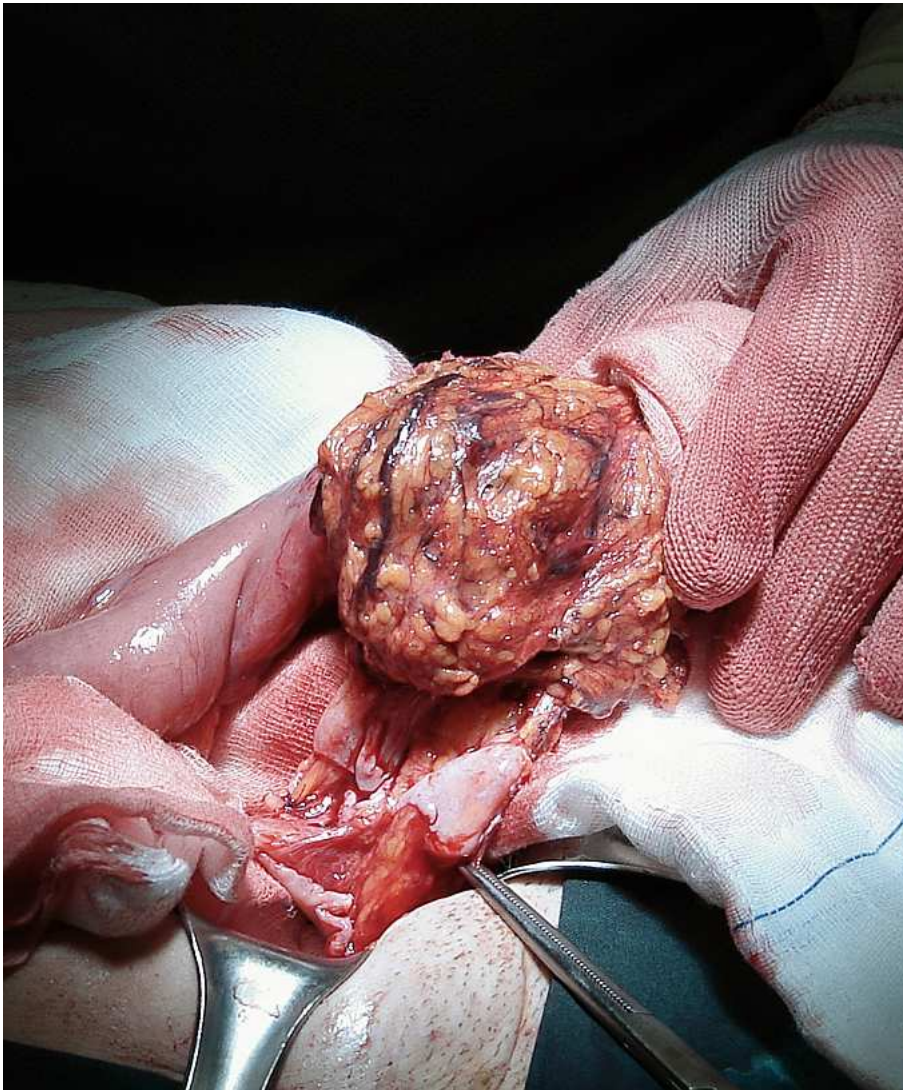Resezione ileale ed epiploica con alloplastica sec. Rives per laparocèle mediano recidivo strozzato





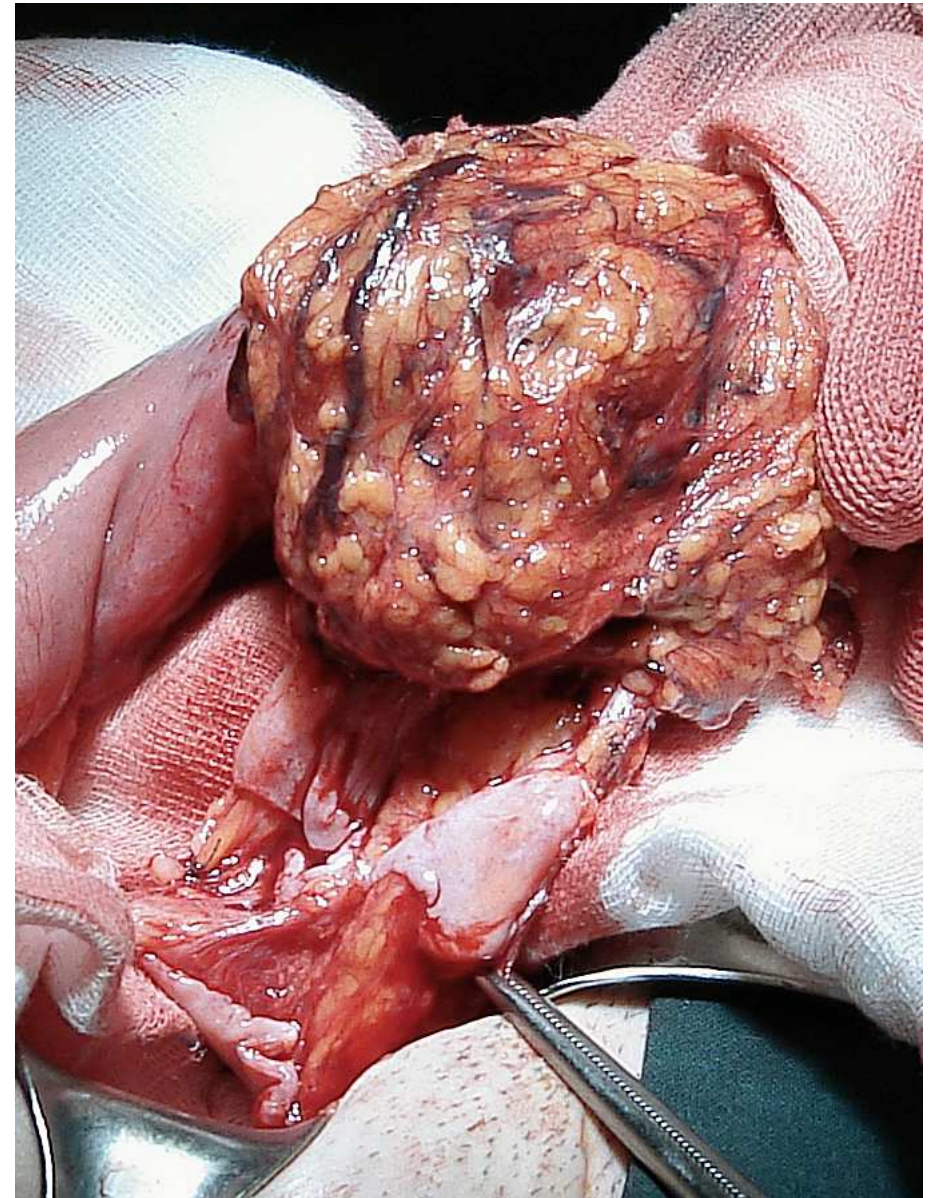


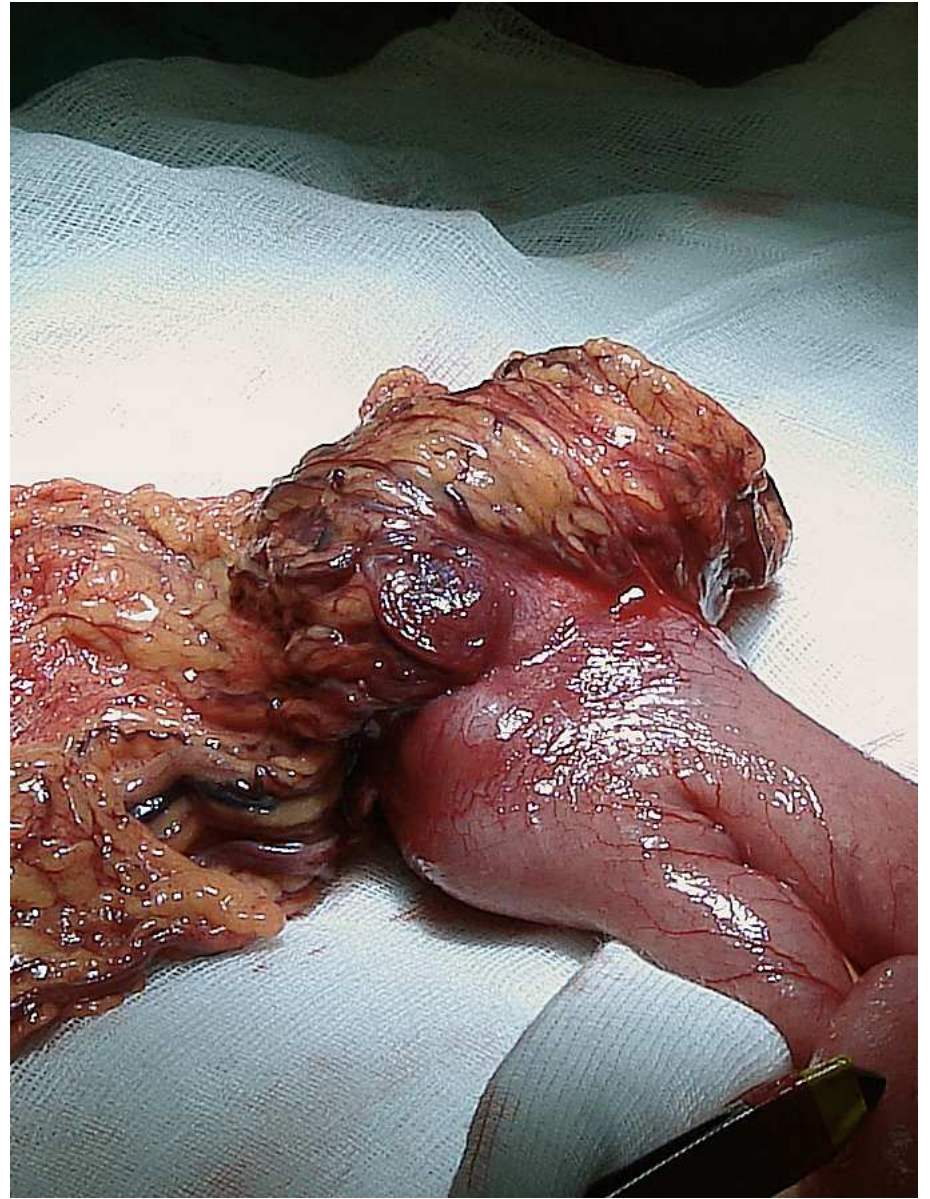
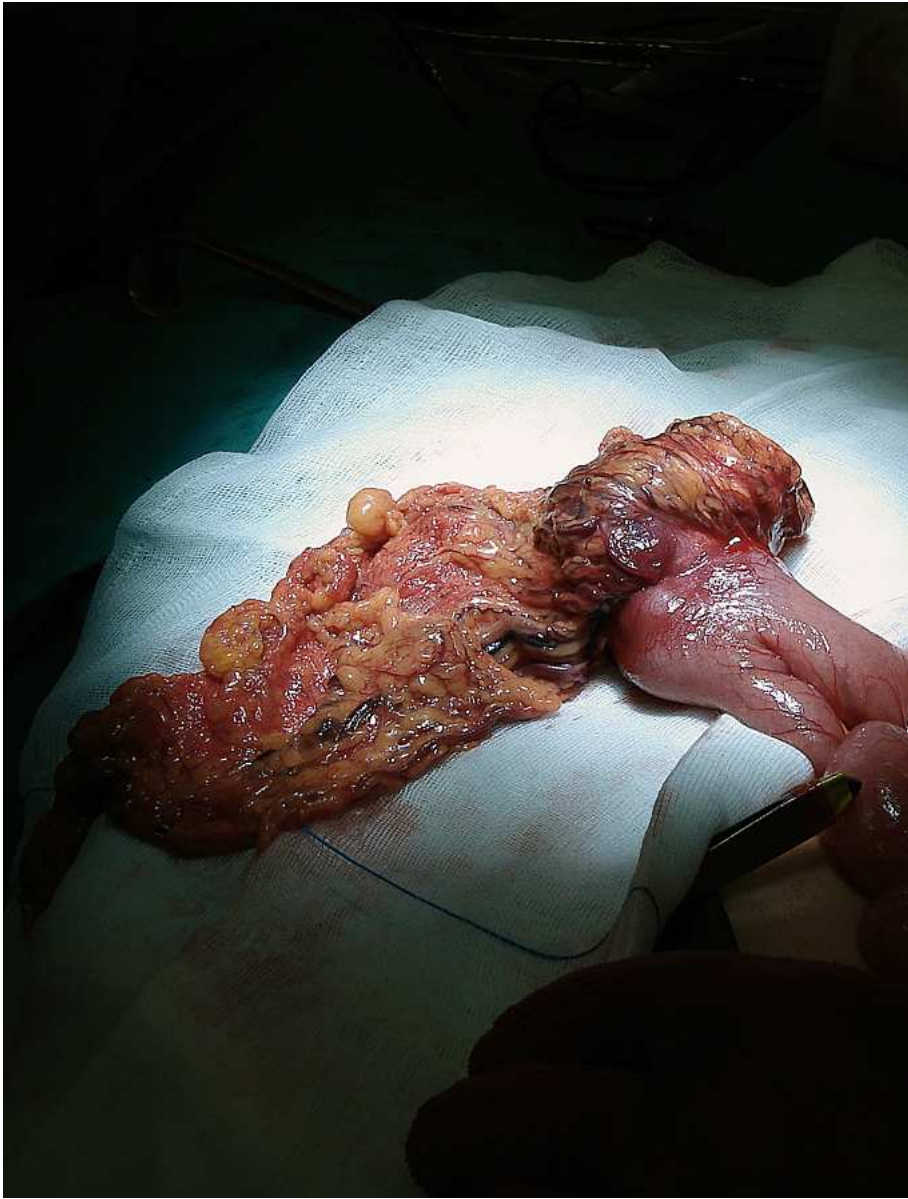

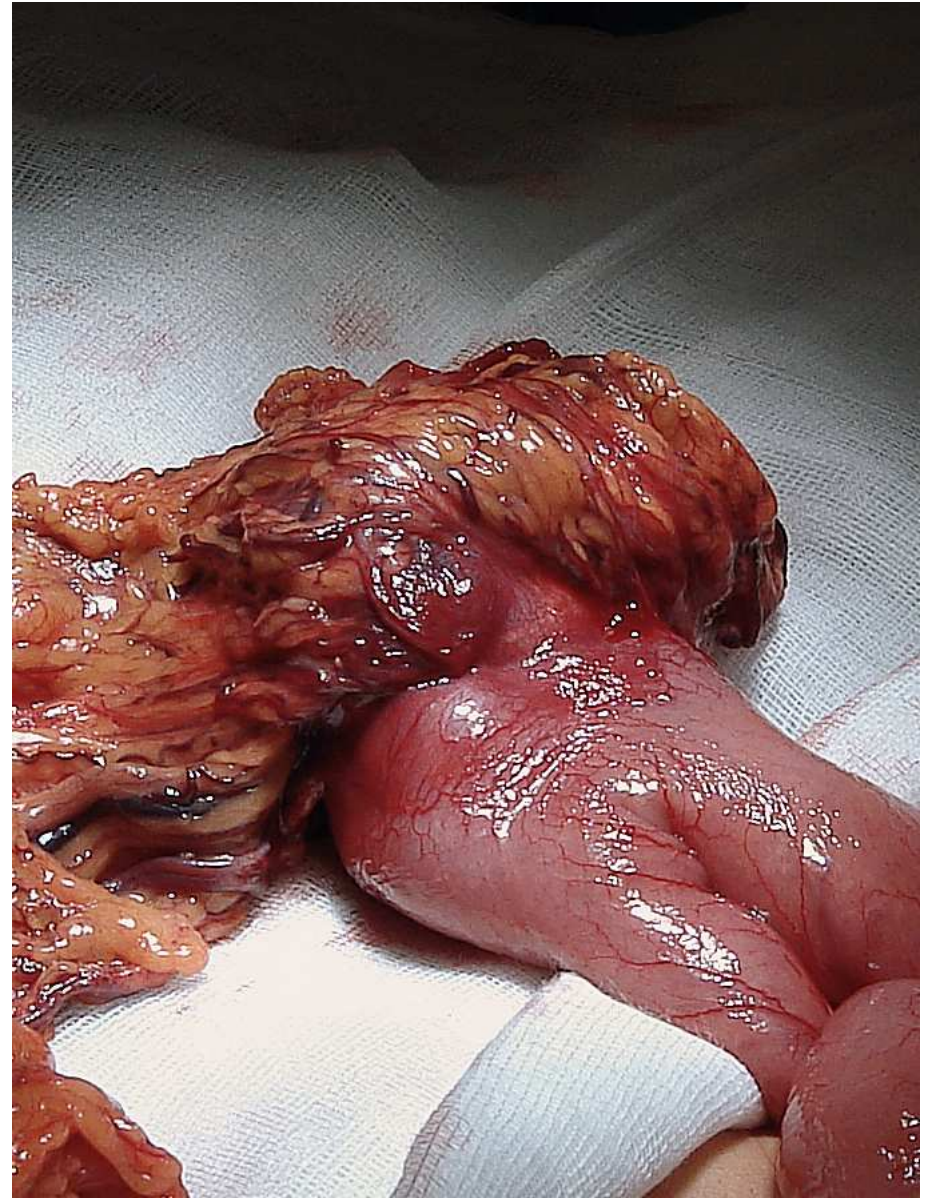
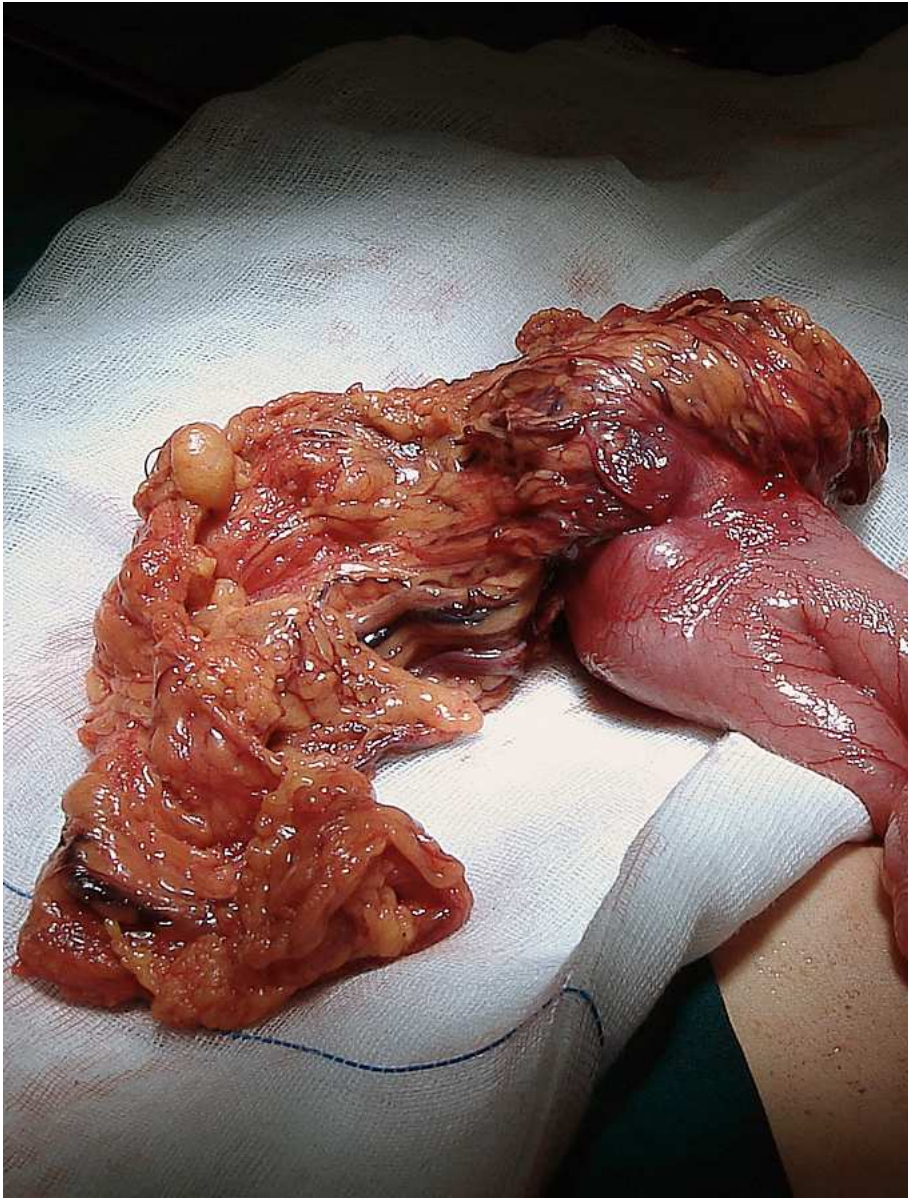


C.M. • Anni: 29 - F • Record: 8 • 14-12-2006

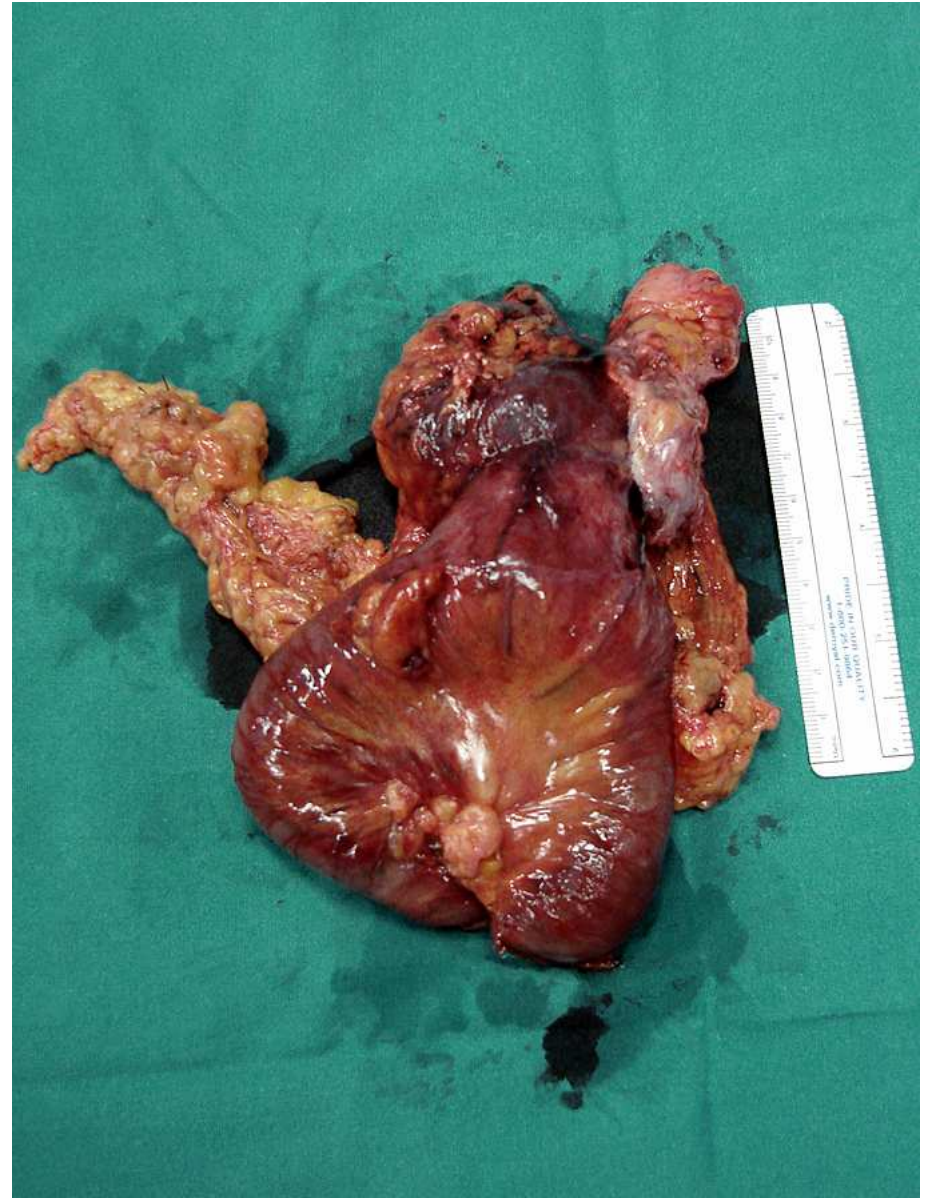
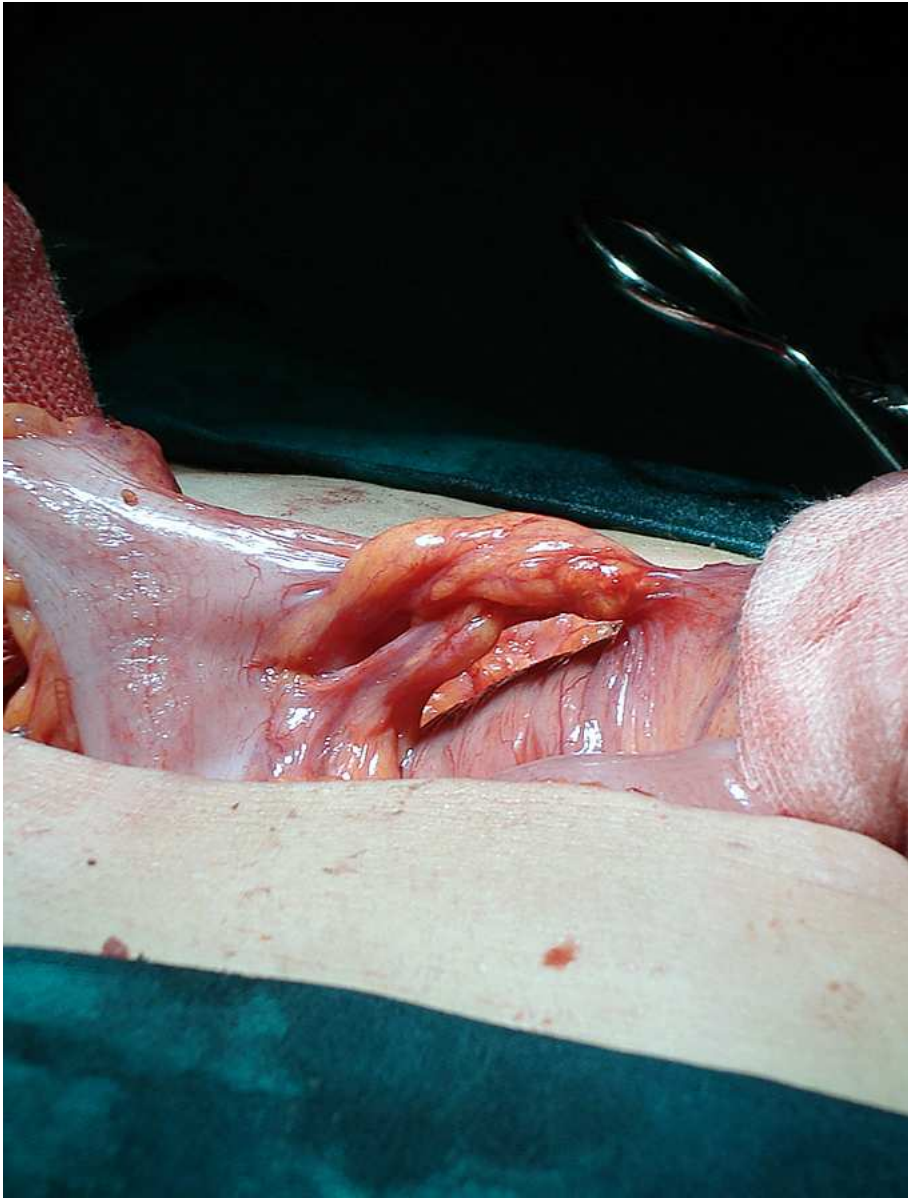
Resezione di massa neoplastiforme costituita da GIST digiuno-ileale, epiploon, peritoneo parietale anteriore e di quello della cupola vescicale. Appendicectomia

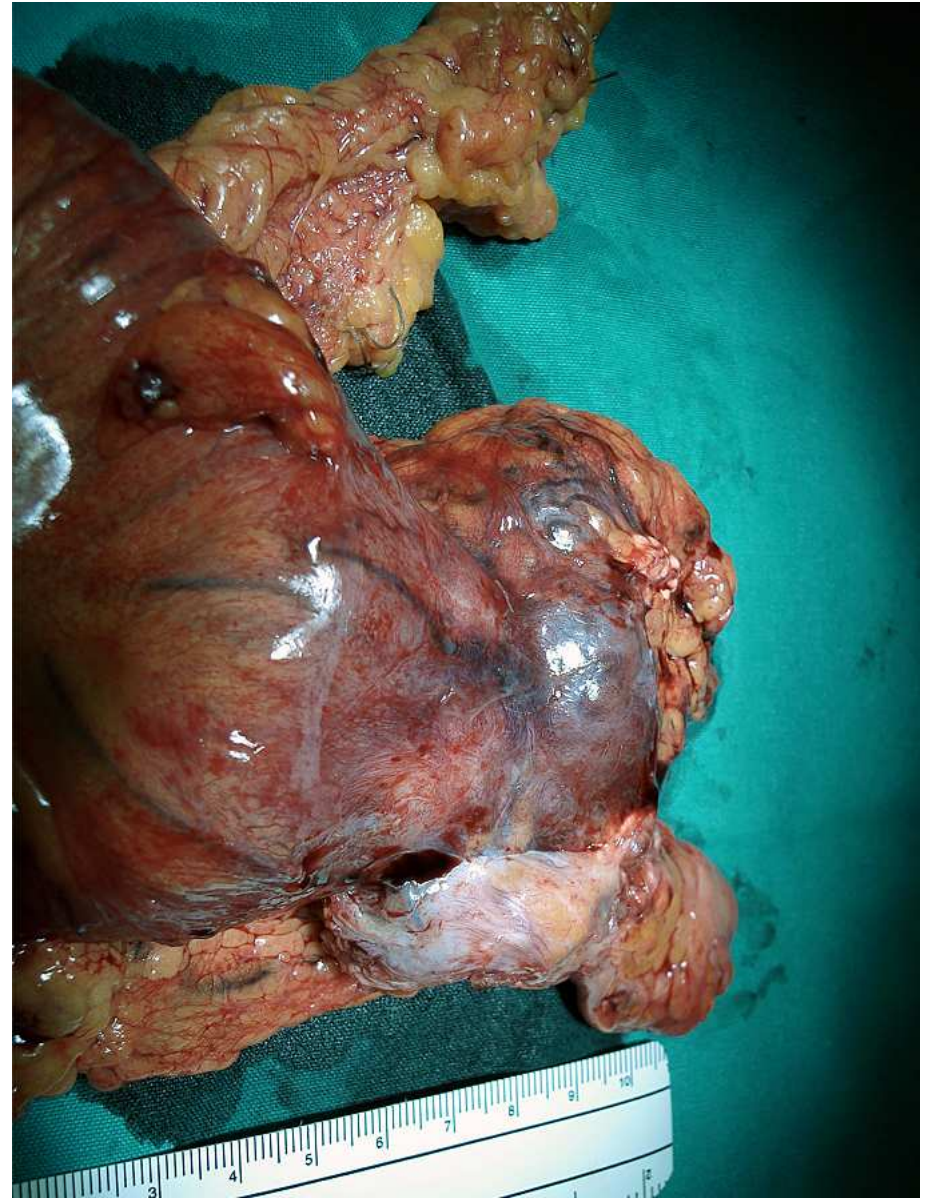
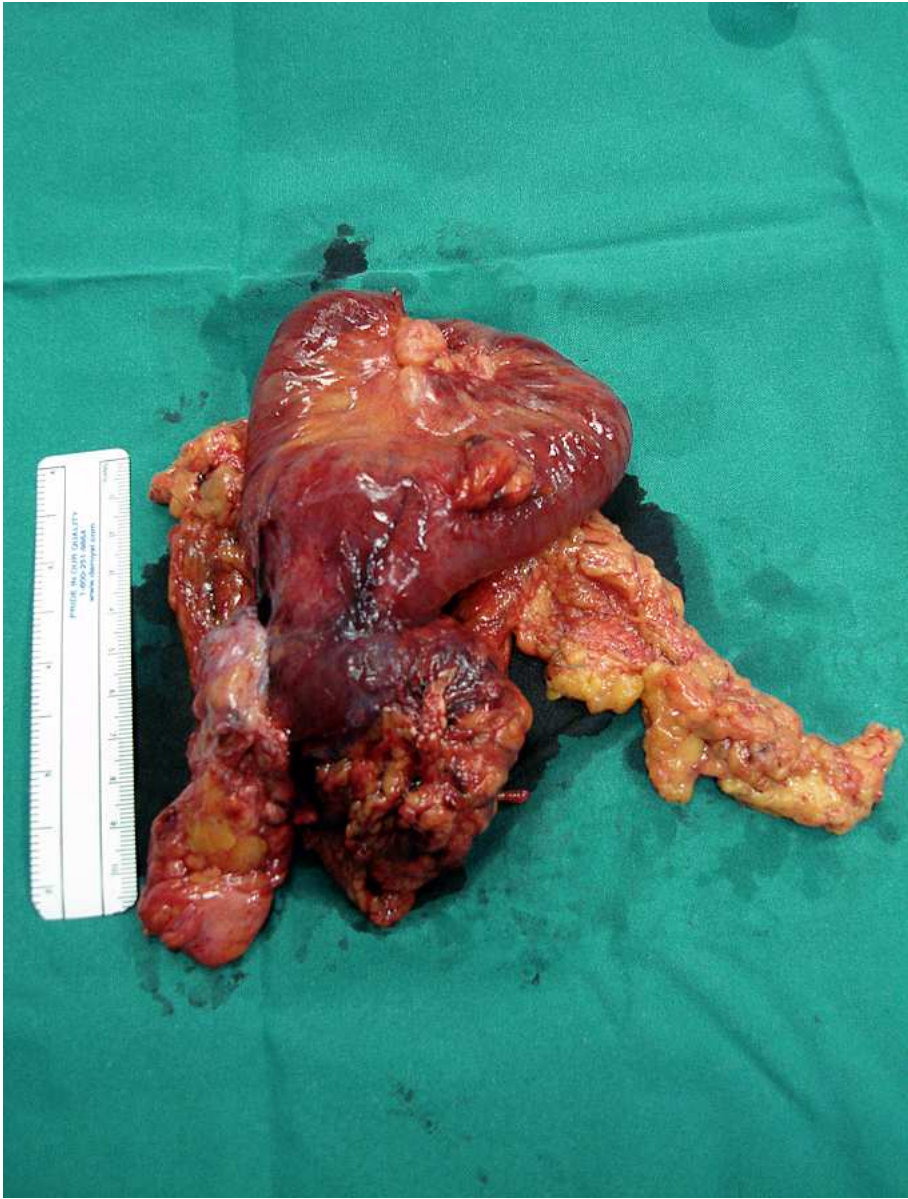


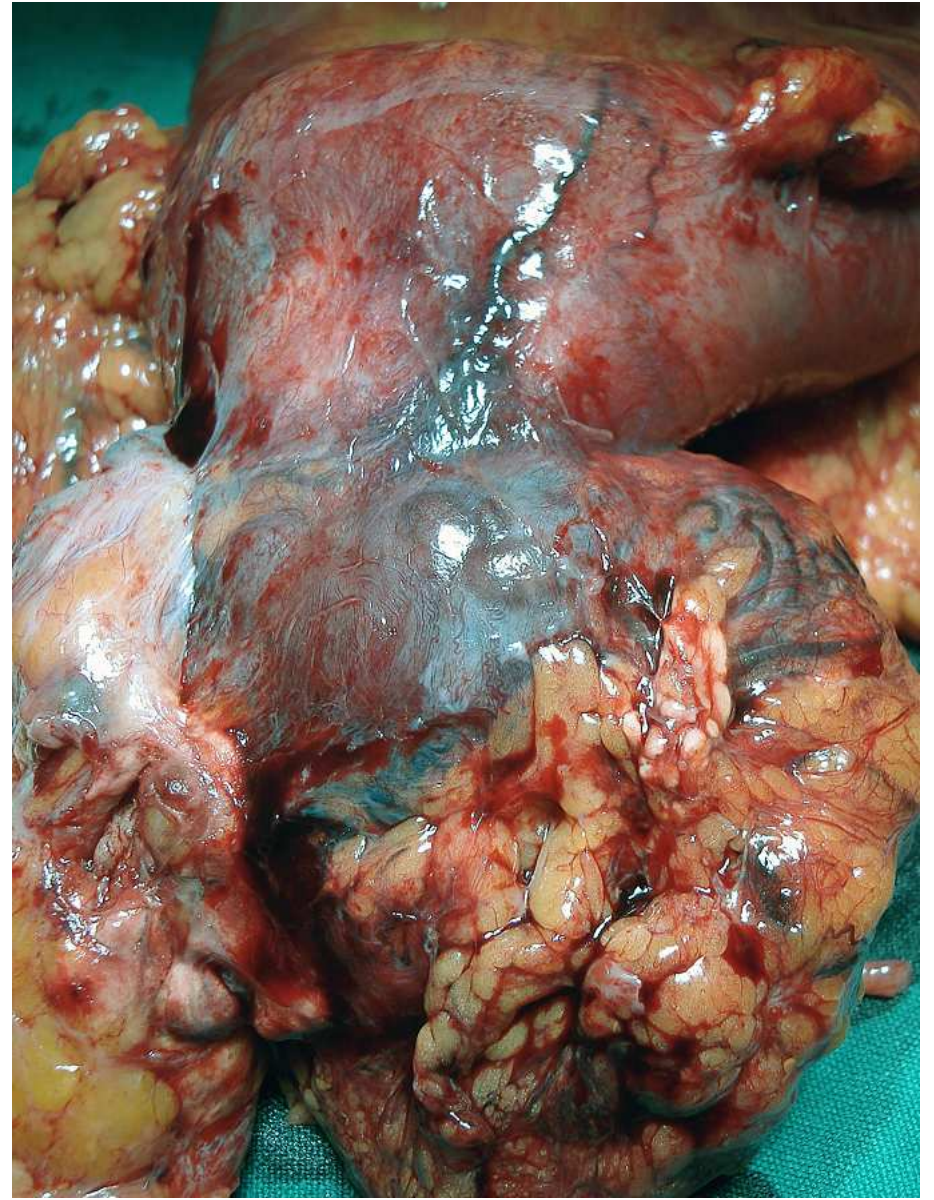
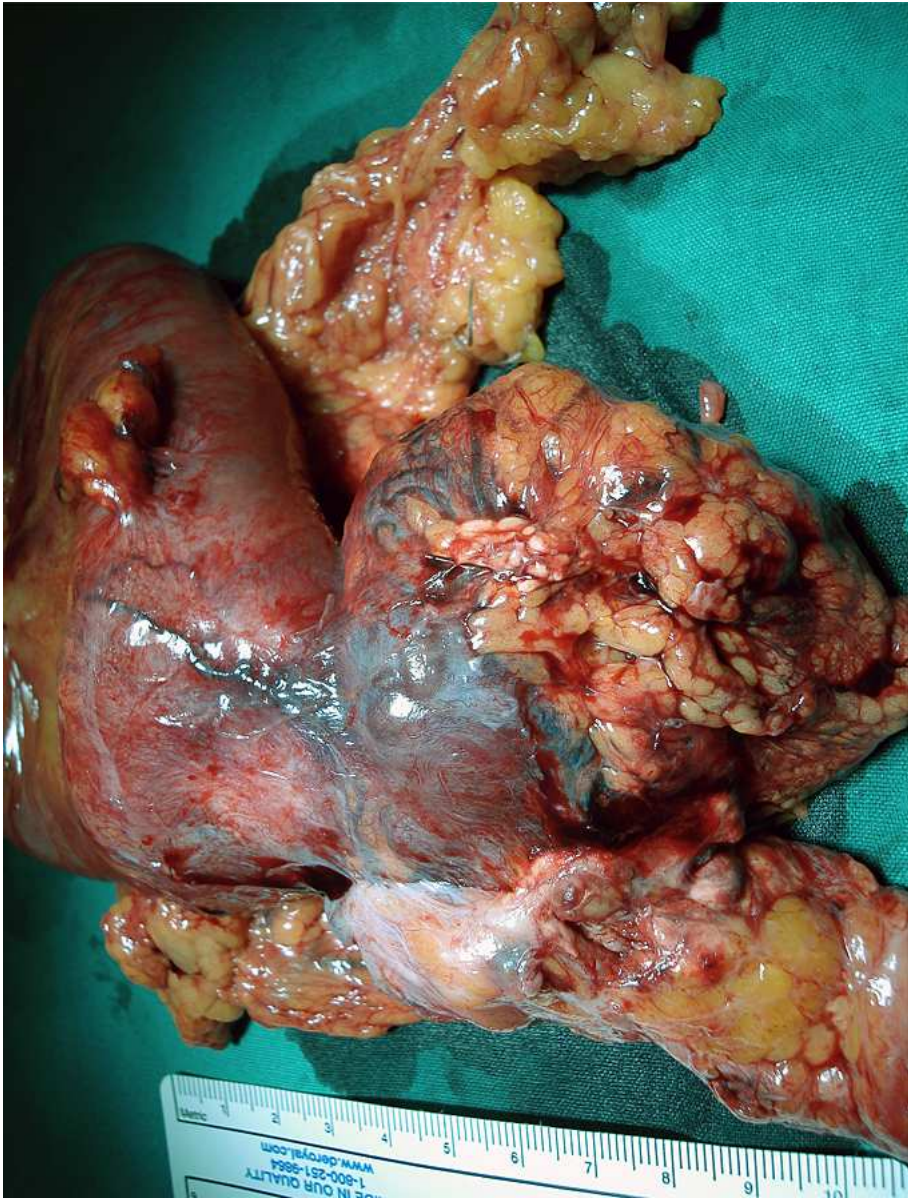


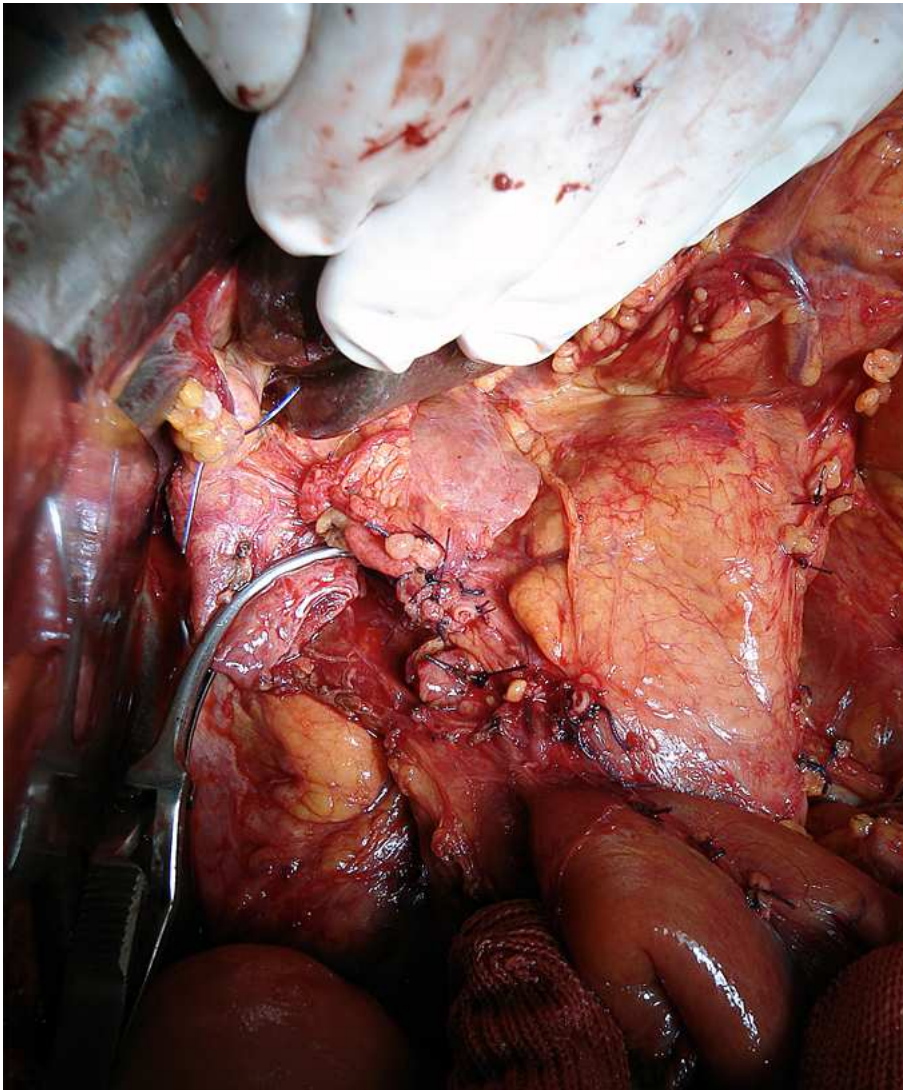






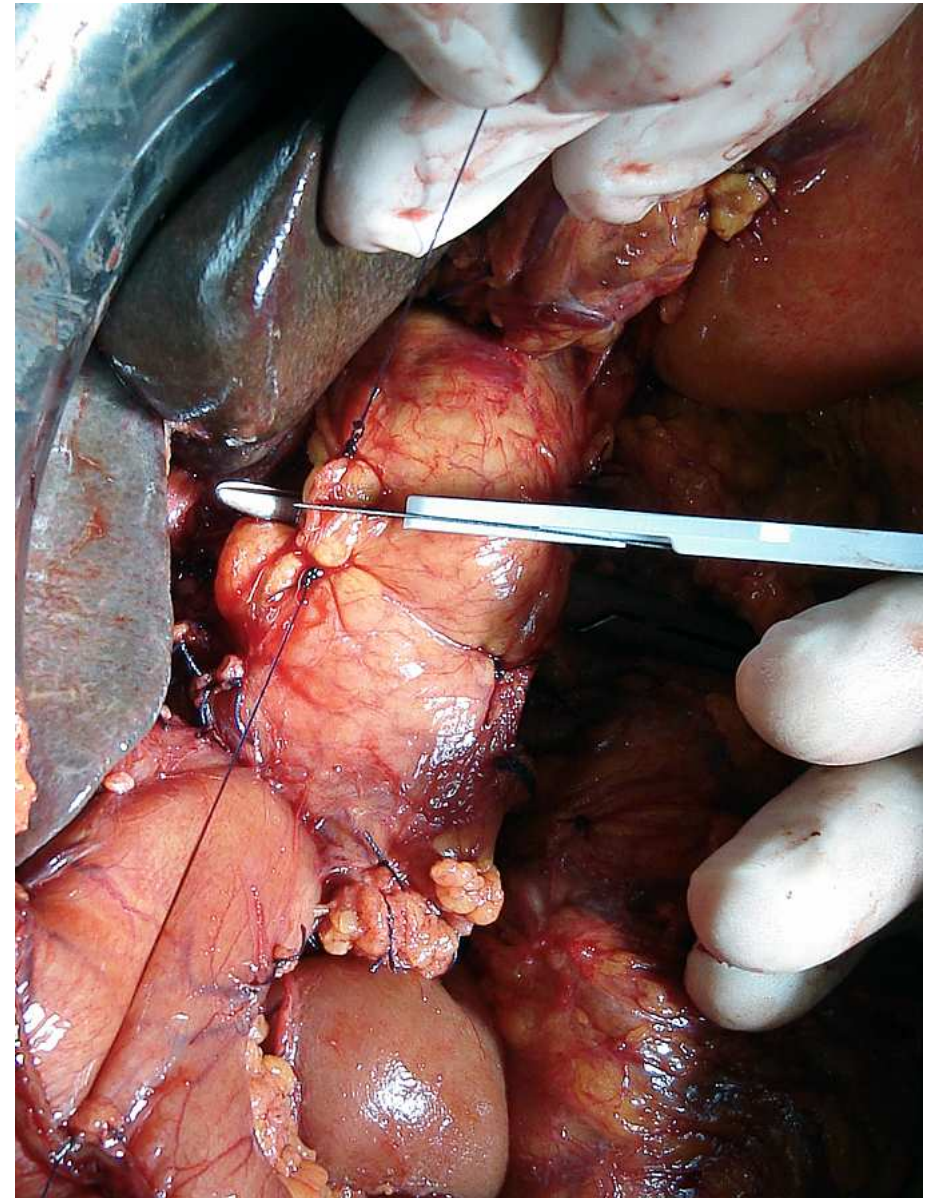


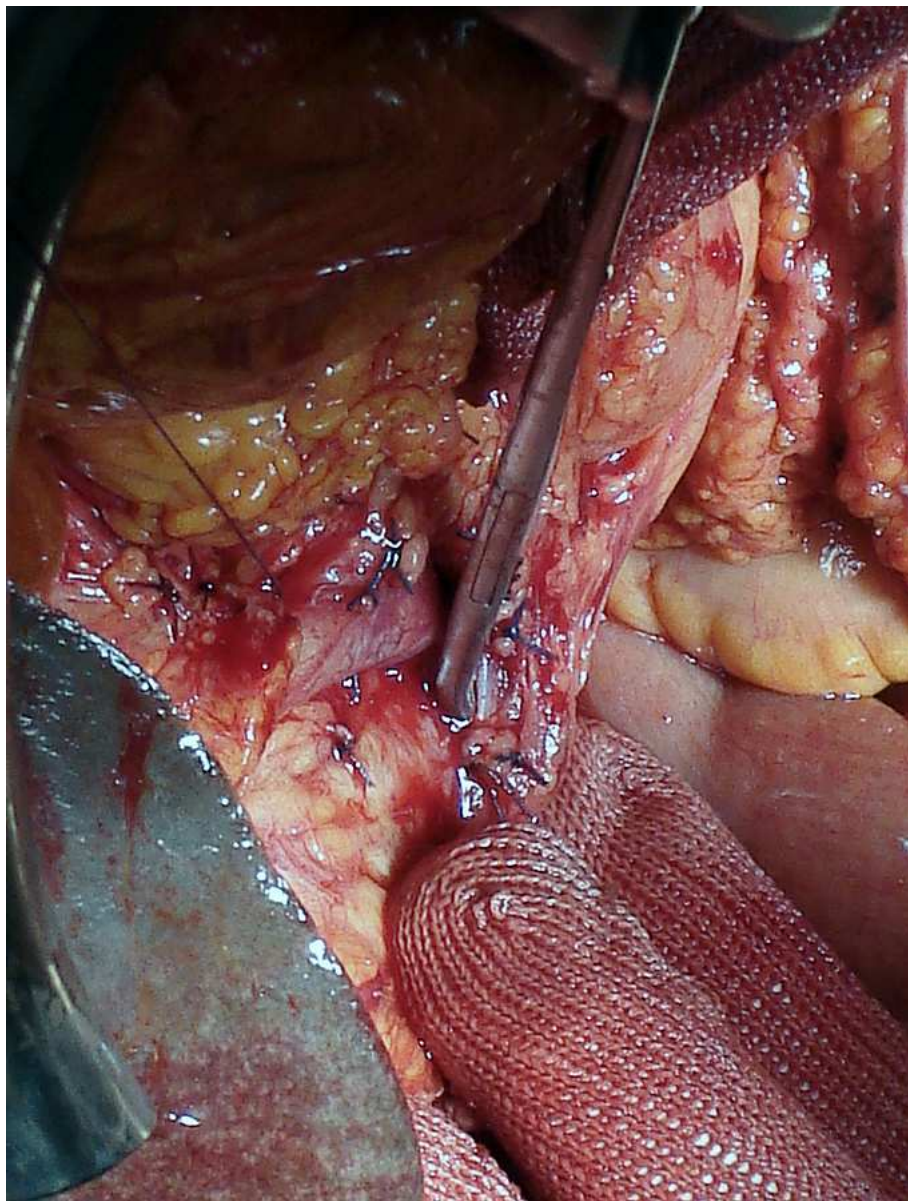
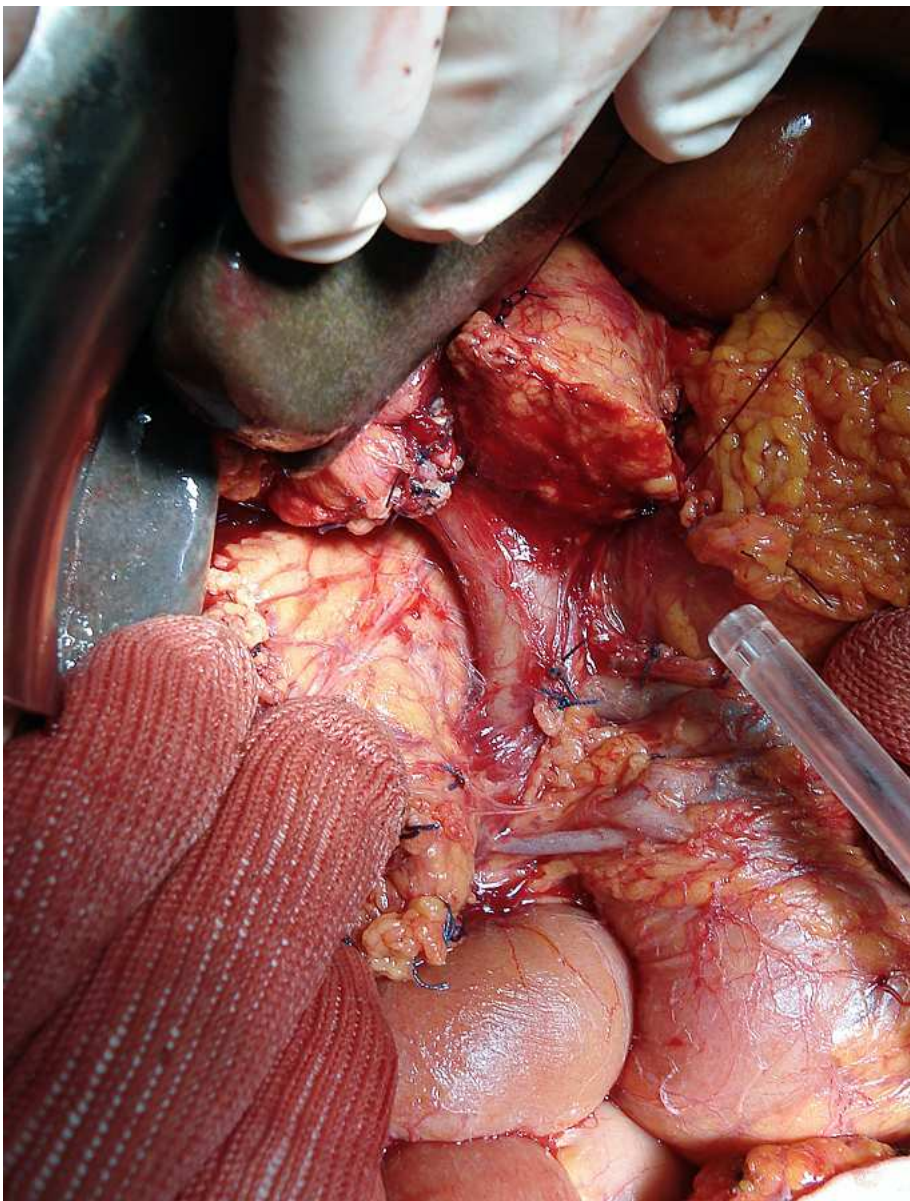


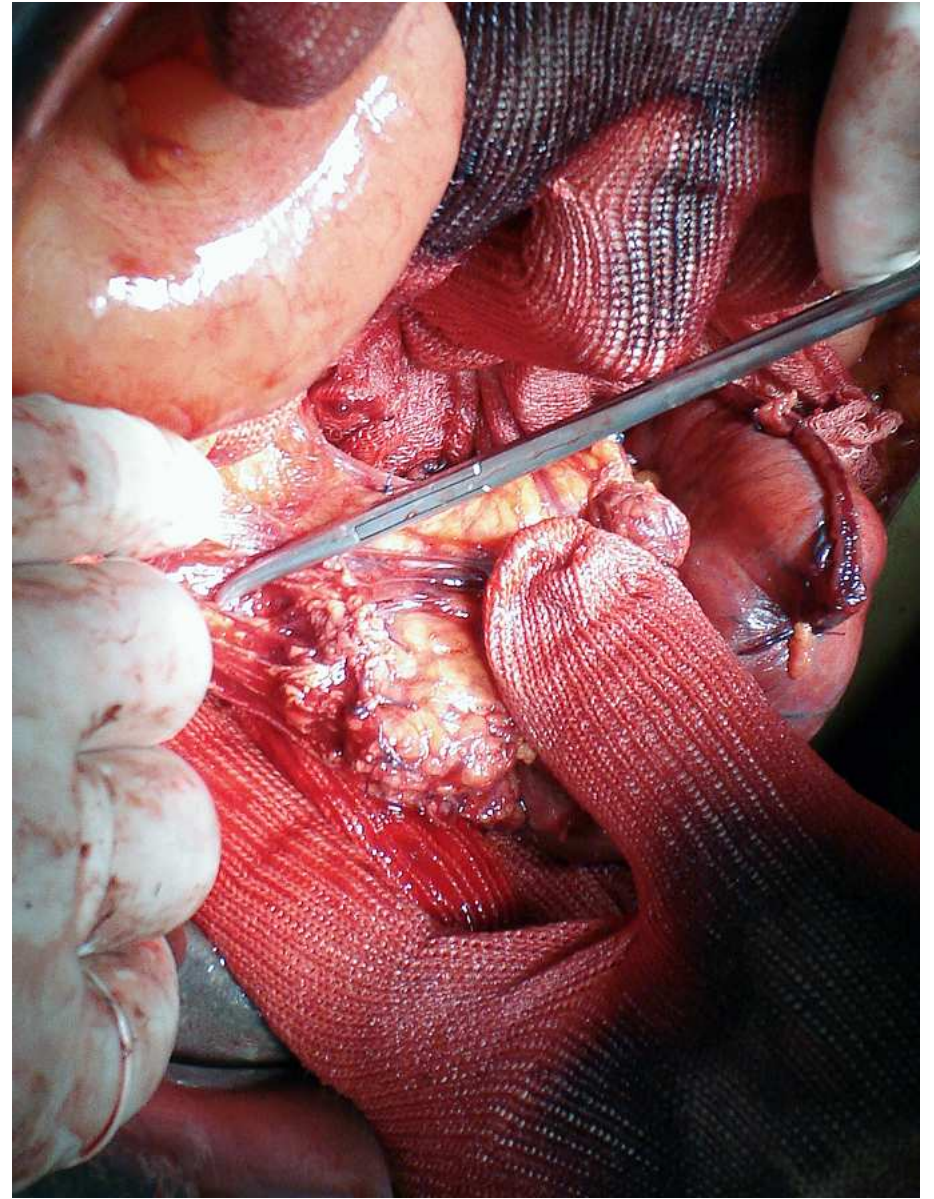
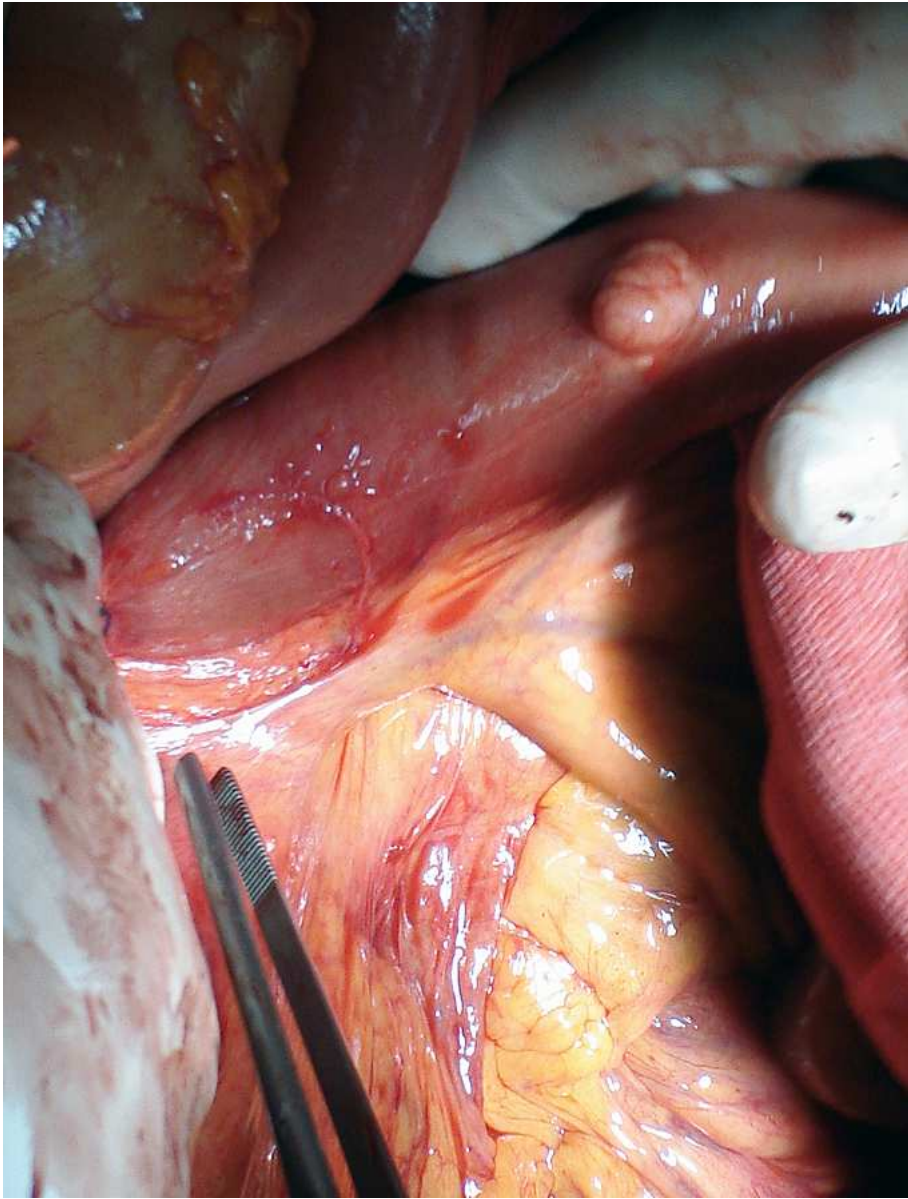


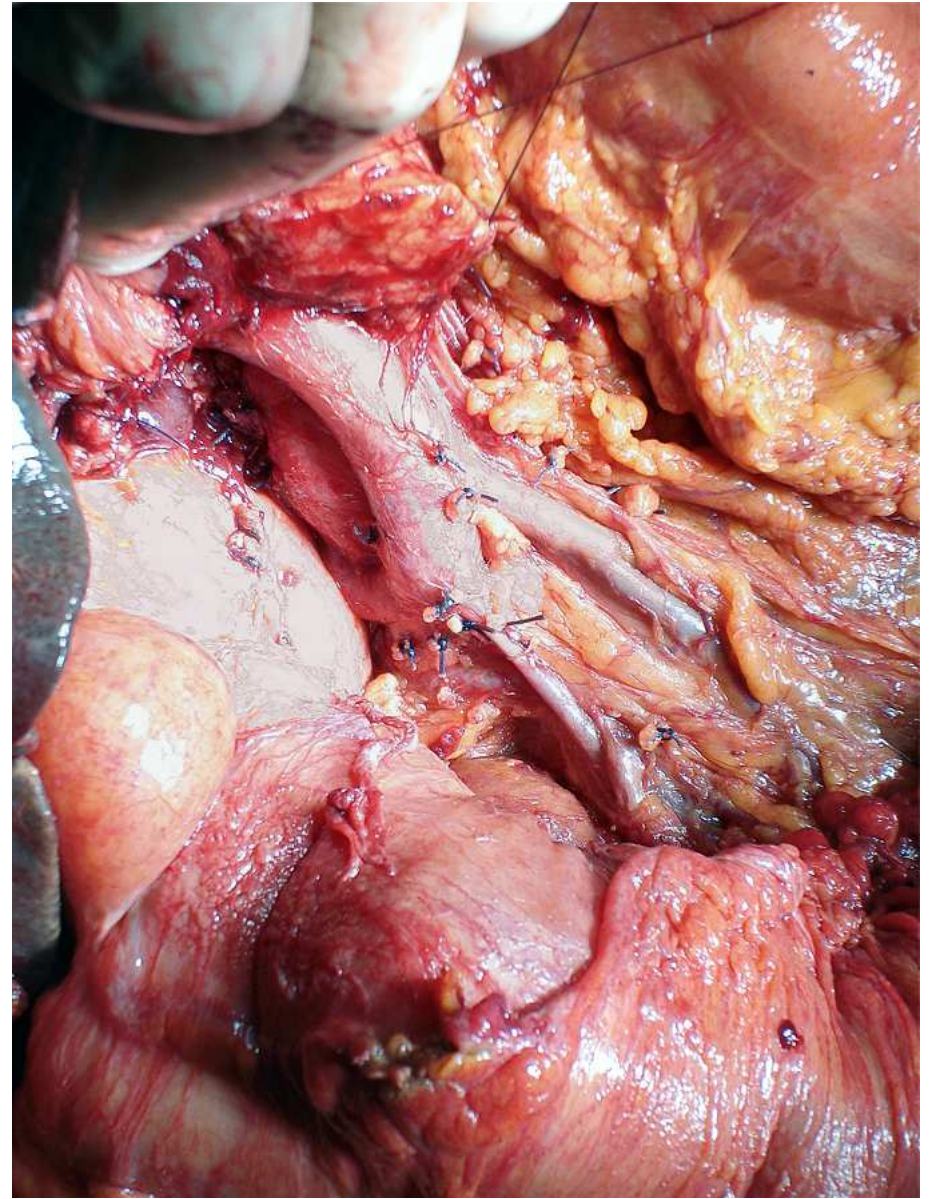
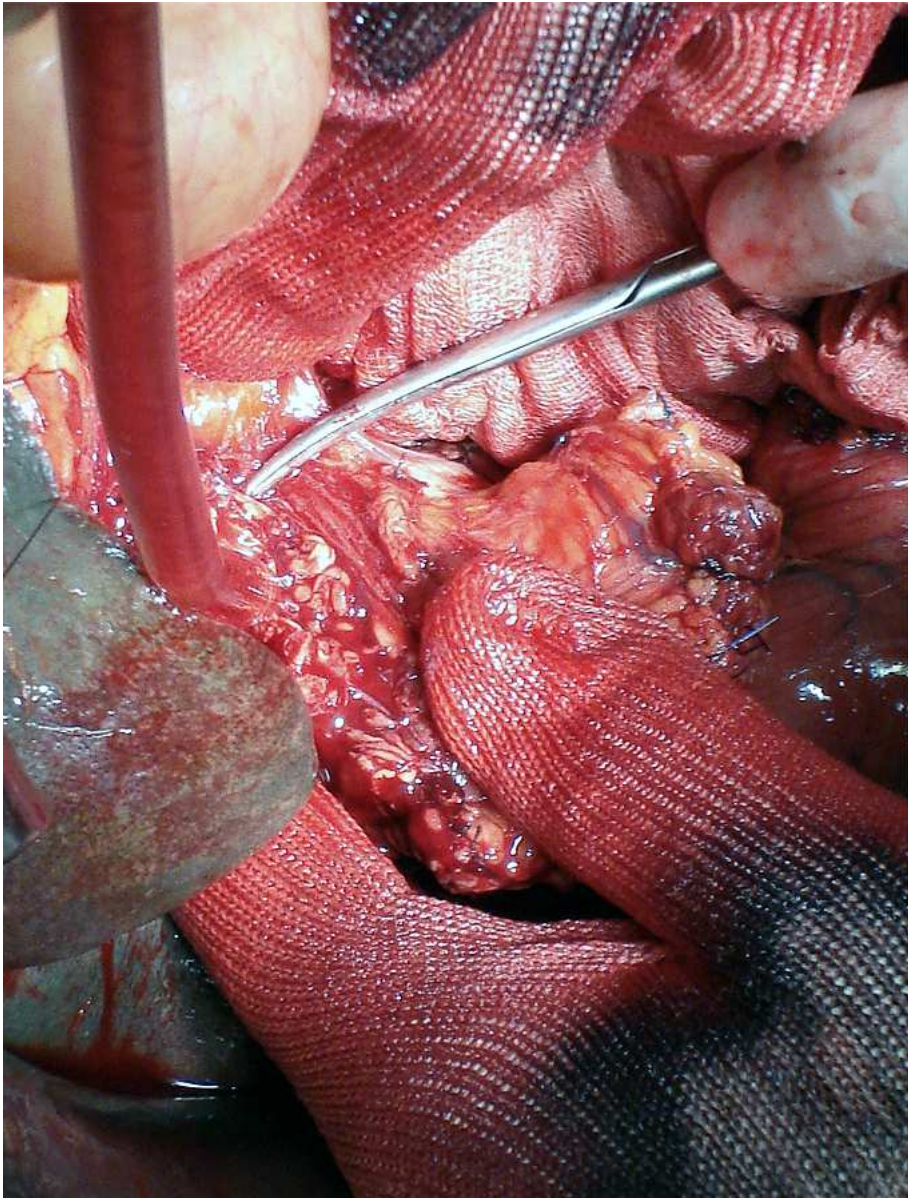
O.A. • Anni: 63 - F • Record: 9 • 04-01-2007

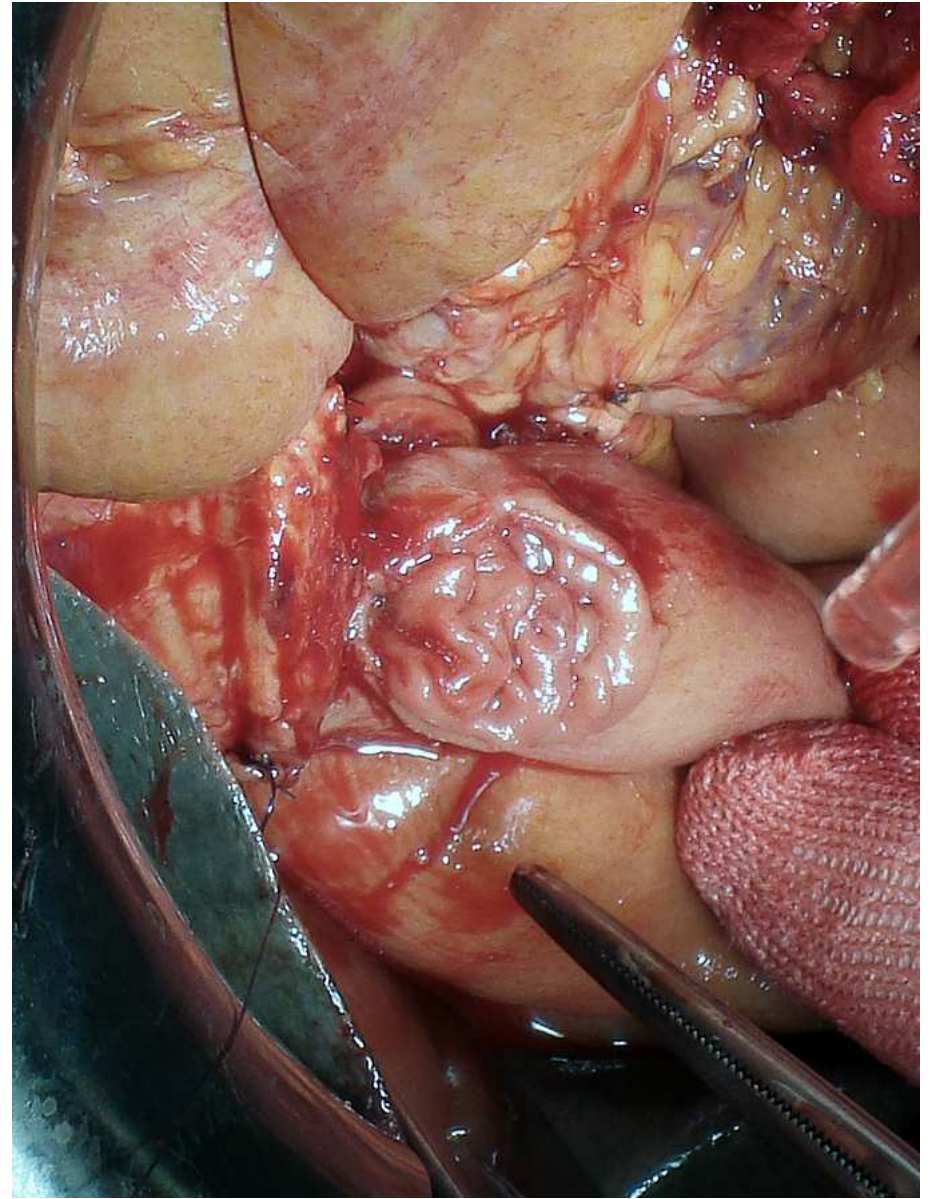
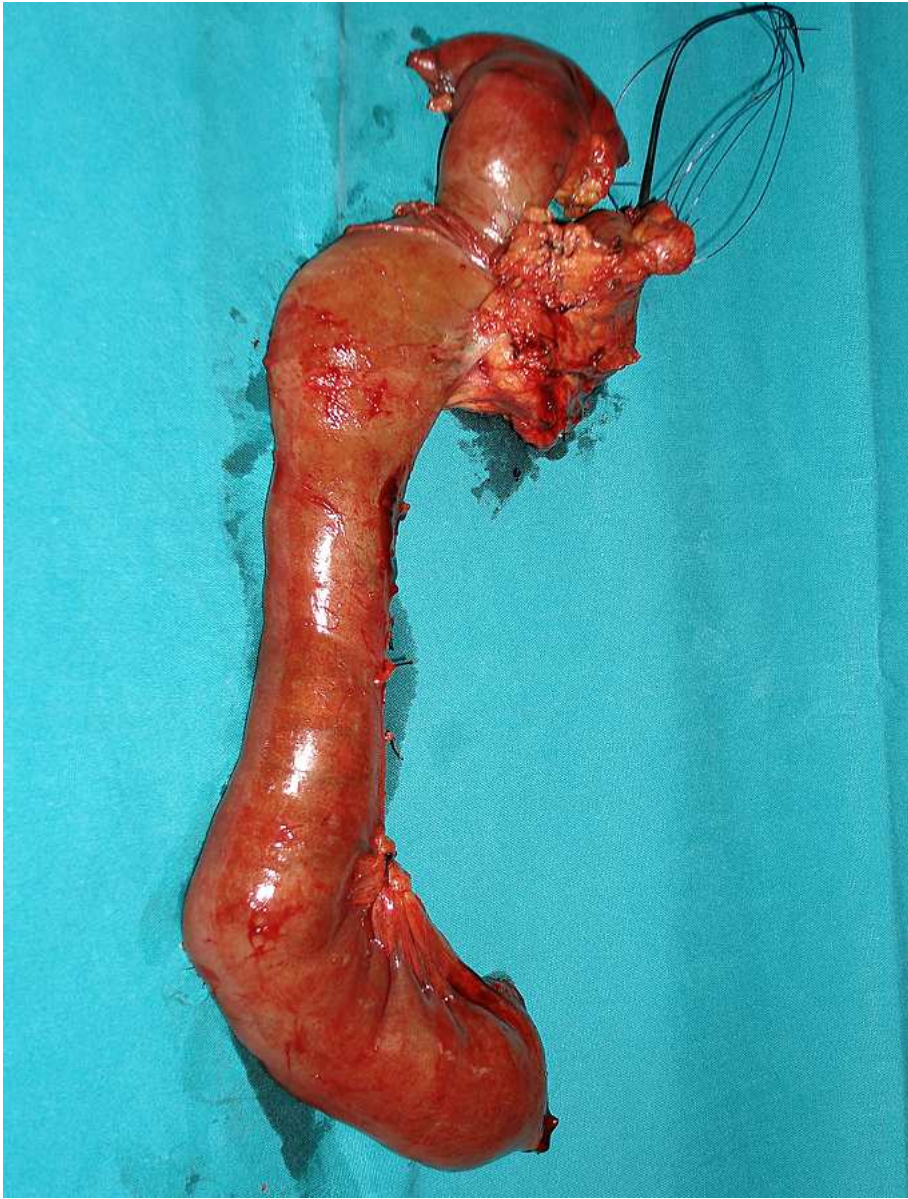
Duodenocefalopancreatectomia per ittero colostatico da adenocarcinoma delcoledoco terminale e della testa del pancreas



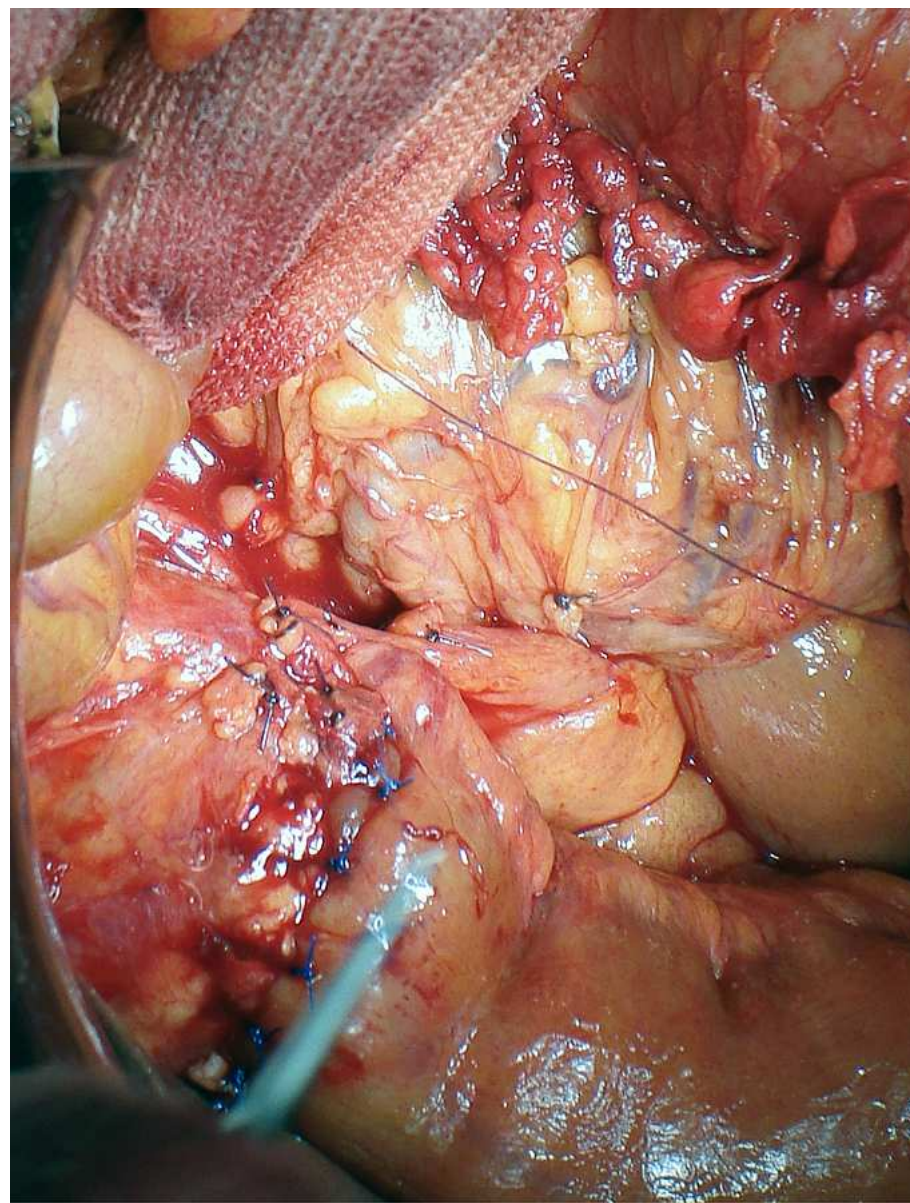
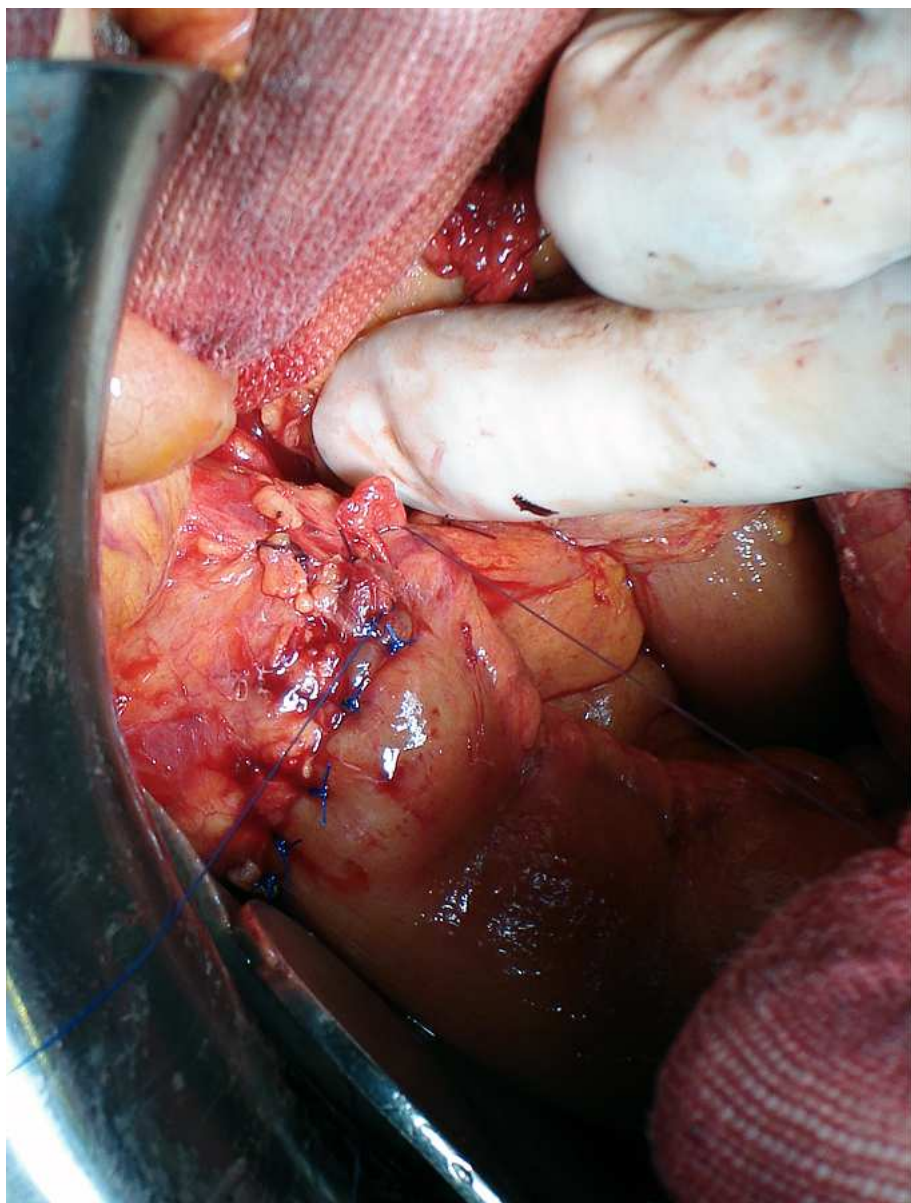


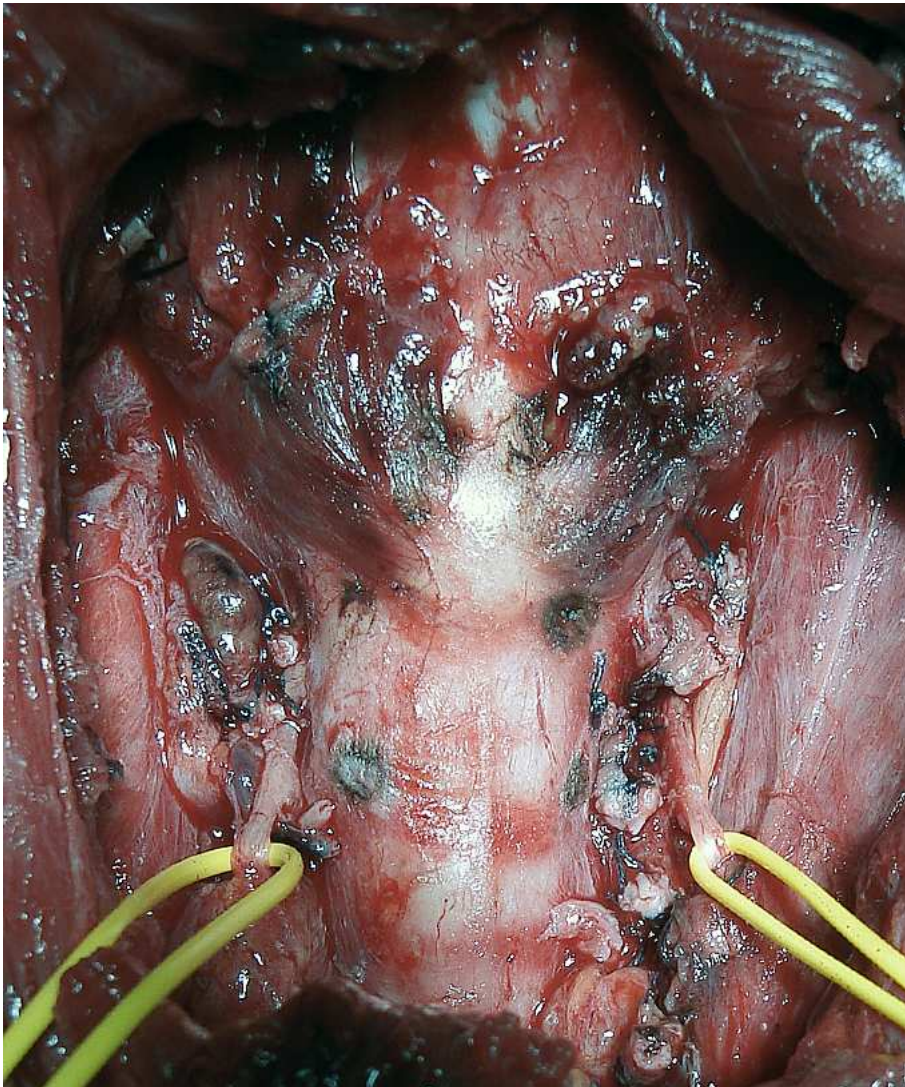






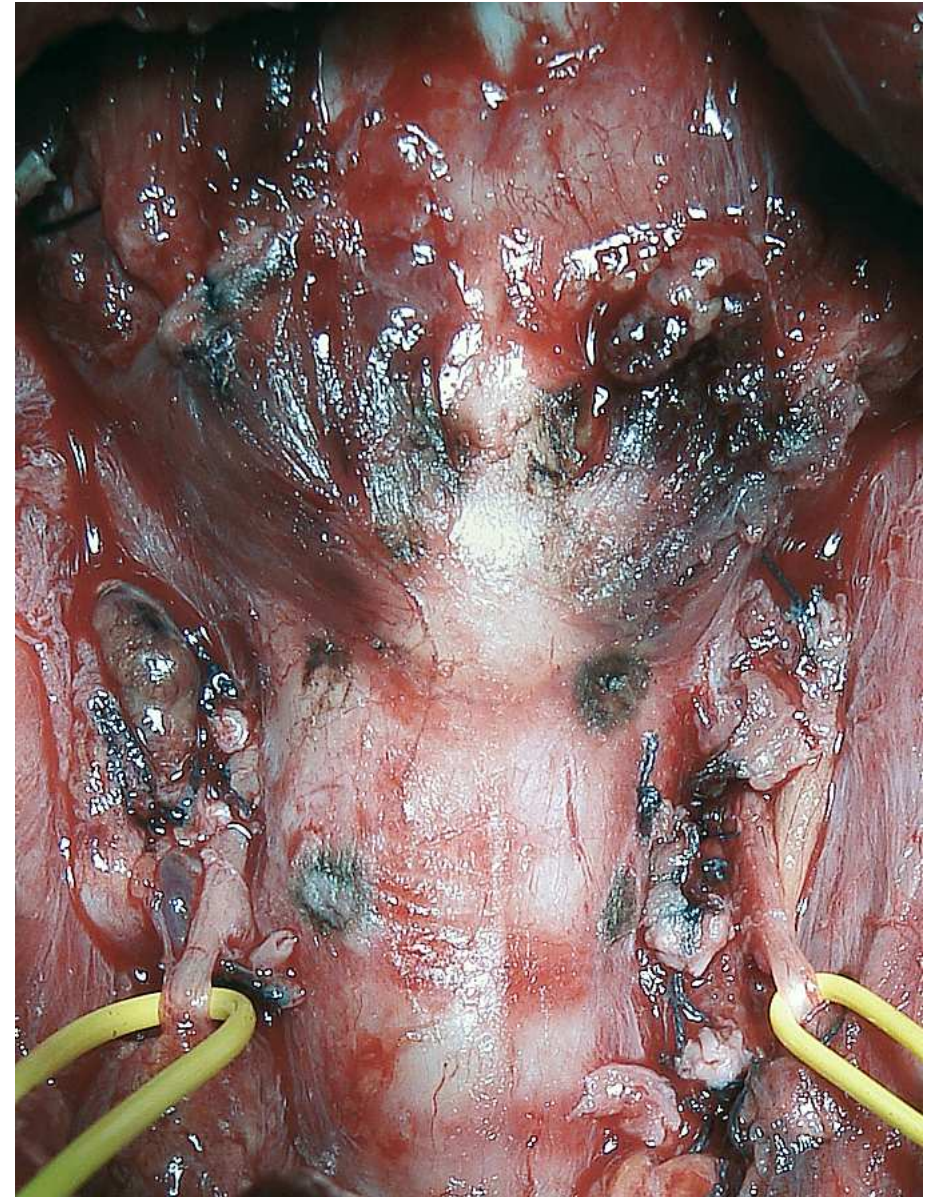




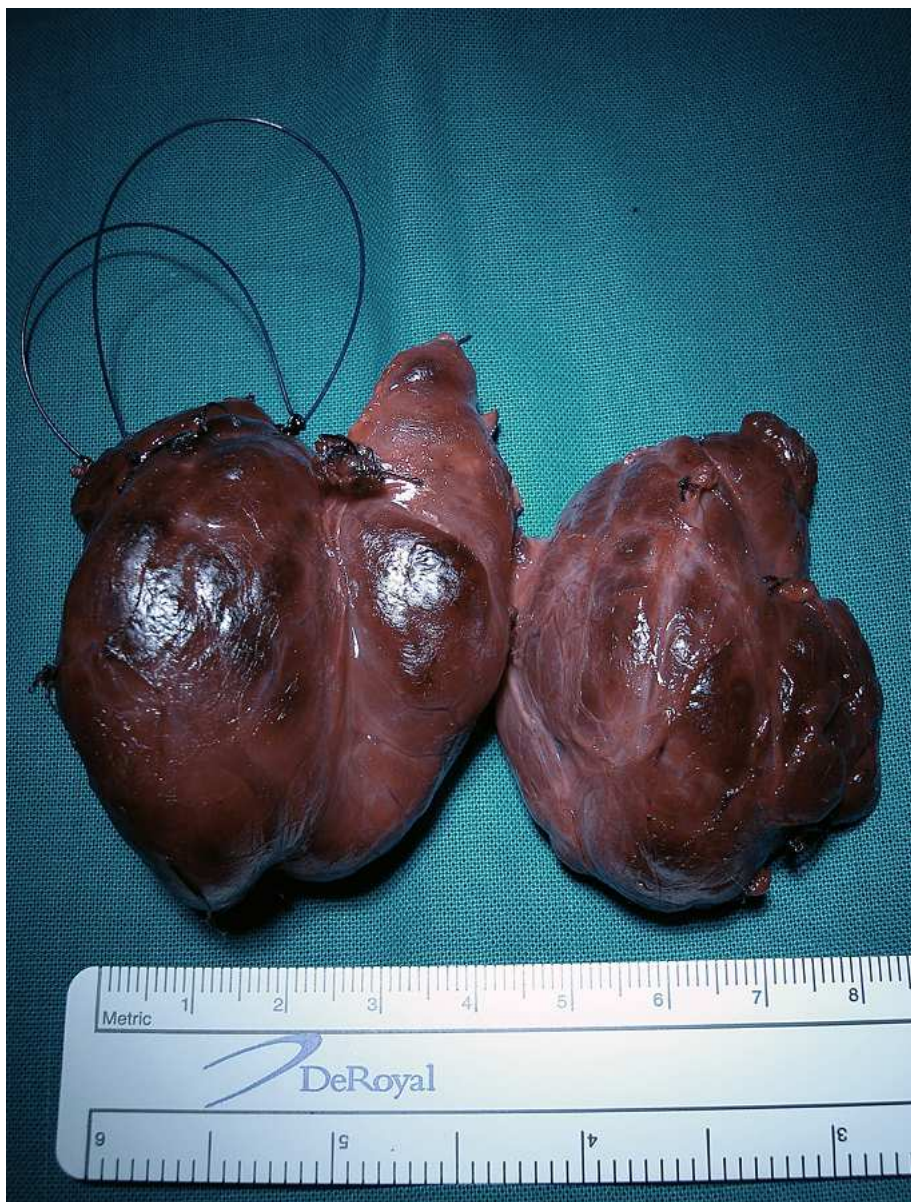


P.L. • Anni: 51 - F • Record: 10 • 22-01-2007

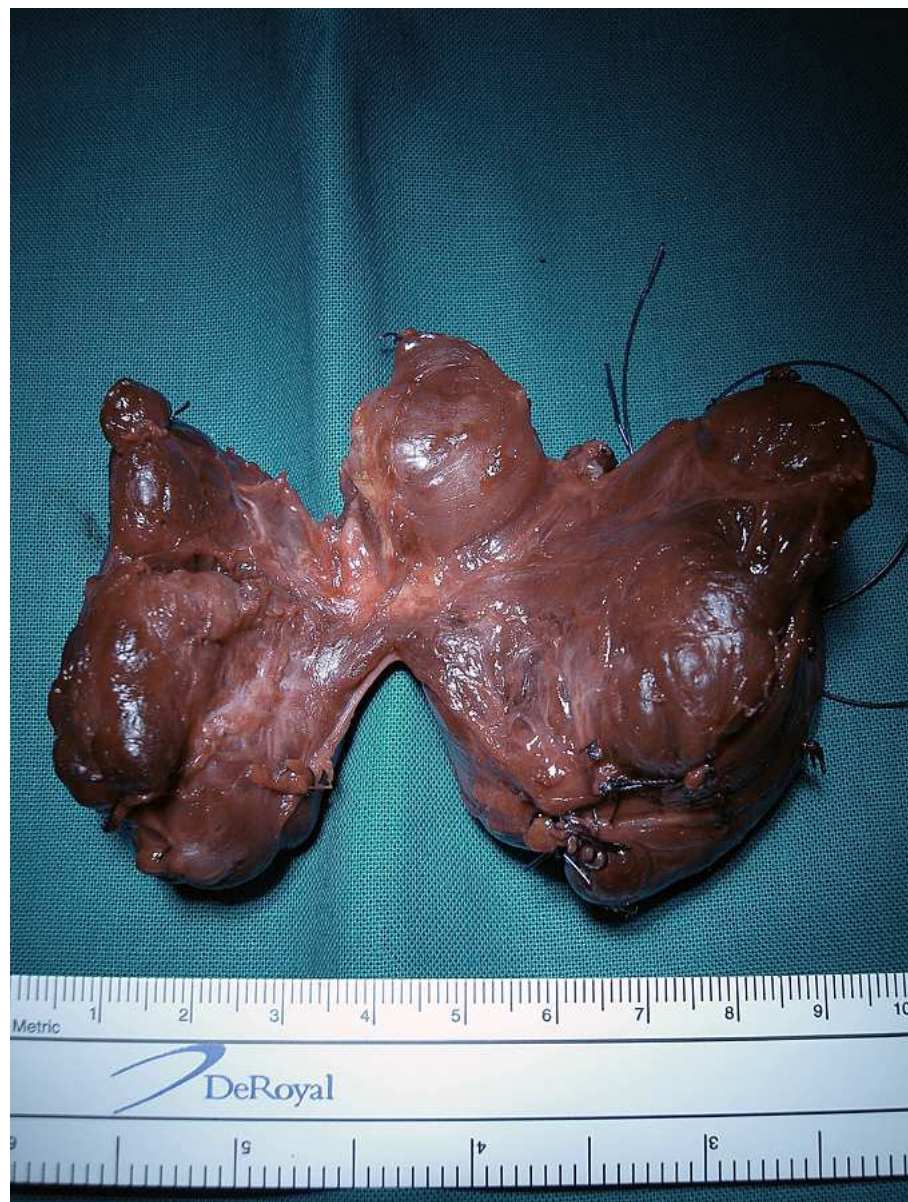Tiroidectomia totale extracapsulare per gozzo plurinodulare con sezione dei muscoli pretiroidei



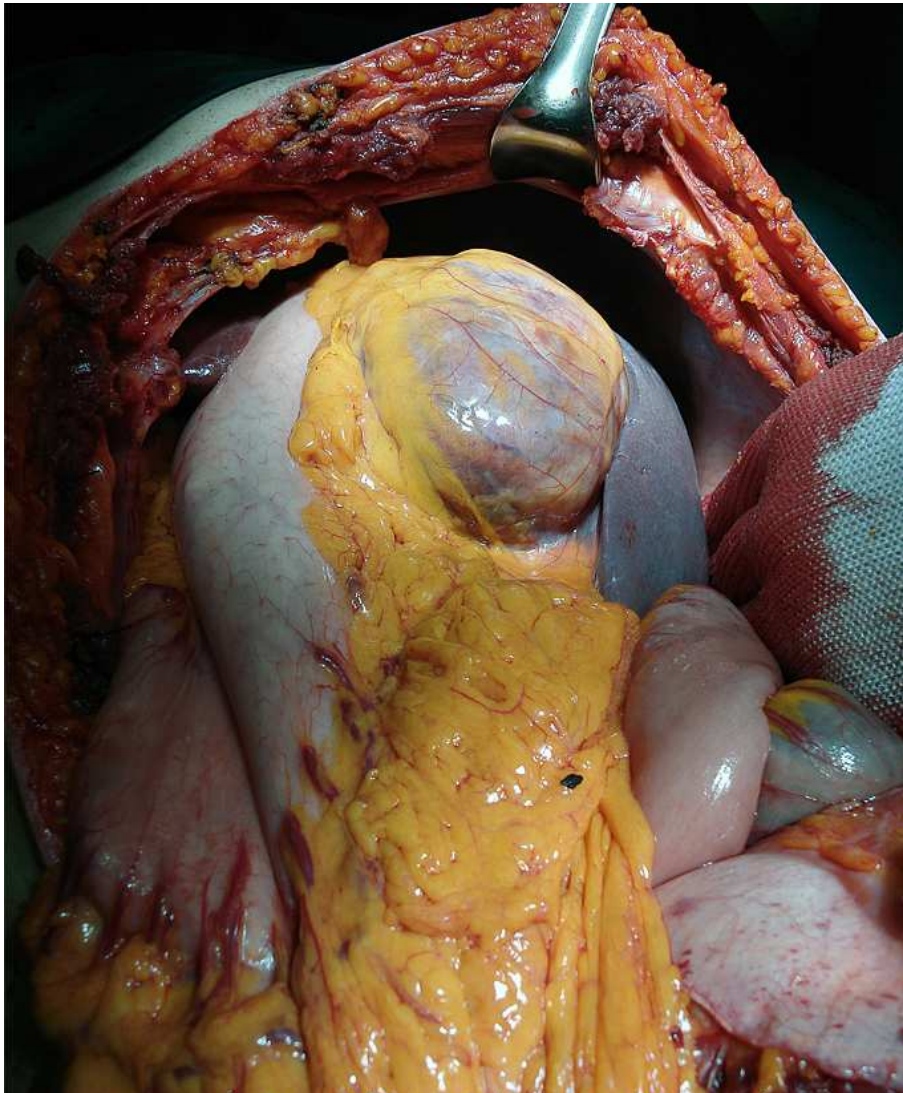
Isolamento dei nervi laringei inferiori (ricorrenti)



Lobo destro - Istmo - Lobo sinistro (v. ant.)

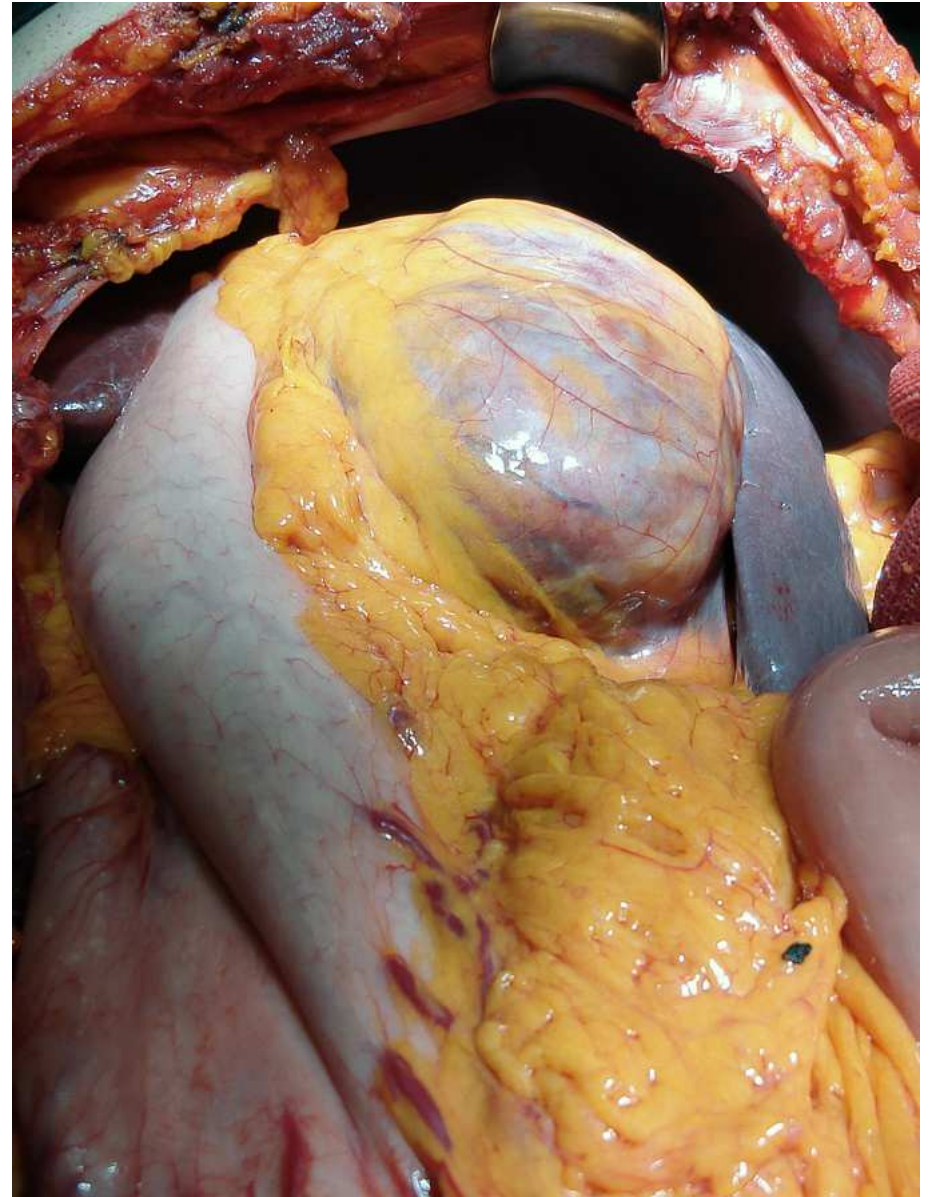

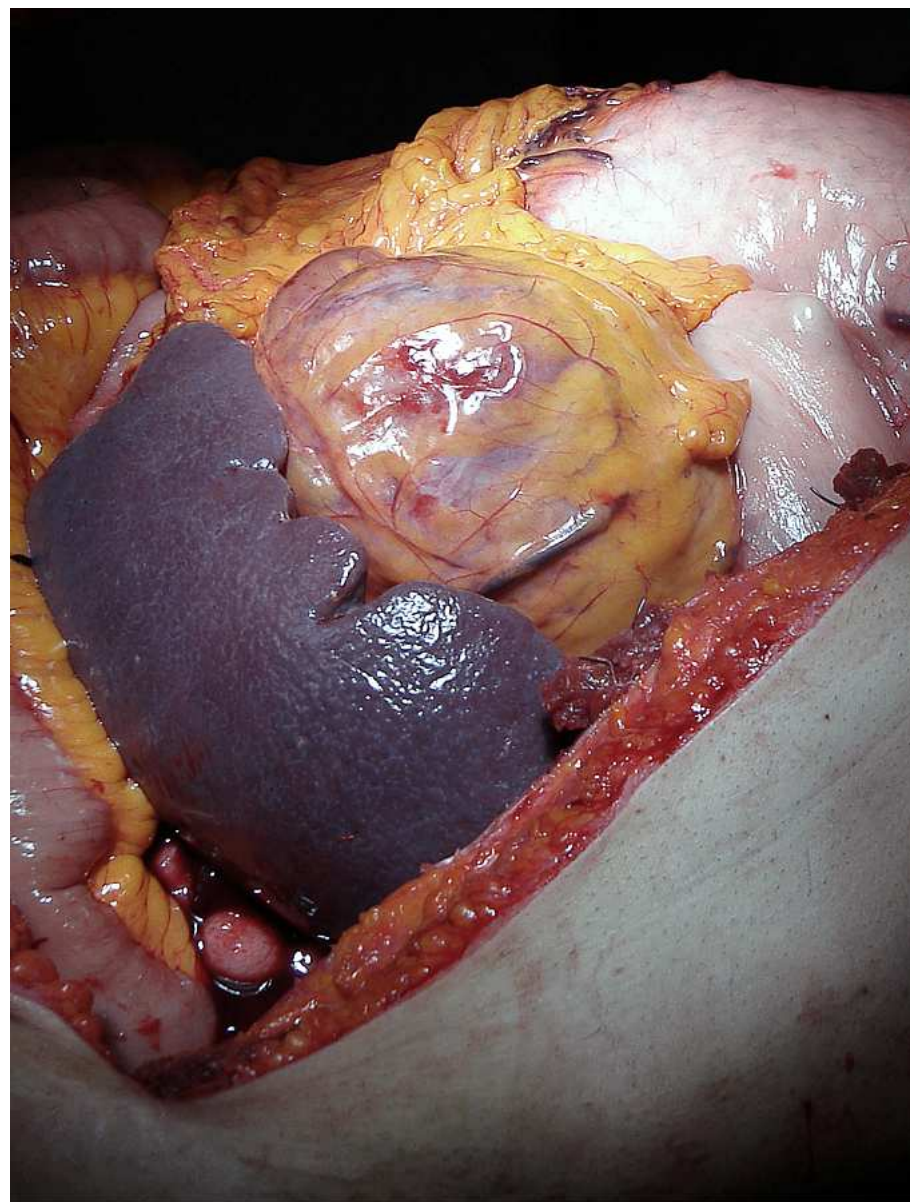
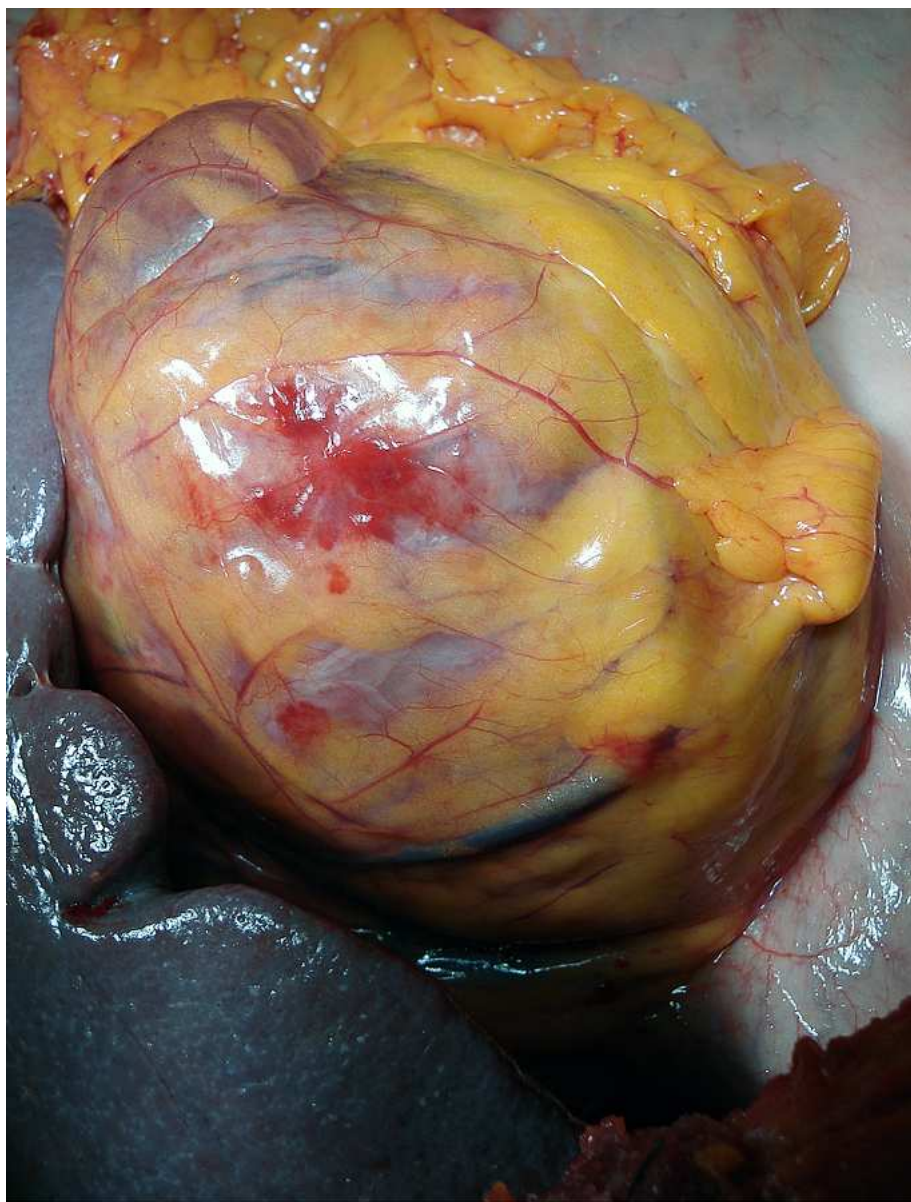Lobo sinistro - Istmo - Lobo destro (superficie posteriore)

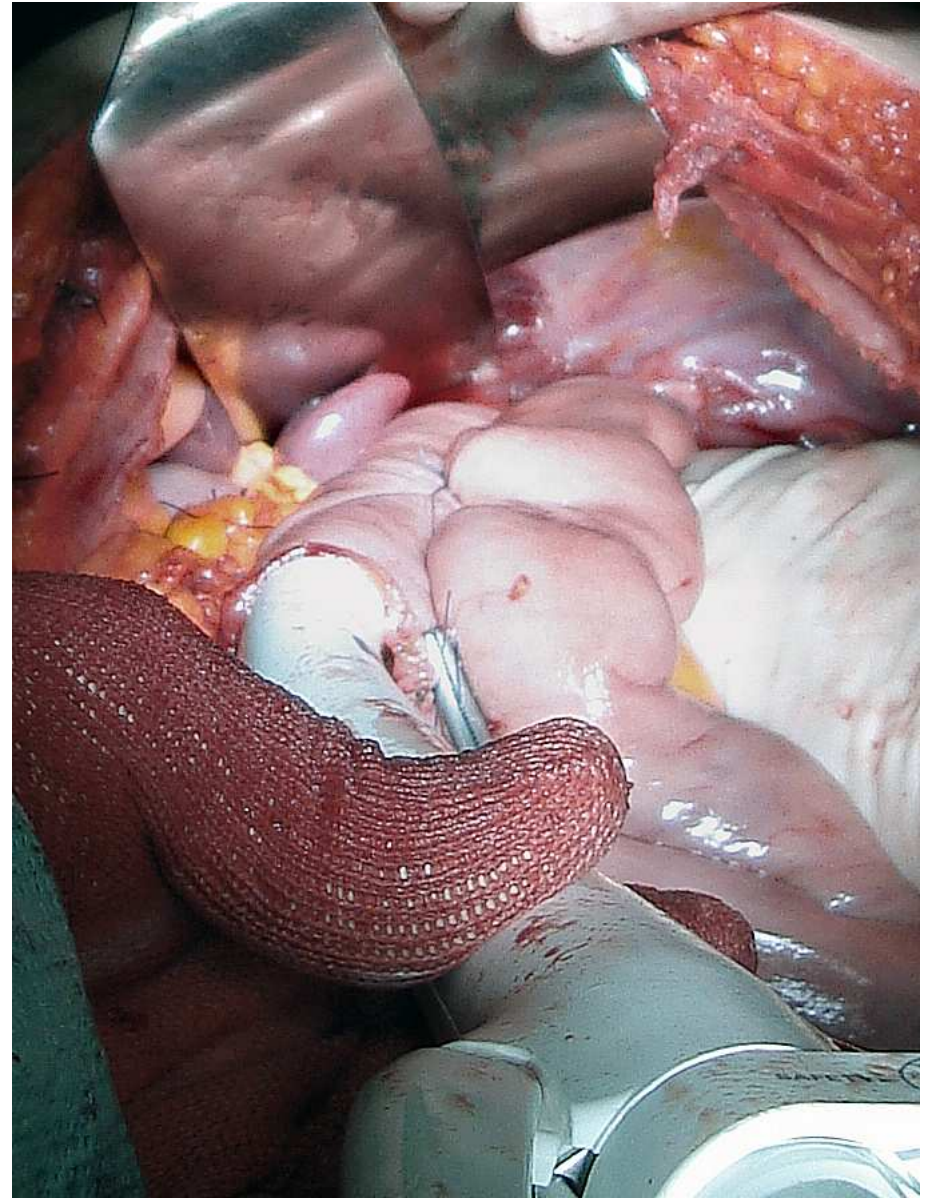
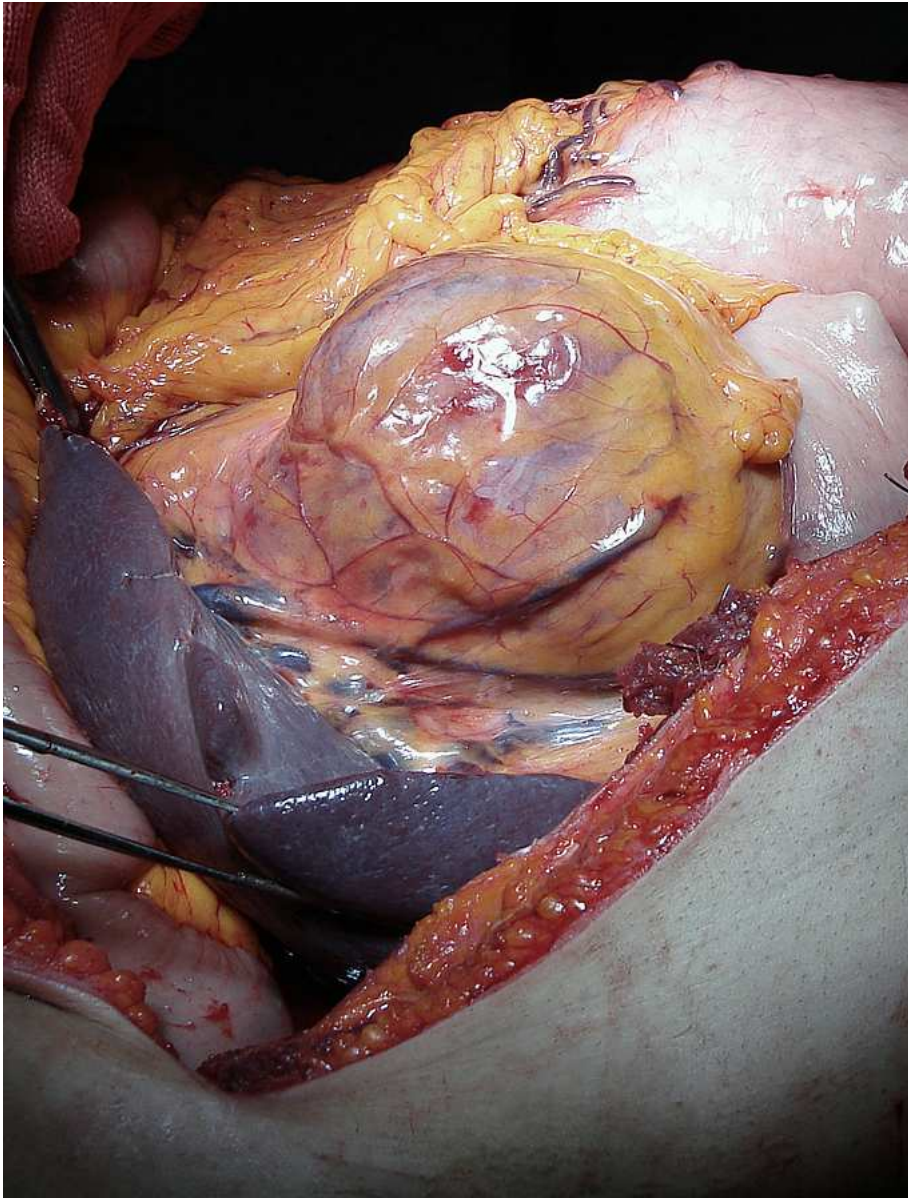


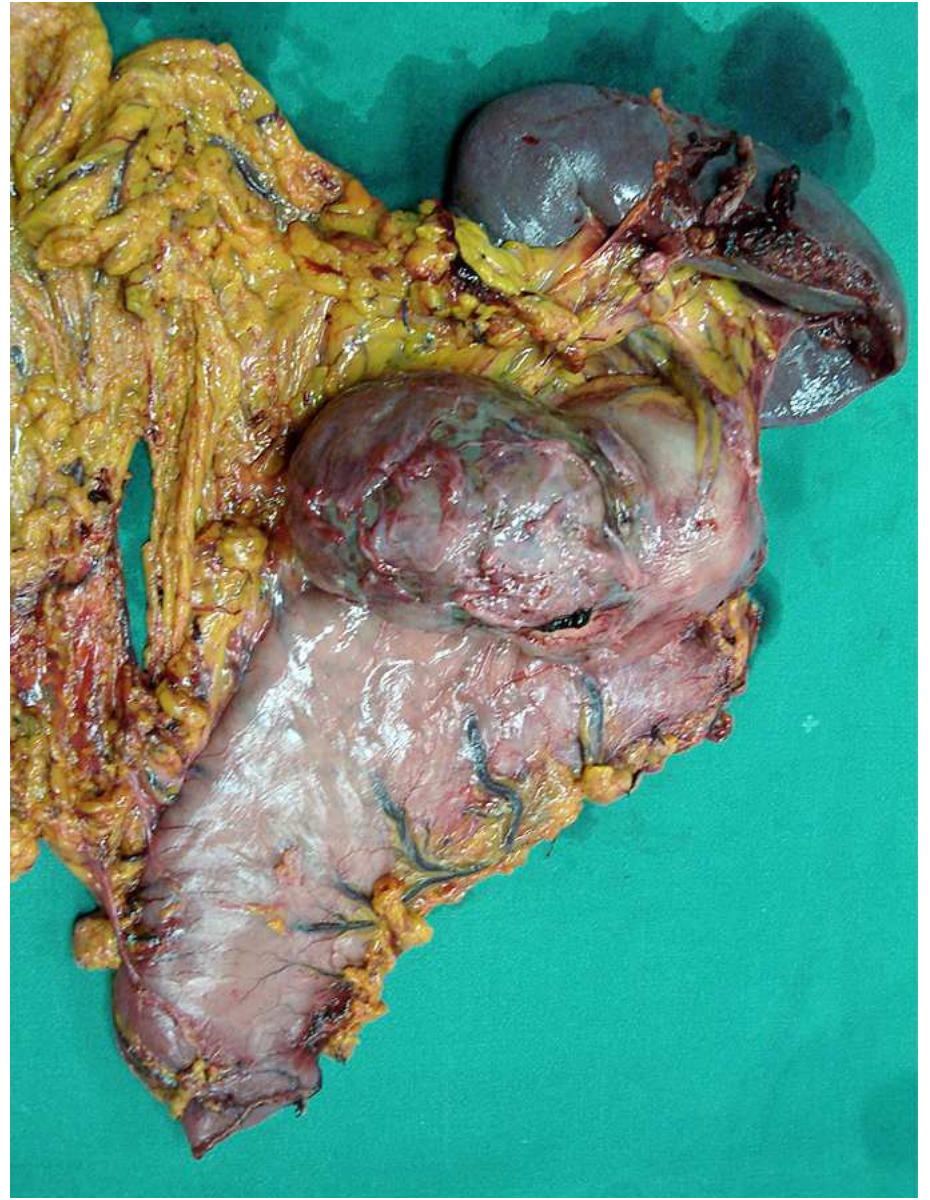
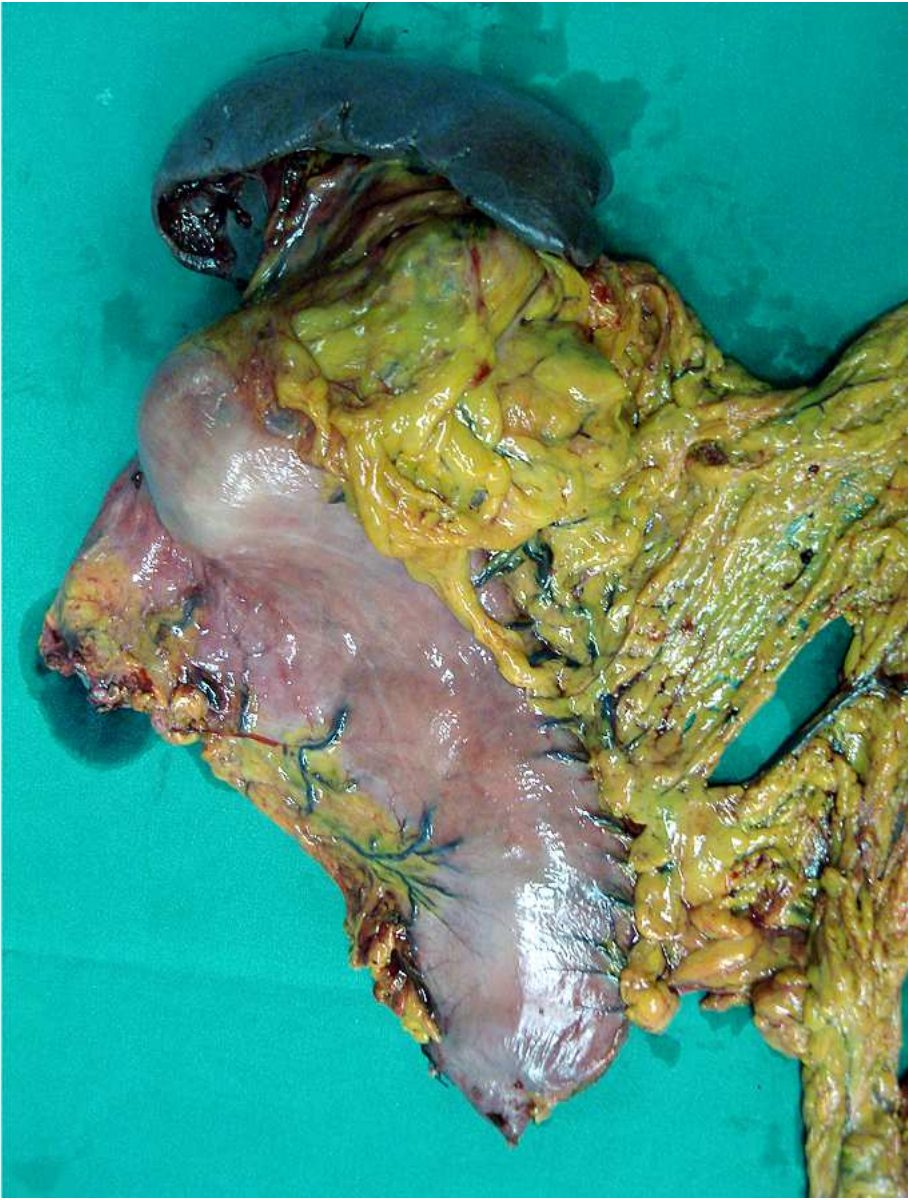D.E. • Anni: 54 - M 🍏 Record: 11 • 08-02-2007

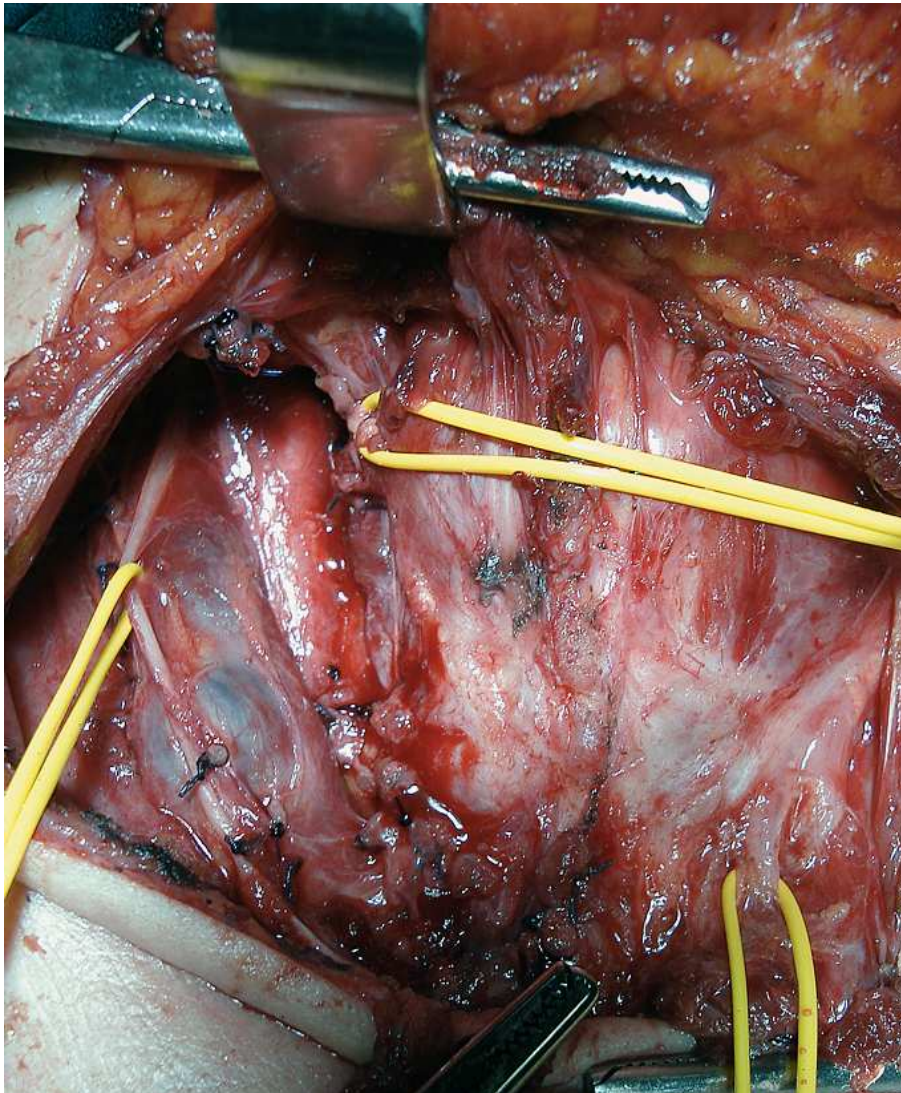
Gastrectomia totale allargata sec. Lortat-Jacob con esofago-digiunostomia sec. Lahey e reservoir sec. Hoffmann per ematemasi da gist gastrico





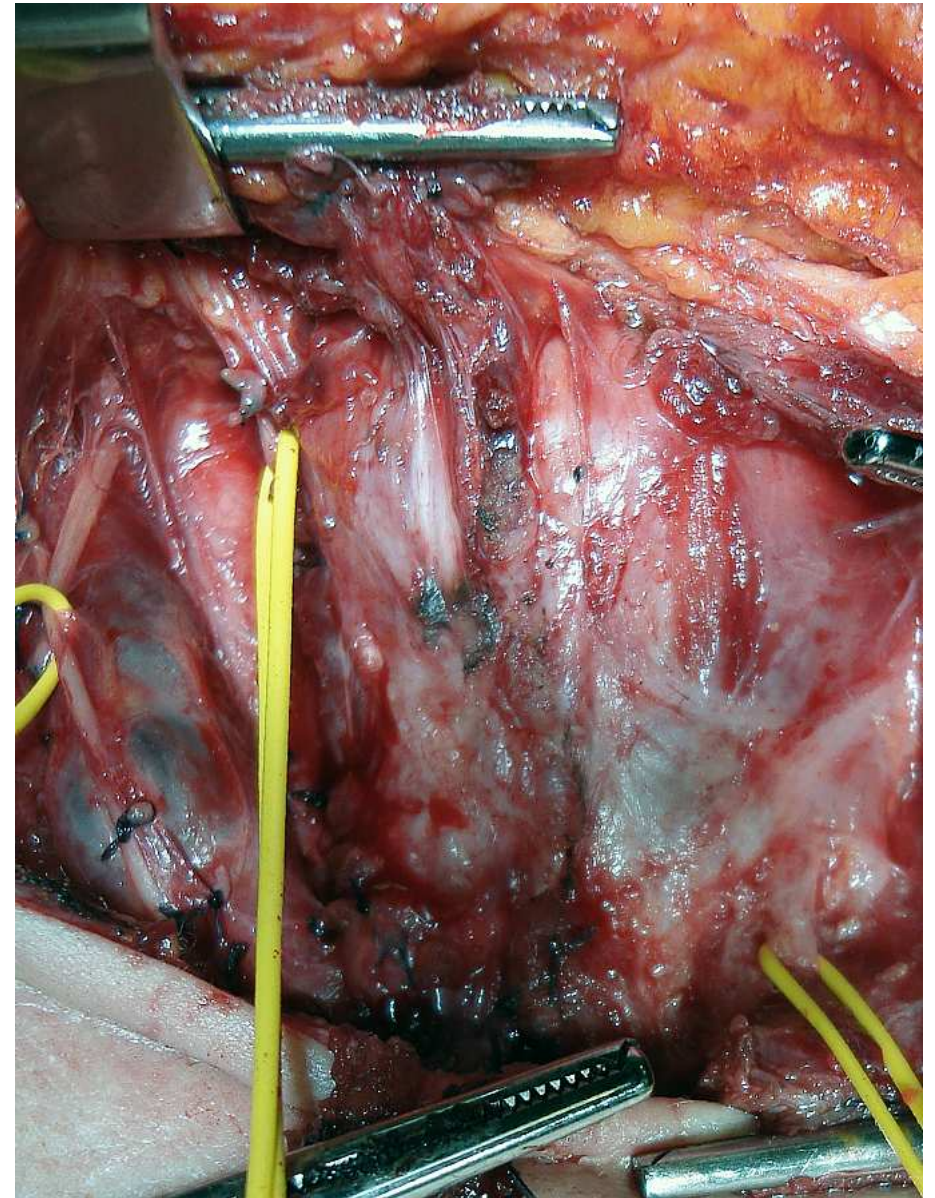






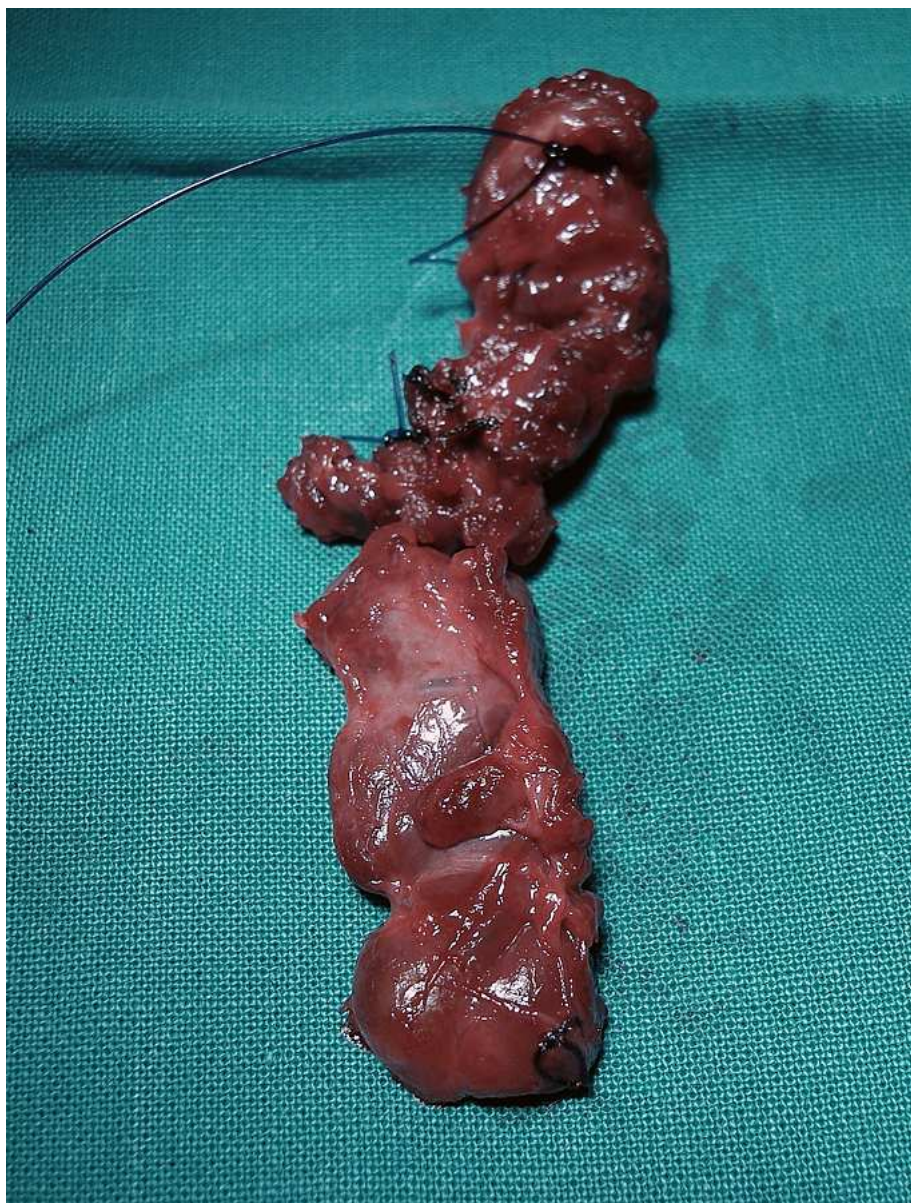
M.M.R. • Anni: 58 - F • Record: 12 • 15-02-2007

Totalizzazione a dx in plurioperata di tiroidectomia subtotale per carcinoma papillifero con sezione dei muscoli pretiroidei

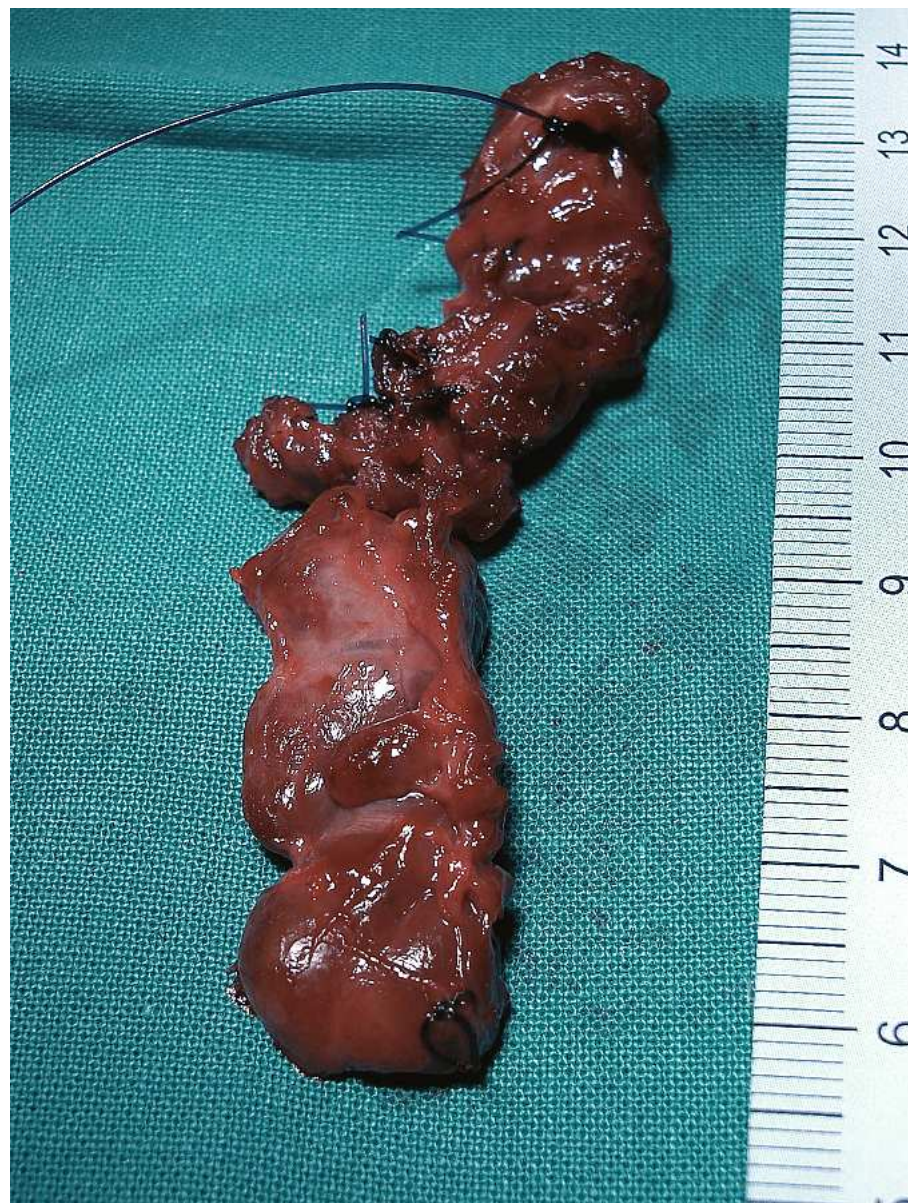

Isolamento dei nervi laringei inferiori (ricorrenti)

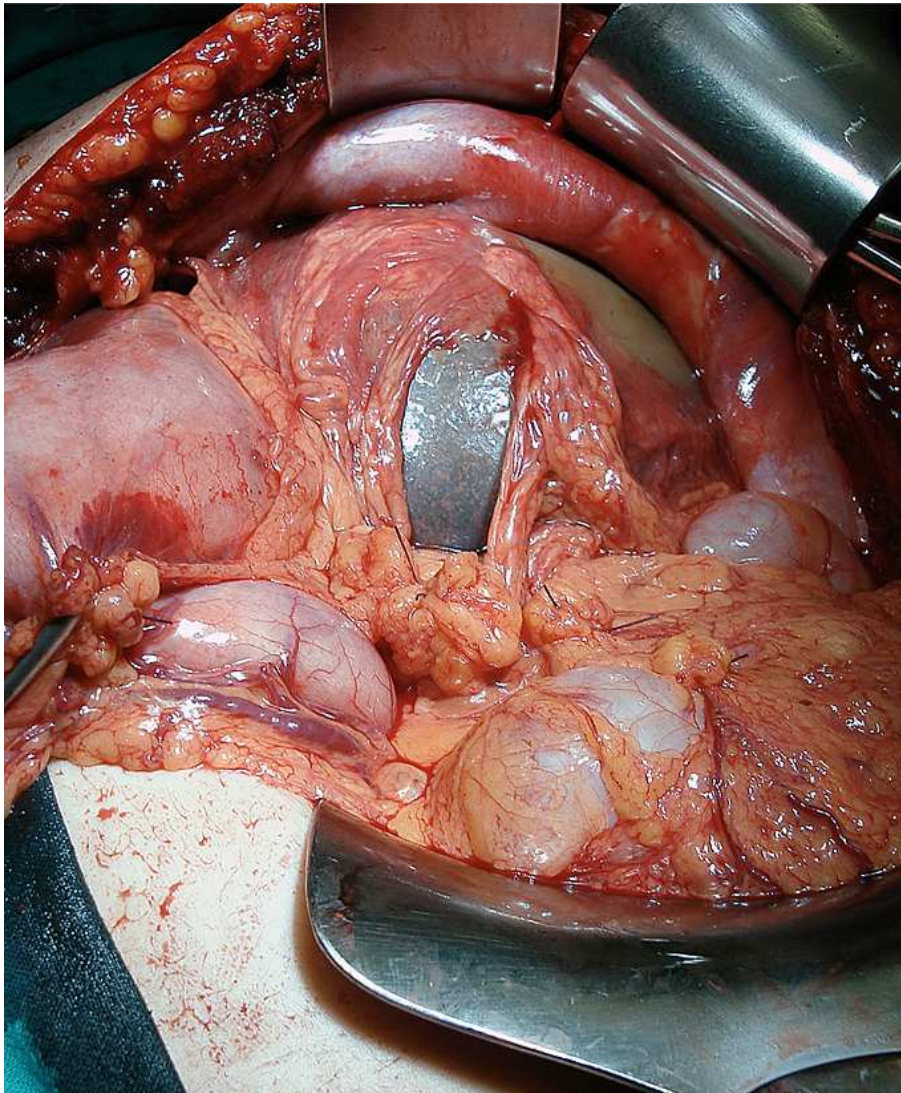




Residuo del lobo tiroideo destro (superficie anteriore)

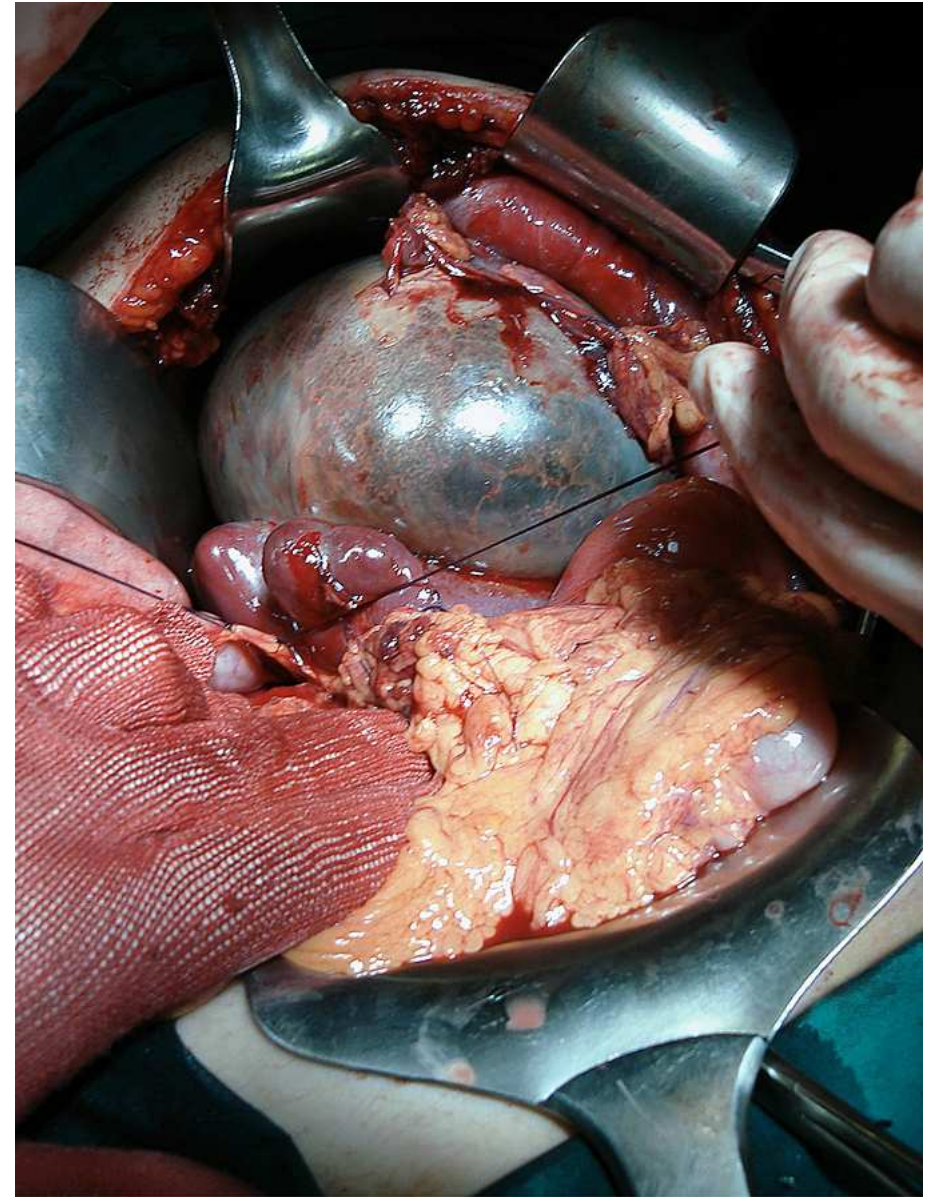


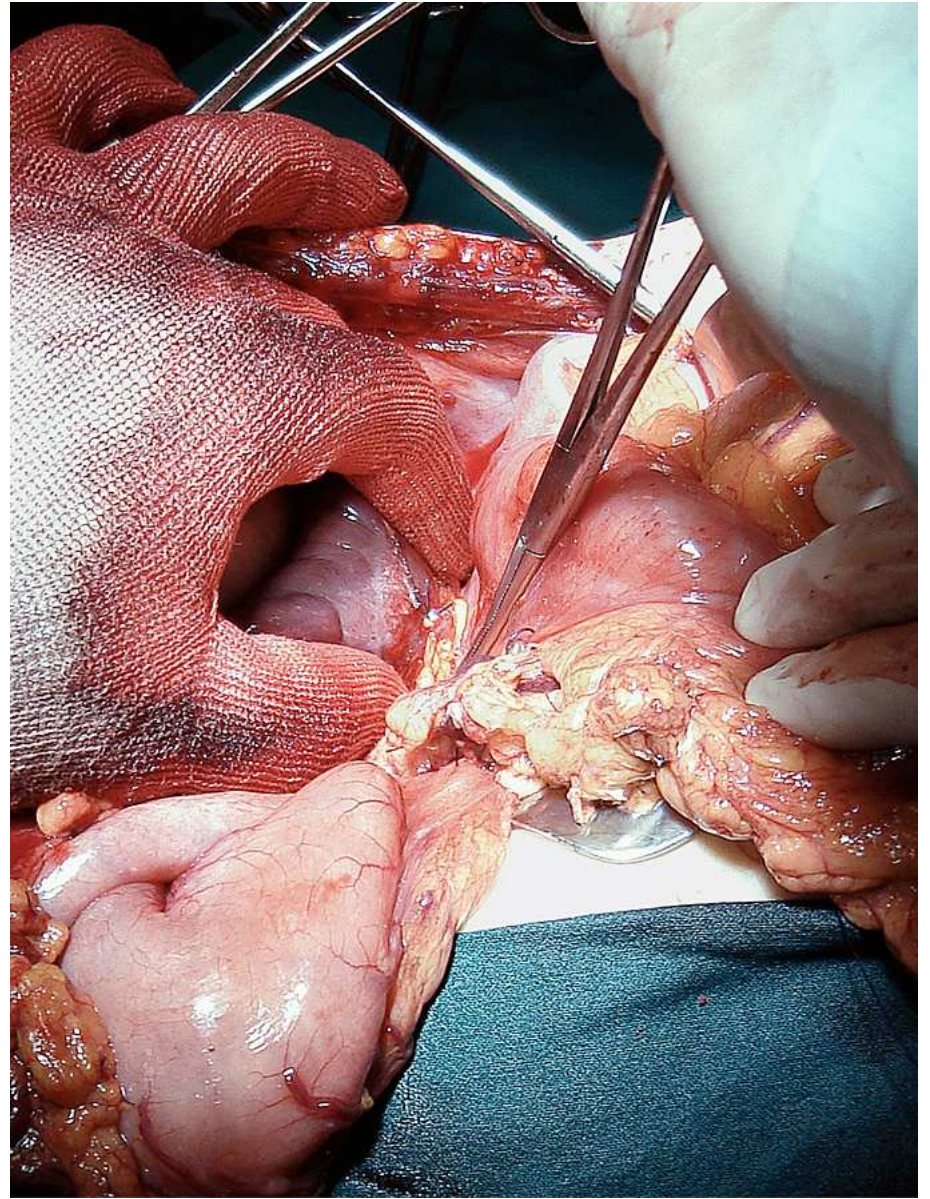
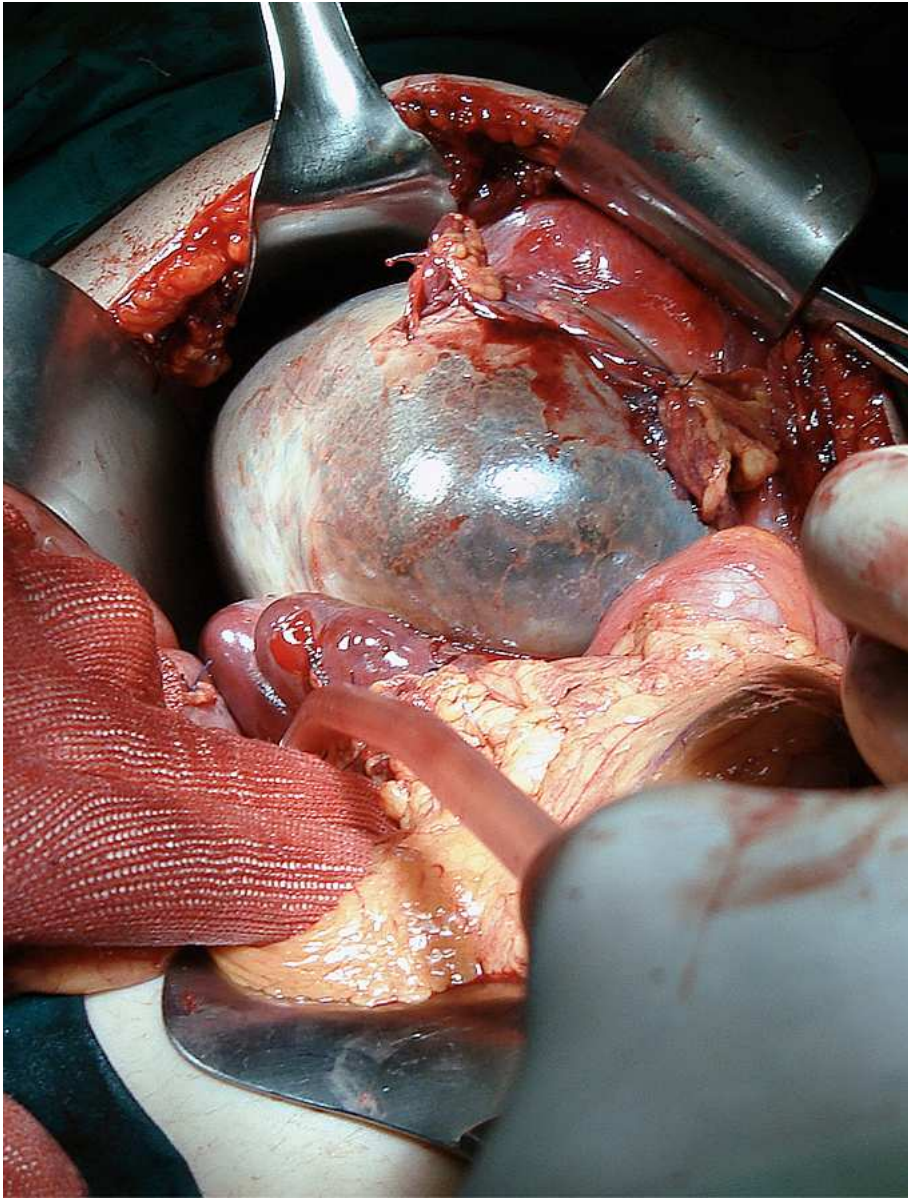
Residuo del lobo tiroideo destro (superficie posteriore)

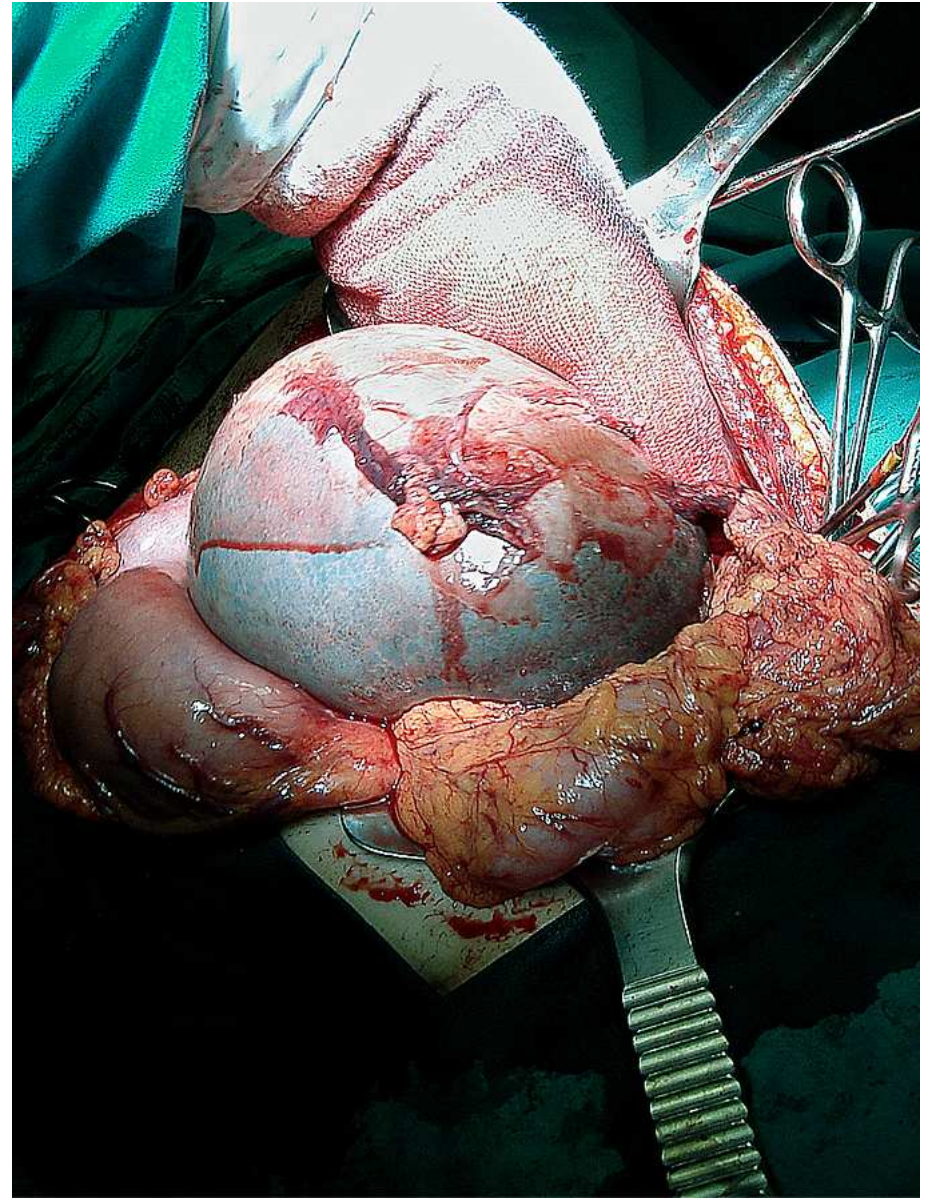
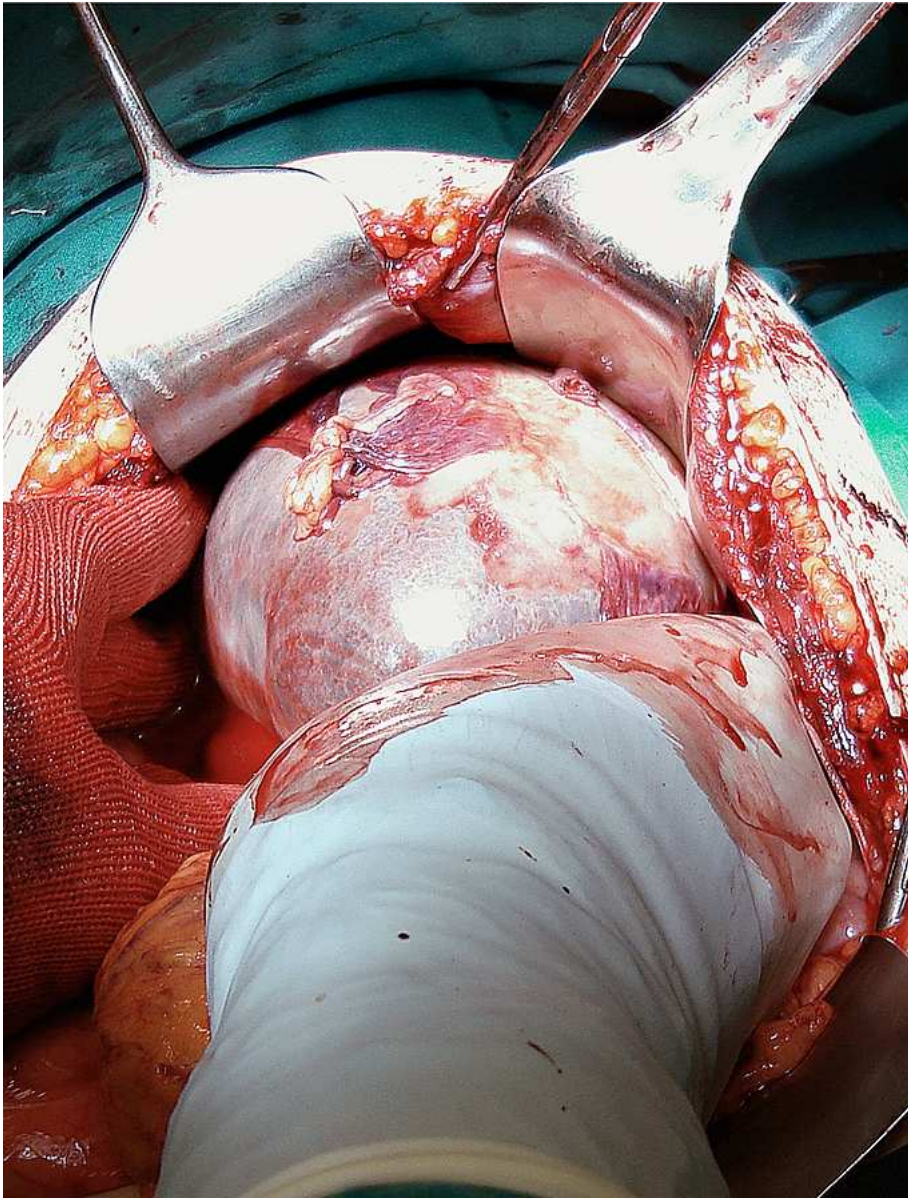


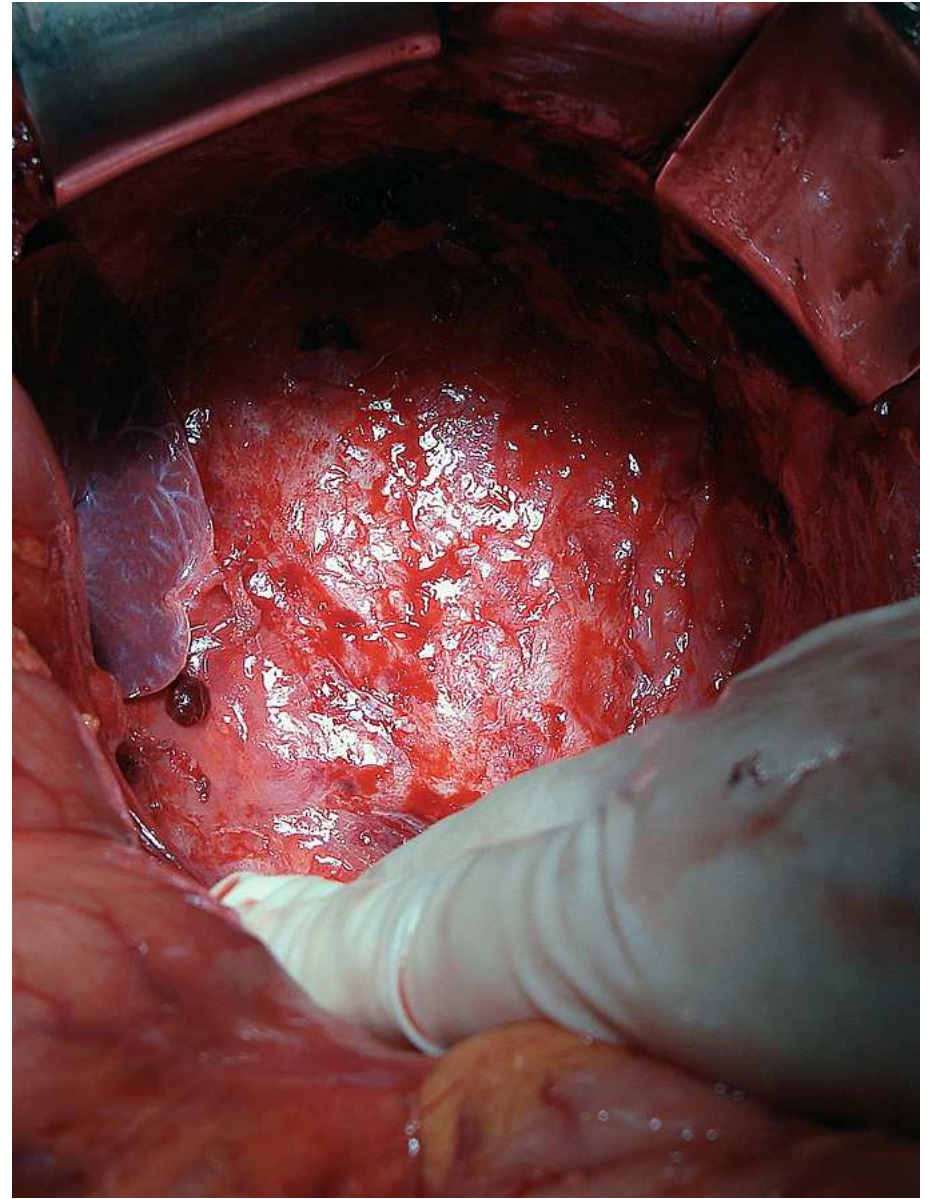
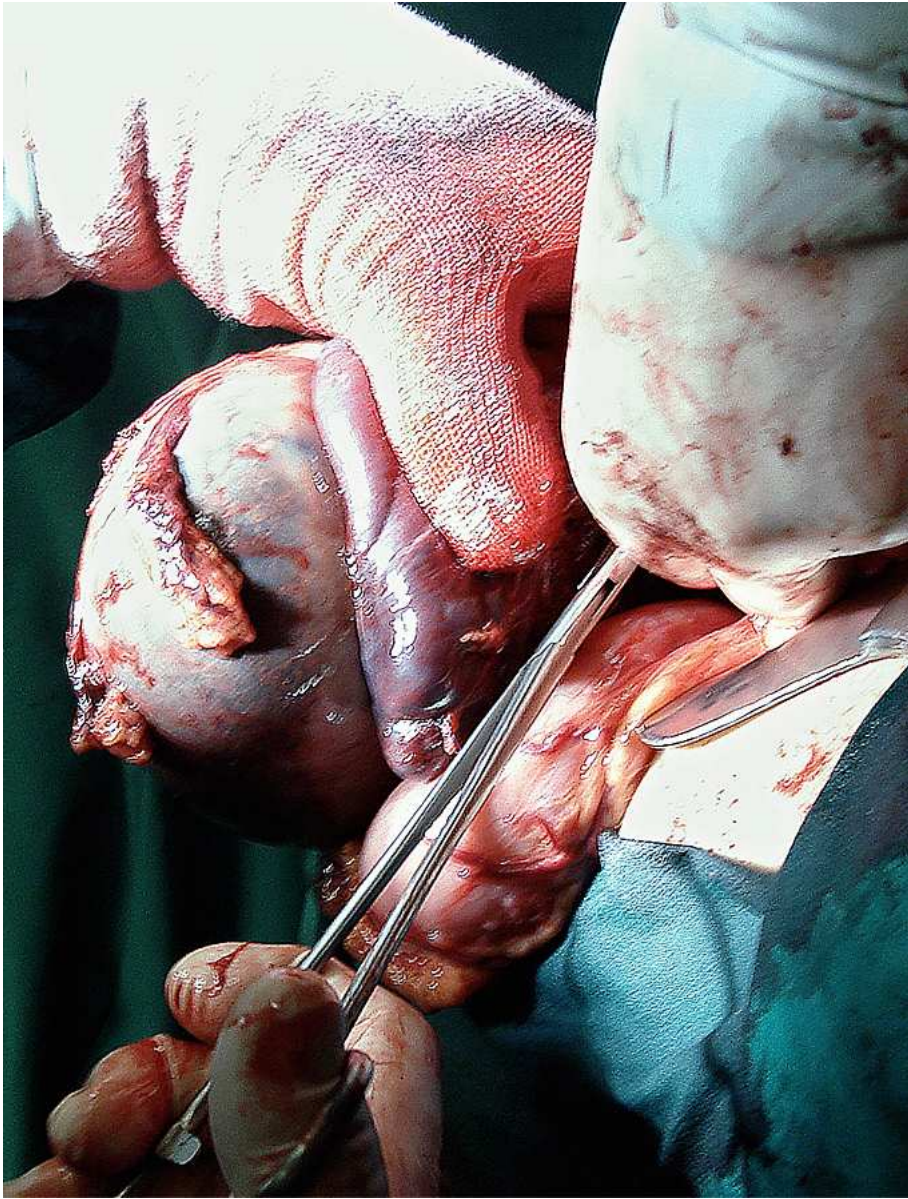
S.L. • Anni: 32 - F • Record: 13 • 22-02-2007

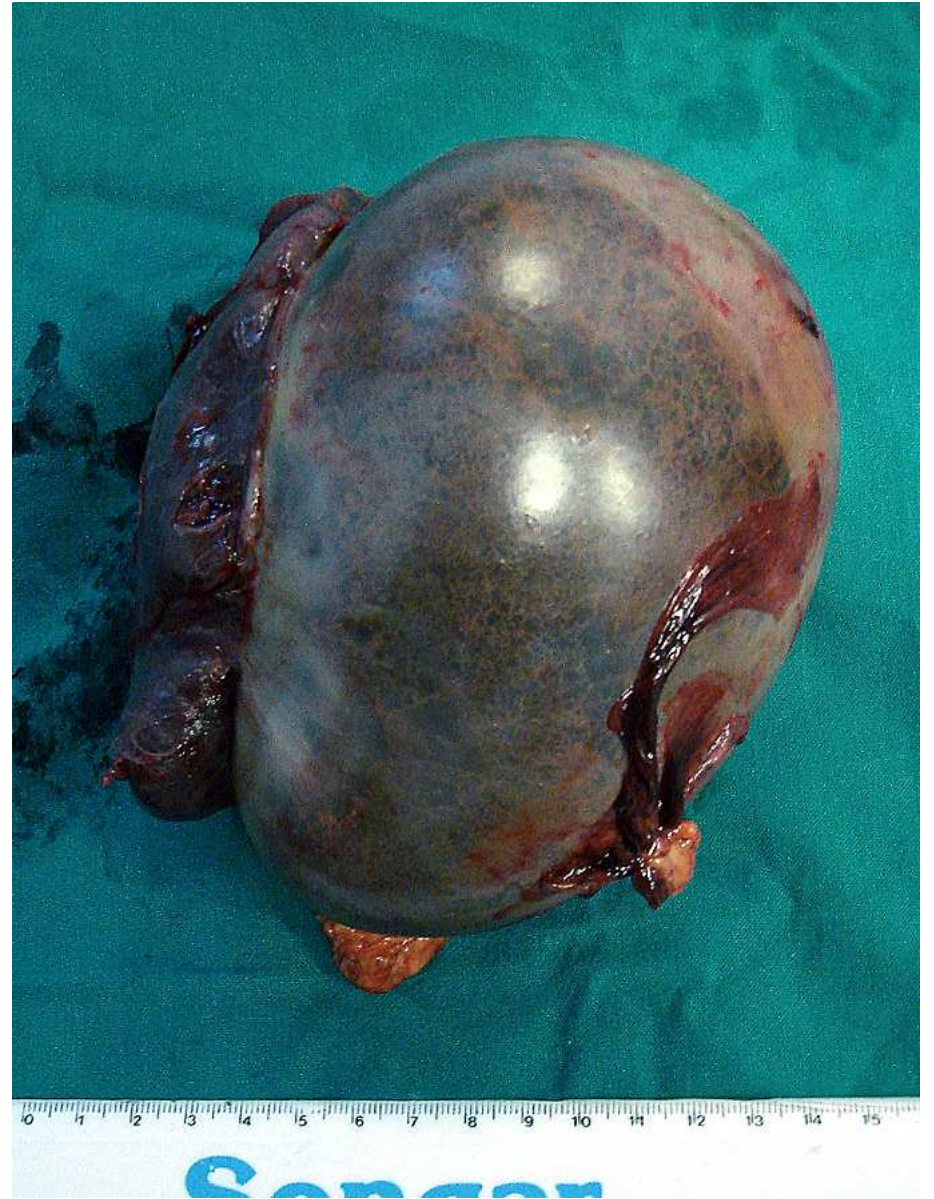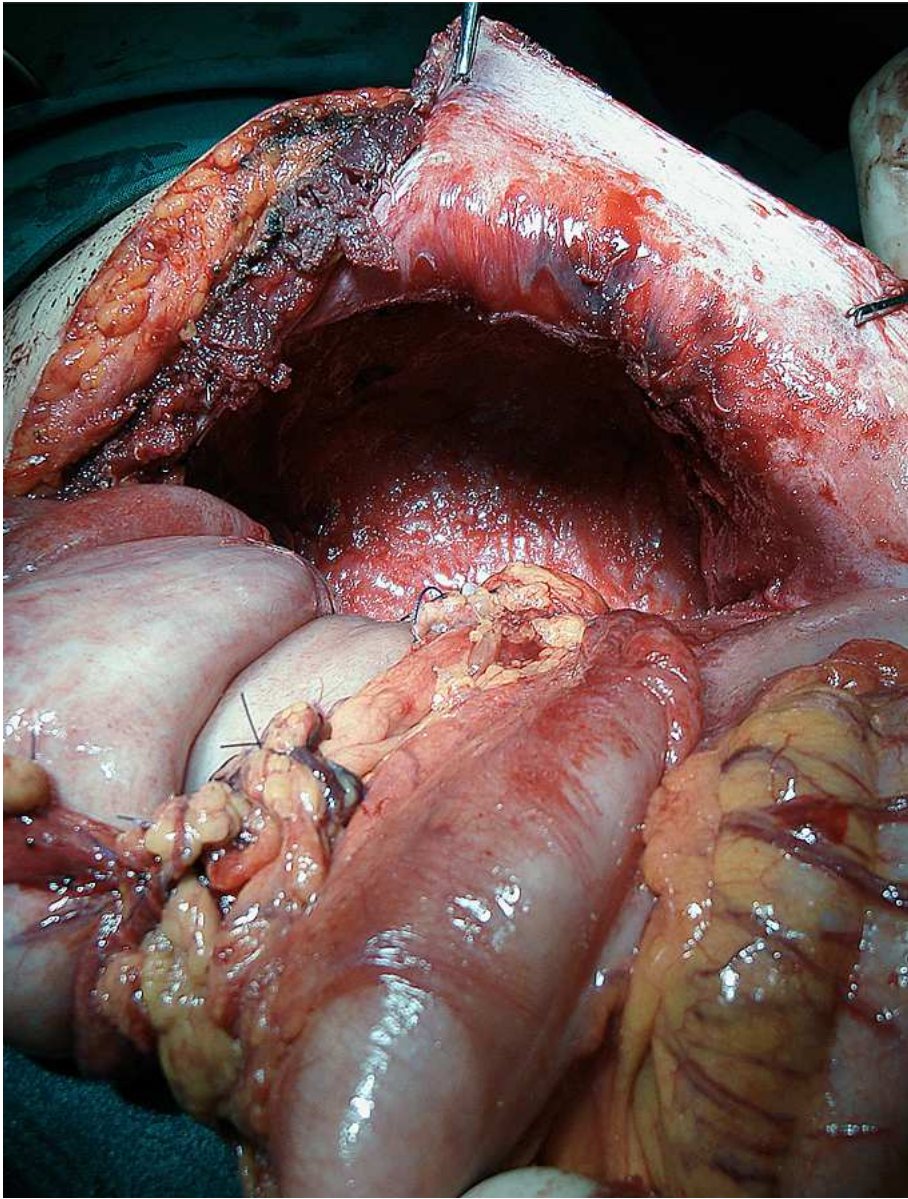
Splenectomia per pseudocisti della milza

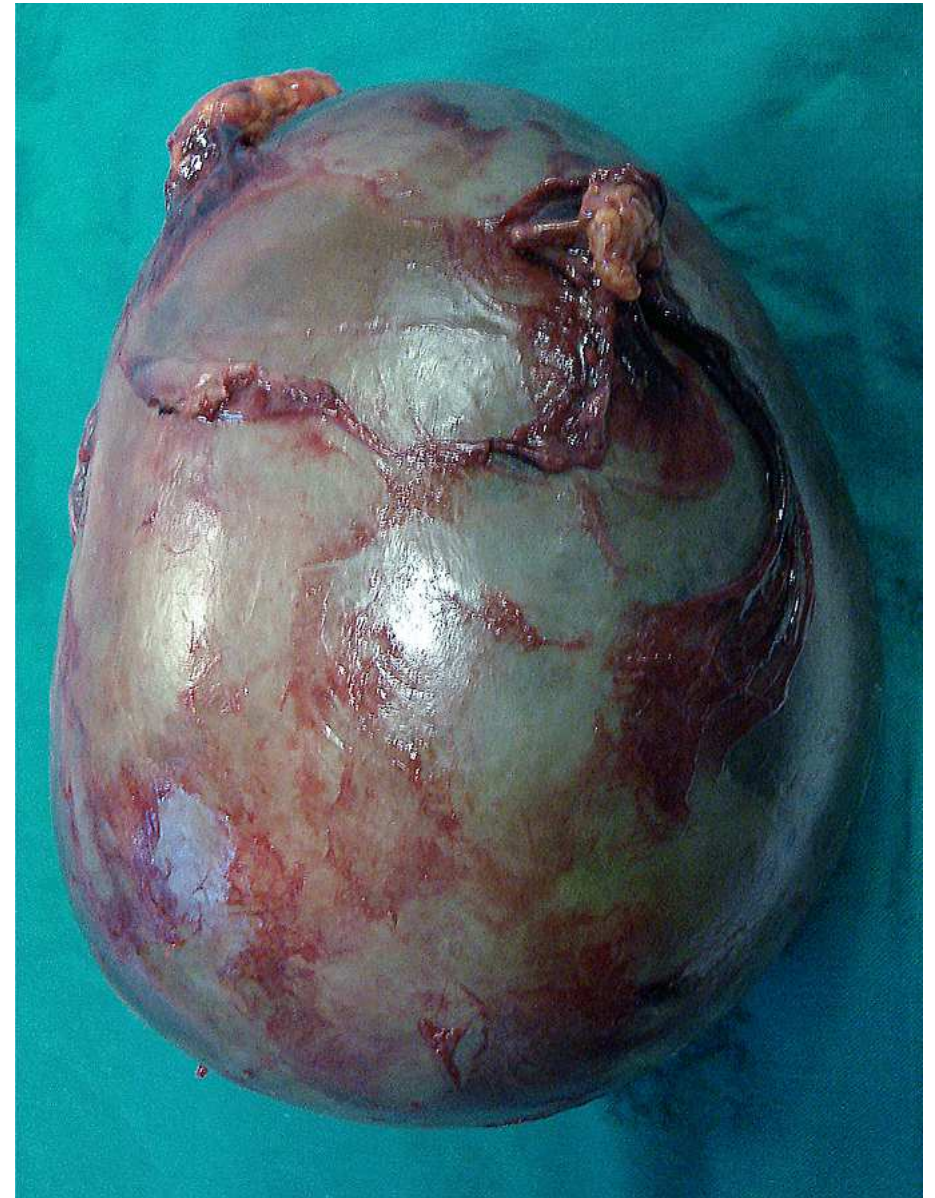
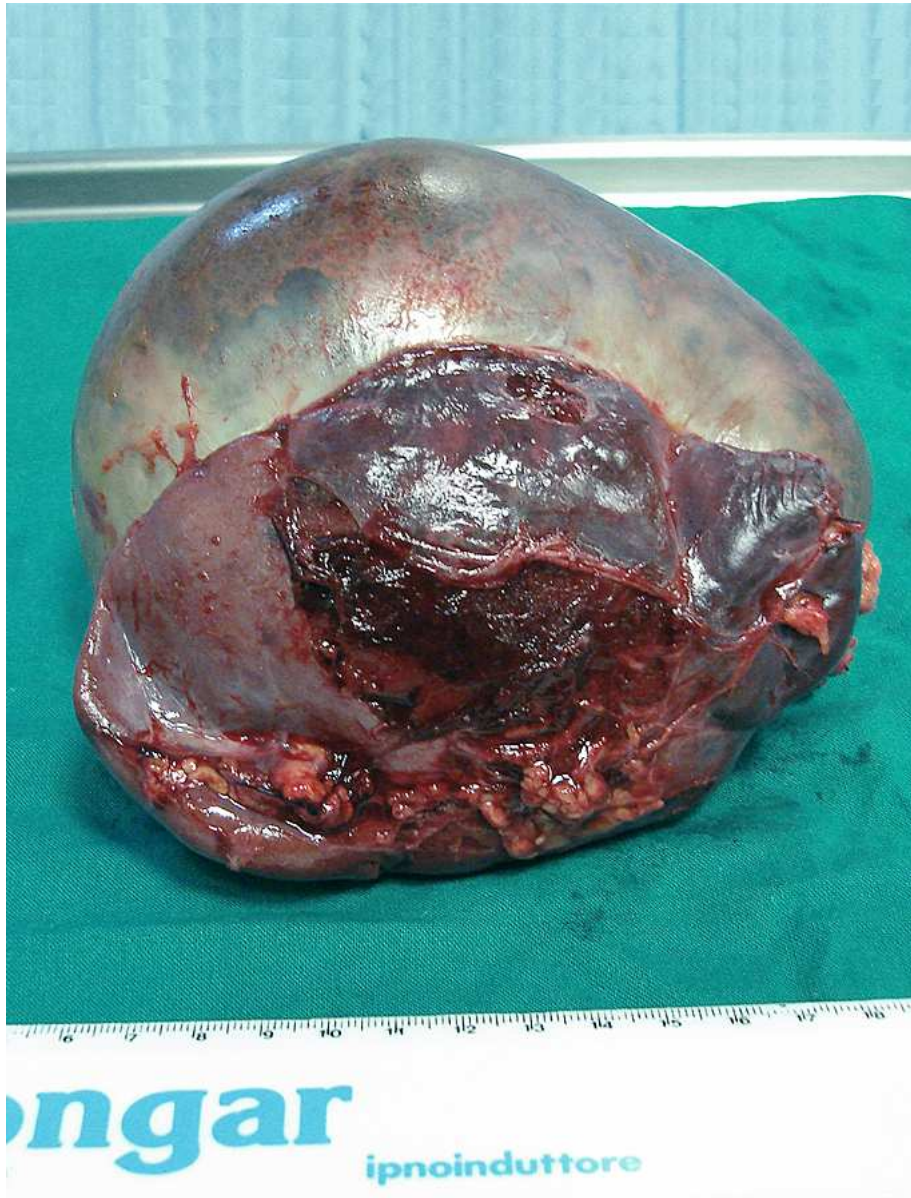

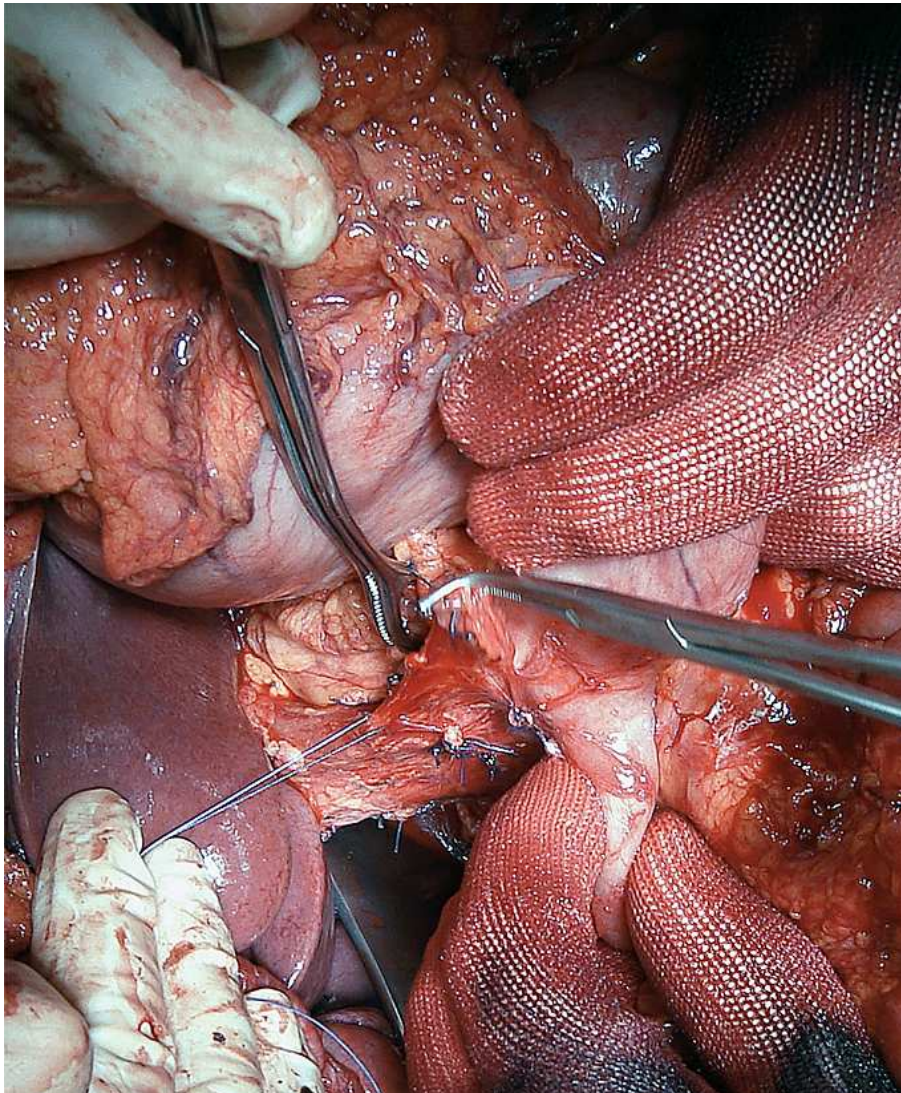






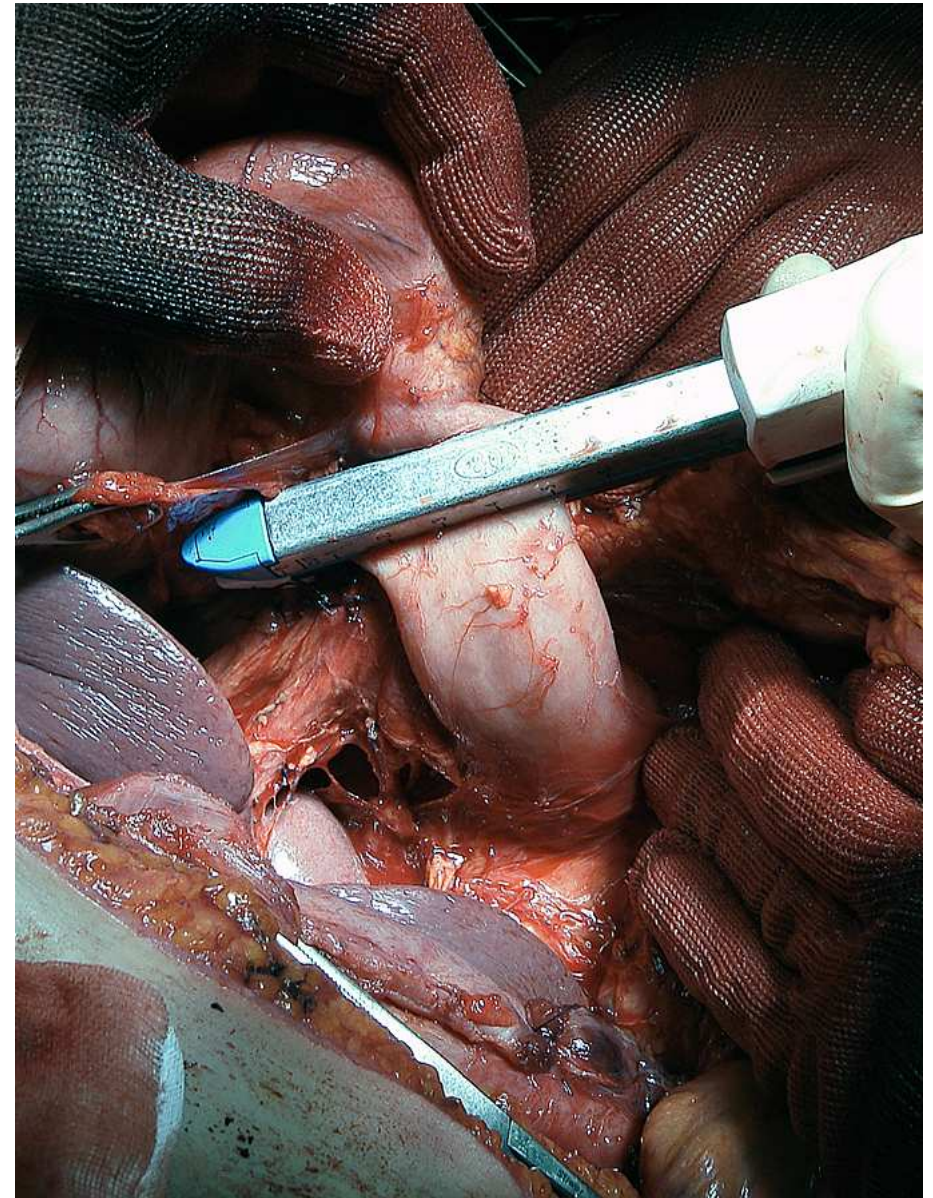




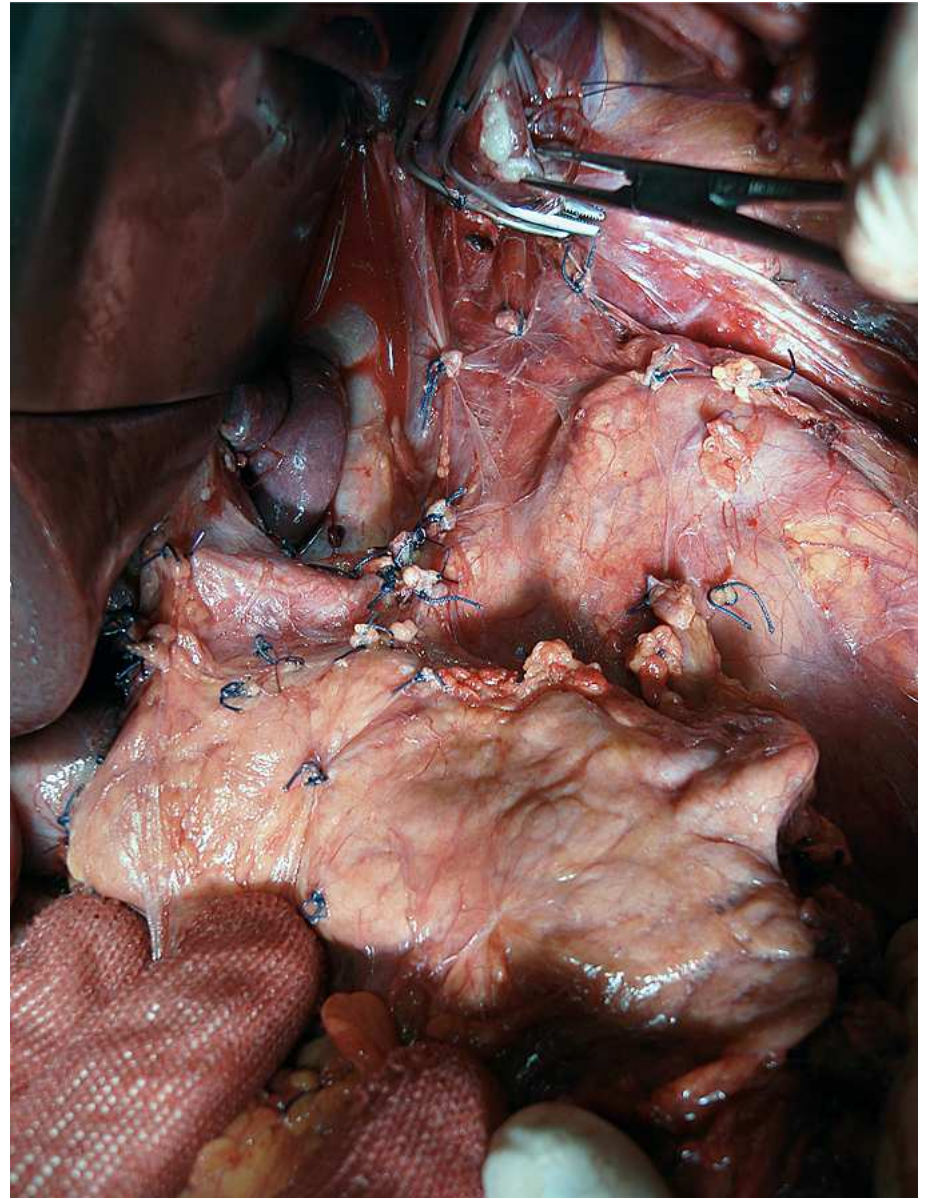
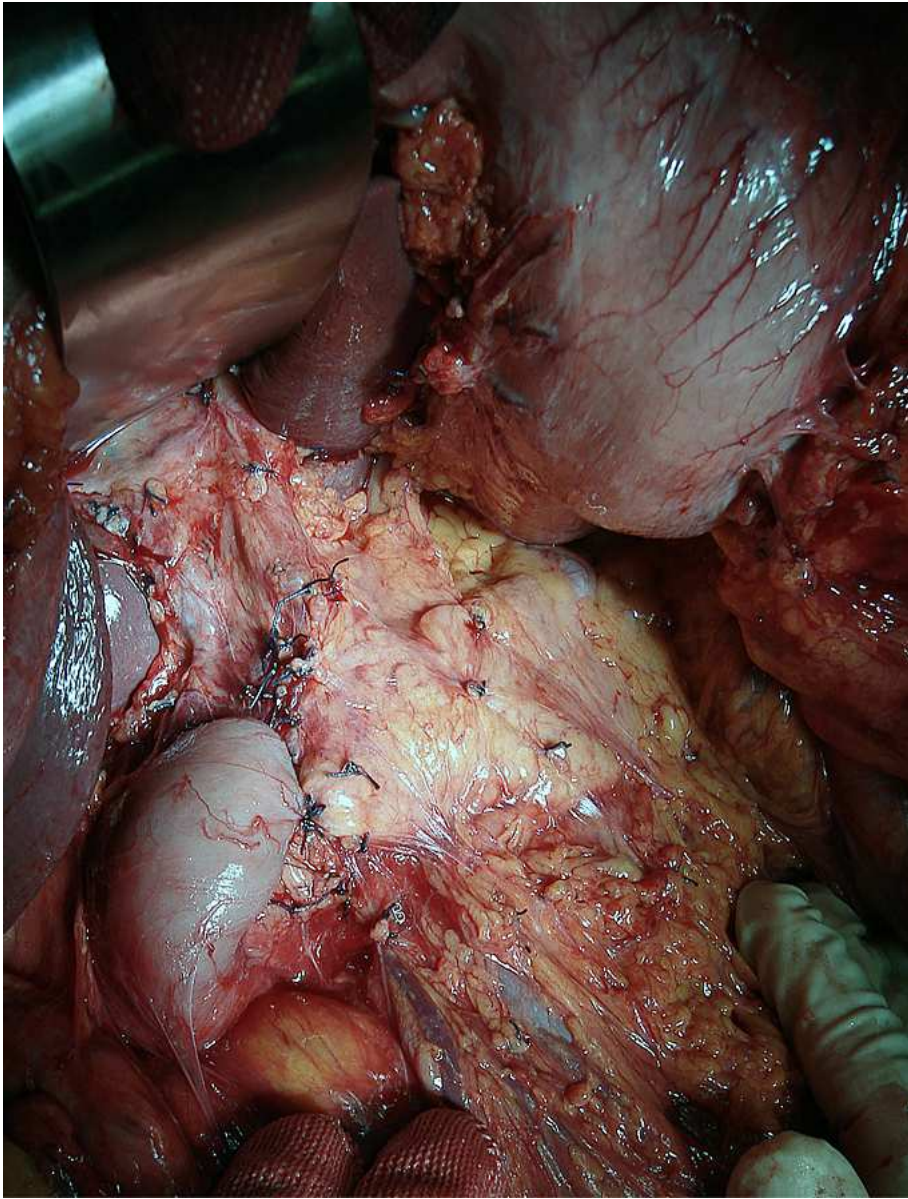


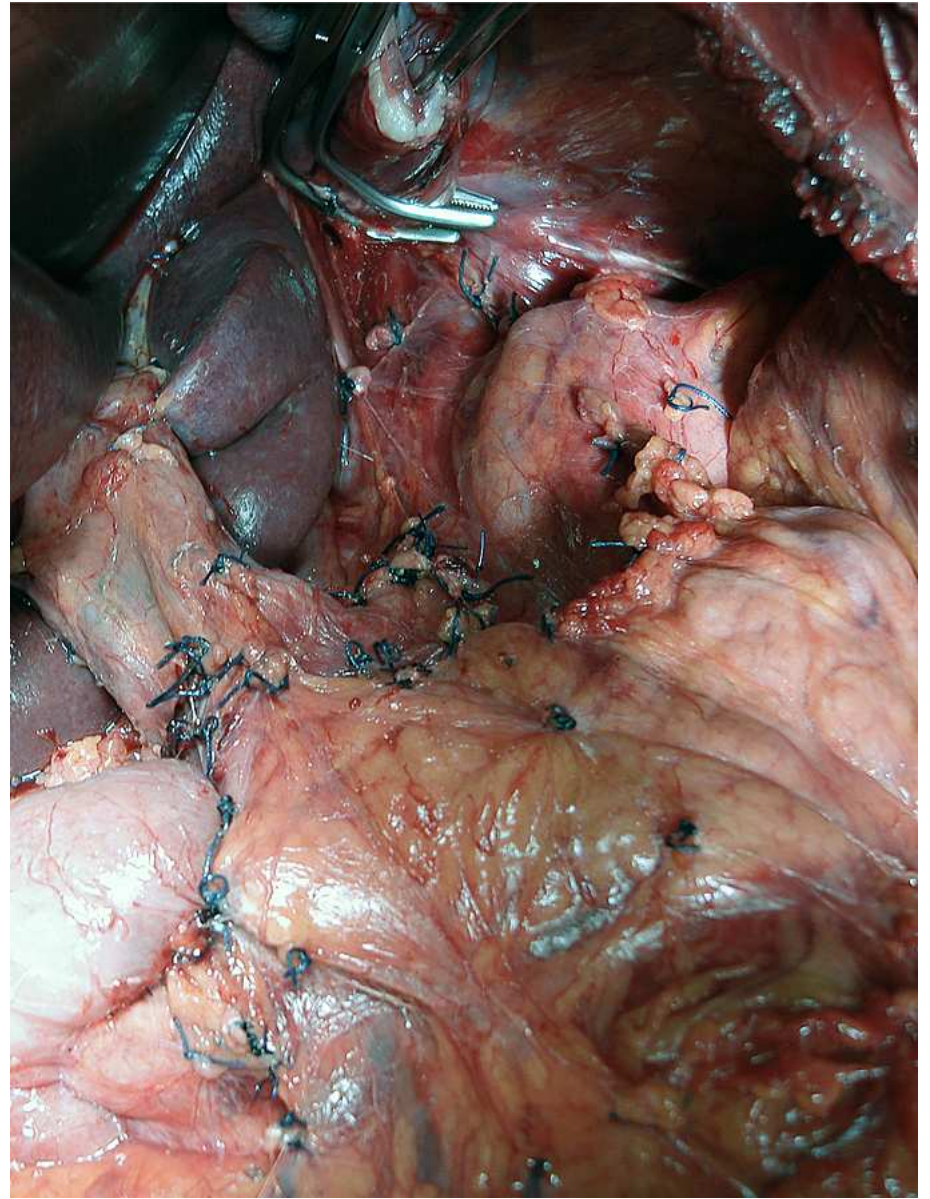
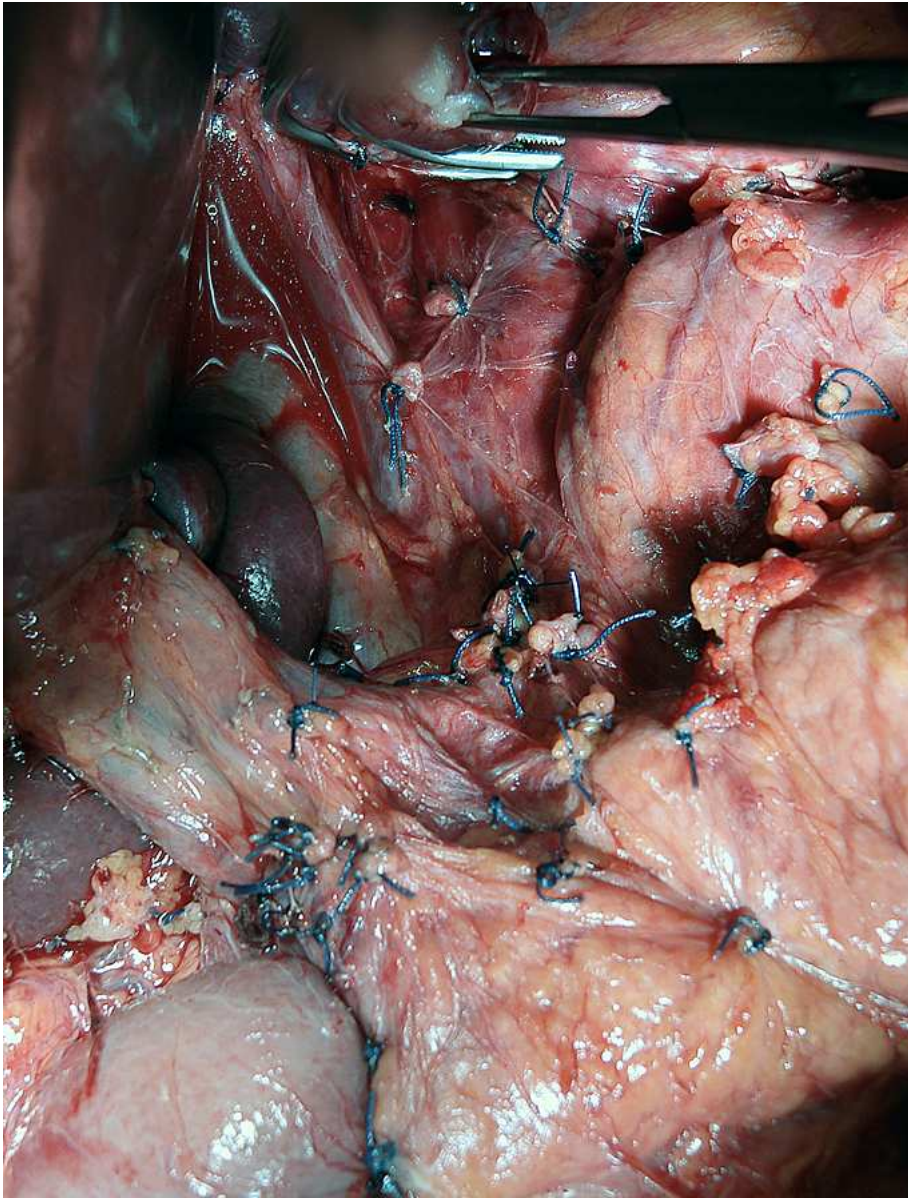
I.M.R. • Anni: 55 - F • Record: 14 • 22-02-2007

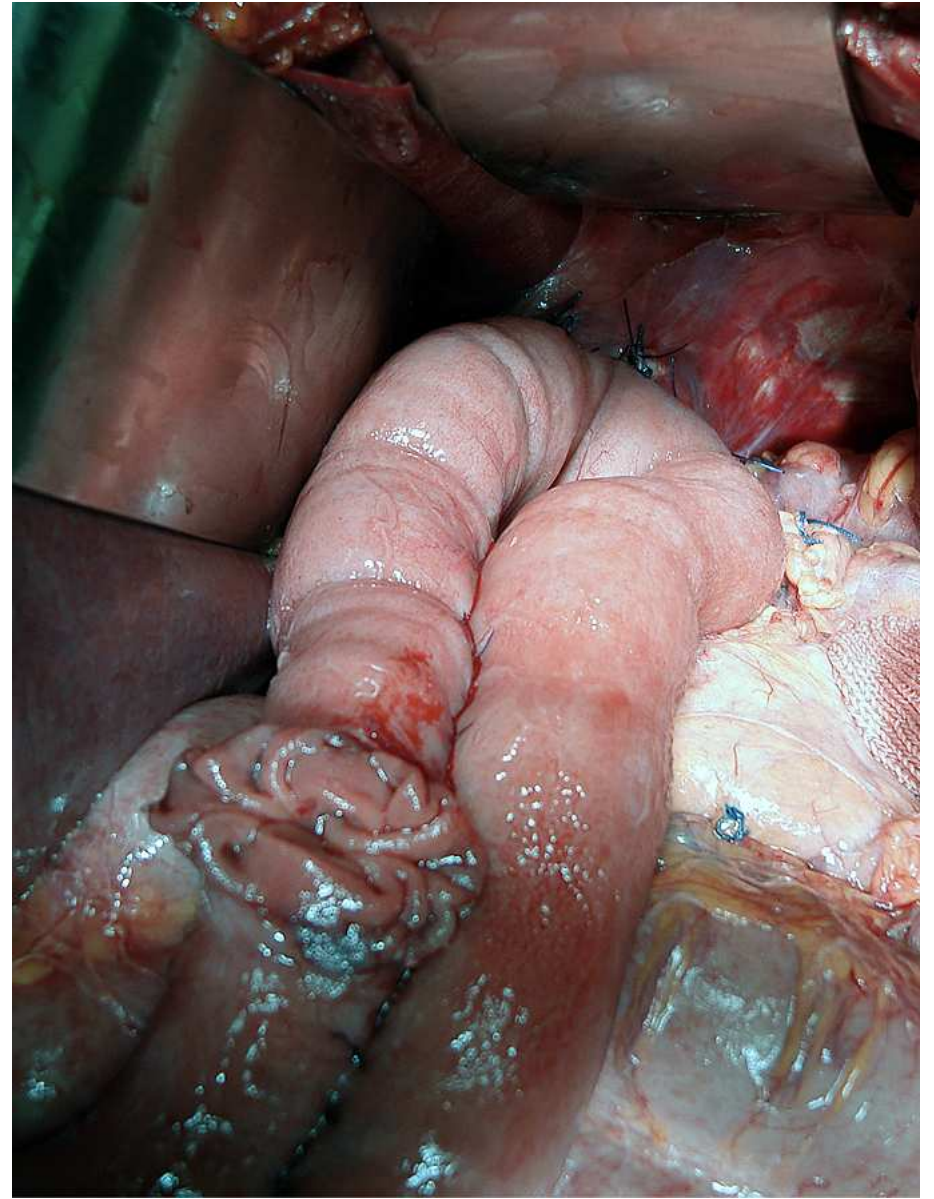
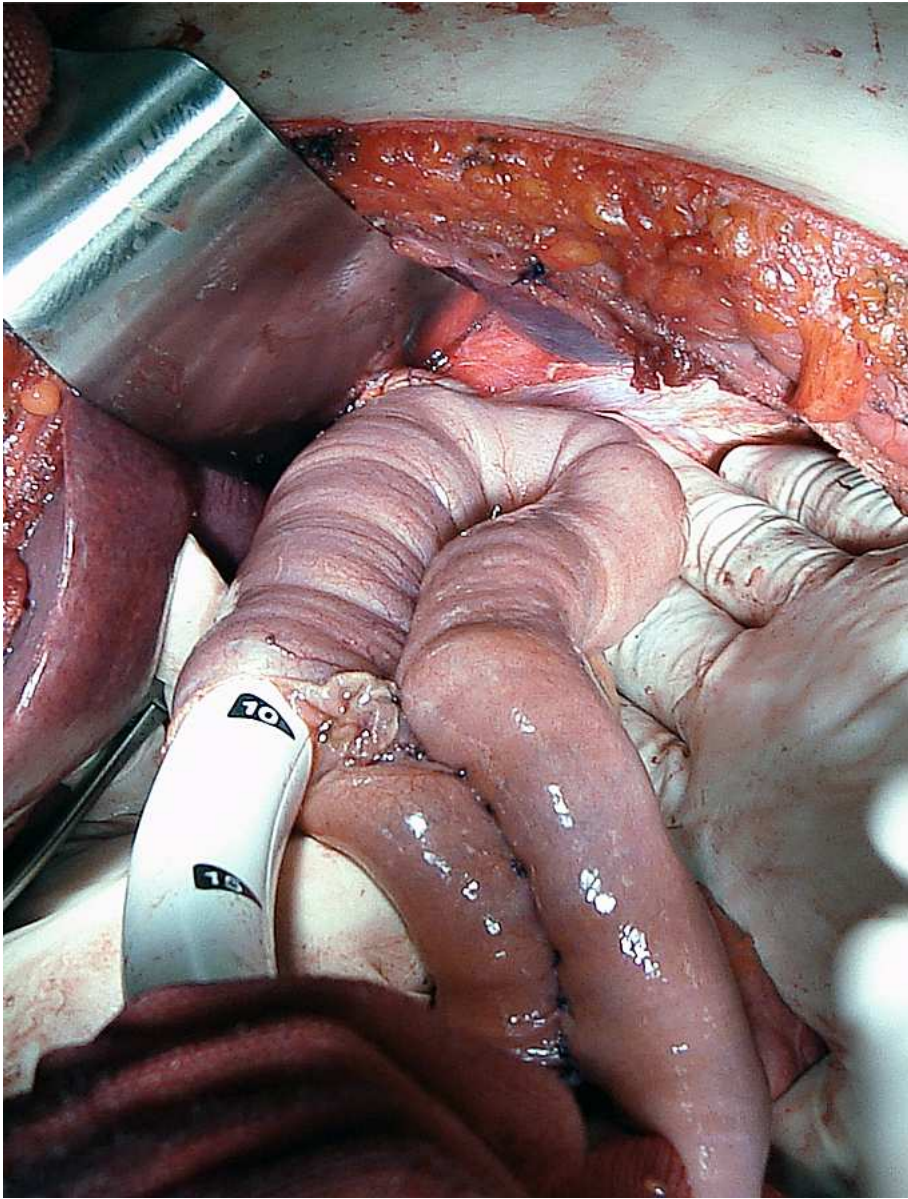
Gastrectomia totale allargata sec. Lortat-Jacob con splenectomia, epiploiectomia, linfadenectomia N3 e colecistectomia con esofagodigunostomia sec. Lahey e reservoir sec. Hoffmann per linite plastica

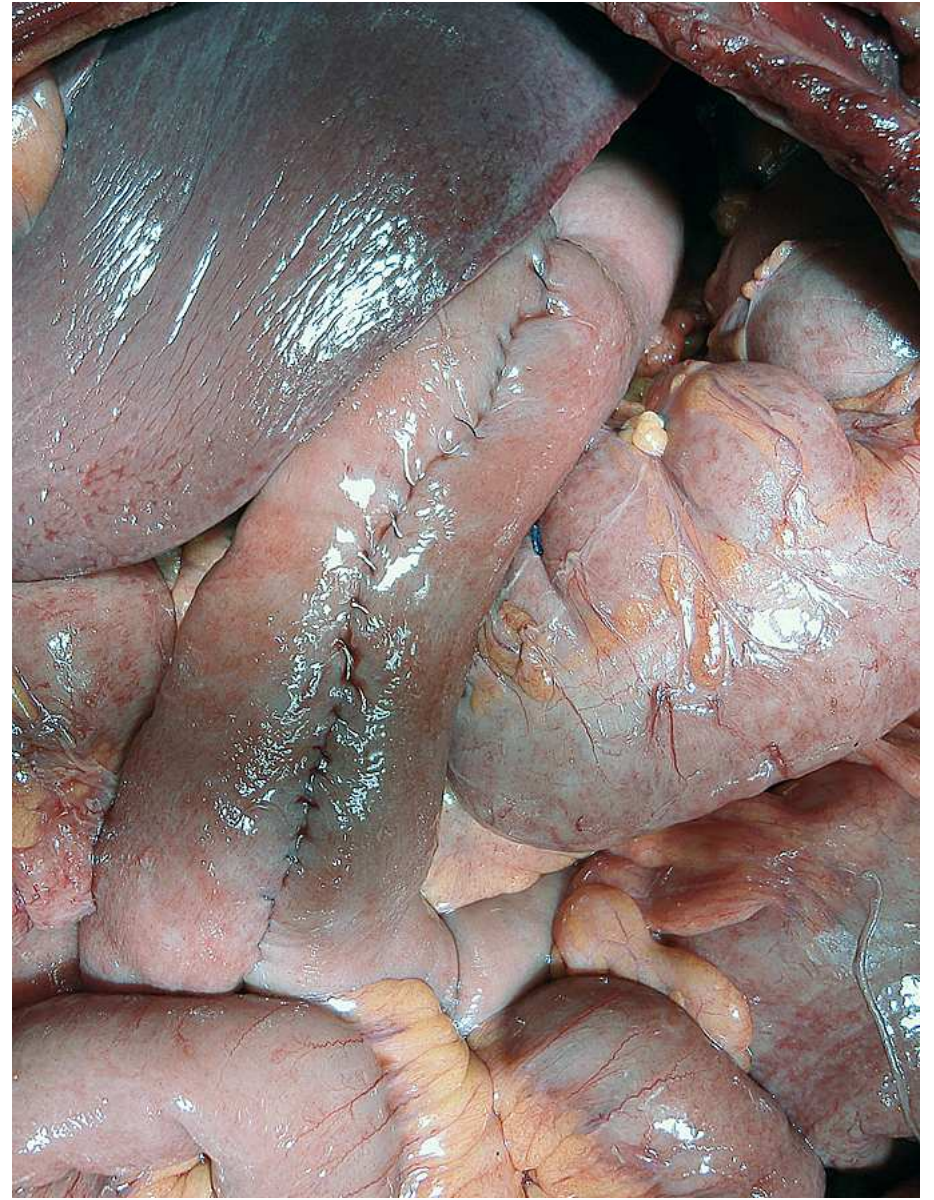
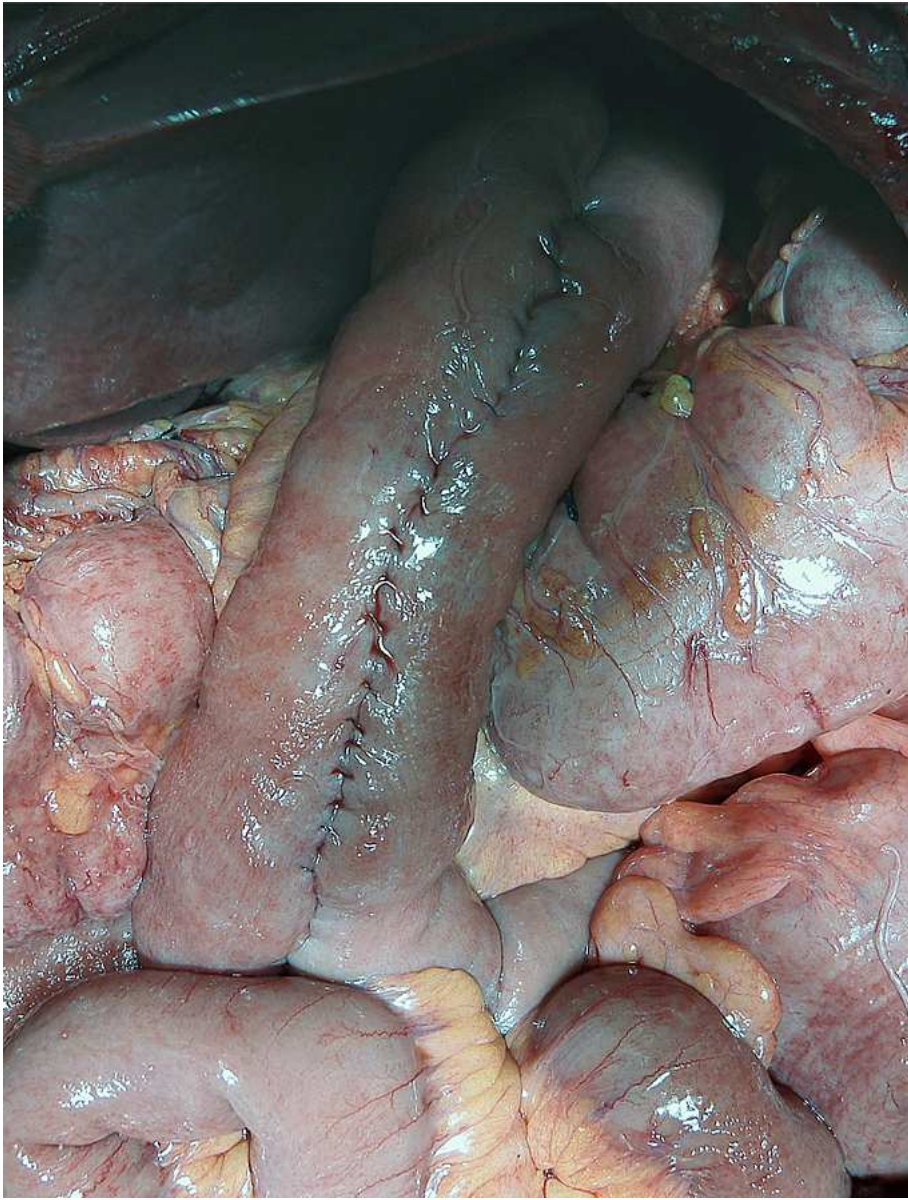
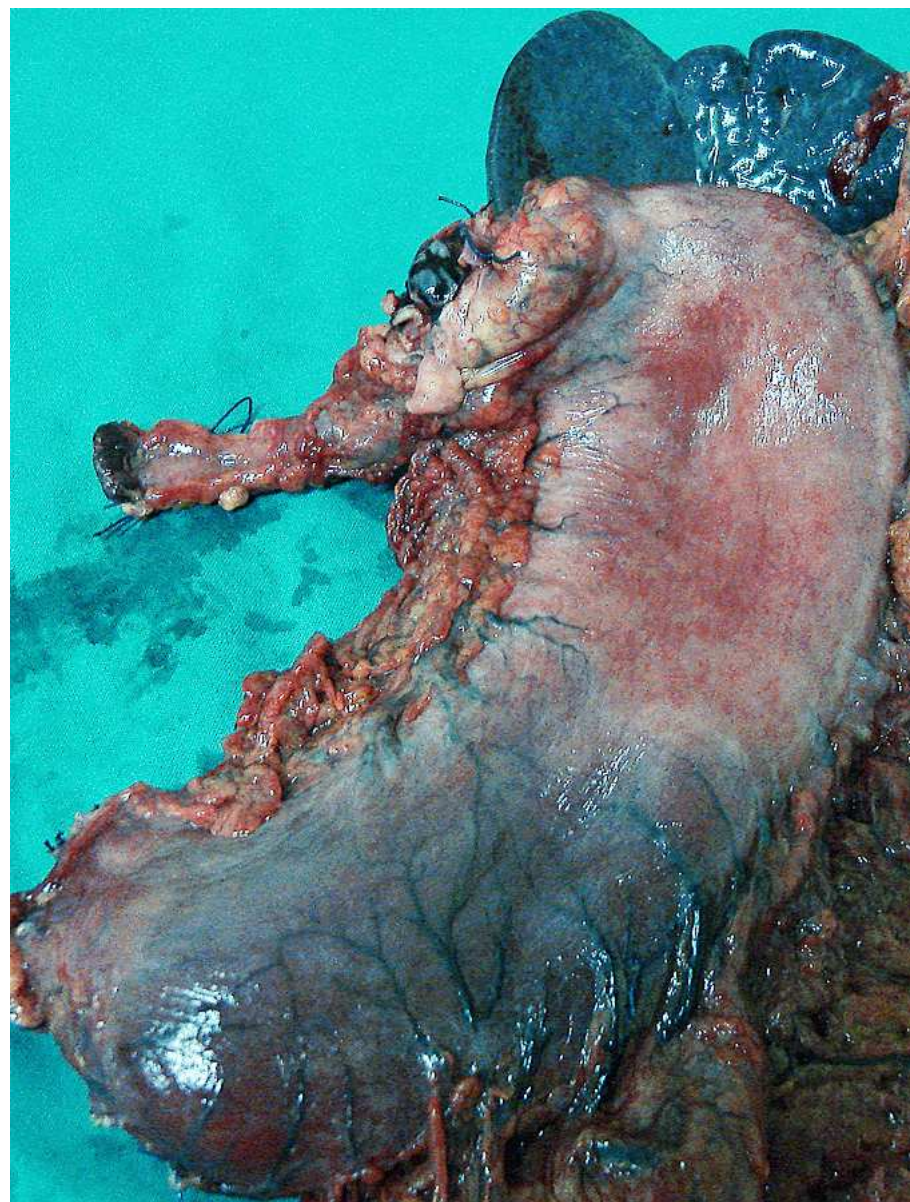


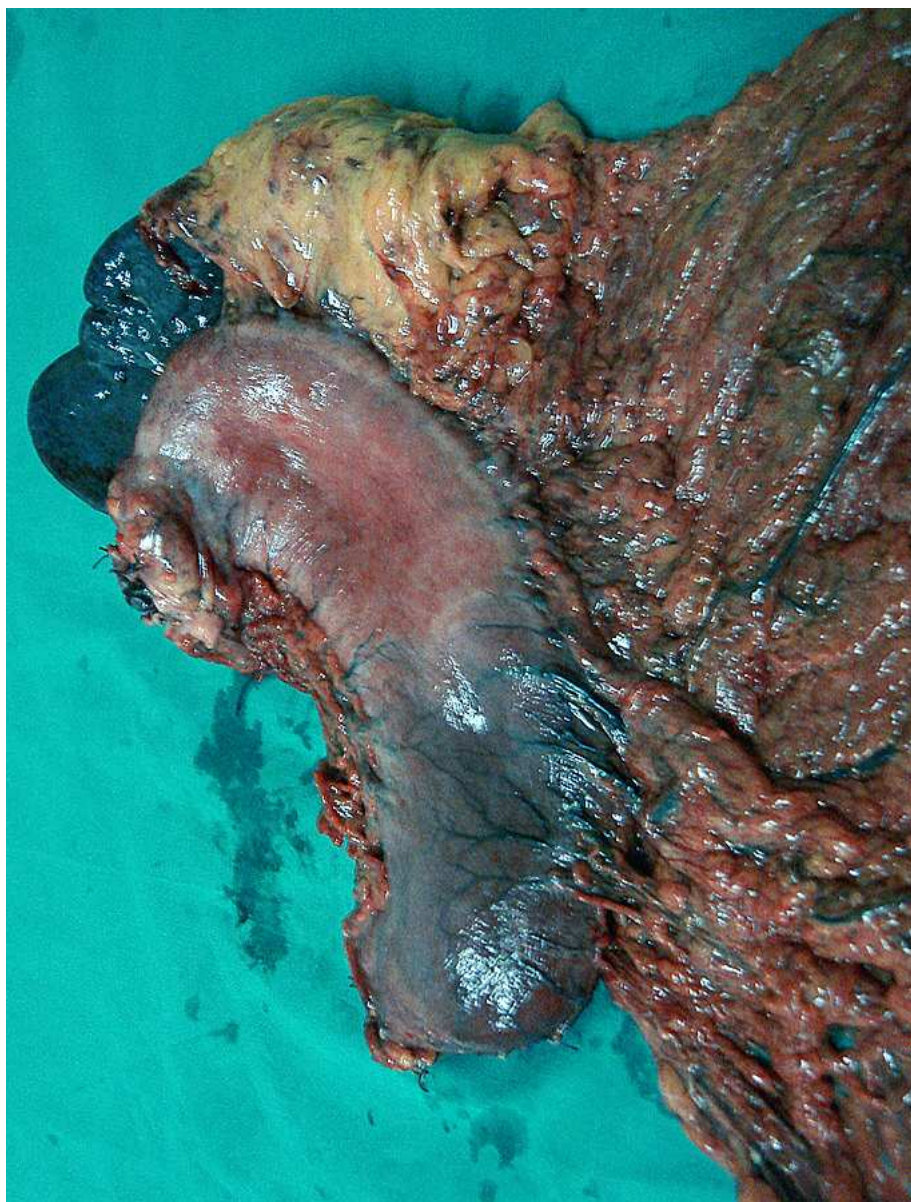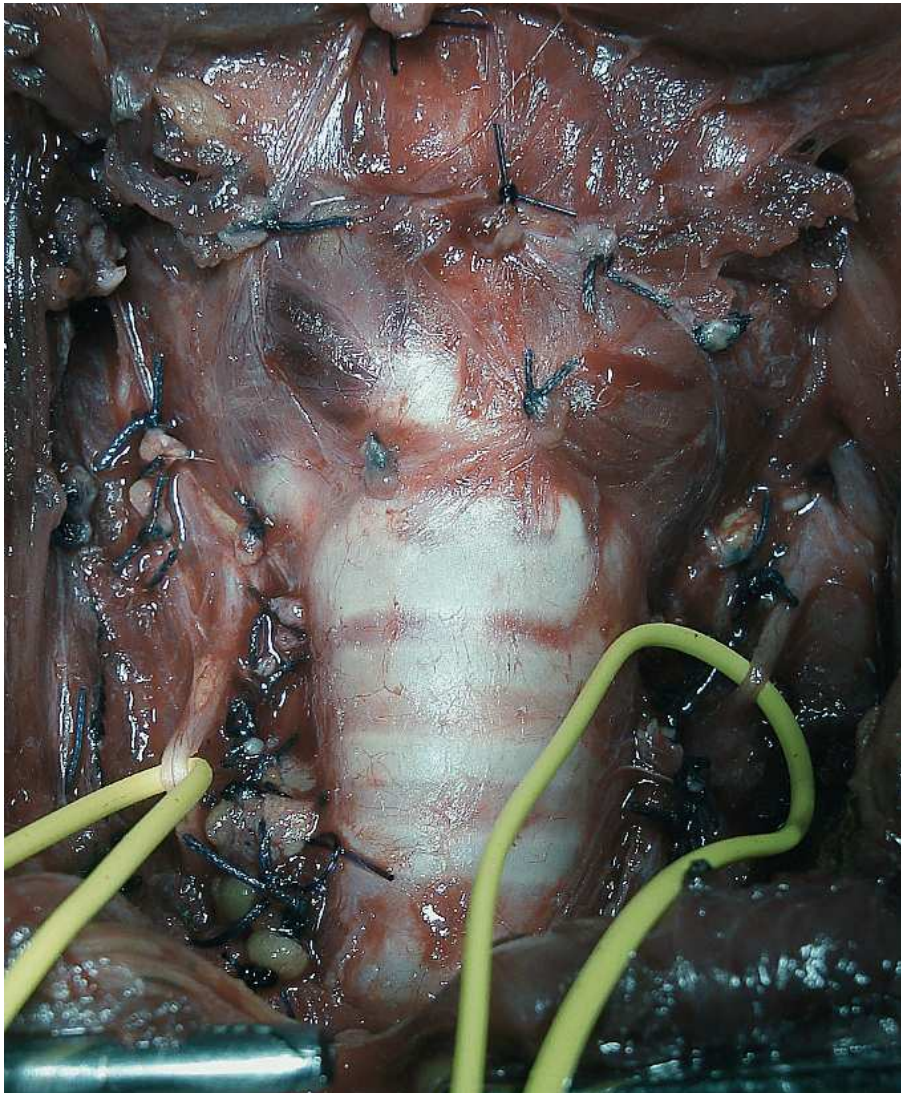






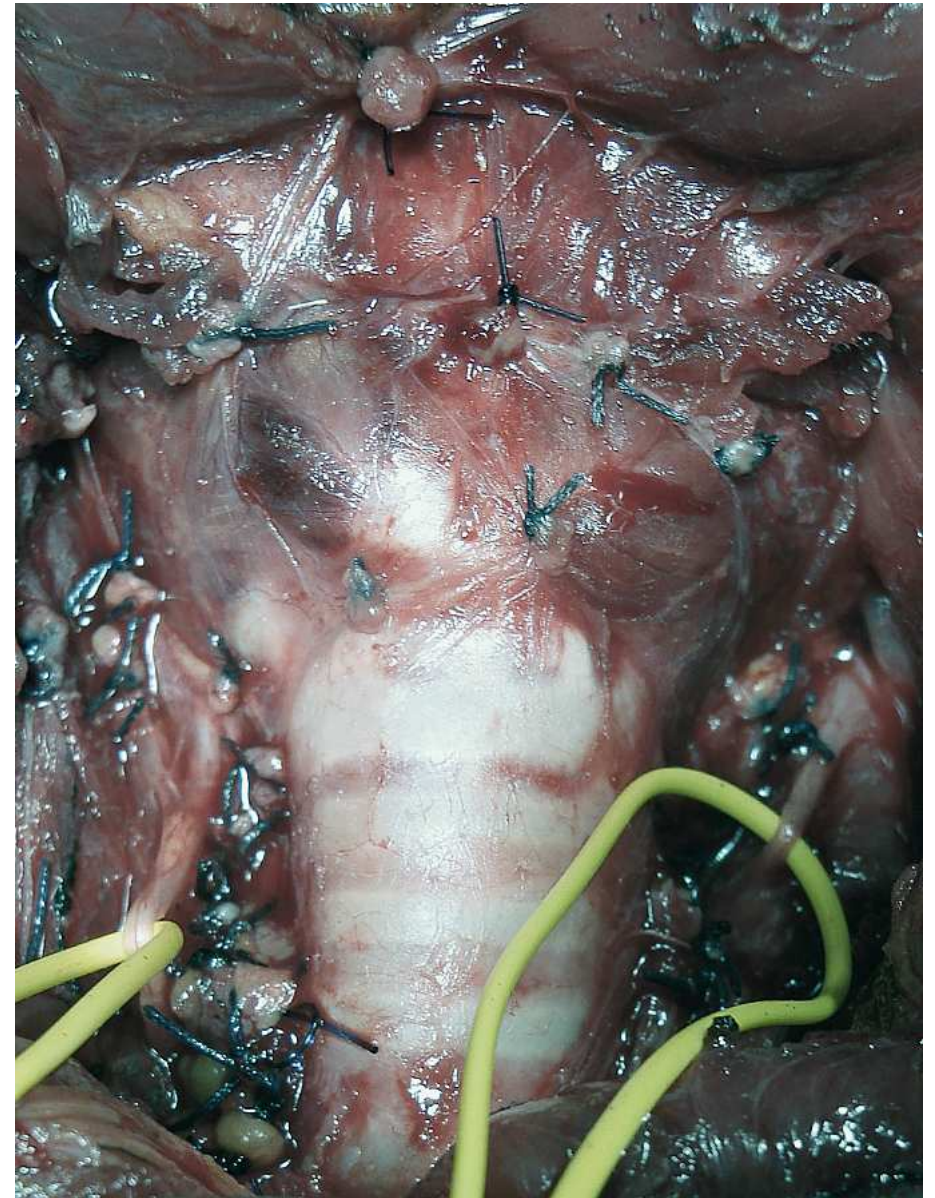






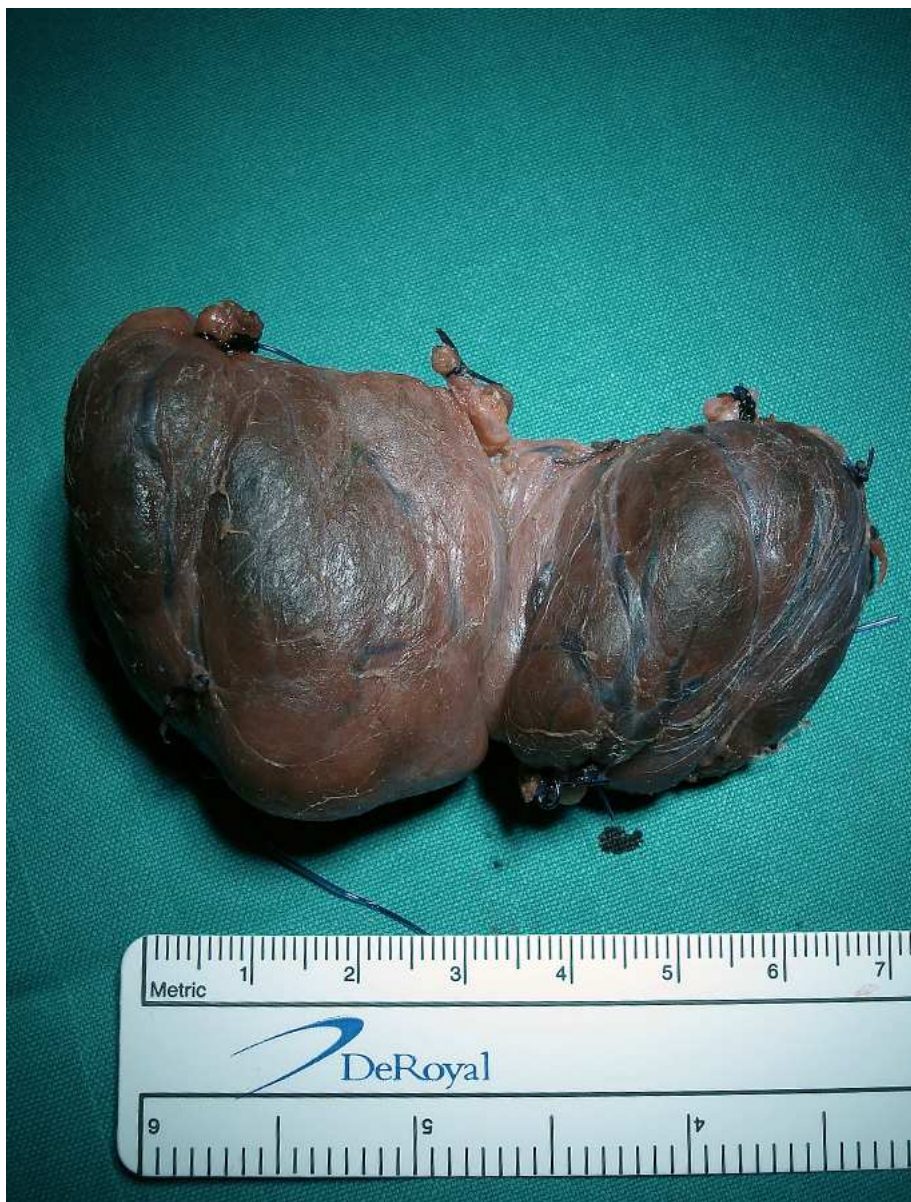S.M. • Anni: 59 - F • Record: 15 • 15-03-2007

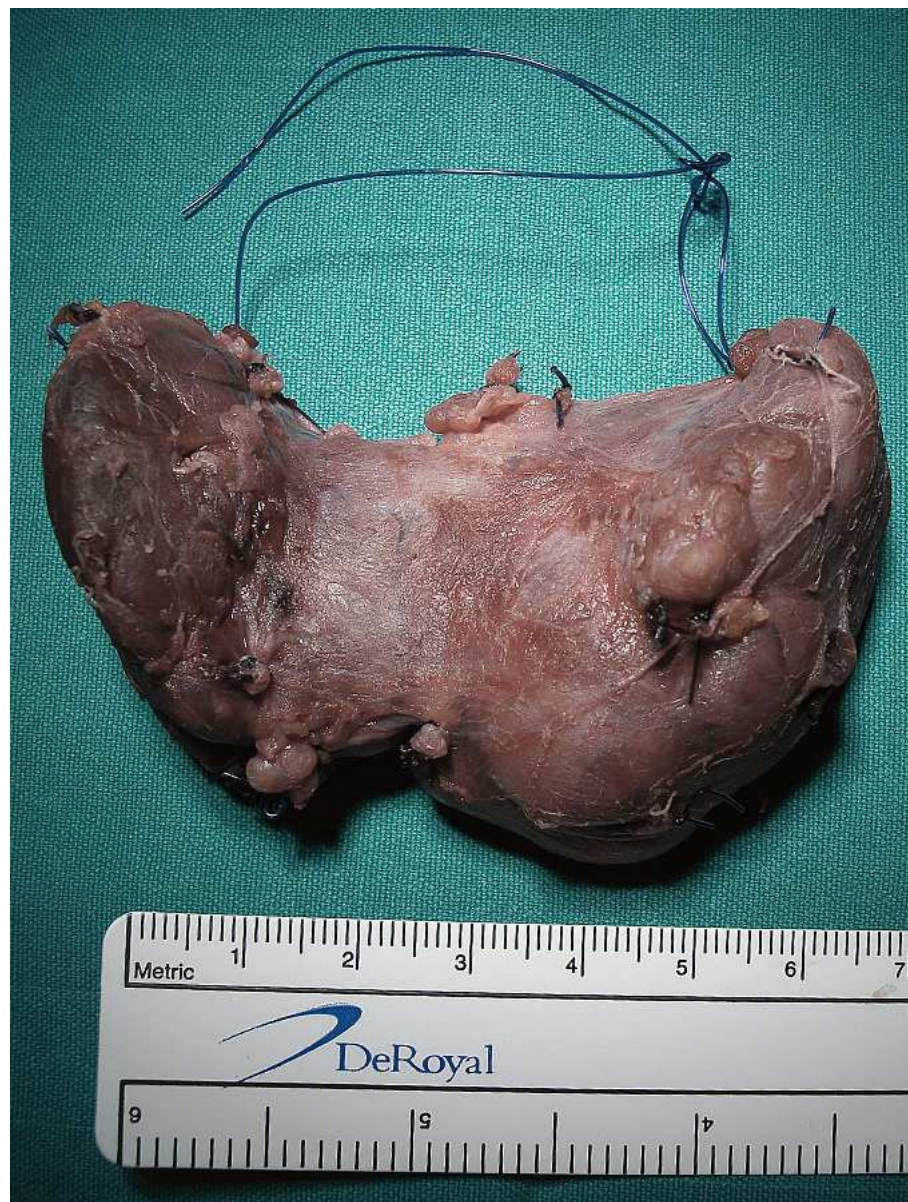Tiroidectomia totale extracapsulare per adenoma follicolare del lobo dx in gozzo plurinodulare con sezione dei muscoli pretiroidei



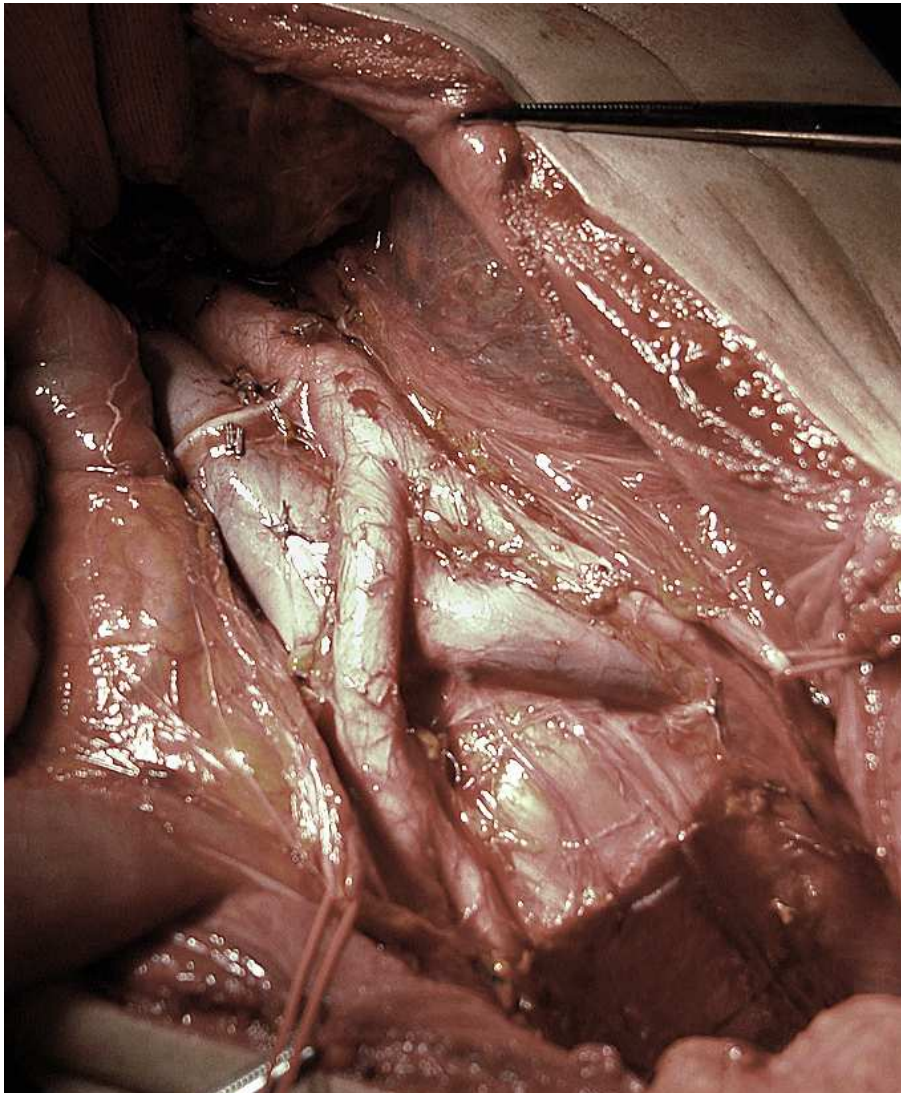
Isolamento dei nervi laringei inferiori (ricorrenti)



Lobo destro - Istmo - Lobo sinistro (superficie anteriore)

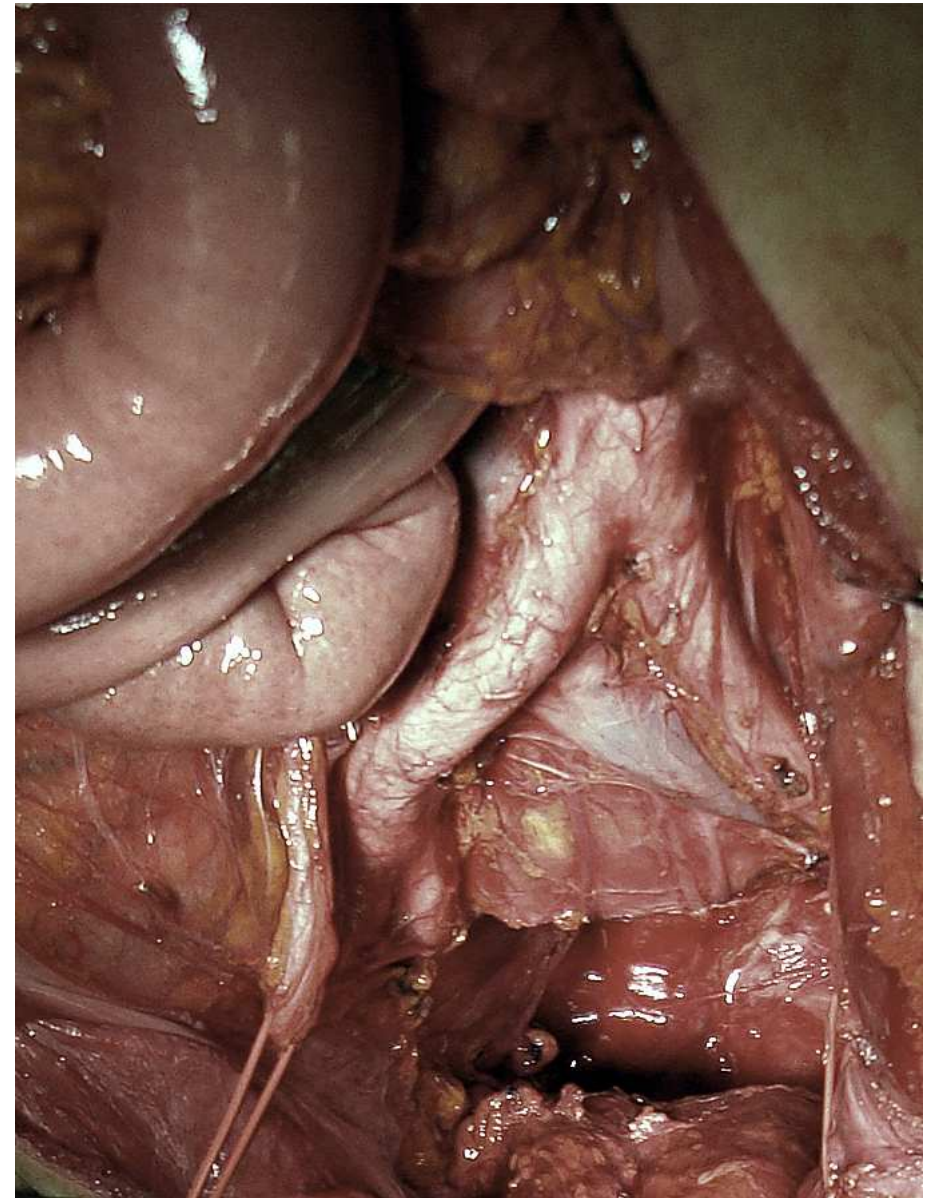


Lobo sinistro - Istmo - Lobo destro (superficie posteriore)

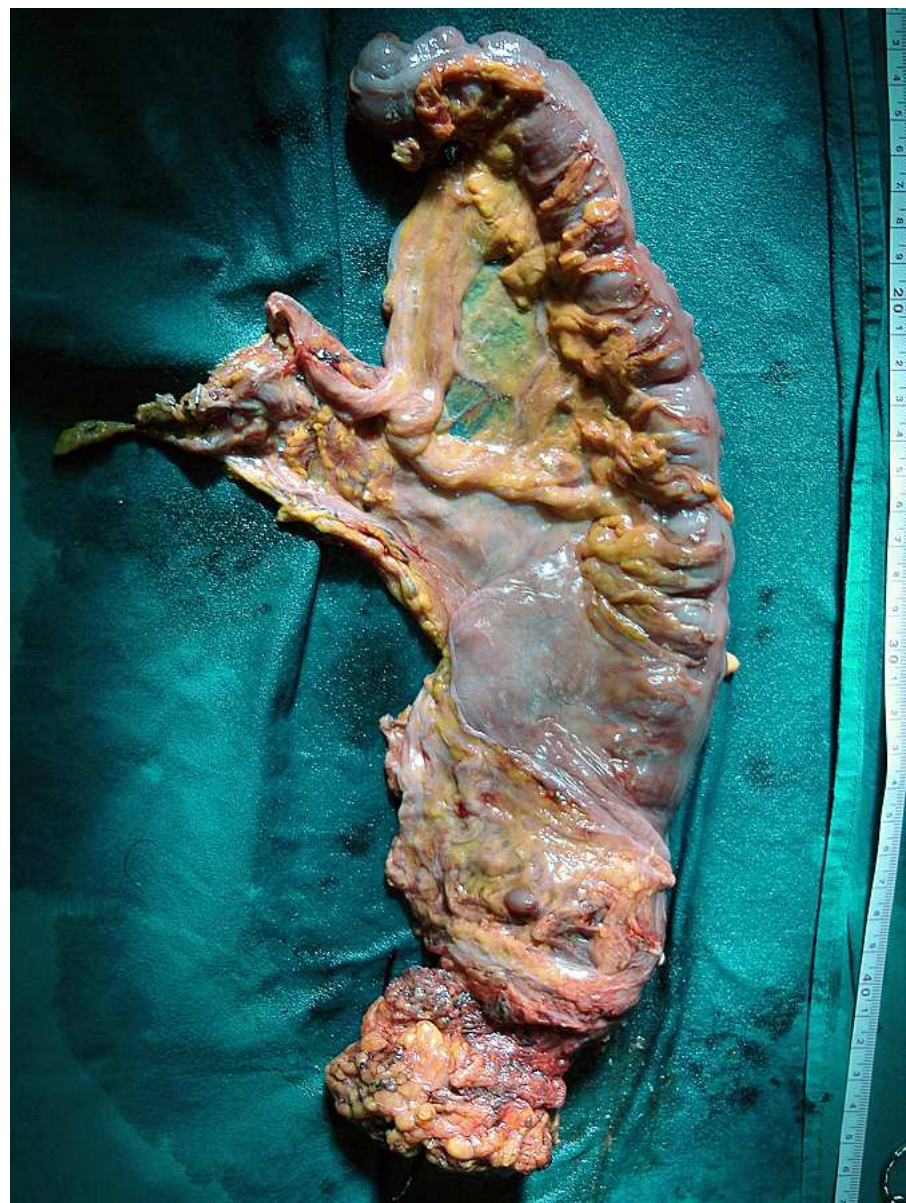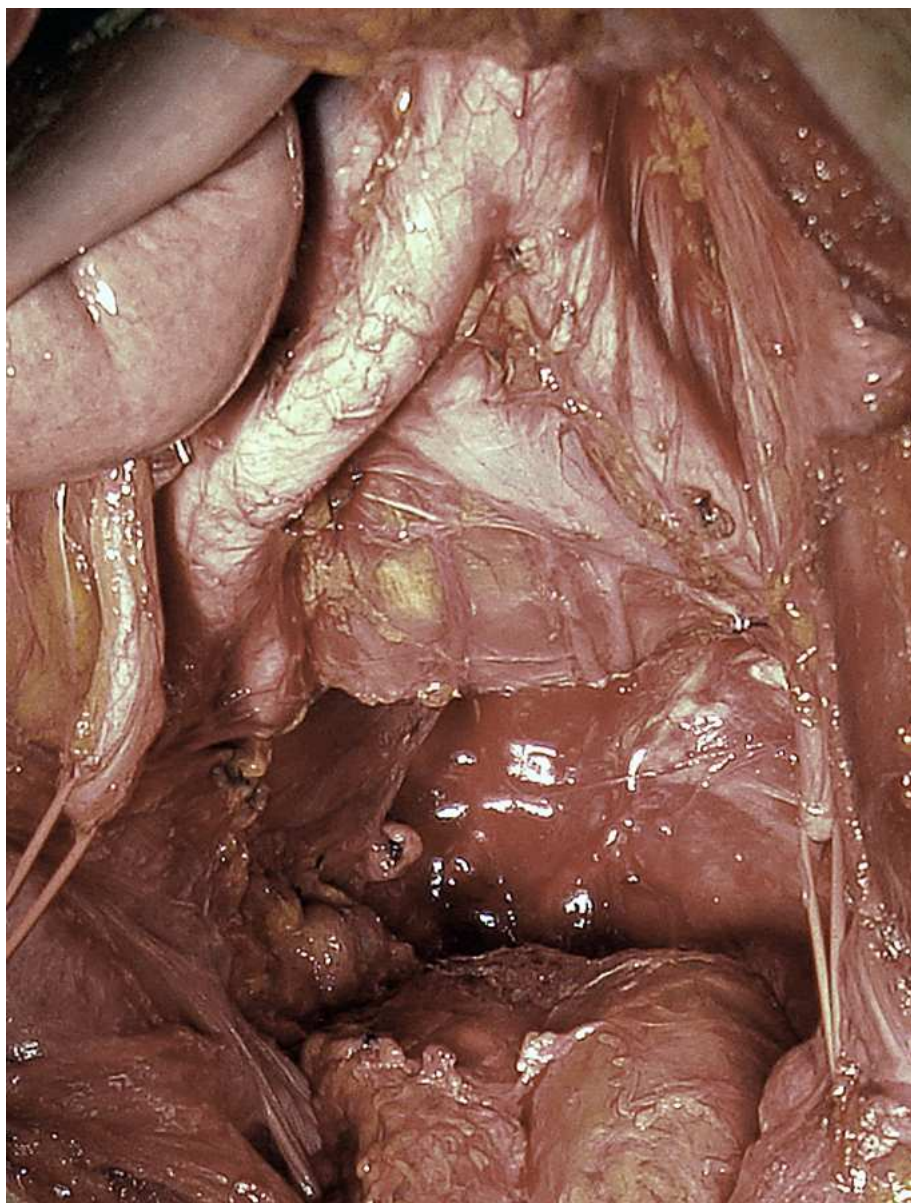


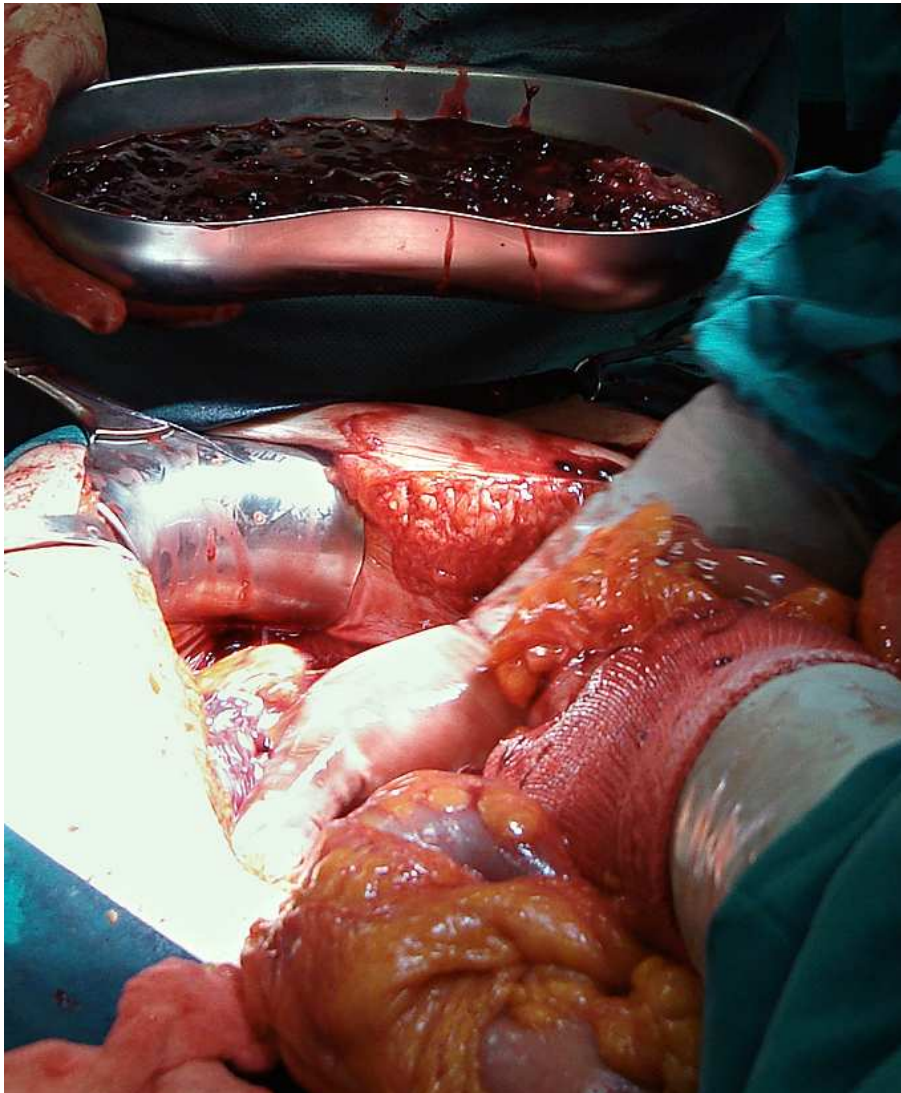
S.G. • Anni: 60 - M  Record: 16 • 22-03-2007

Amputazione del retto per via addominoperineale sec. Miles con linfoadenectomia preaortica, paraaortica sn, intercavaoartica, presacrale ed iliaca bilaterale per adenocarcinoma del retto



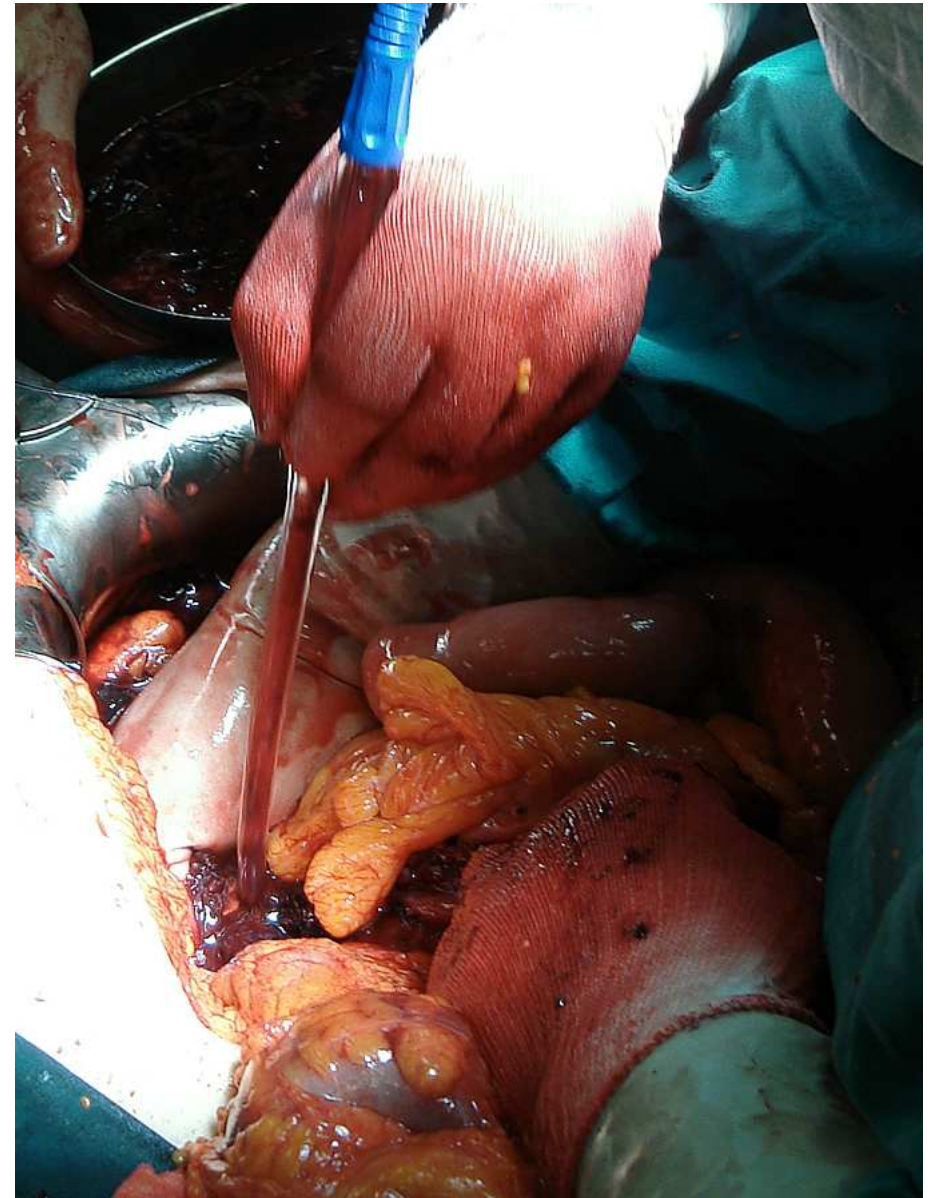


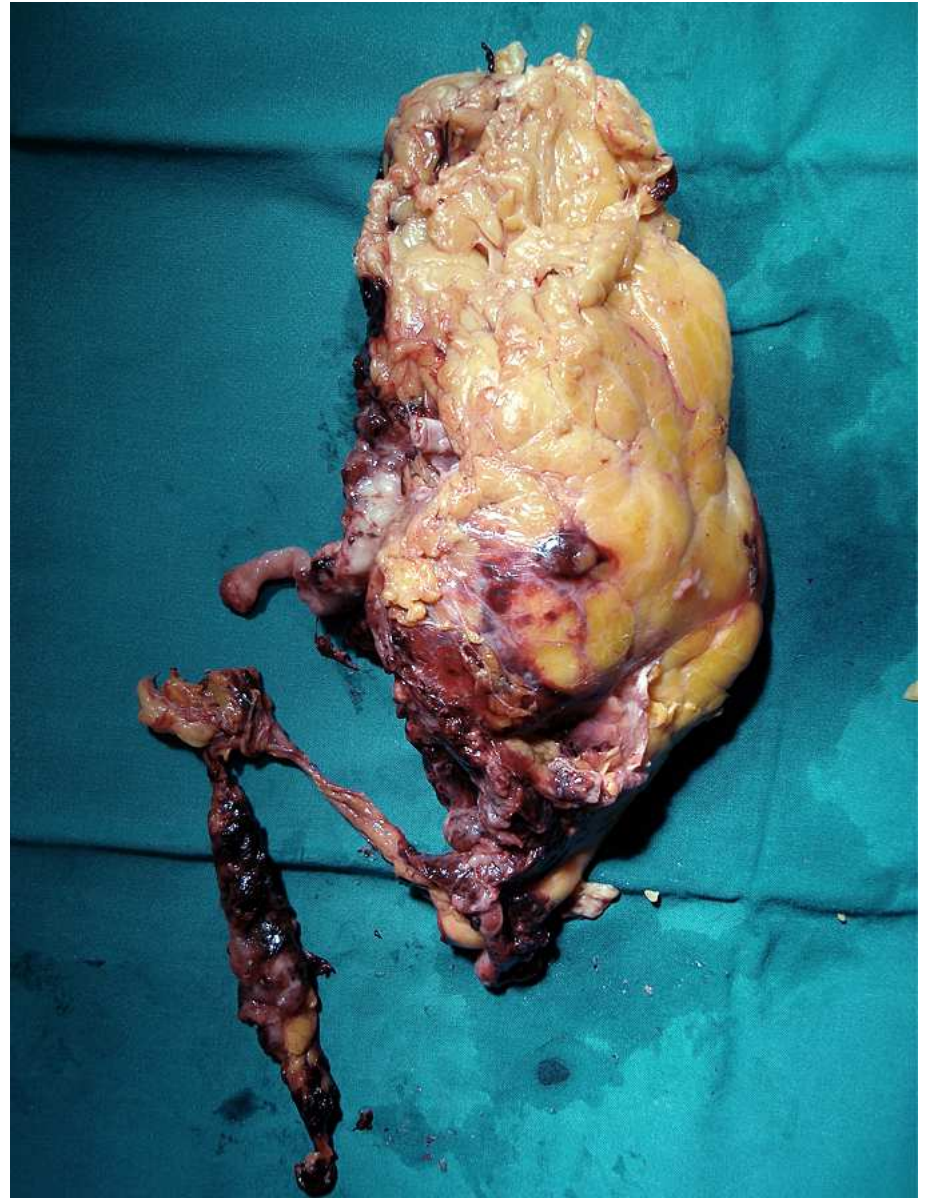
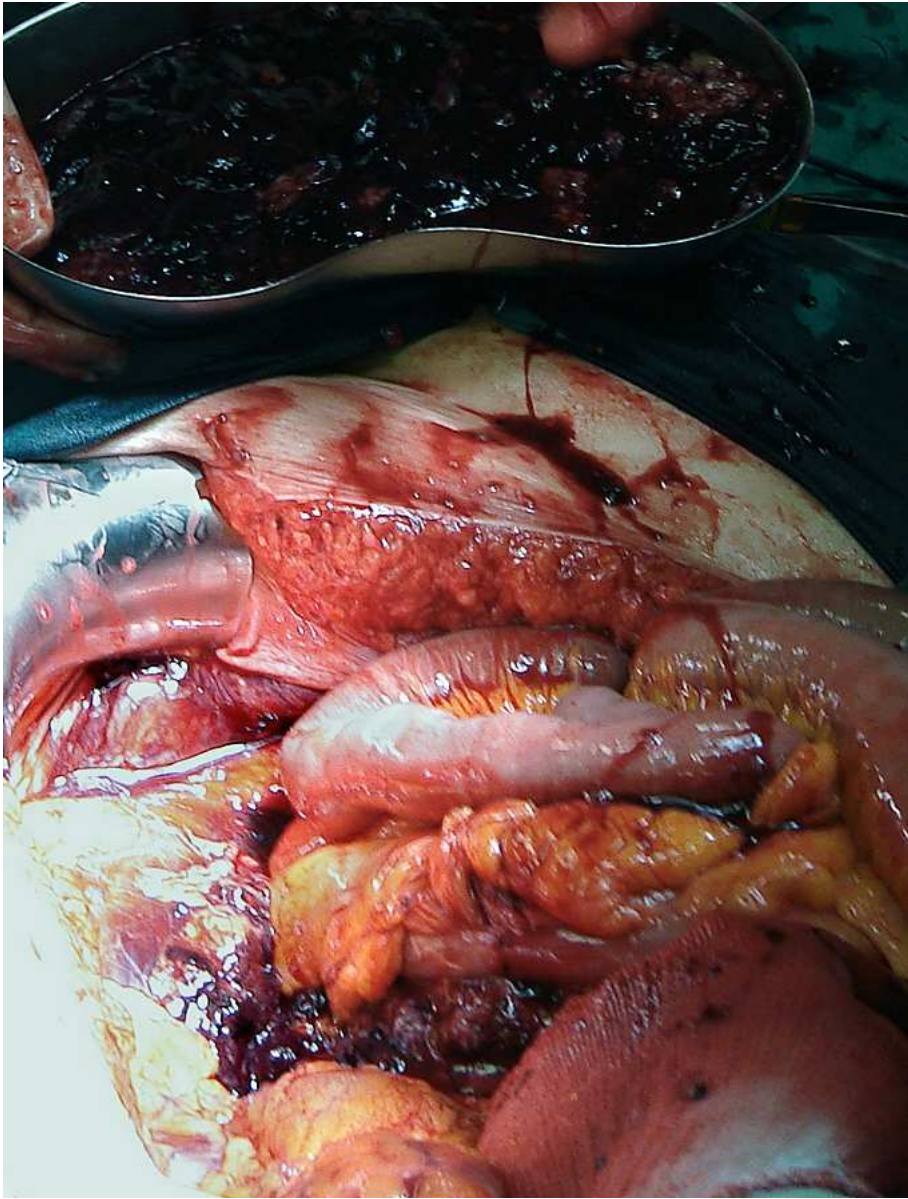

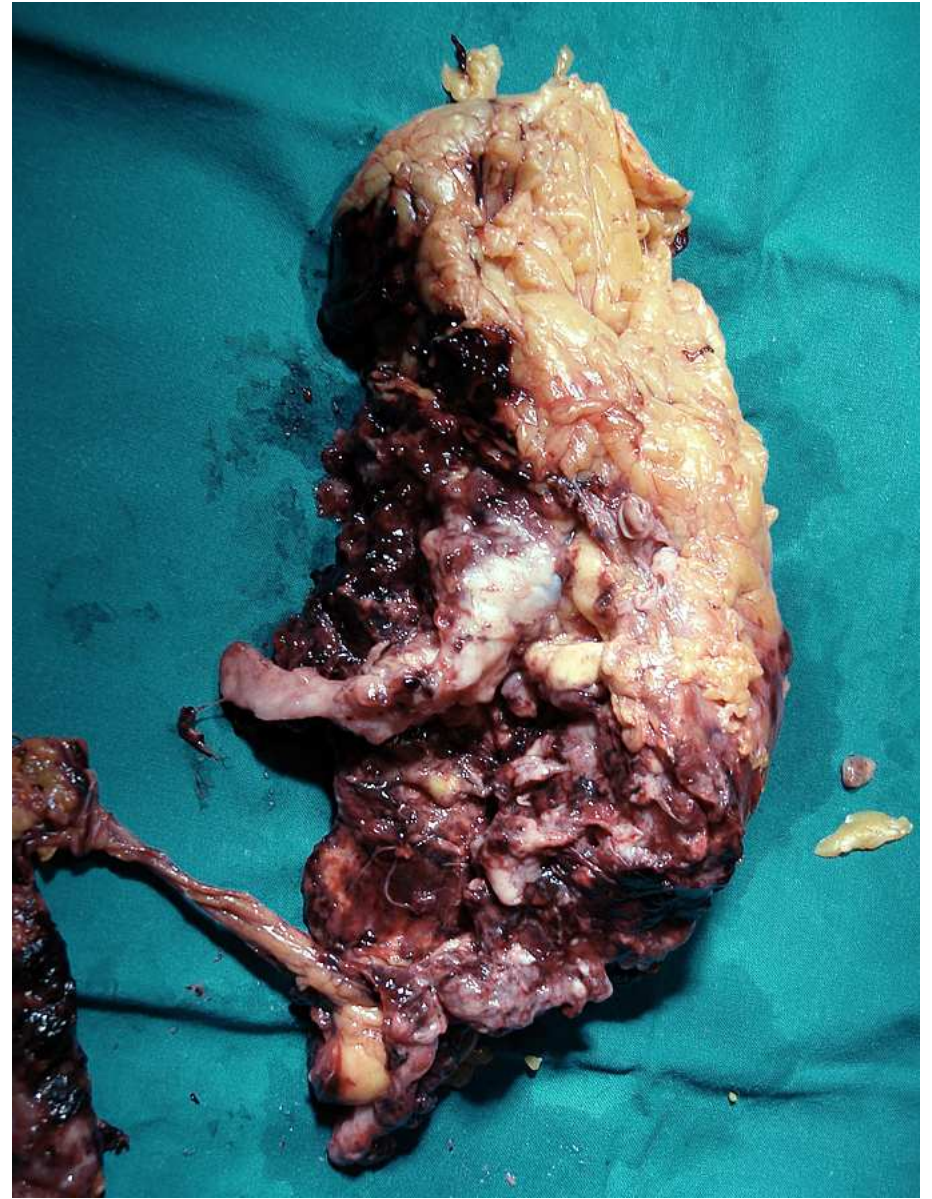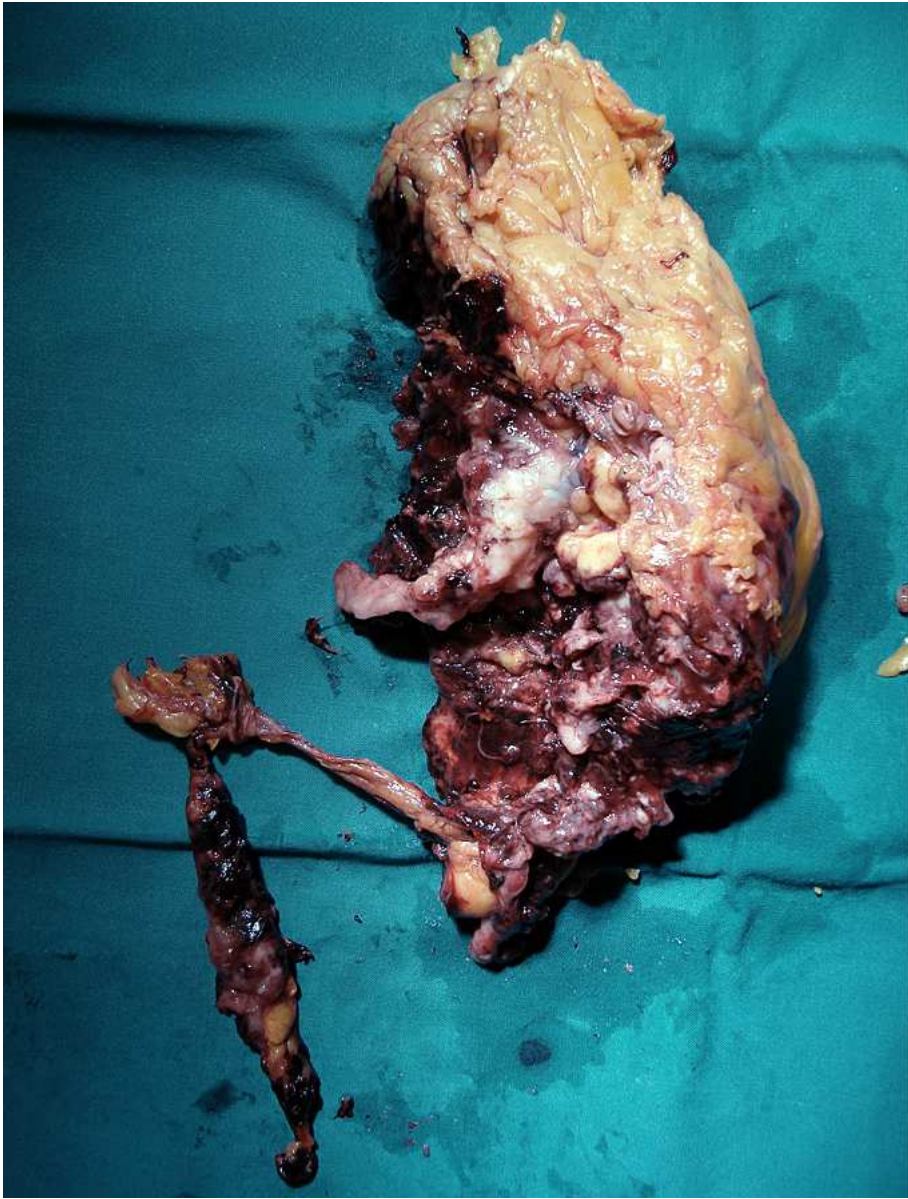


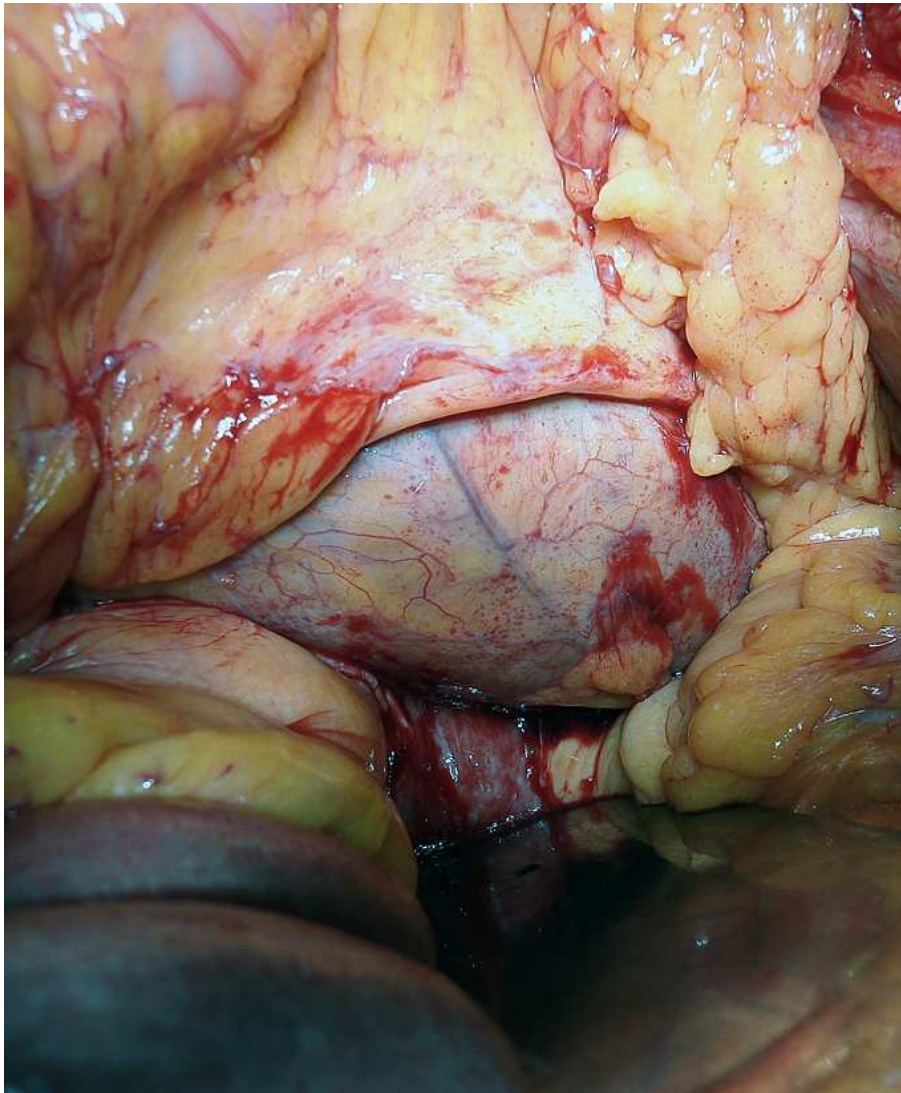
S.A. • Anni: 76 - M  Record: 17 • 28-03-2007

Nefrectomia sn e toilette per emoretroperitoneo da rottura spontanea di grossa neoplasia retroperitoneale



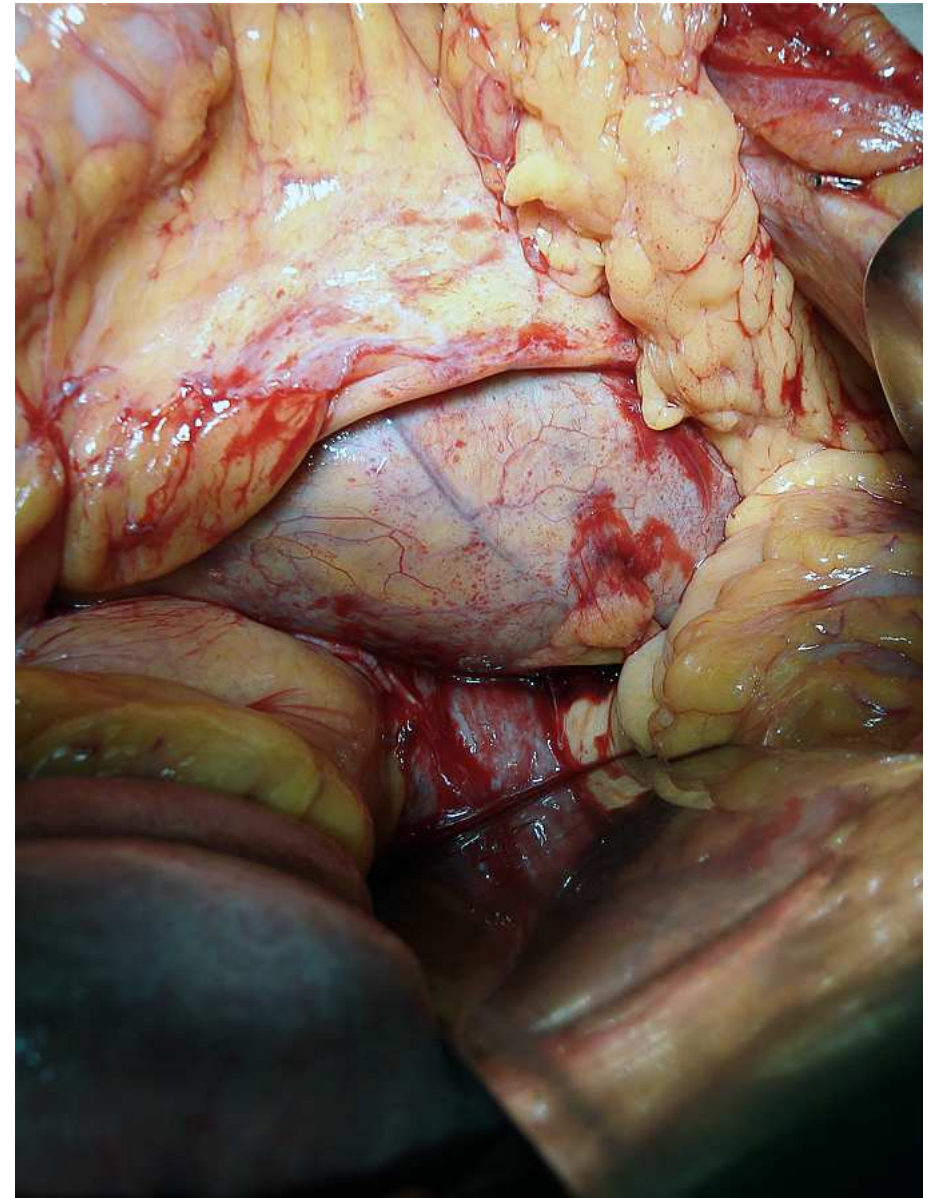

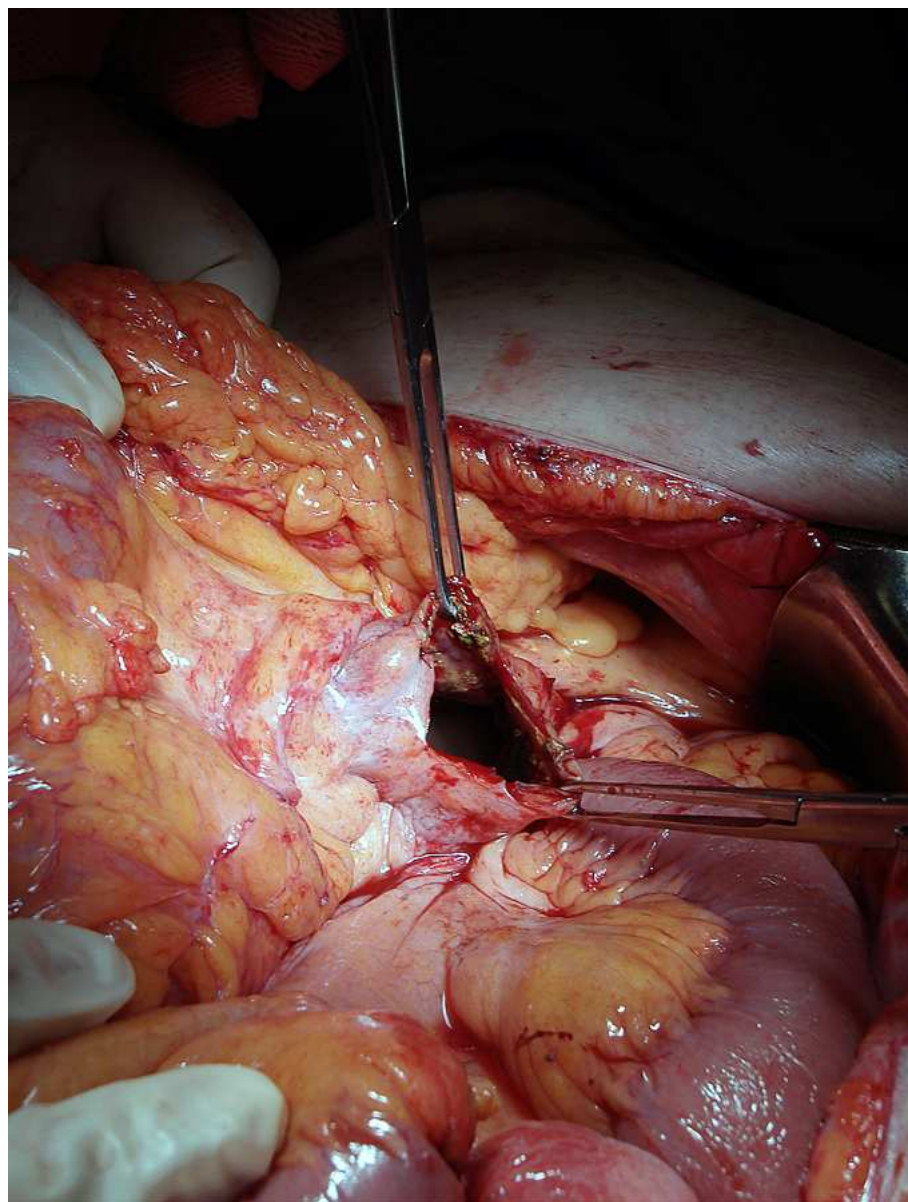
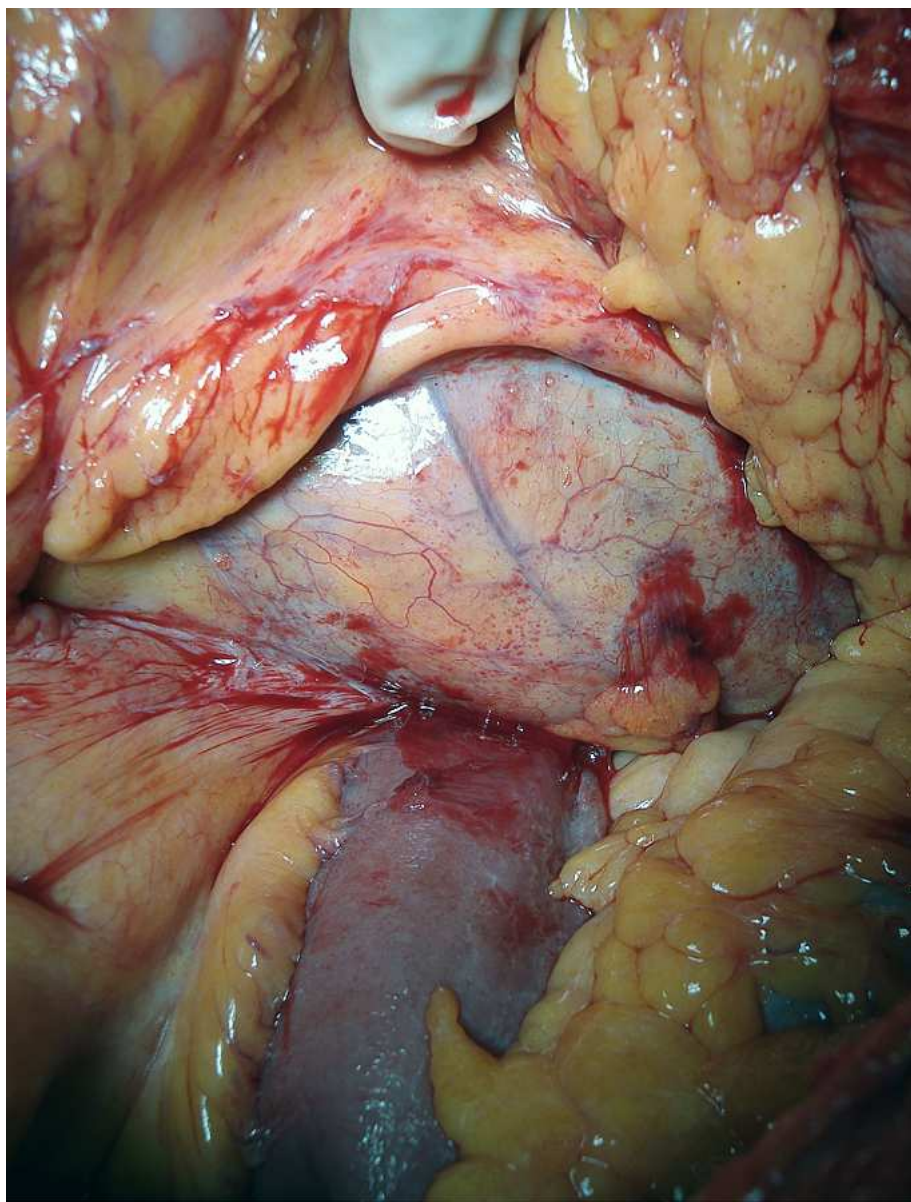


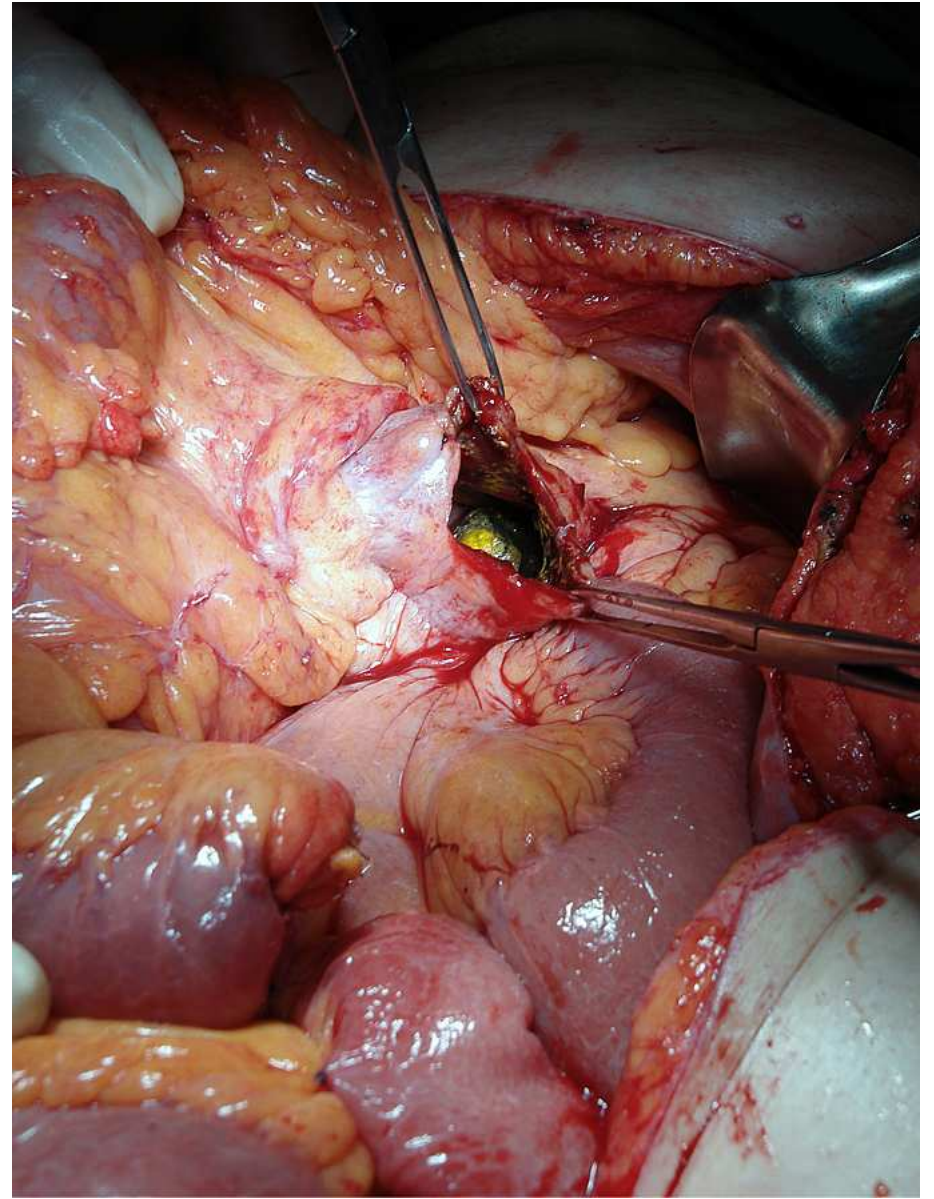
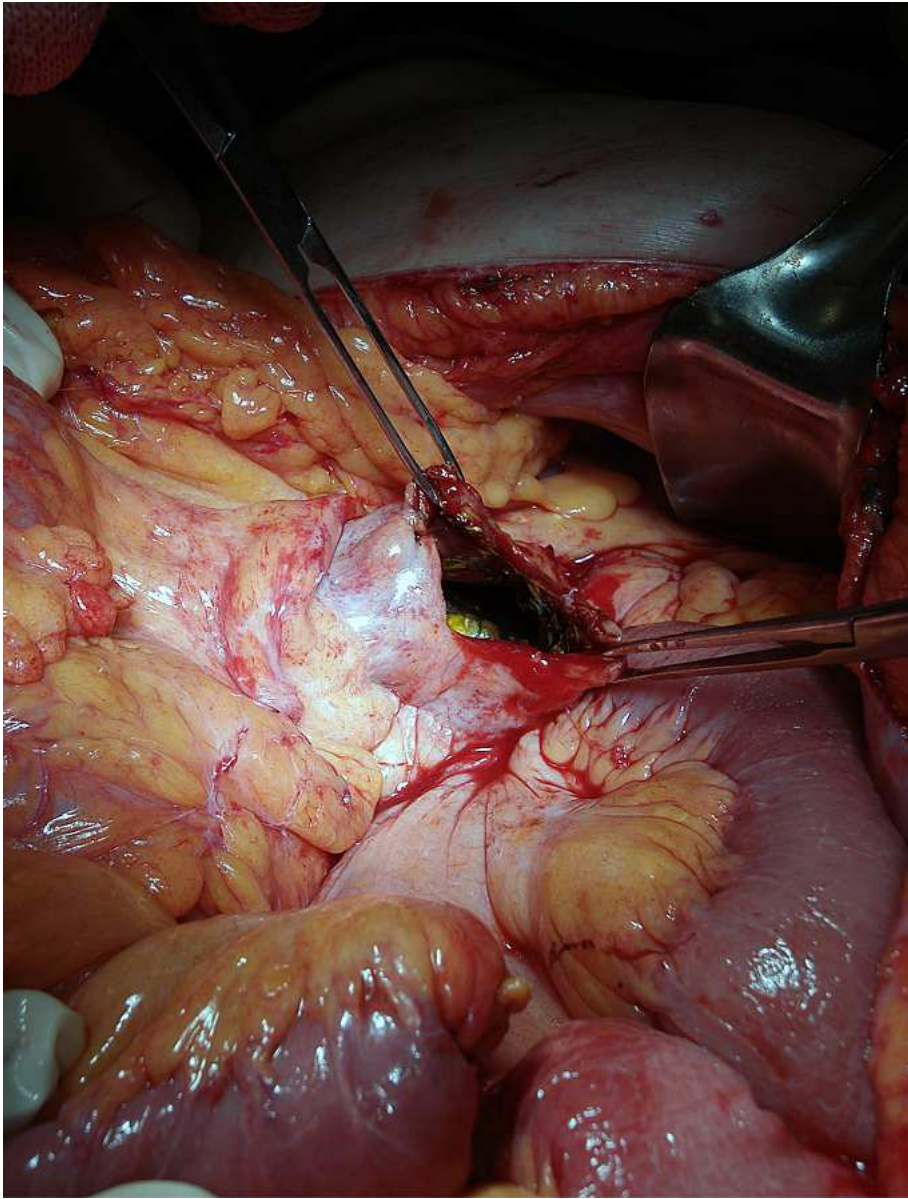


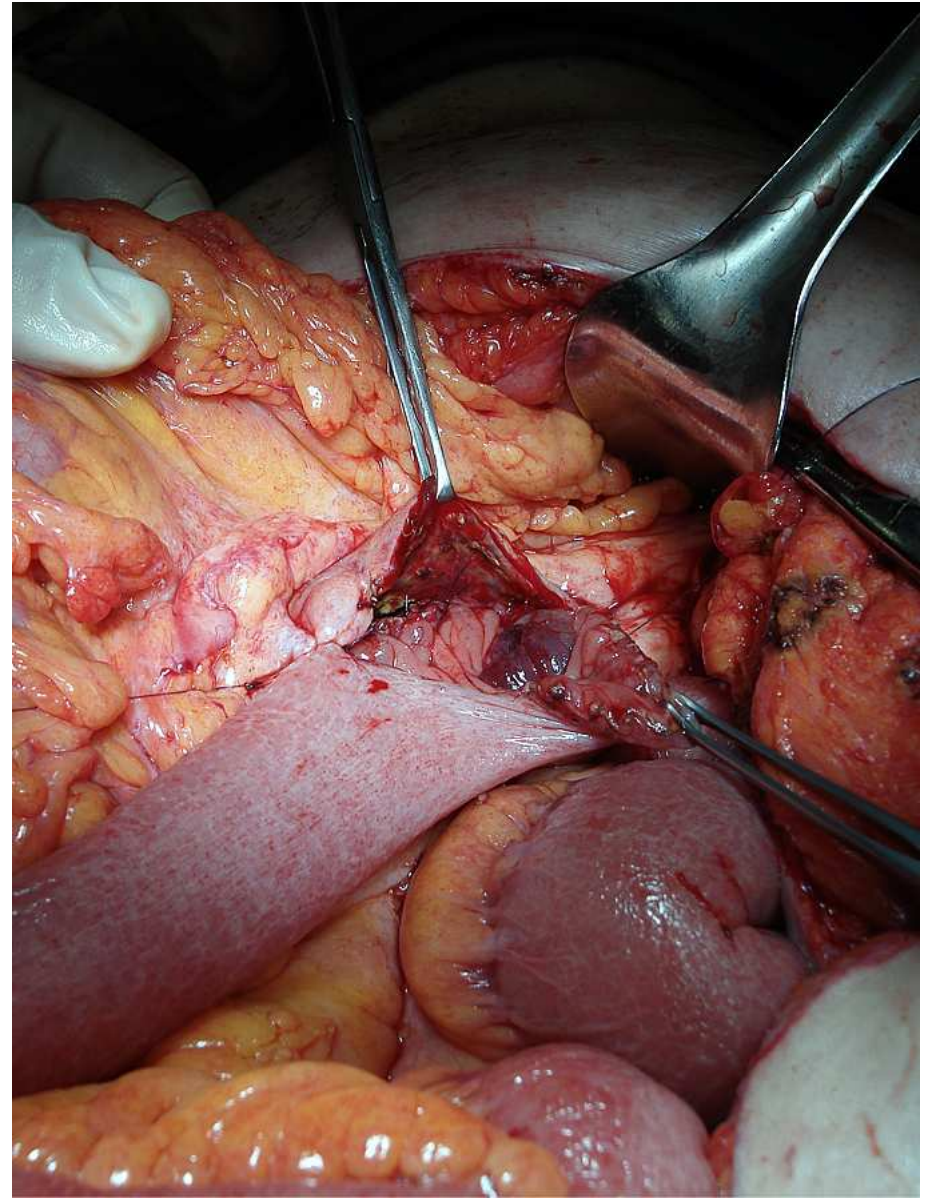
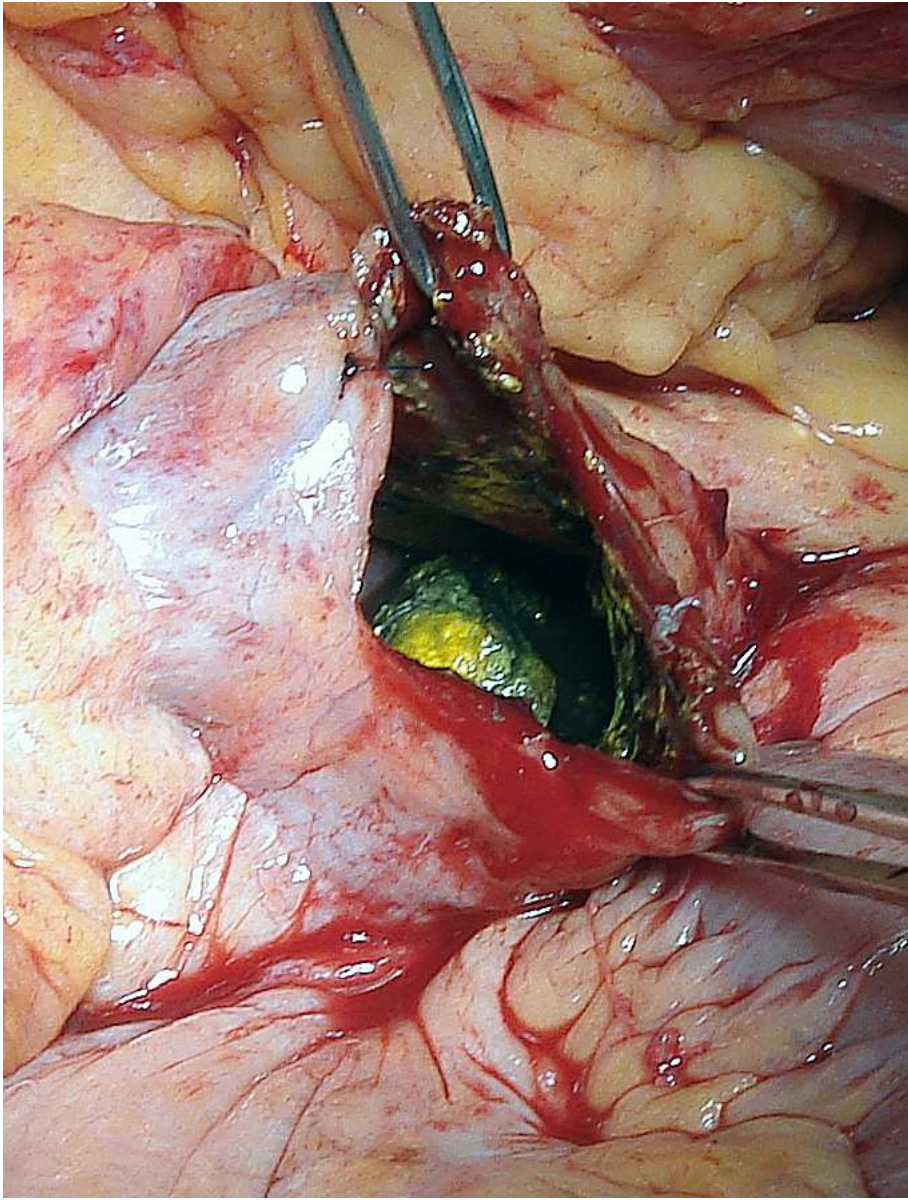
S.C. • Anni: 77 - F • Record: 18 • 12-04-2007

Cisto-digiunostomia transmesocolica con ansa digiunale defunzionizzata e colecistectomia retrograda per pseudocisti pancreatici e colecistoliti

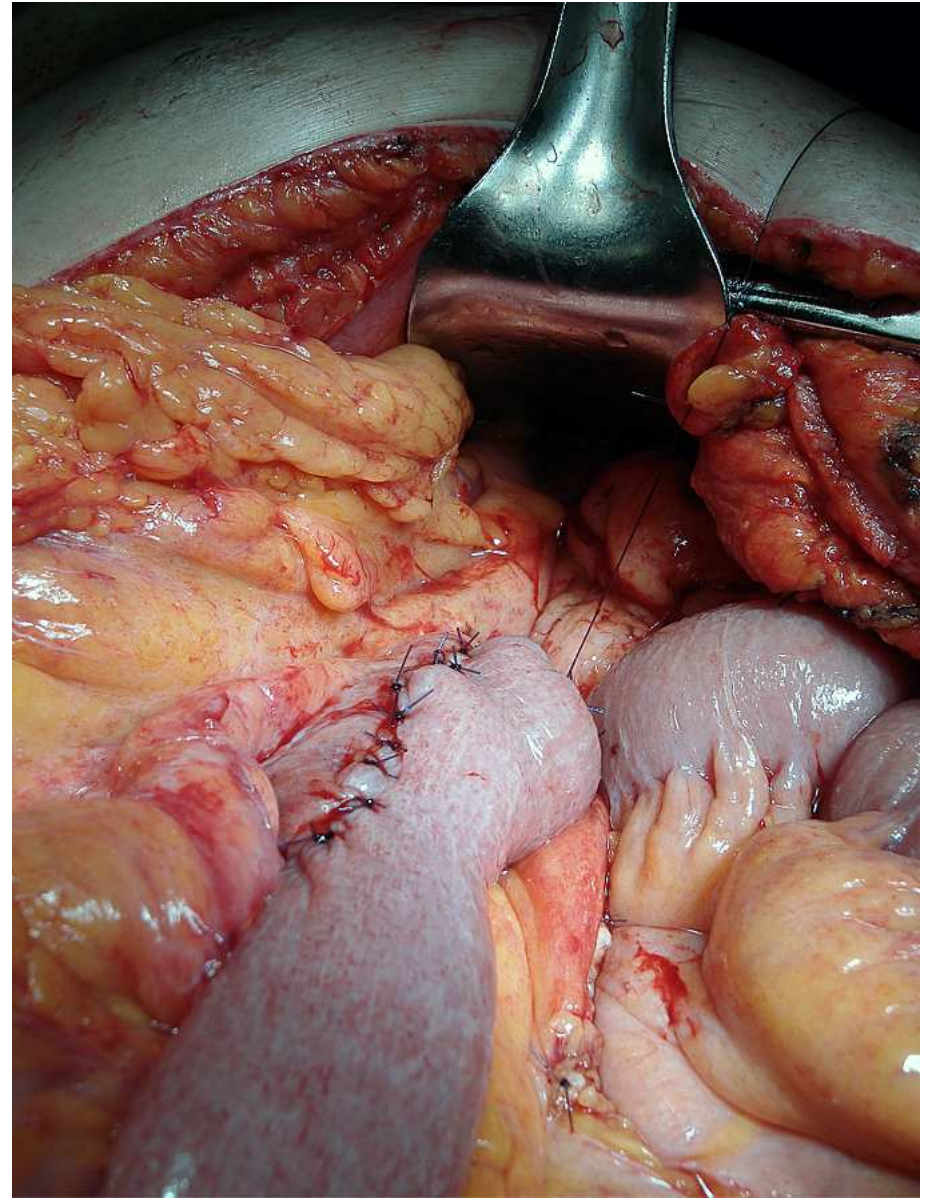
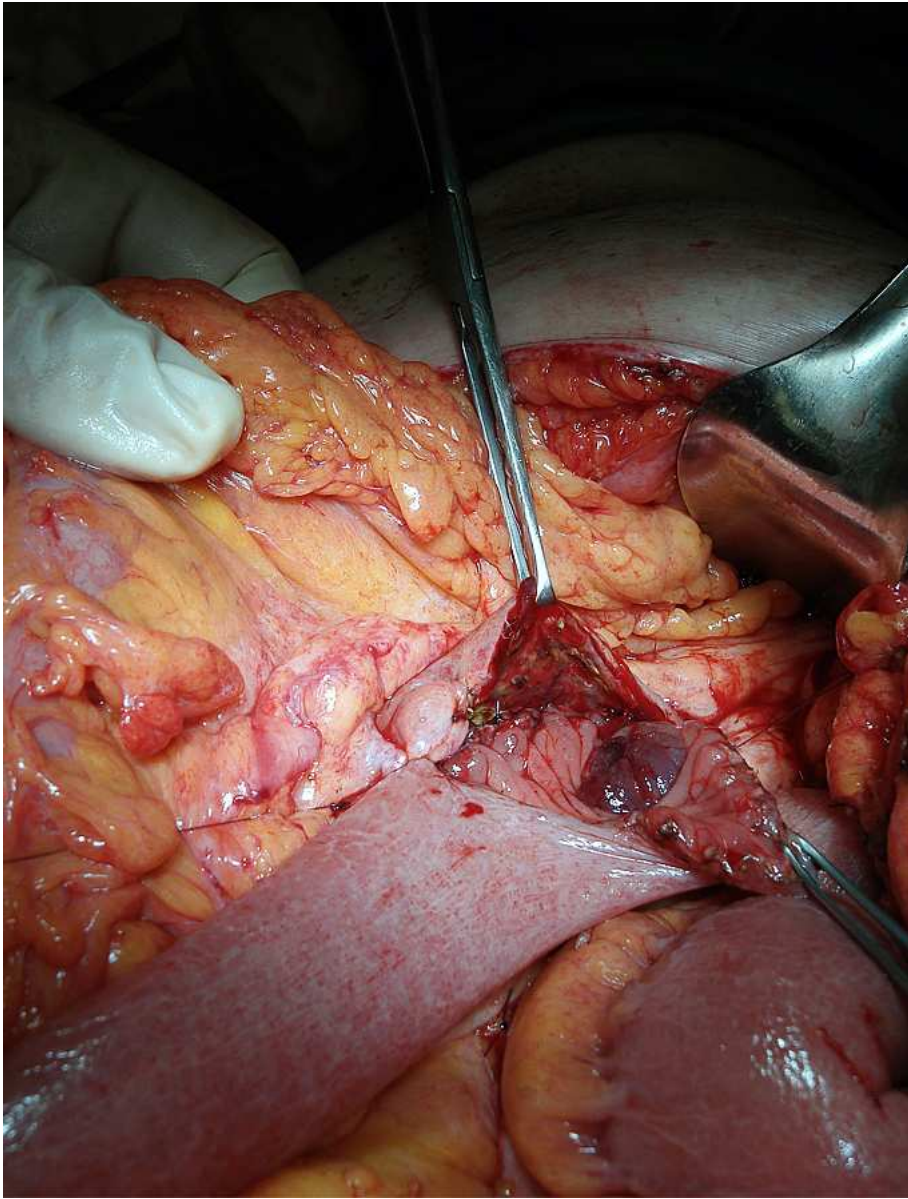


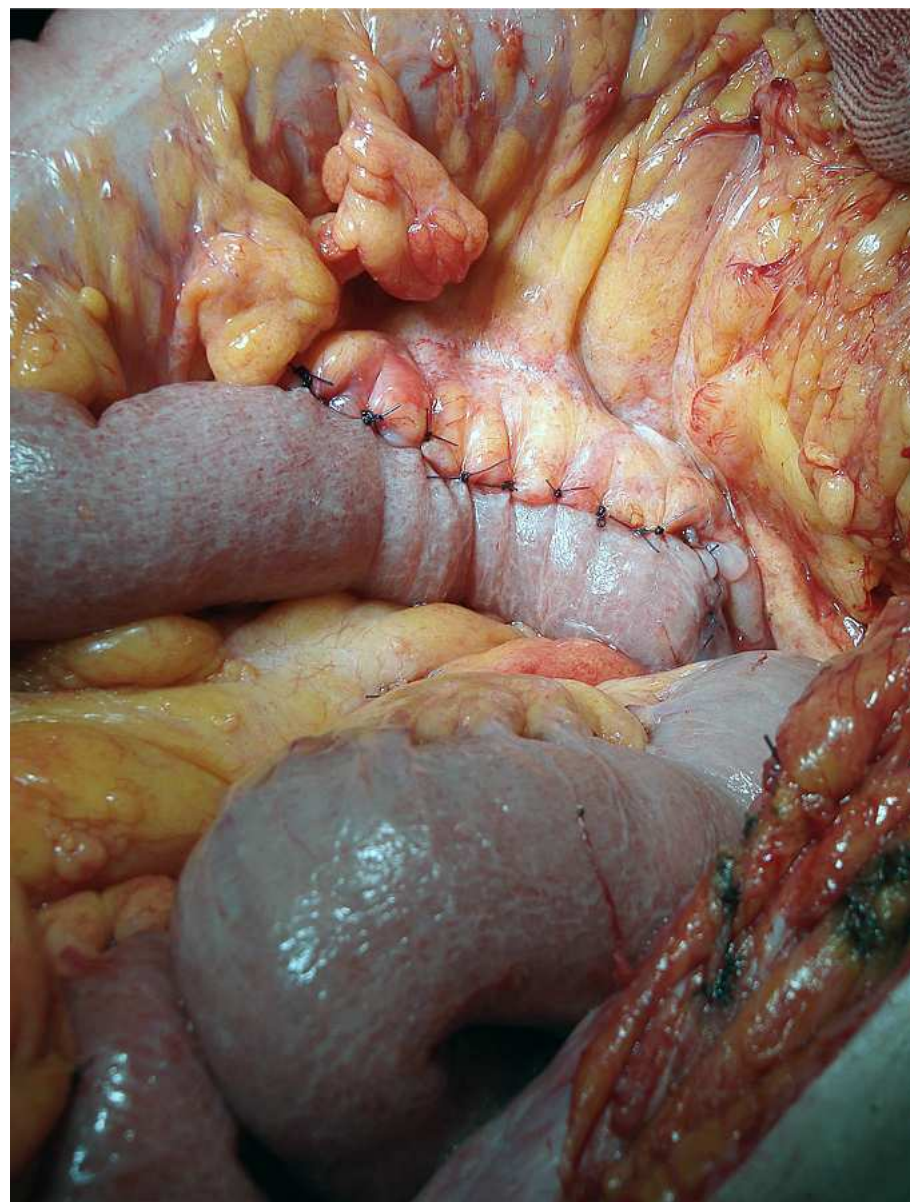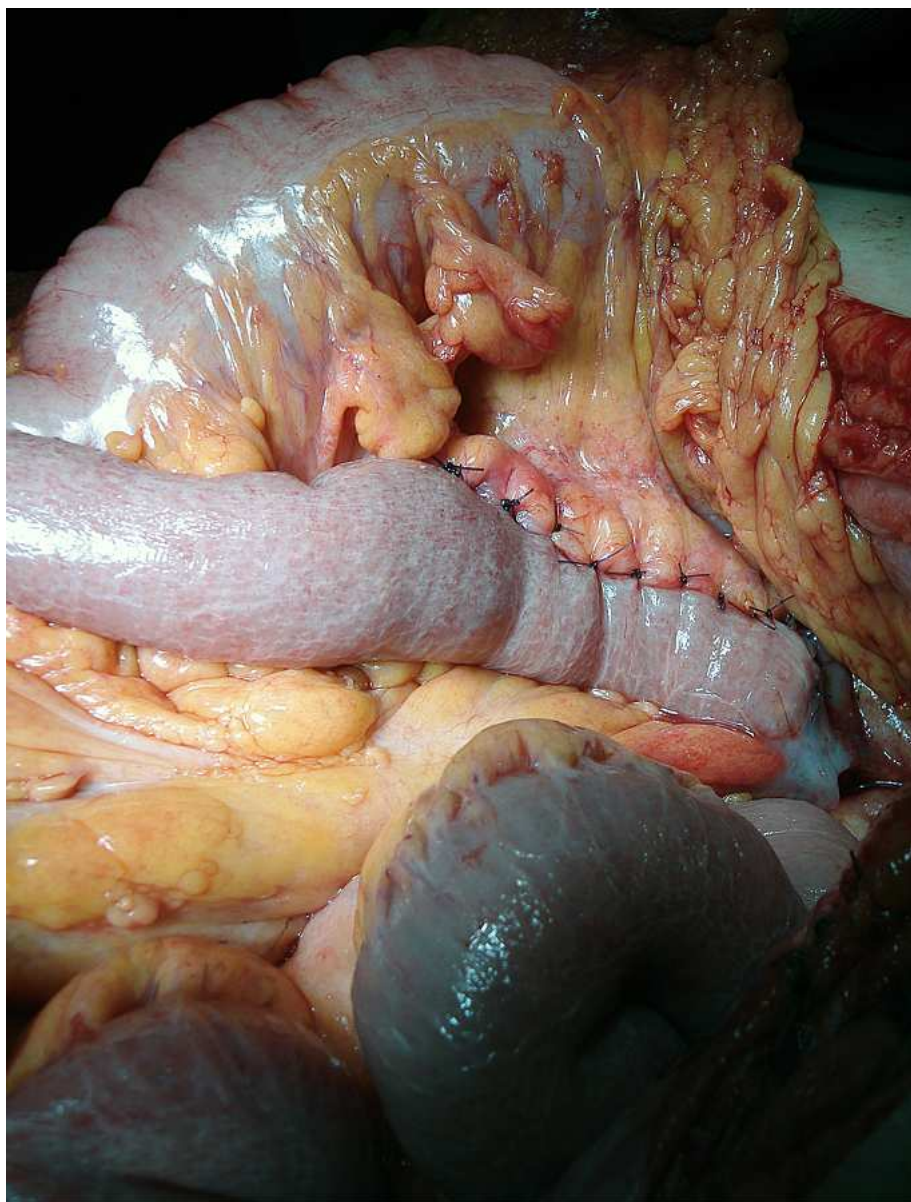


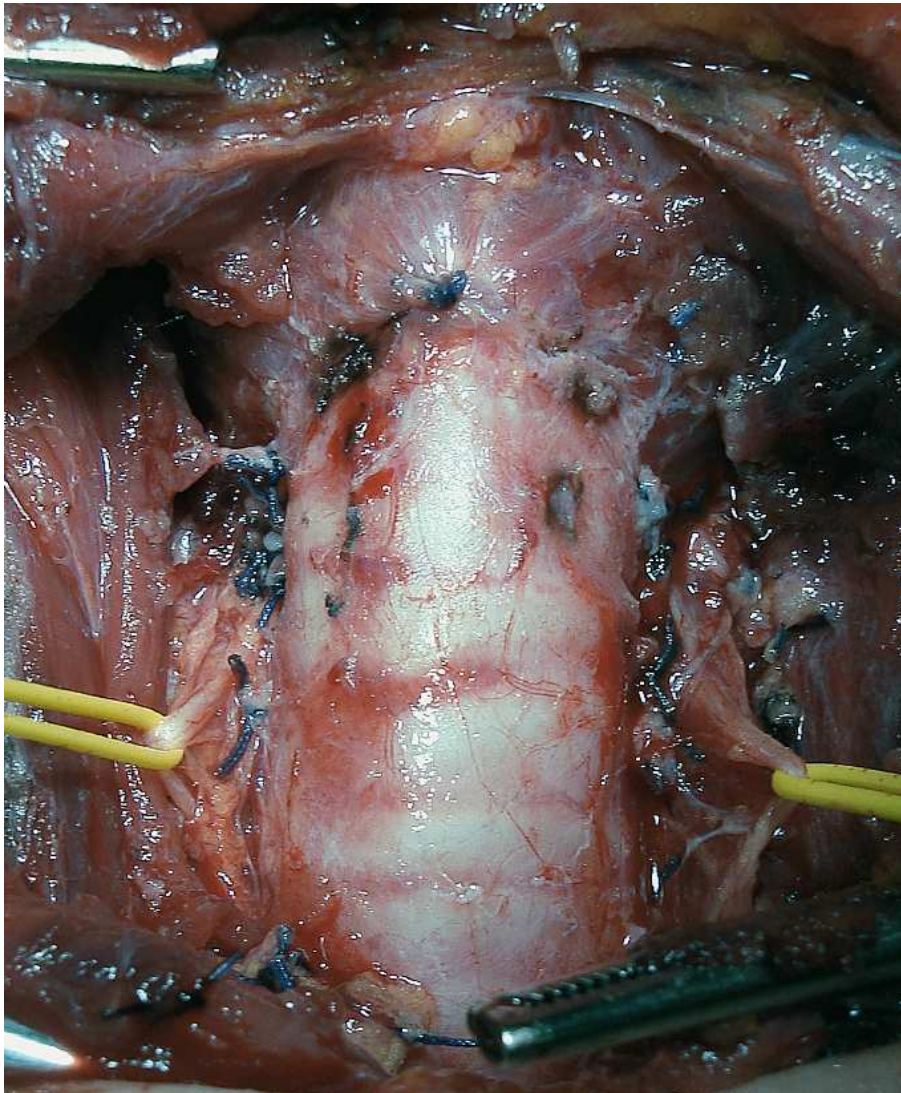






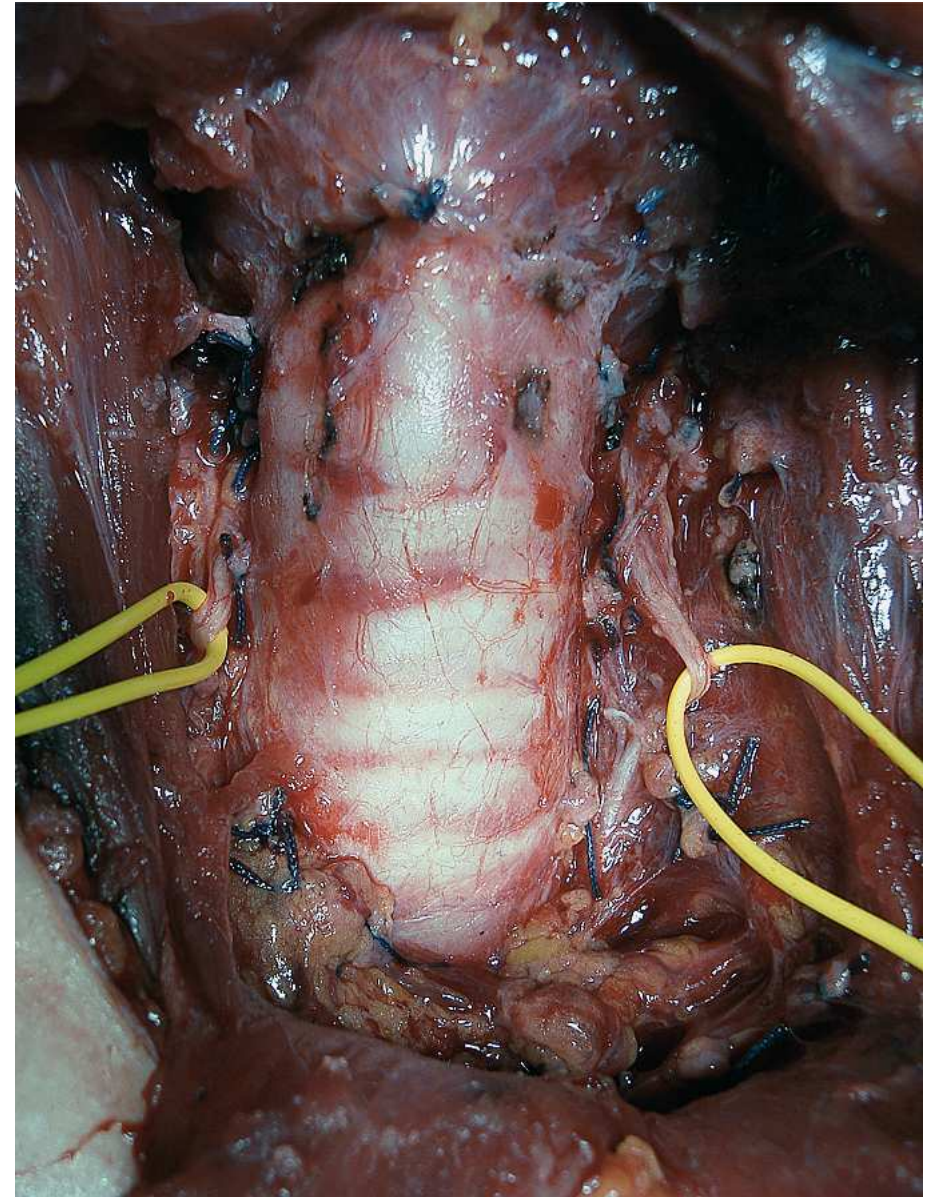





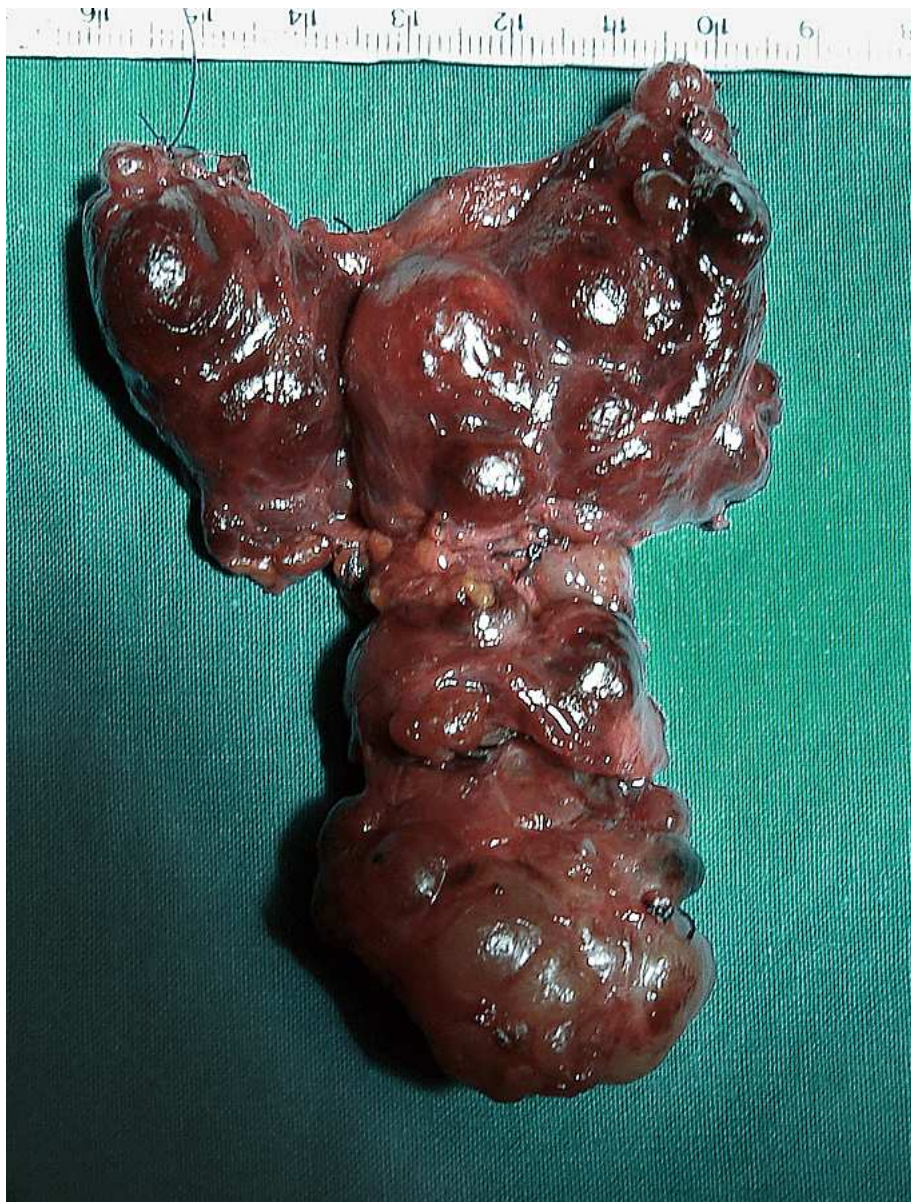
A.P. • Anni: 32 - F • Record: 19 • 16-04-2007

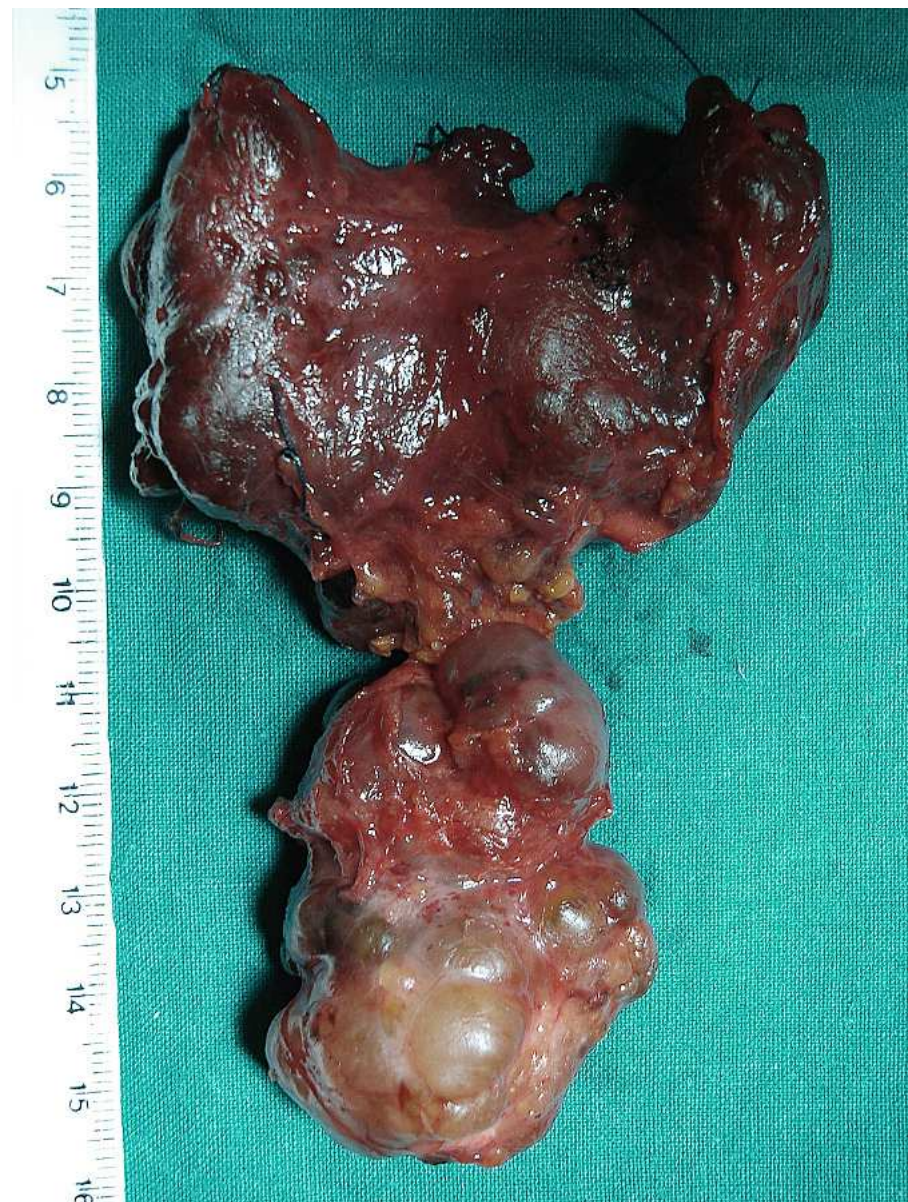Tiroidectomia totale extracapsulare per gozzo plurinodulare plongeant con sezione dei muscoli pretiroidei



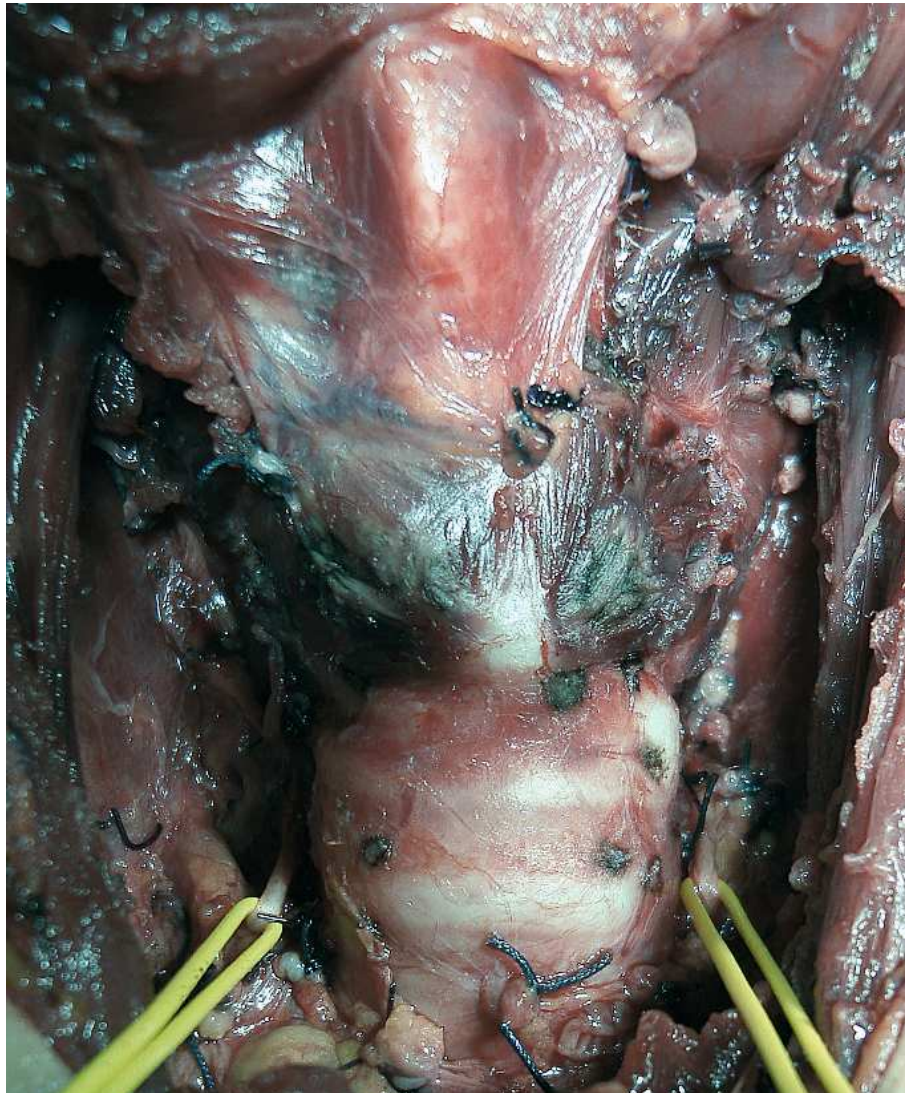
Isolamento dei nervi laringei inferiori (ricorrenti)



Lobo destro - Istmo - Lobo sinistro (superficie anteriore)

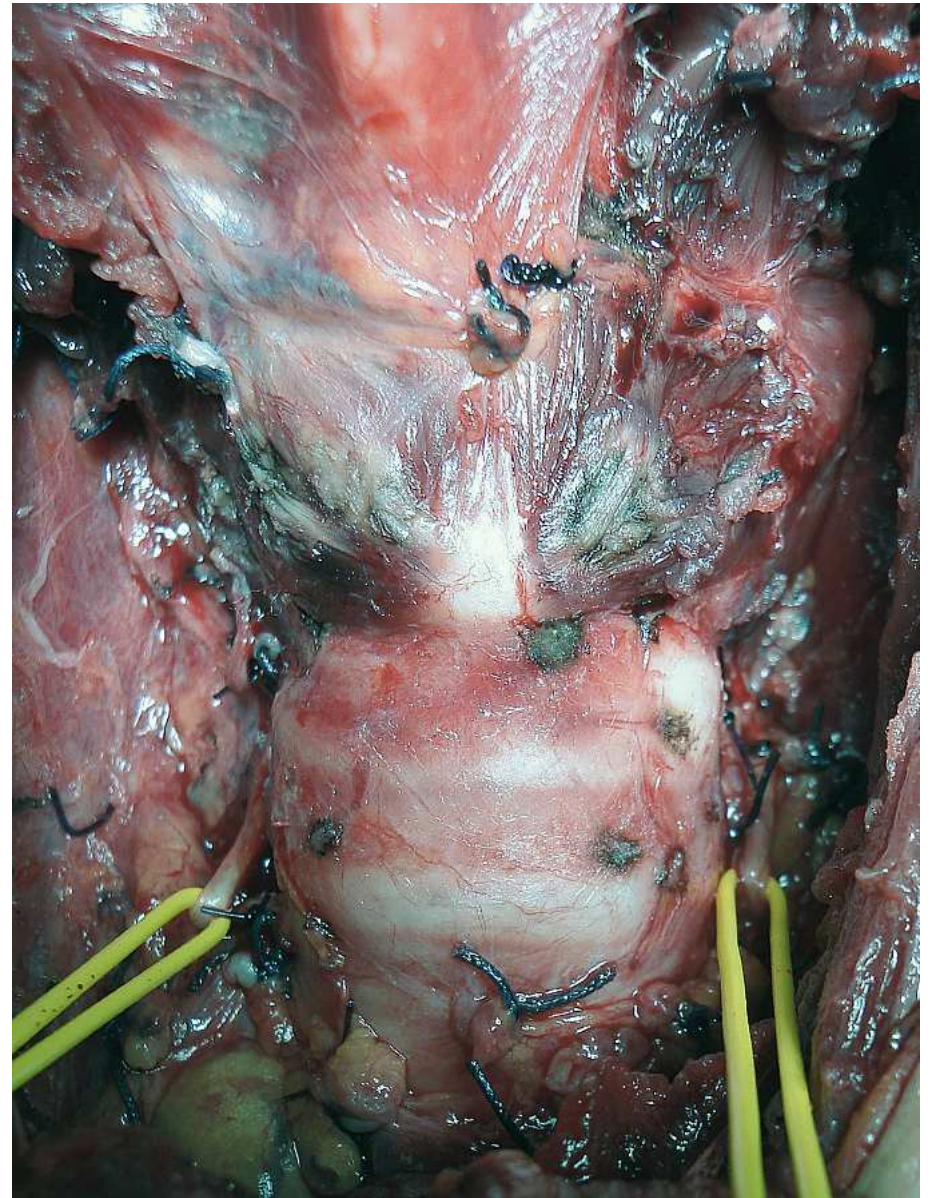


Lobo sinistro - Istmo - Lobo destro (superficie posteriore)

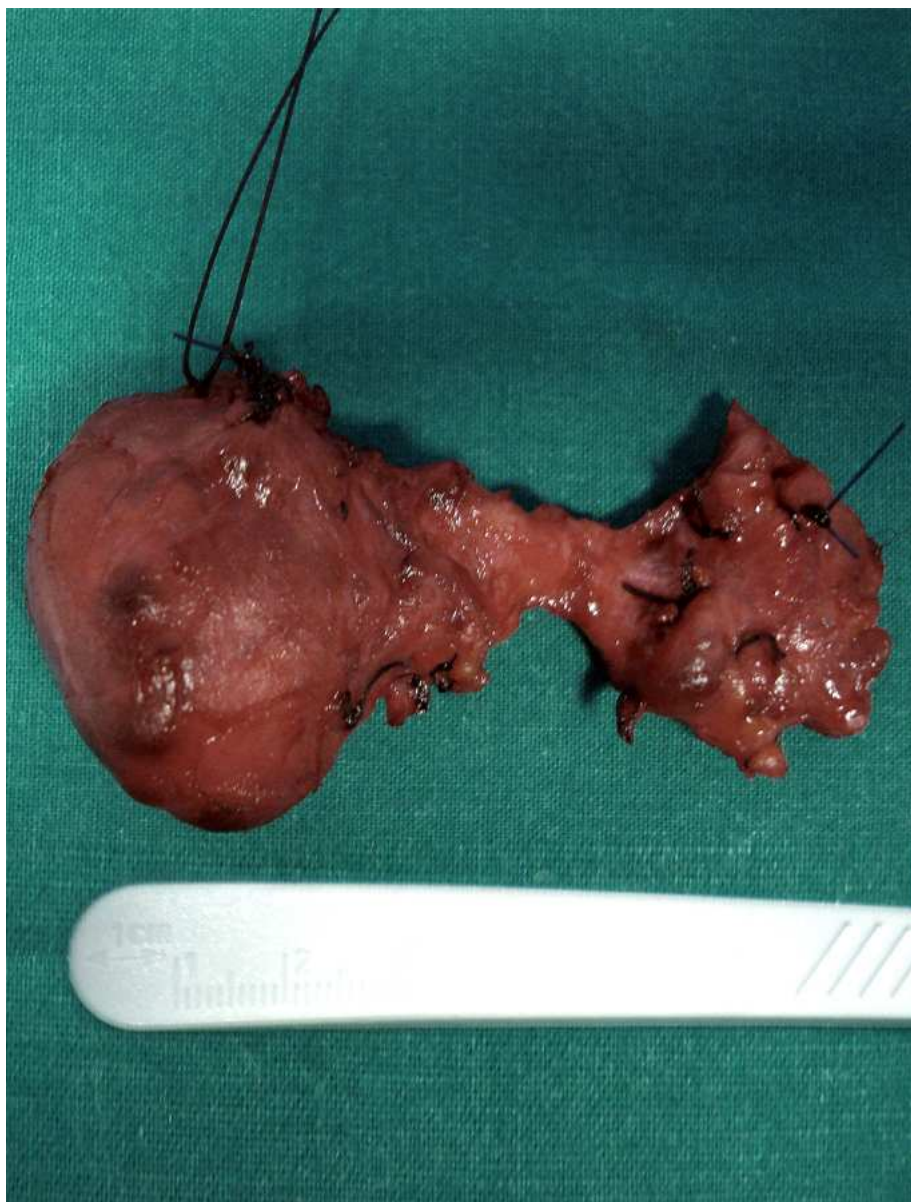


S.F. • Anni: 50 - M 🍏 Record: 20 • 19-04-2007

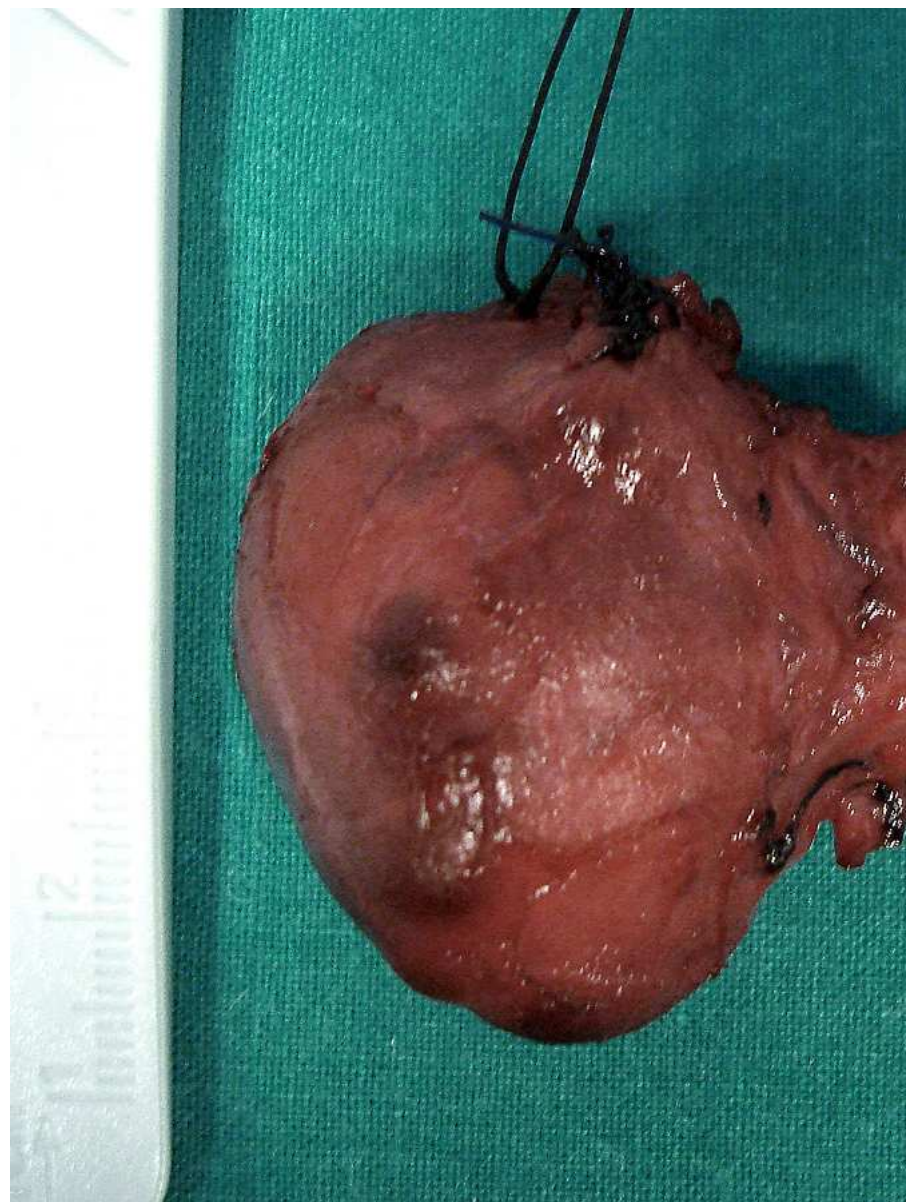
Tiroidectomia totale extracapsulare per gozzo plurinodulare con sezione dei muscoli pretiroidei



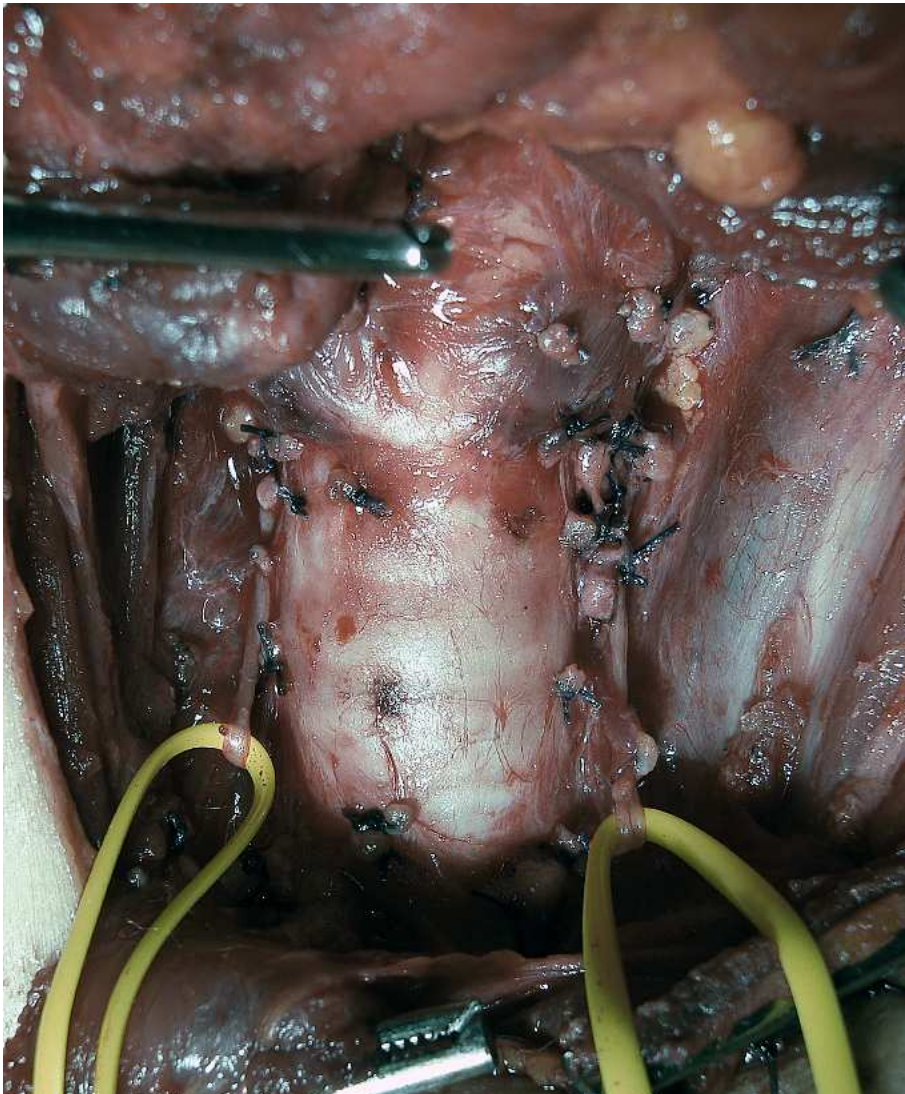
Isolamento dei nervi laringei inferiori (ricorrenti)



Lobo destro - Istmo - Lobo sinistro (superficie anteriore)

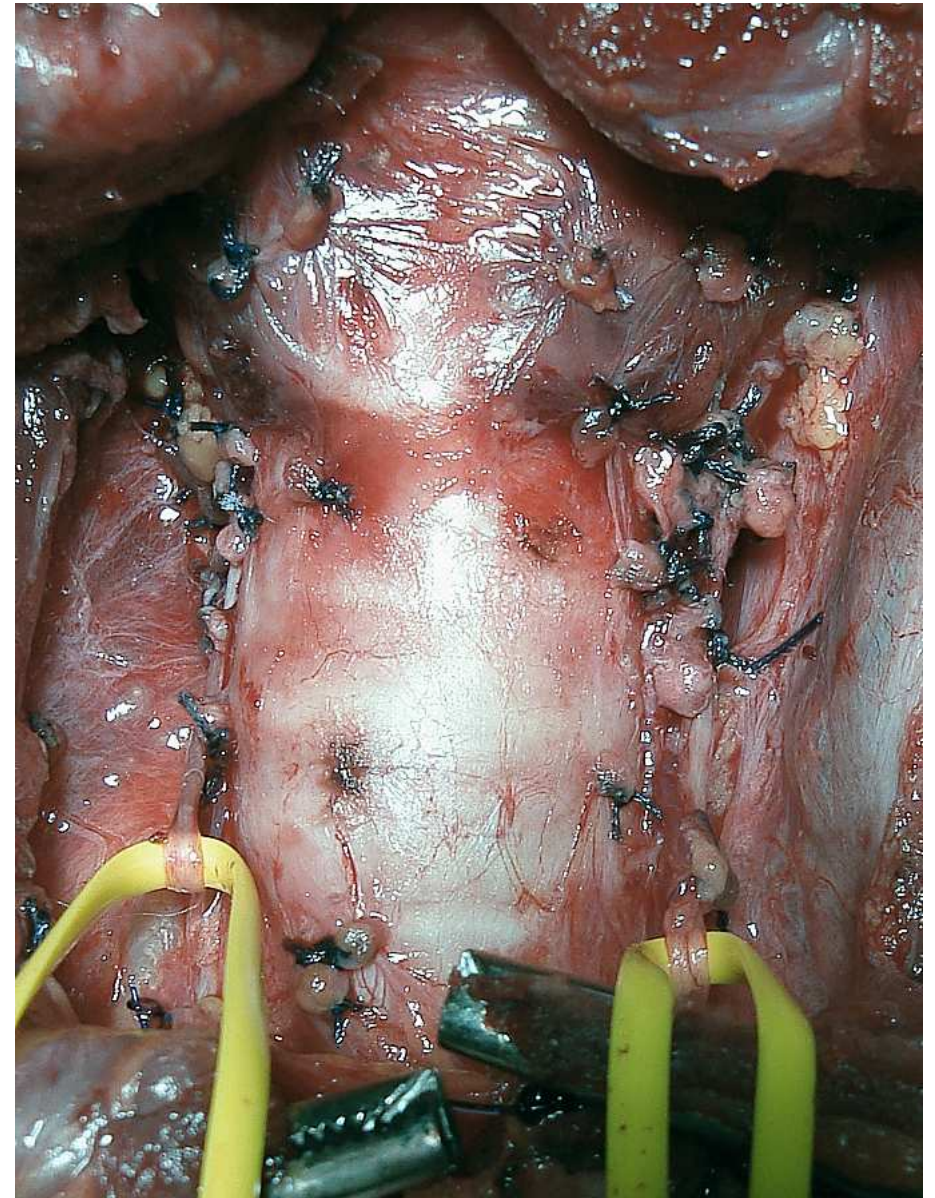


Lobo tiroideo dx (superficie anteriore)

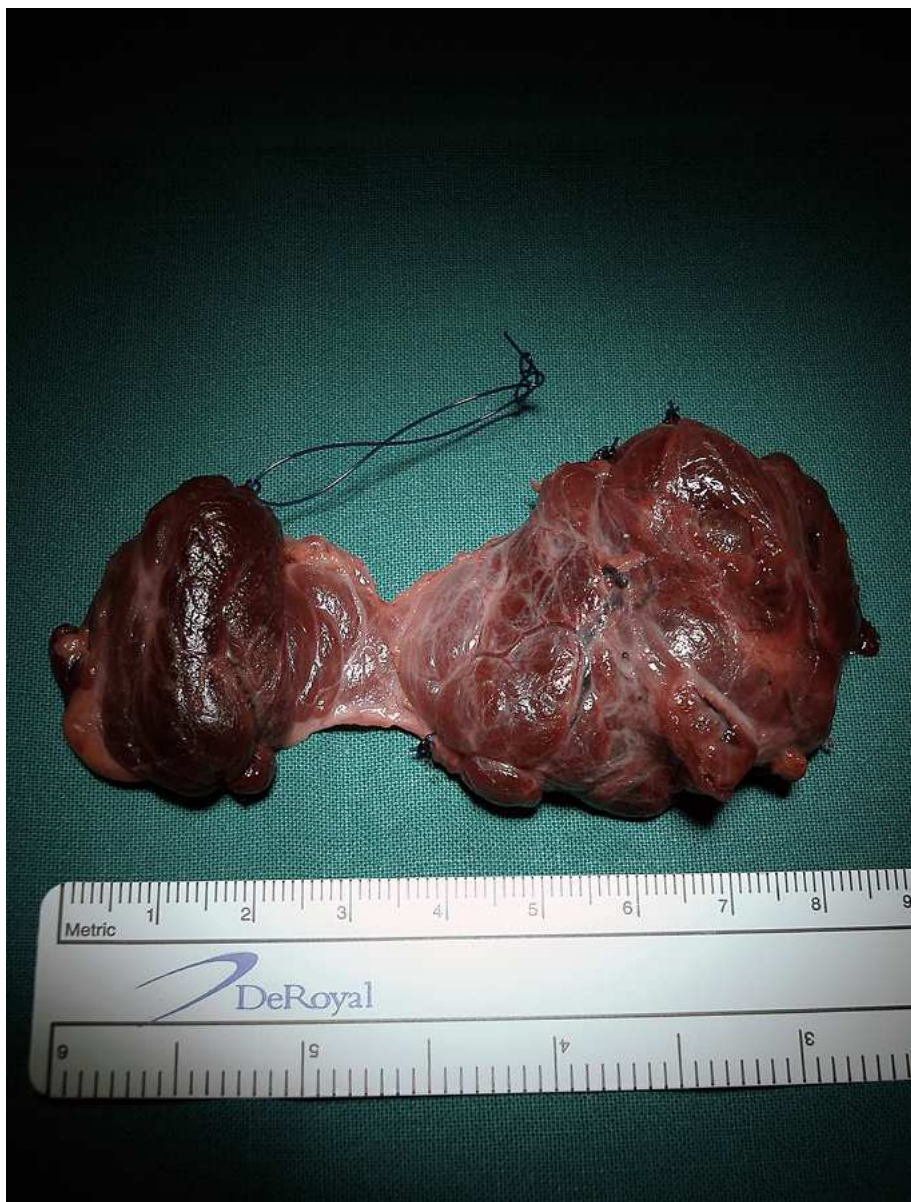

Y.S. • Anni: 41 - F • Record: 21 • 14-05-2007

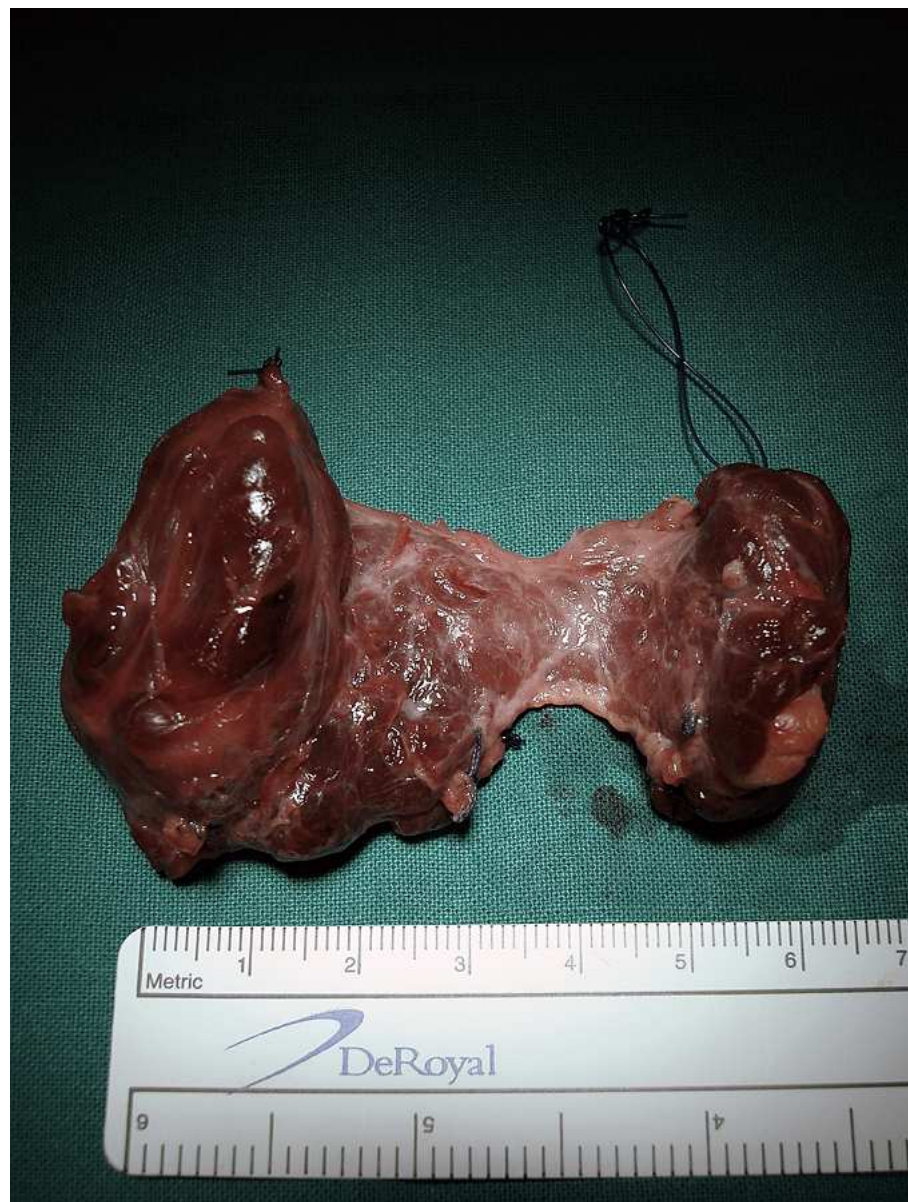Tiroidectomia totale extracapsulare per gozzo plurinodulare con sezione dei muscoli pretiroidei



Isolamento dei nervi laringei inferiori (ricorrenti)

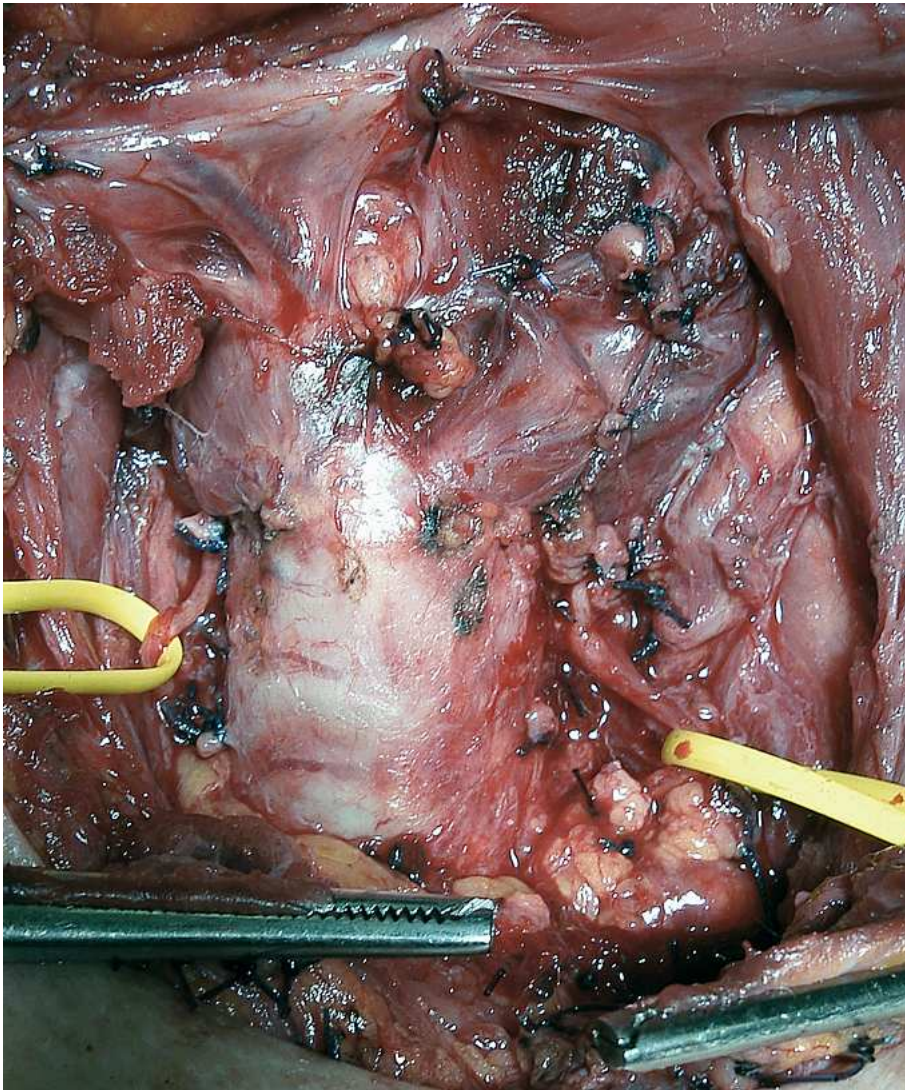


Lobo destro - Istmo - Lobo sinistro (superficie anteriore)



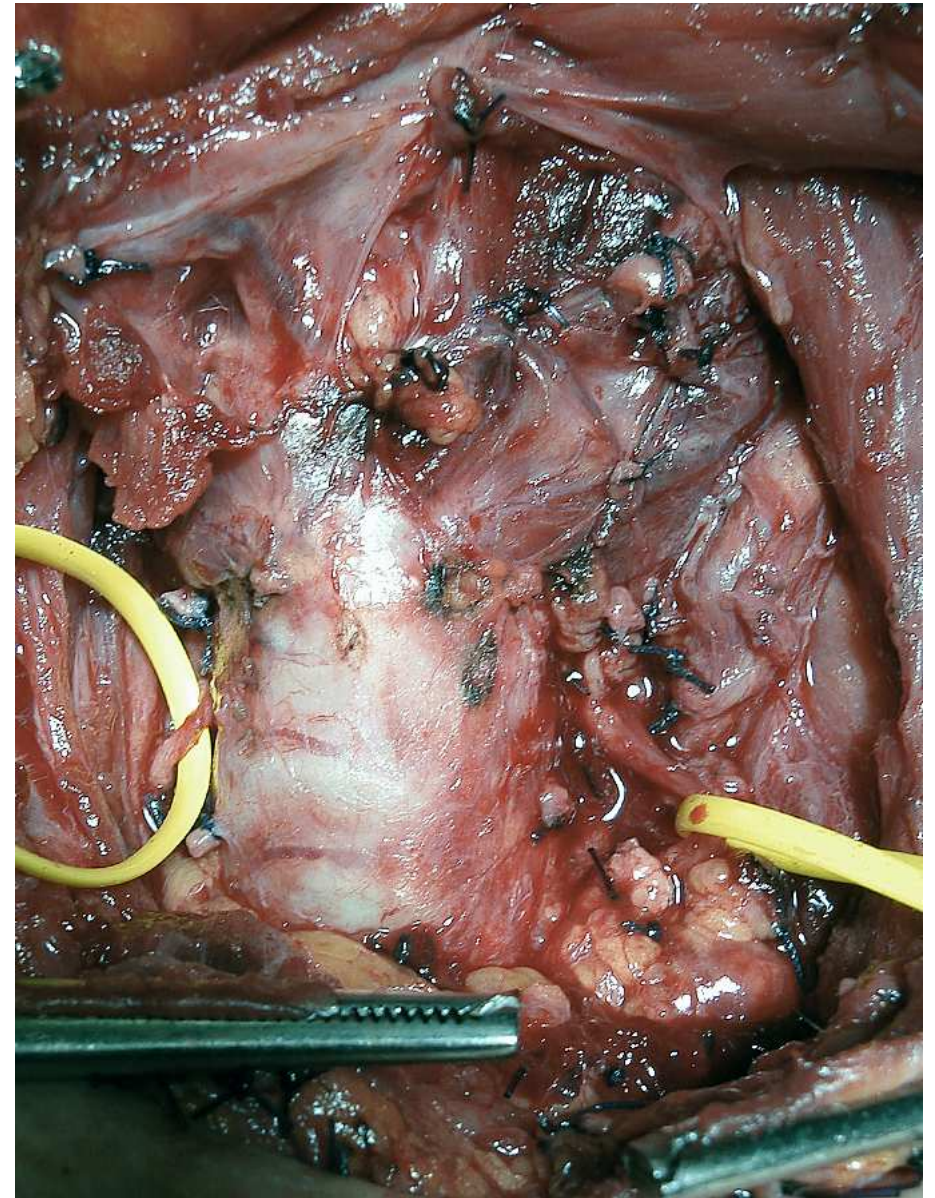
Lobo sinistro - Istmo - Lobo destro (superficie posteriore)



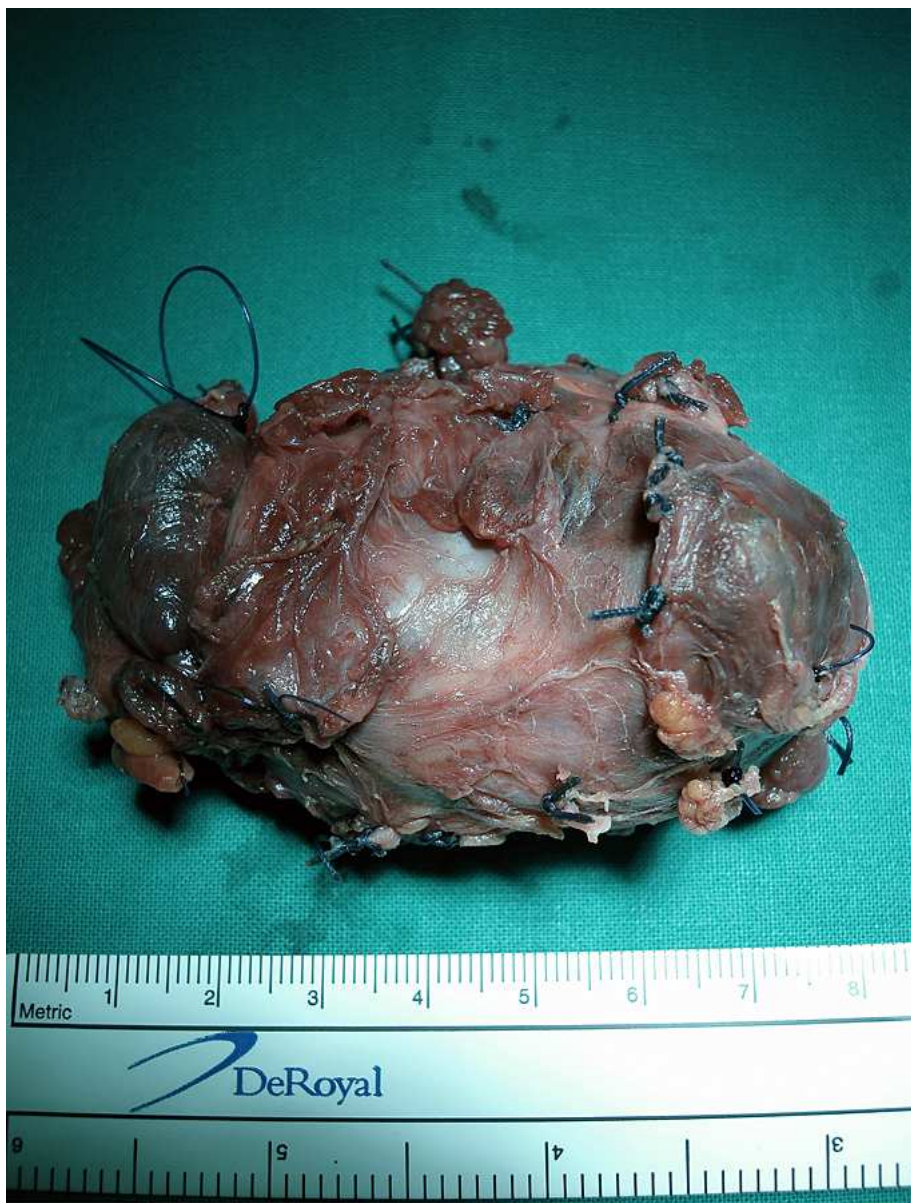

C.M.G. • Anni: 57 - F • Record: 22 • 21-05-2007

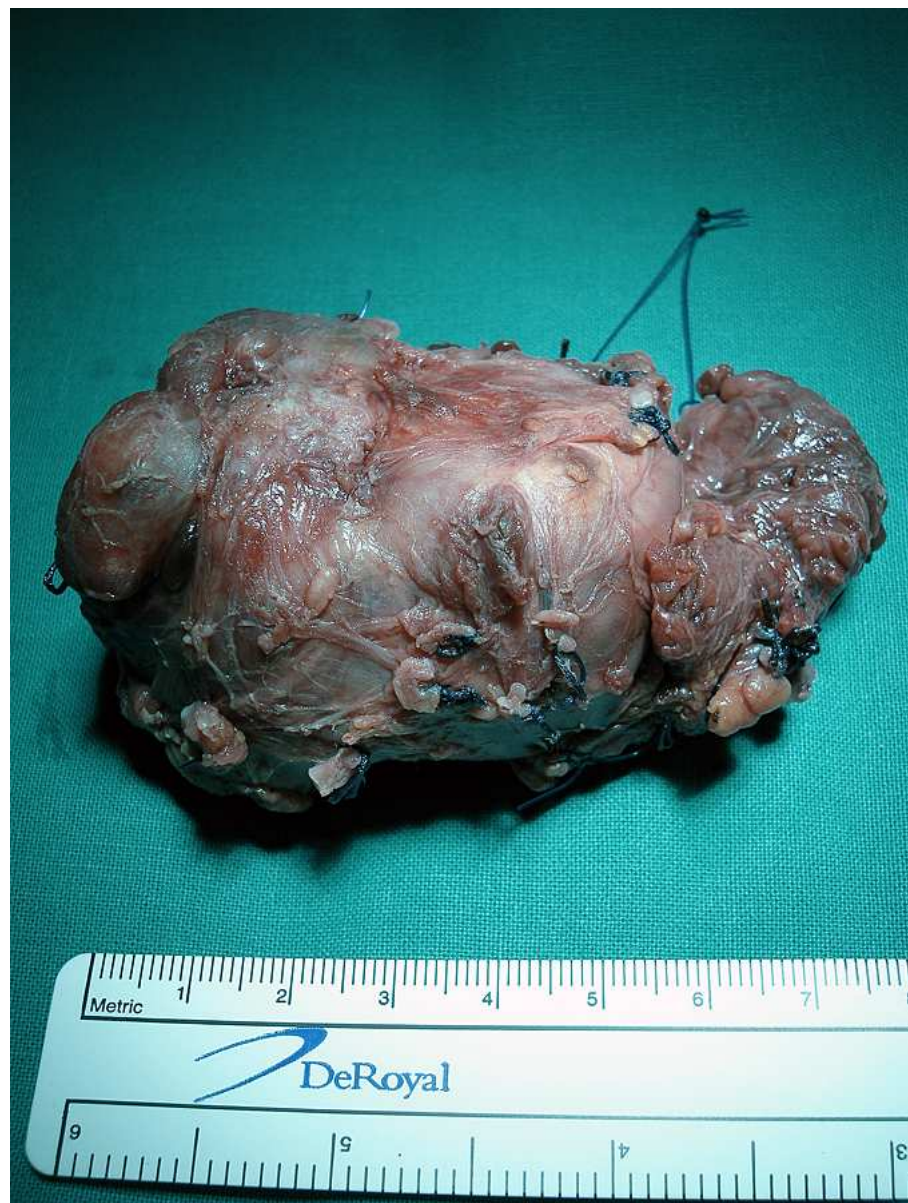Tiroidectomia totale extracapsulare per carcinoma papillare in gozzo plurinodulare plongeant a sn con sezione dei muscoli pretilroidei



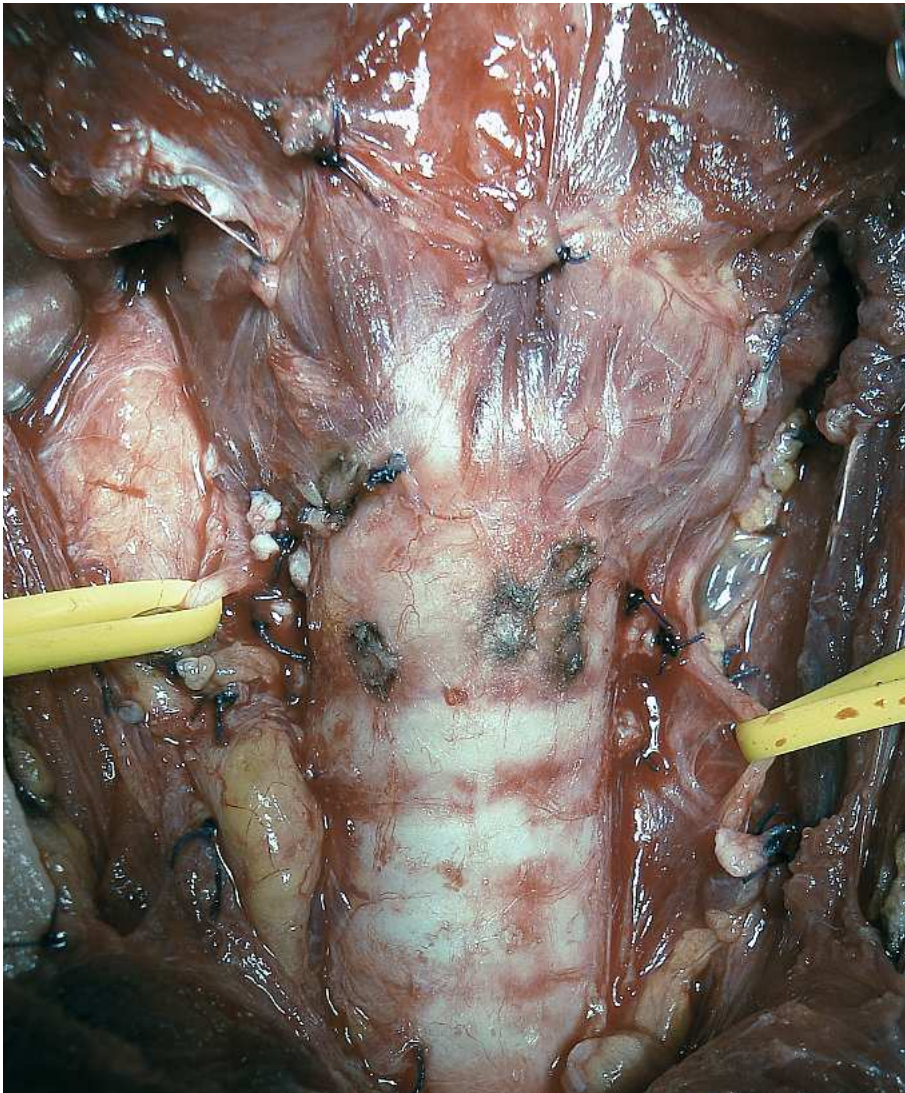
Isolamento dei nervi laringei inferiori (ricorrenti)



Lobo destro - Istmo - Lobo sinistro (superficie anteriore)

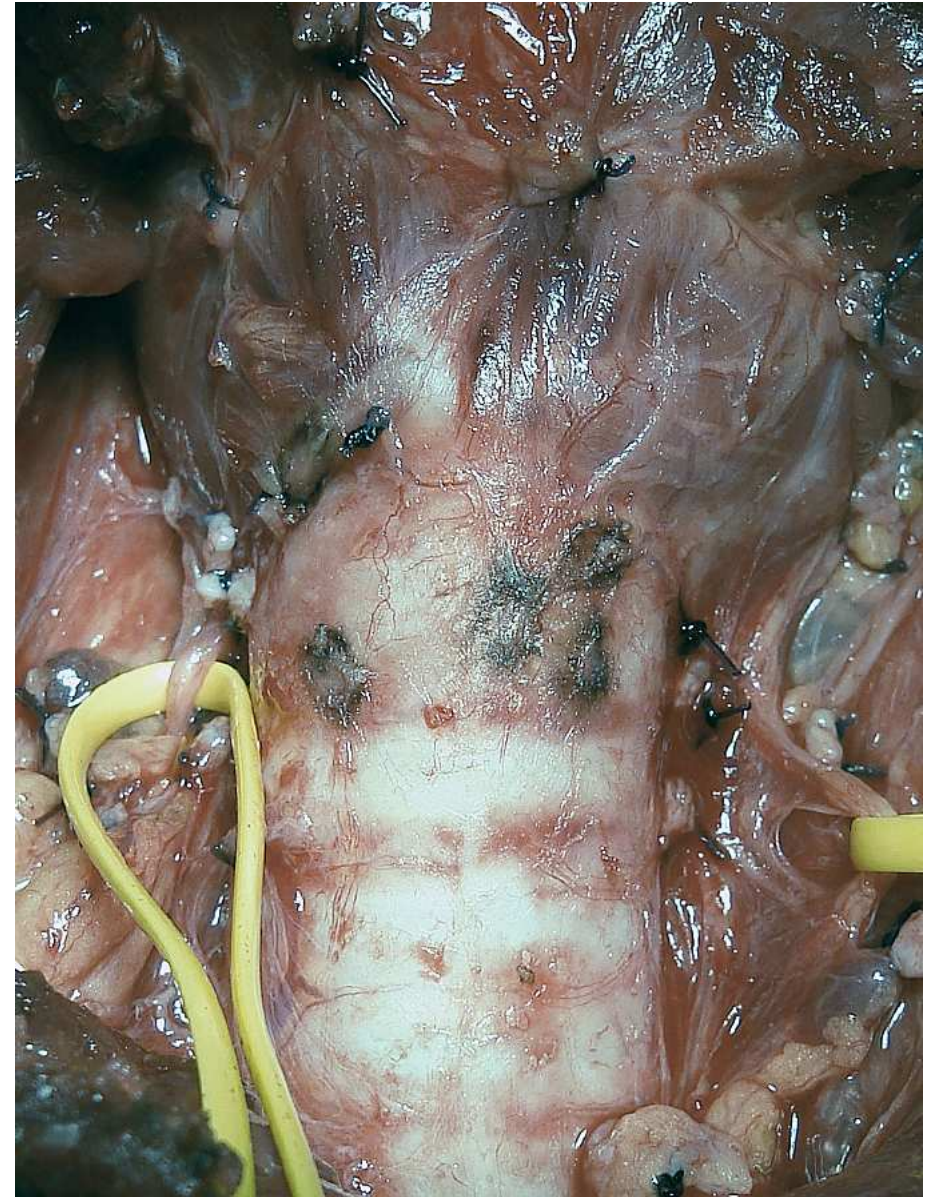


Lobo sinistro - Istmo - Lobo destro (superficie posteriore)

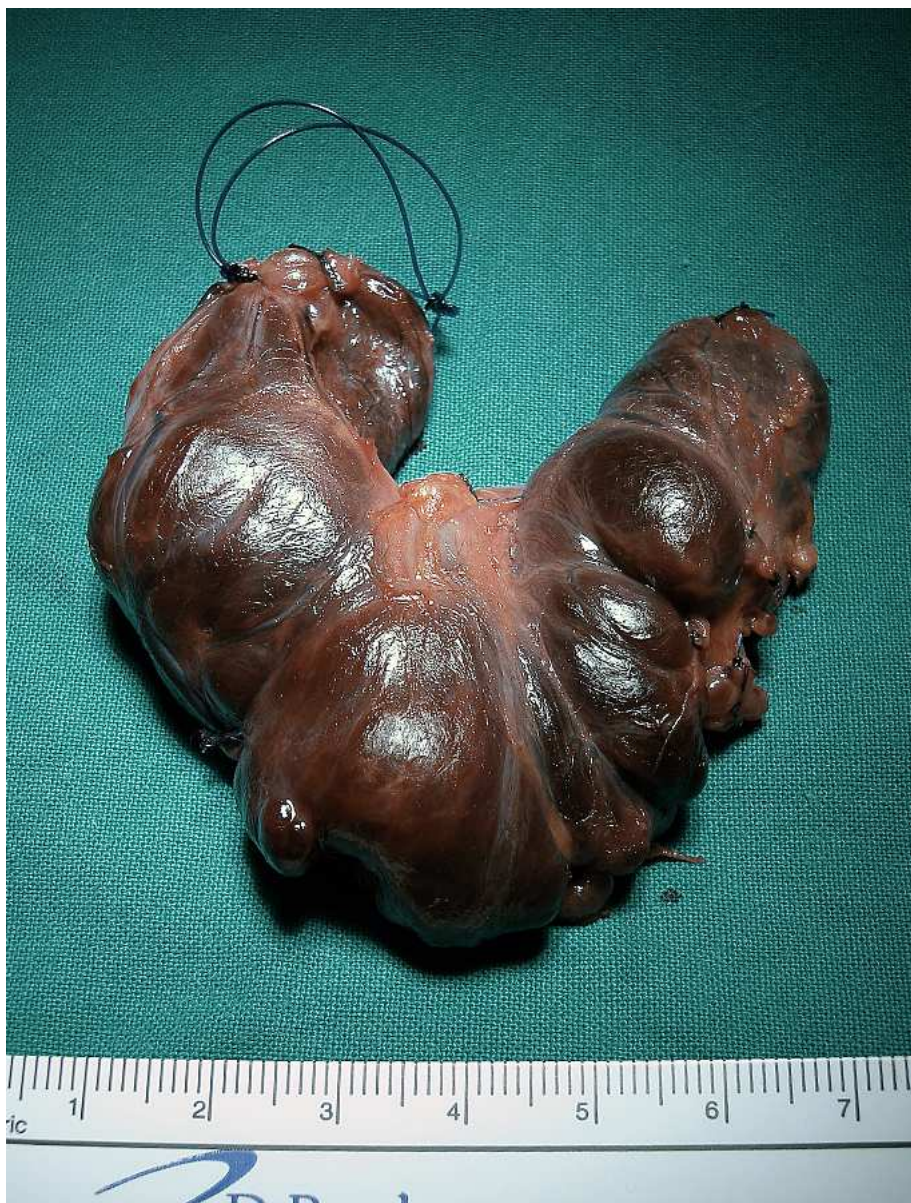


M.G. • Anni: 43 - F • Record: 23 • 28-05-2007

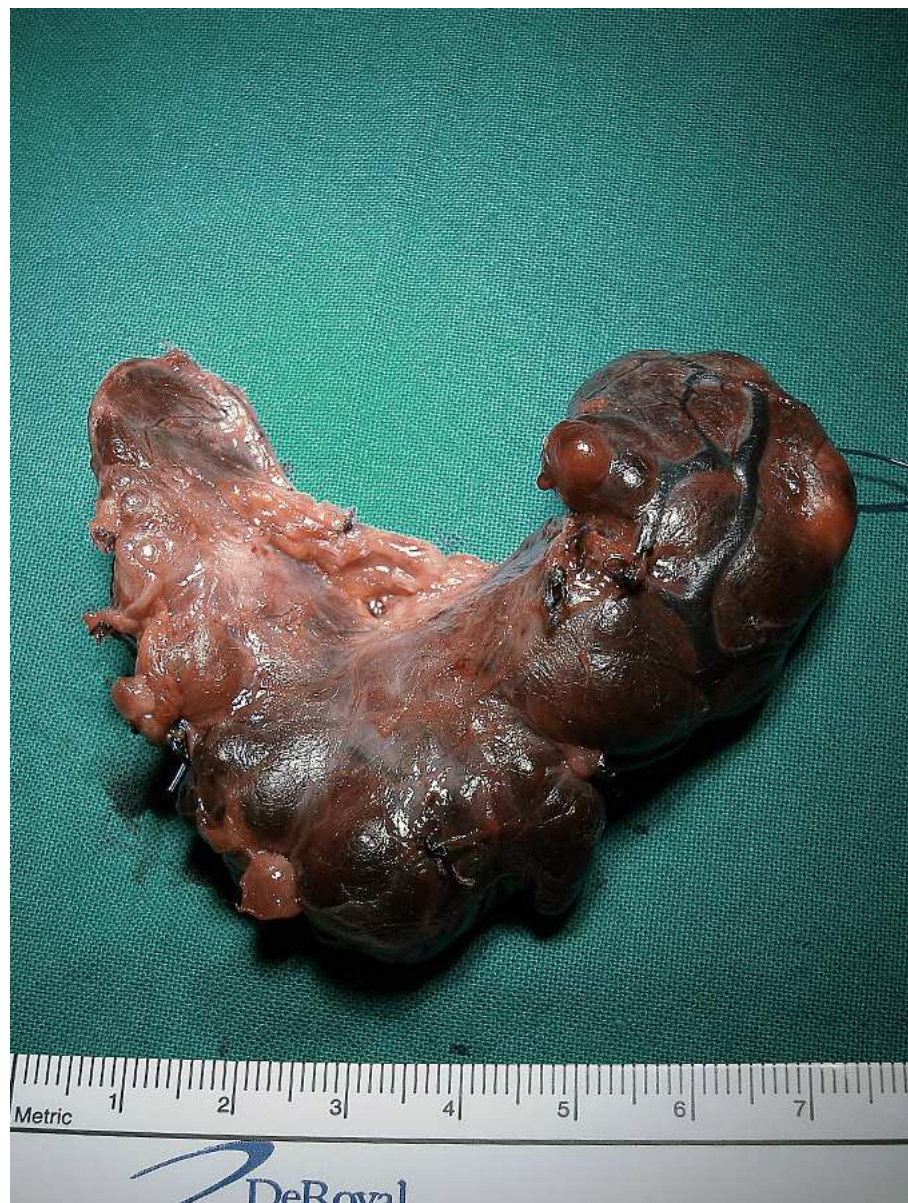
Tiroidectomia totale extracapsulare per gozzo plurinodulare tossico con sezione dei muscoli pretiroidei



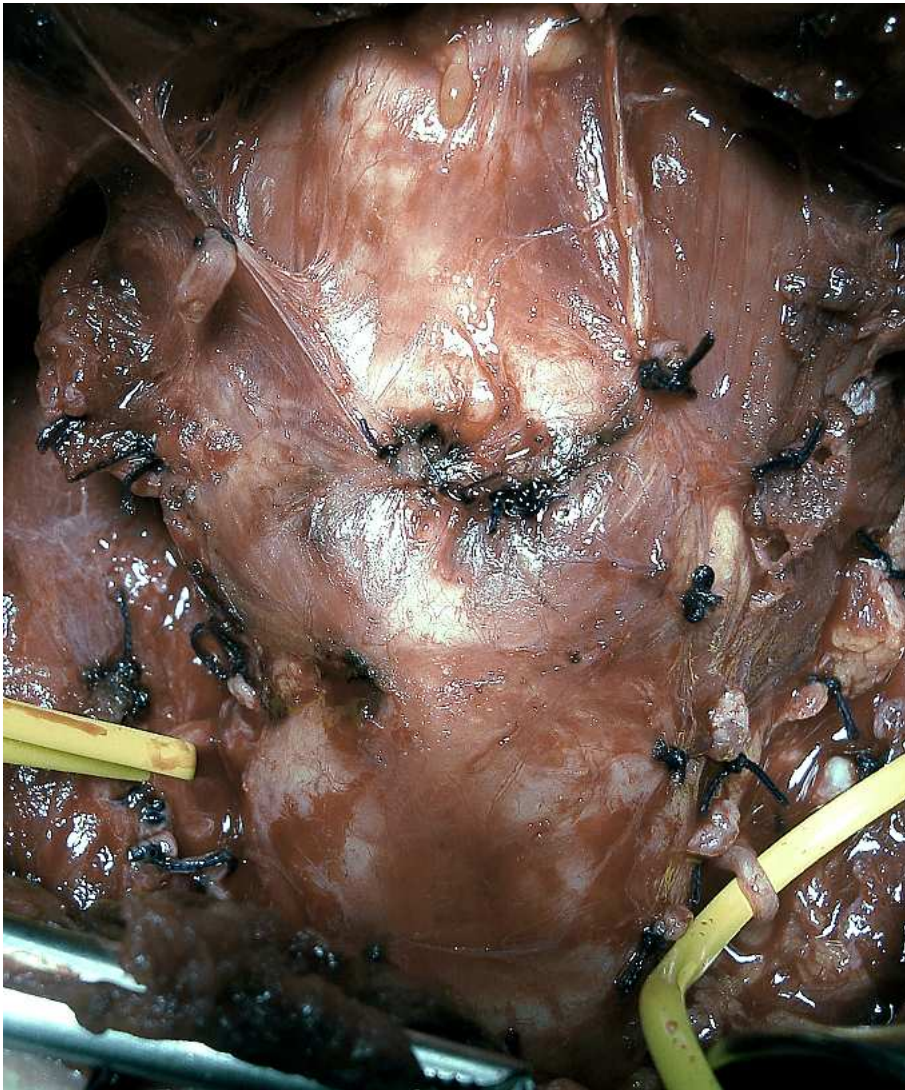Isolamento dei nervi laringei inferiori (ricorrenti)



Lobo destro - Istmo - Lobo sinistro (superficie anteriore)

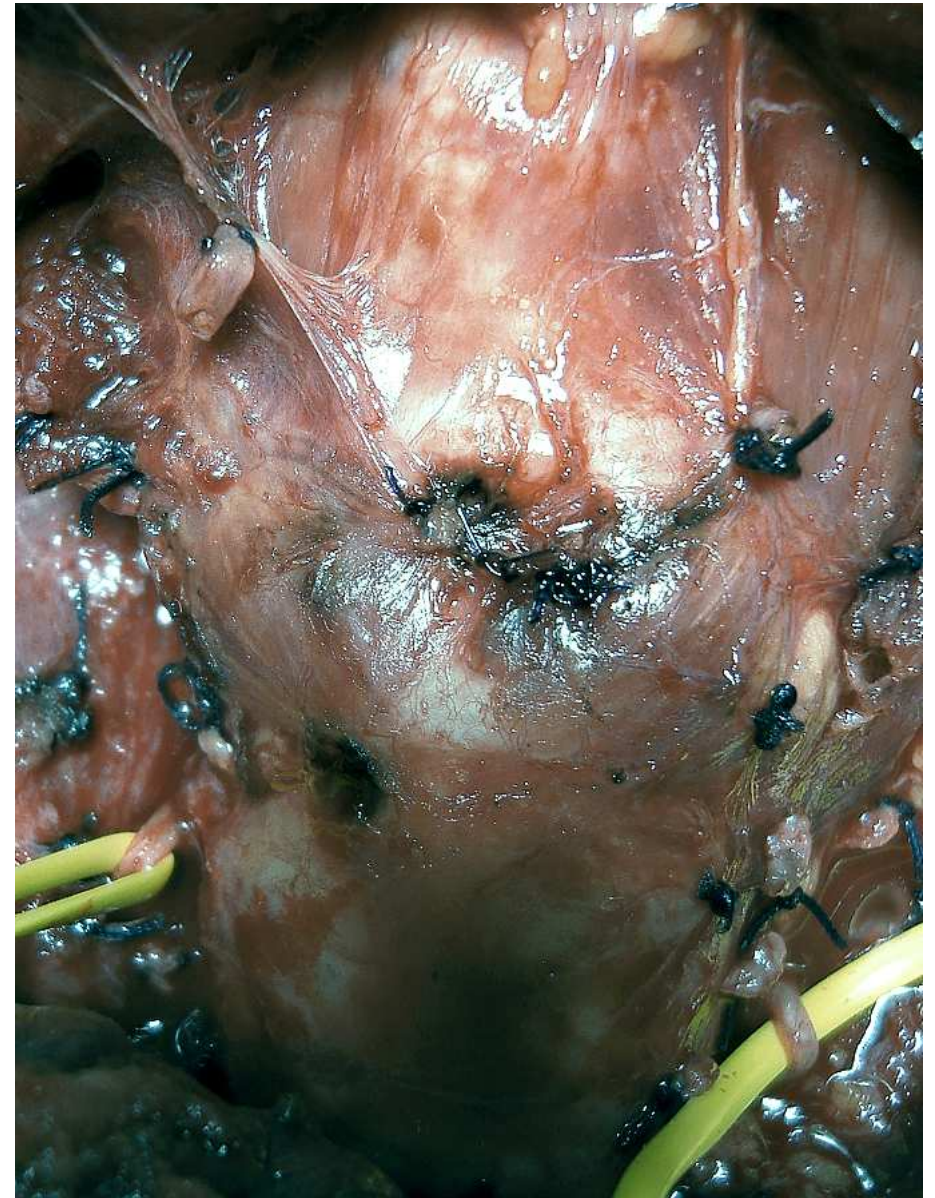


Lobo sinistro - Istmo - Lobo destro (superficie posteriore)

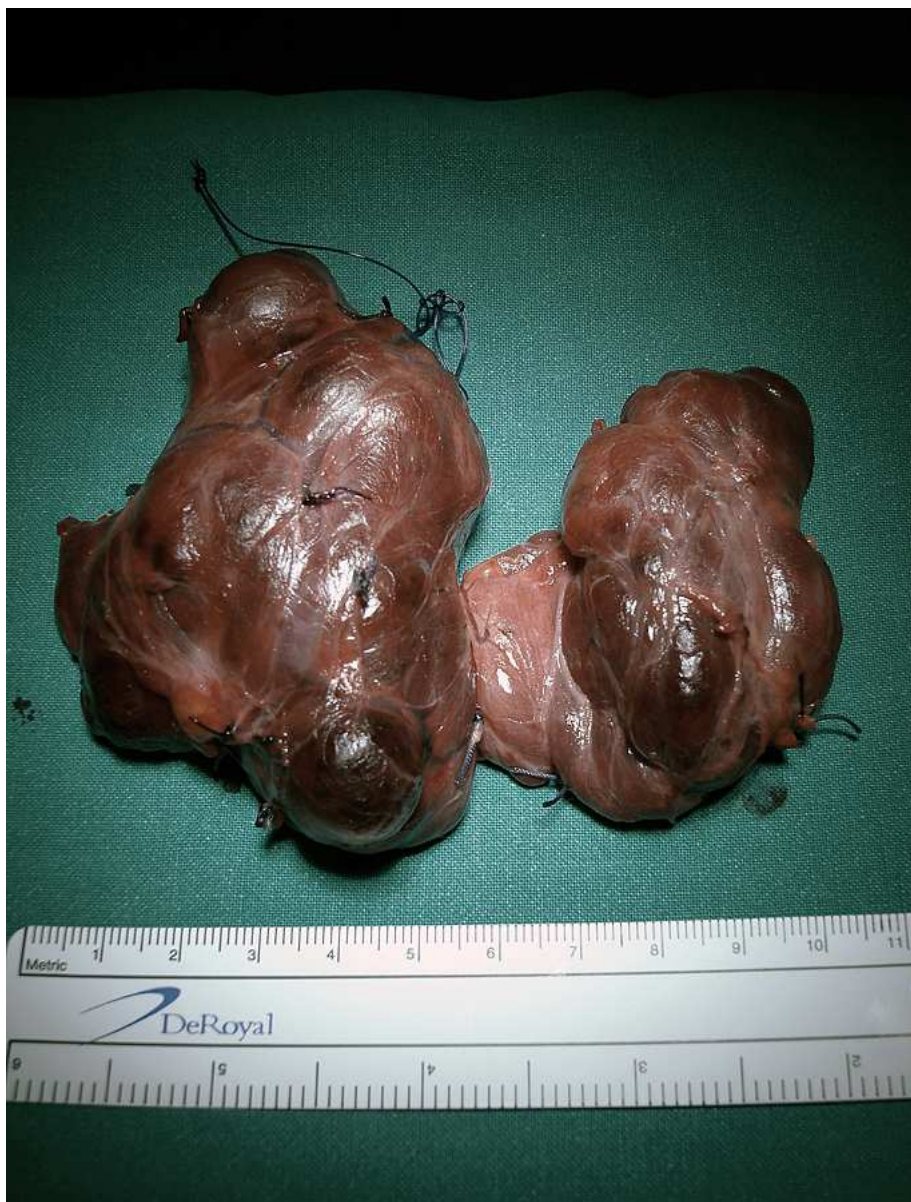

I.S. • Anni: 60 - M • Record: 24 • 31-05-2007

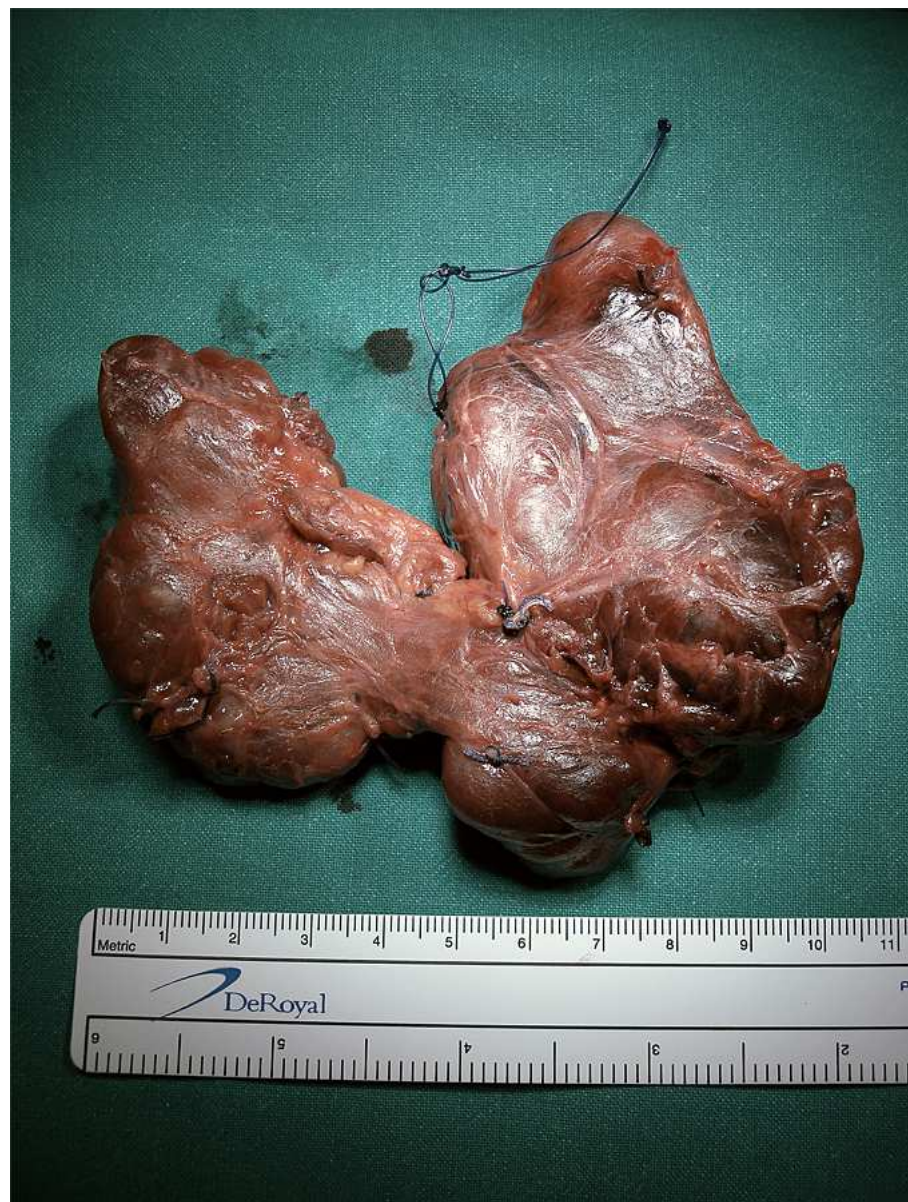Tiroidectomia totale extracapsulare per gozzo plurinodulare plongeant con sezione dei muscoli pretiroidei



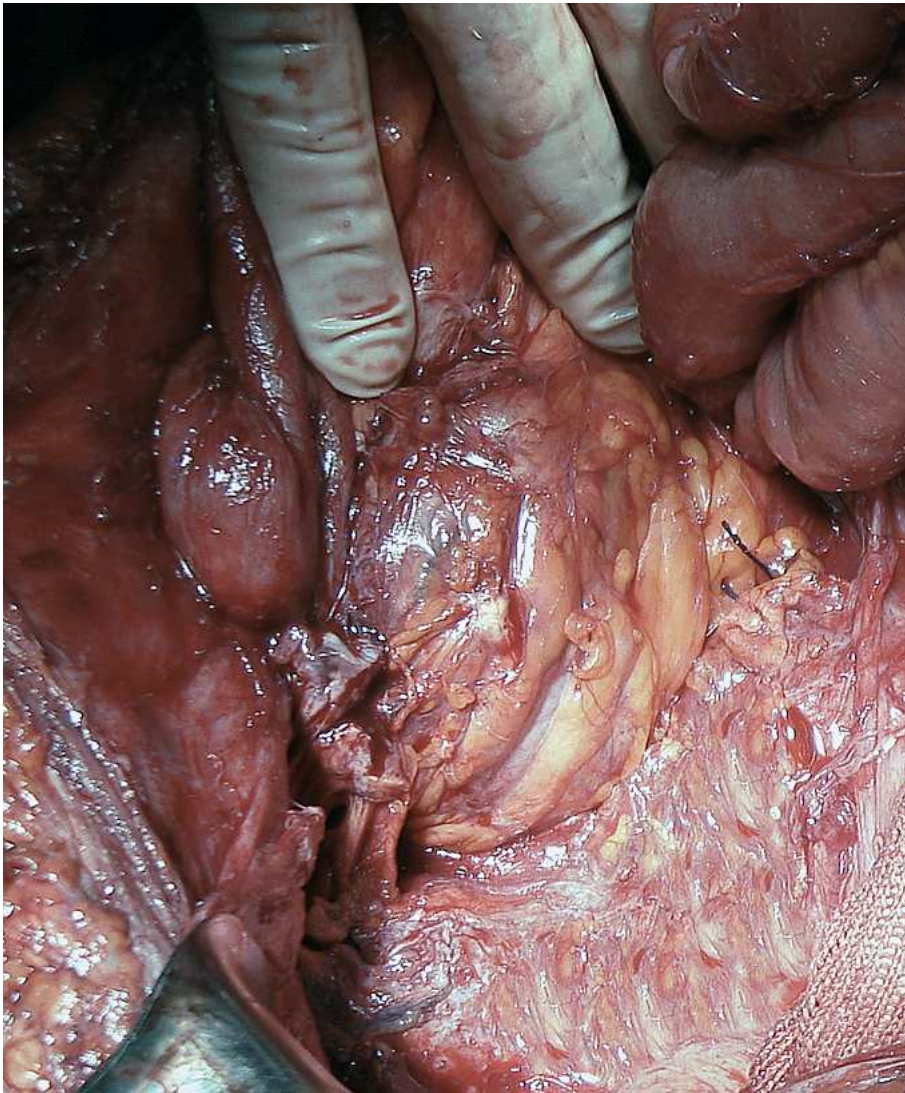
Isolamento dei nervi laringei inferiori (ricorrenti)



Lobo destro - Istmo - Lobo sinistro (superficie anteriore)

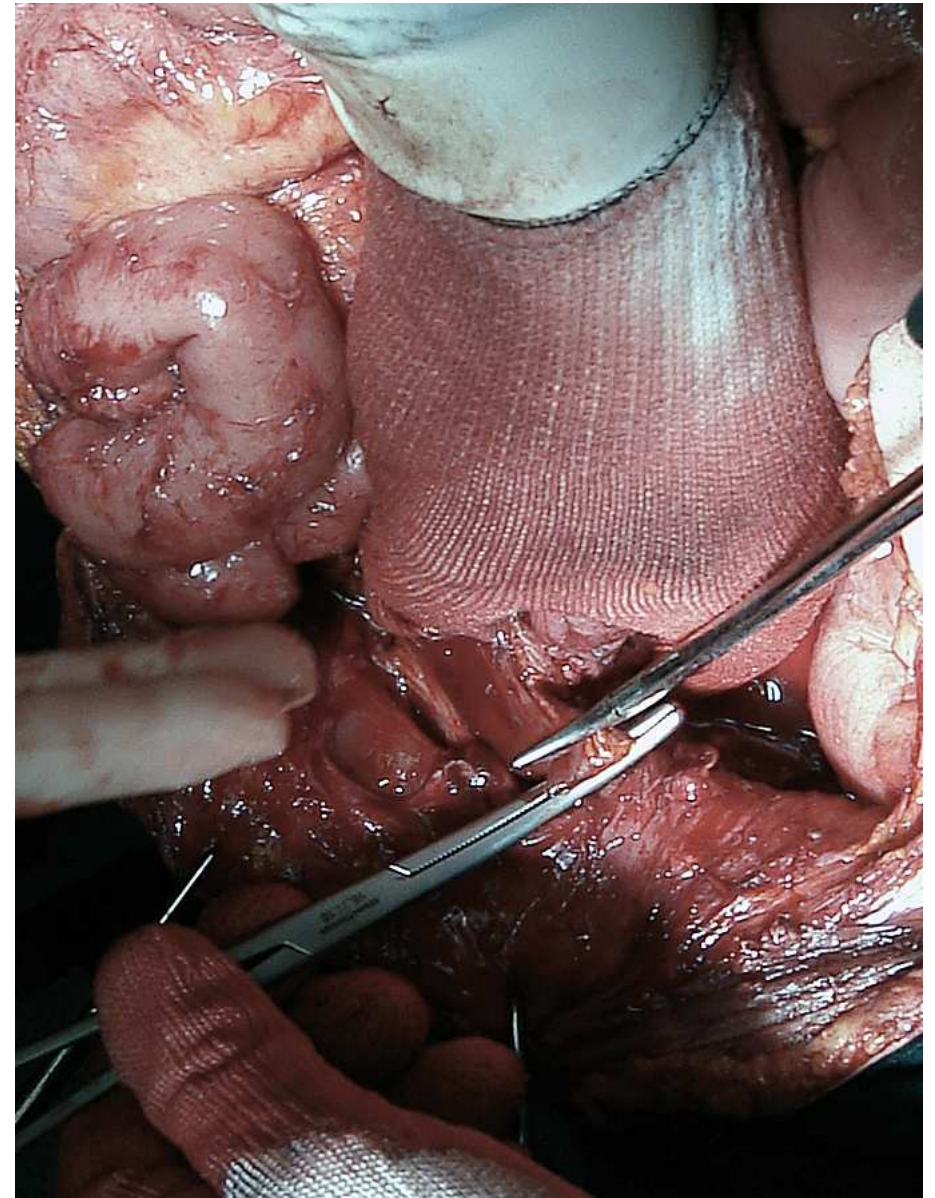


Lobo sinistro - Istmo - Lobo destro (superficie posteriore)

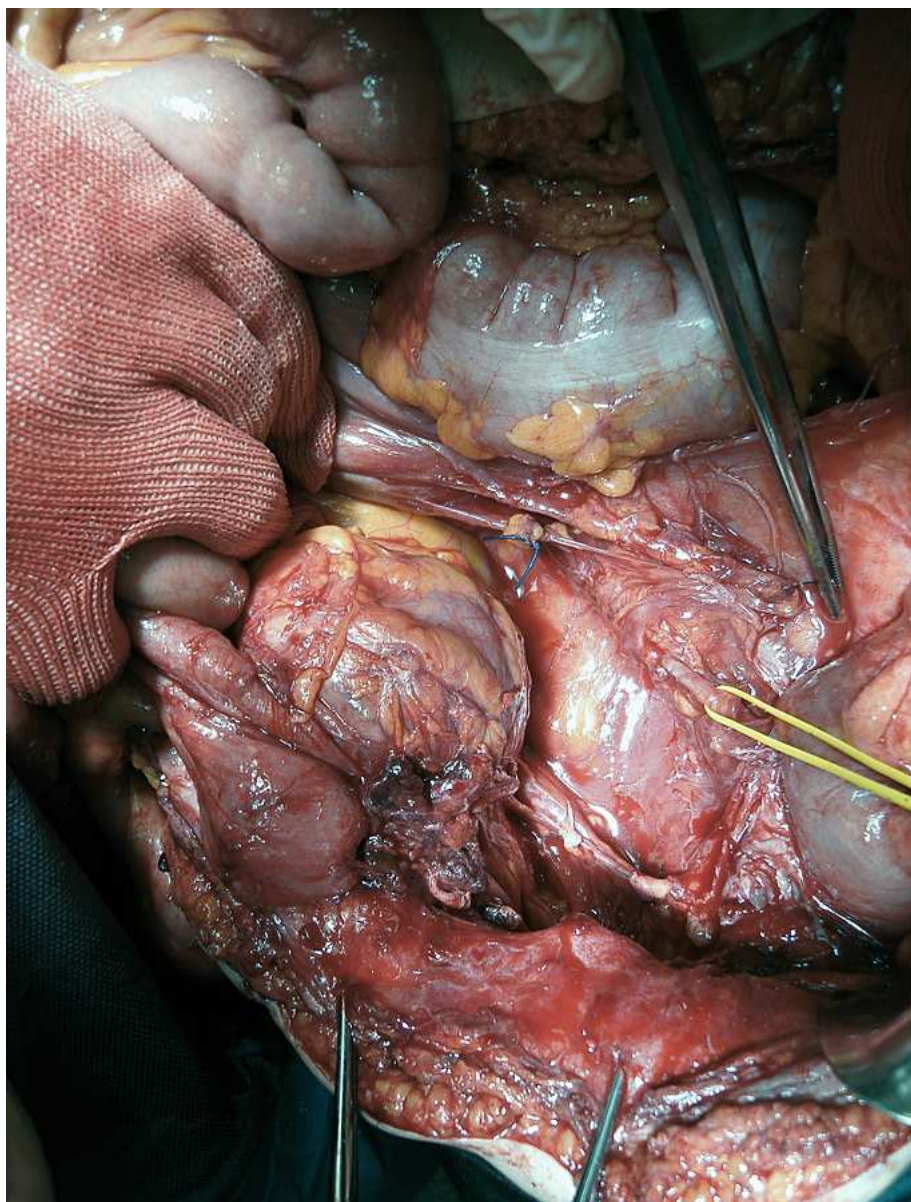


P.G. • Anni: 57 - F • Record: 25 • 31-05-2007

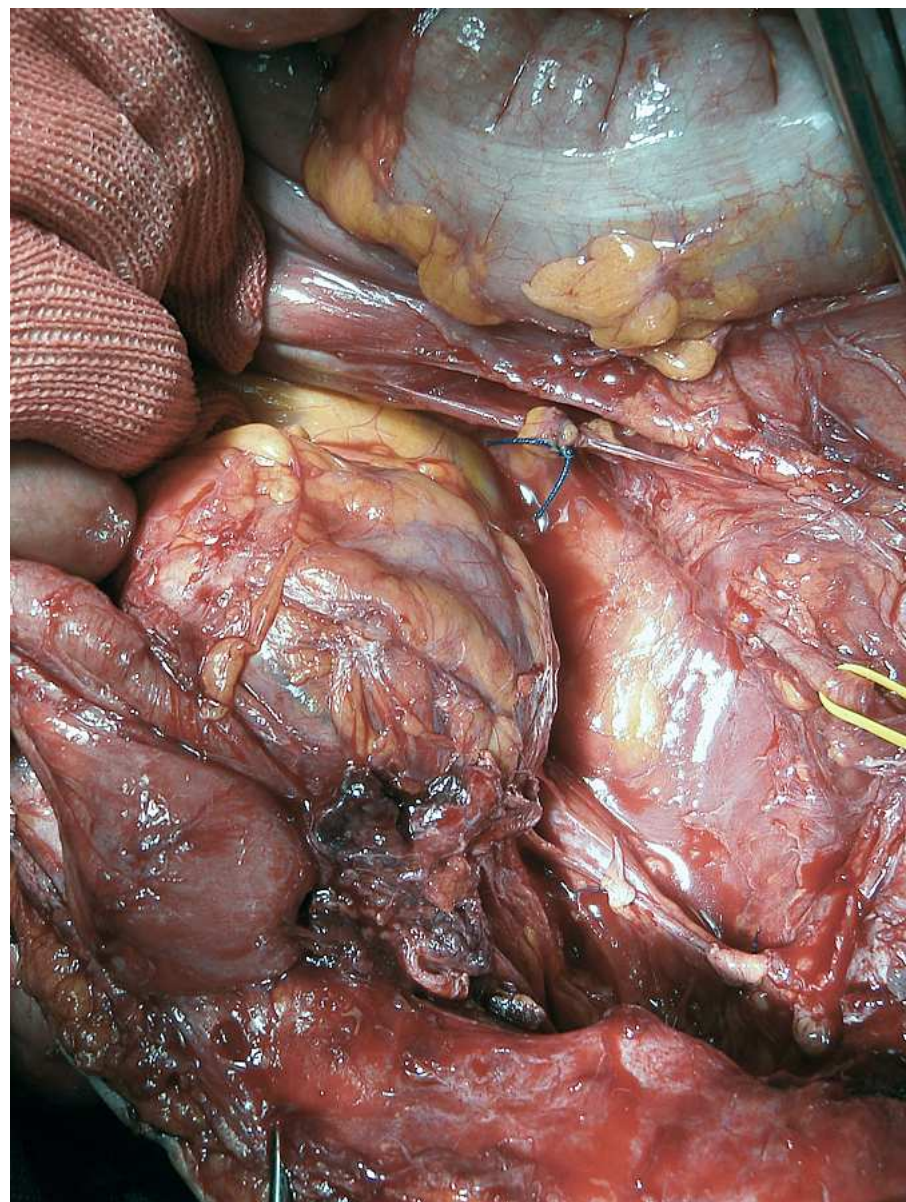
Emicolectomia dx allargata con linfadenectomia perimesenterica superiore per adenocarcinoma del colon dx in recente operata per presunto Ca ovarico



Resezione dei muscoli larghi della parete addominale

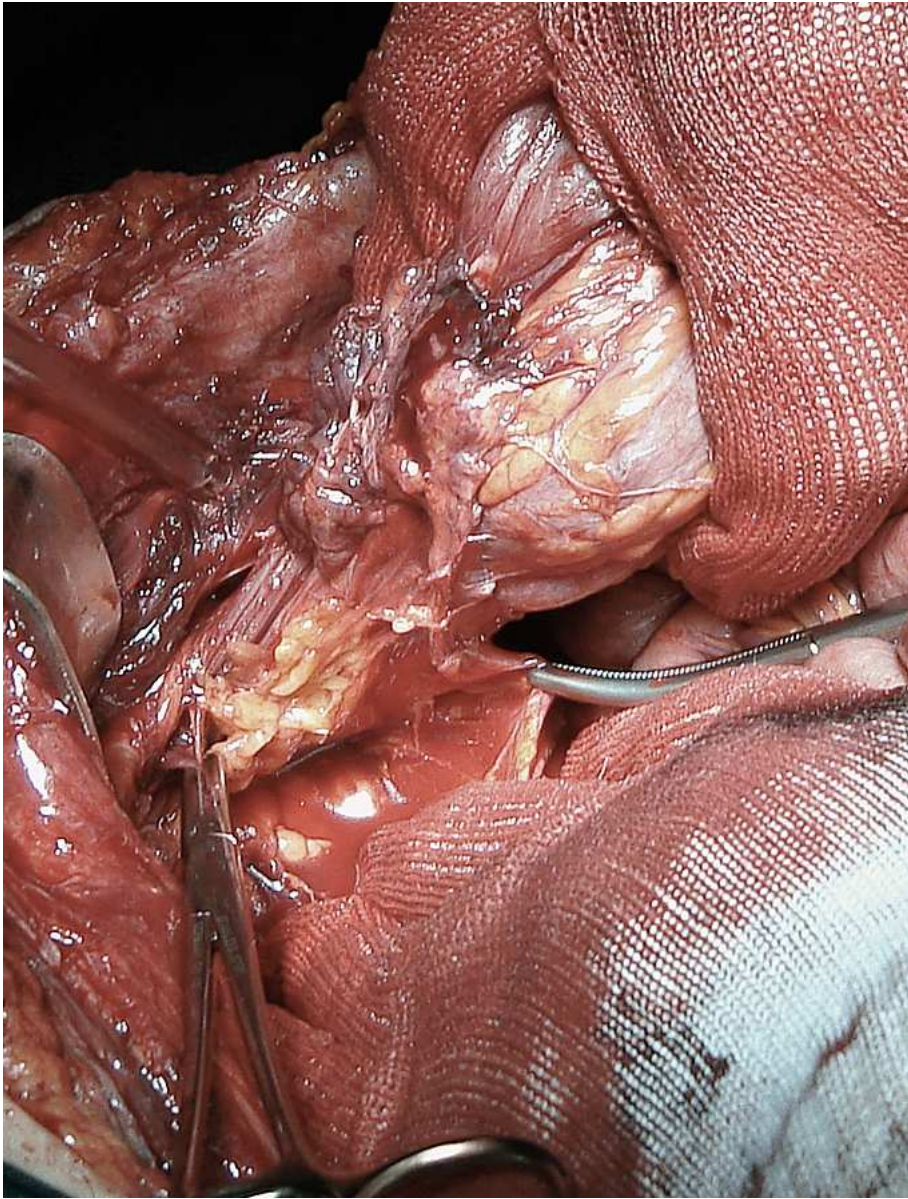


Preparazione retroperitoneale della parete posteriore del cieco ed isolamento dell'uretere dx

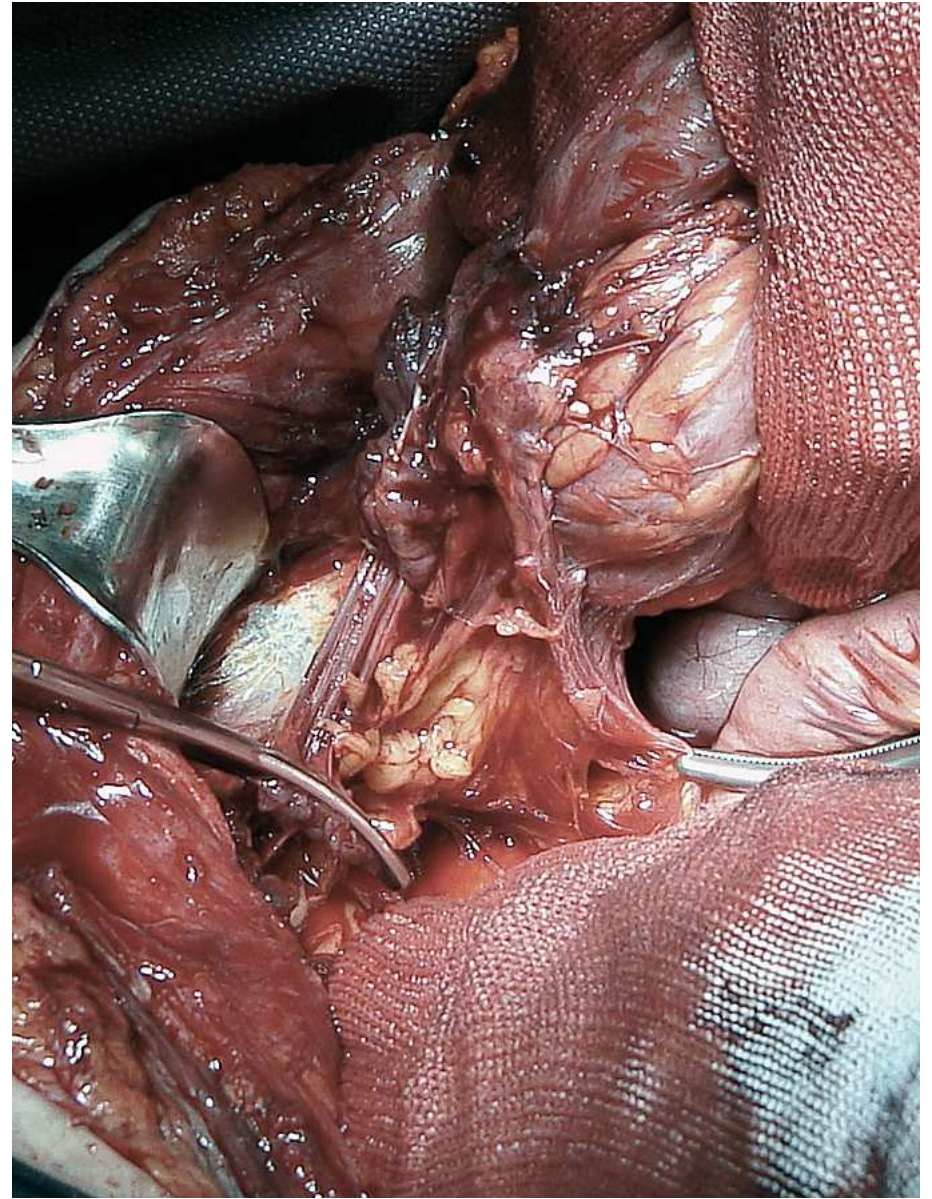


Apertura della regione retroperitoneale e preparazione della parete posteriore del cieco

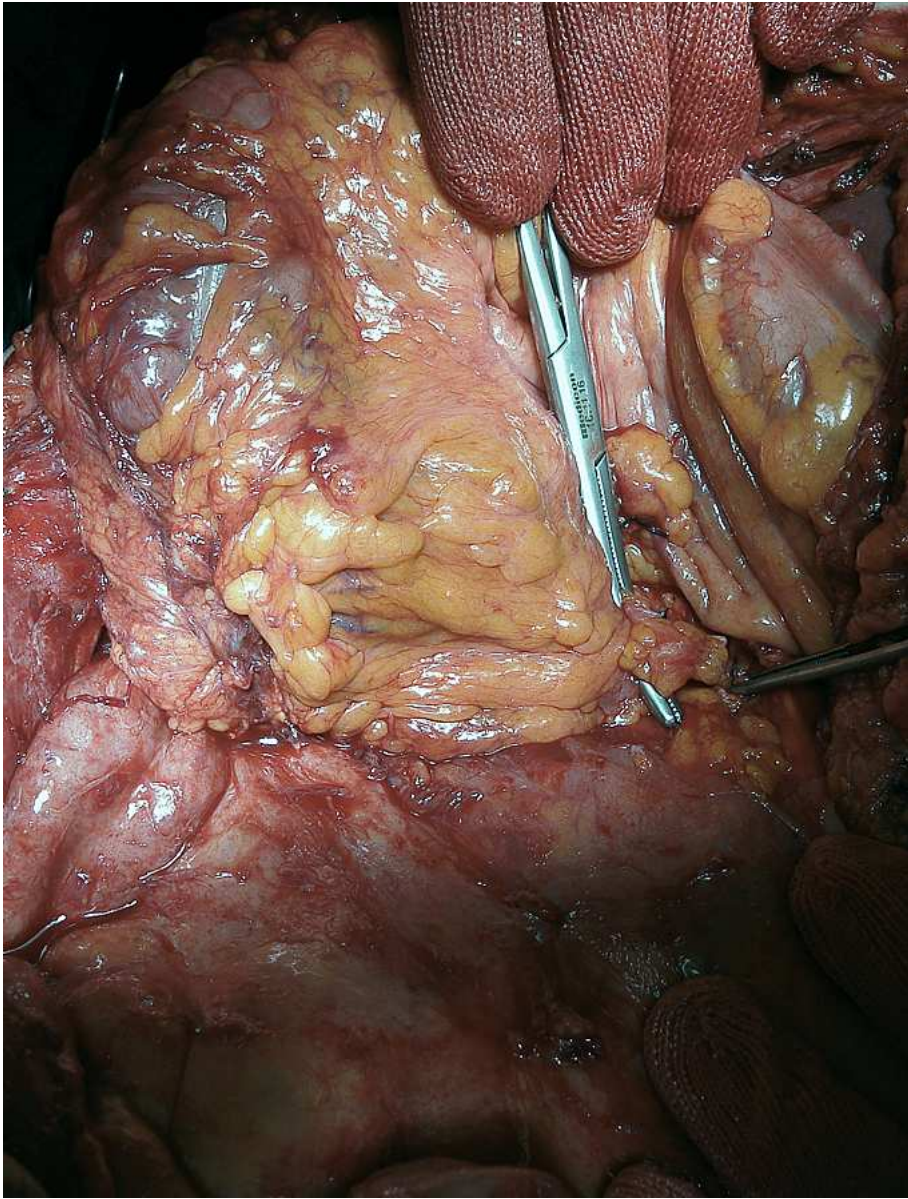




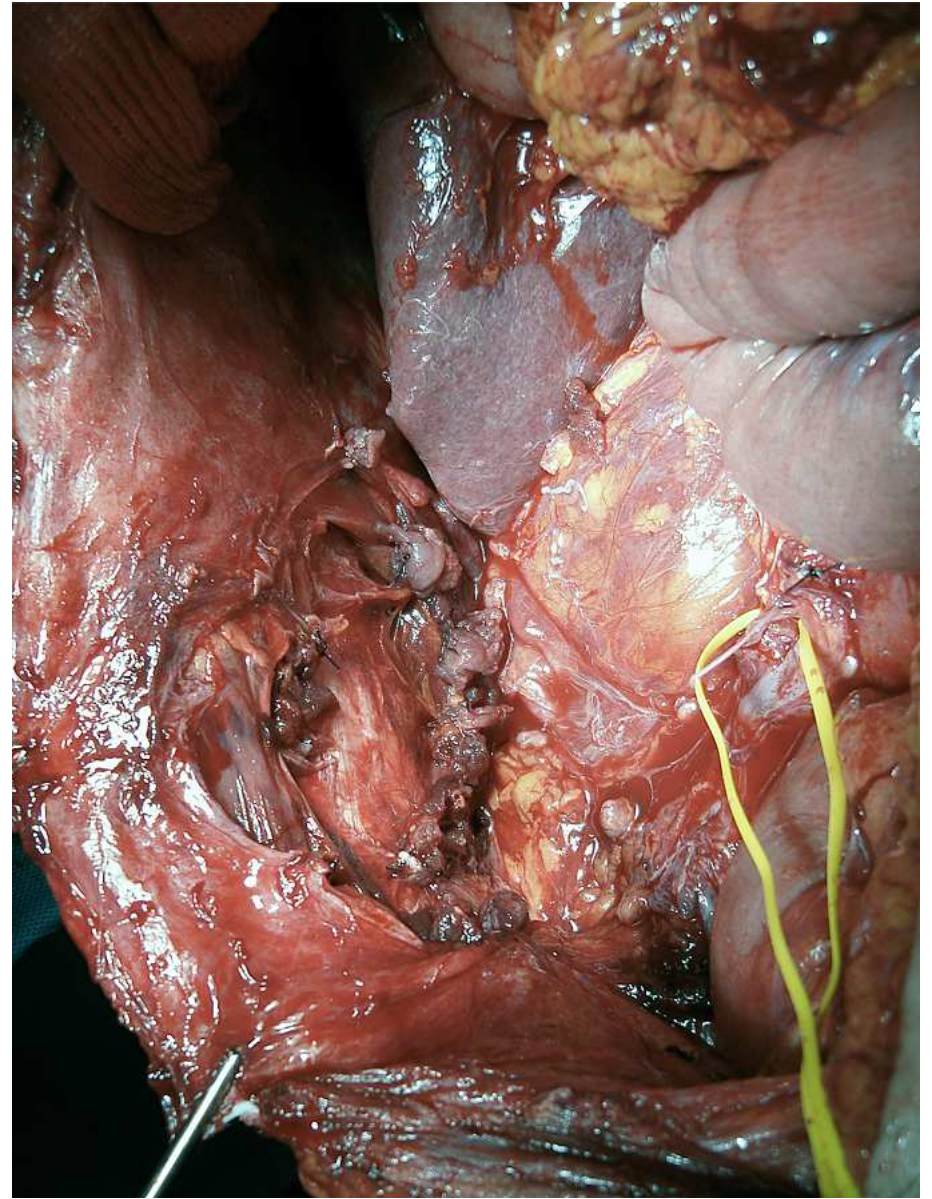
Preparazione e resezione parziale dei muscoli larghi dell'emiaddome dx



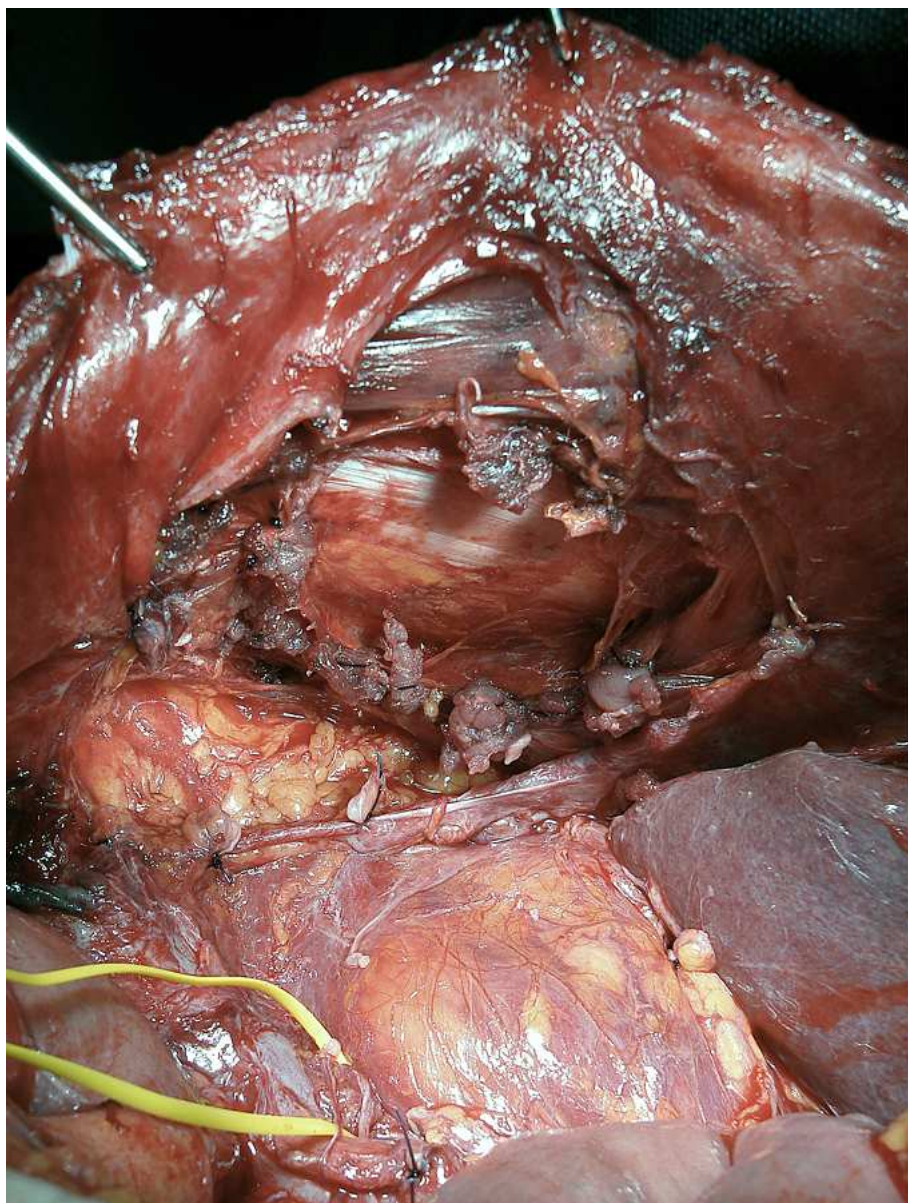
Preparazione e sezione dei vasi epigastrici inferiori infiltrati dalla massa neoplastica



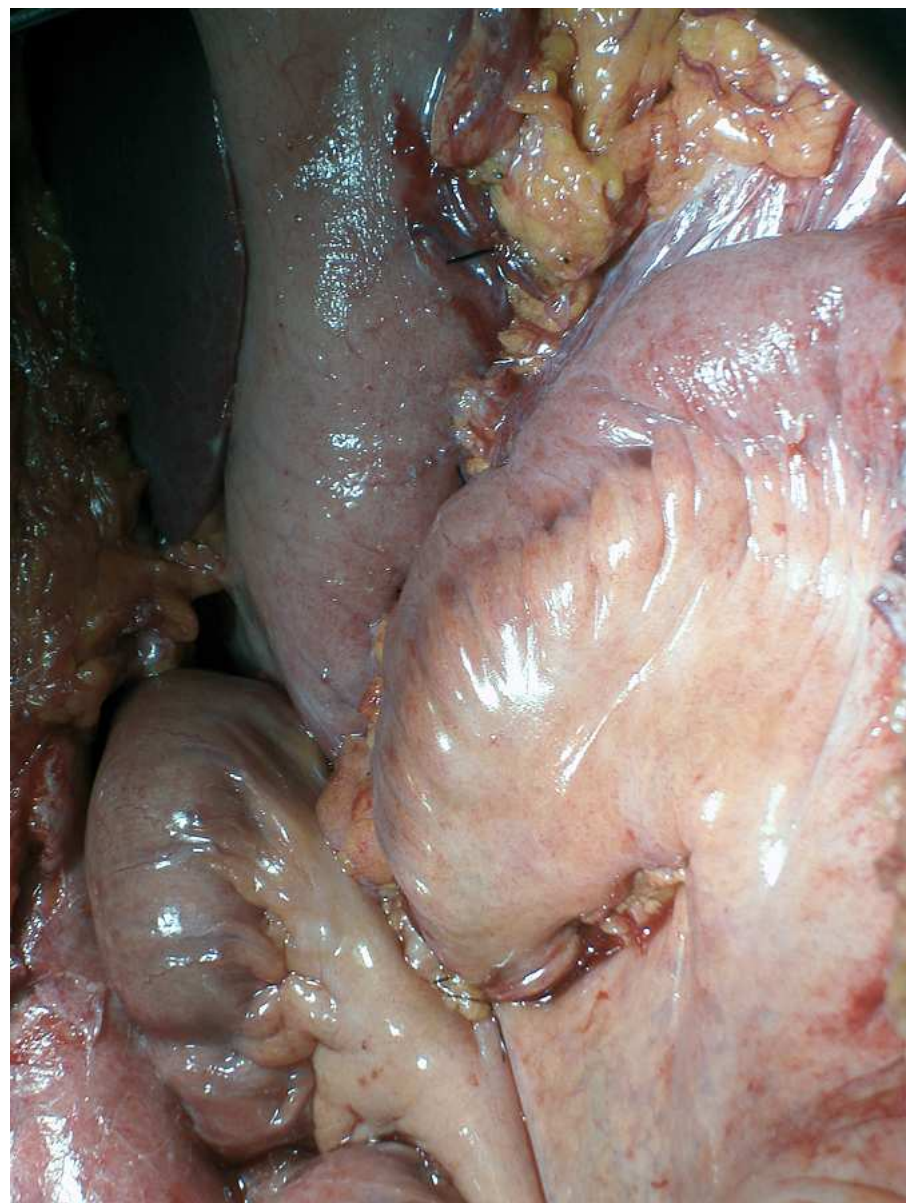Apertura del mesentere ed inizio della linfadenectomia perimesenterica superiore



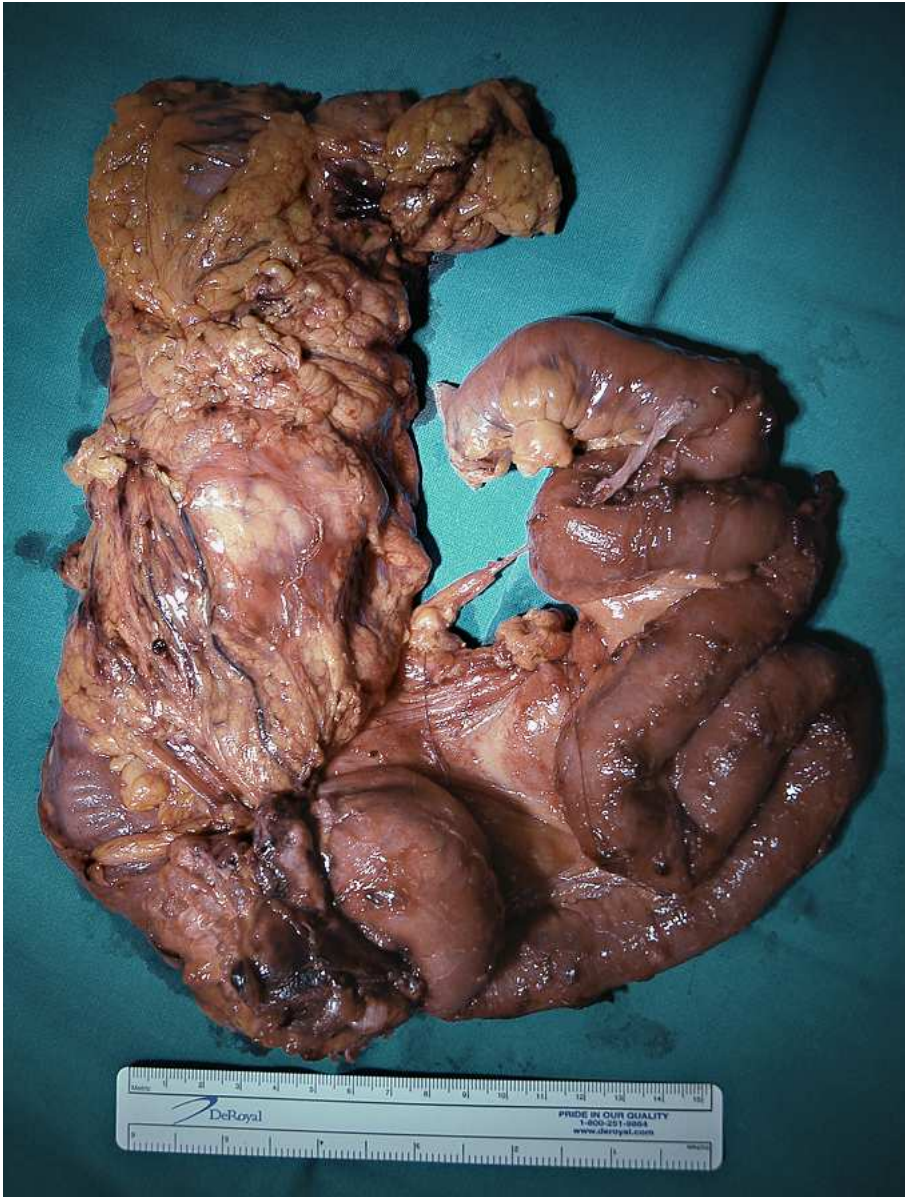Visione del cavo addominale al termine dell'emicolectomia dx allargata



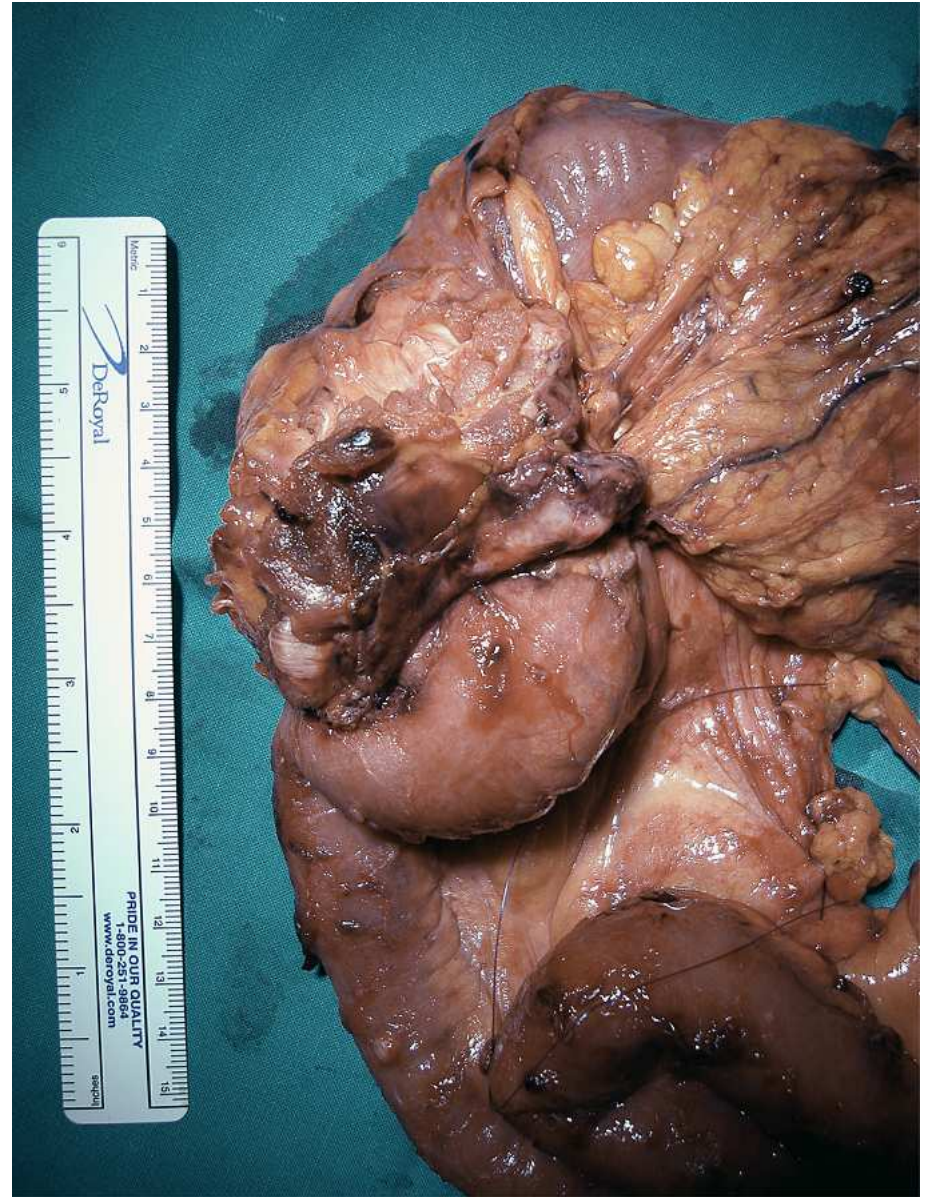Asportazione parziale del peritoneo parietale, della fascia posteriore e dei muscoli larghi



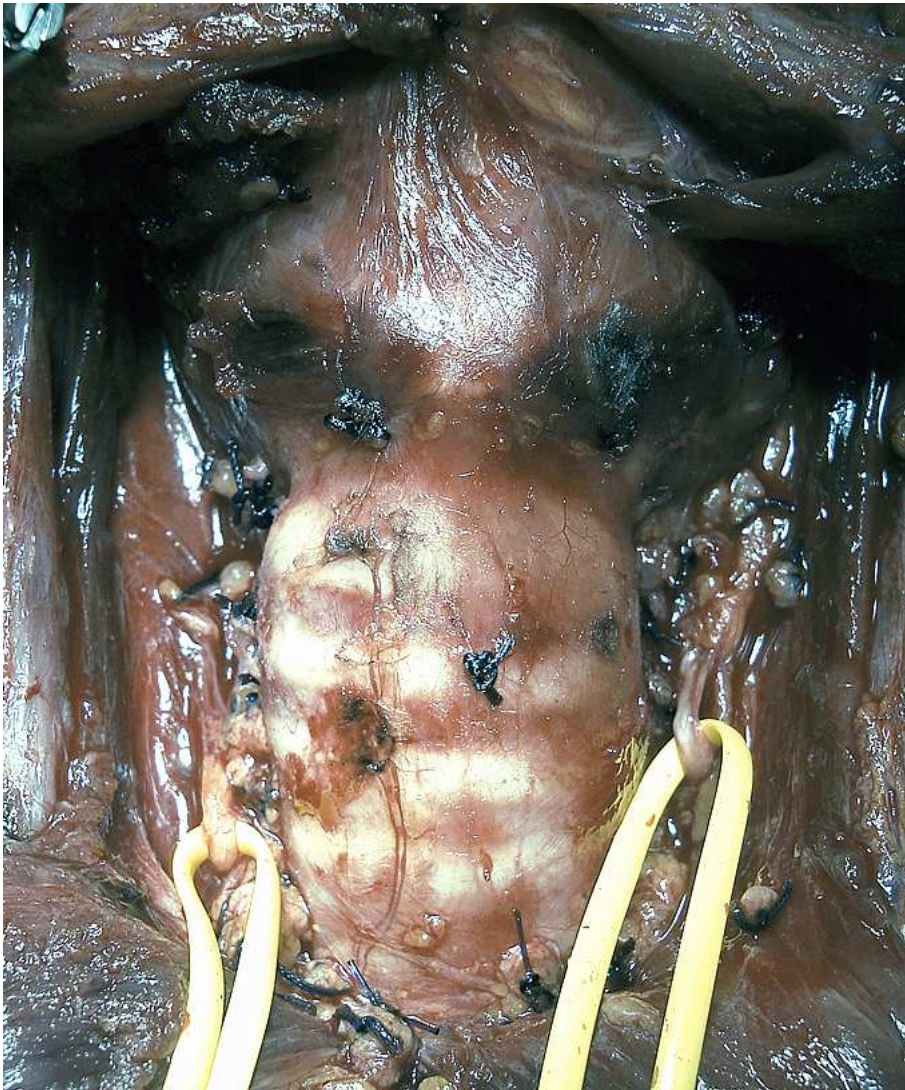Ileo-trasversostomia L.L. anisoperistaltica in duplice strato (GIA 55 - Monocryl 3/0)



Emicolectomia dx allargata con linfadenectomia perimesenterica superiore

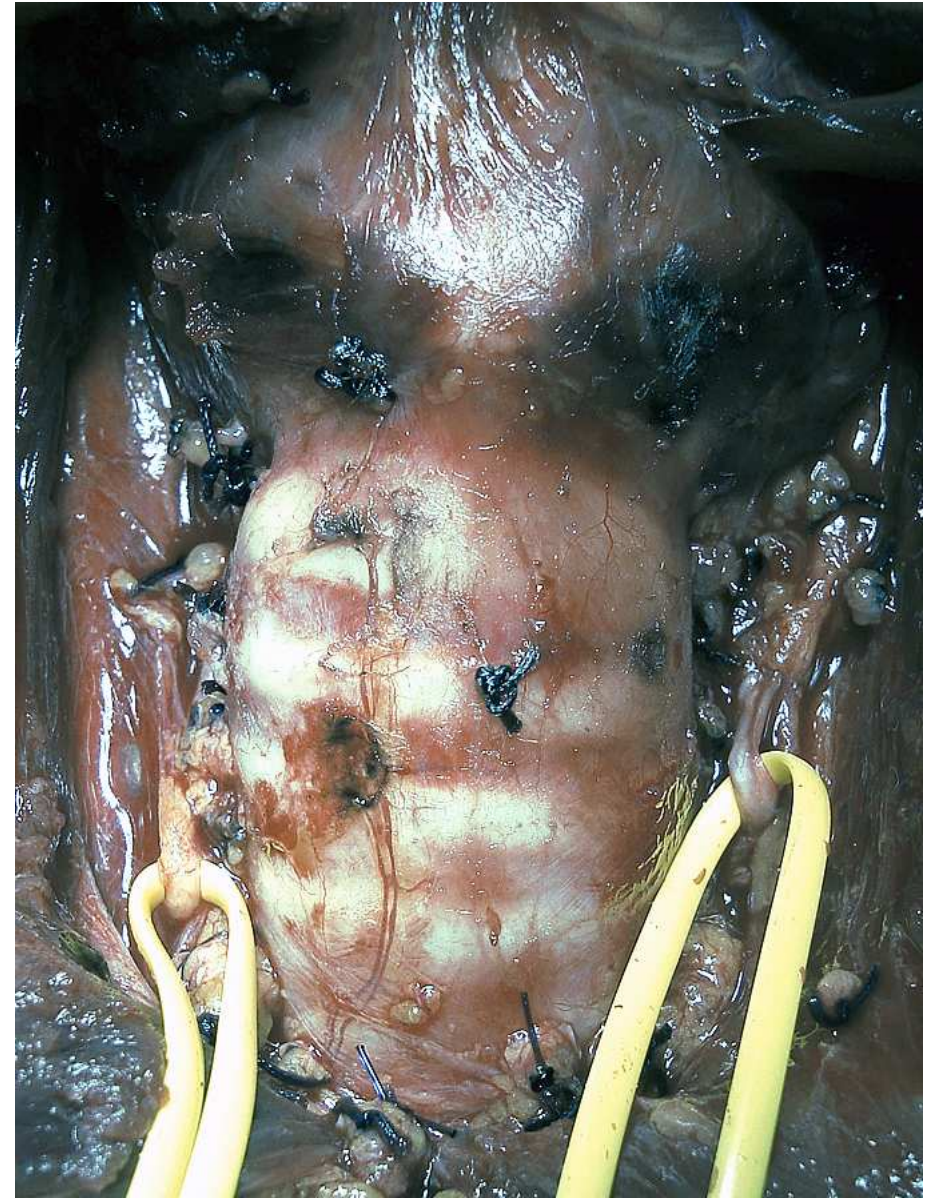


Neoplasia del cieco-ascendente

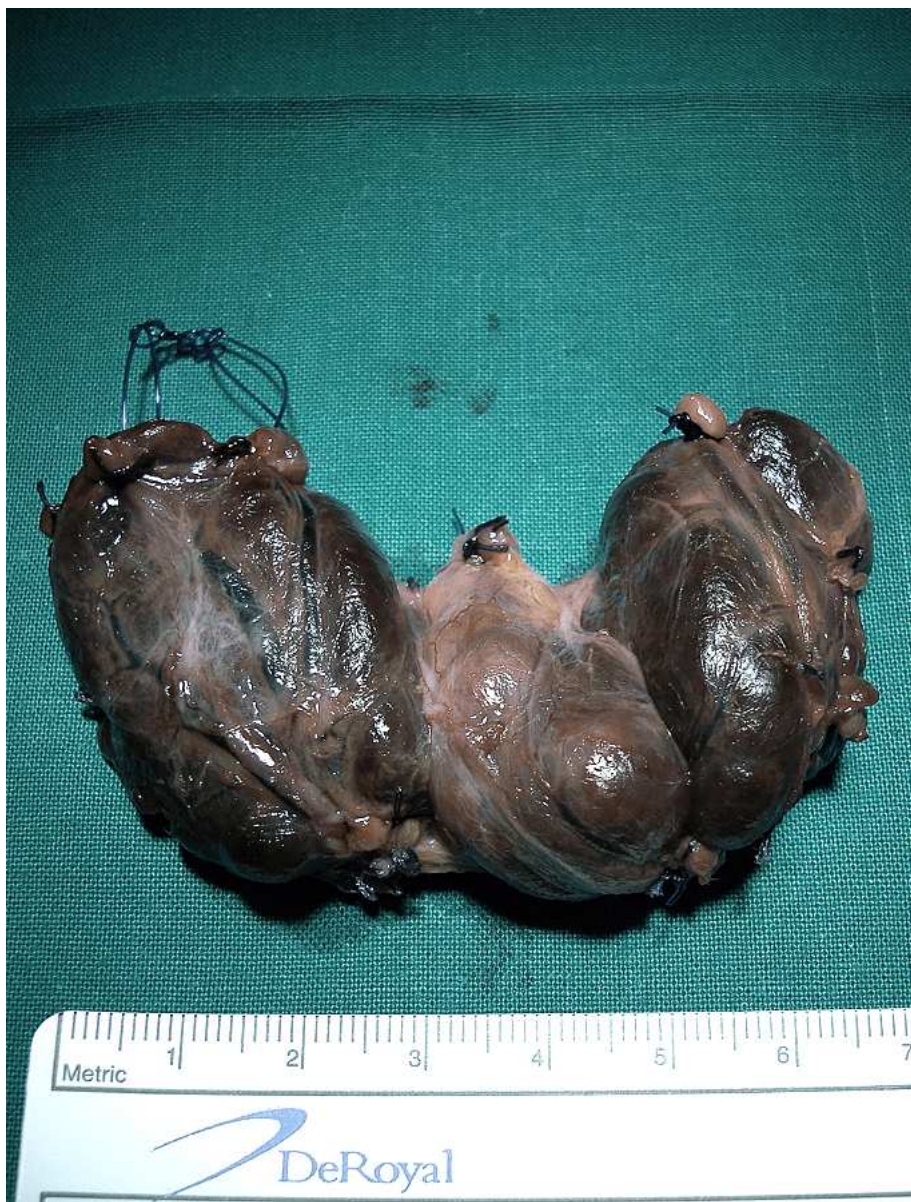

S.G. • Anni: 48 - M • Record: 26 • 07-06-2007

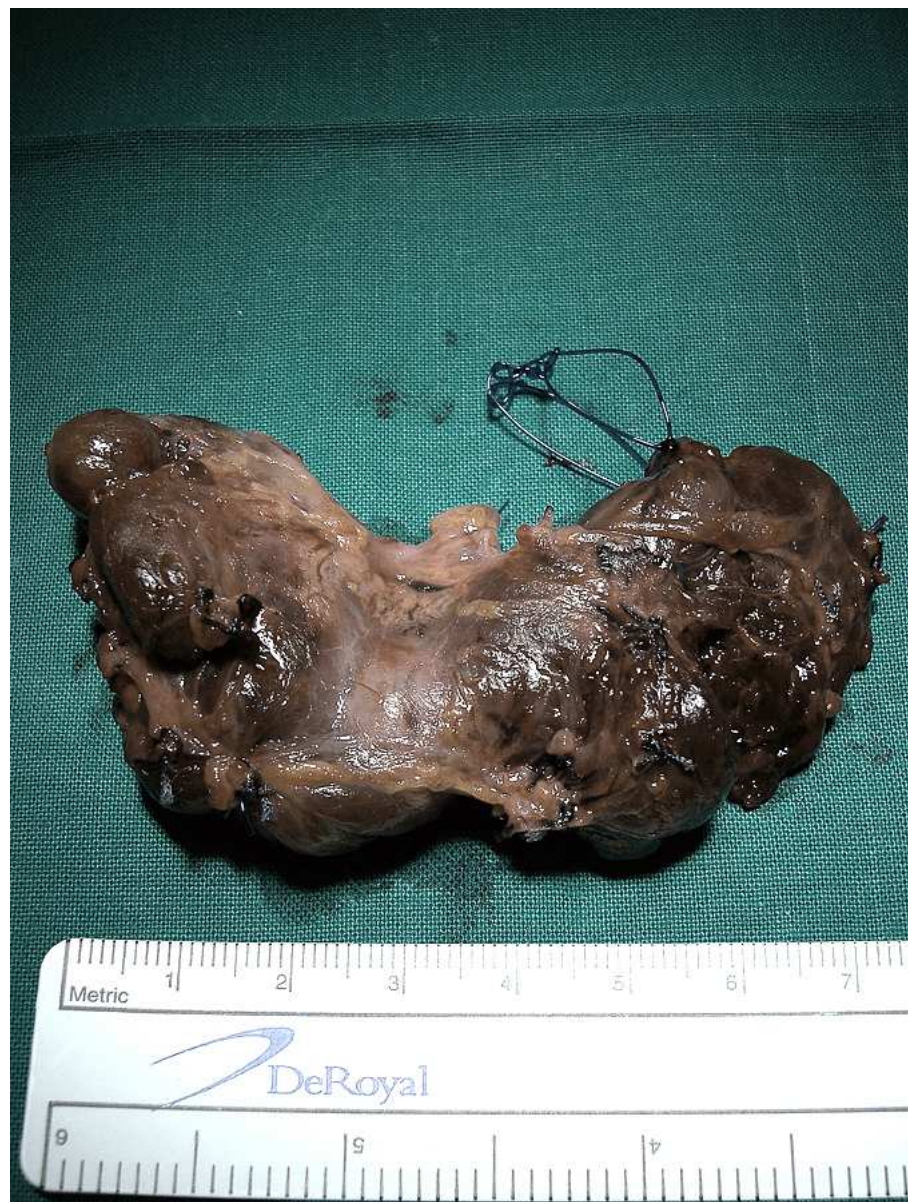Tiroidectomia totale extracapsulare per gozzo plurinodulare con sezione dei muscoli pretiroidei



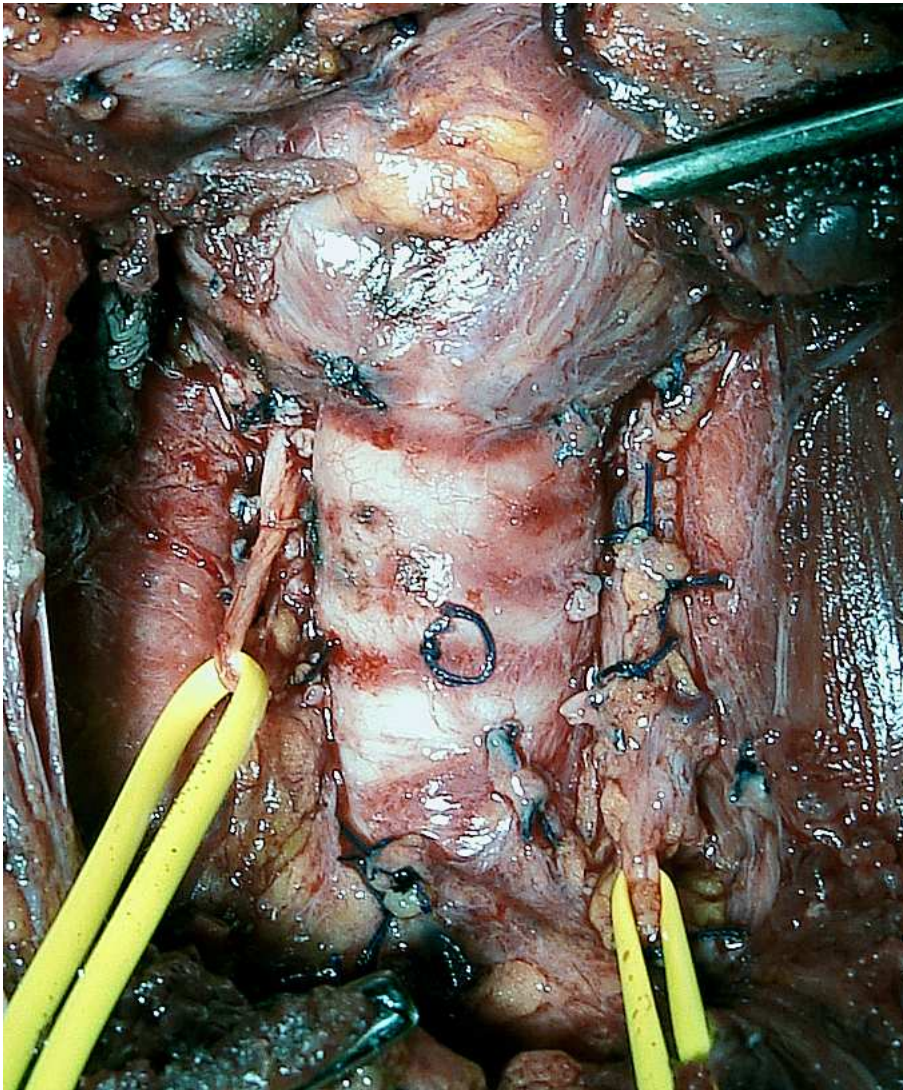
Isolamento dei nervi laringei inferiori (ricorrenti)



Lobo destro - Istmo - Lobo sinistro (superficie anteriore)

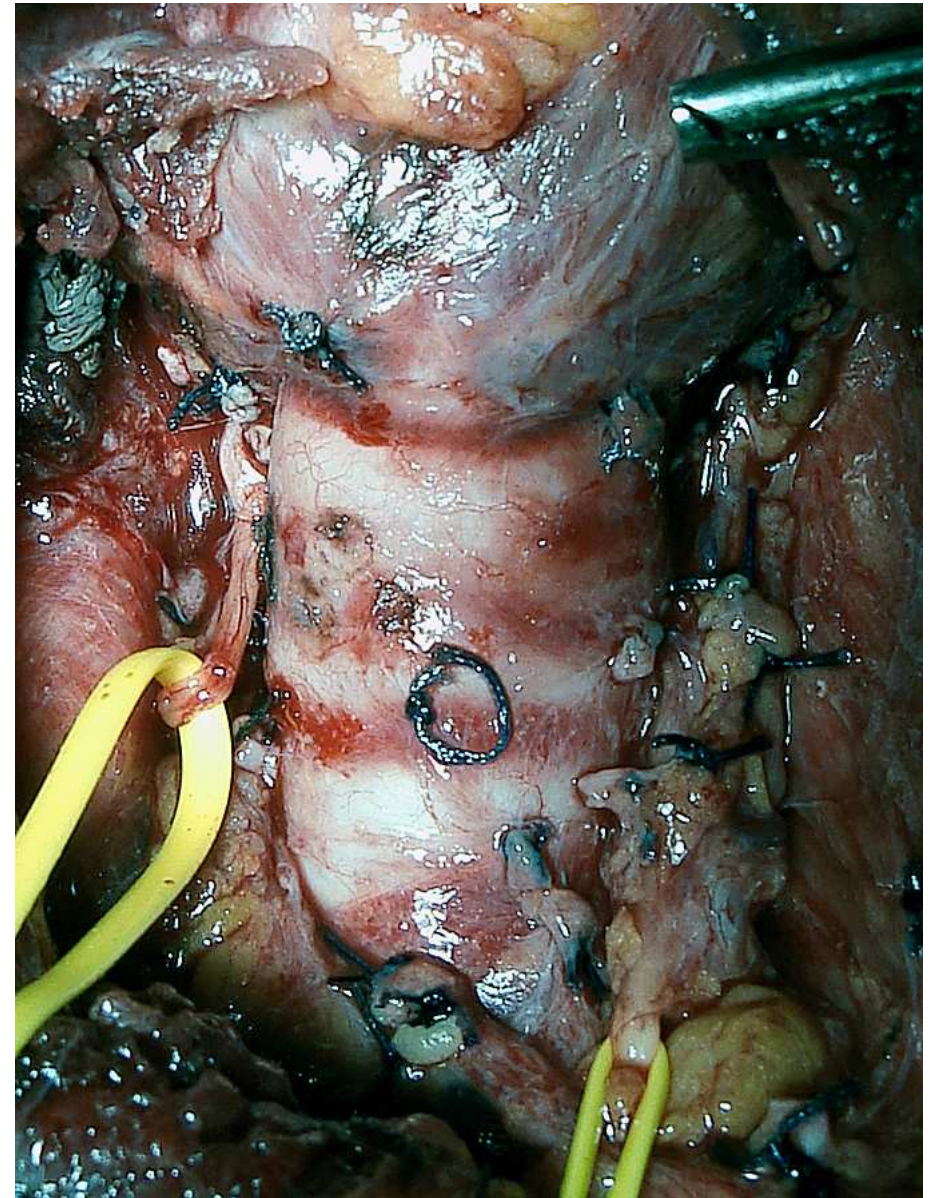


Lobo sinistro - Istmo - Lobo destro (superficie posteriore)

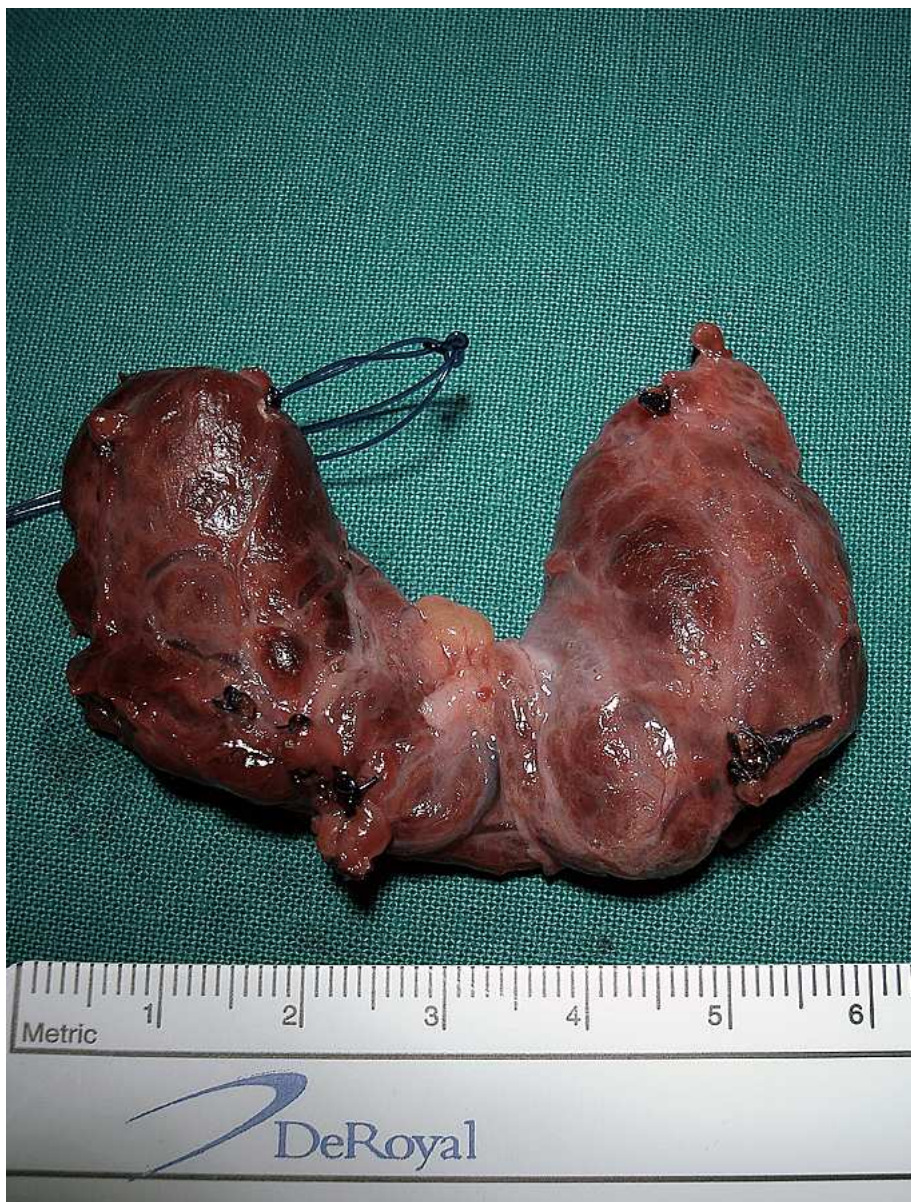

M.M. • Anni: 62 - F • Record: 27 • 07-06-2007

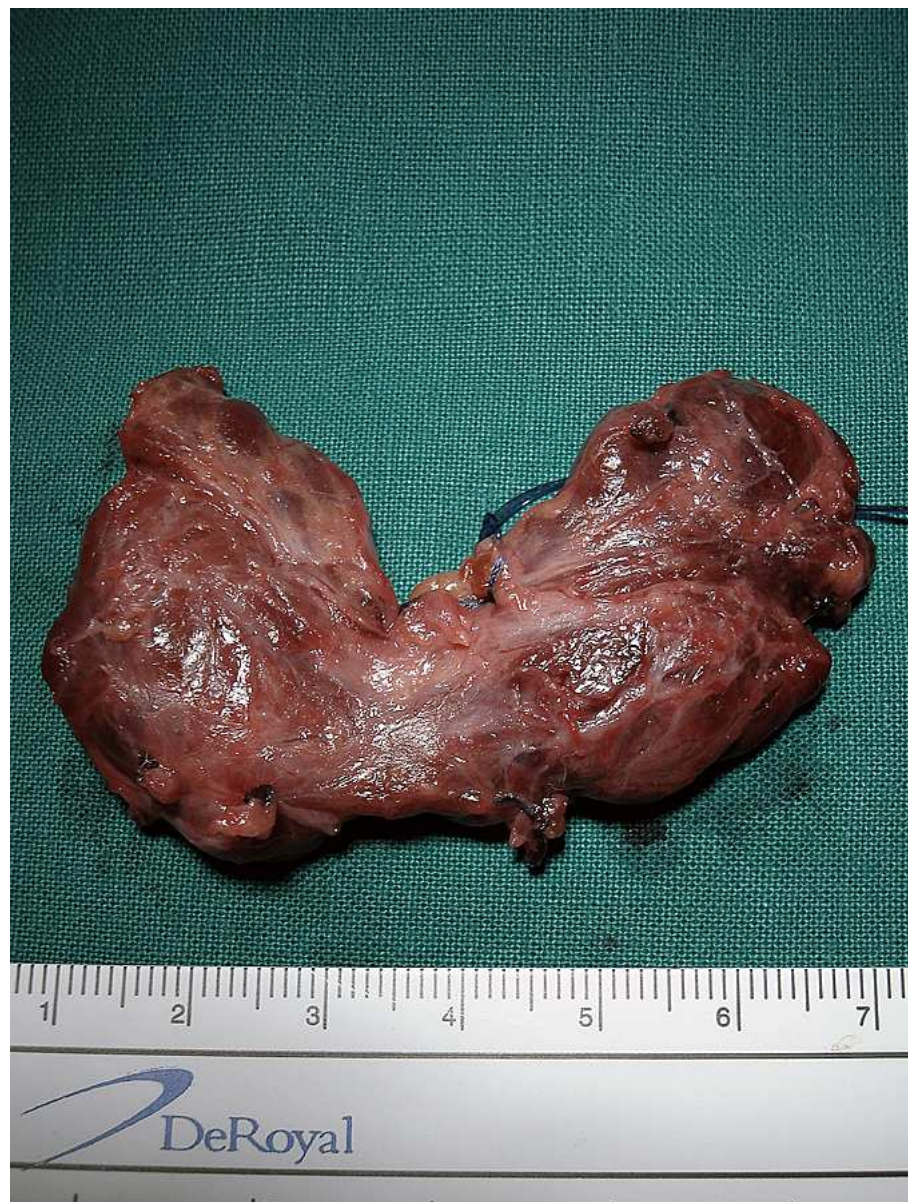Tiroidectomia totale extracapsulare per gozzo plurinodulare con sezione dei muscoli pretiroidei



Isolamento dei nervi laringei inferiori (ricorrenti)

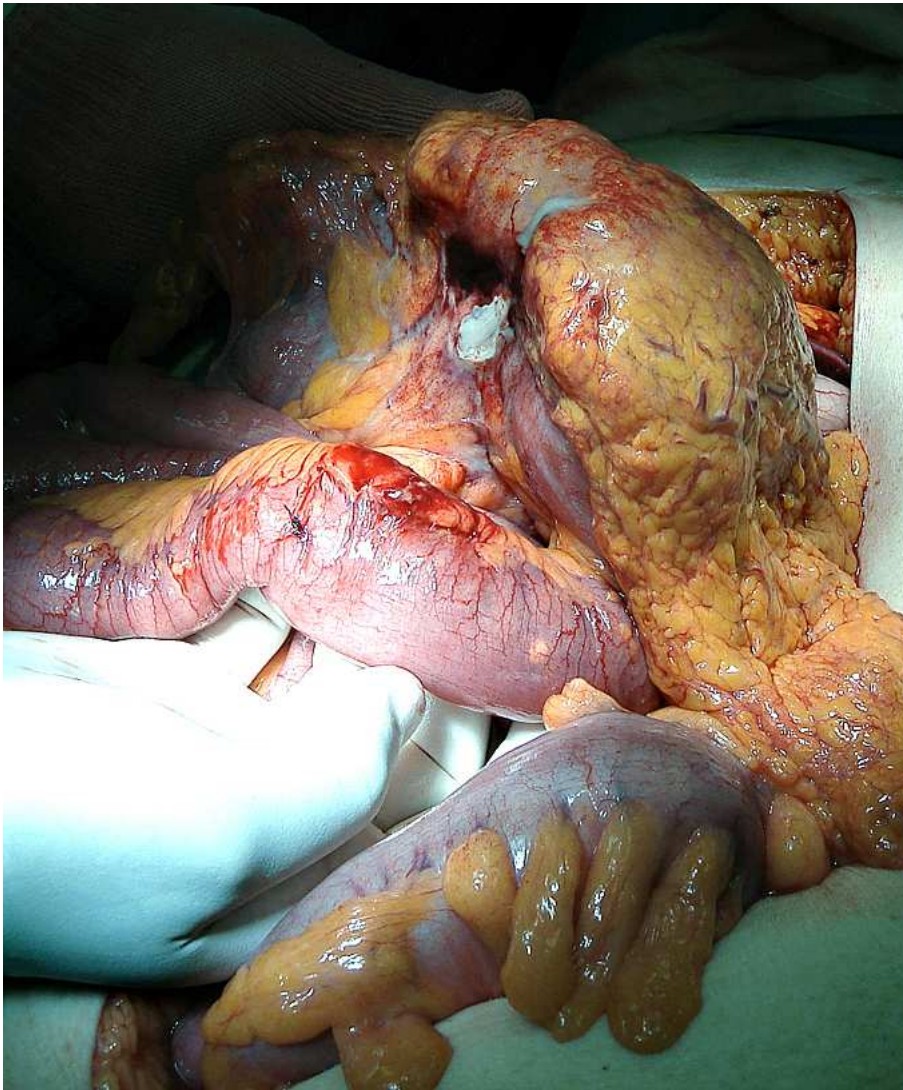

Lobo destro - Istmo - Lobo sinistro (superficie anteriore)



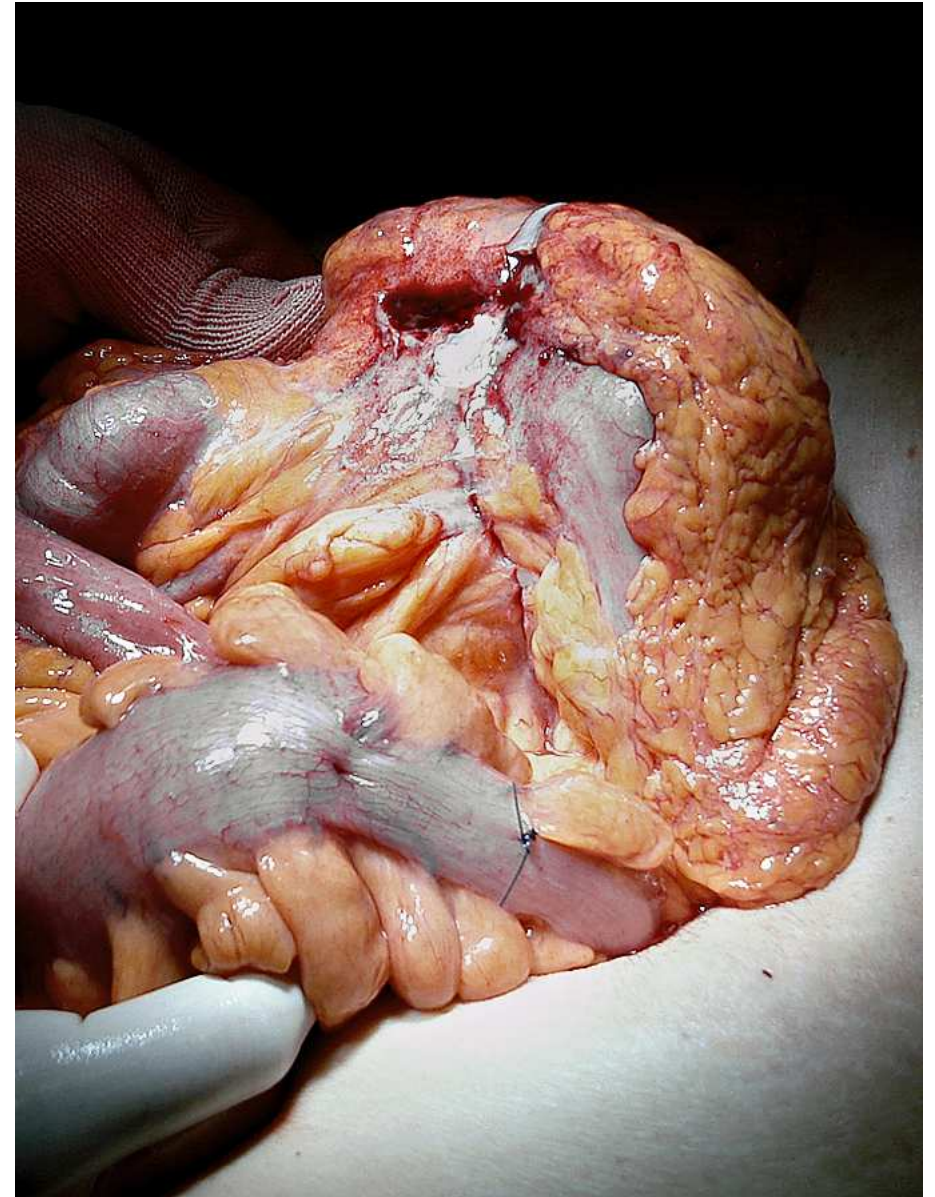
Lobo sinistro - Istmo - Lobo destro (superficie posteriore)

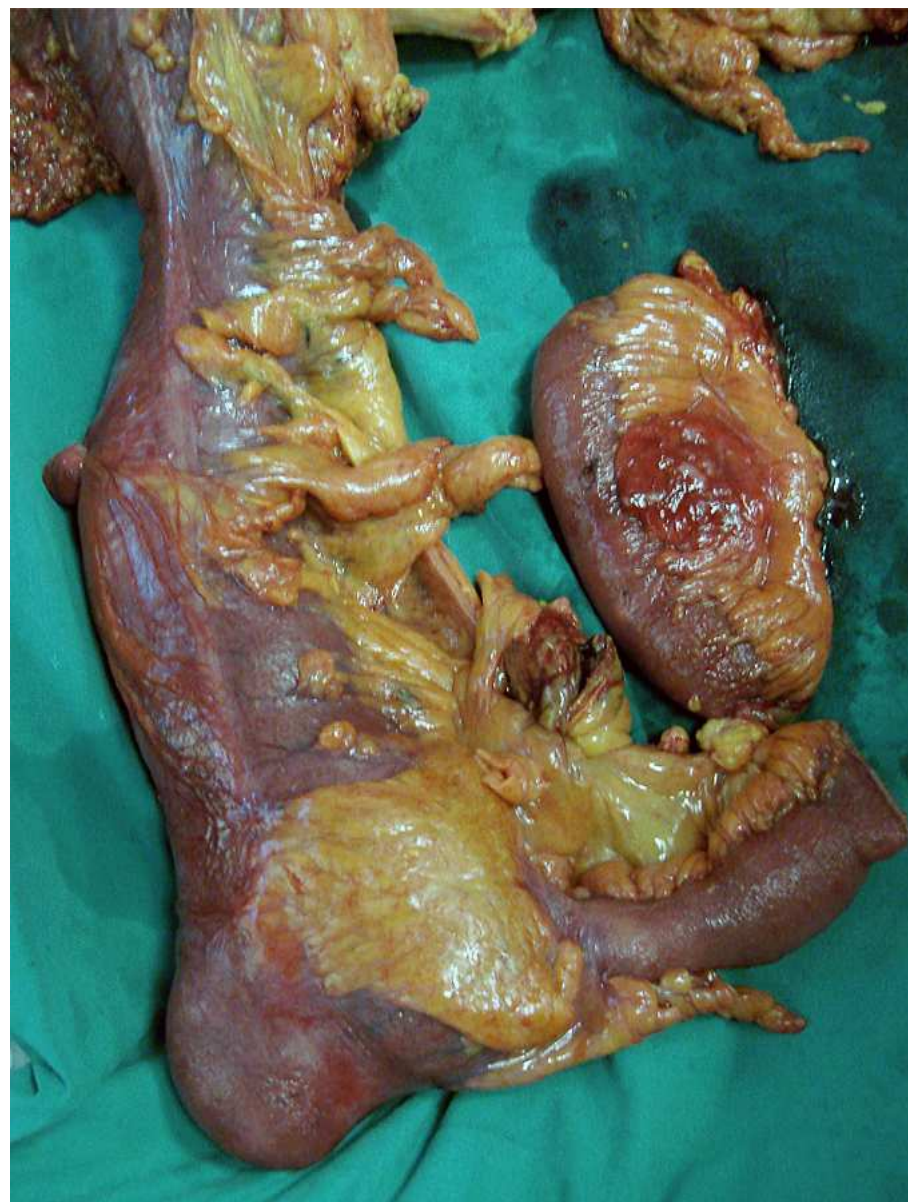
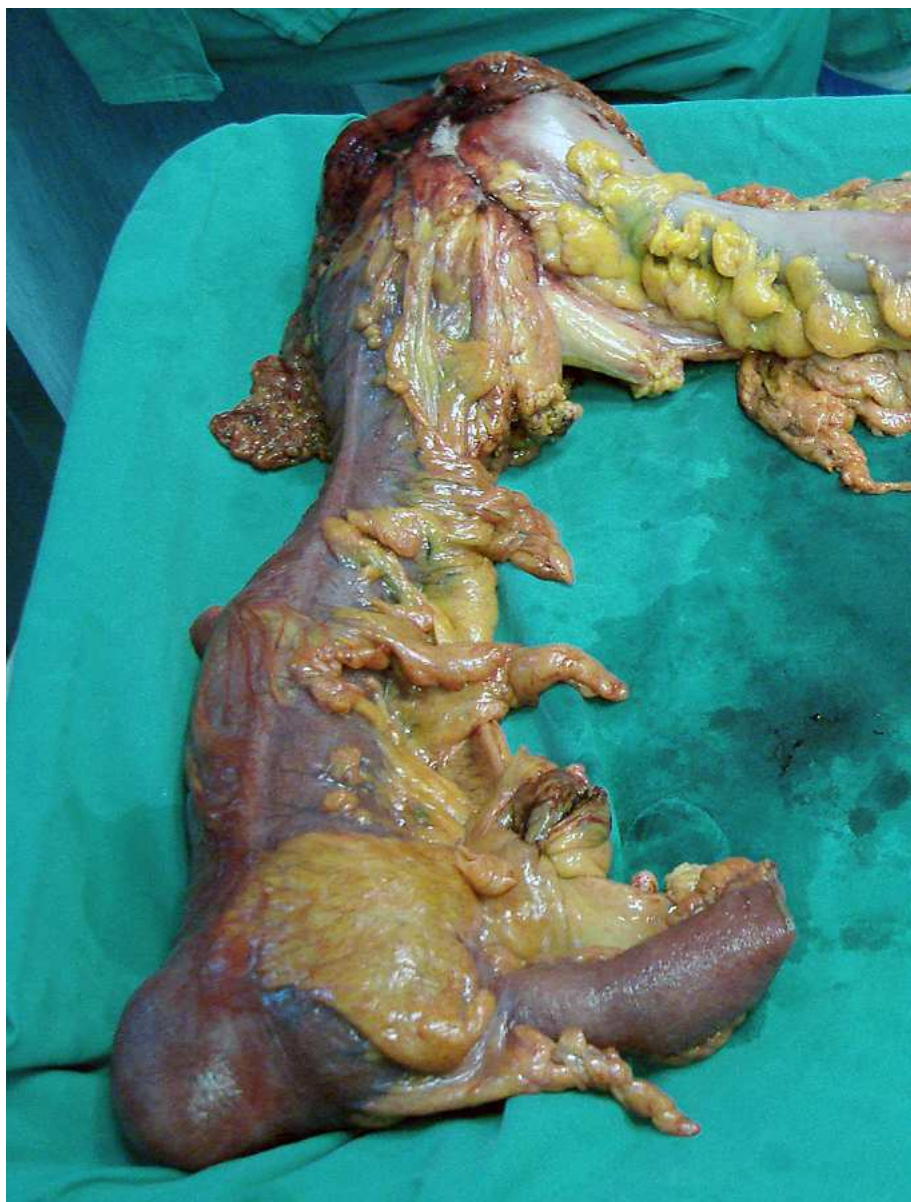
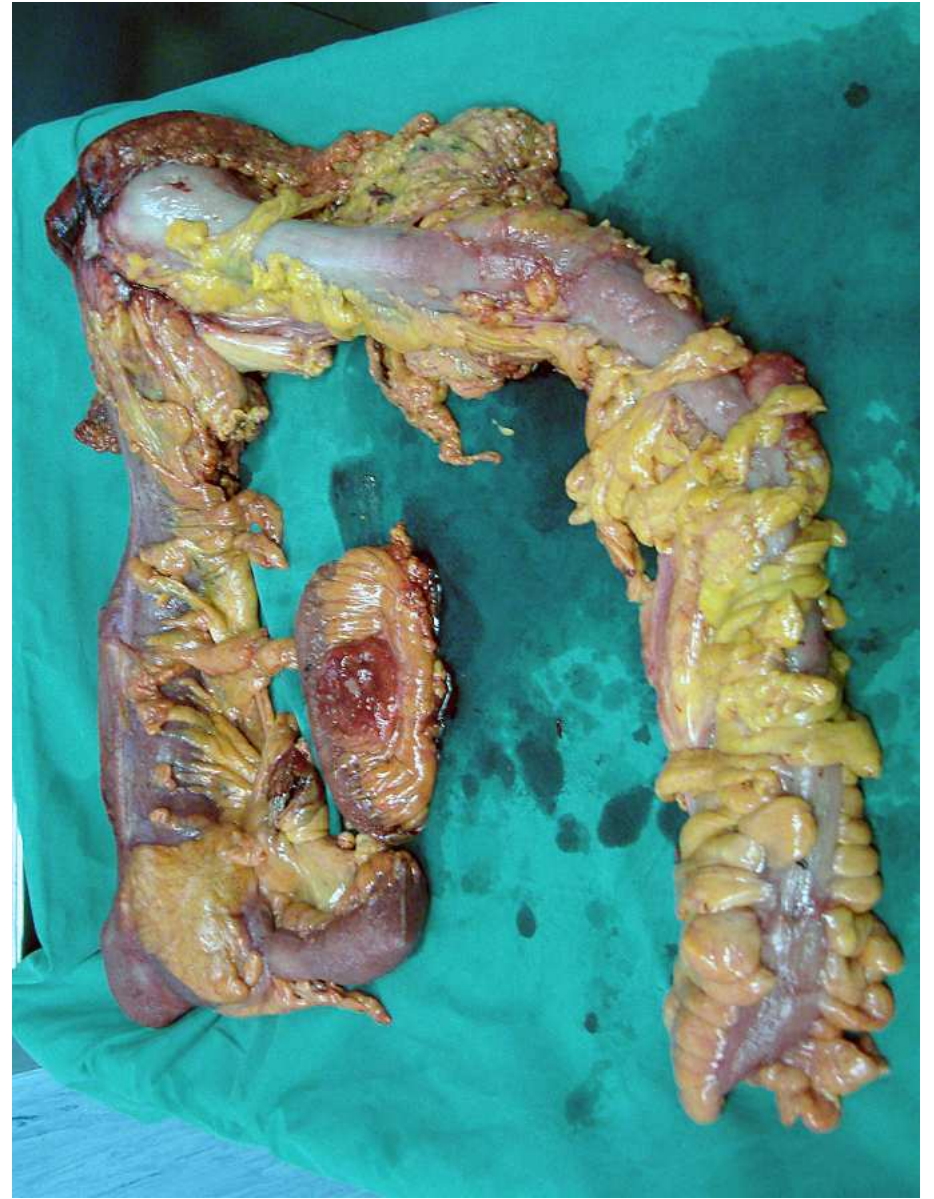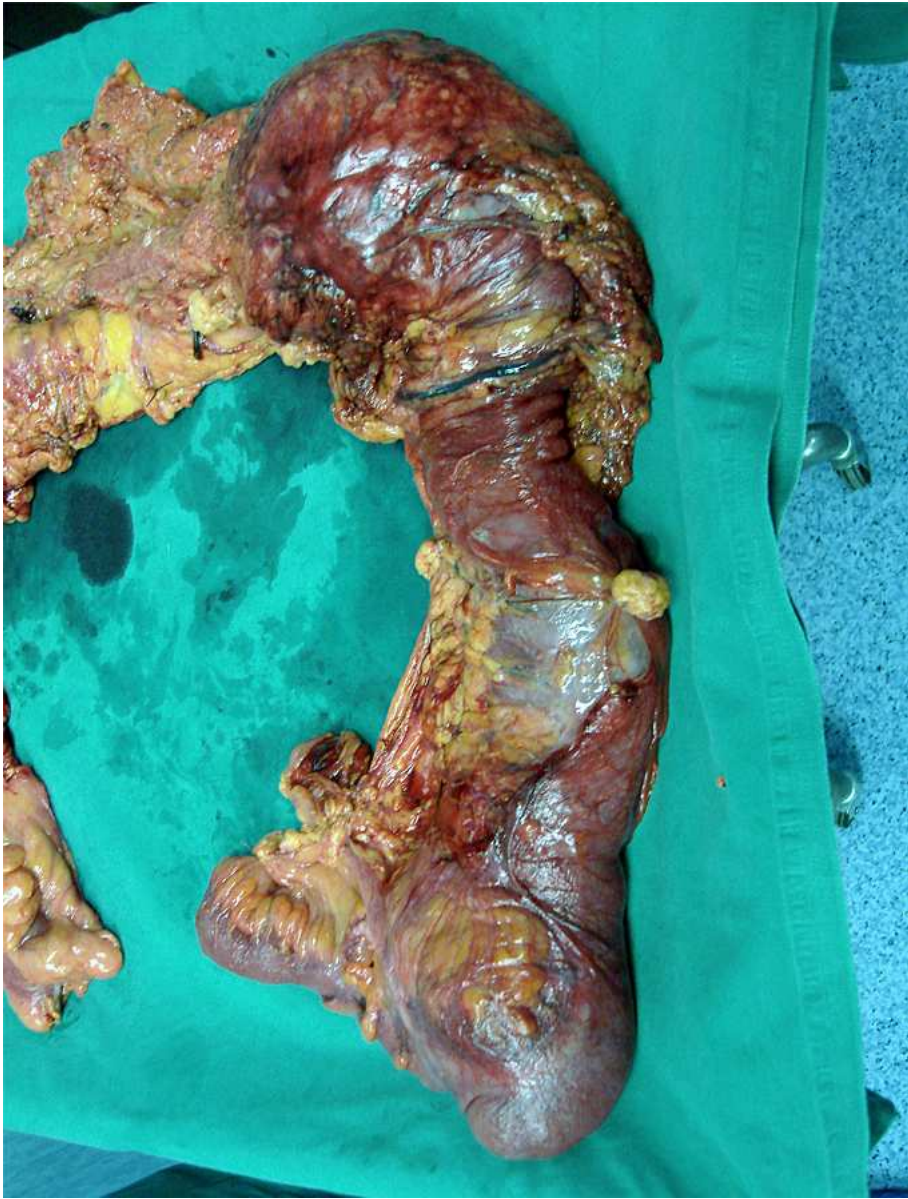


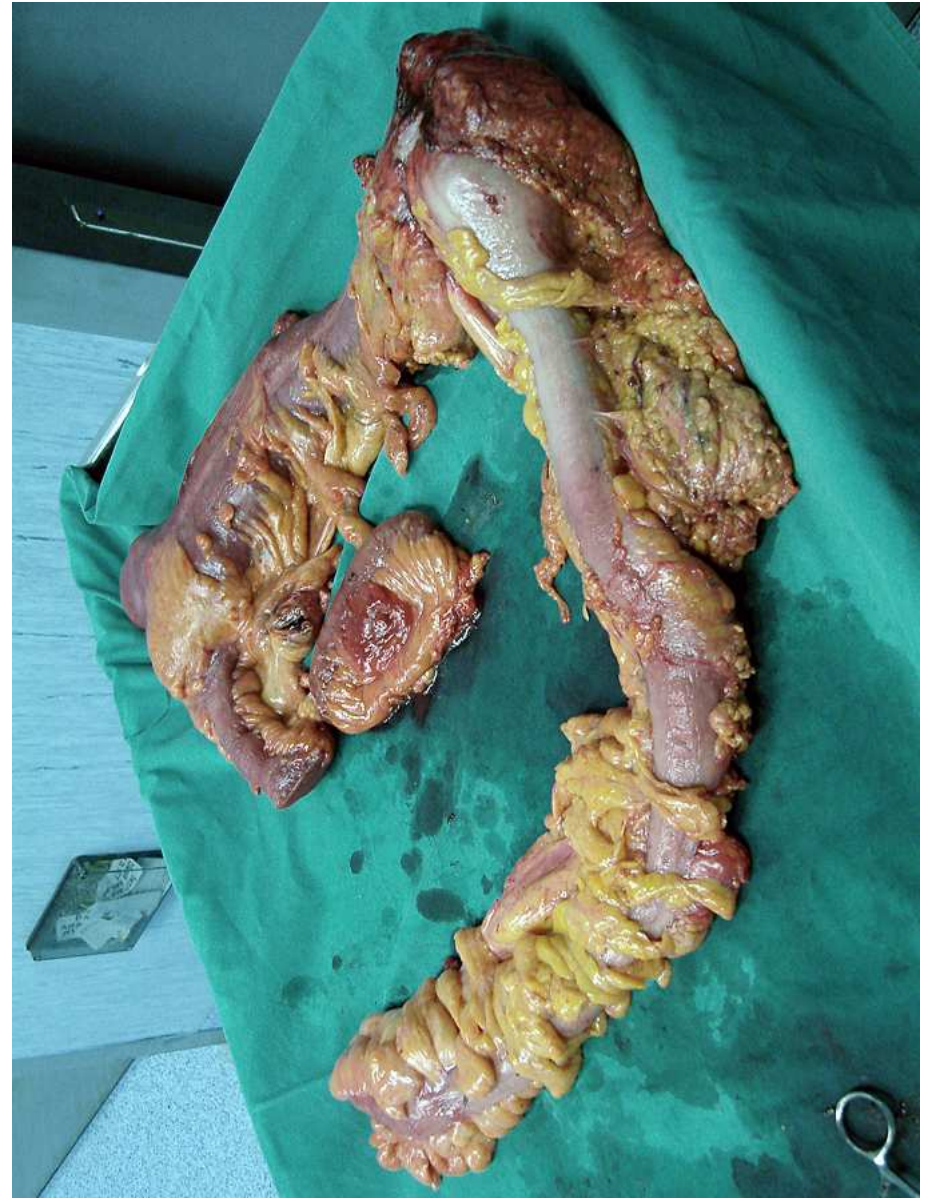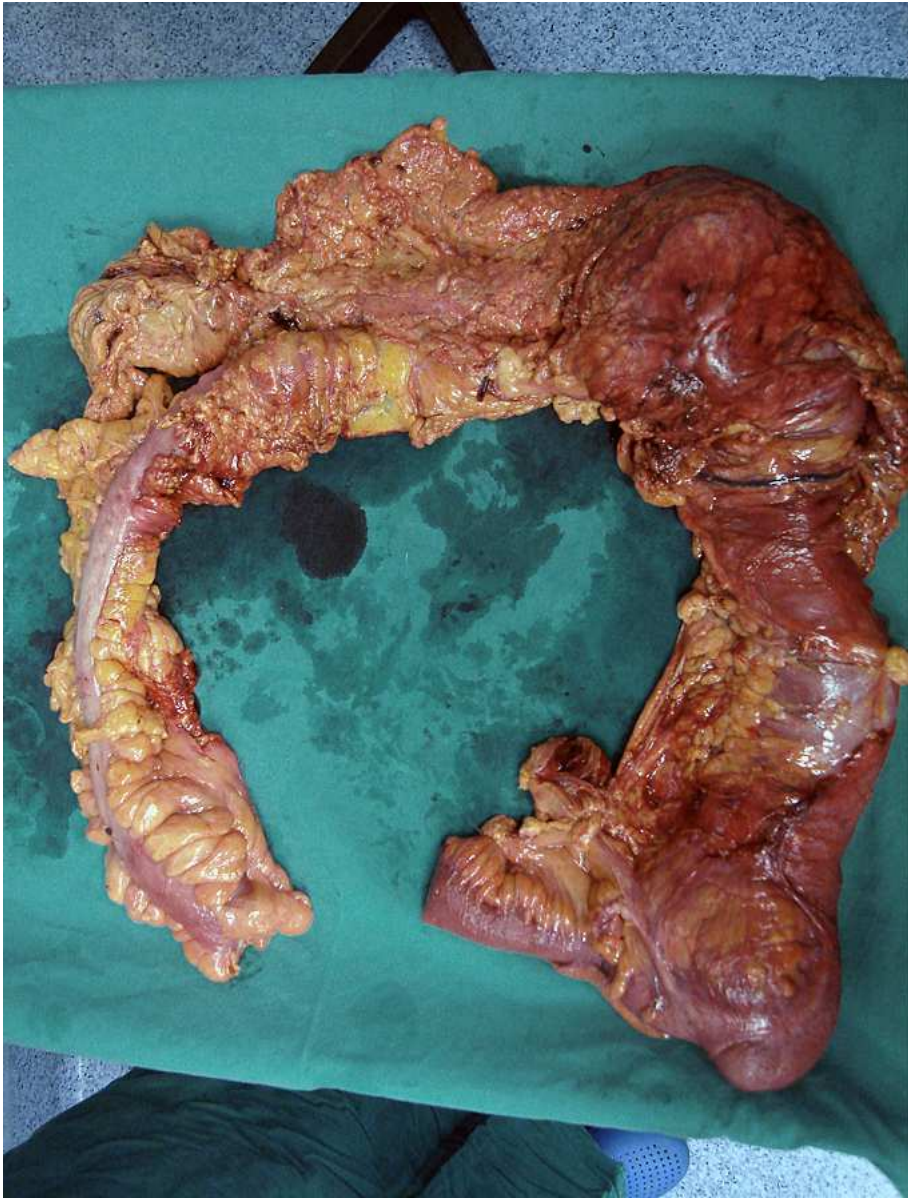A.O. • Anni: 70 - F • Record: 28 • 14-06-2007

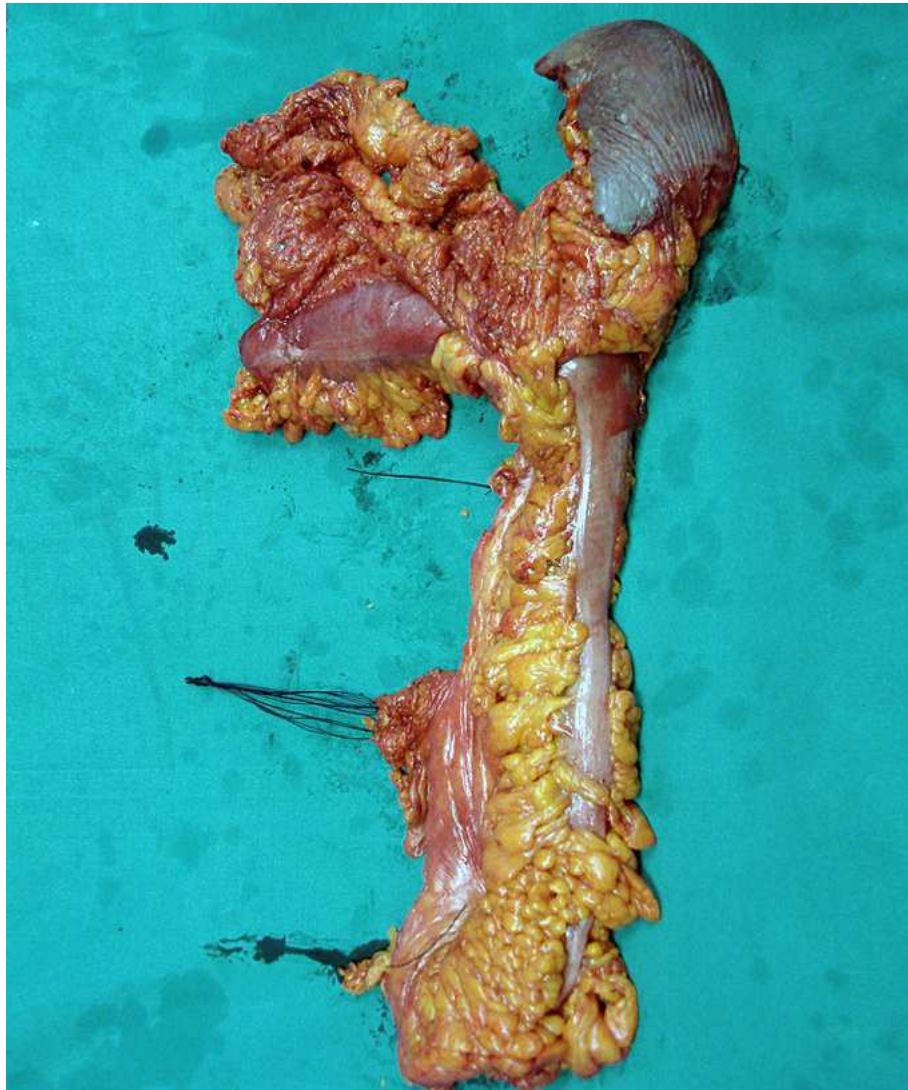
Colectomia totale e resezione ileale. Digiuno-ileostomia isoperistaltica ed ileo-rettostomia anisoperistaltica L.L. in duplice strato (GIA e Monocryl) per duplice adenocarcinoma del colon dx e del discendente





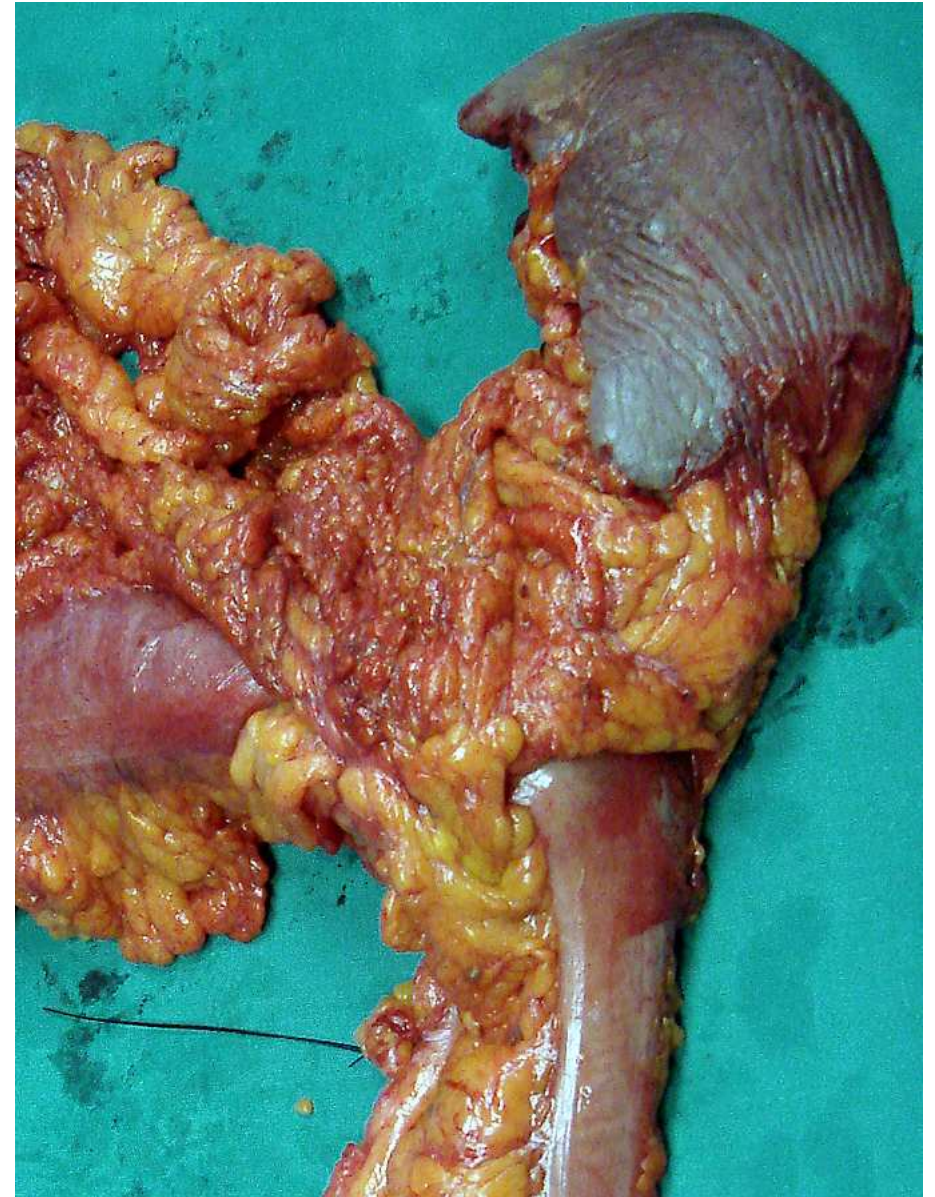




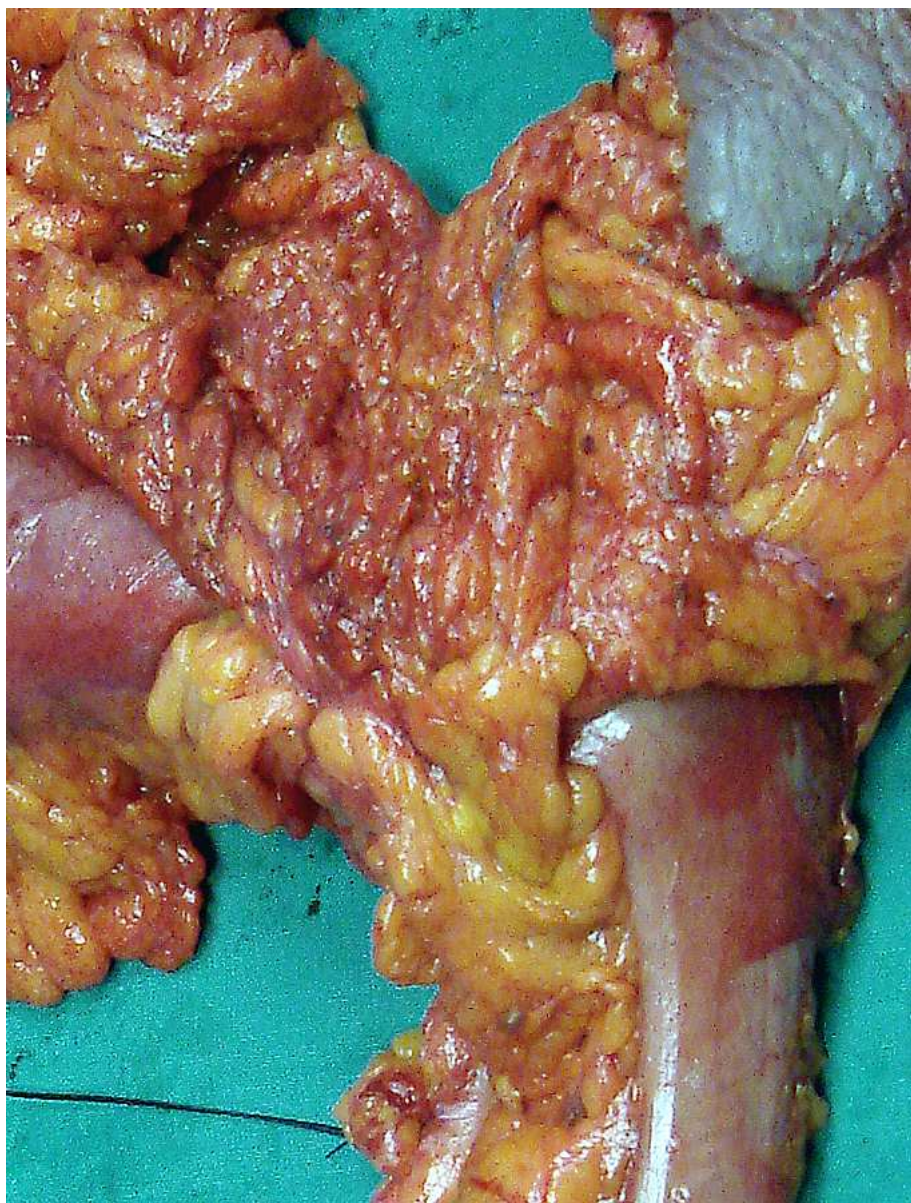

F.V. • Anni: 67 - M • Record: 29 • 12-09-2007

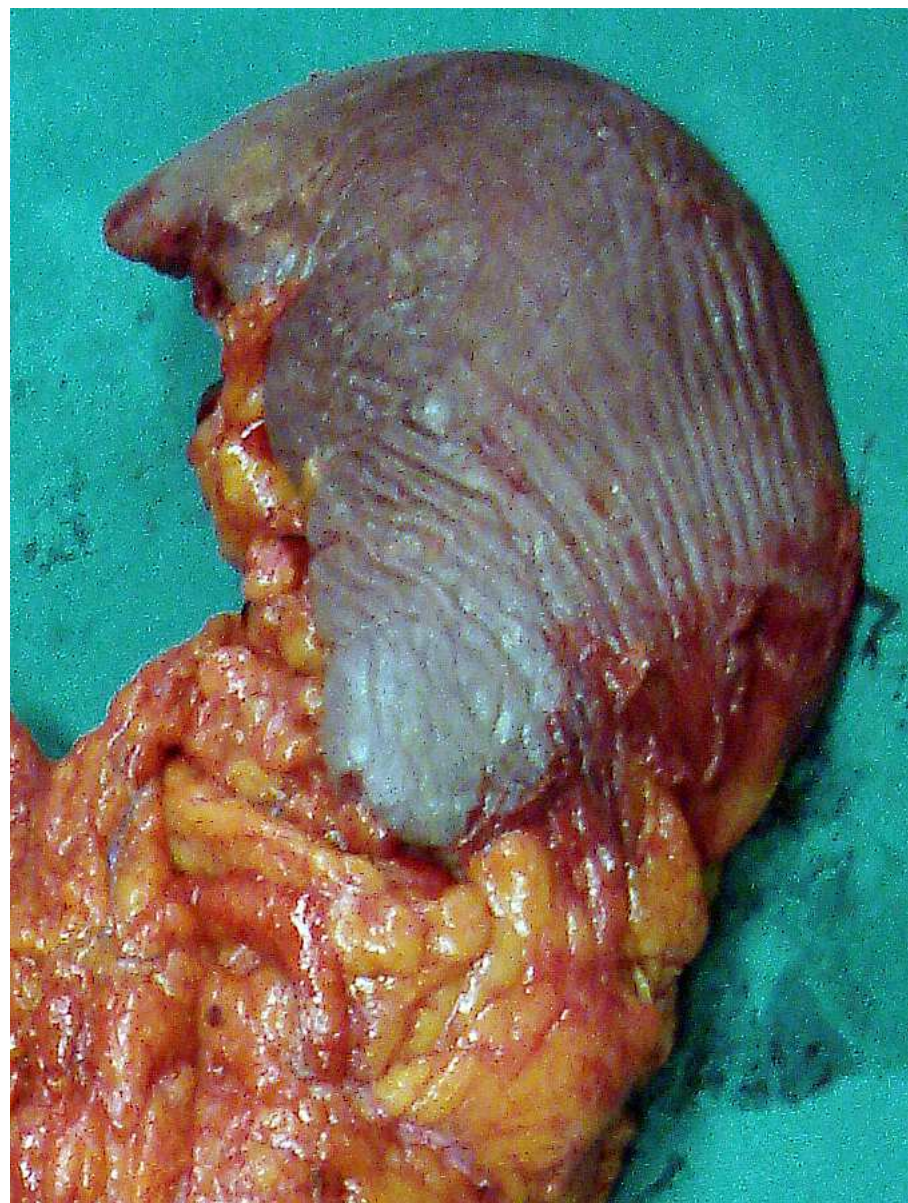
Emicolectomia sn allargata con splenectomia e linfadenectomia lombo-aorto-iliaca bilaterale ed intercavo-aortica per occlusione intestinale da adenocarcinoma stenossante della flessura splenica del colon



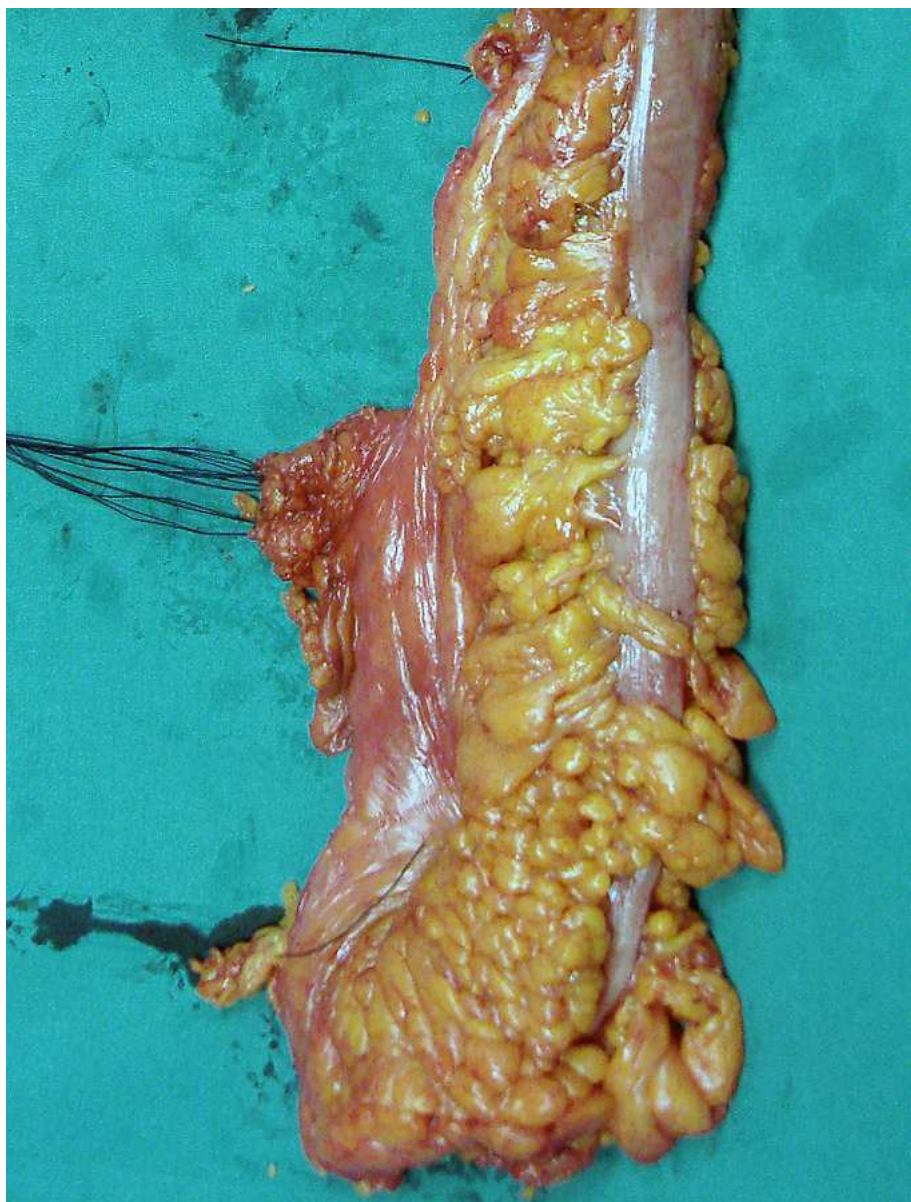
Flessura splenica del colon - Milza



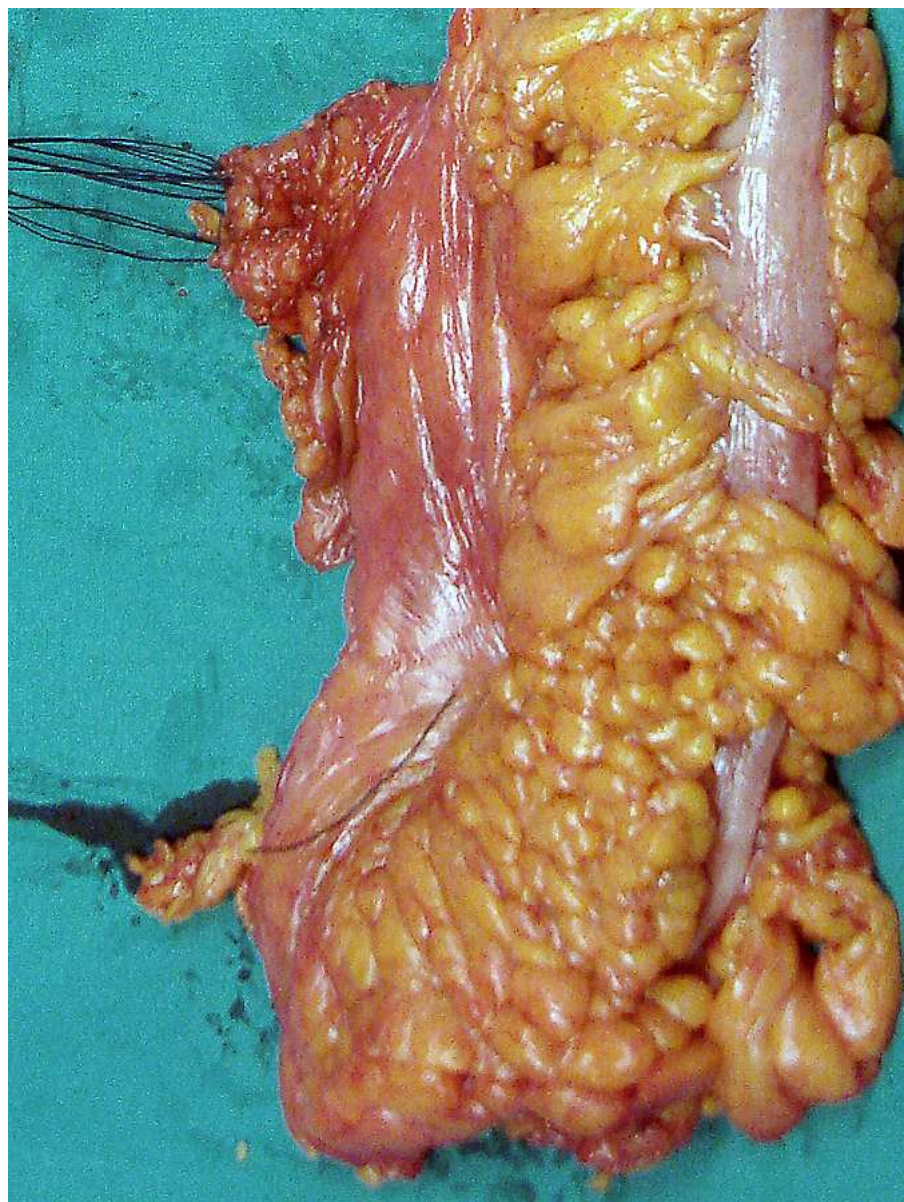
Stenosi neoplastica della flessura splenica del colon



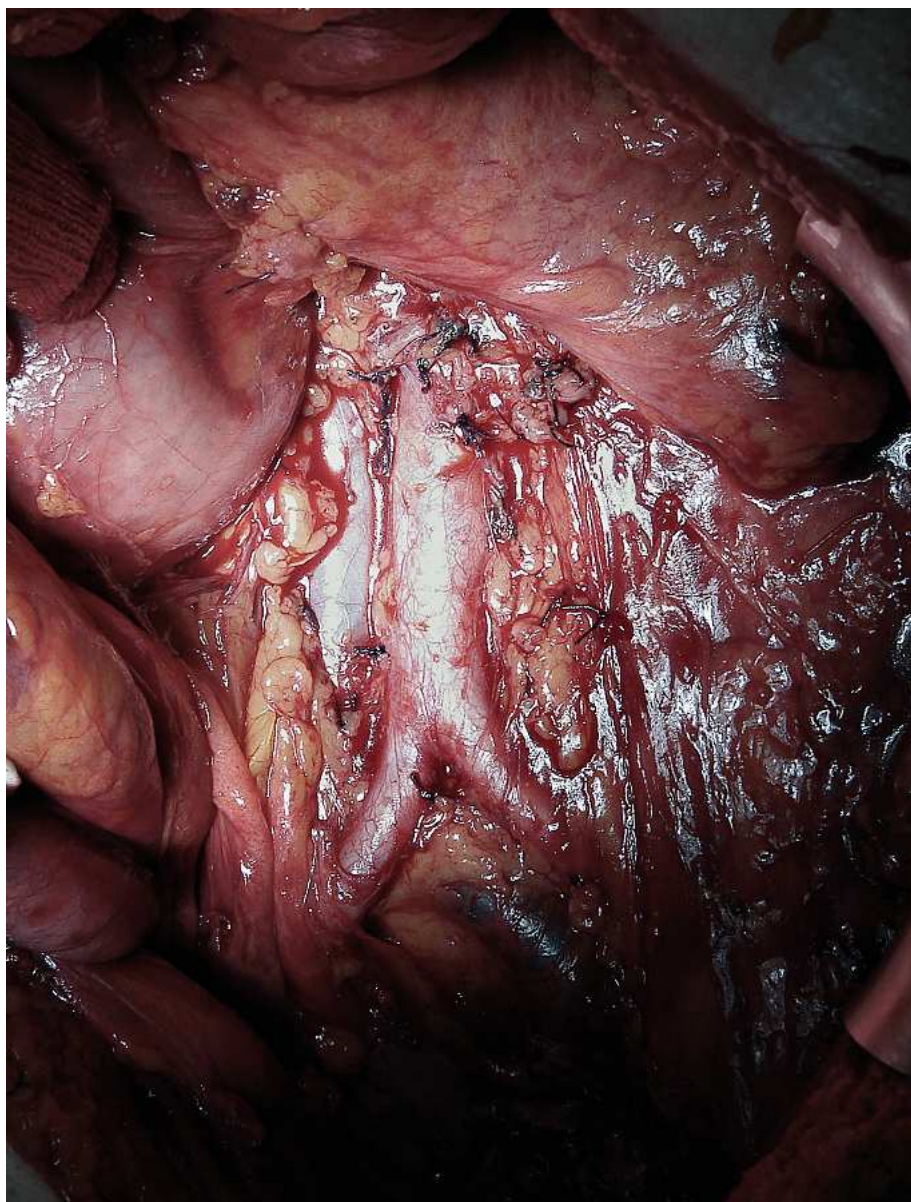
Milza



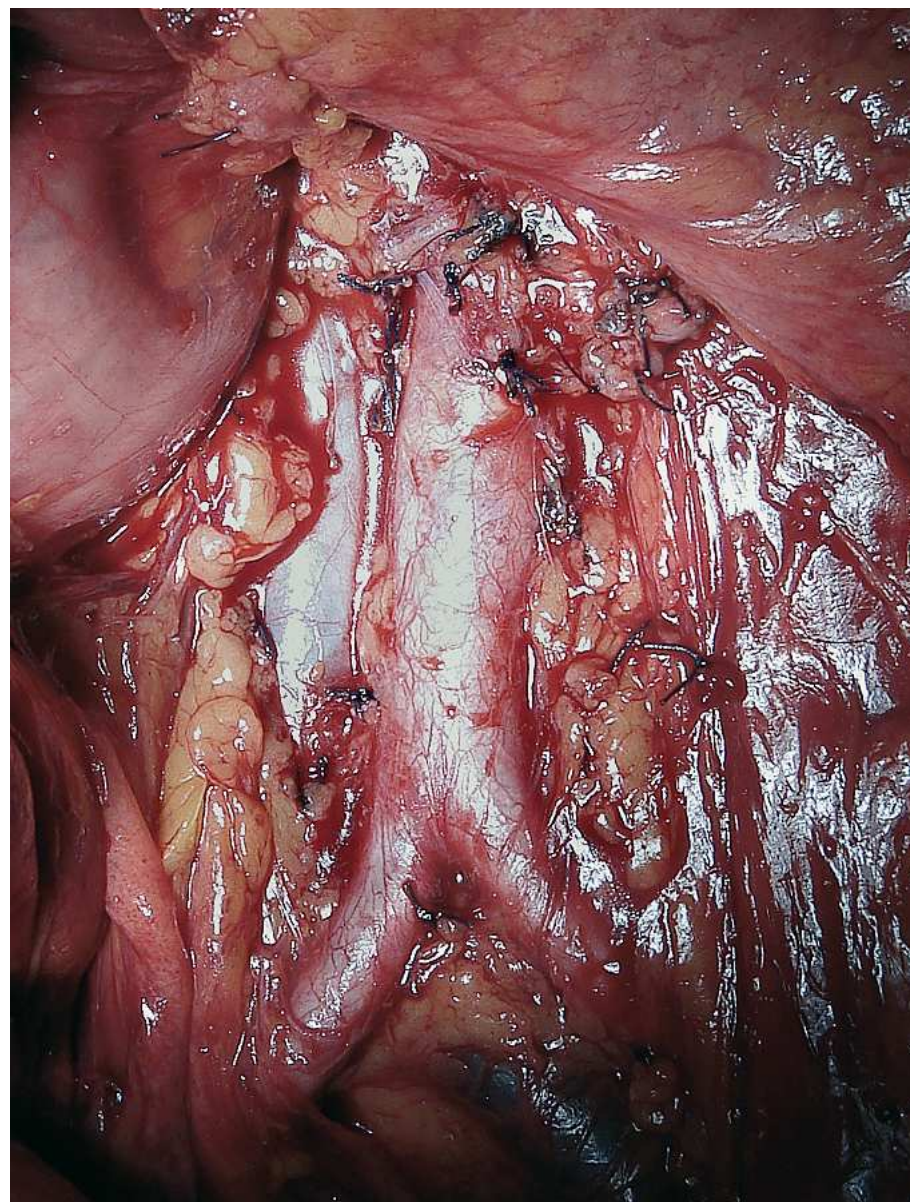
Vena mesenterica inf. - Linfonodi intercavo-lombo-aorto-iliaci bilaterali



Linfonodi intercavo-lombo-aorto-iliaci bilaterali

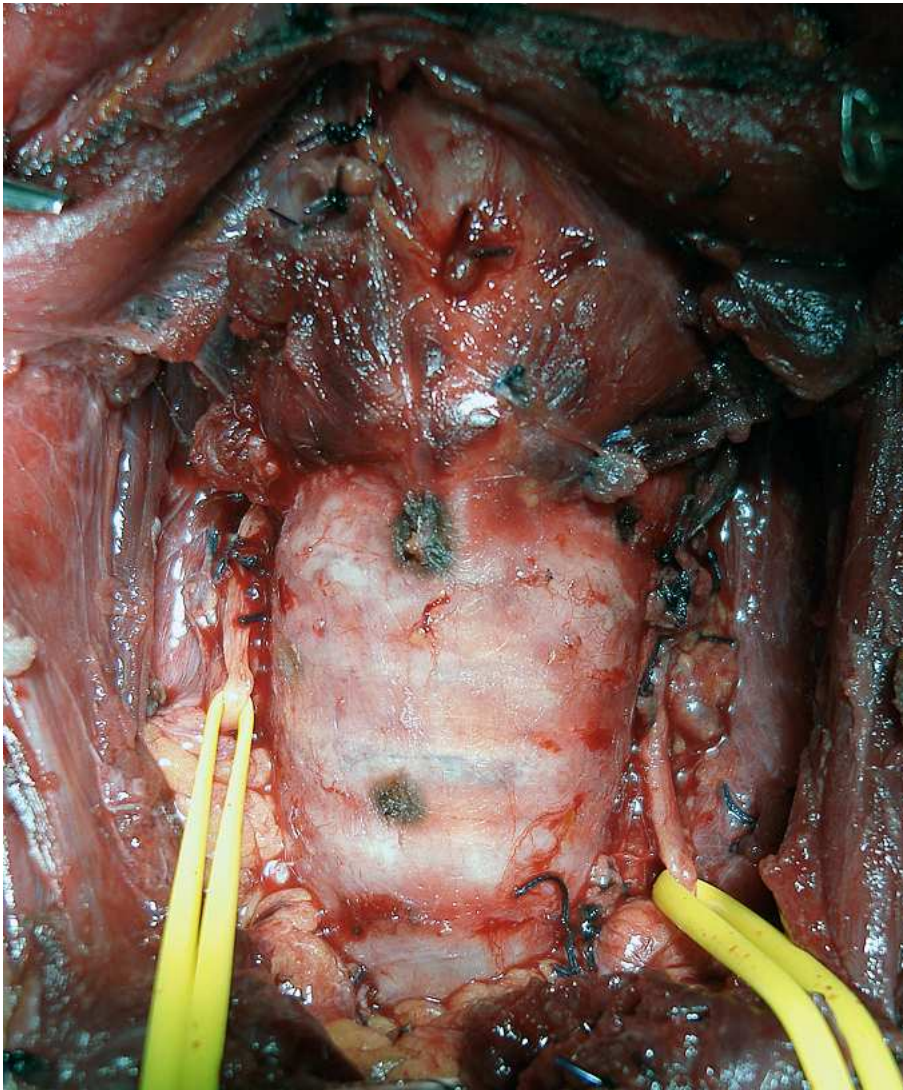


Linfoadenectomia intercavo-lombo-aorto-iliaca bilaterale



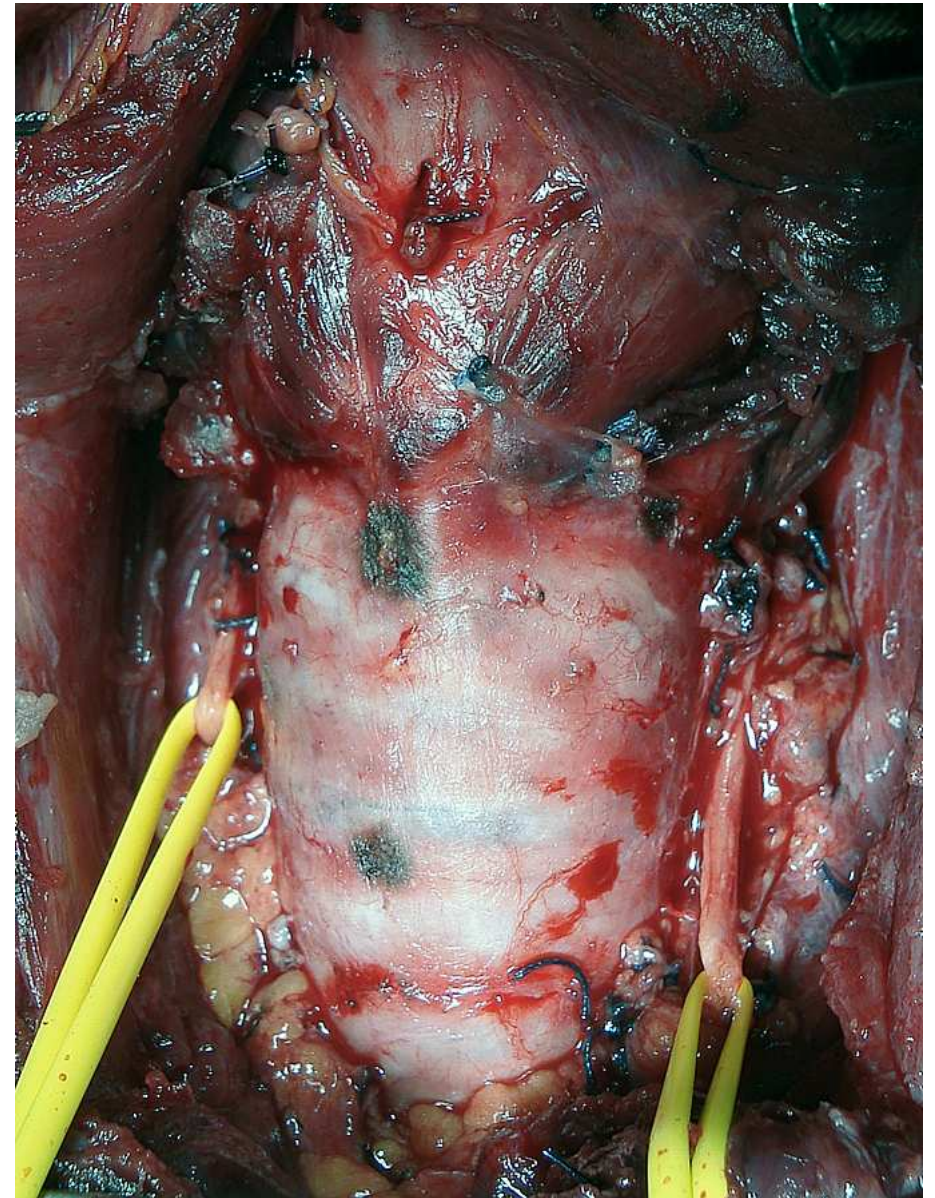
Linfoadenectomia intercavo-lombo-aorto-iliaca bilaterale



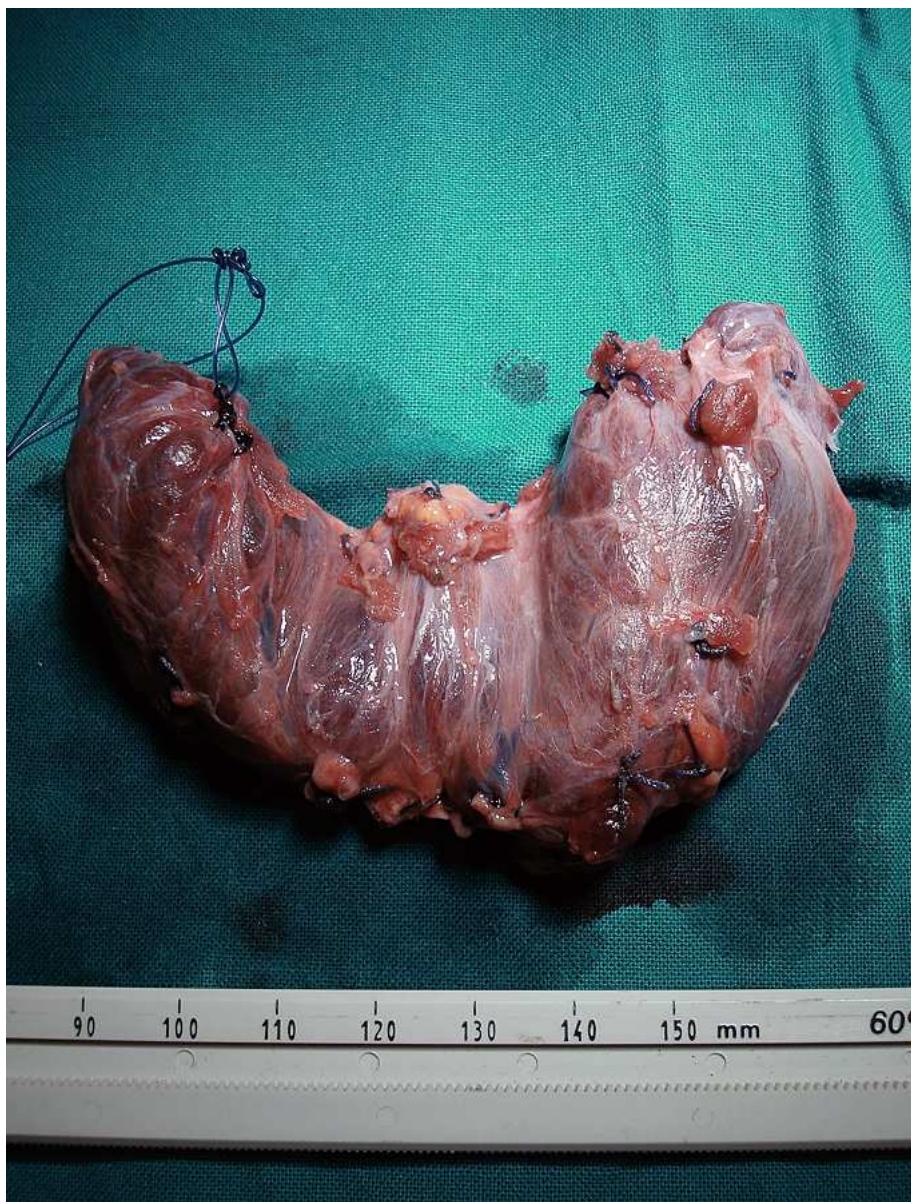

F.G. • Anni: 48 - M • Record: 30 • 28-09-2007

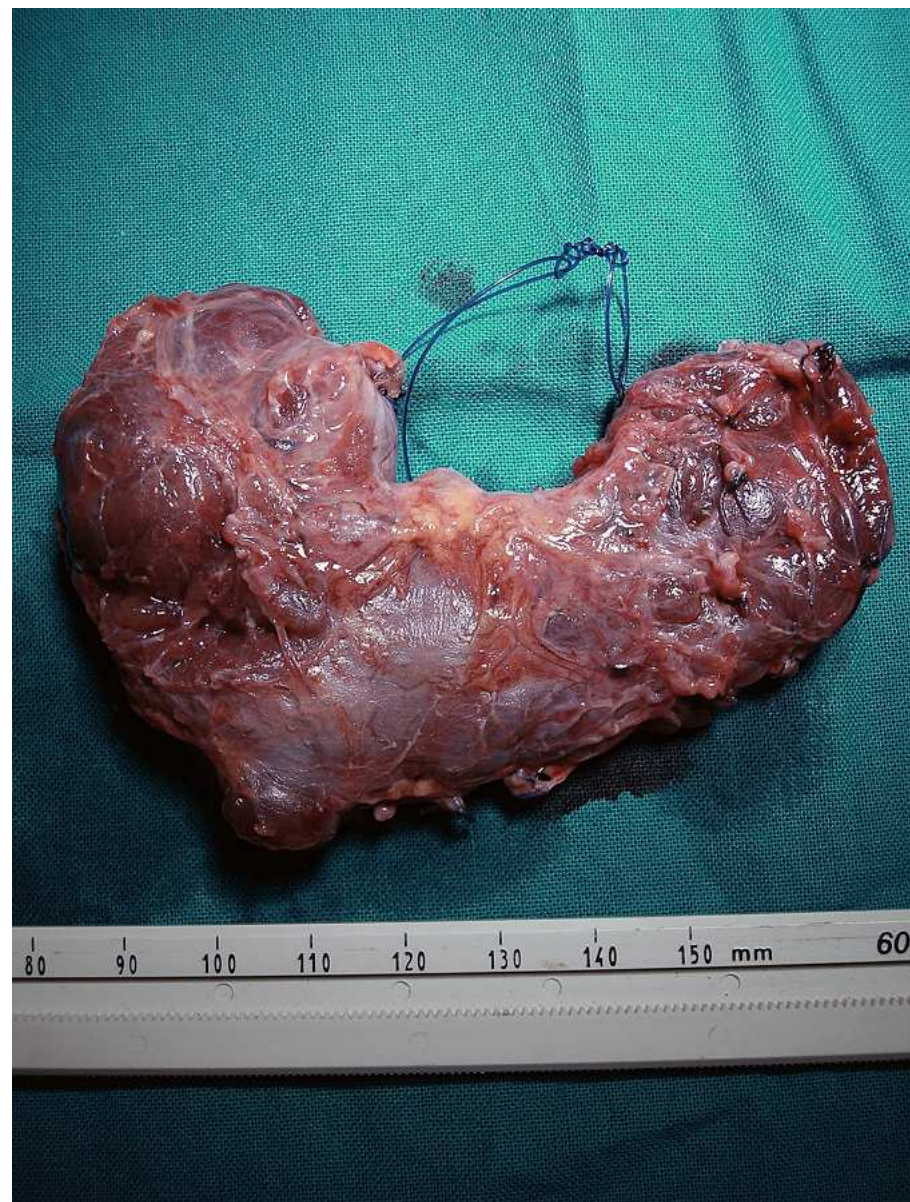
Tiroidectomia totale extracapsulare per gozzo plurinodulare con sezione dei muscoli pretiroidei



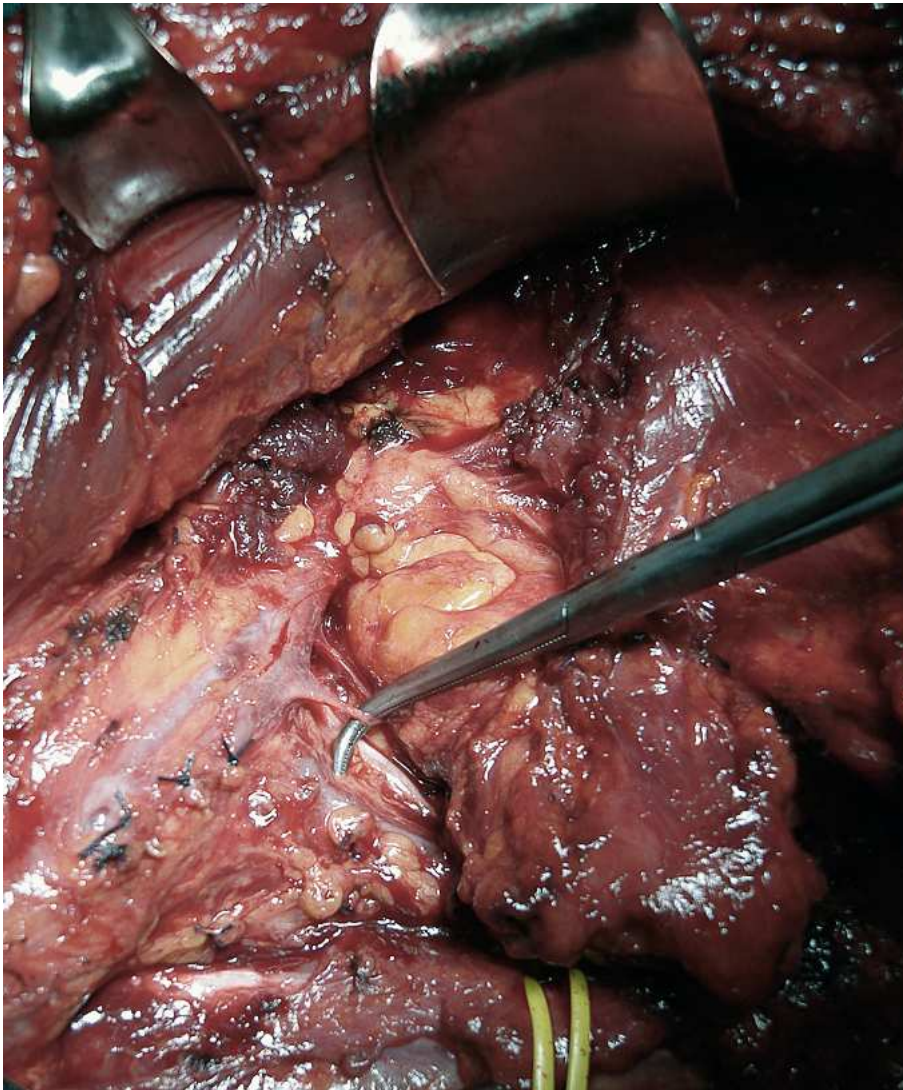
Isolamento dei nervi laringei inferiori (ricorrenti)



Lobo destro - Istmo - Lobo sinistro (superficie anteriore)

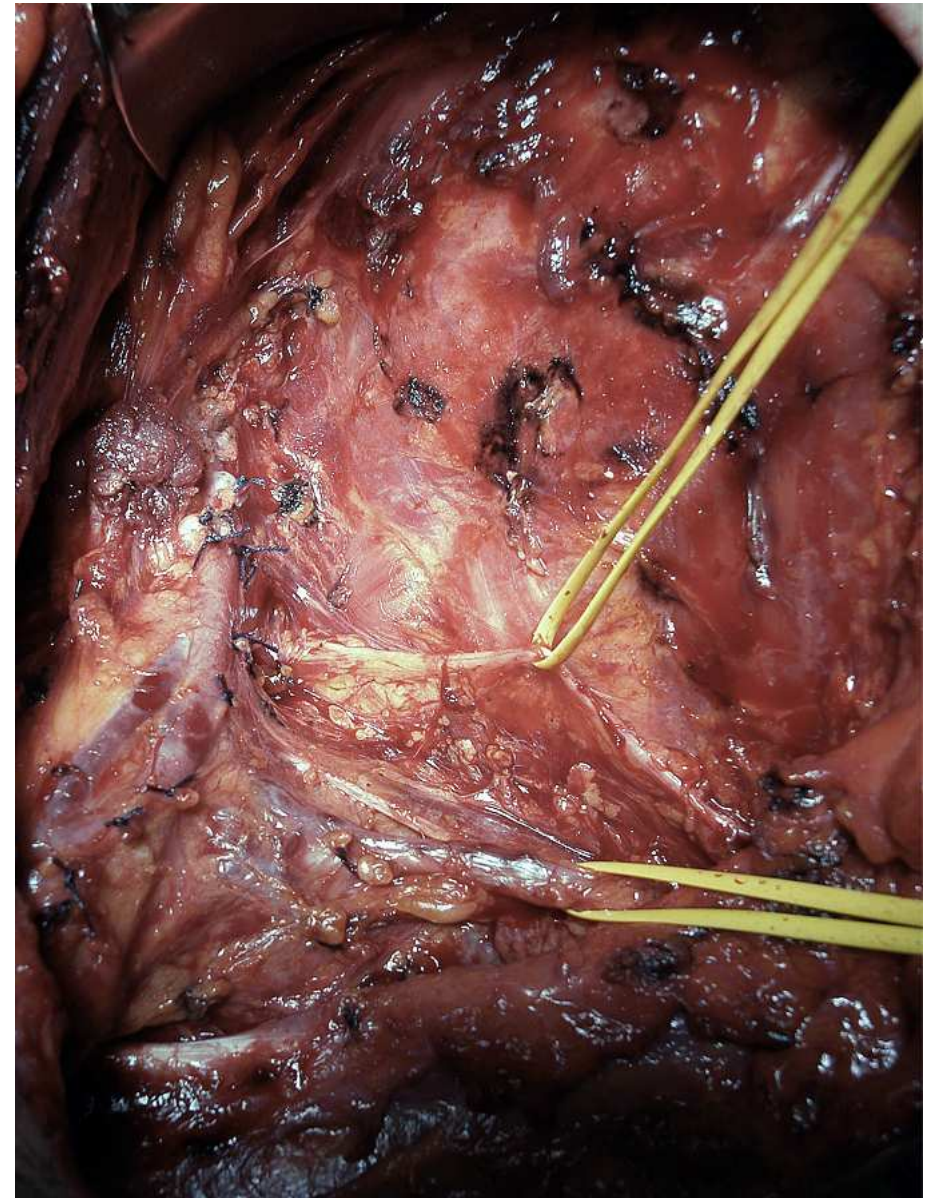


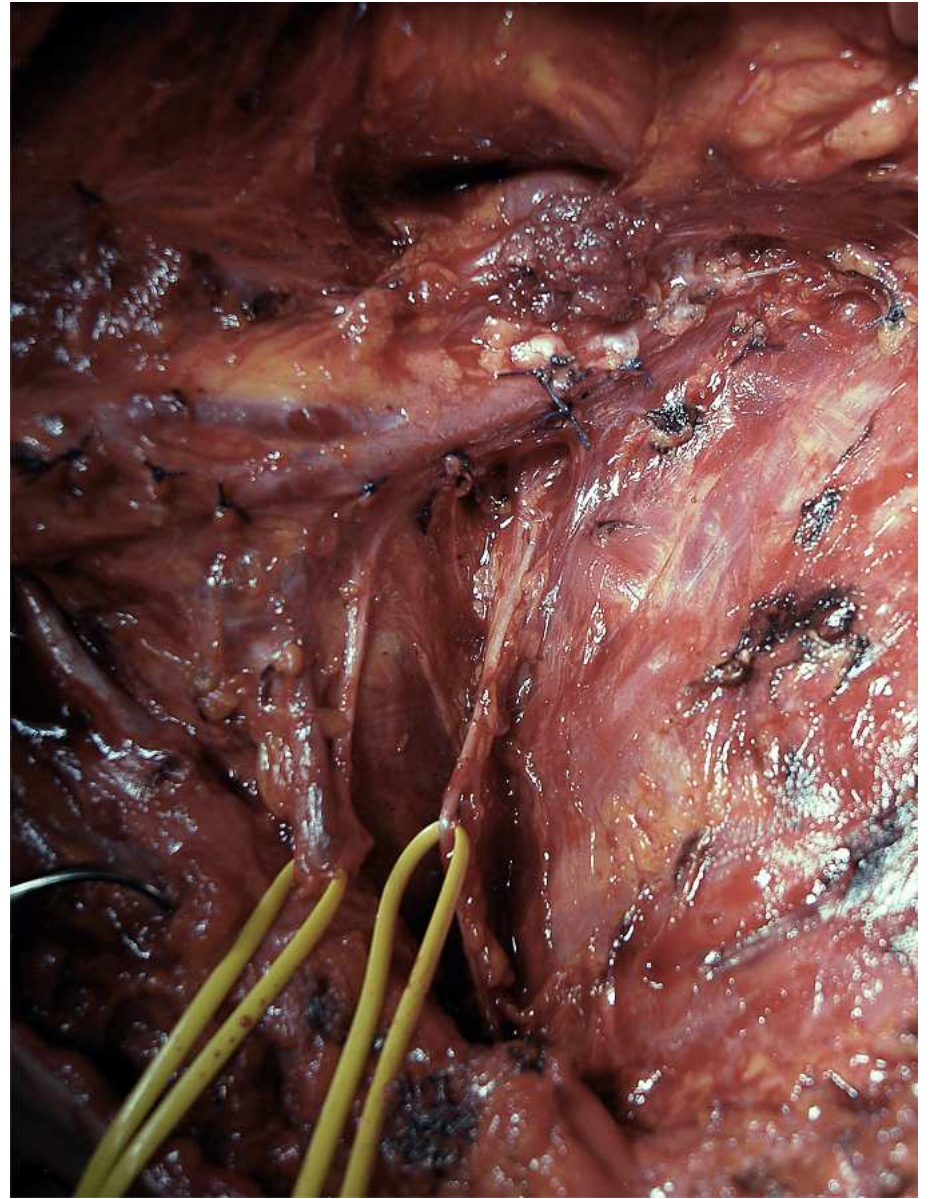
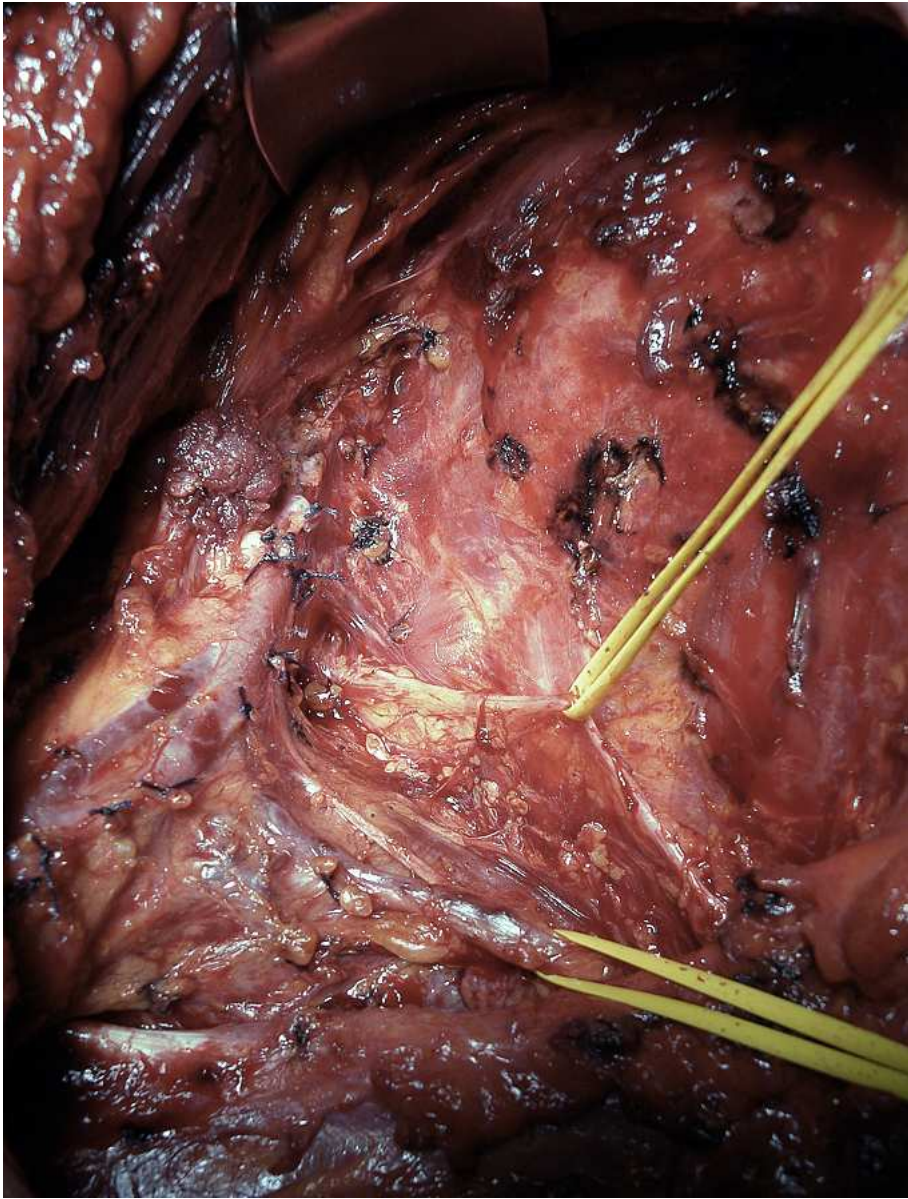
Lobo sinistro - Istmo - Lobo destro (superficie posteriore)

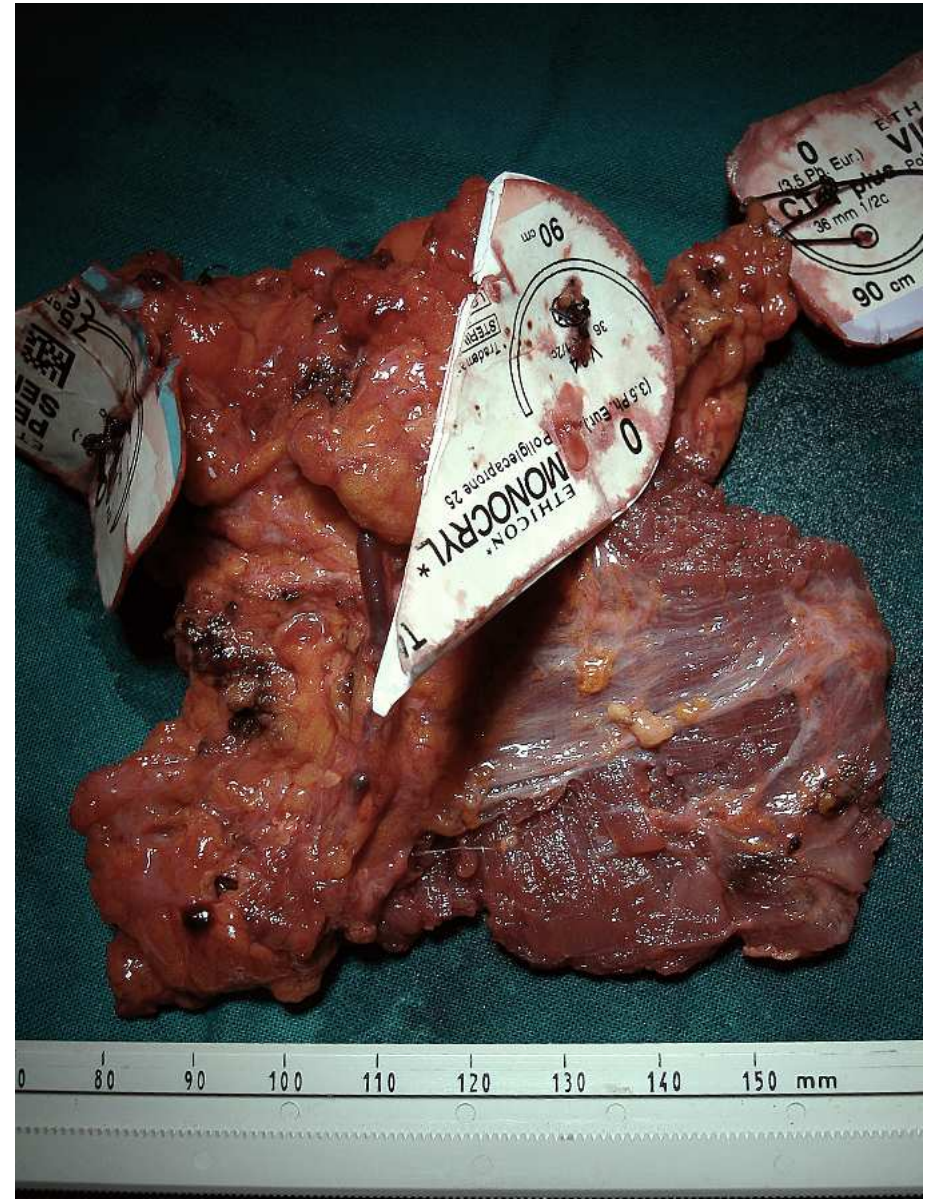
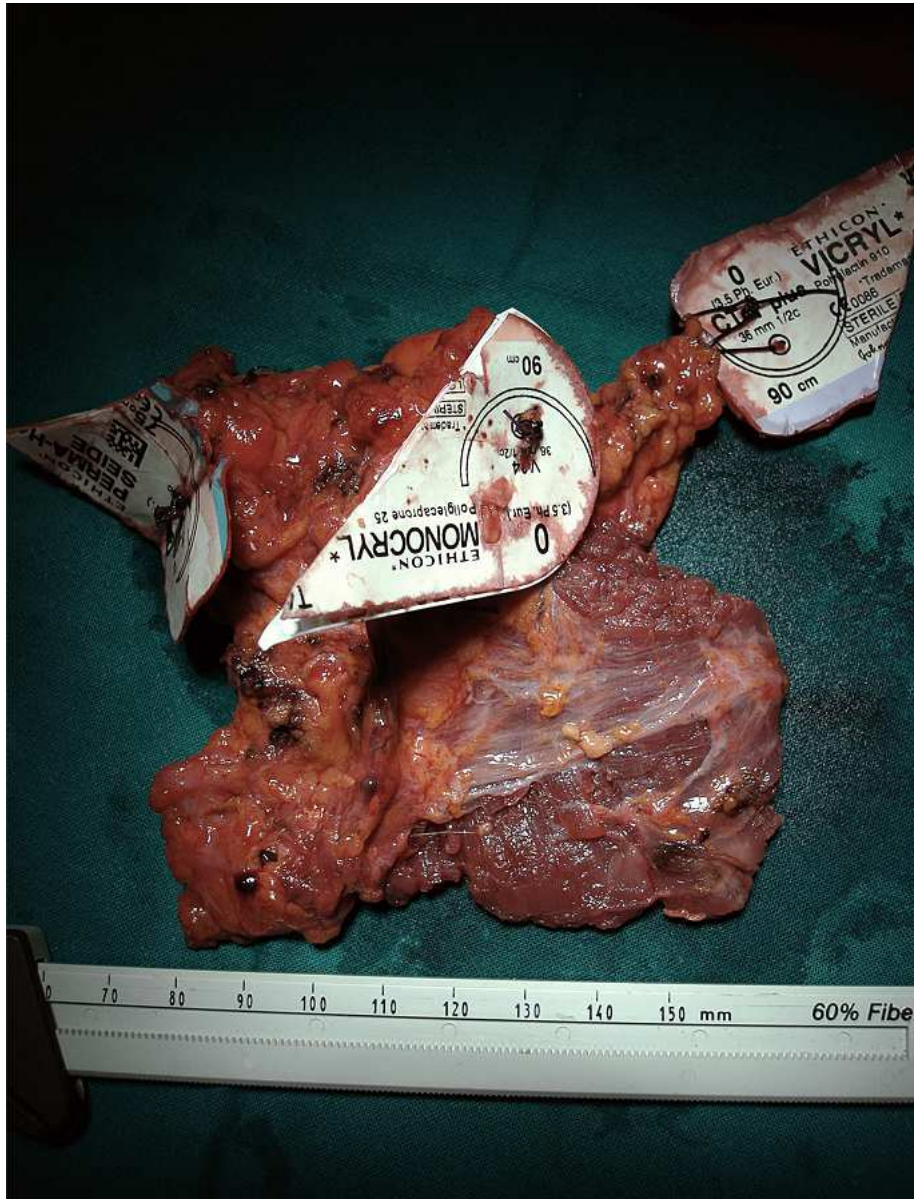
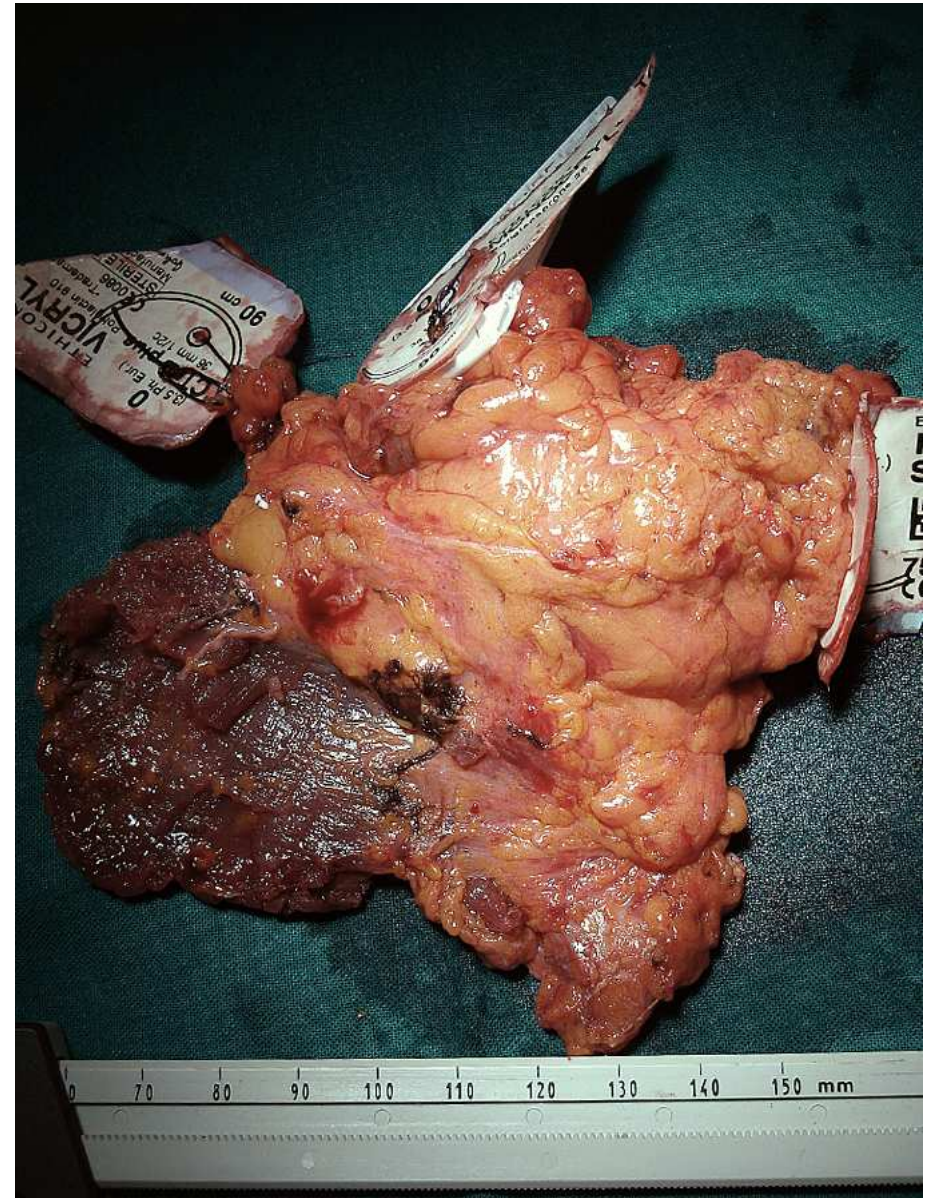
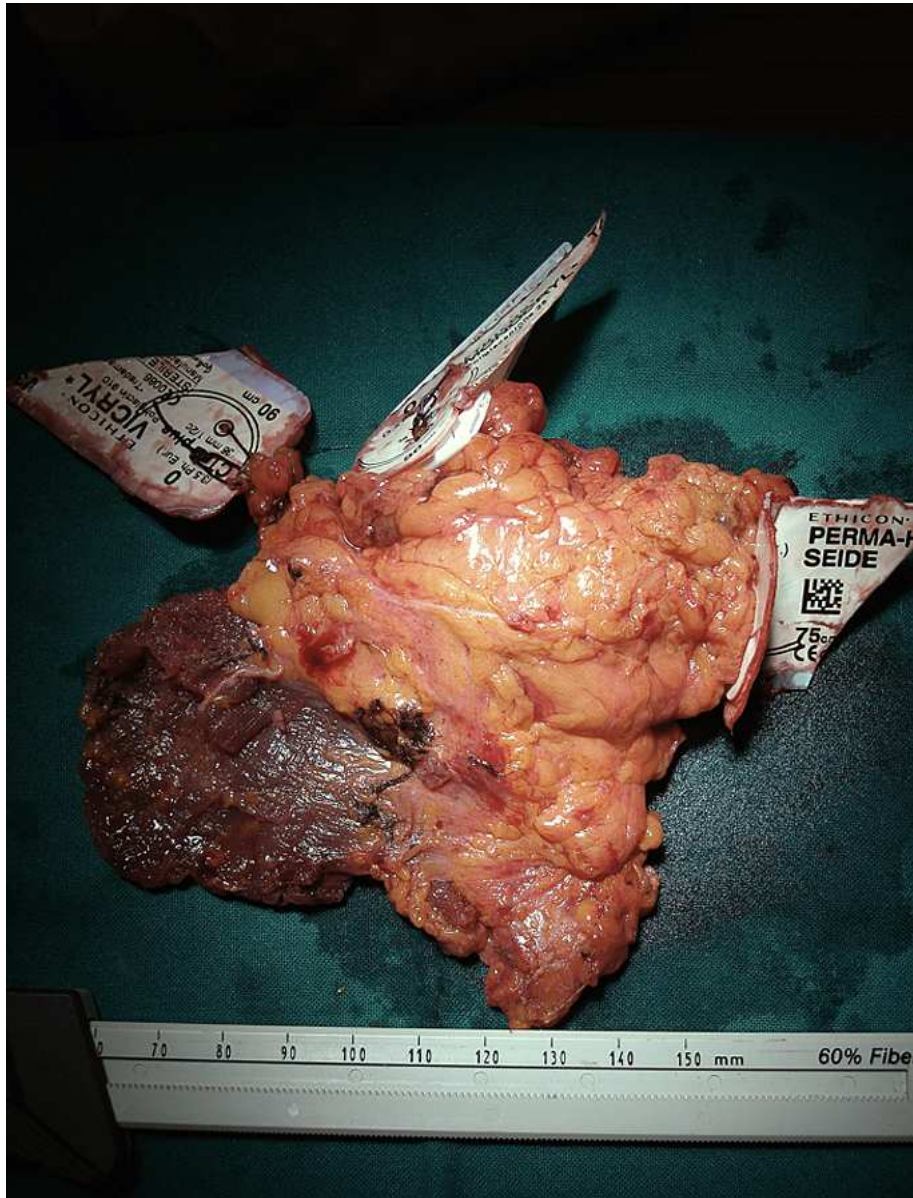C.M. • Anni: 47 - F • Record: 31 • 04-10-2007

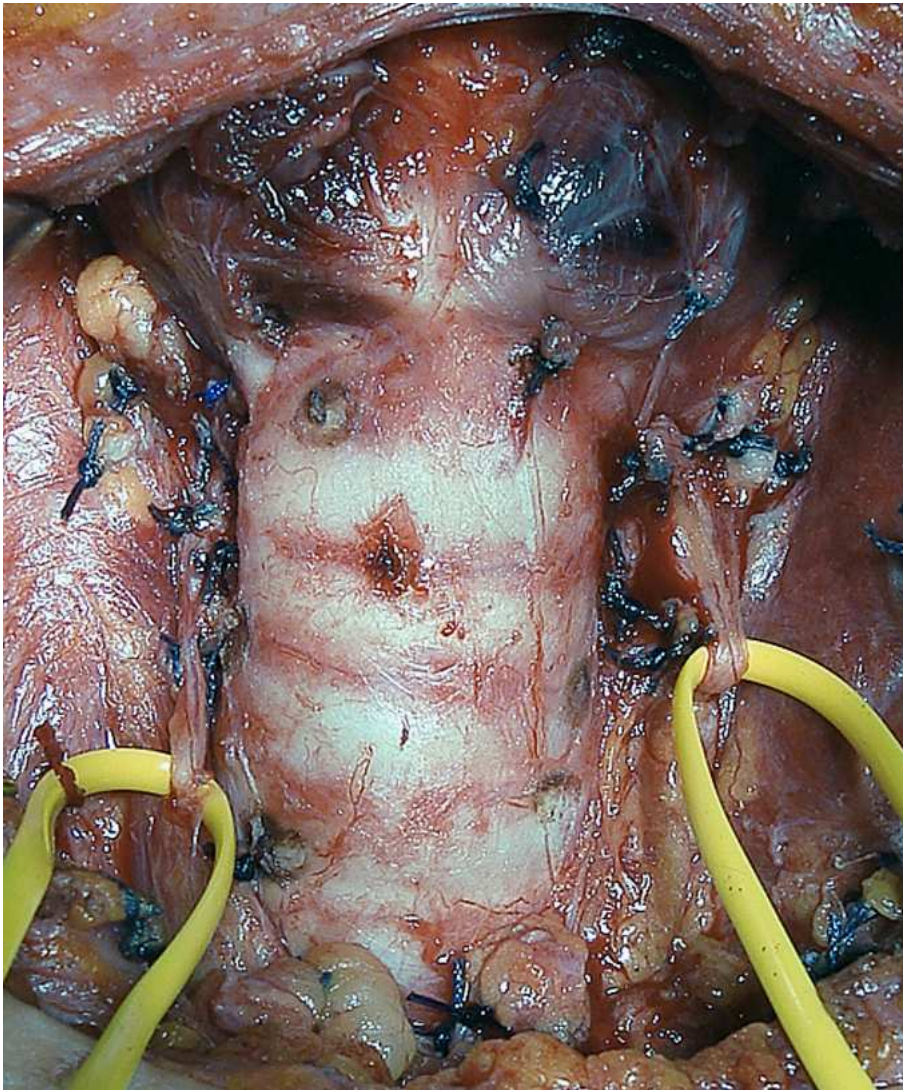
Svuotamento ascellare dx in operata di QUART SE dx per ca duttale





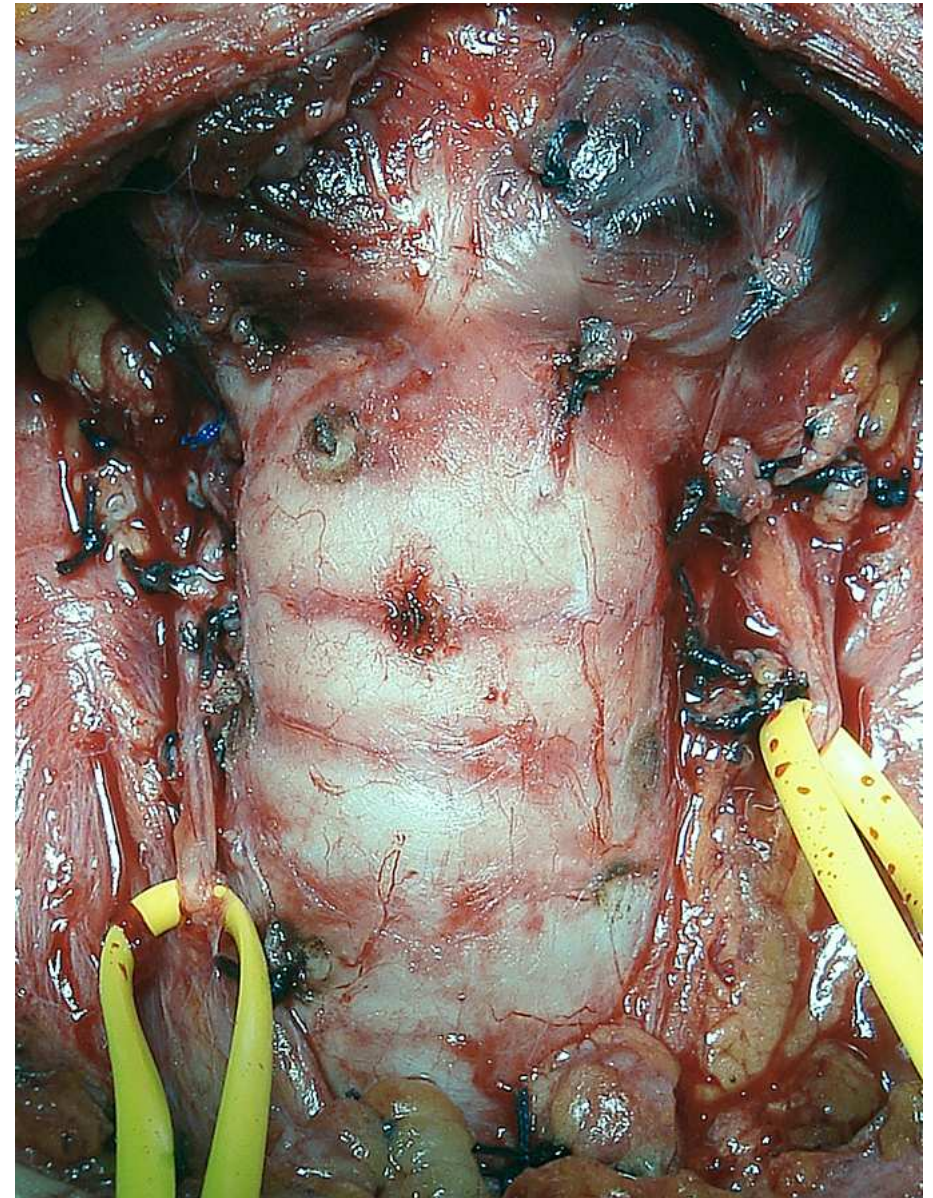




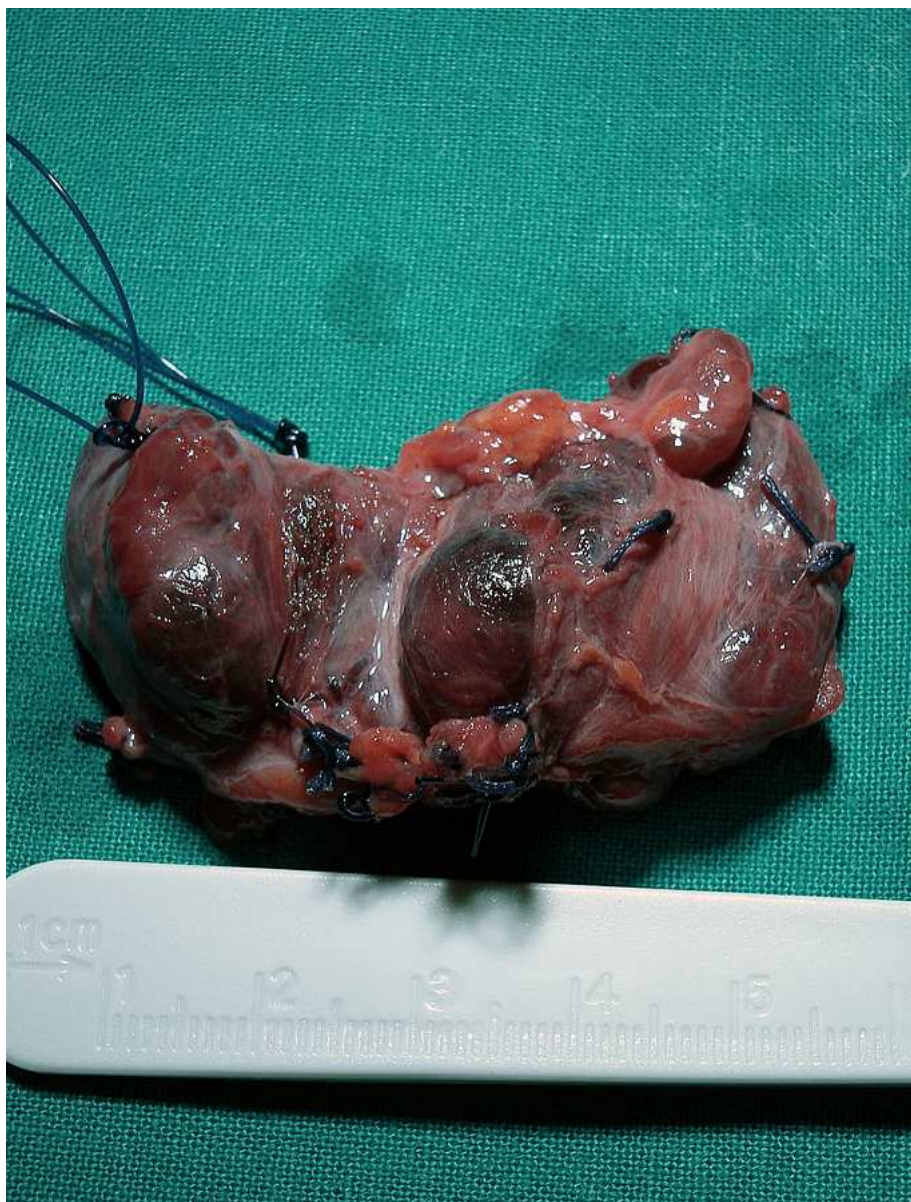


C.E. • Anni: 40 - F • Record: 32 • 11-10-2007

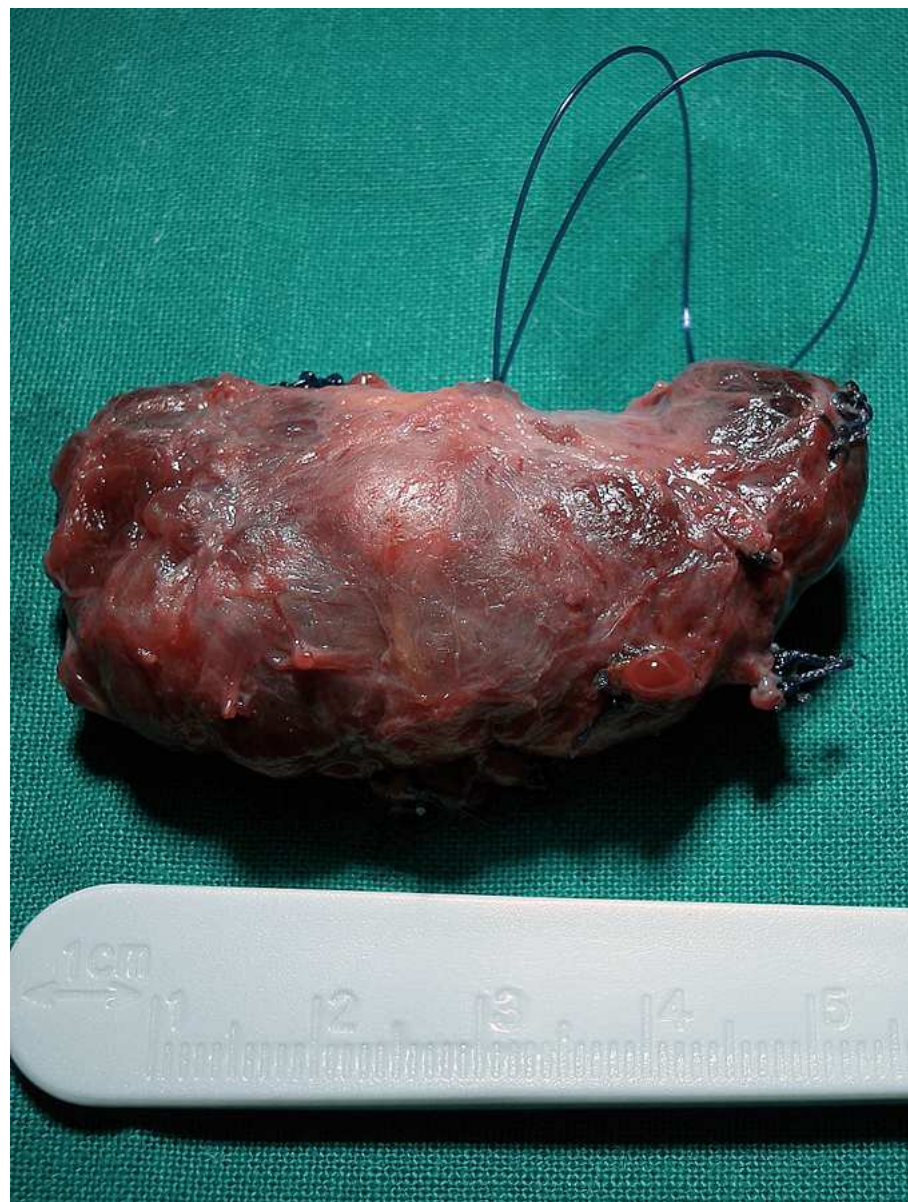
Tiroidectomia totale extracapsulare per carcinoma papillare dell'istmo tiroideo in gozzo plurinodulare



Isolamento dei nervi laringei inferiori (ricorrenti)

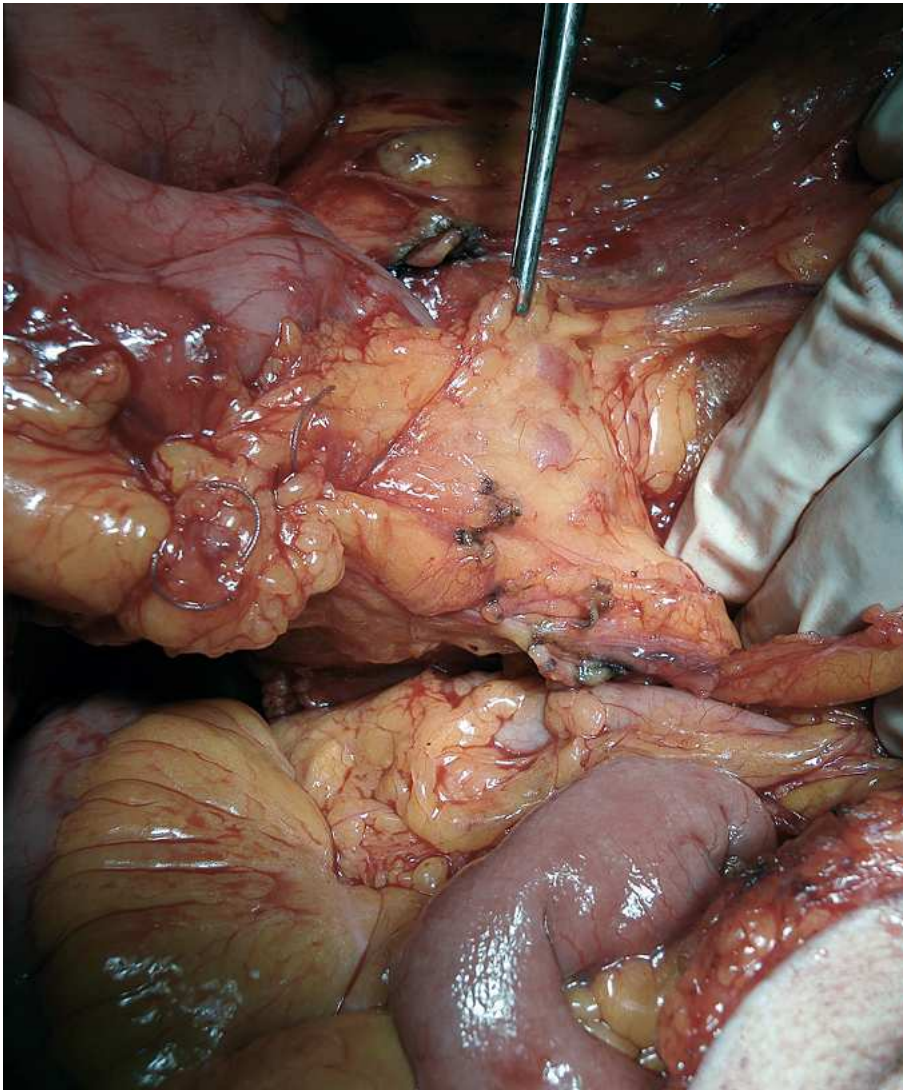


Lobo destro - Istmo - Lobo sinistro (superficie anteriore)



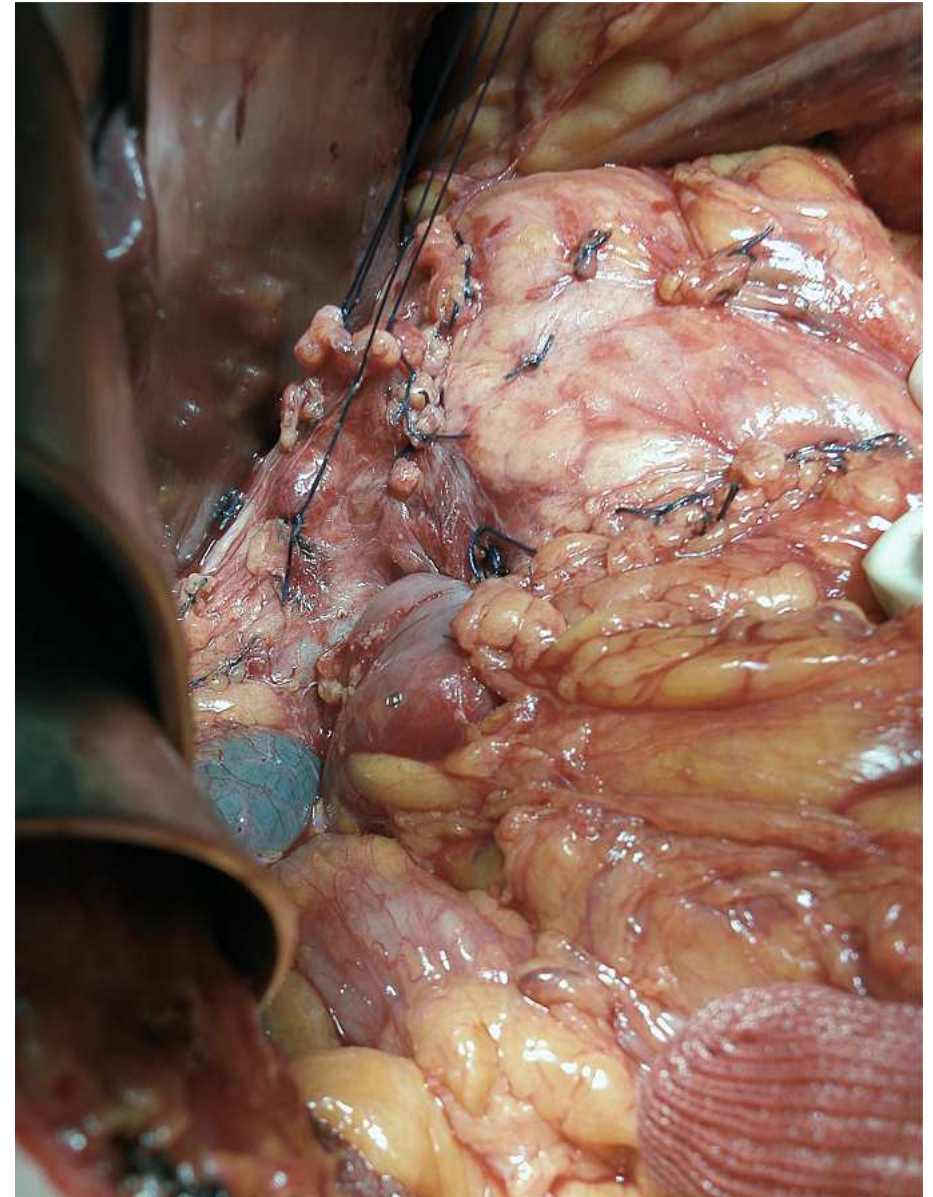
Lobo sinistro - Istmo - Lobo destro (superficie posteriore)



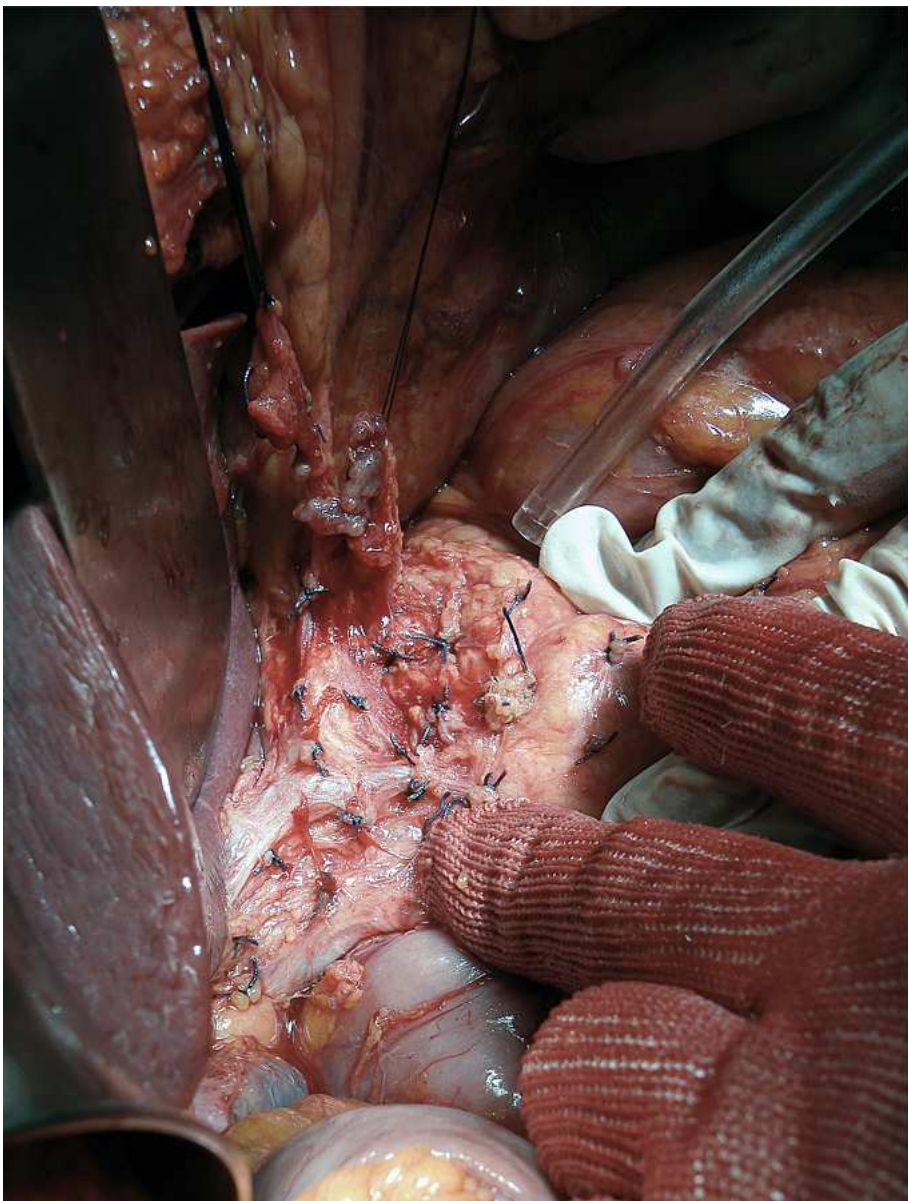


D.S.A. • Anni: 57 - M  Record: 33 • 15-10-2007

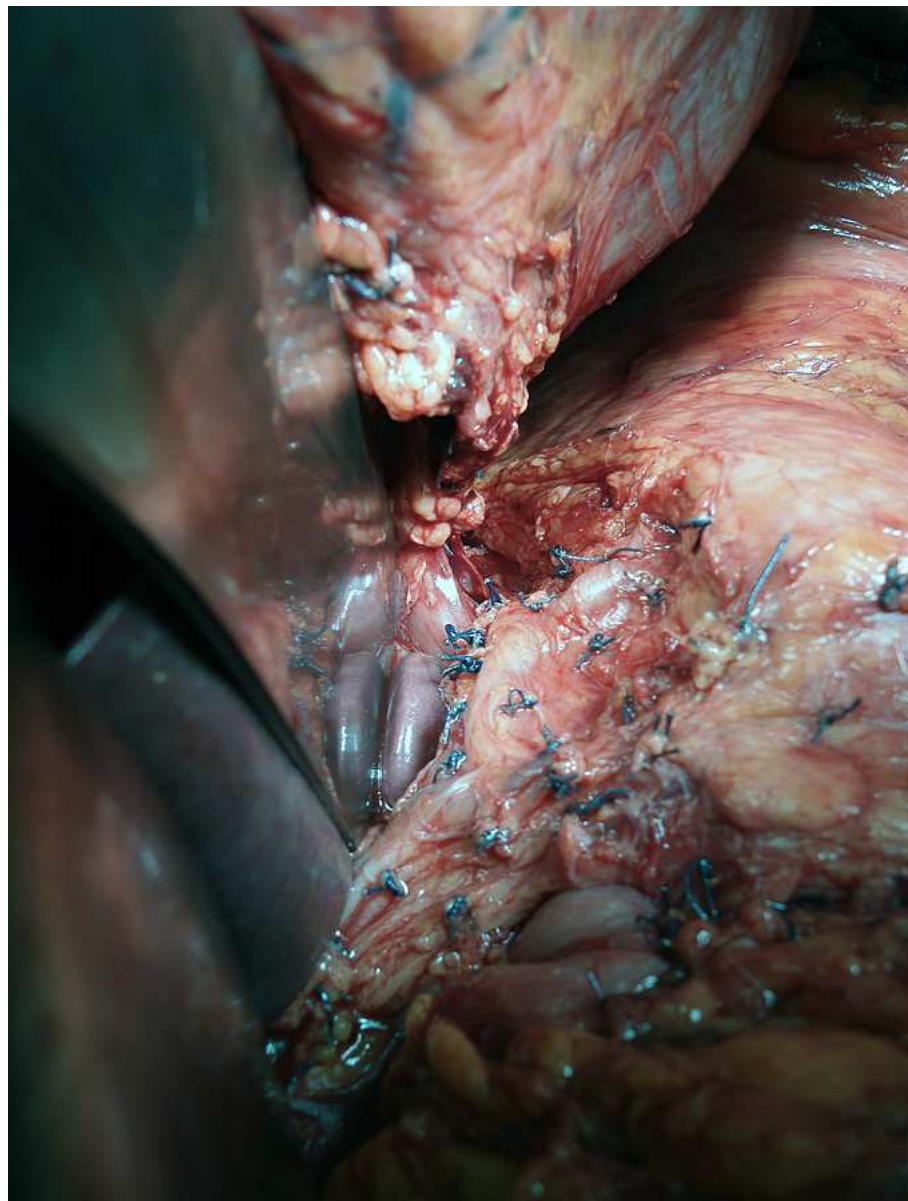
Gastrectomia totale per neoplasia della regione antrale. Esofago-digiunostomia T.L. con ansa alla Roux antecolica, reservoir sec. Hunt-Lawrence e digiunodigiunostomia L.L. al piede d'ansa



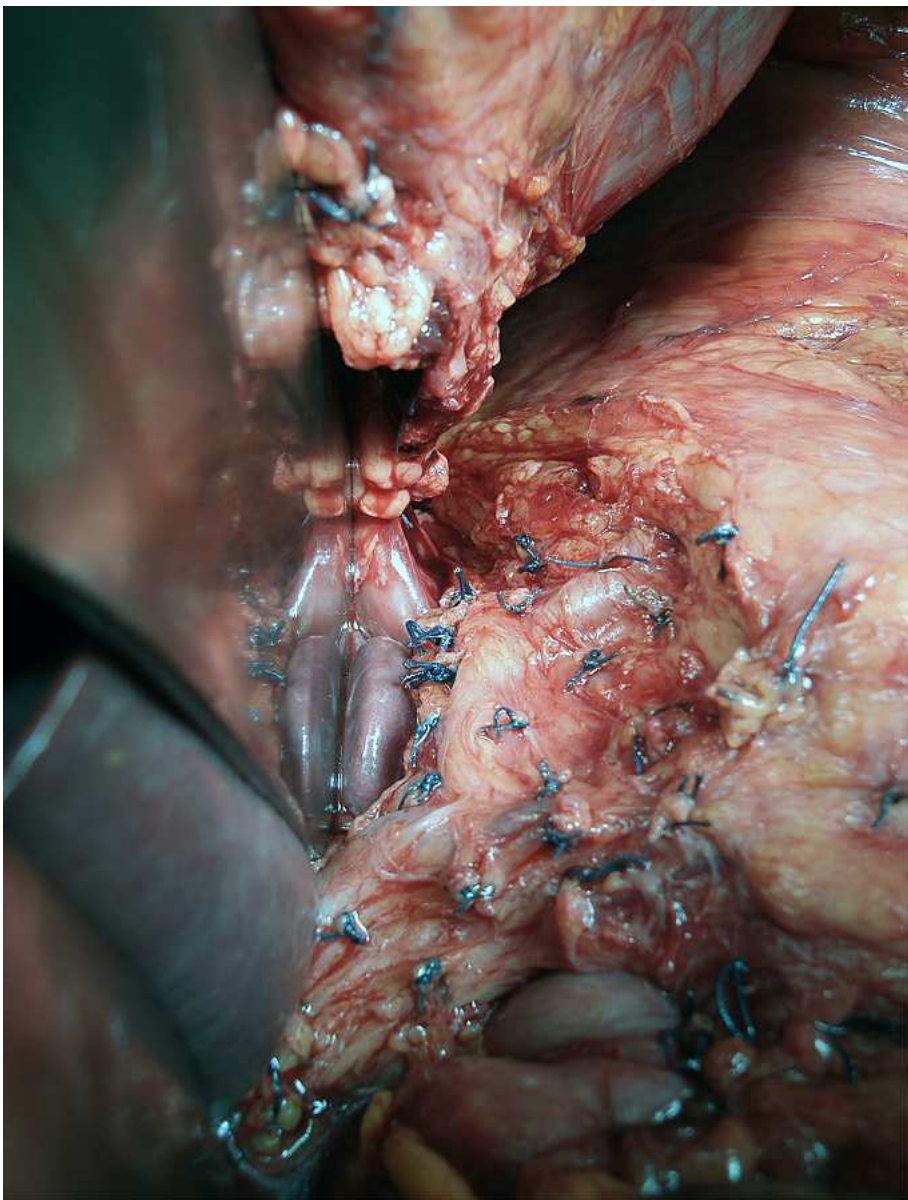
Linfoadenectomia del peduncolo epatico sec. Brenier



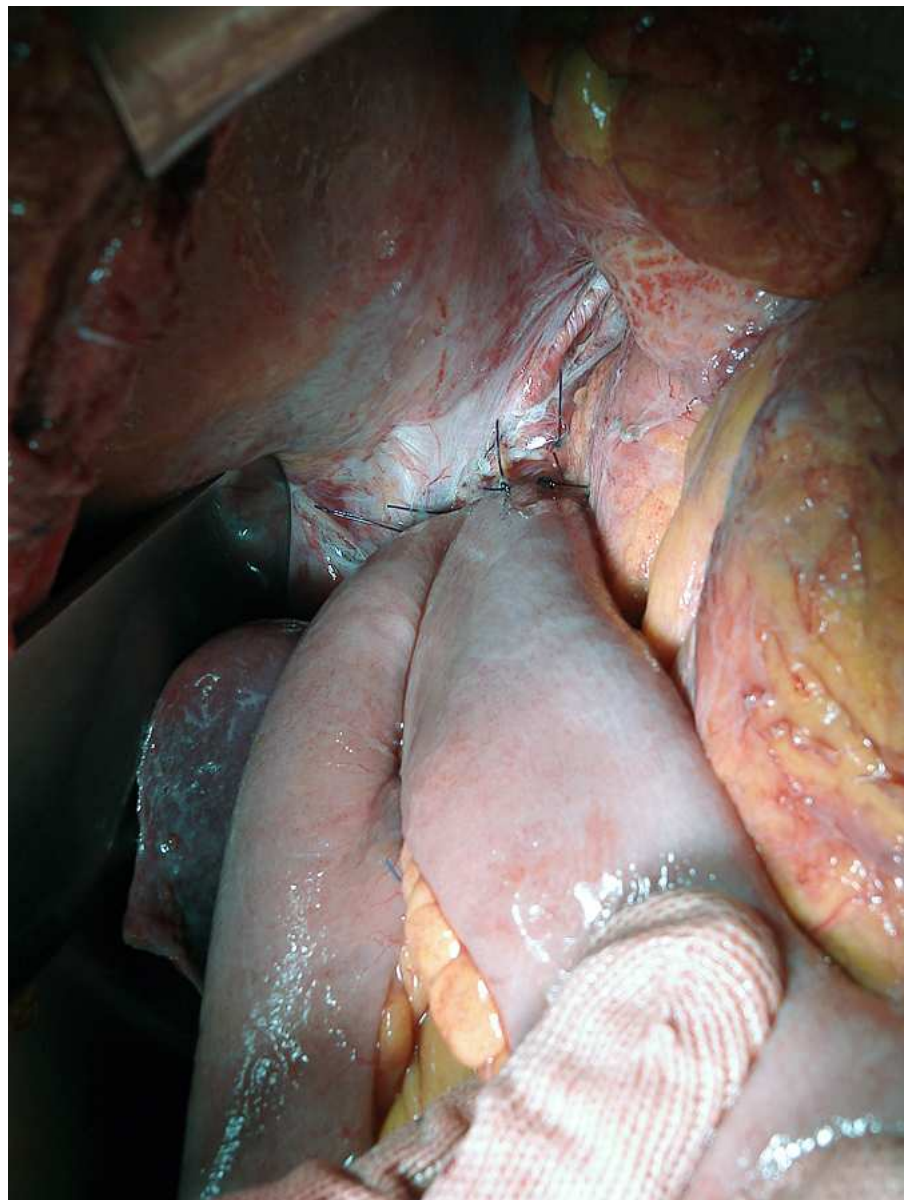Linfoadenectomia di I-II e III livello



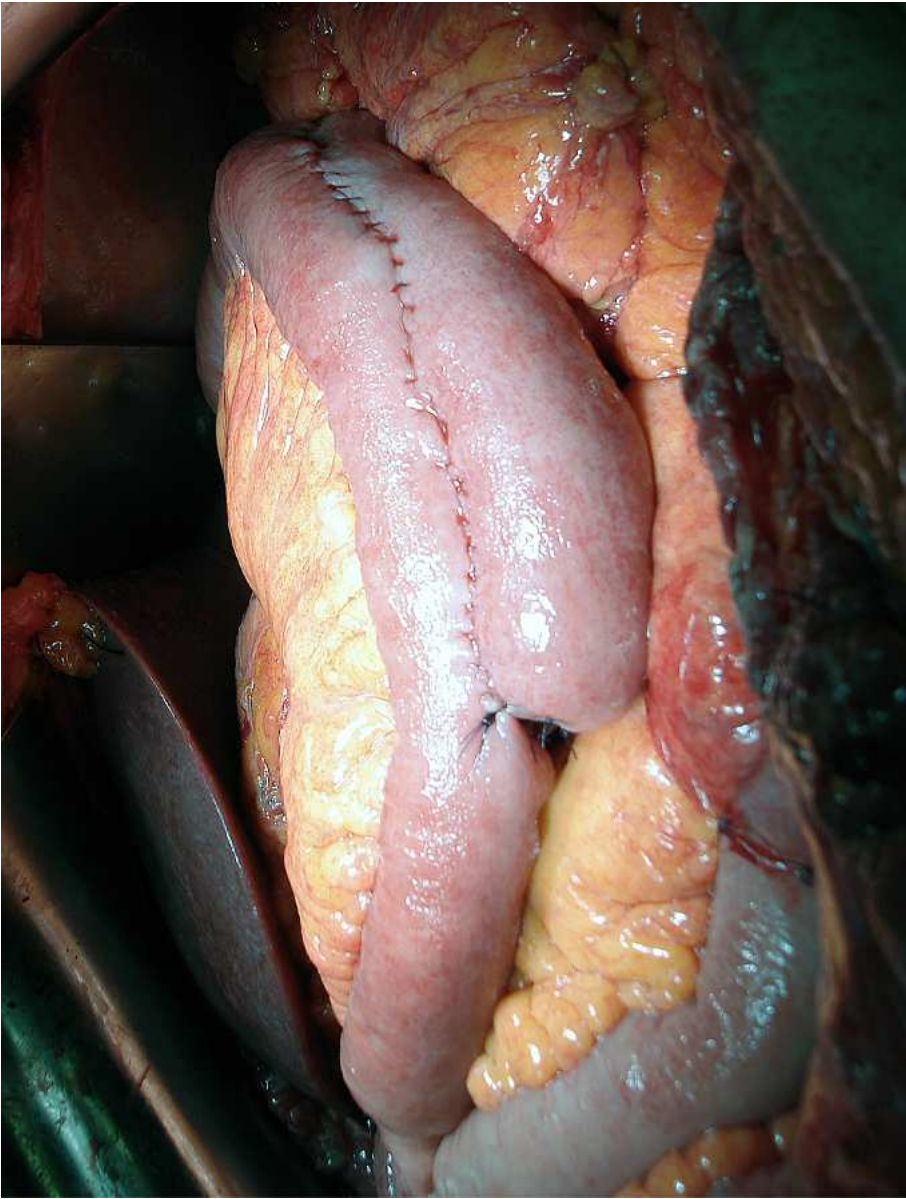Linfoadenectomia del tripode celiaco (arteria epatica, splenica, gastrica sn)



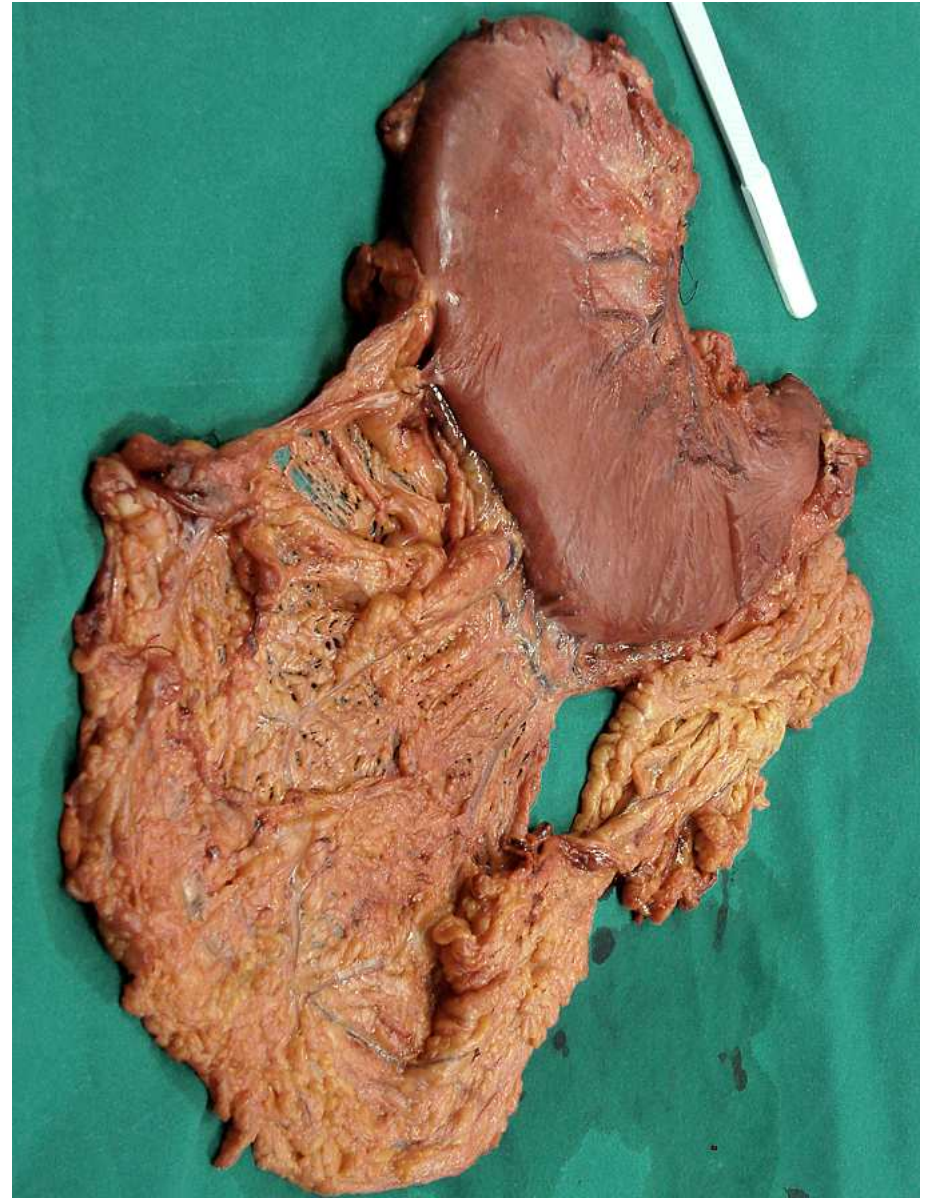
Linfoadenectomia retropancreatica e del tripode celiaco



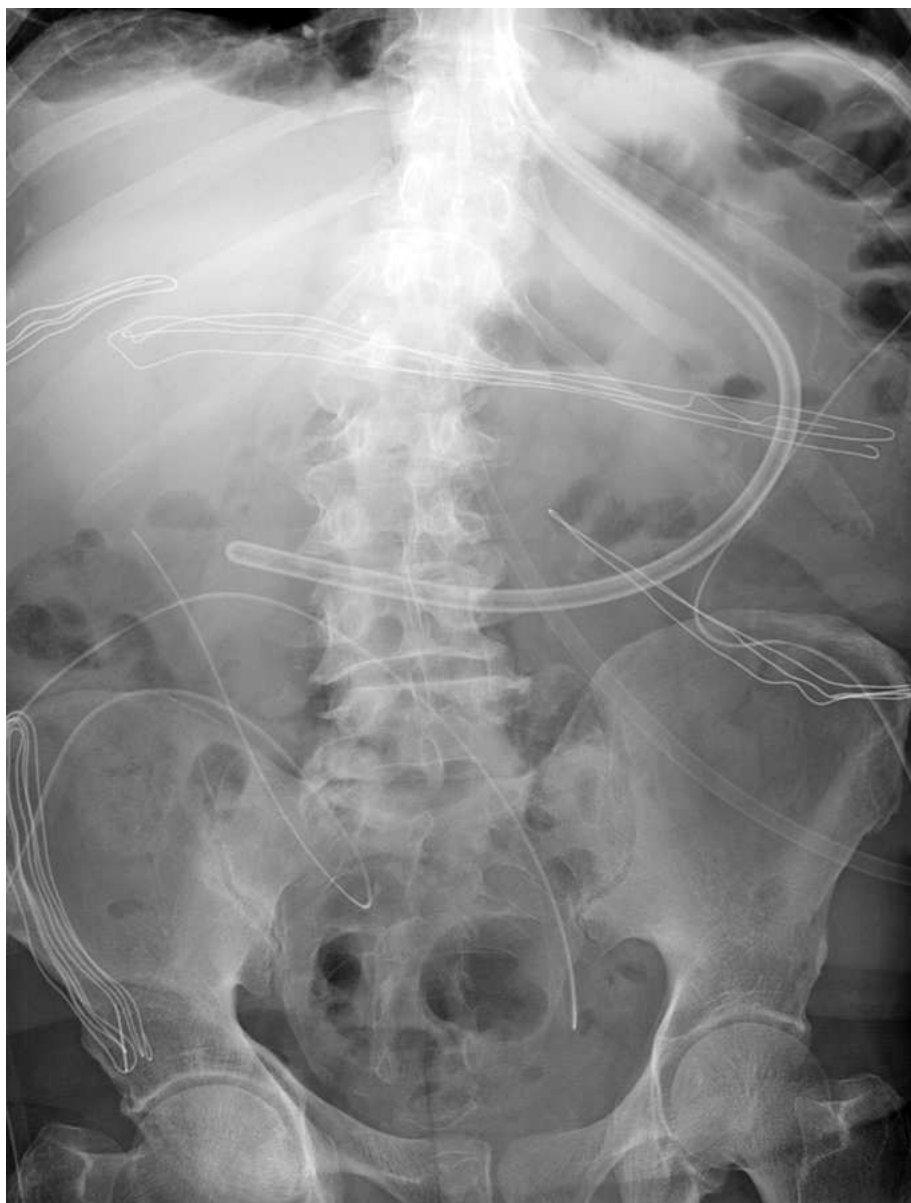Esofago-digiunostomia T.L. con ansa alla Roux



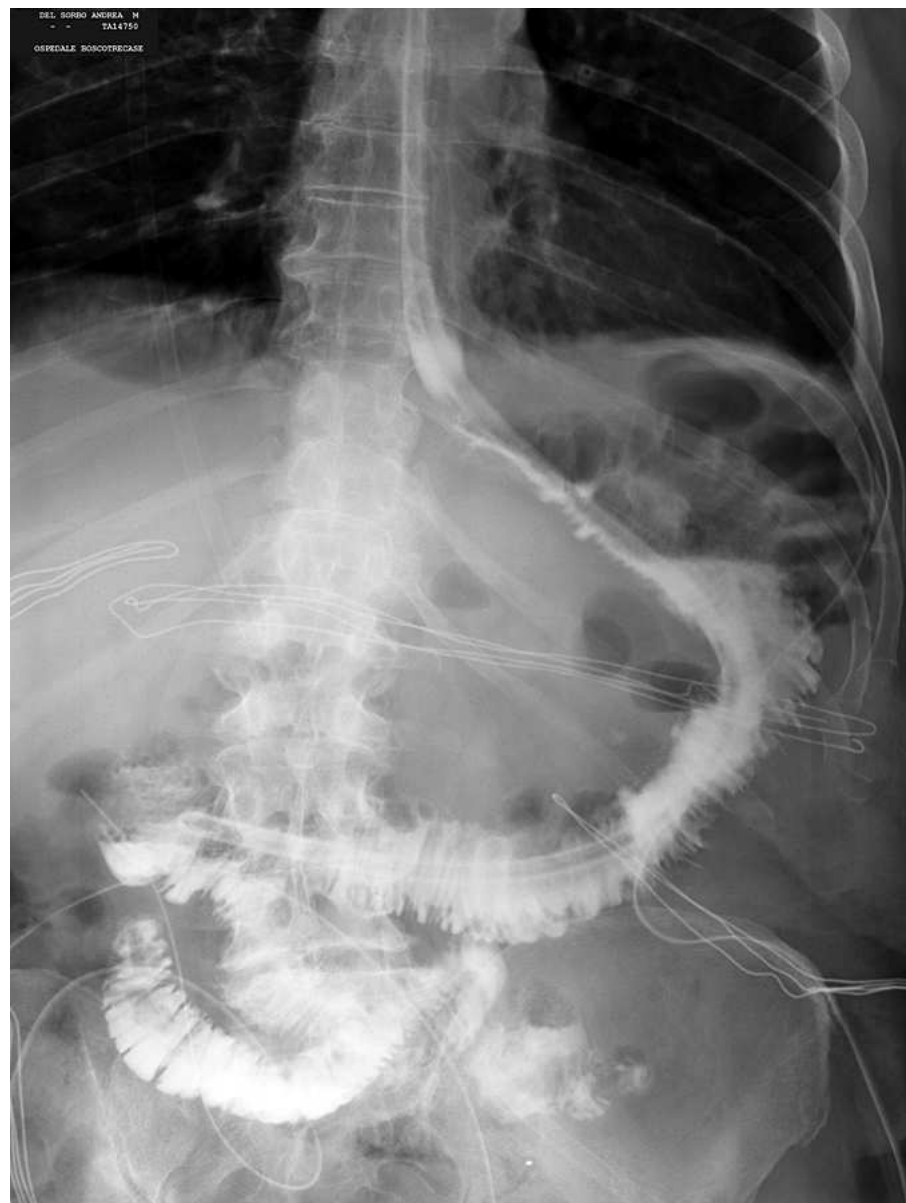Reservoir (sacca pseudogastrica) sec. Hunt-Lawrence



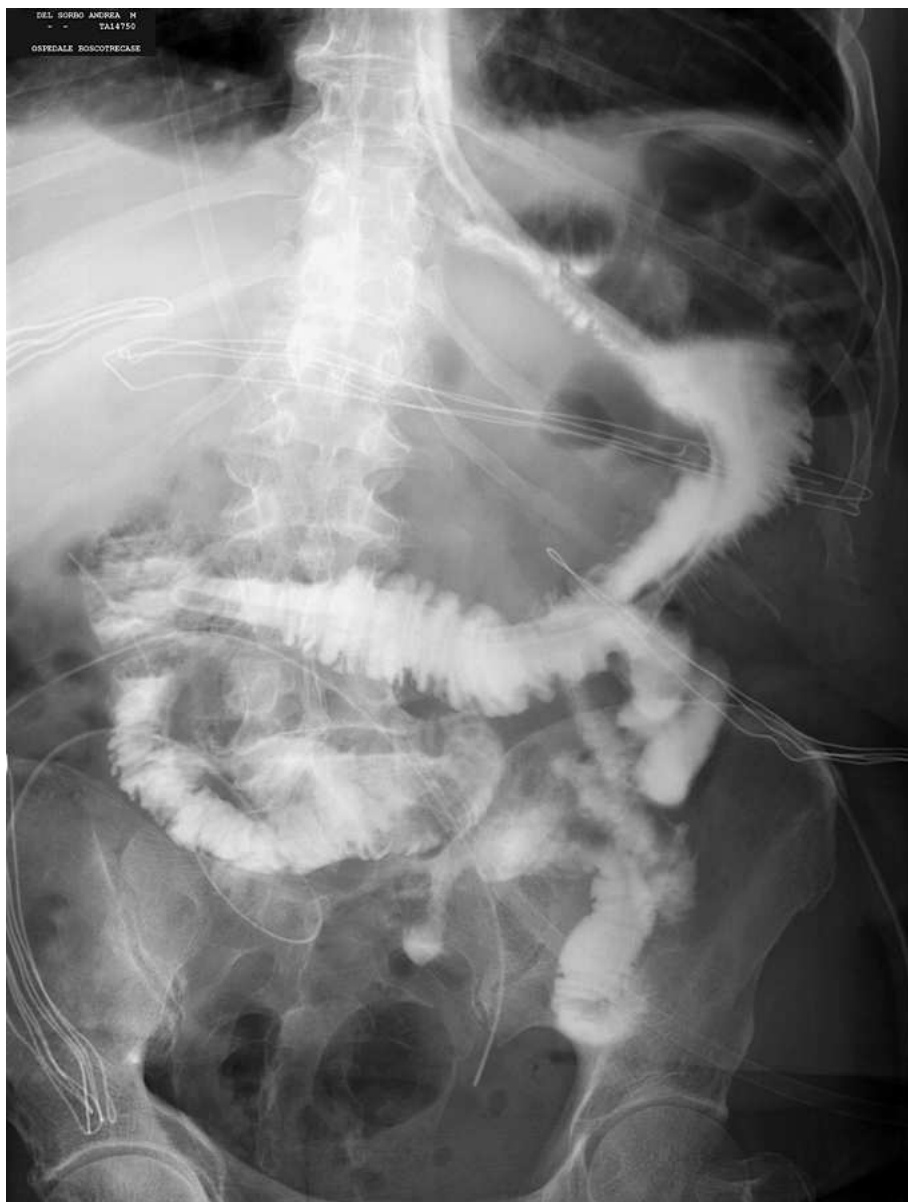Gastrectomia totale con epiploiectomia e linfadenectomia di I-II e III livello



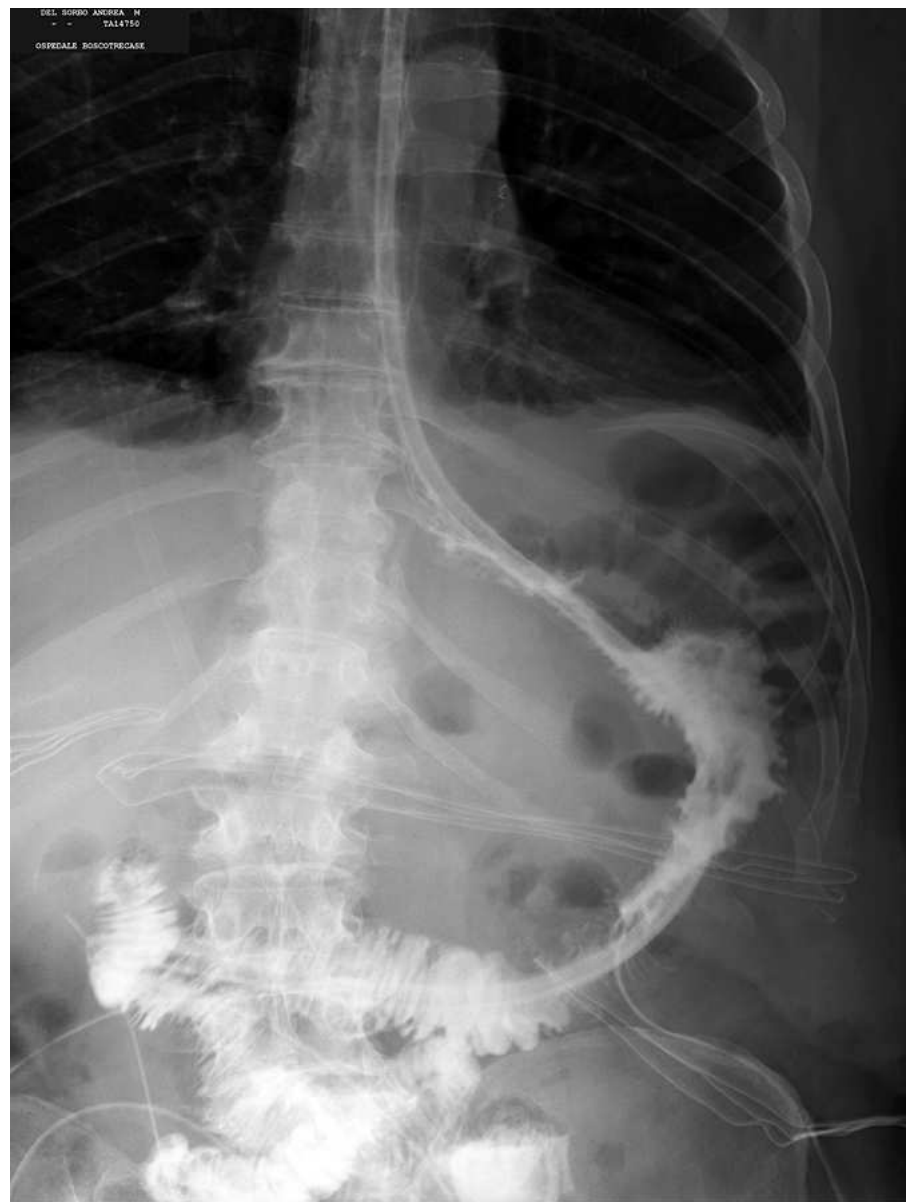Esofago-digiunostomia TL con ansa alla Roux antecolica e reservoir sec. Hunt-Lawrence



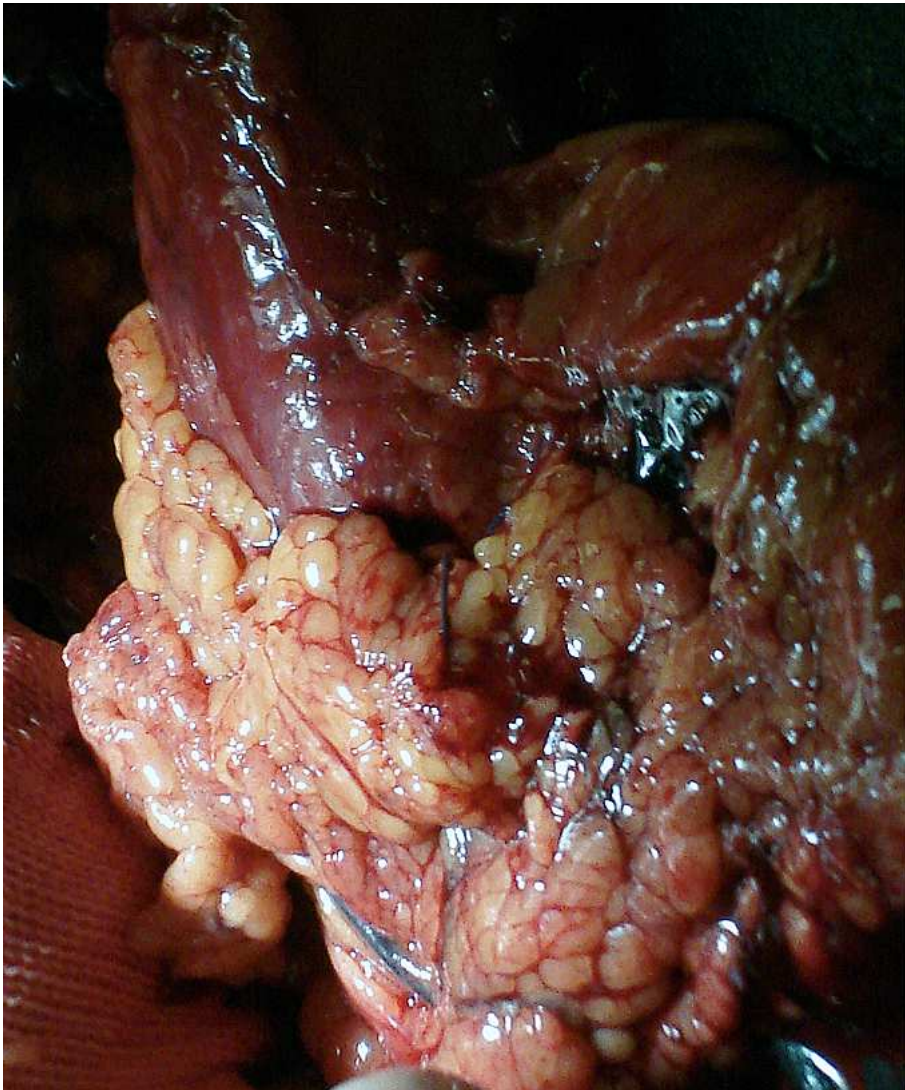
Controllo radiologico post-operatorio (X giornata)



Controllo radiologico post-operatorio (X giornata)

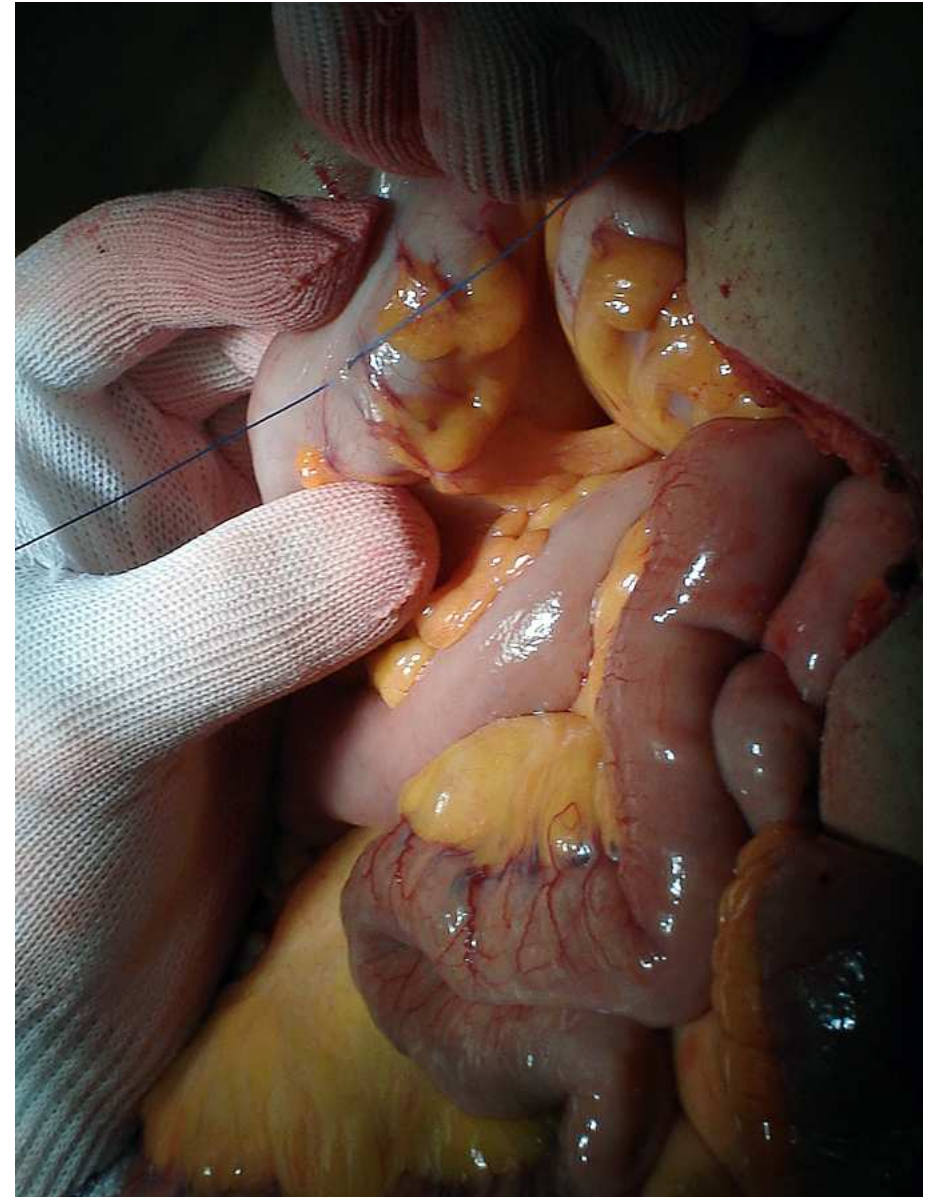

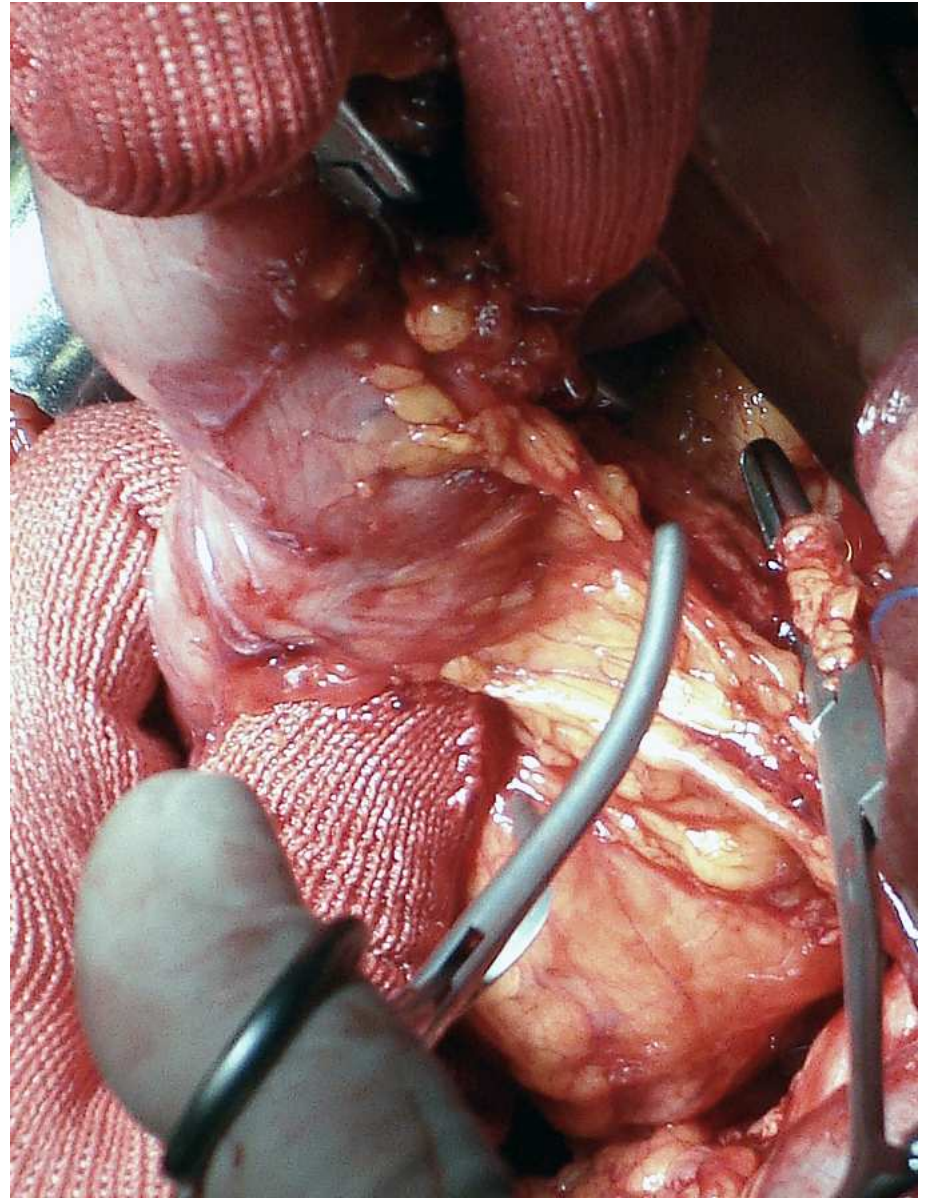
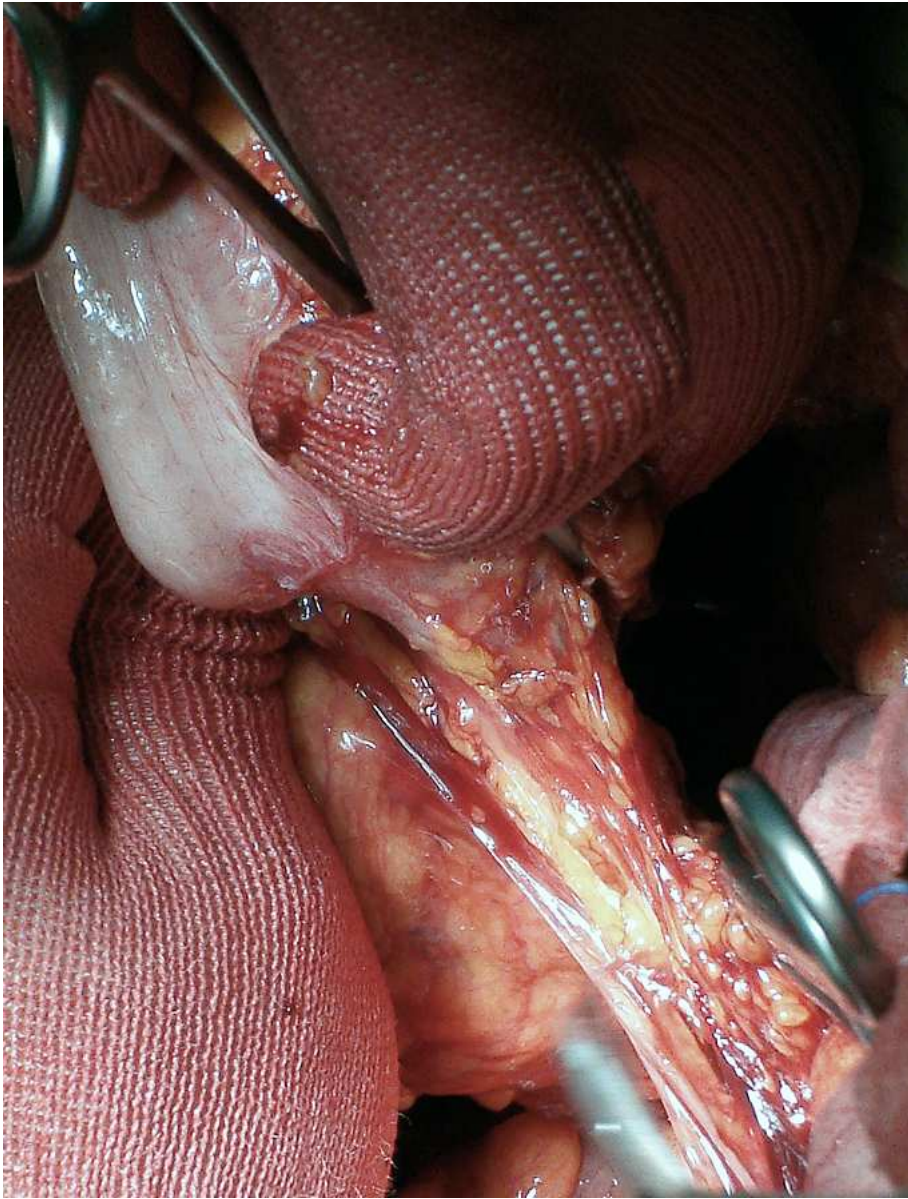
Controllo radiologico post-operatorio (X giornata)



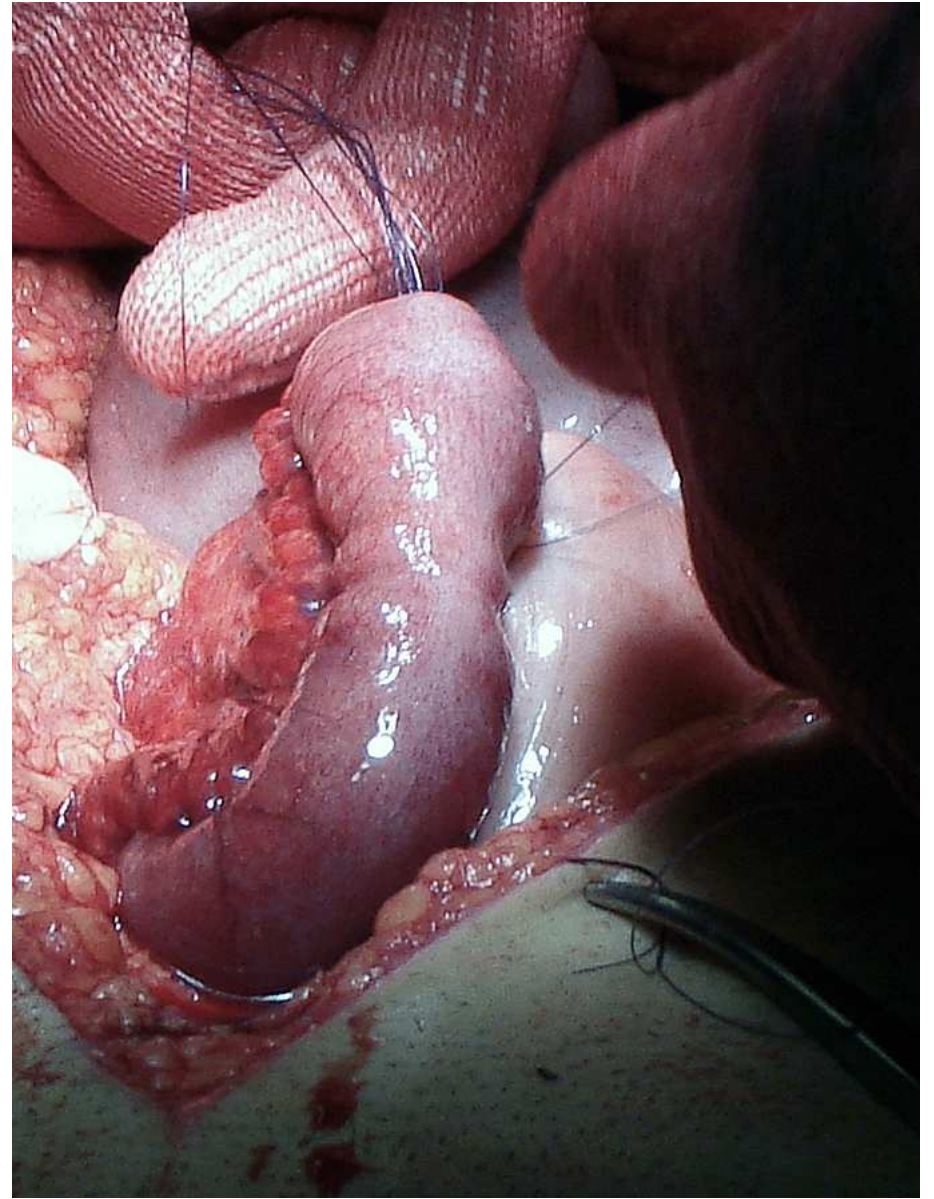
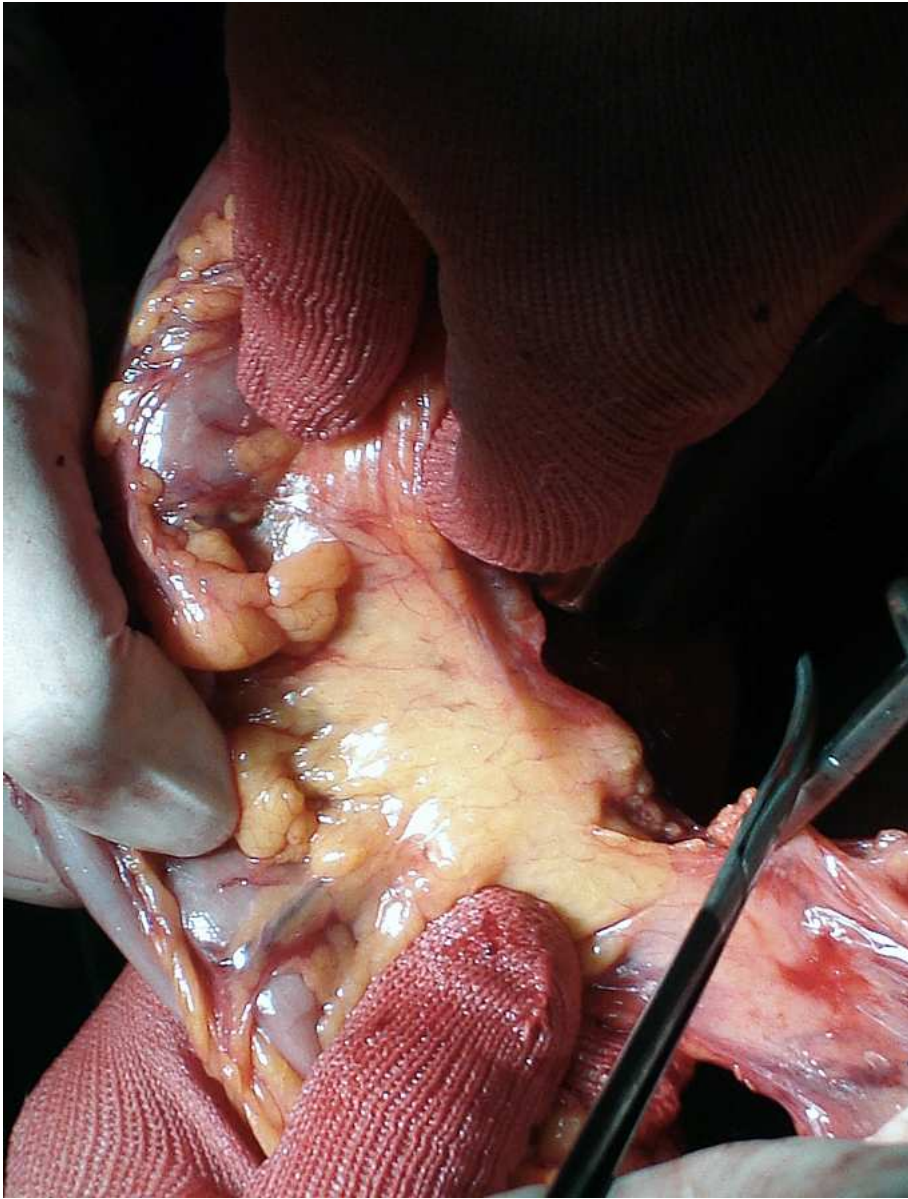
A.A. • Anni: 72 - M • Record: 34 • 17-10-2007

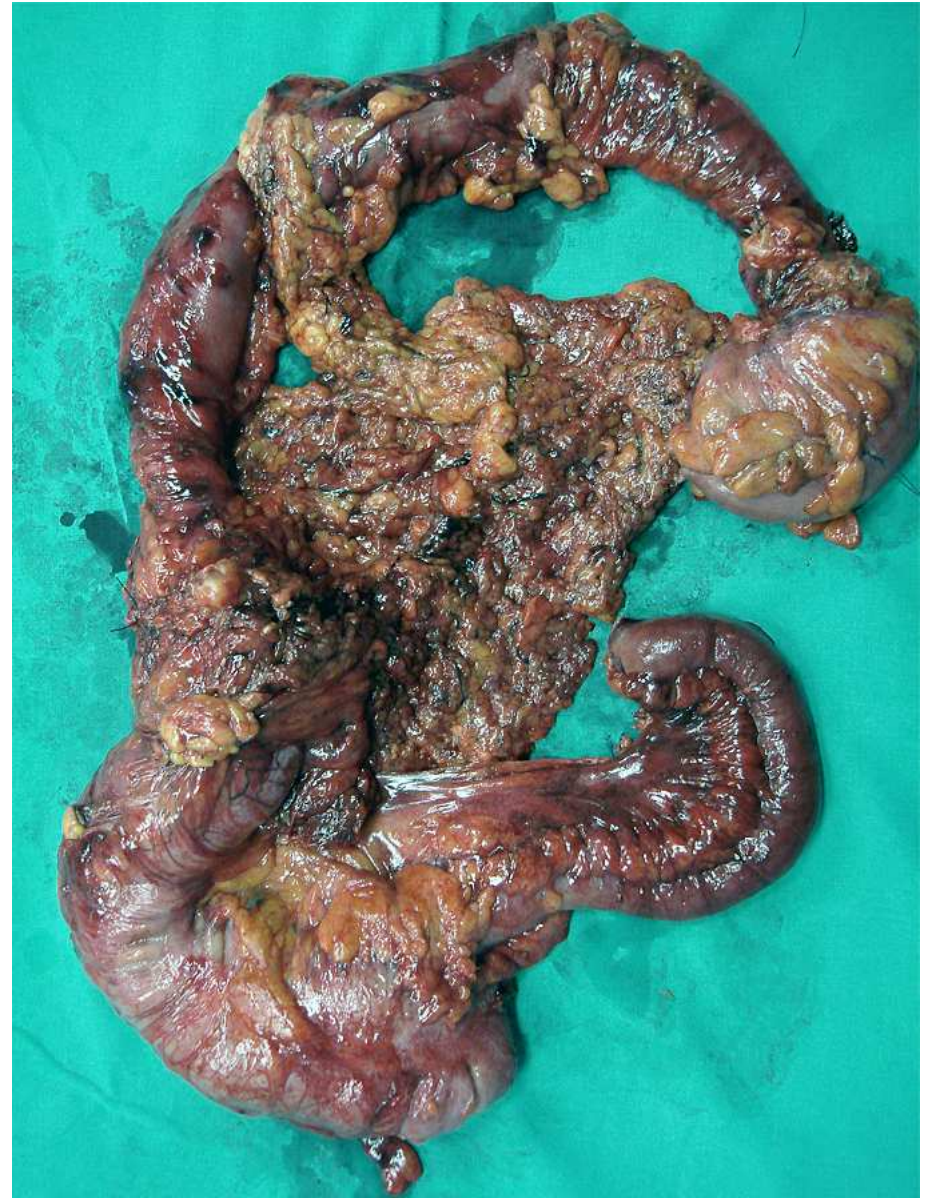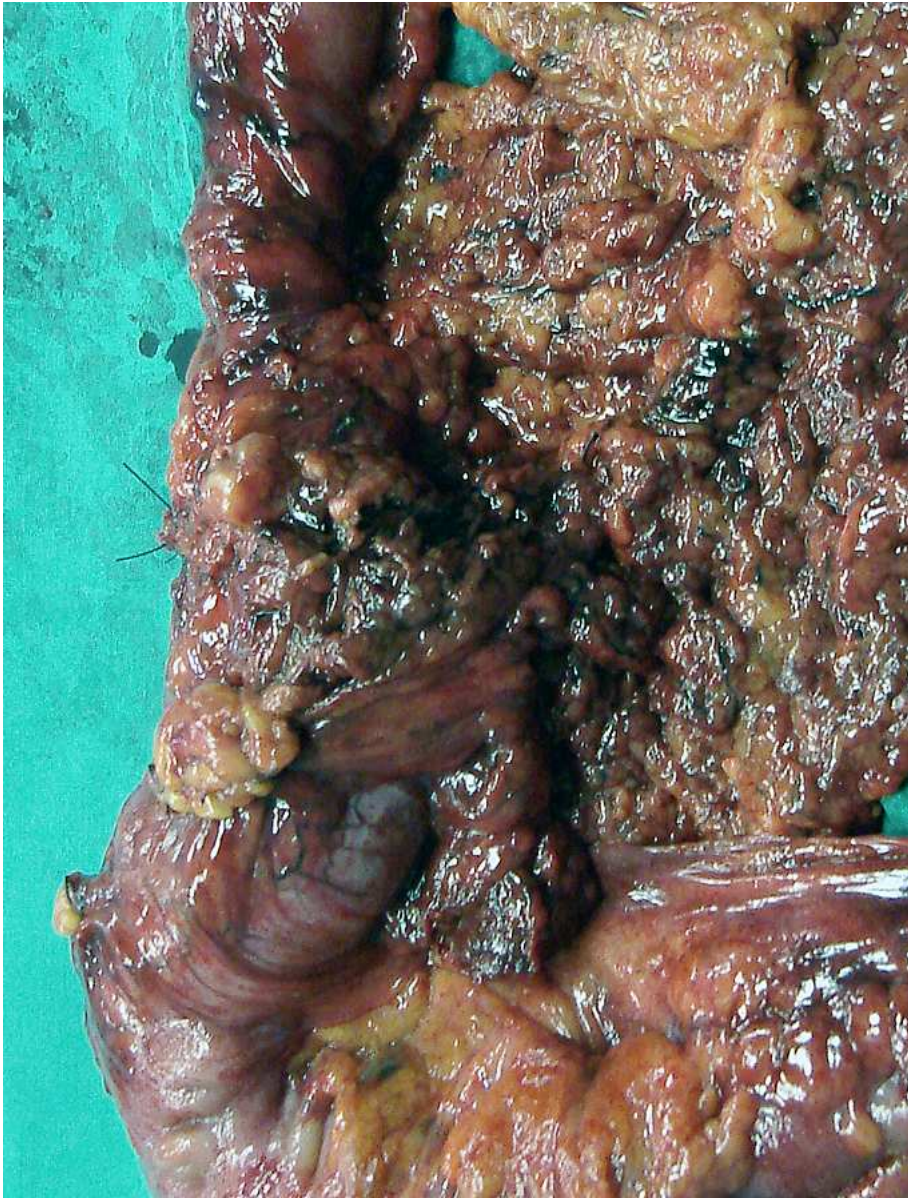Emicolectomia dx allargata al discendente-sigma e linfadenectomia perimesenterica superiore per neoplasia stenosante della flessura epatica e polipo sessile del discendente

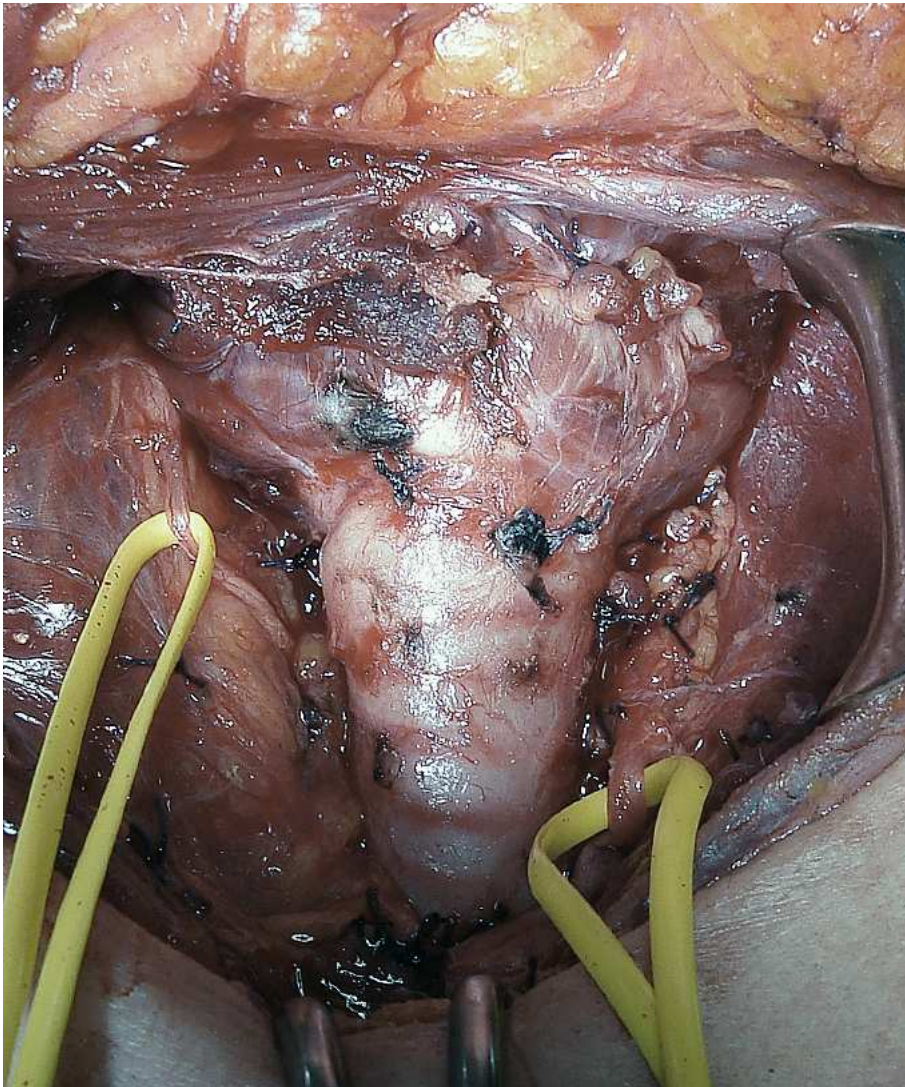






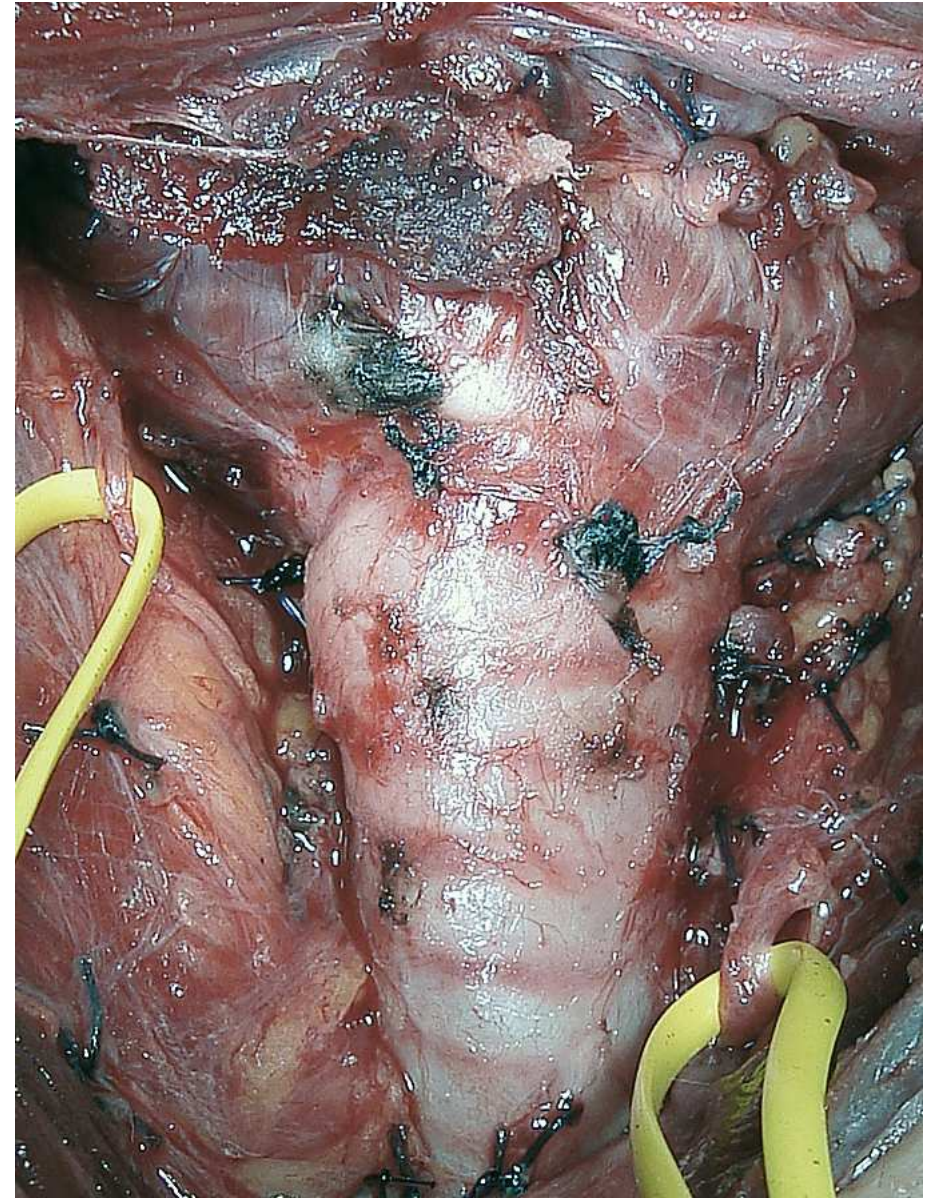




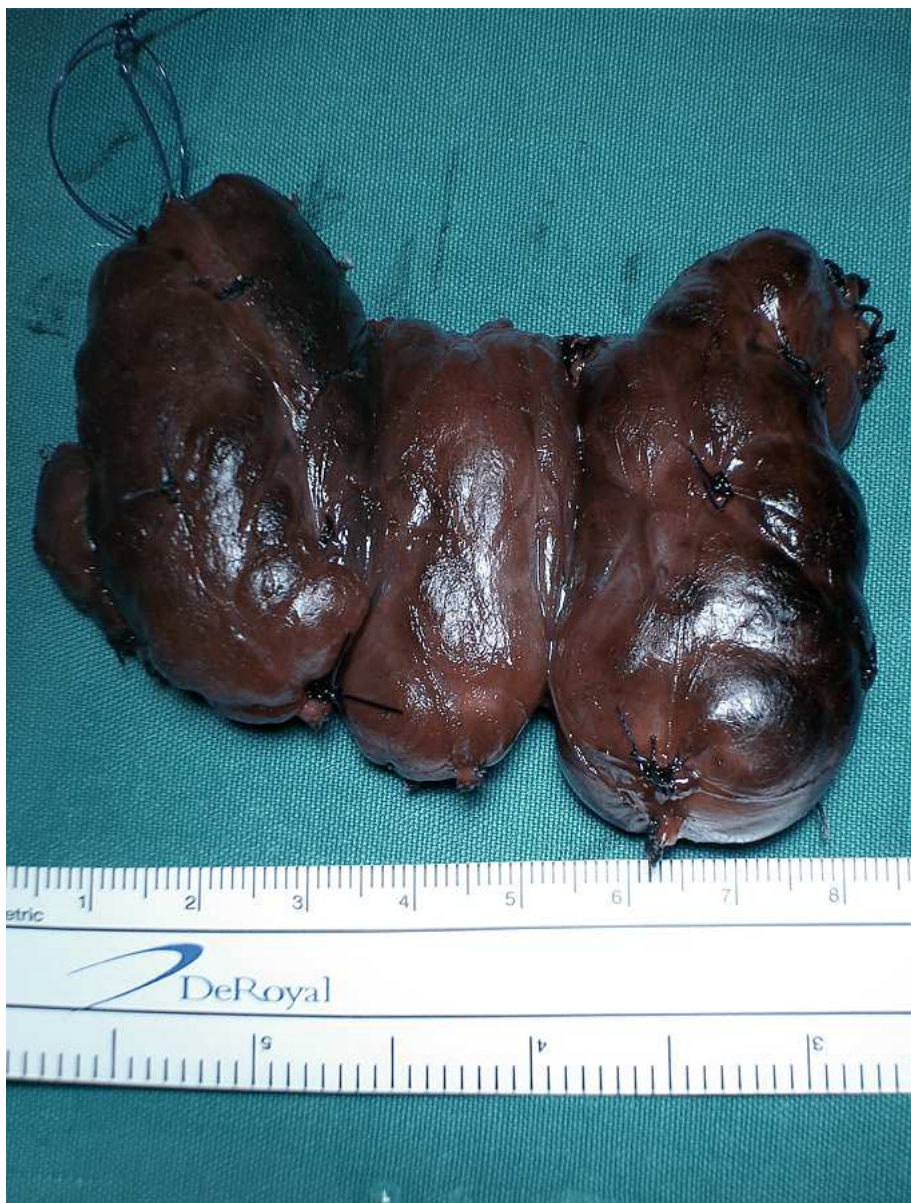

N.M. • Anni: 42 - F • Record: 35 • 26-11-2007

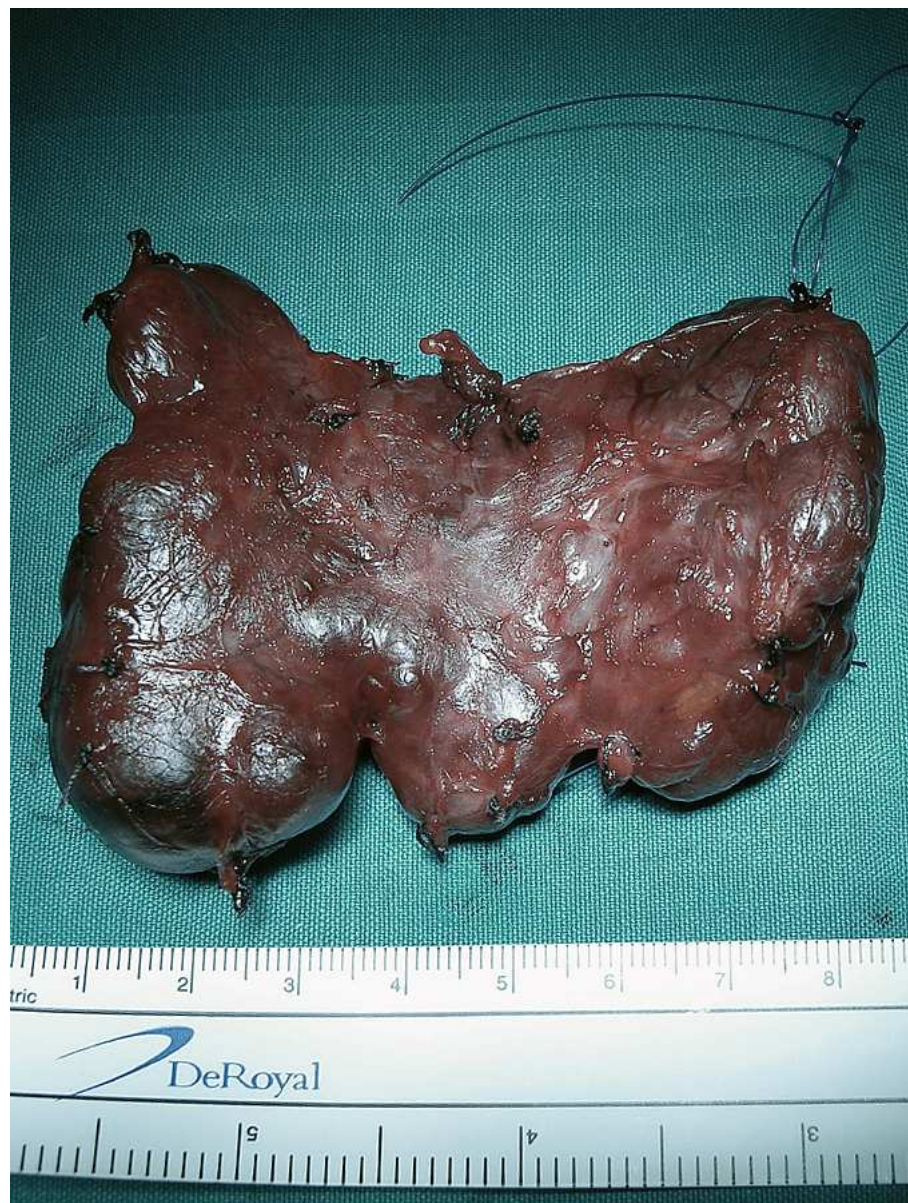Tiroidectomia totale extracapsulare per gozzo plurinodulare tossico



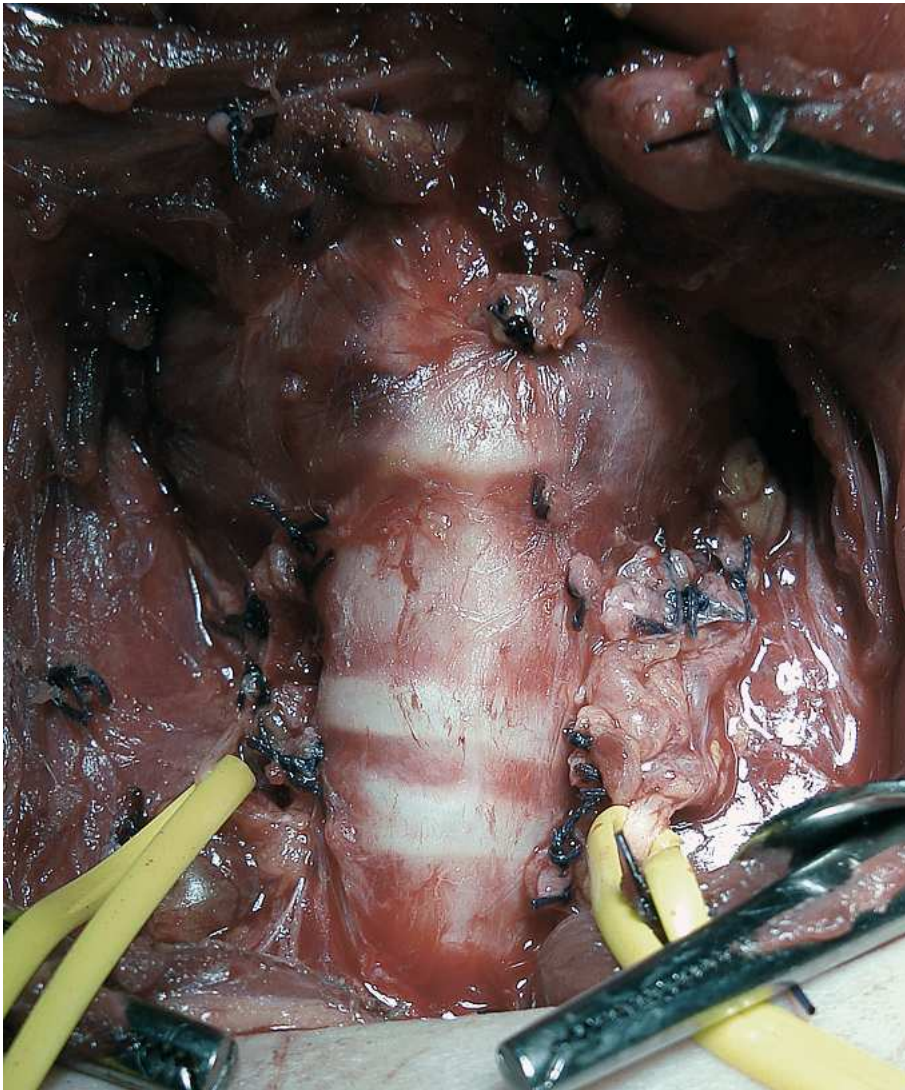
Isolamento dei nervi laringei inferiori (ricorrenti)



Lobo destro - Istmo - Lobo sinistro (superficie anteriore)

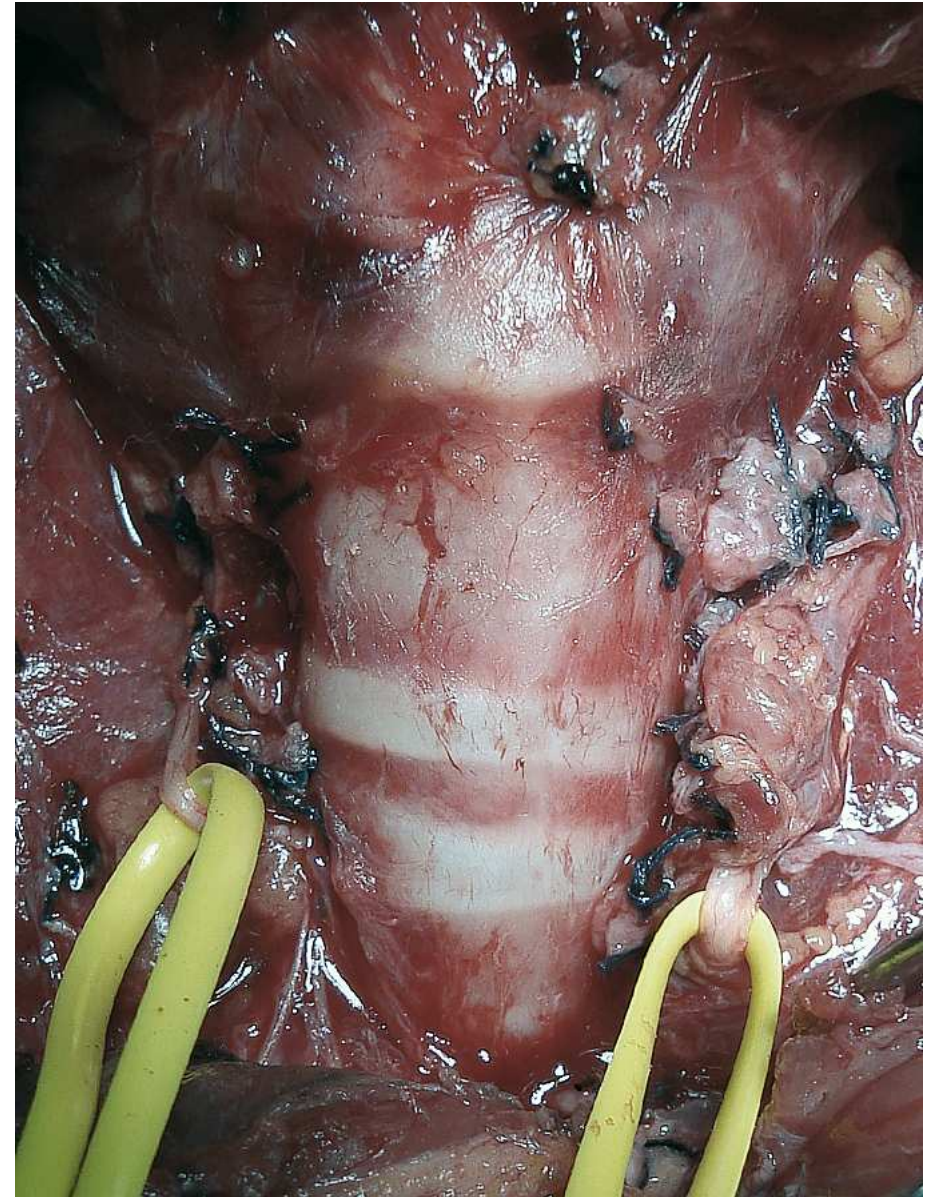


Lobo sinistro - Istmo - Lobo destro (superficie posteriore)

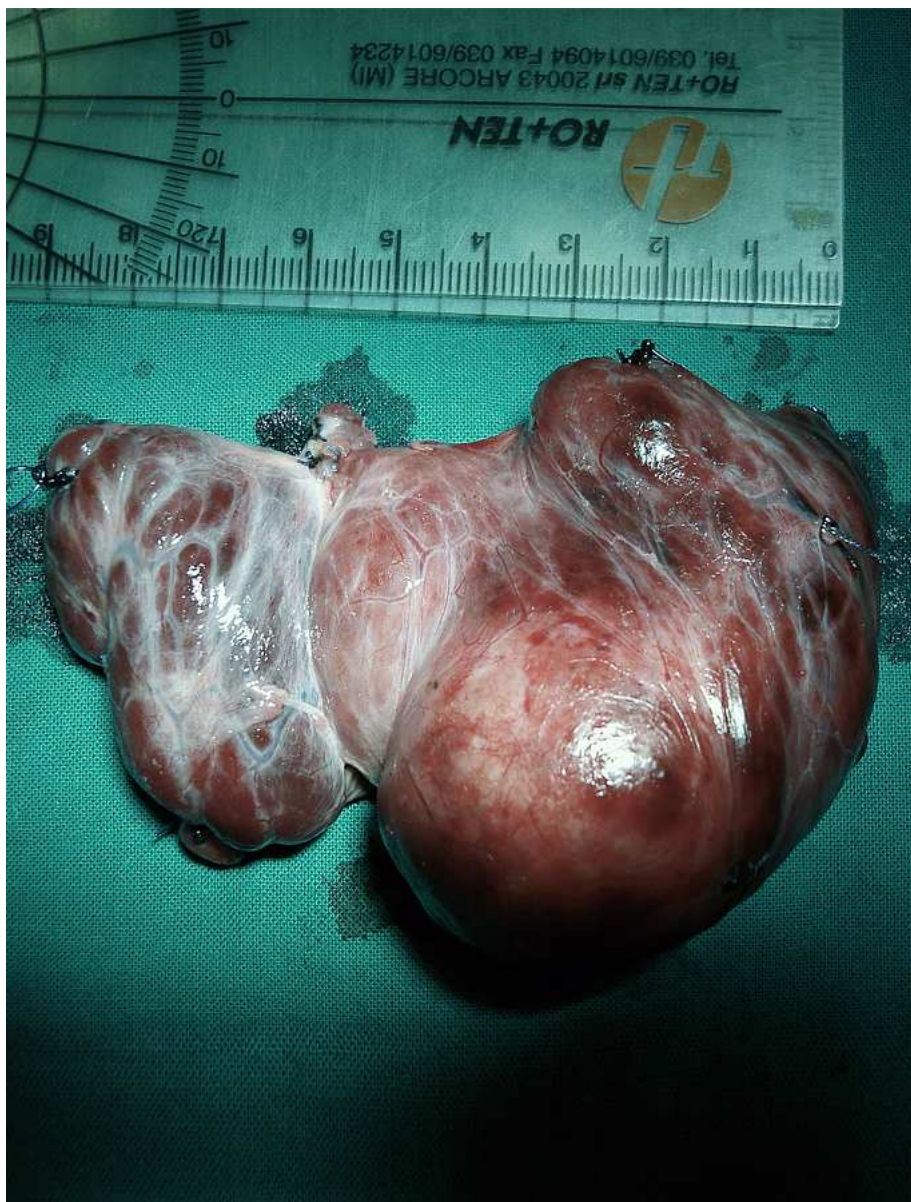

P.I. • Anni: 42 - F • Record: 36 • 13-12-2007

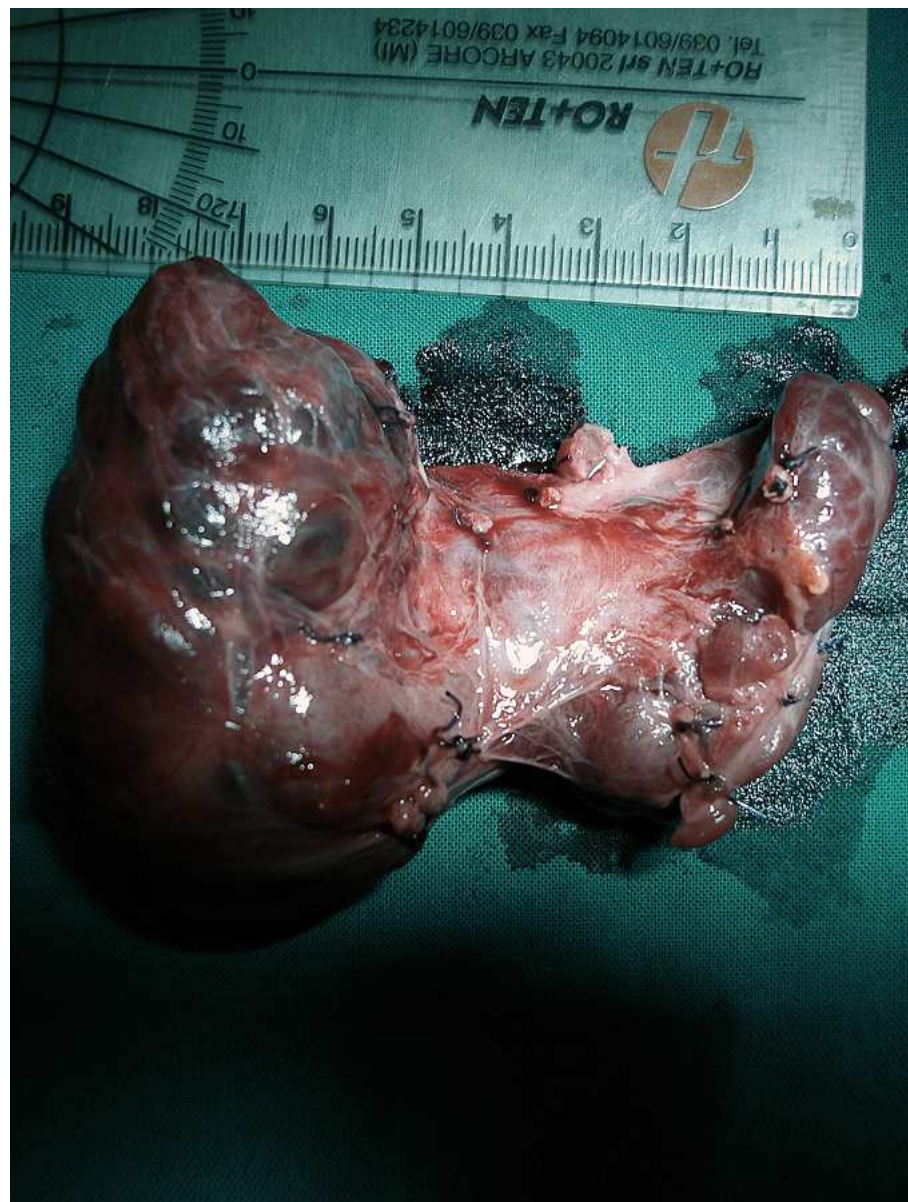Tiroidectomia totale extracapsulare per gozzo plurinodulare plongeant



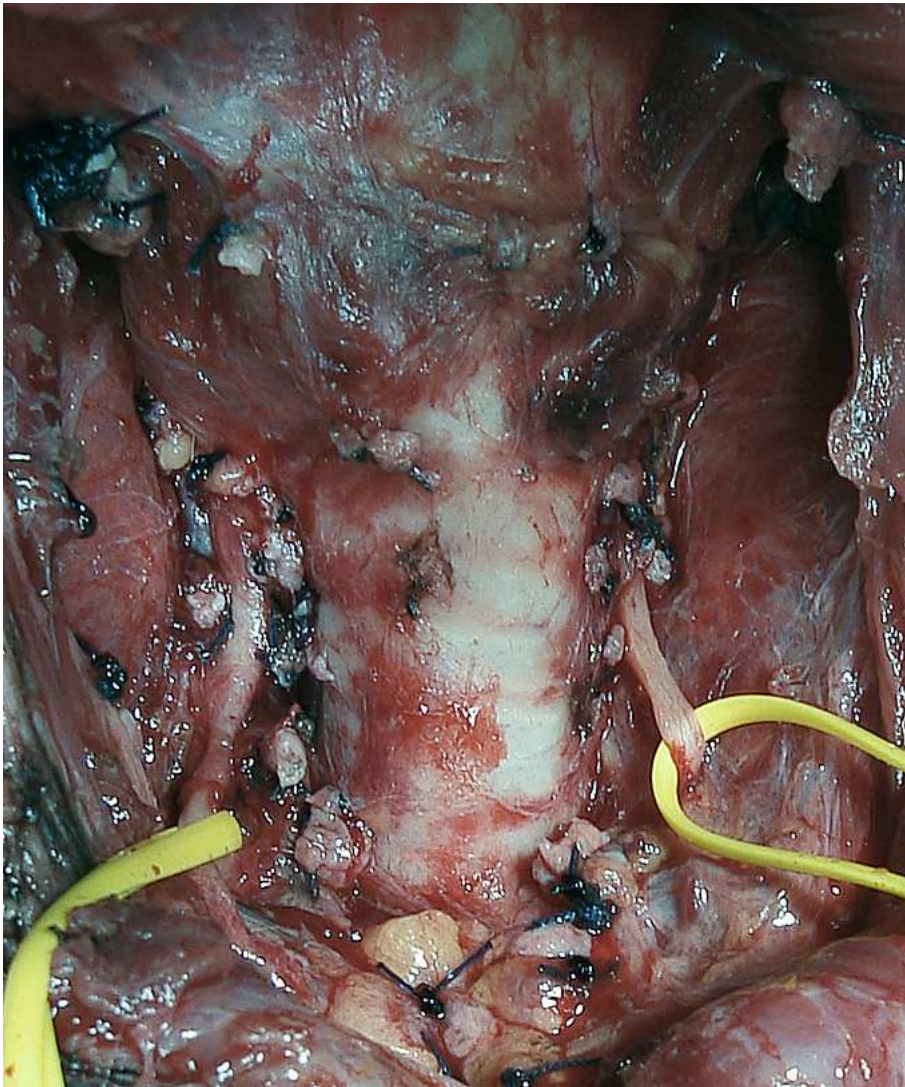
Isolamento dei nervi laringei inferiori (ricorrenti)



Lobo destro - Istmo - Lobo sinistro (superficie anteriore)

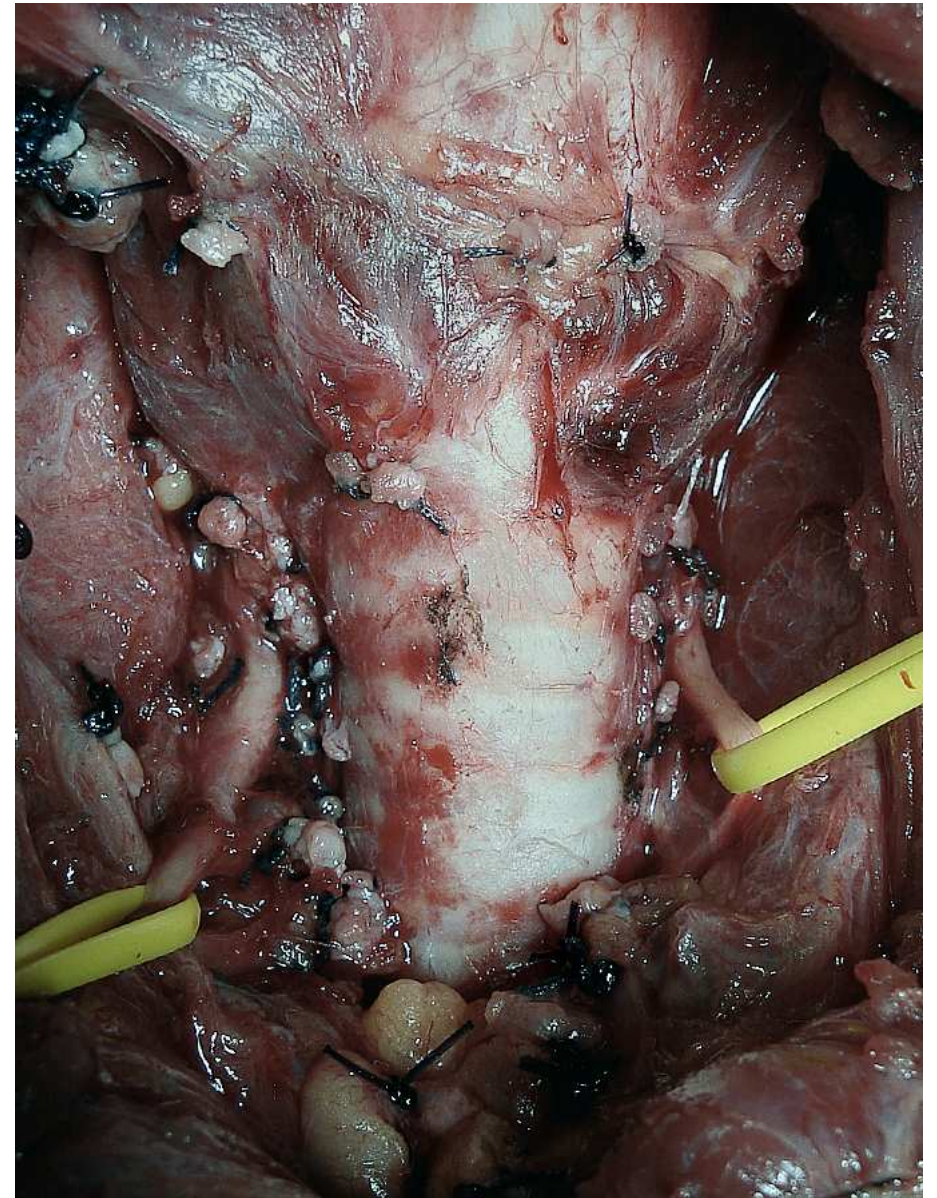


Lobo sinistro - Istmo - Lobo destro (superficie posteriore)

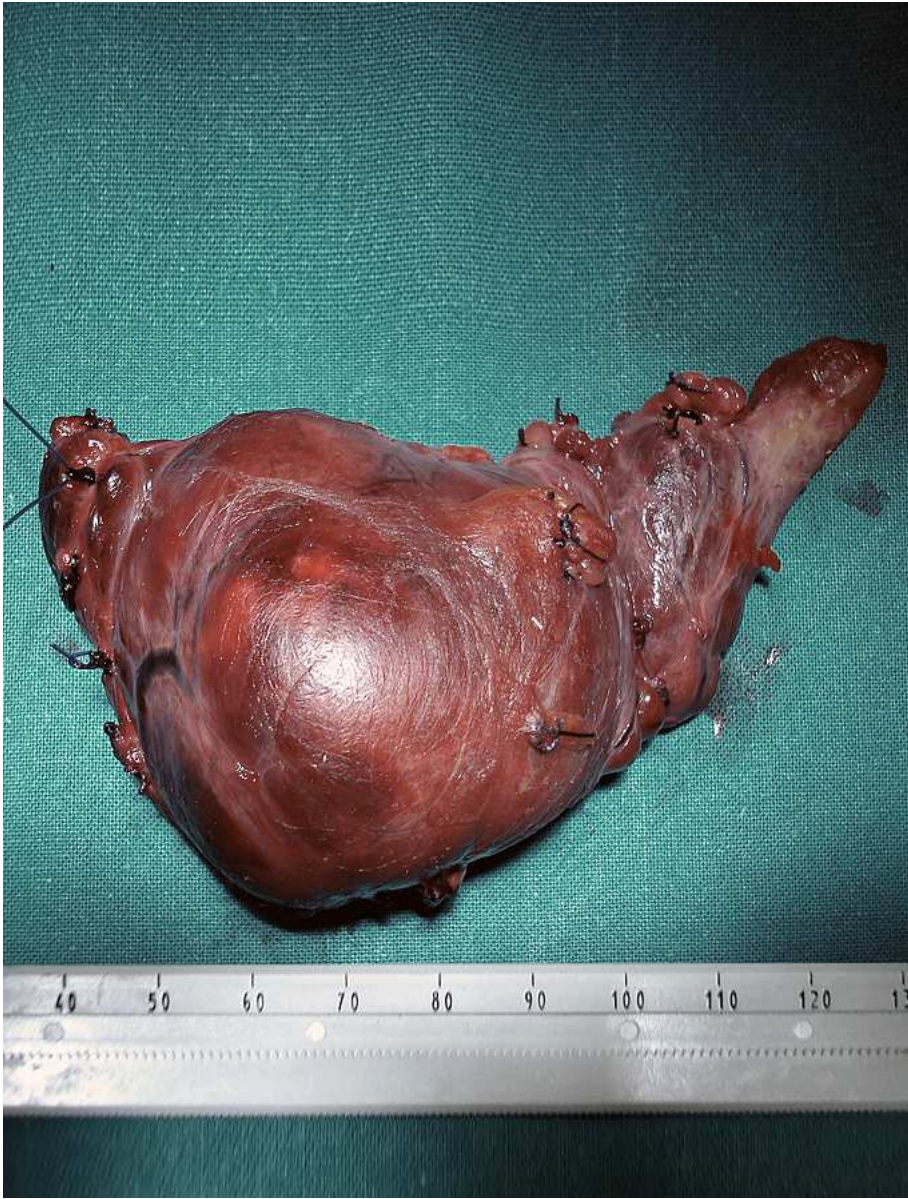

B.A. • Anni: 72 - F • Record: 37 • 20-12-2007

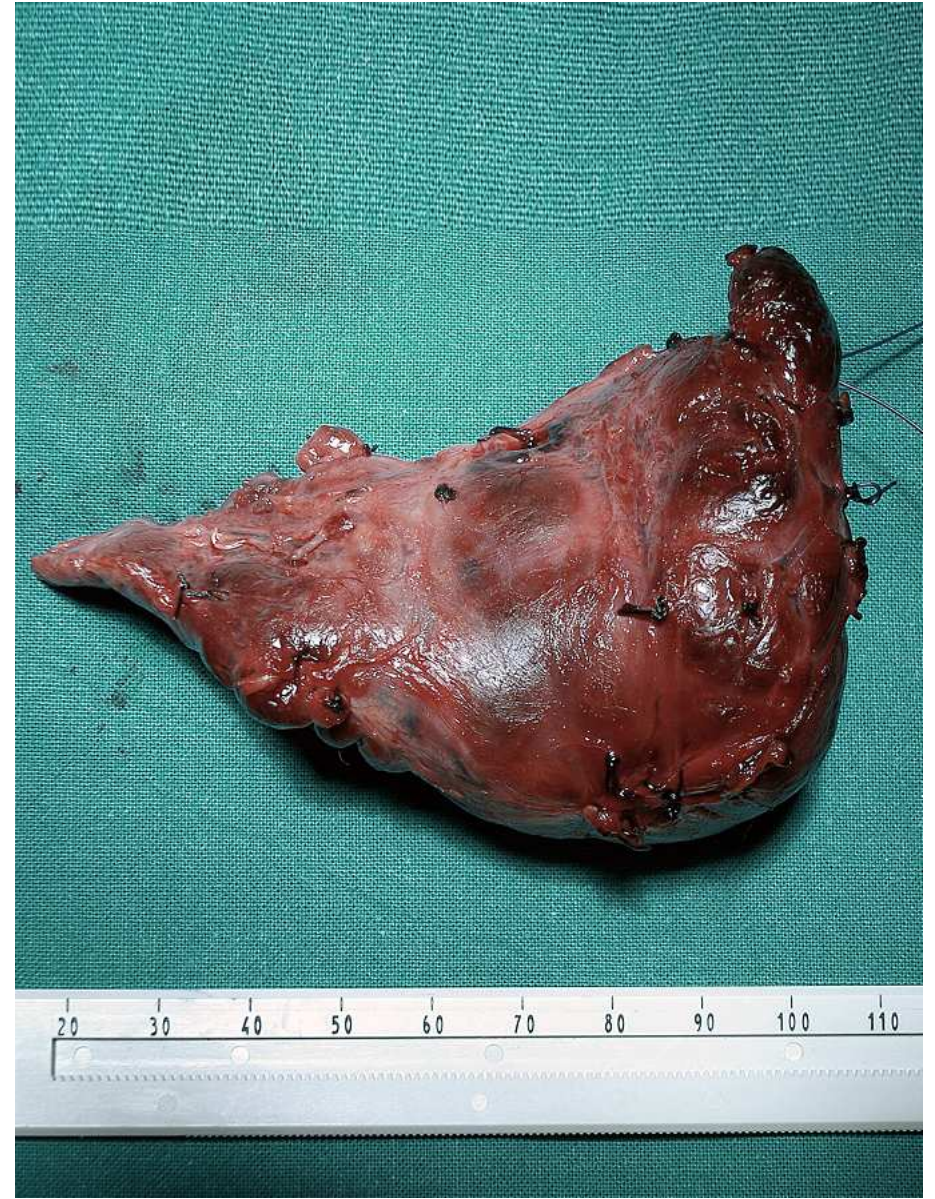Tiroidectomia totale extracapsulare per gozzo plurinodulare plongeant a dx



Isolamento dei nervi laringei inferiori (ricorrenti)

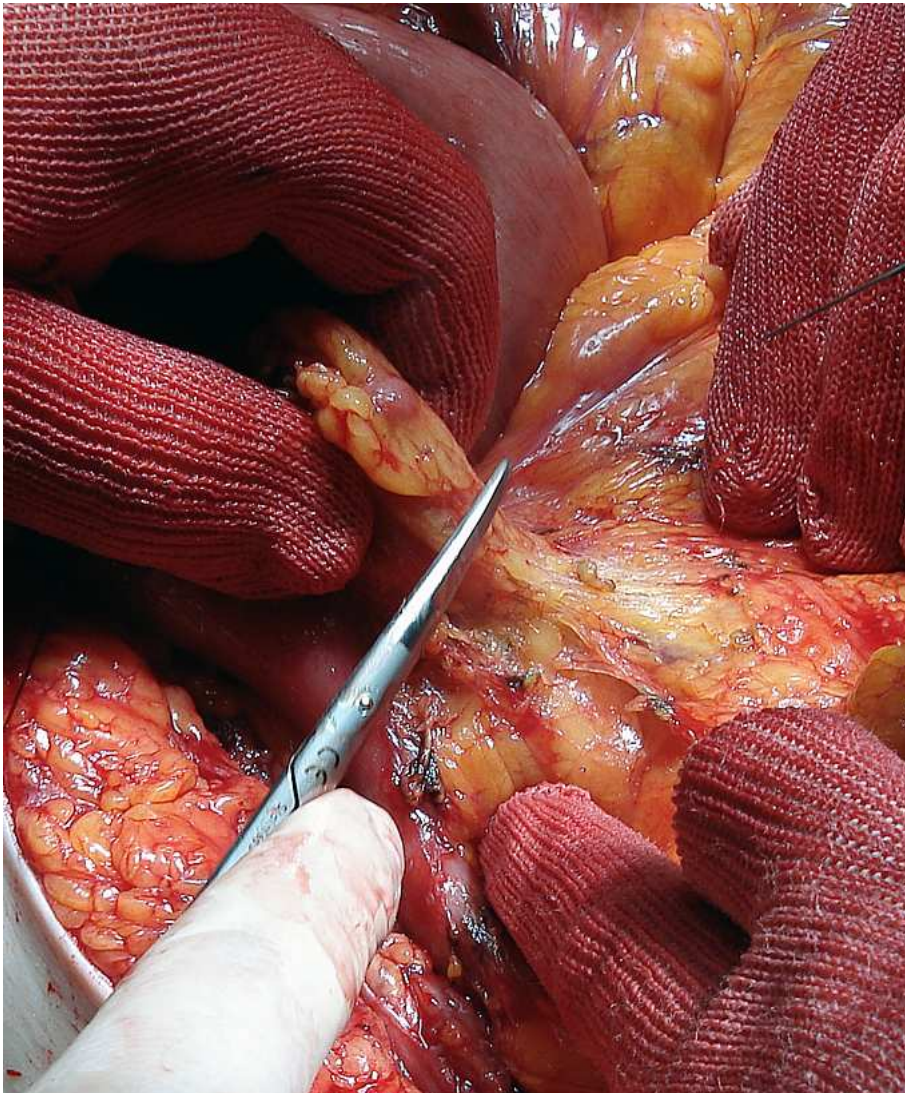

Lobo destro - Istmo - Lobo sinistro (superficie anteriore)



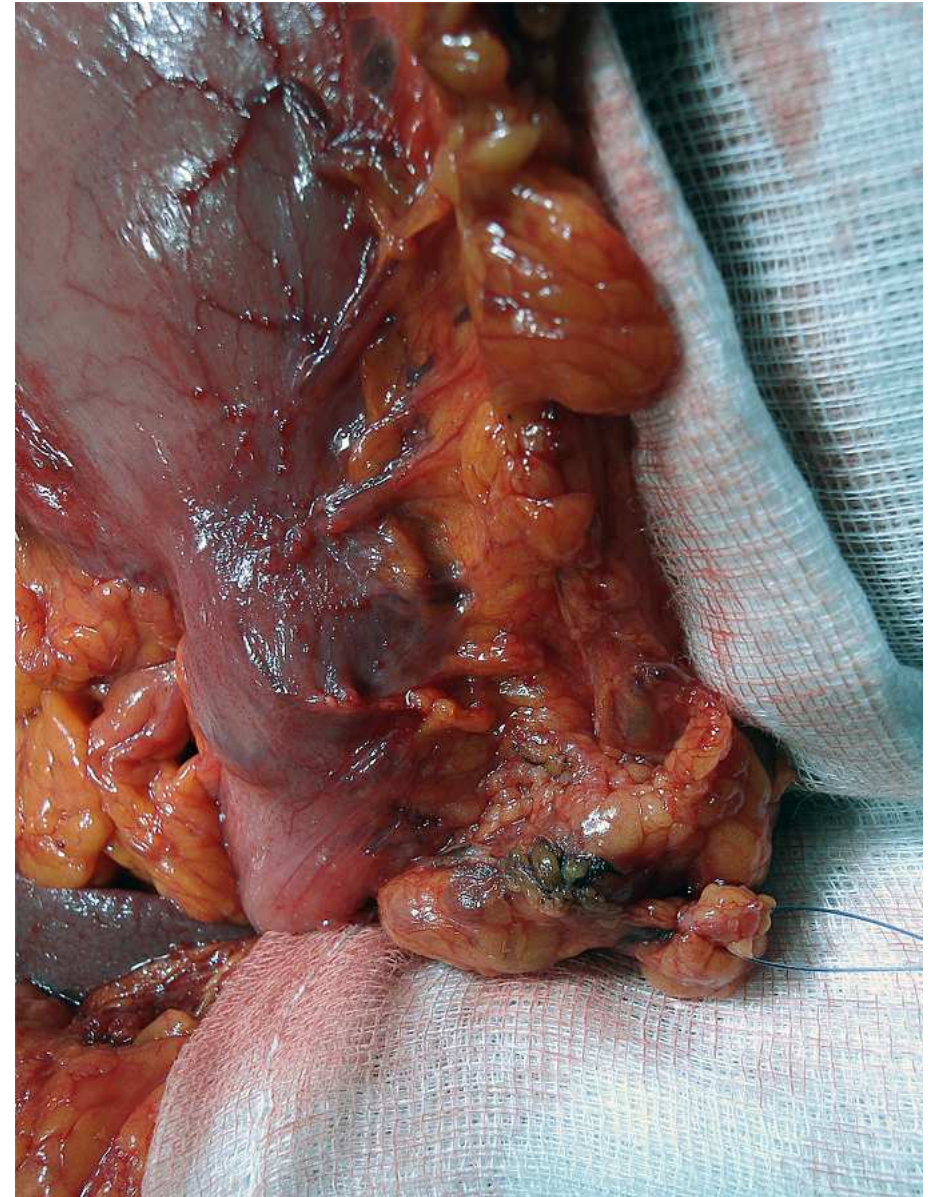
Lobo sinistro - Istmo - Lobo destro (superficie posteriore)



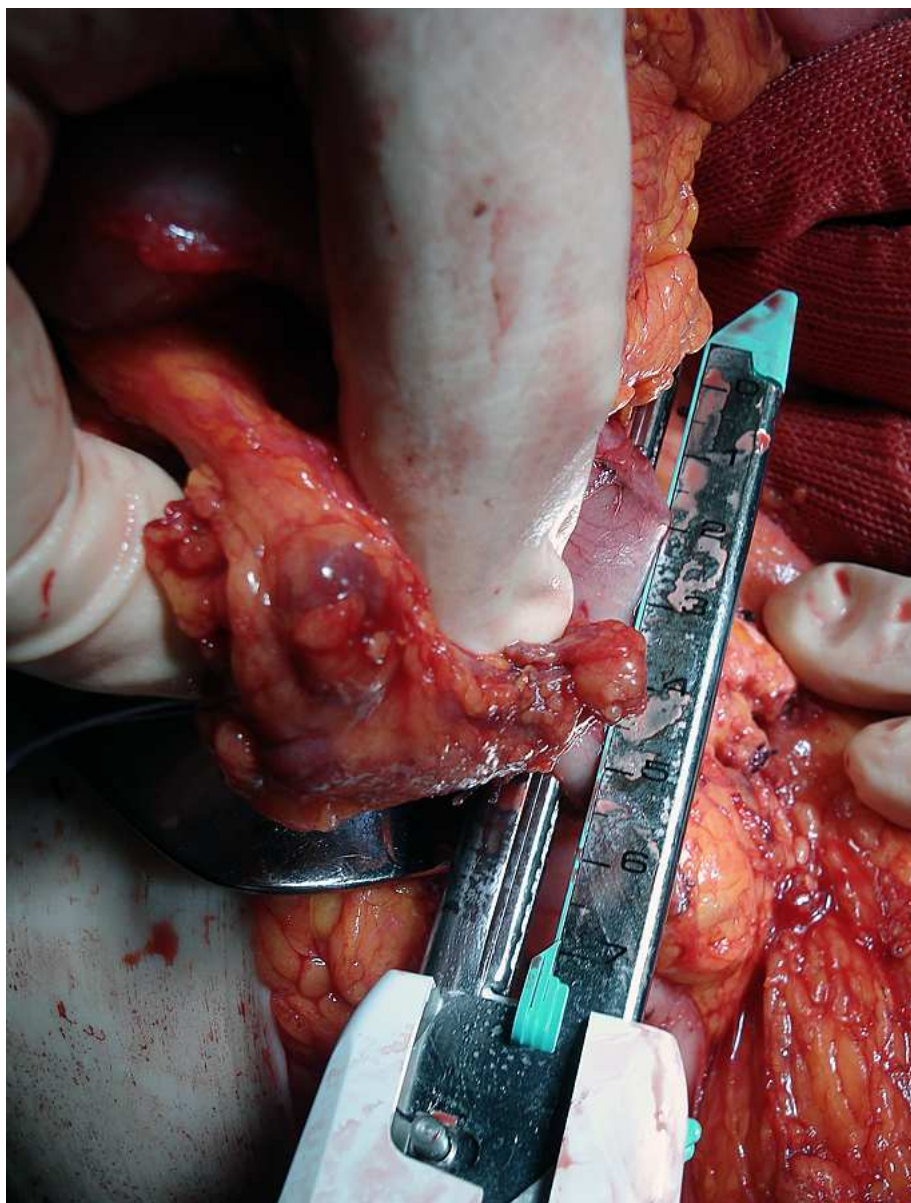


I.R. • Anni: 74 - F • Record: 38 • 07-01-2008

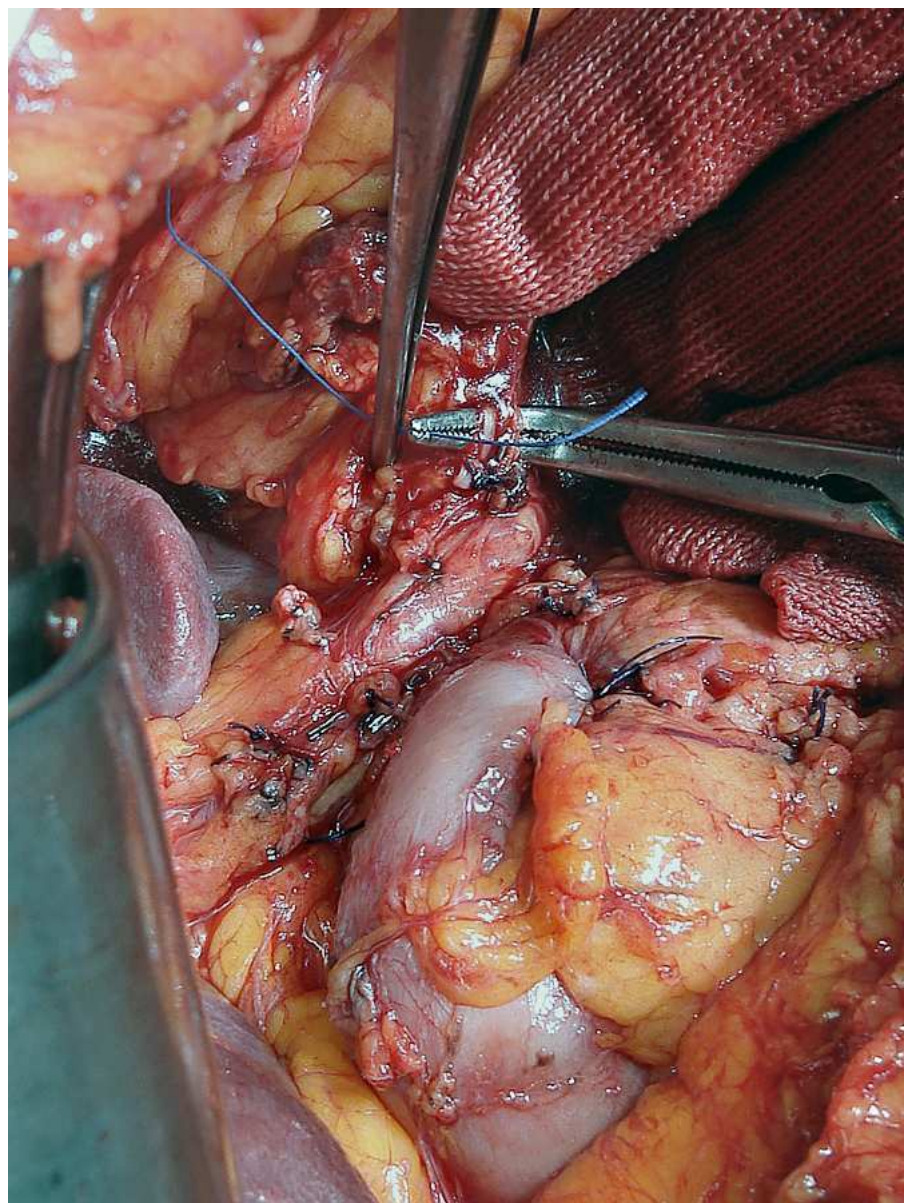
Gastrectomia totale per neoplasia della regione antrale con colecistectomia, epiploectomia e linfoadenectomia N3. Esofago-digiunostomia TL con ansa alla Roux transmesocolica e reservoir sec. Hunt-Lawrence



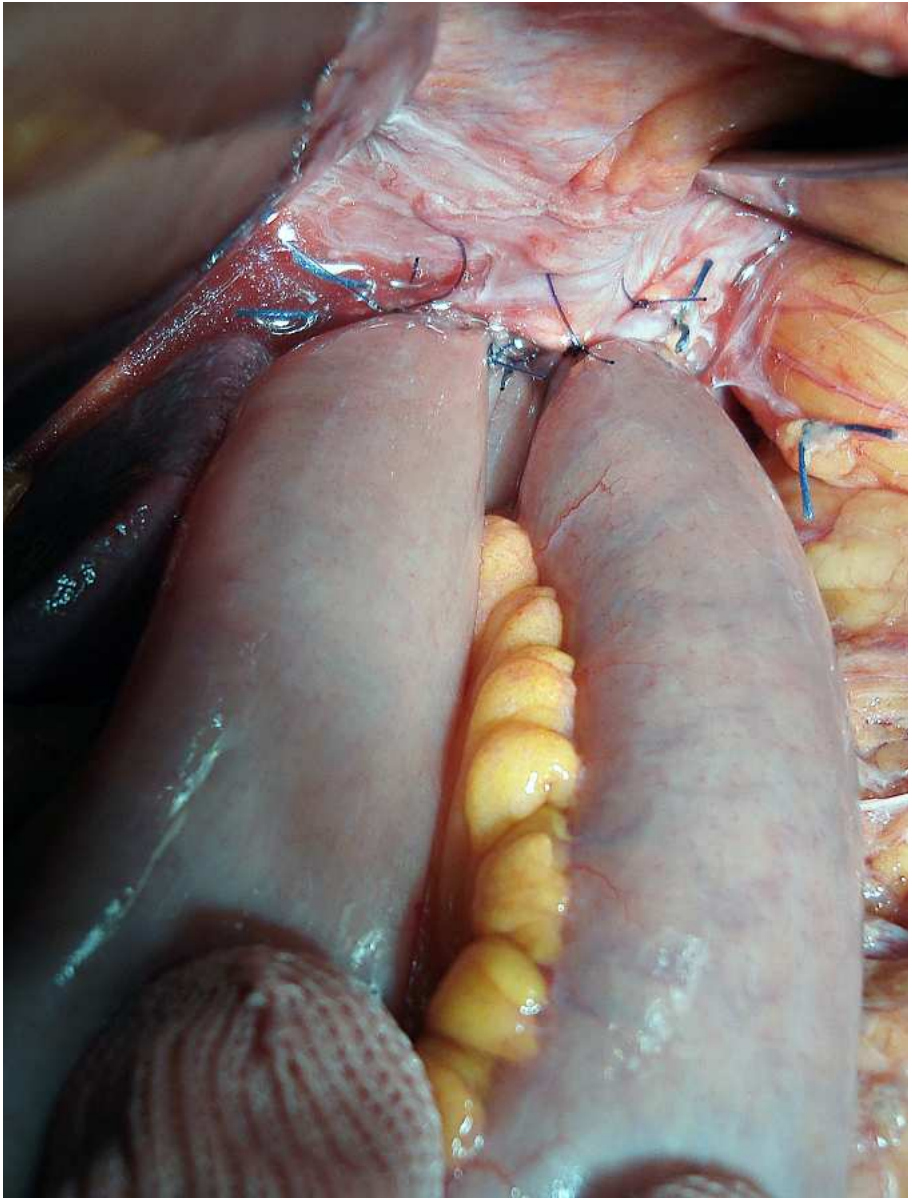Neoplasia della regione antro-pilorica



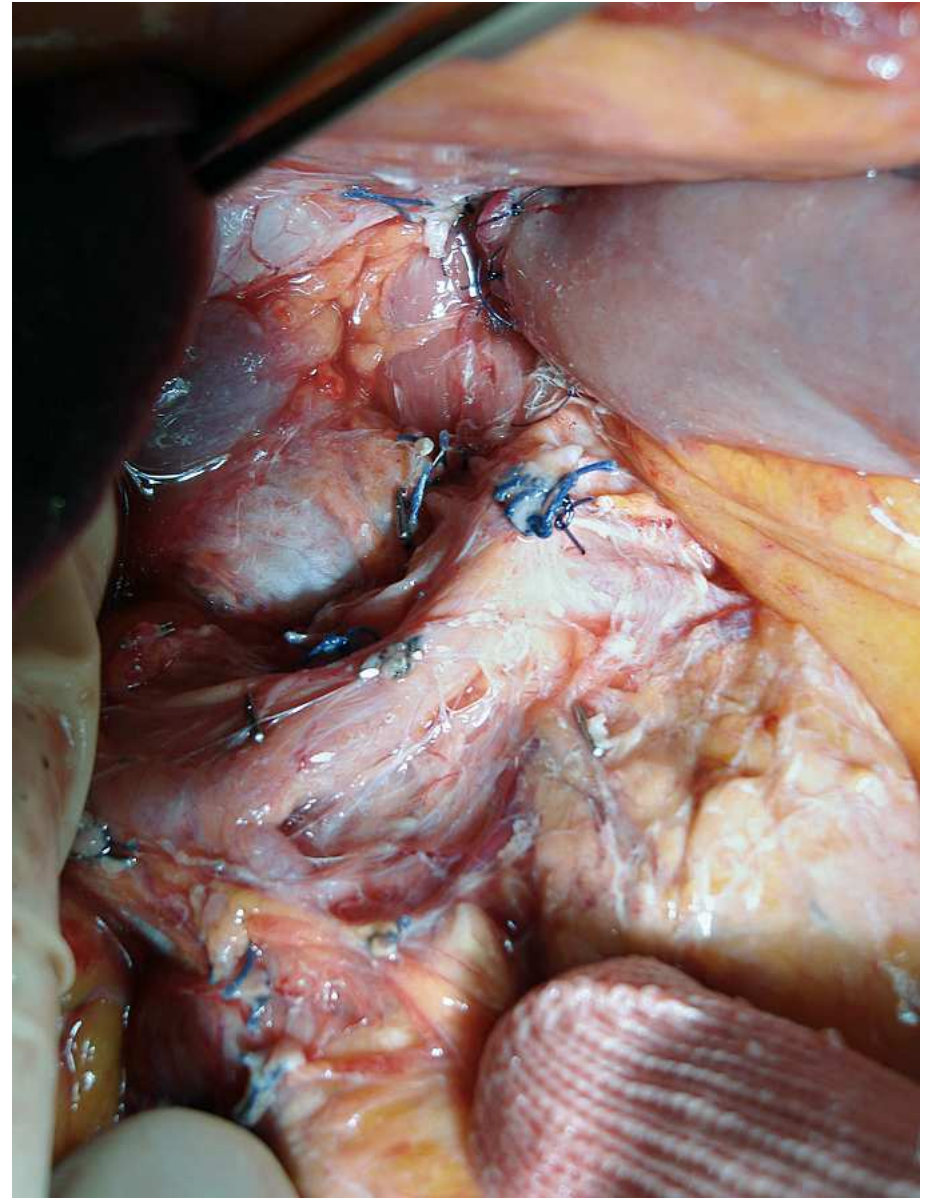
Sezione duodenale. Linfonodi sovrapilorici e del piccolo omento



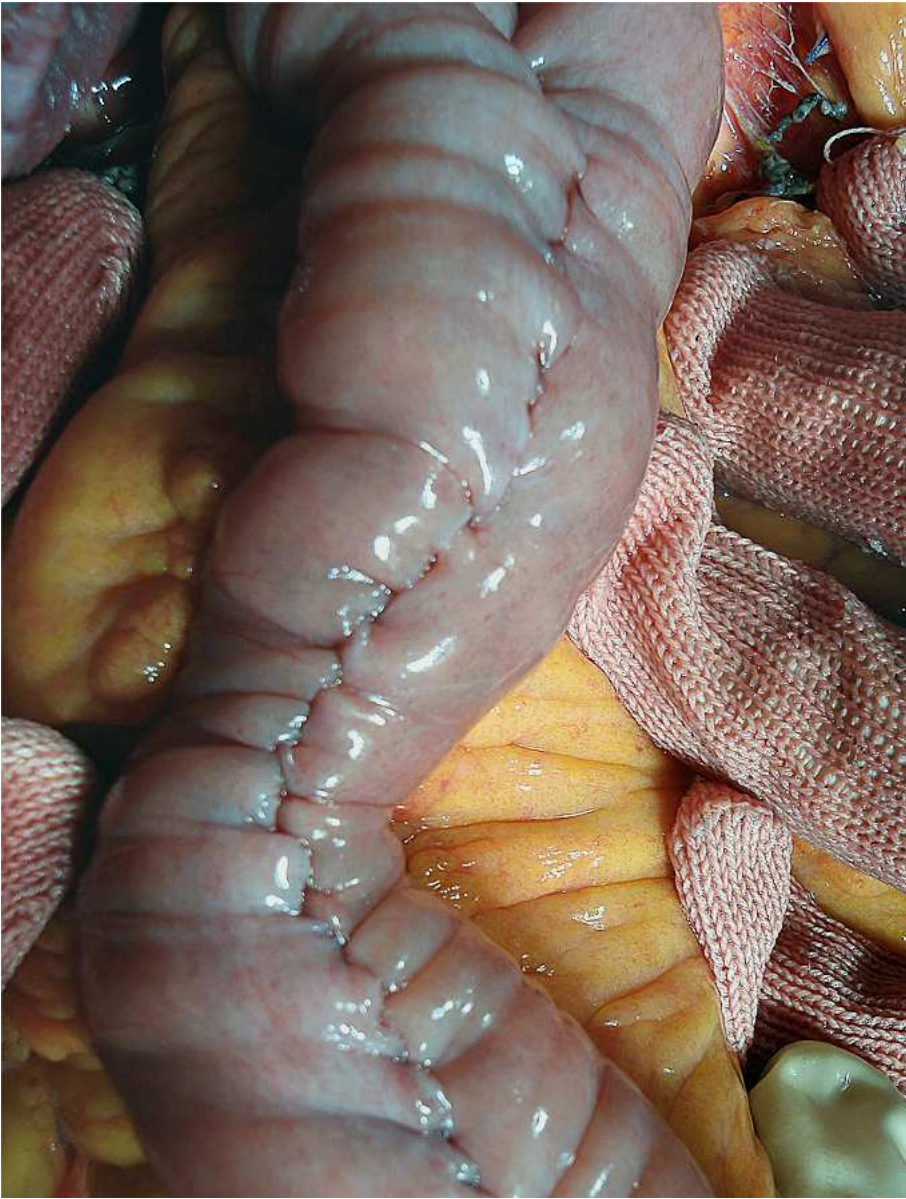Linfoadenectomia del tripode celiaco (arteria epatica, splenica, gastrica sn)



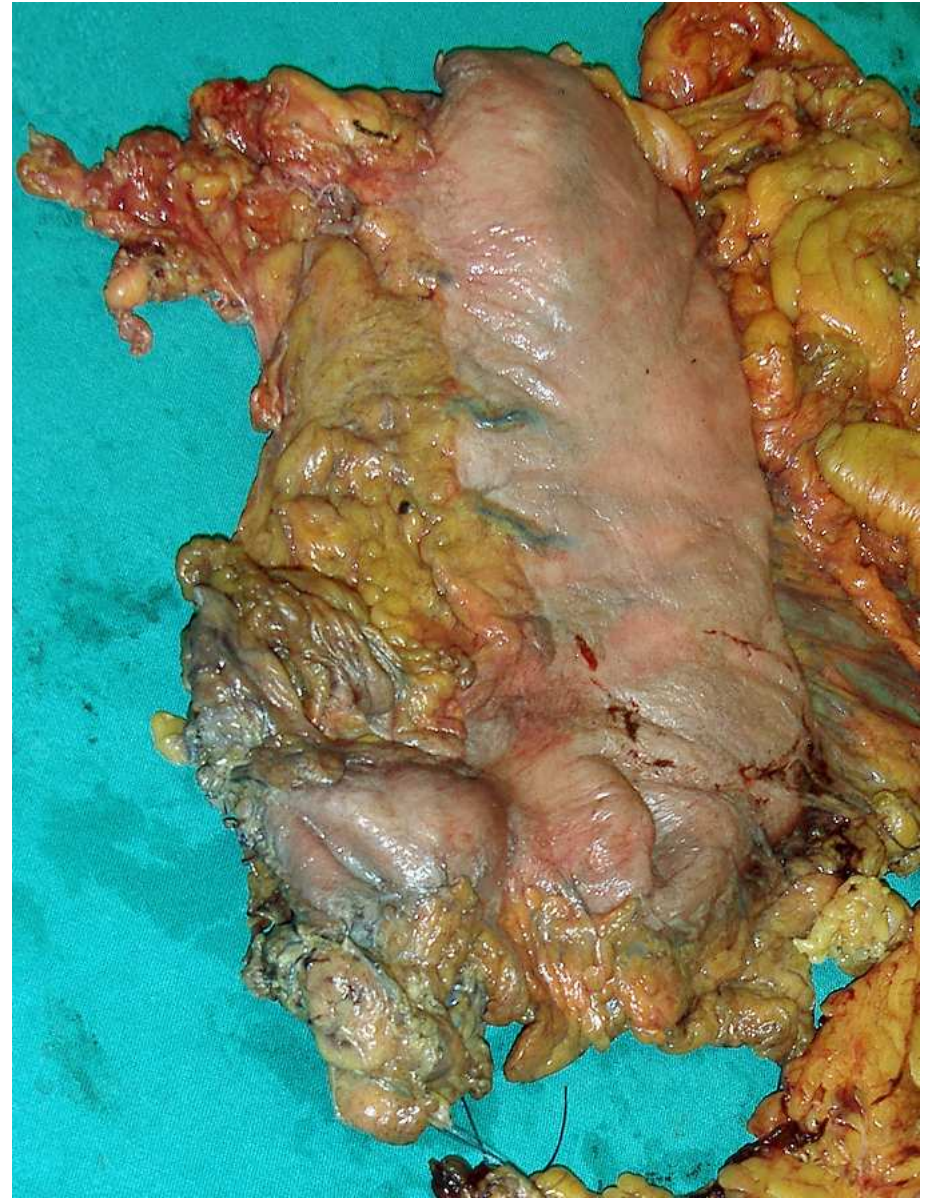Esofago-digiunostomia T.L. transmesocolica con ansa alla Roux



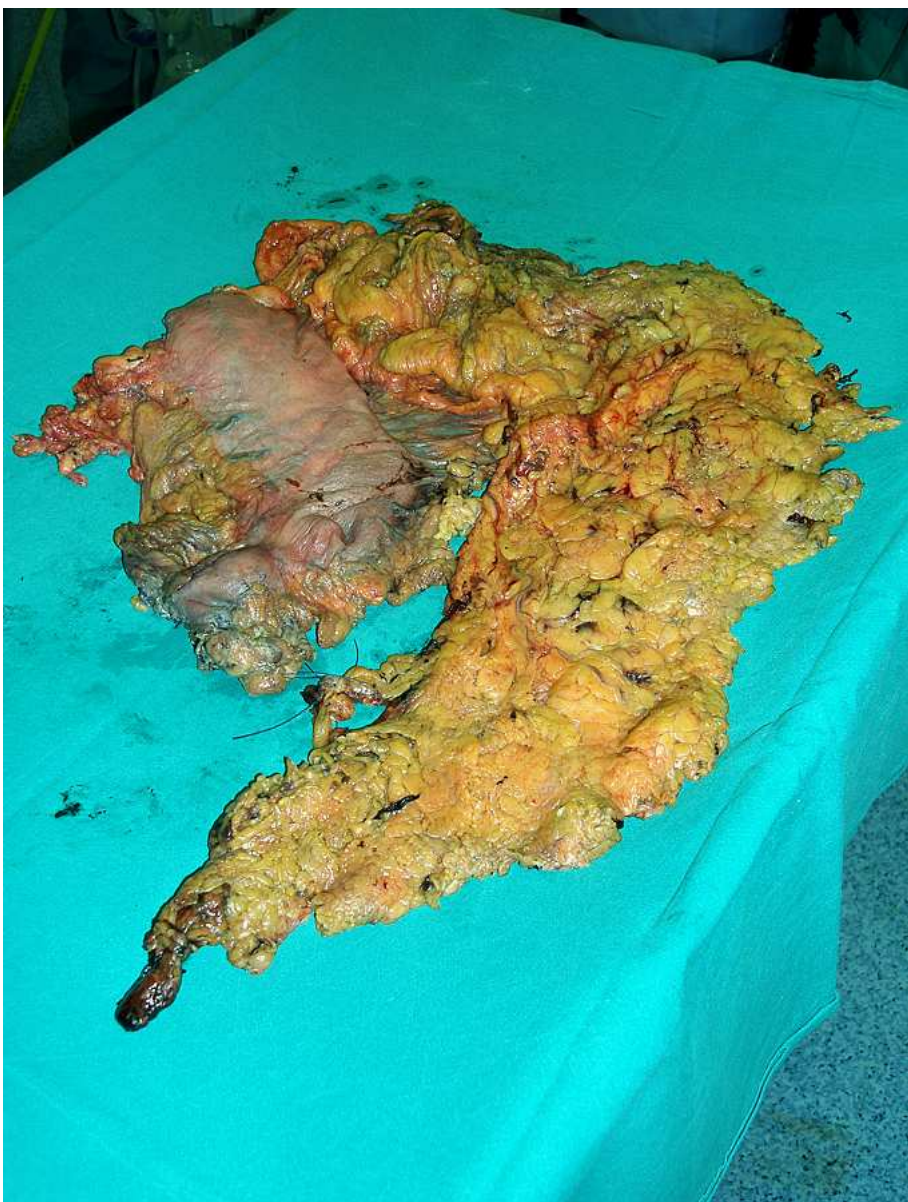Linfoadenectomia dell'arteria epatica e del tripode celiaco



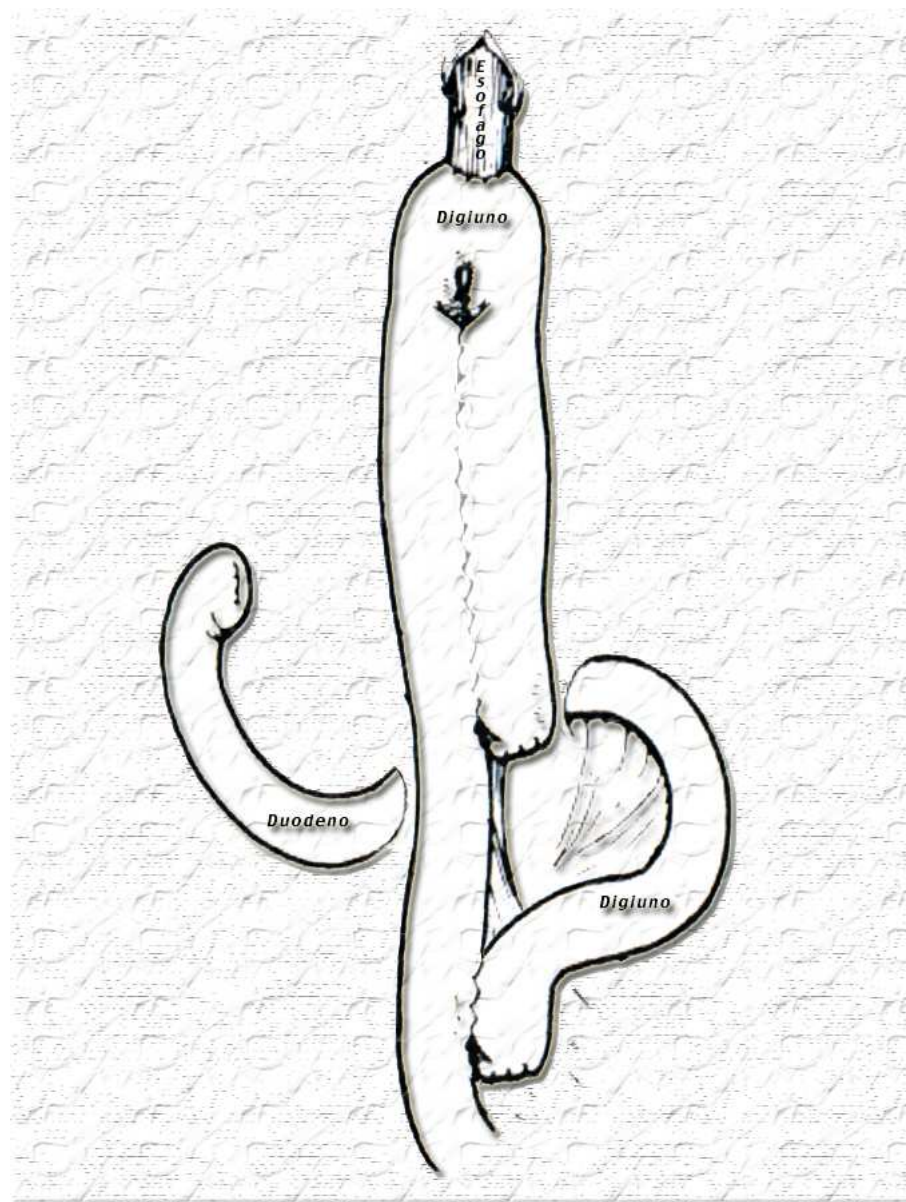
Reservoir (sacca pseudogastrica) sec. Hunt-Lawrence



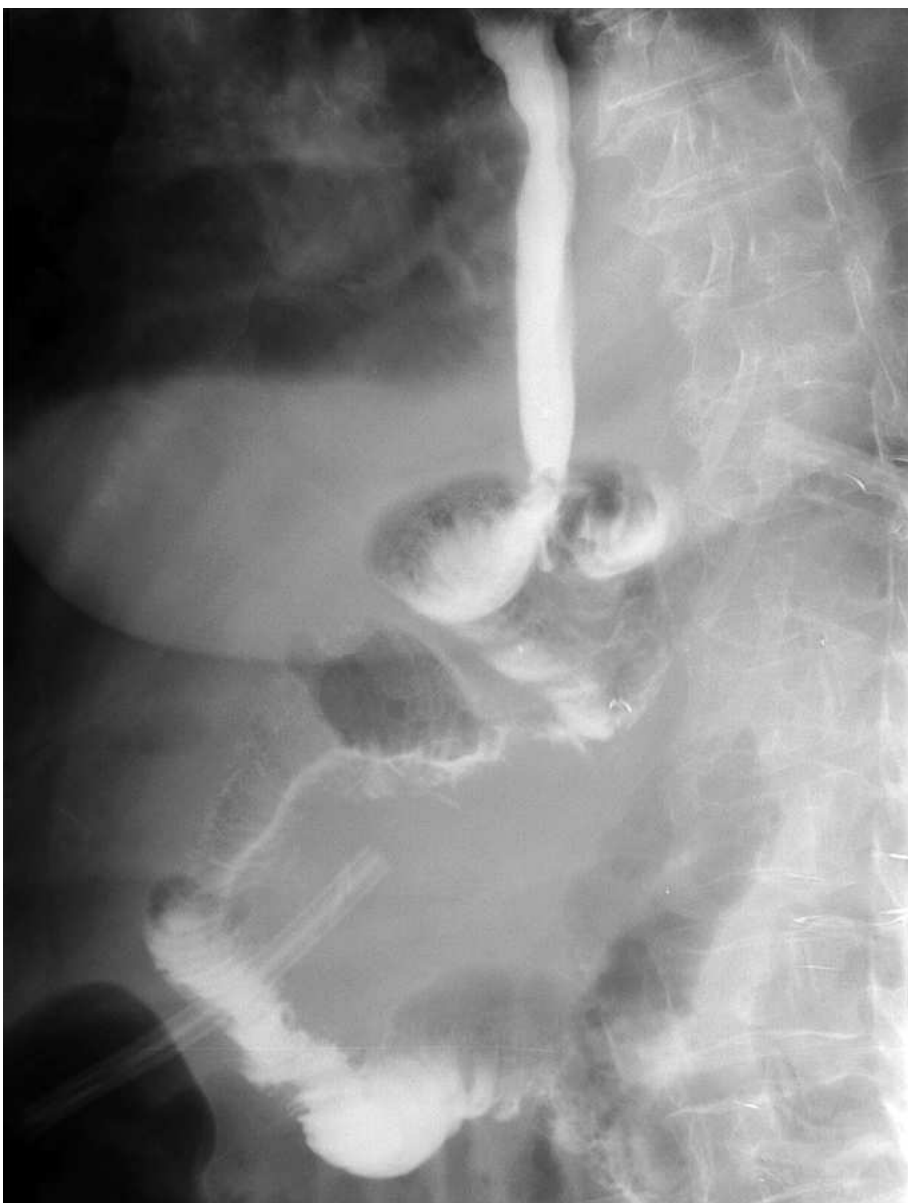Gastrectomia totale allargata per neoplasia della regione antro-pilorica



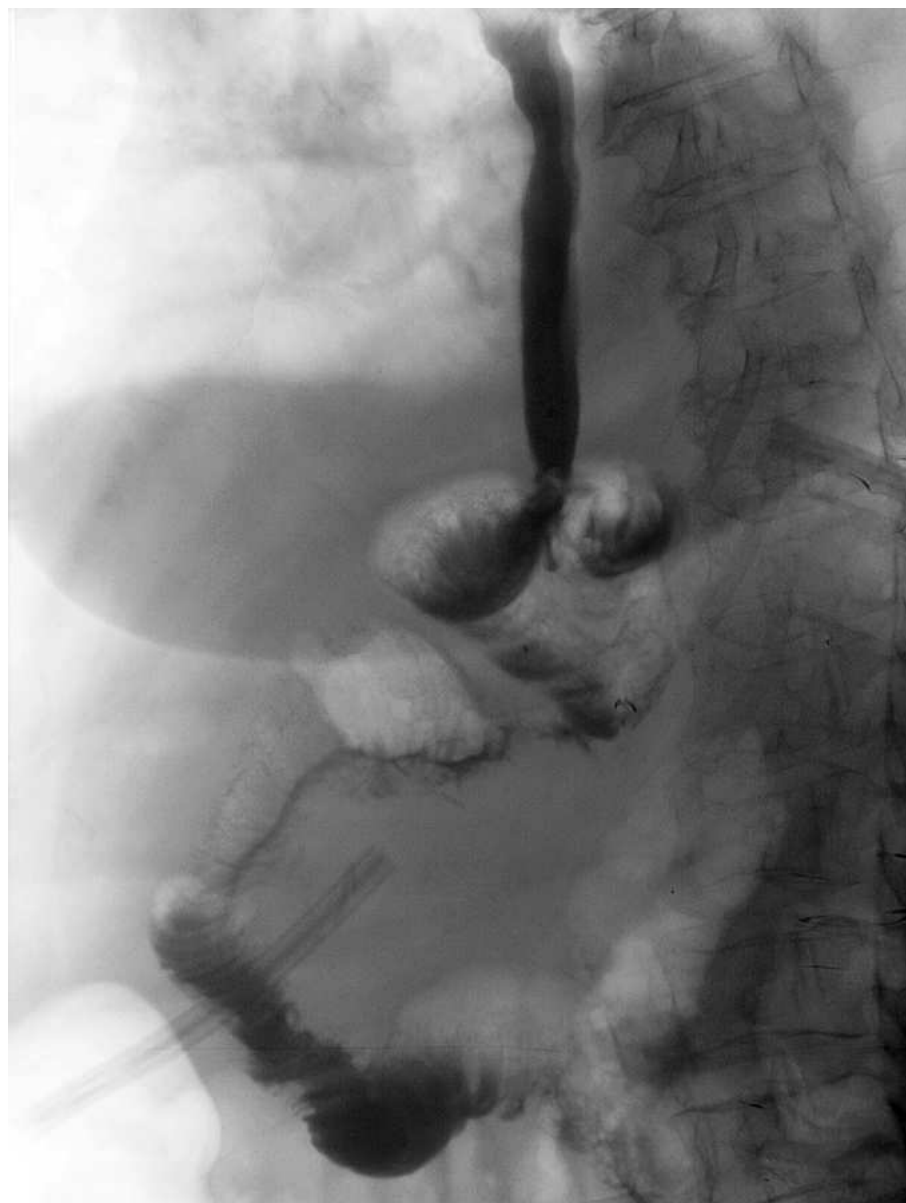Gastrectomia totale con colecistectomia, epiploiectomia e linfadenectomia di I-II e III livello



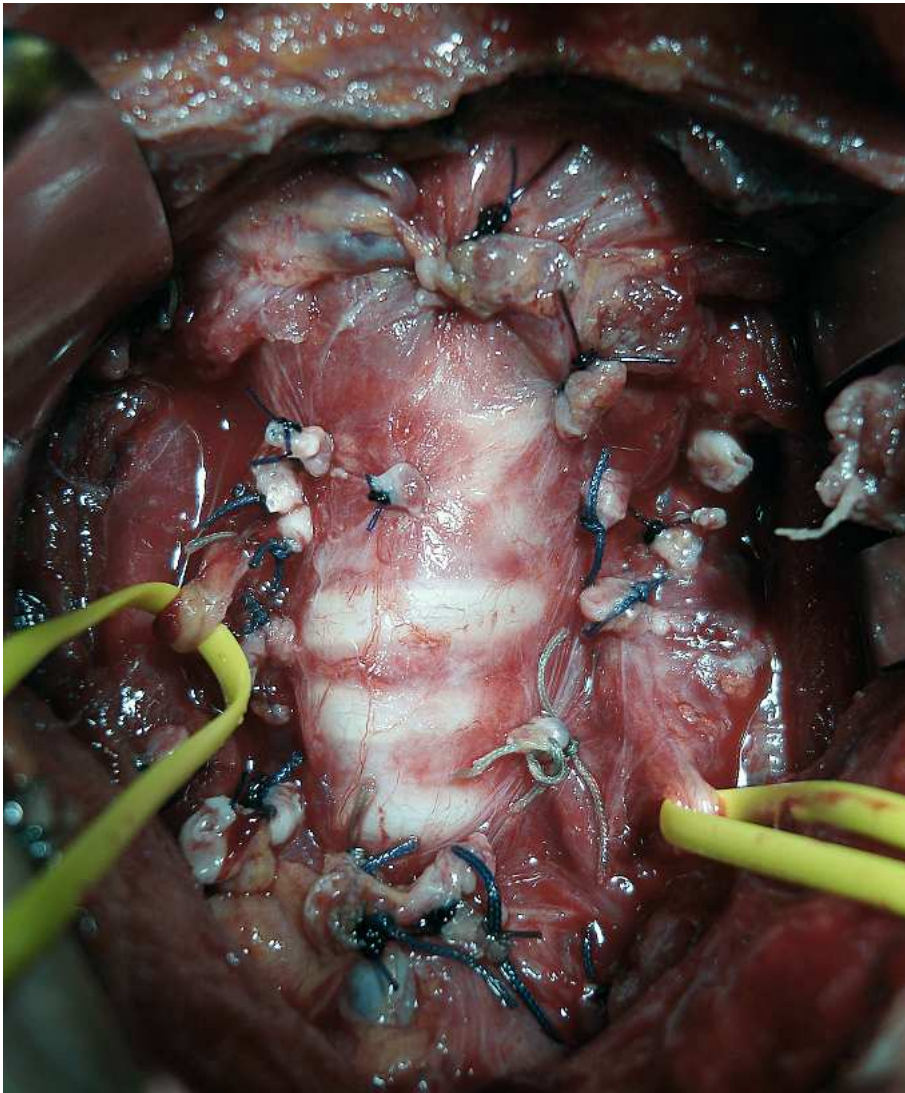
Esofago-digiunostomia con ansa alla Roux transmesocolica e reservoir sec. Hunt-Lawrence



Controllo radiologico post-operatorio (X giornata)

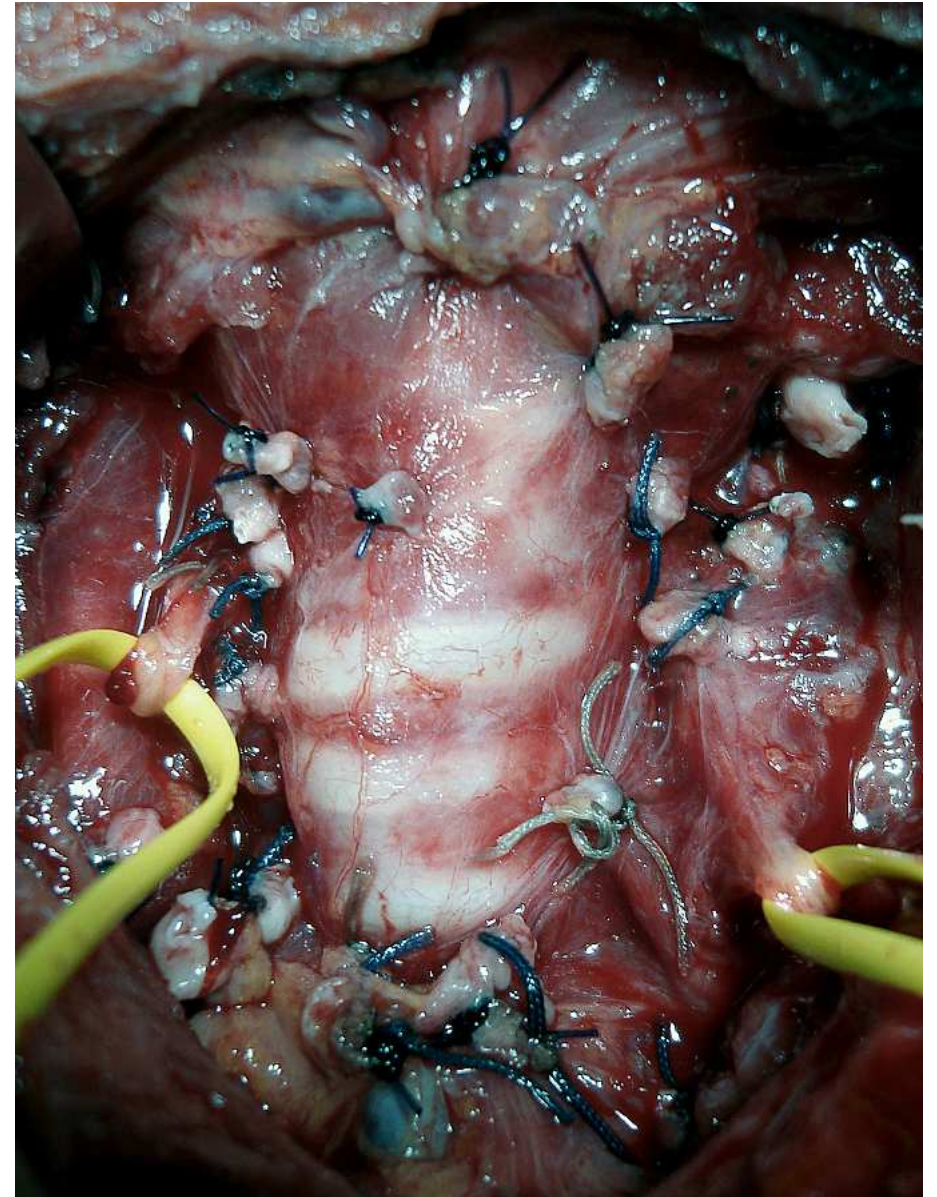


Controllo radiologico post-operatorio (X giornata)

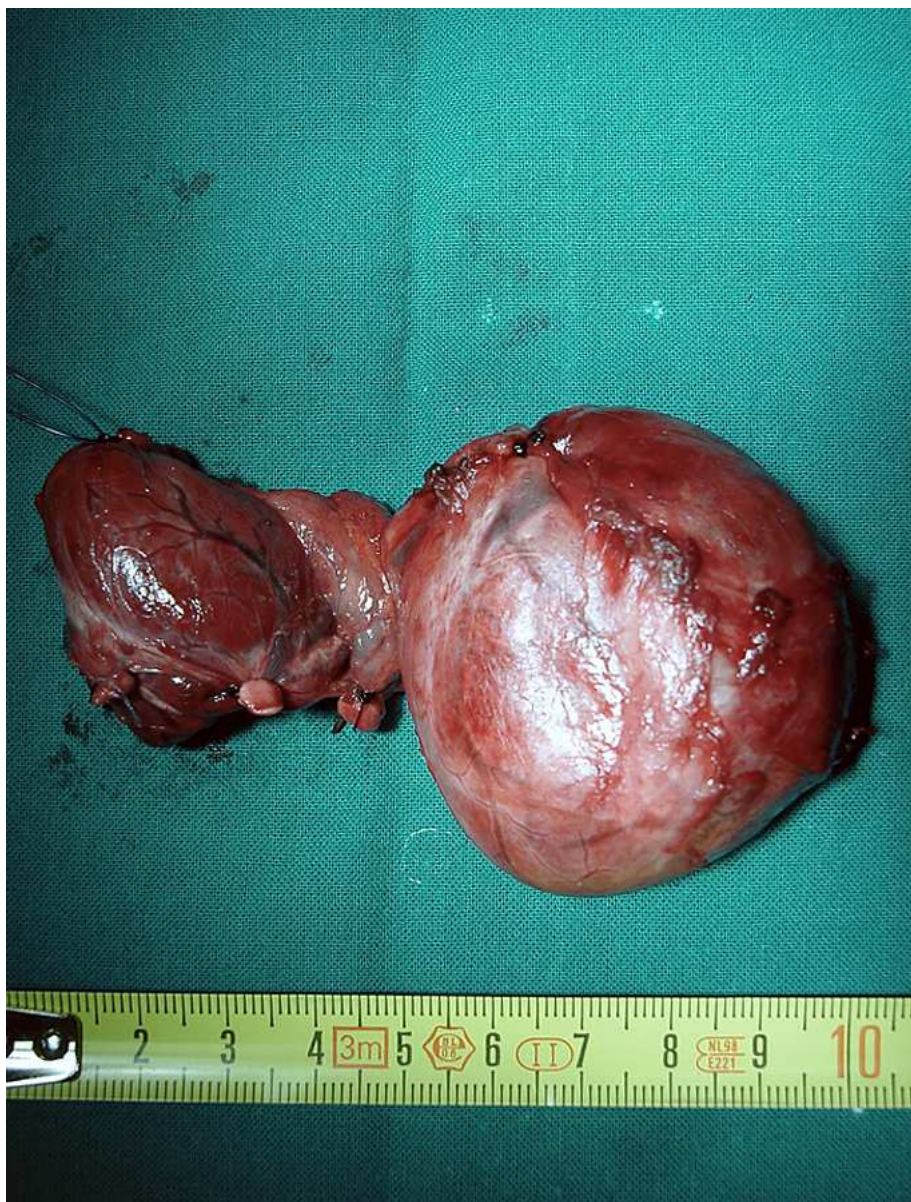

A.G. • Anni: 72 - F • Record: 39 • 17-01-2008

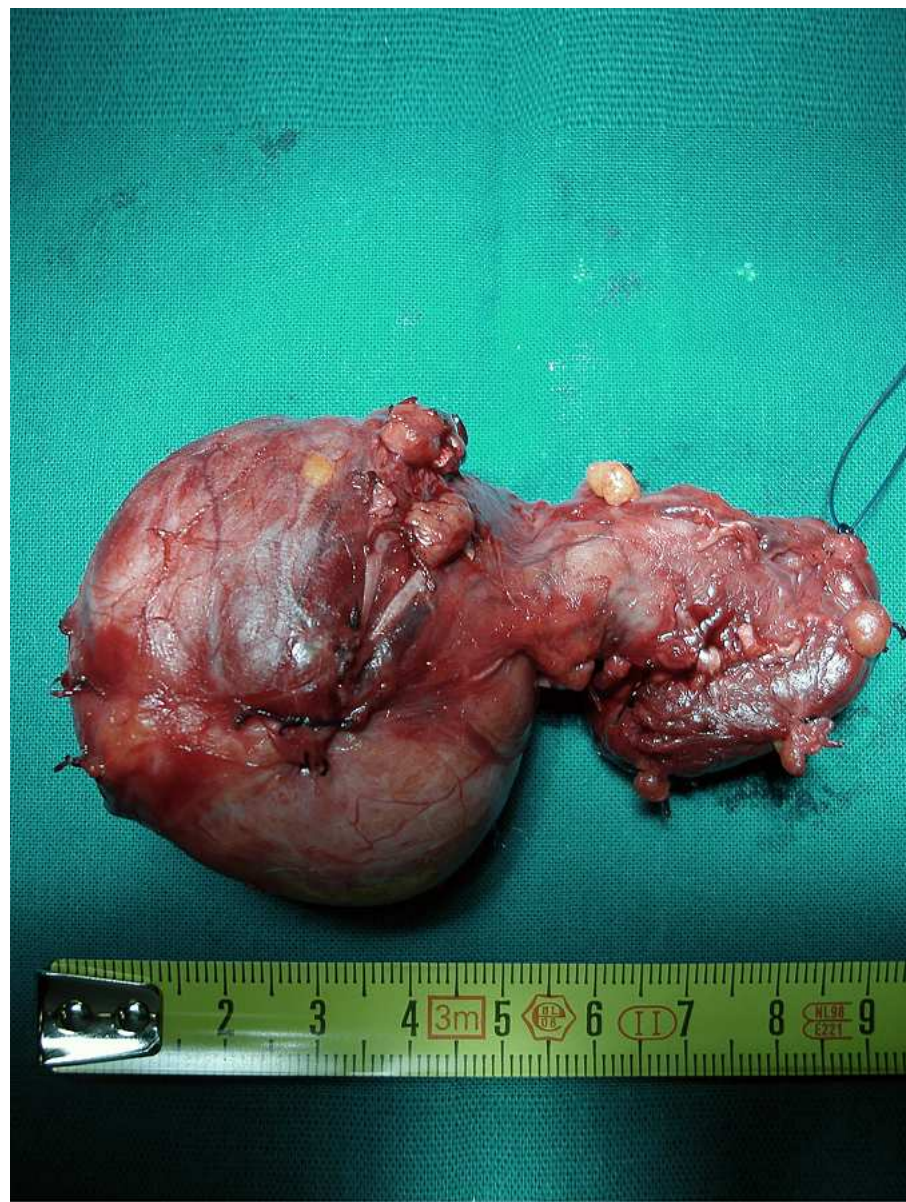
Tiroidectomia totale extracapsulare per gozzo plurinodulare plongeant a sn



Isolamento dei nervi laringei inferiori (ricorrenti)

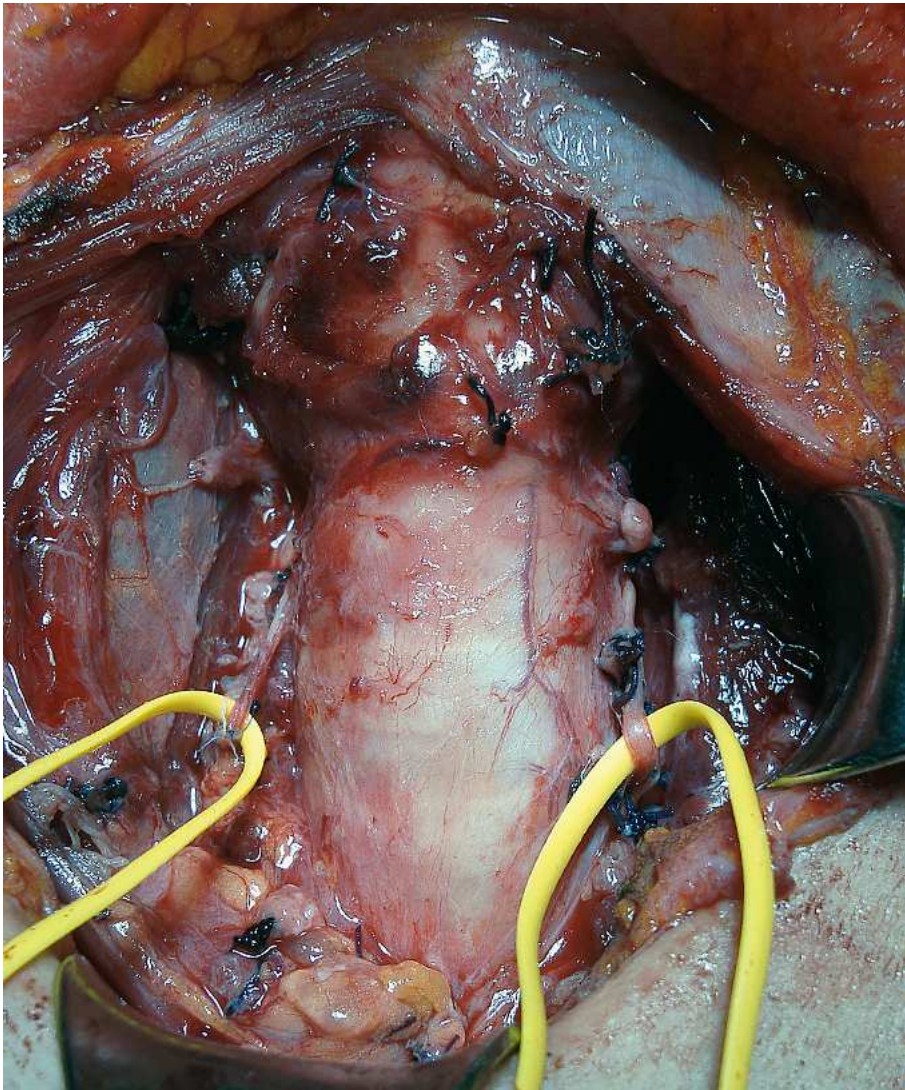


Lobo destro - Istmo - Lobo sinistro (superficie anteriore)



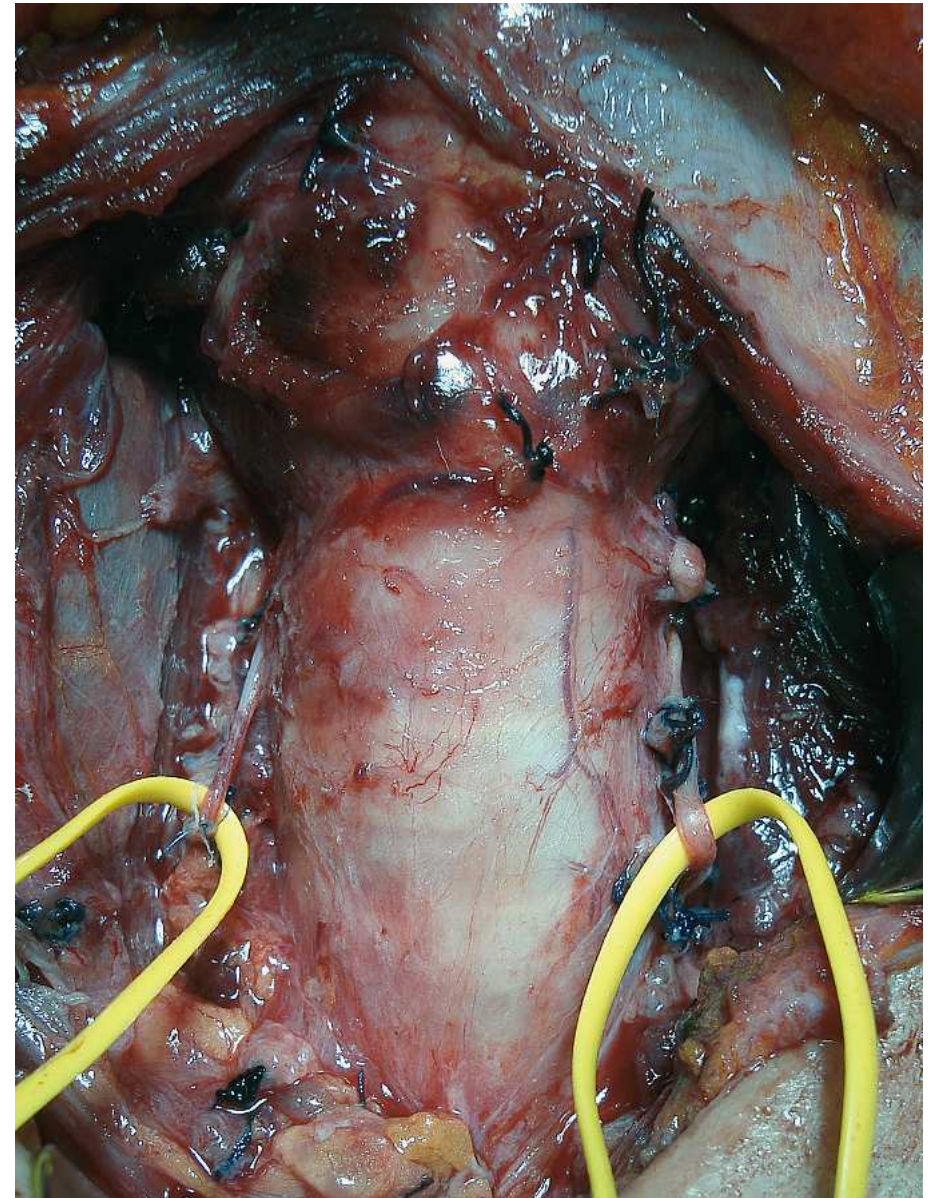
Lobo sinistro - Istmo - Lobo destro (superficie posteriore)



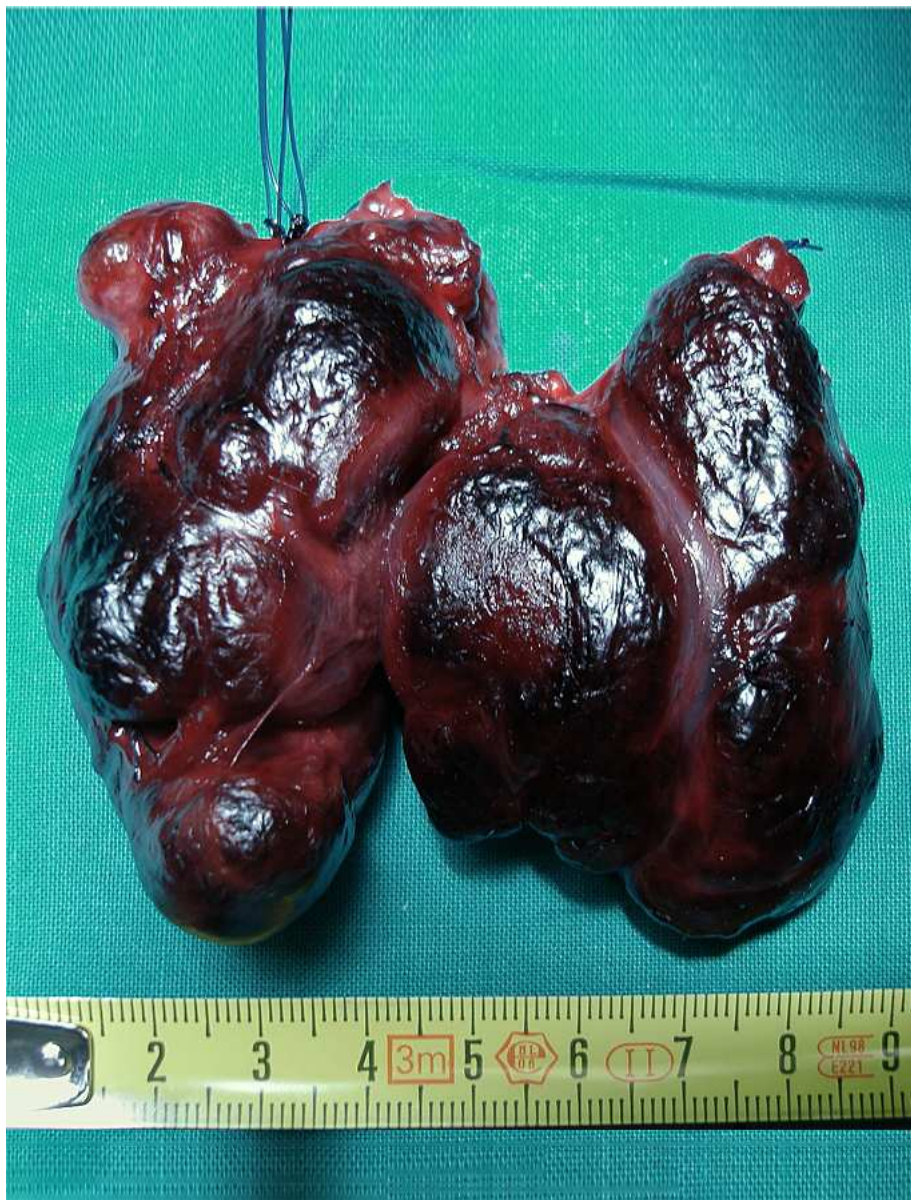


E.E. • Anni: 61 - F • Record: 40 • 27-03-2008

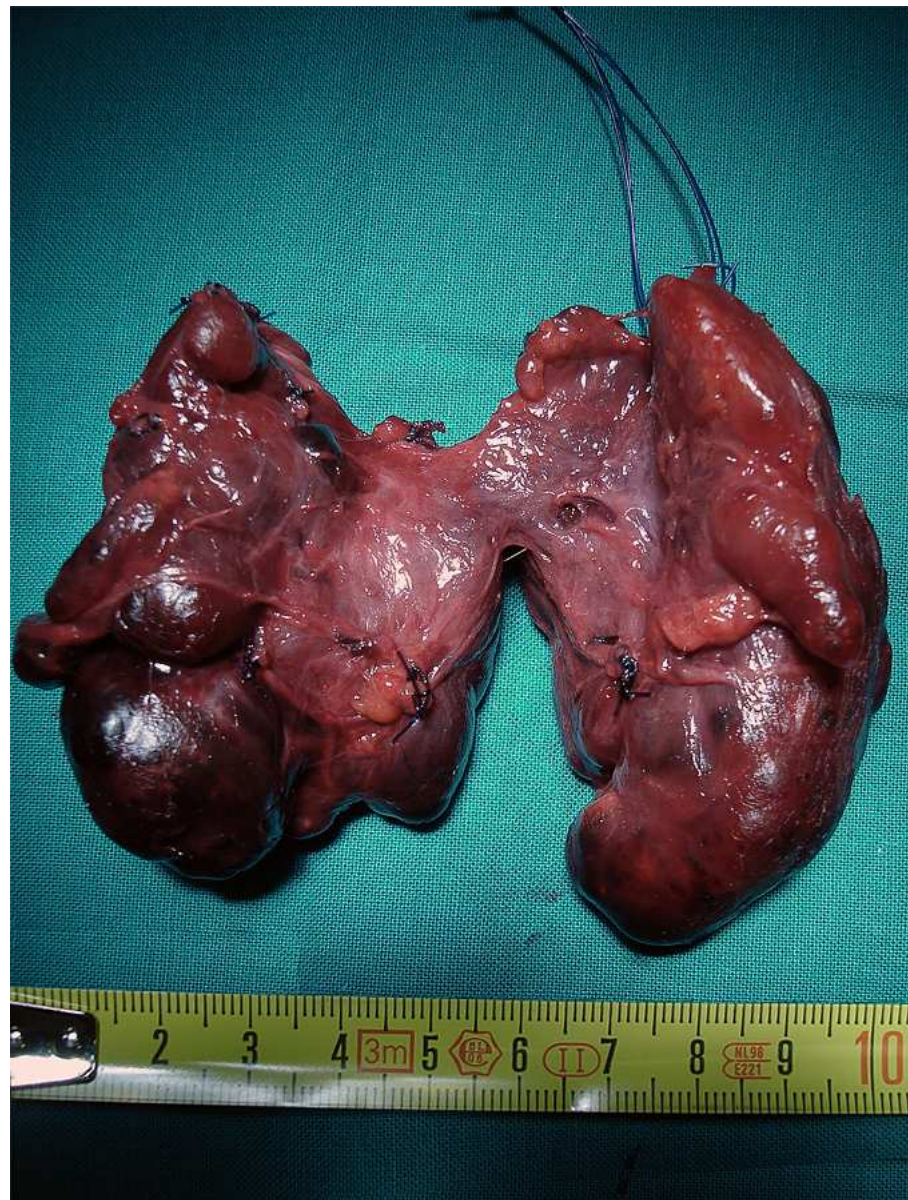
Tiroidectomia totale extracapsulare per gozzo plurinodulare plongeant



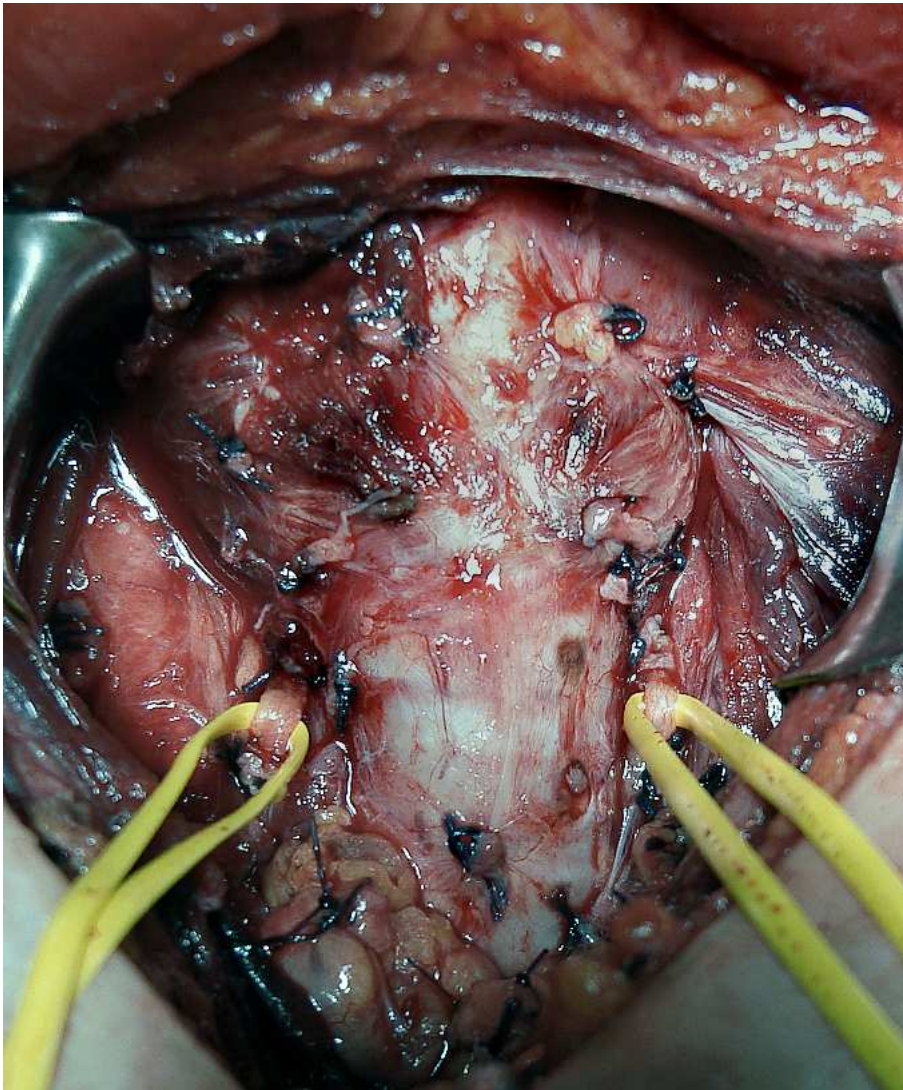
Isolamento dei nervi laringei inferiori (ricorrenti)



Lobo destro - Istmo - Lobo sinistro (superficie anteriore)

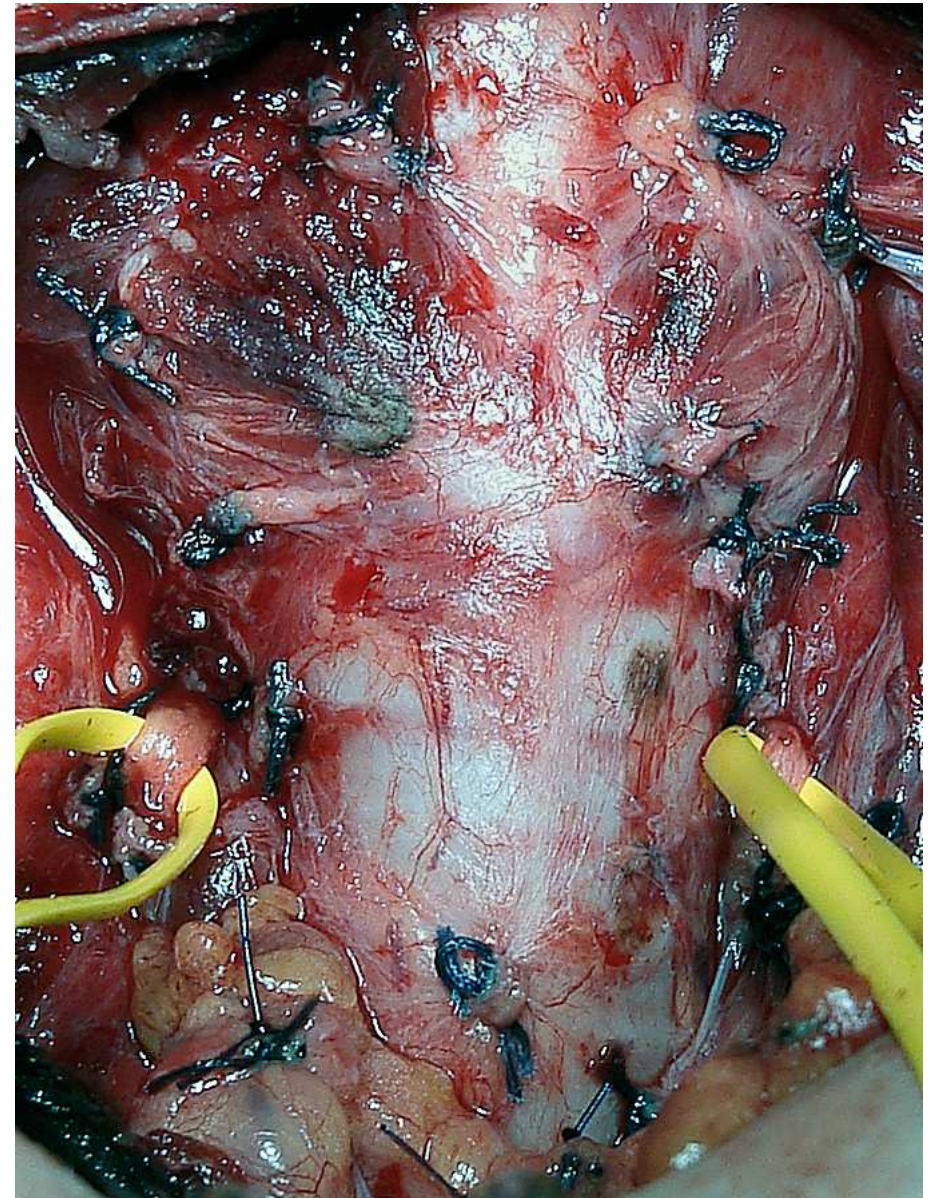


Lobo sinistro - Istmo - Lobo destro (superficie posteriore)

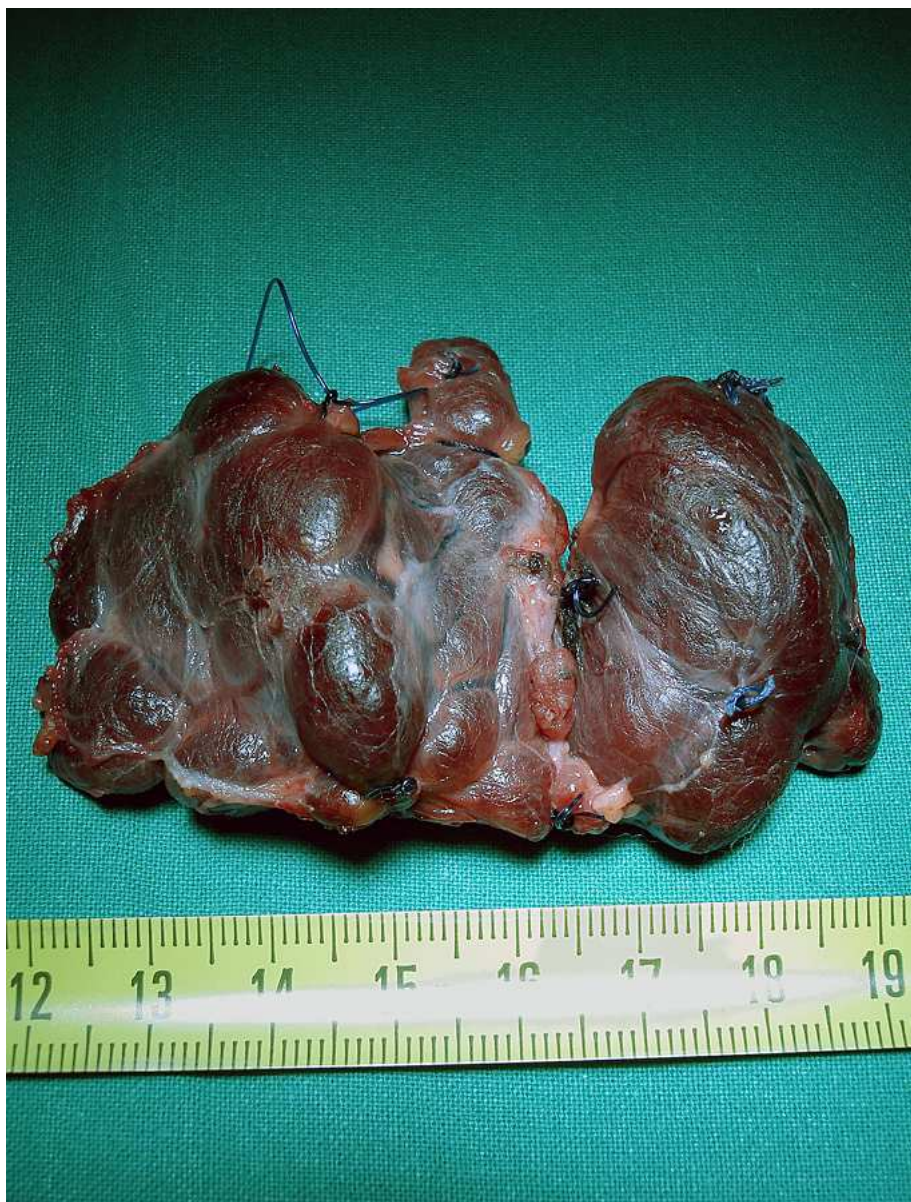

P.M. • Anni: 34 - F • Record: 41 • 17-04-2008

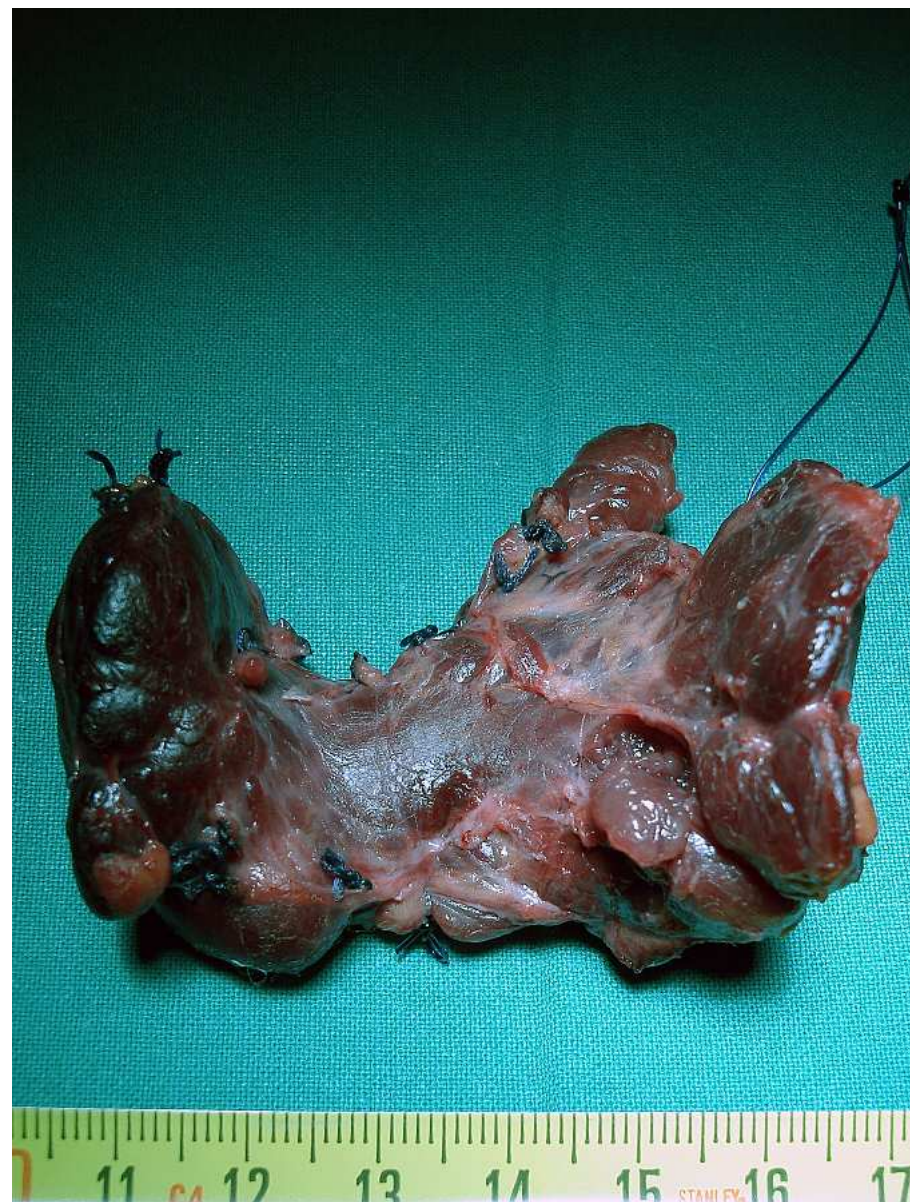
Tiroidectomia totale extracapsulare per carcinoma misto (papillare e follicolare) multifocale della tiroide in gozzo plurinodulare tossico.



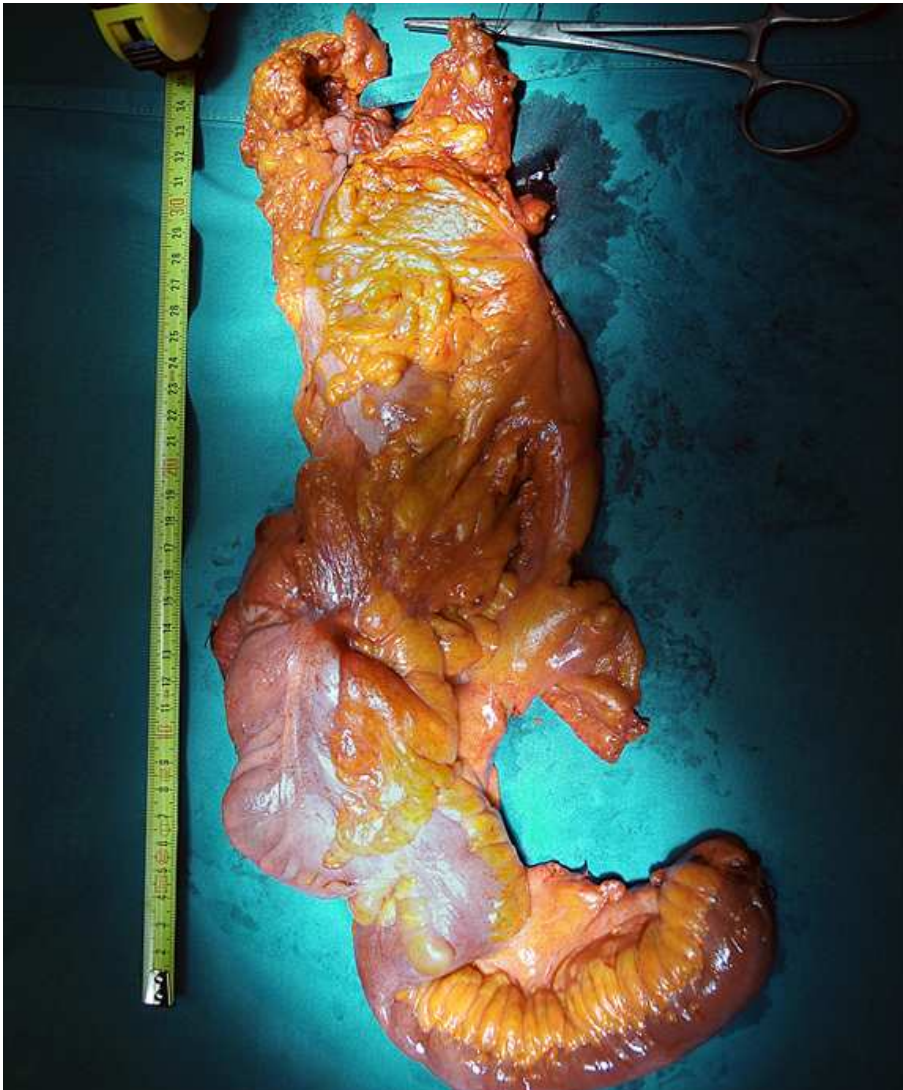
Isolamento dei nervi laringei inferiori (ricorrenti)



Lobo destro - Istmio - Lobo sinistro (superficie anteriore)

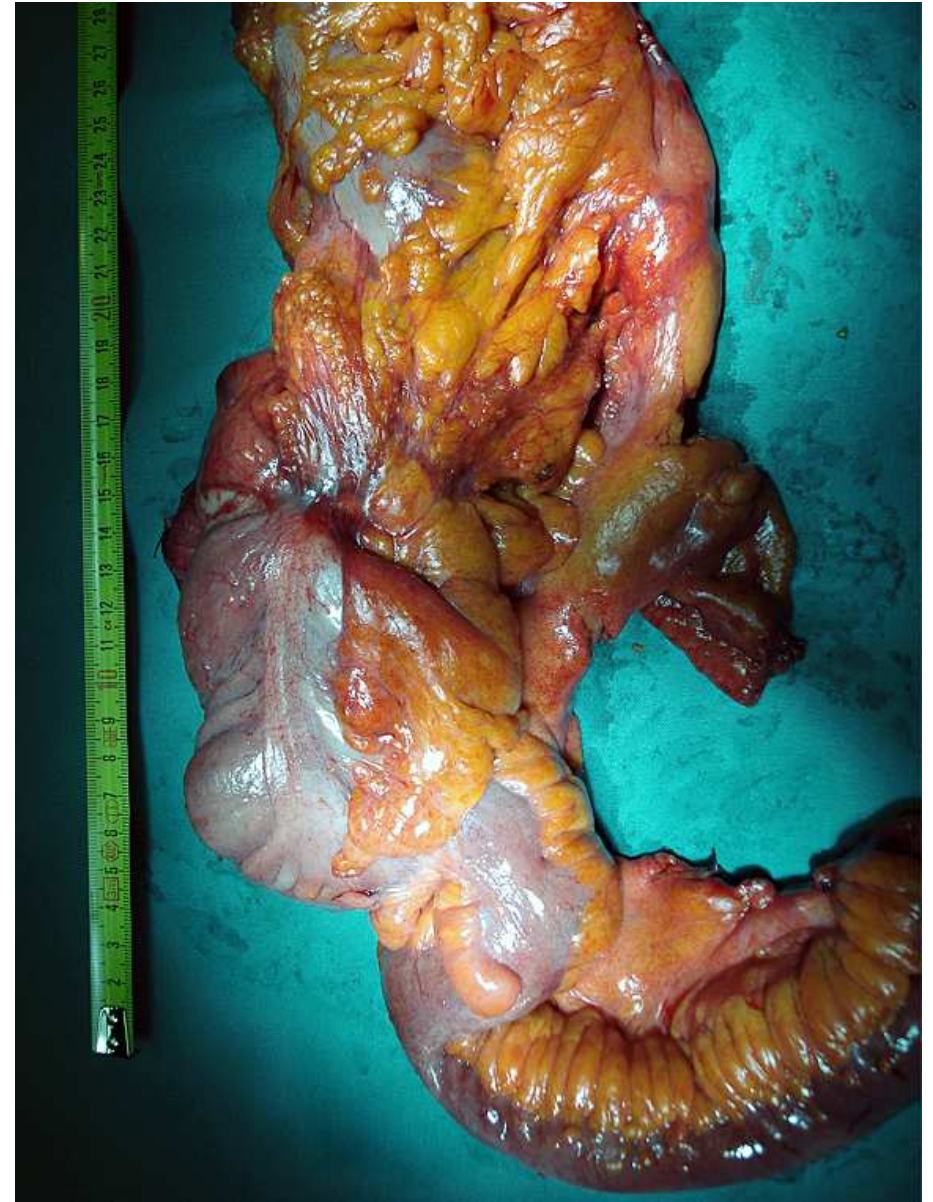

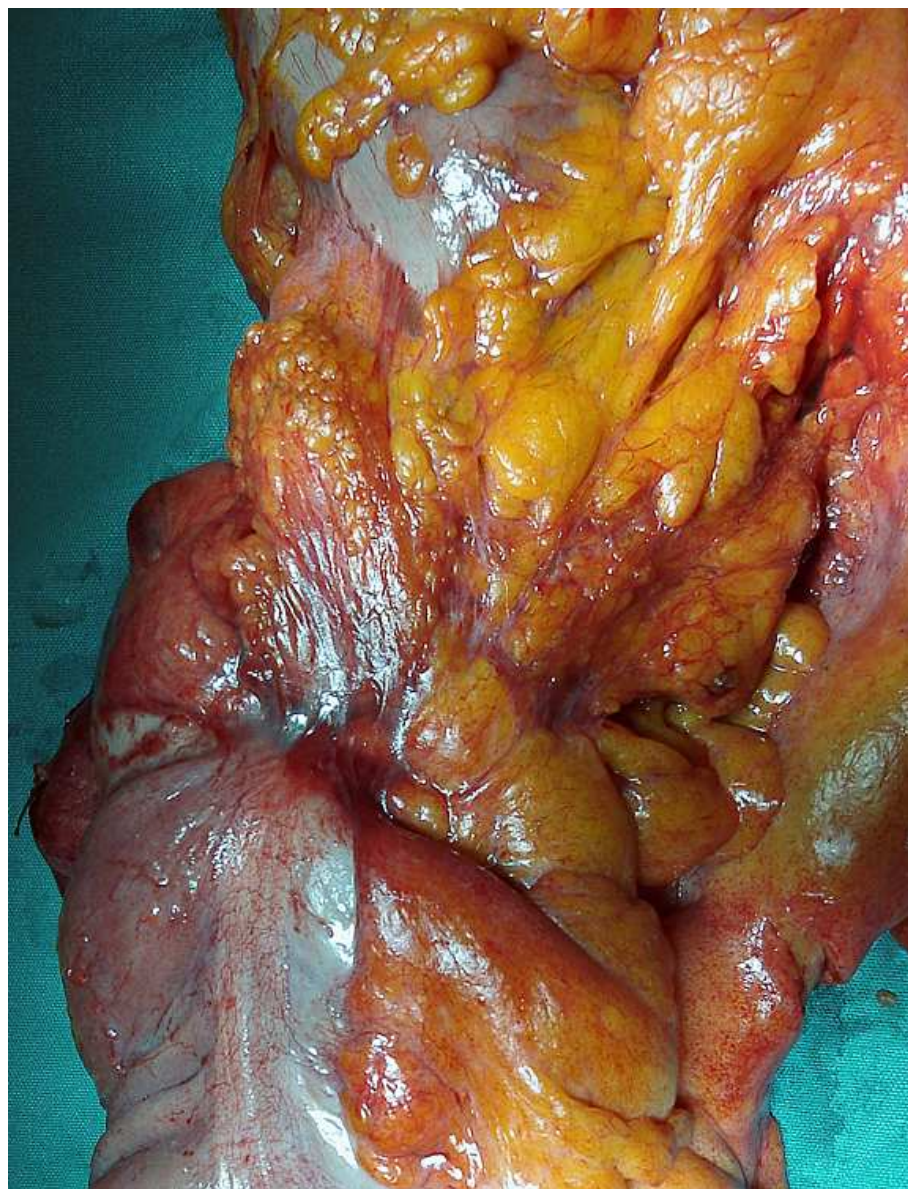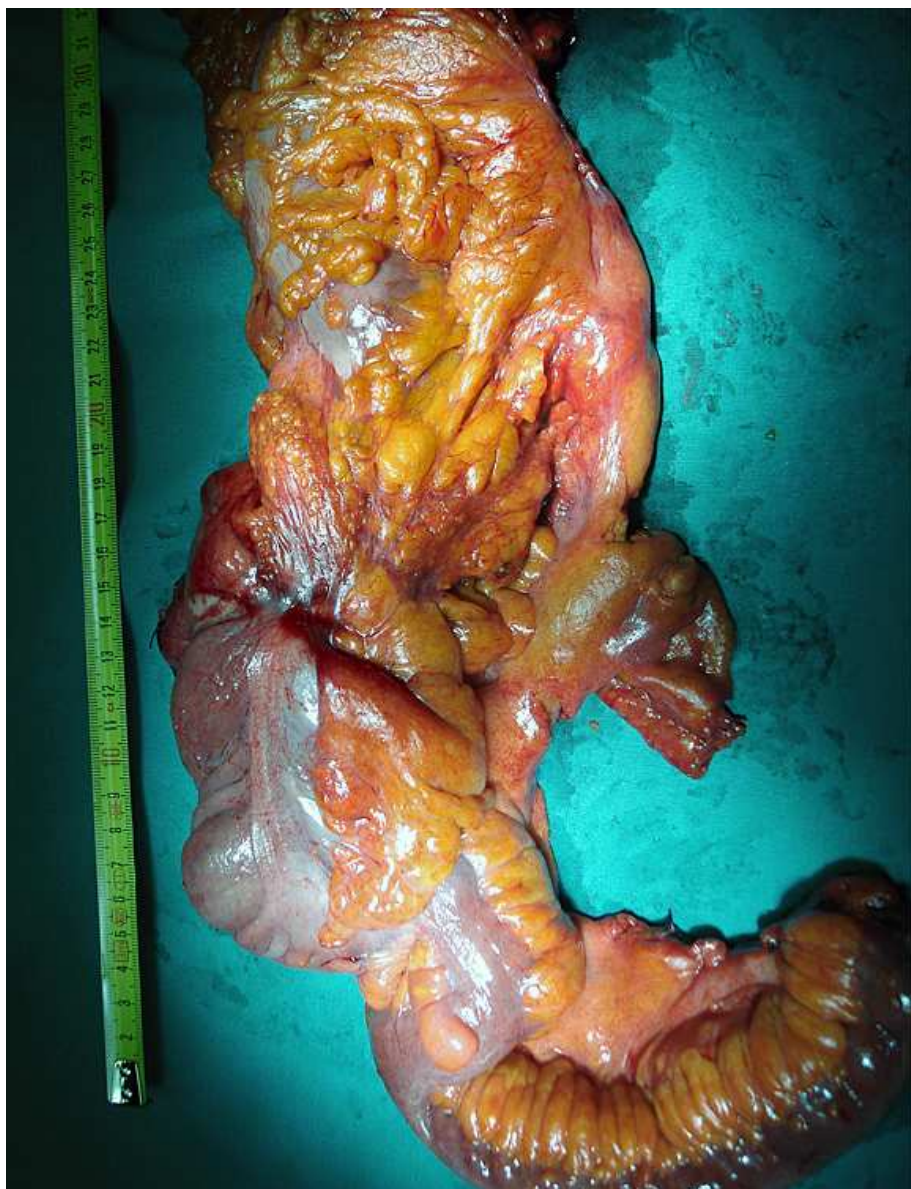
Lobo sinistro - Istmio - Lobo destro (superficie posteriore)

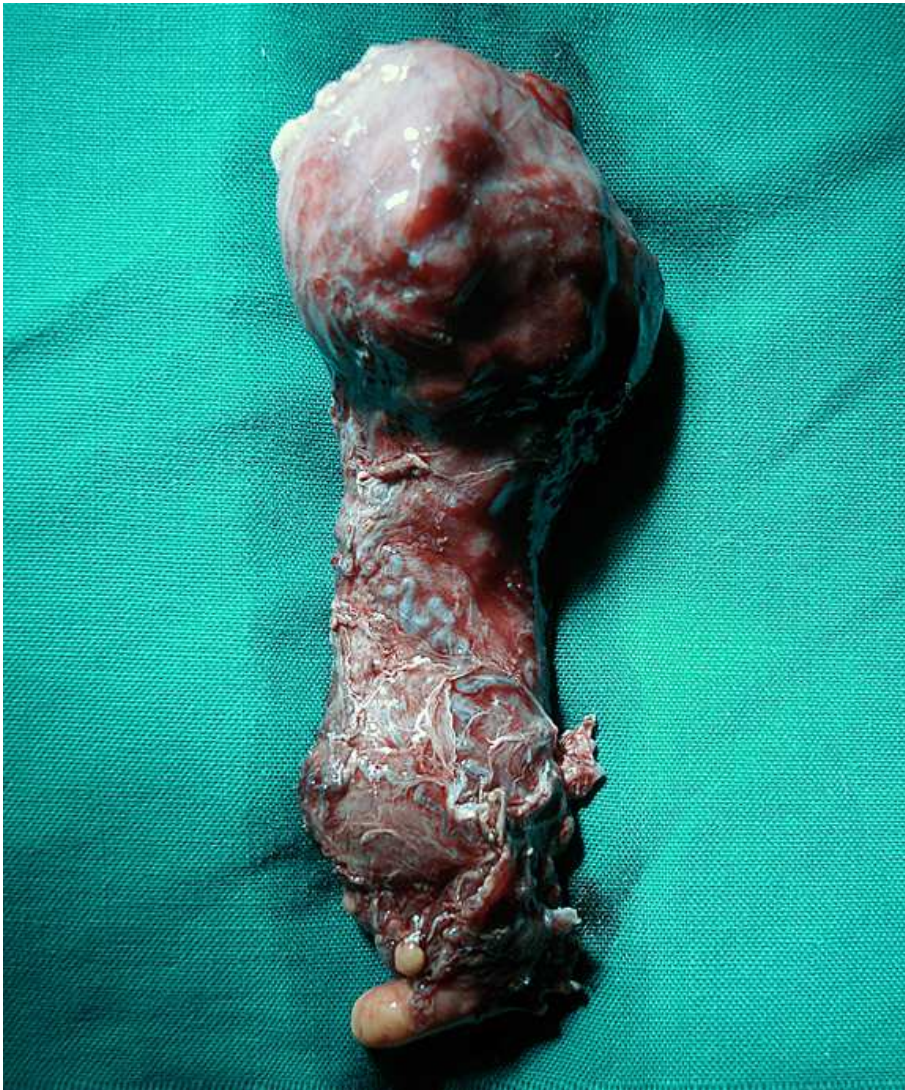

V.A. • Anni: 79 - F • Record: 42 • 05-07-2008

Emicolectomia dx con linfadenectomia perimesenterica superiore e laparalloplastica sec. Rives per adenocarcinoma sanguinante della flessura epatica del colon, ernia ombelicale e diastasi dei muscoli retti

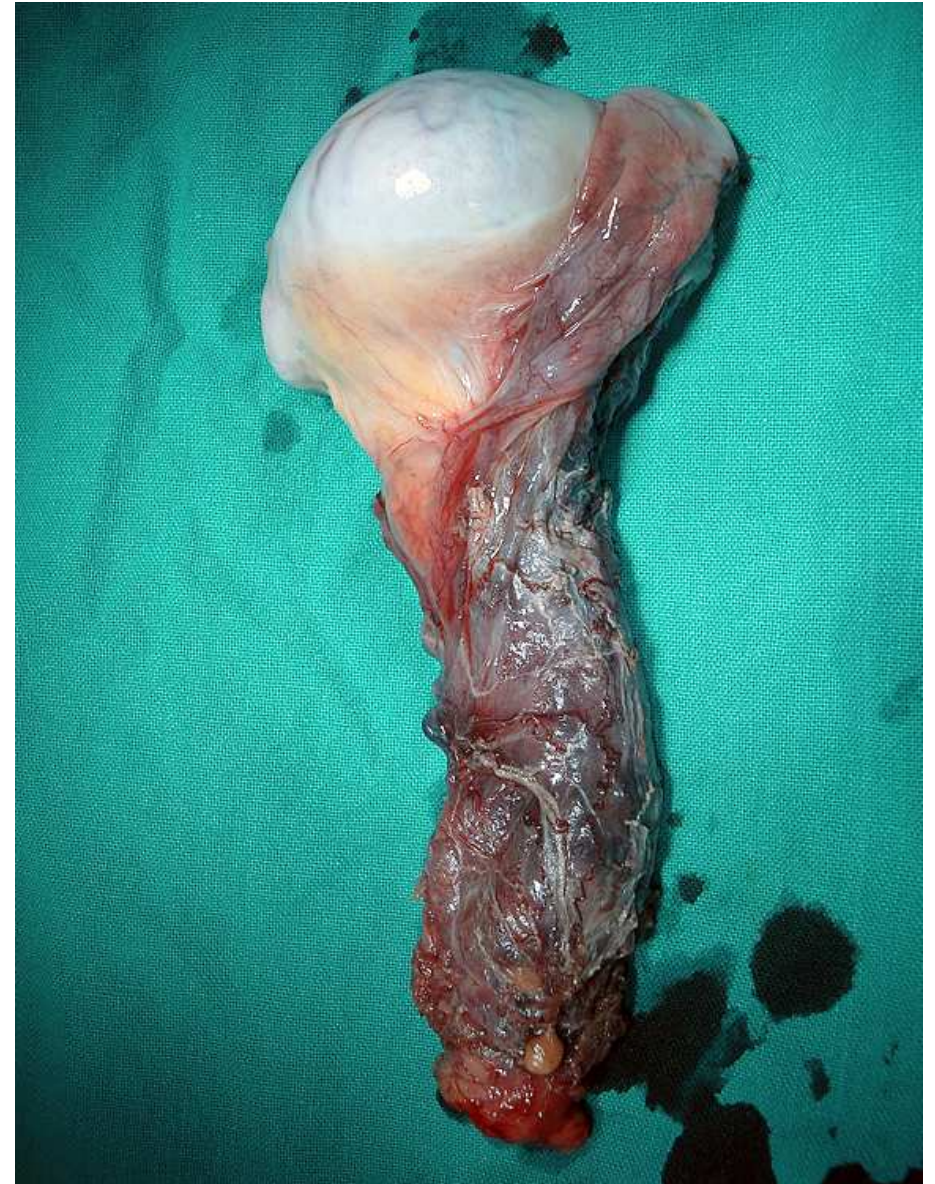

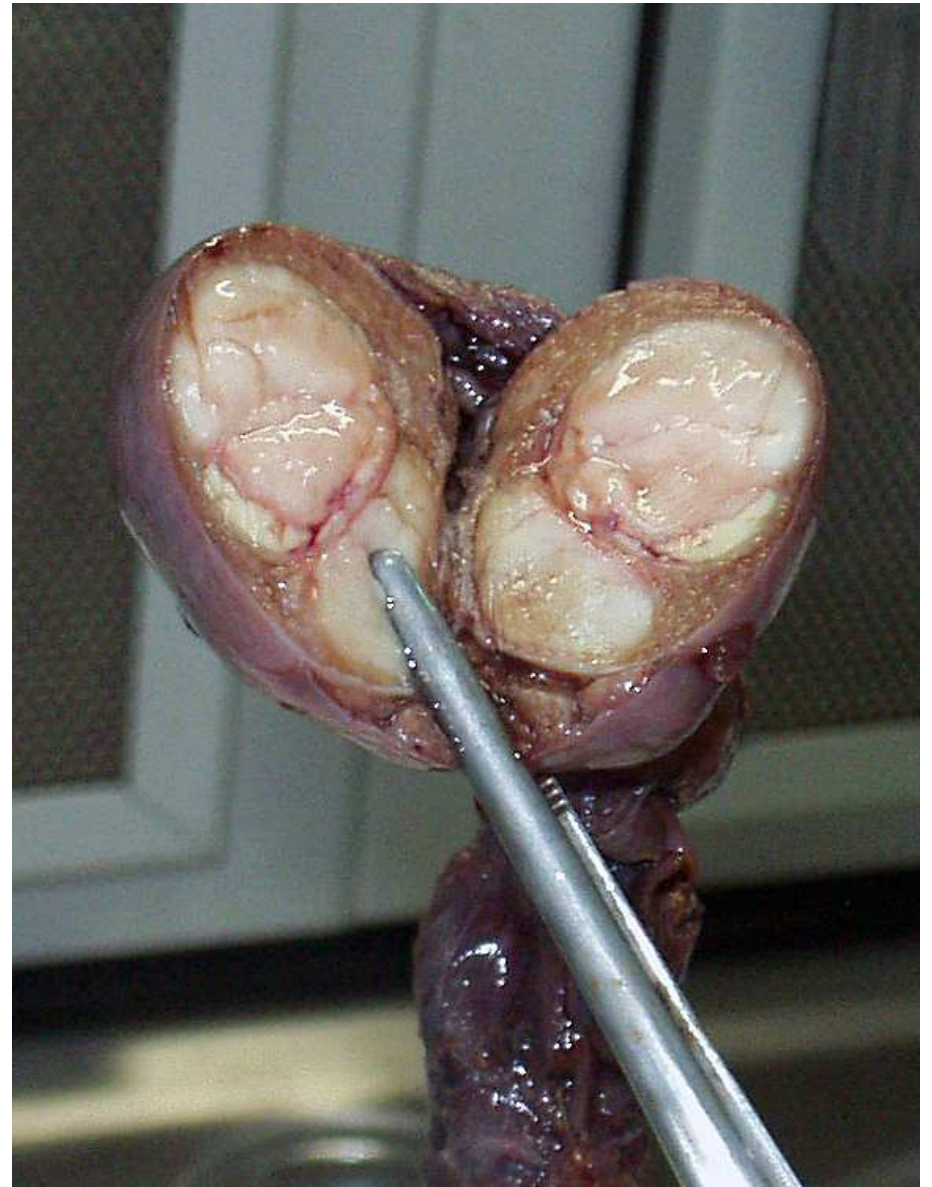
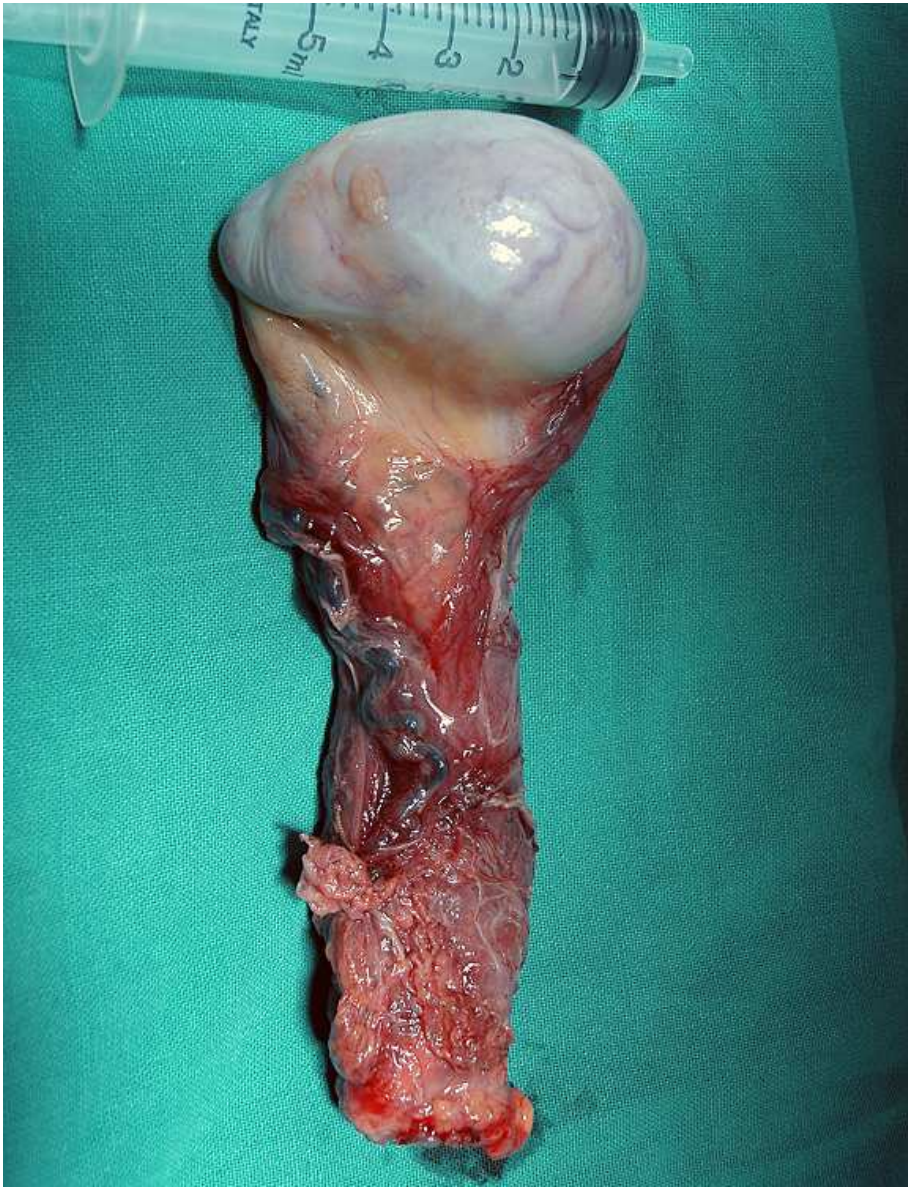




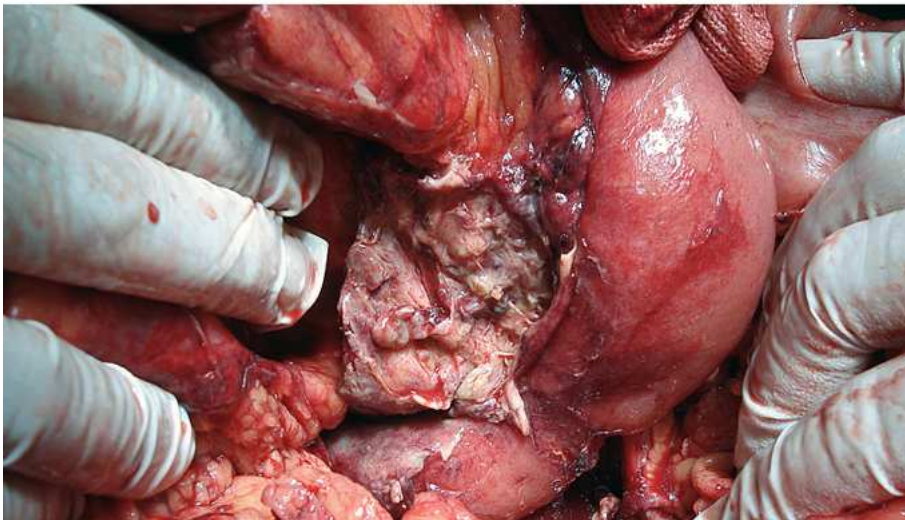
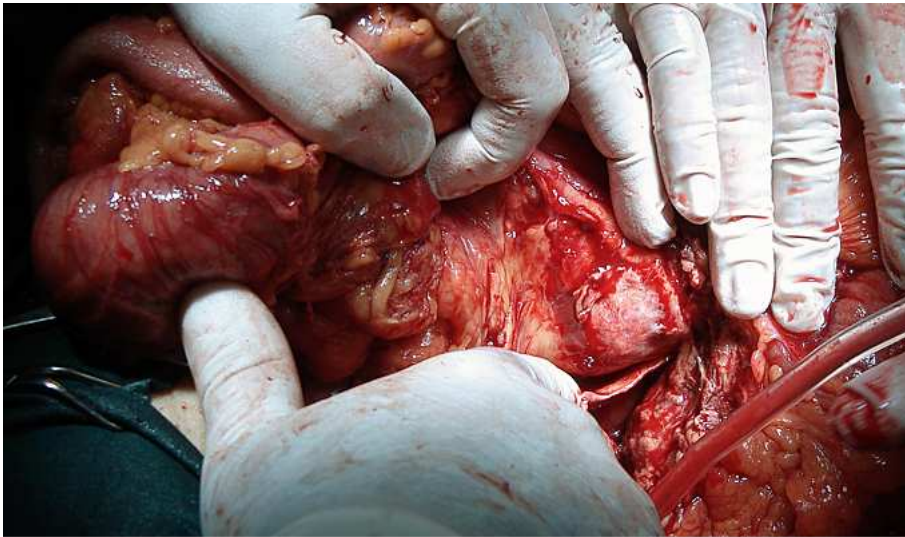
F.C. • Anni: 31 - M • Record: 43 • 07-07-2008

Orchifunicectomia per seminoma del testicolo sn



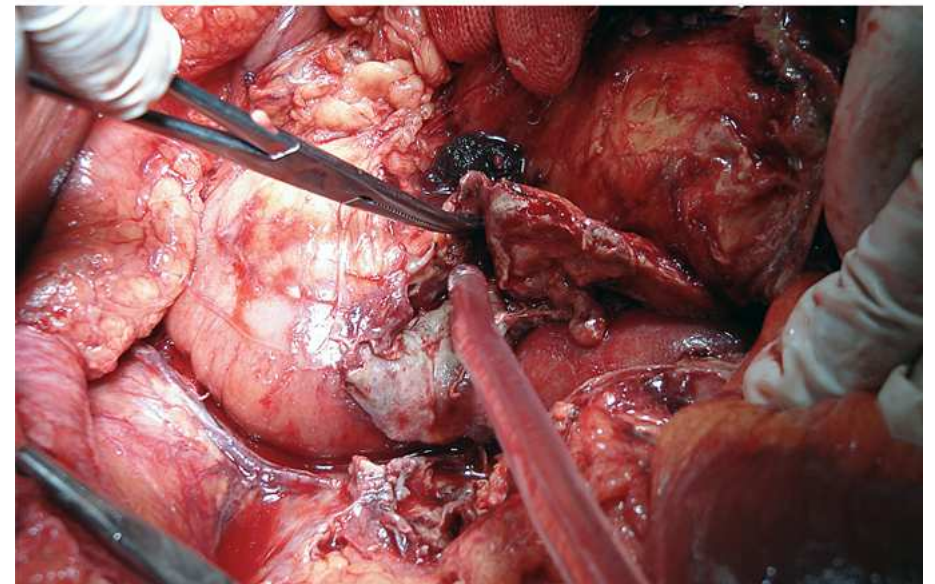
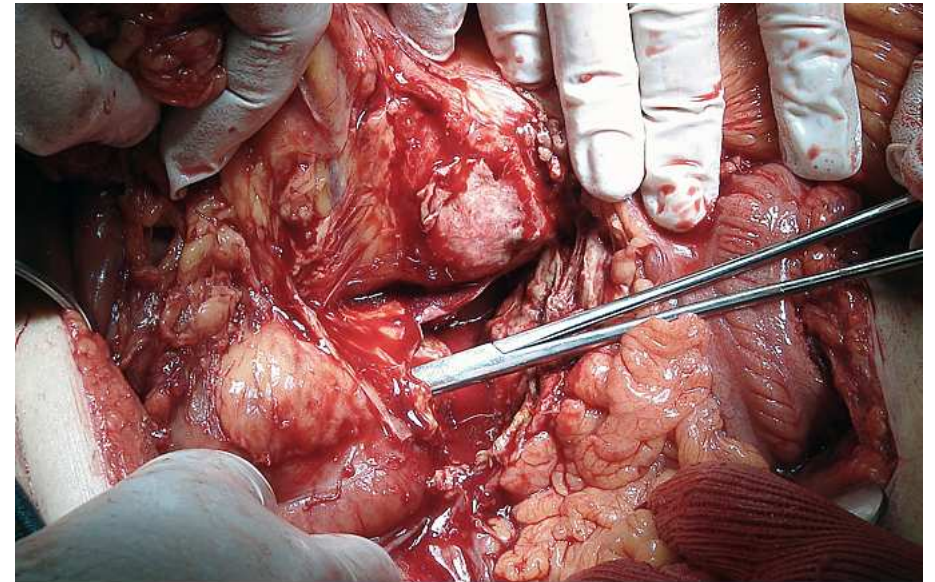


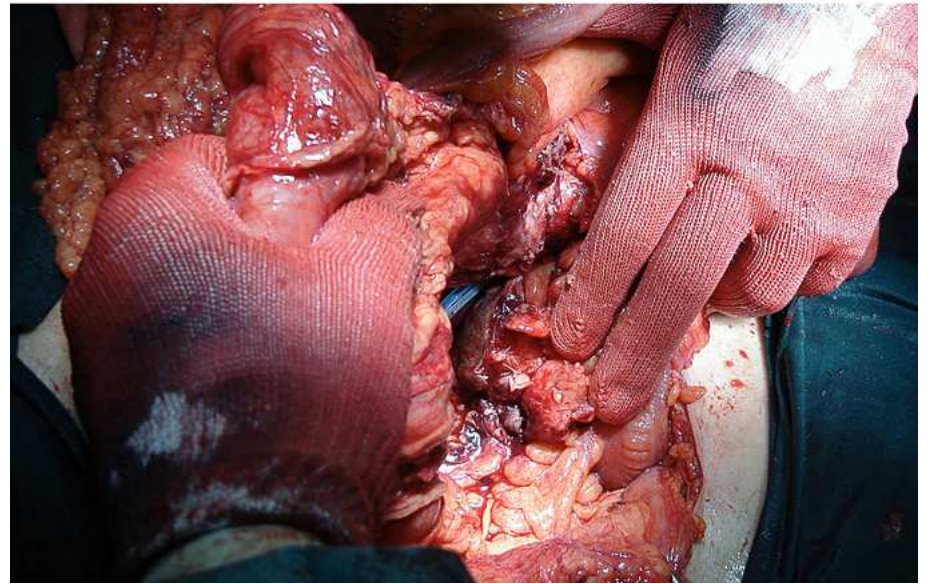
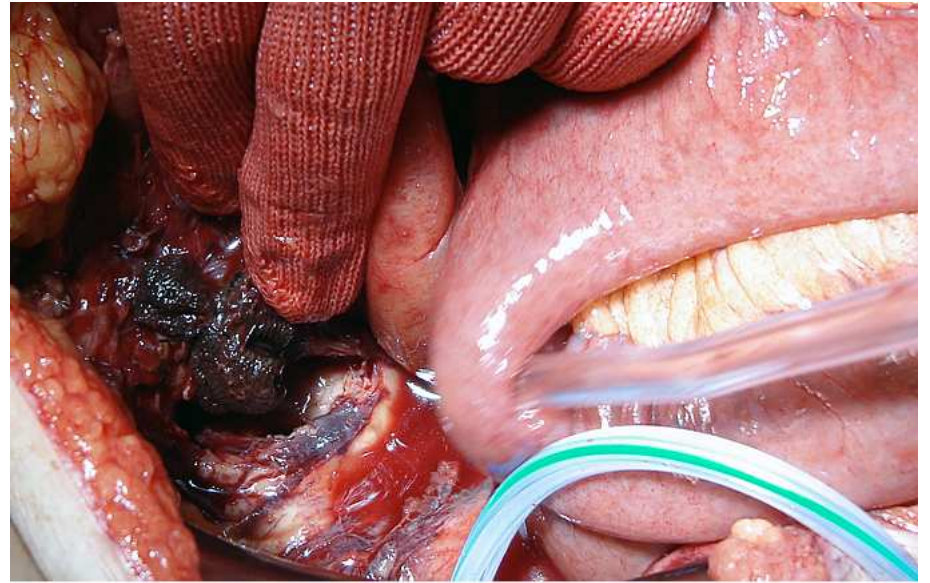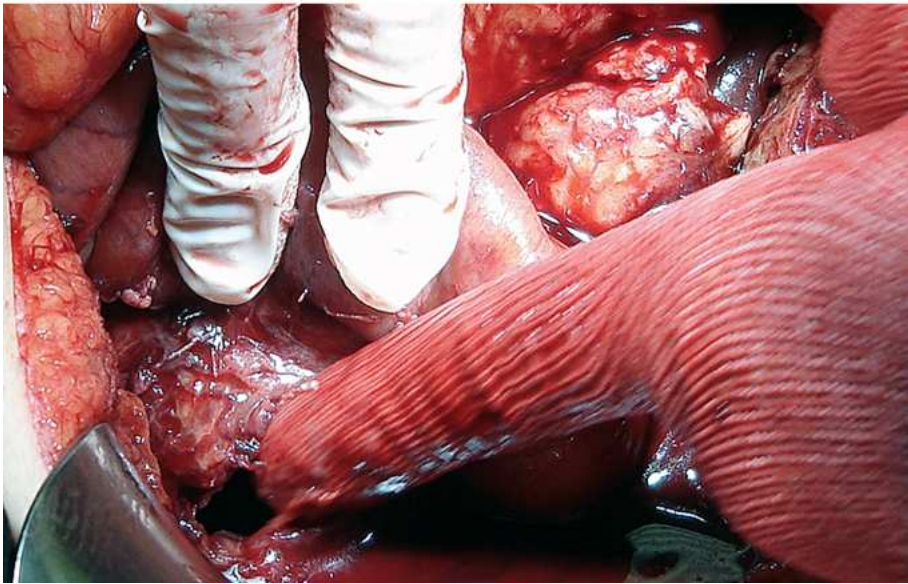

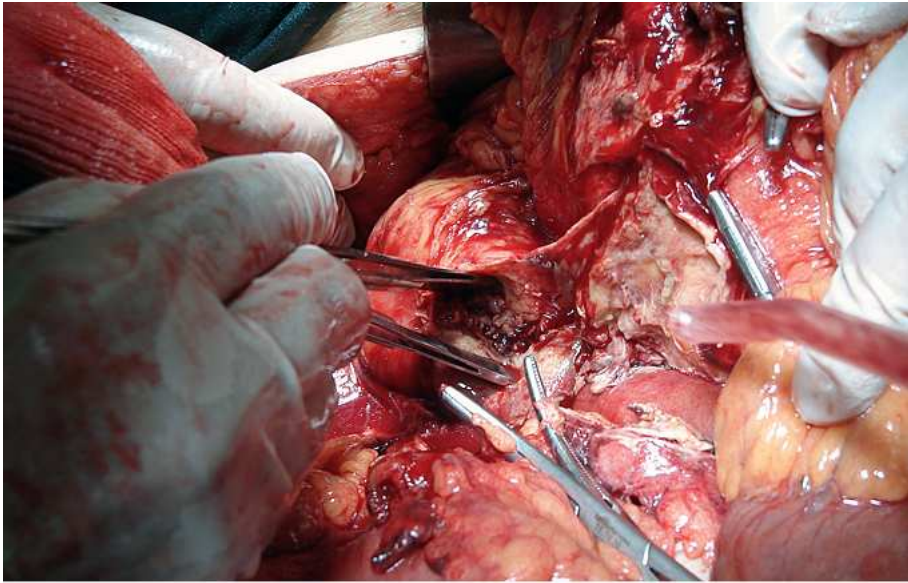
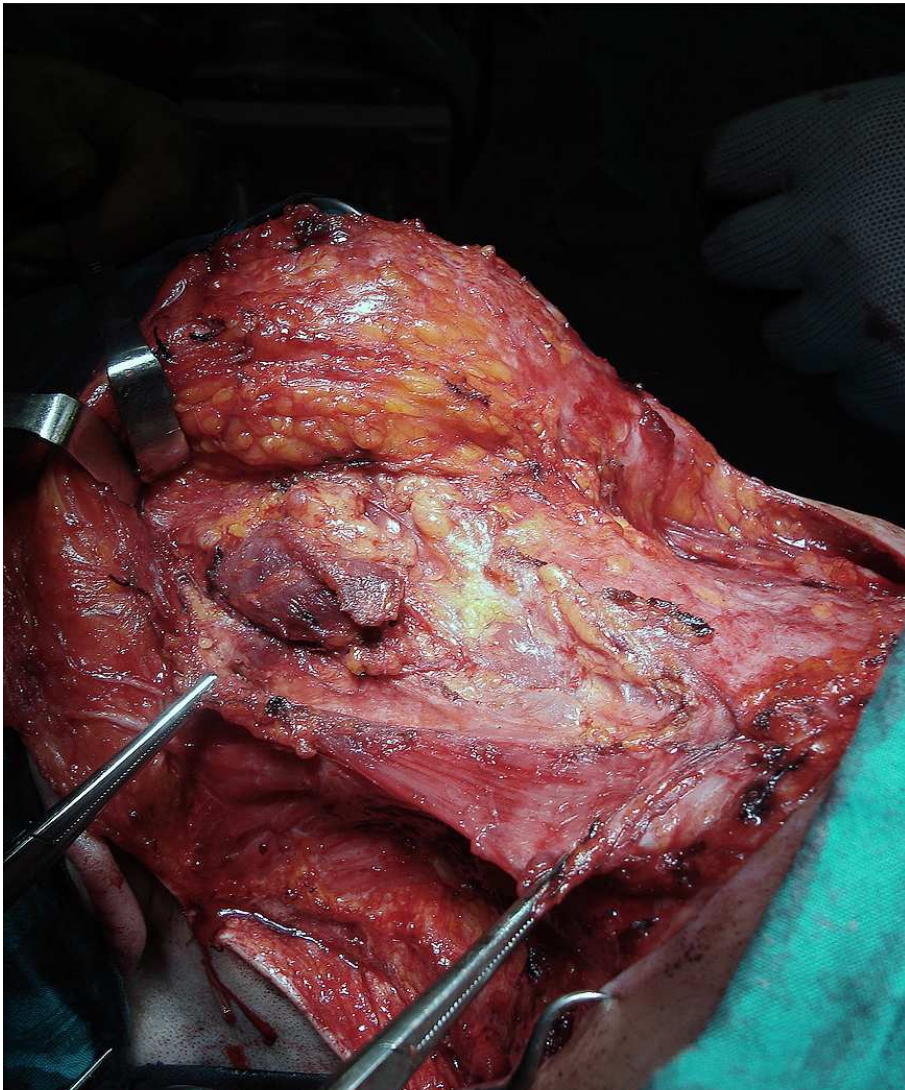


P.V. • Anni: 78 - M • Record: 44 • 11-09-2008

Apertura e drenaggio di ascesso della testa del pancreas

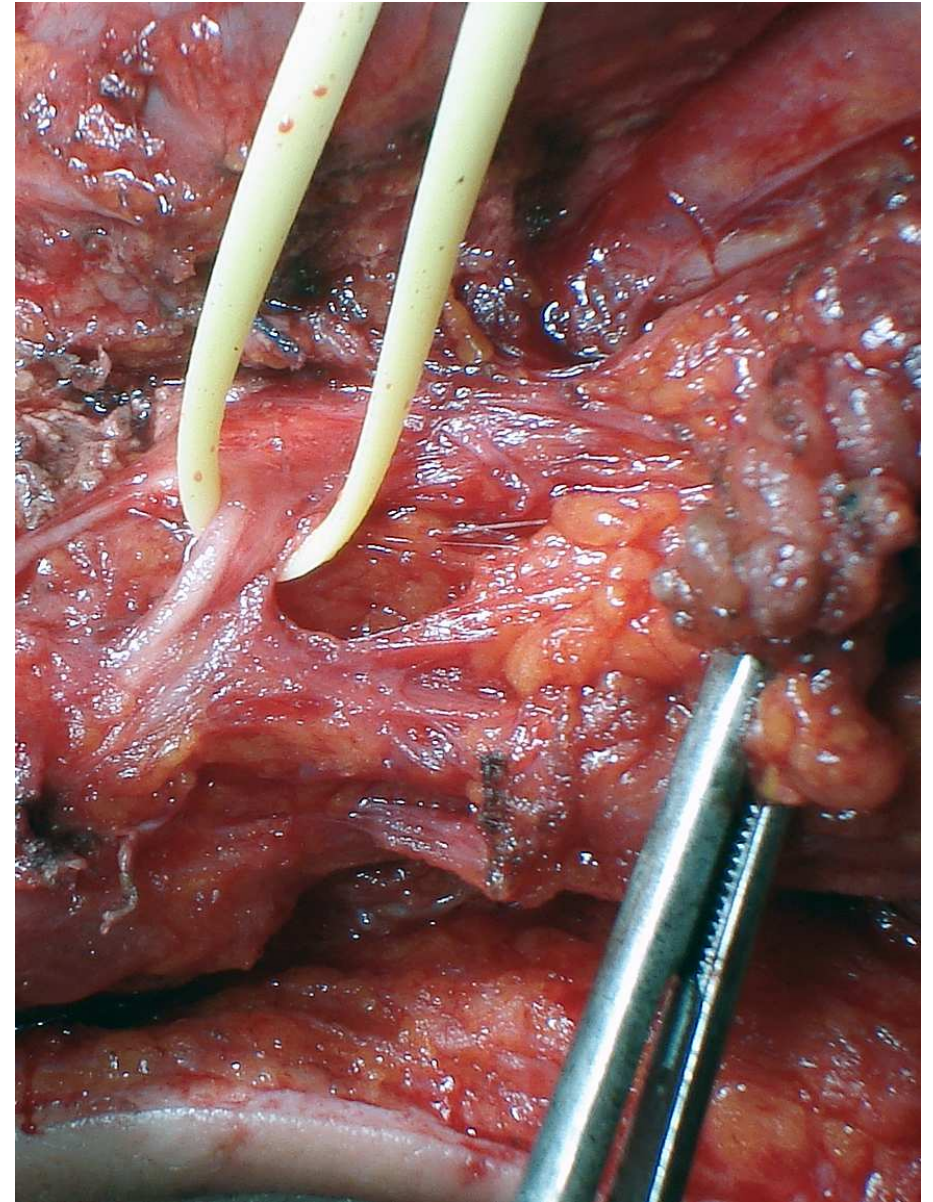




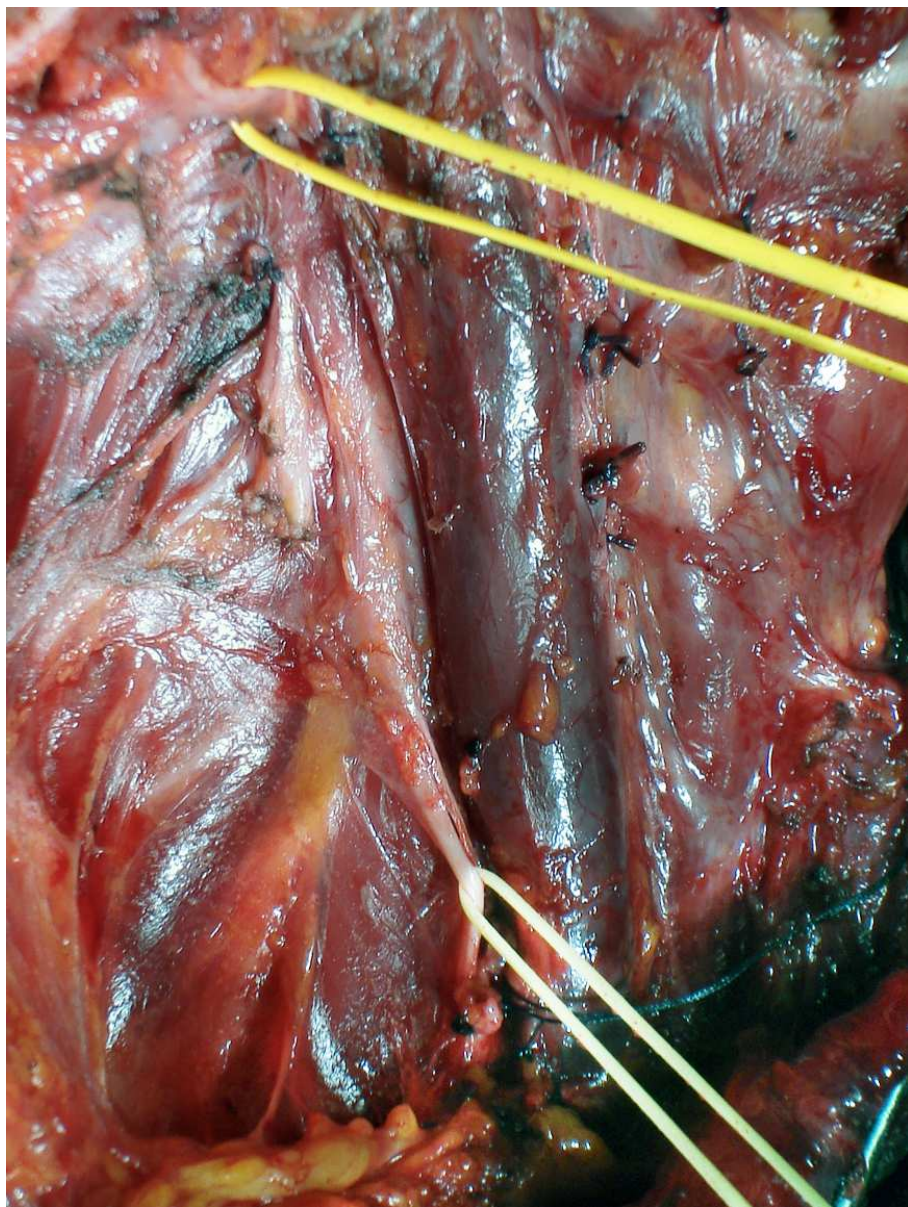


C.A. • Anni: 54 - F • Record: 45 • 02-10-2008

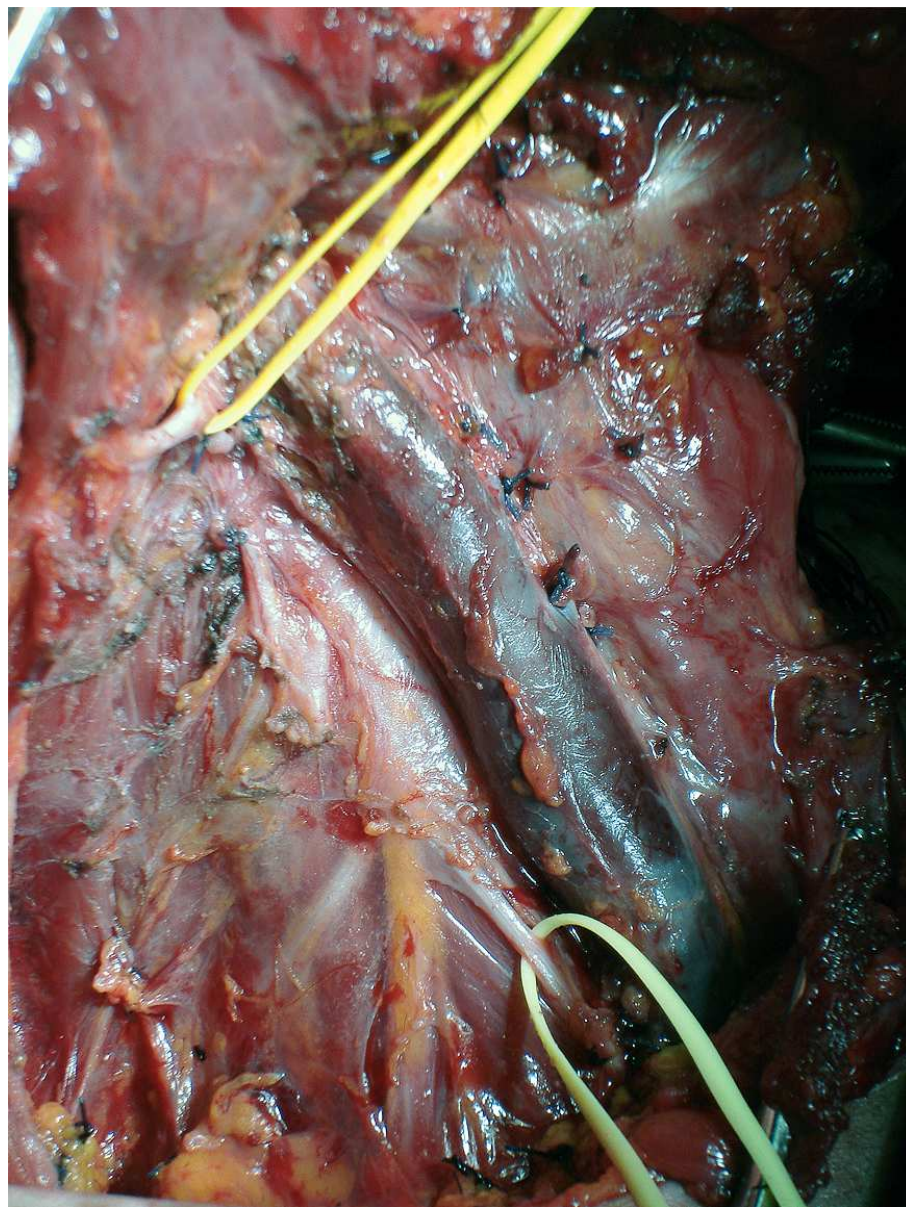
Linfectomia cervico-mediastinica dx per metastasi linfonodali L.C. e mediastiniche in operata per carcinoma papillifero del lobo dx della tiroide



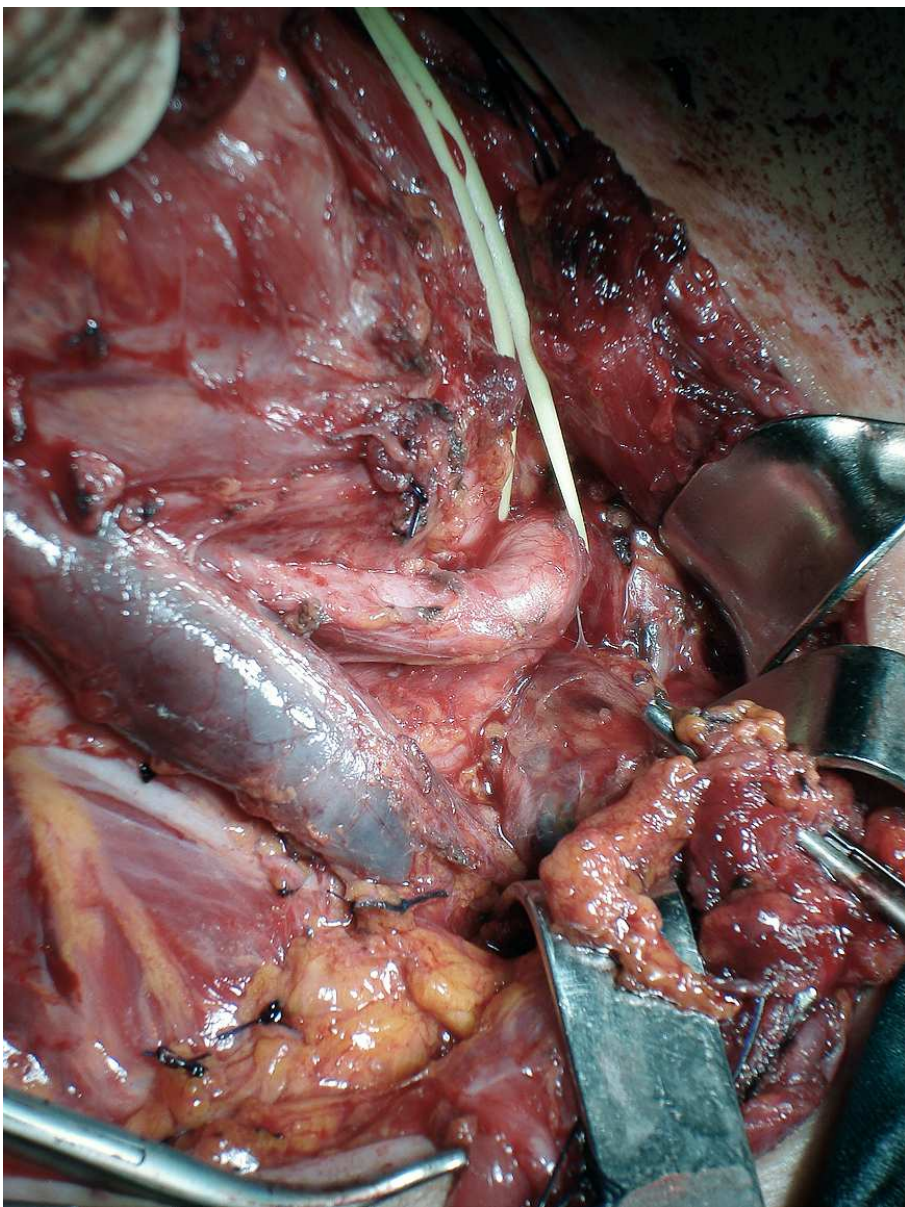Linfectomia L.C.



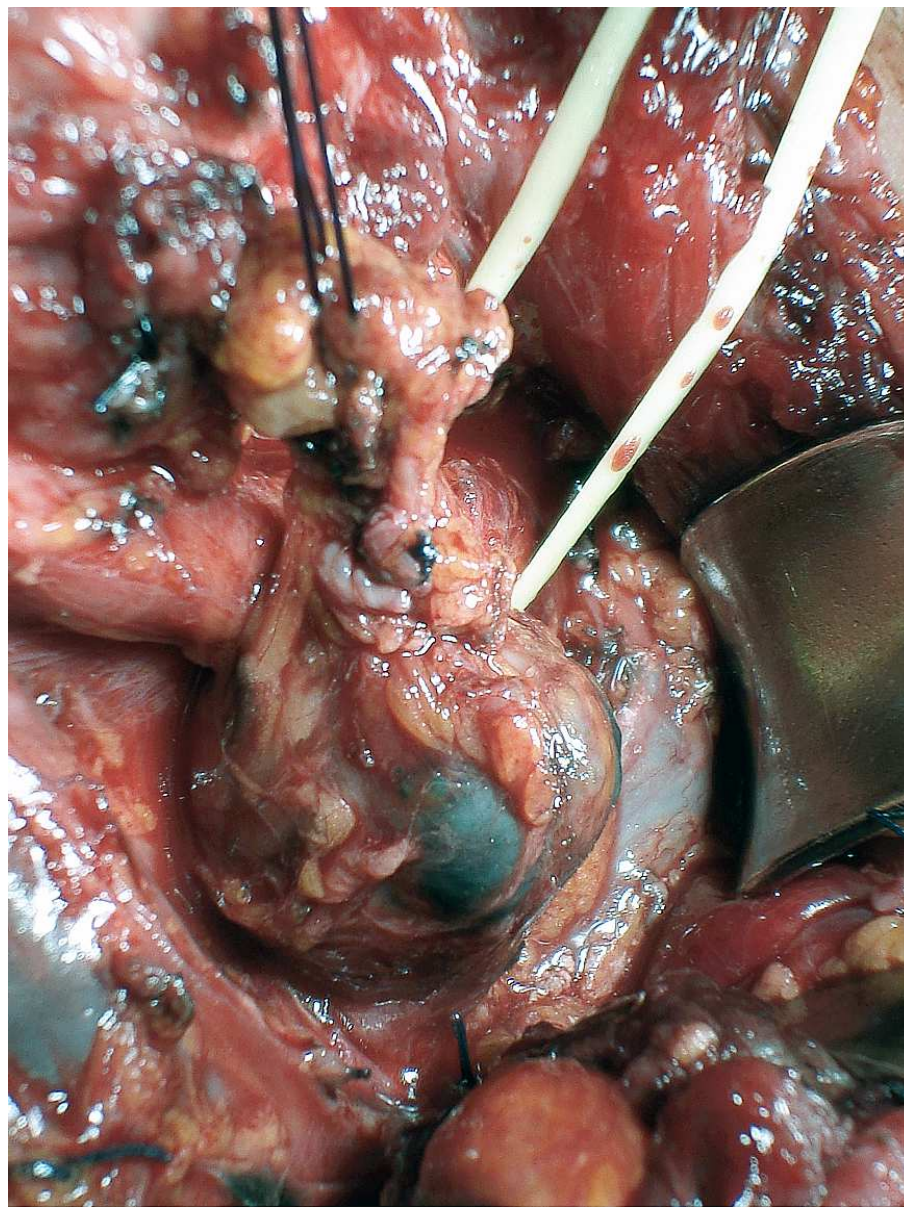
Nervo accessorio spinale - Plesso cervicale - Nervo frenico



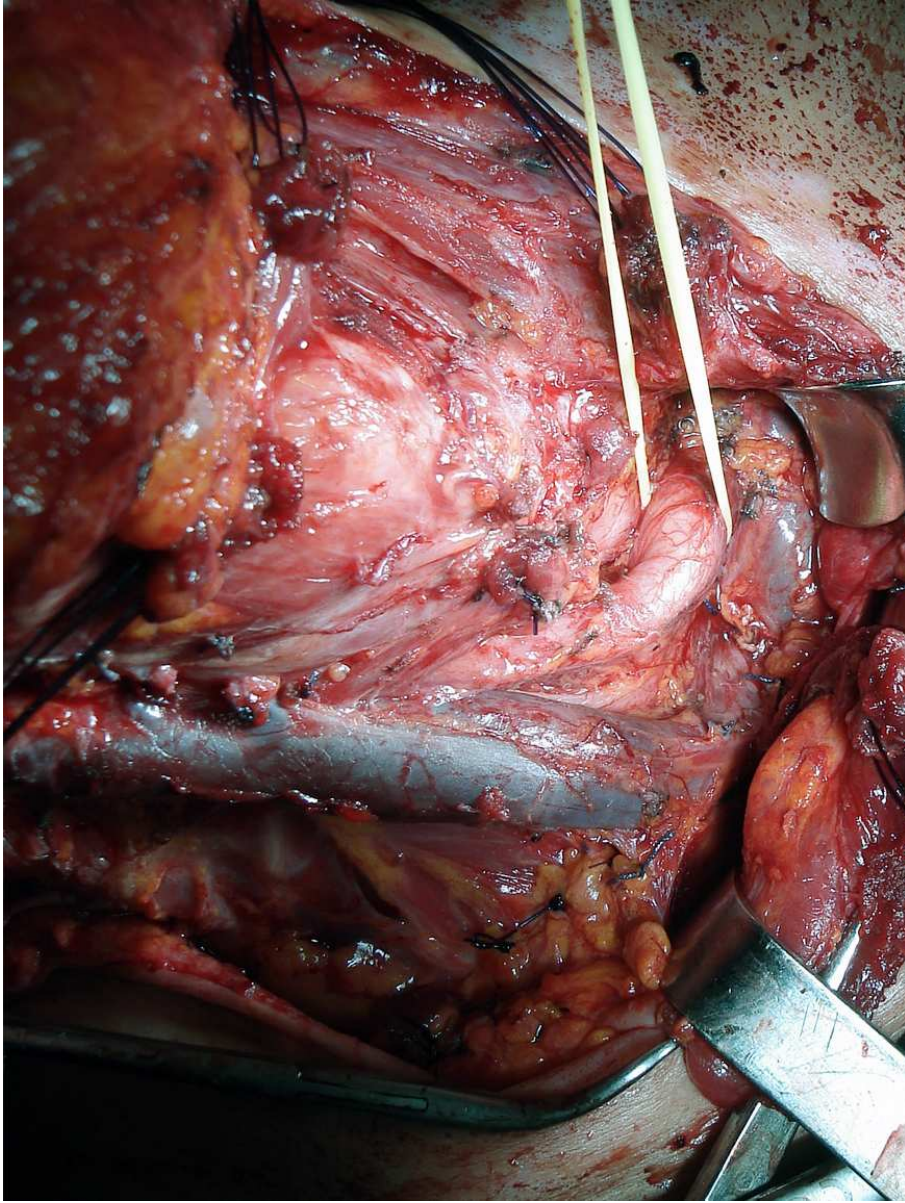
Nervo accessorio spinale - Nervo frenico



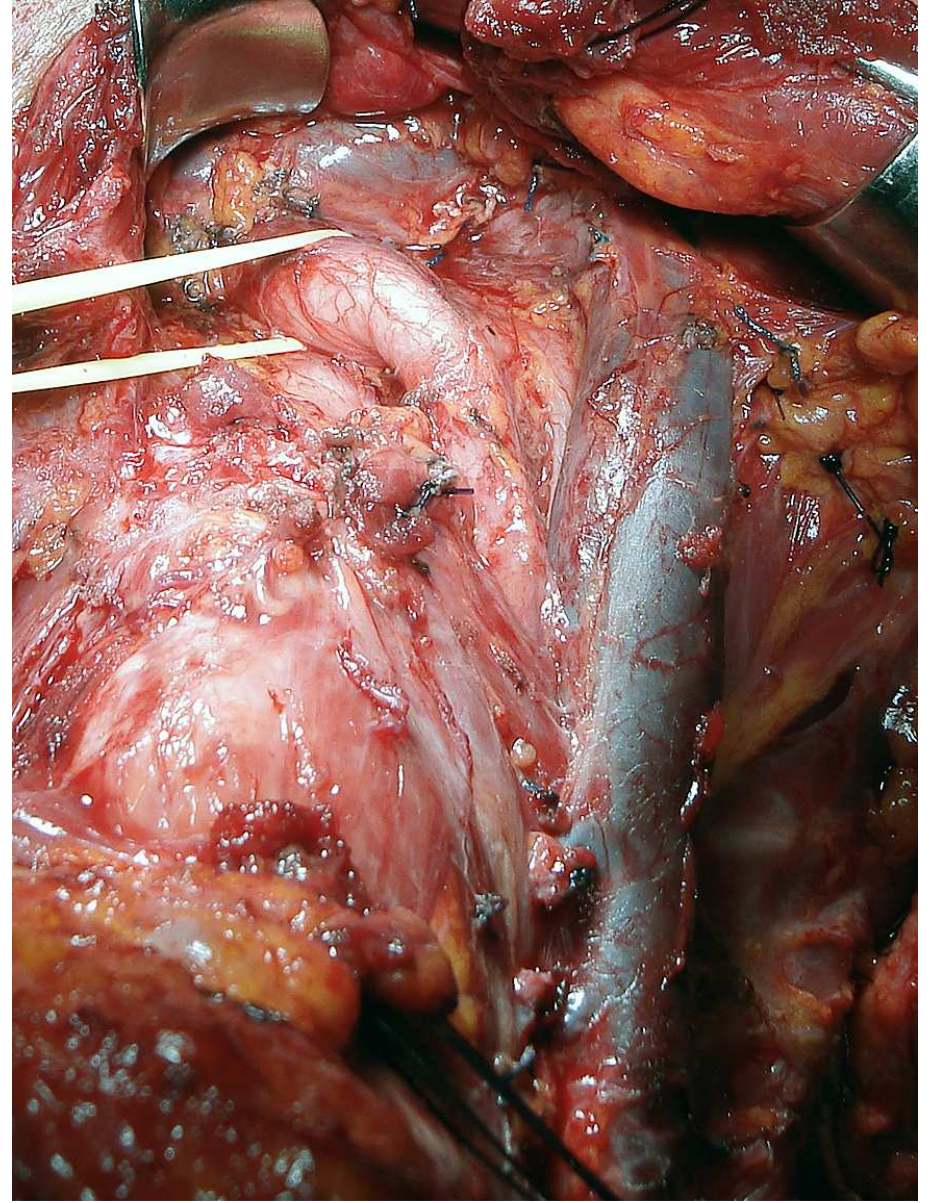
Arteria Carotide - Pacchetto linfonodale mediastinico e L.C. - Vena giugulare



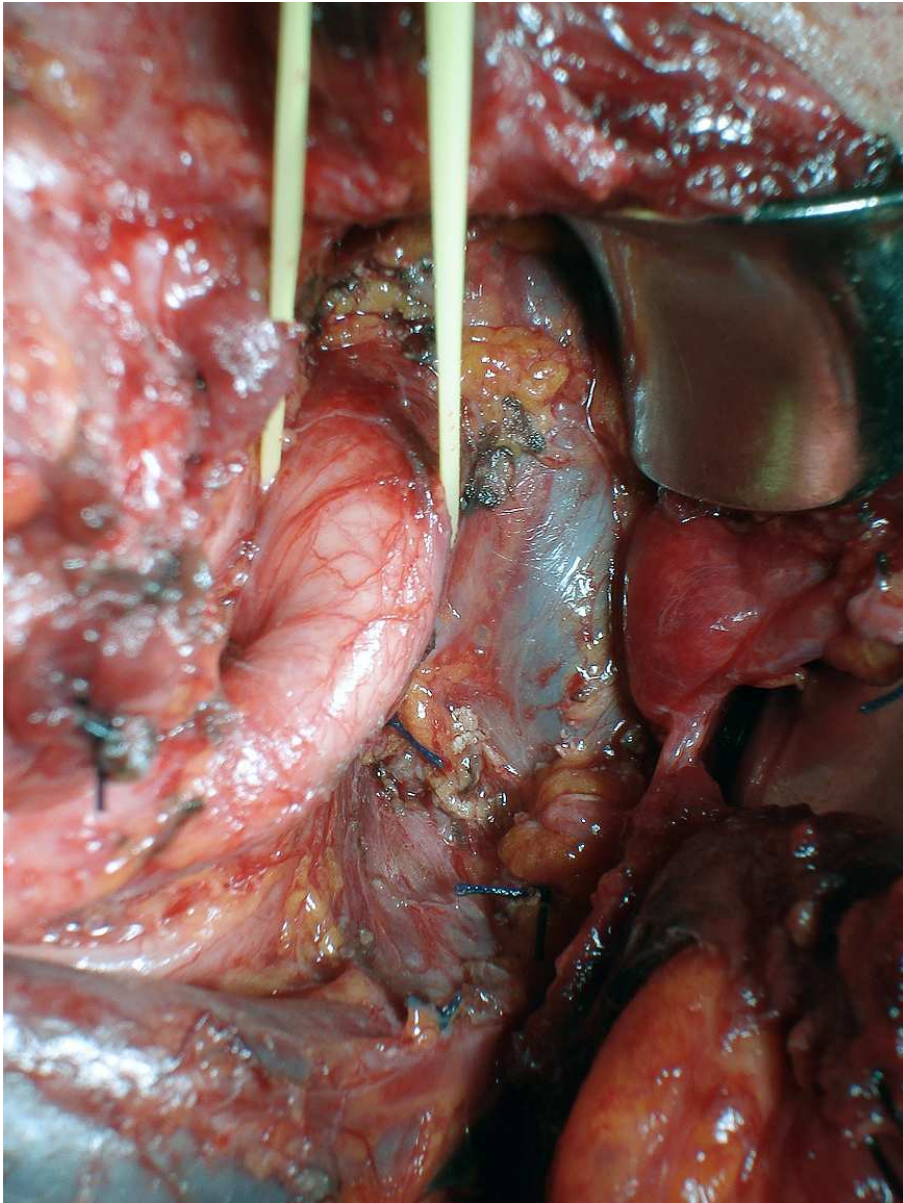
Linfectomia mediastinica



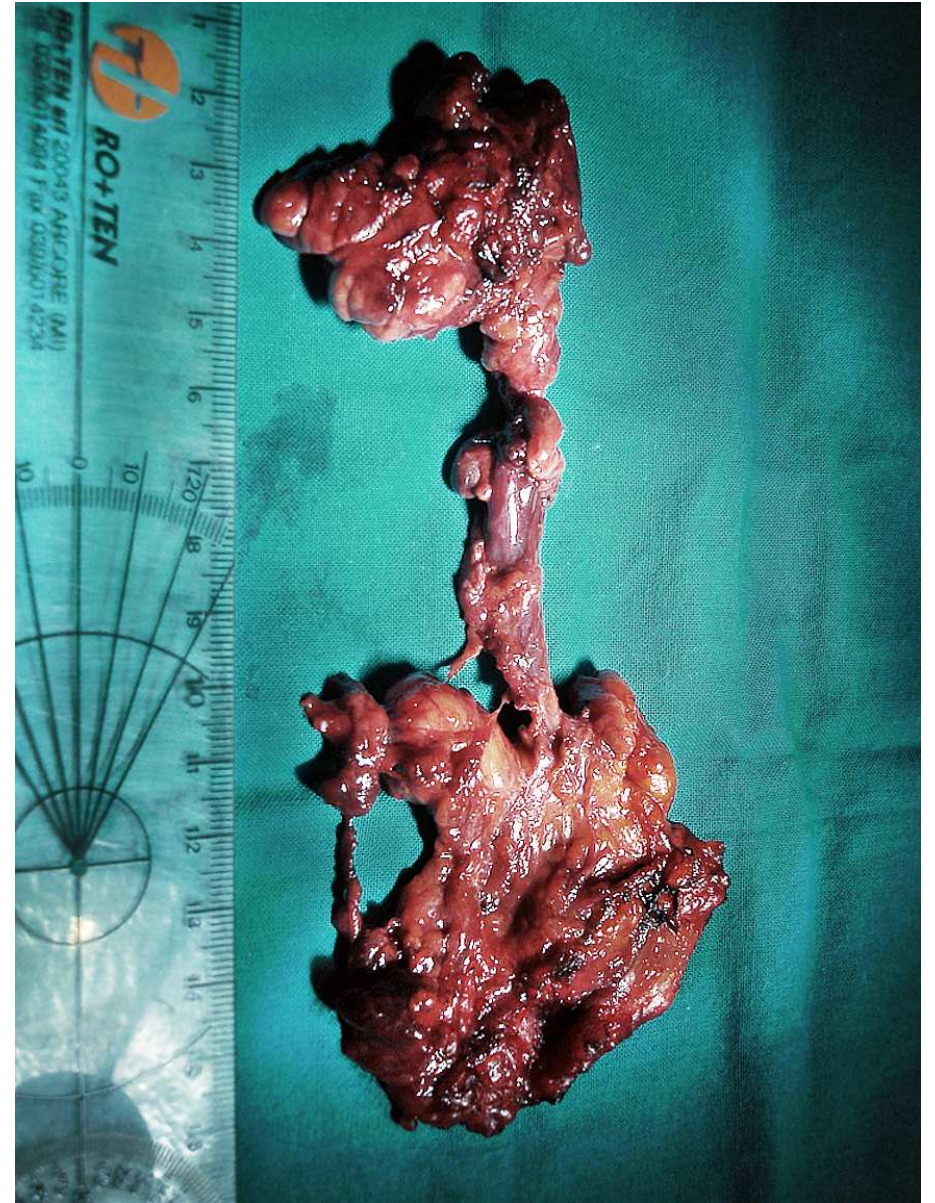
Vena anonima - Arteria carotide (loop giallo) - Vena giugulare



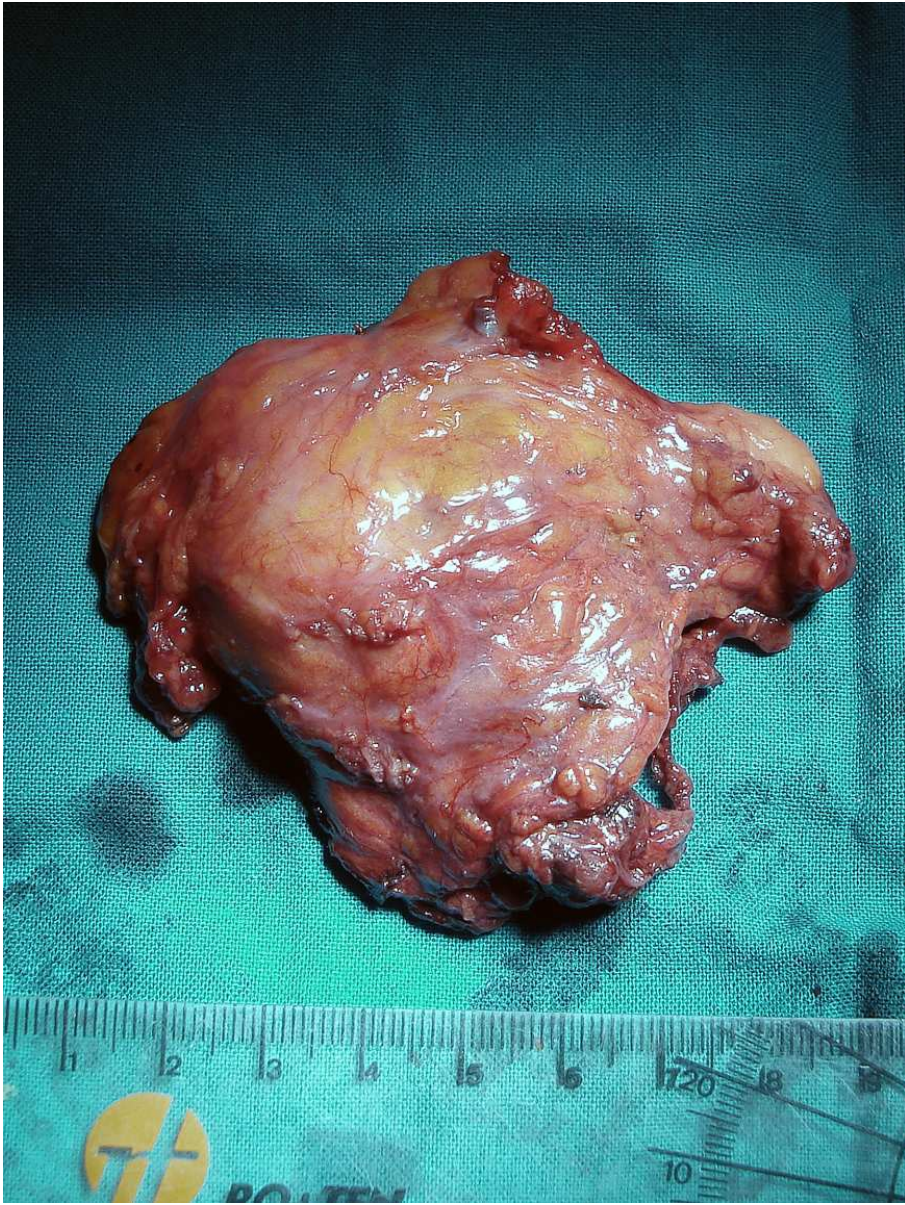
Vena anonima - Arteria carotide (loop giallo) - Vena giugulare



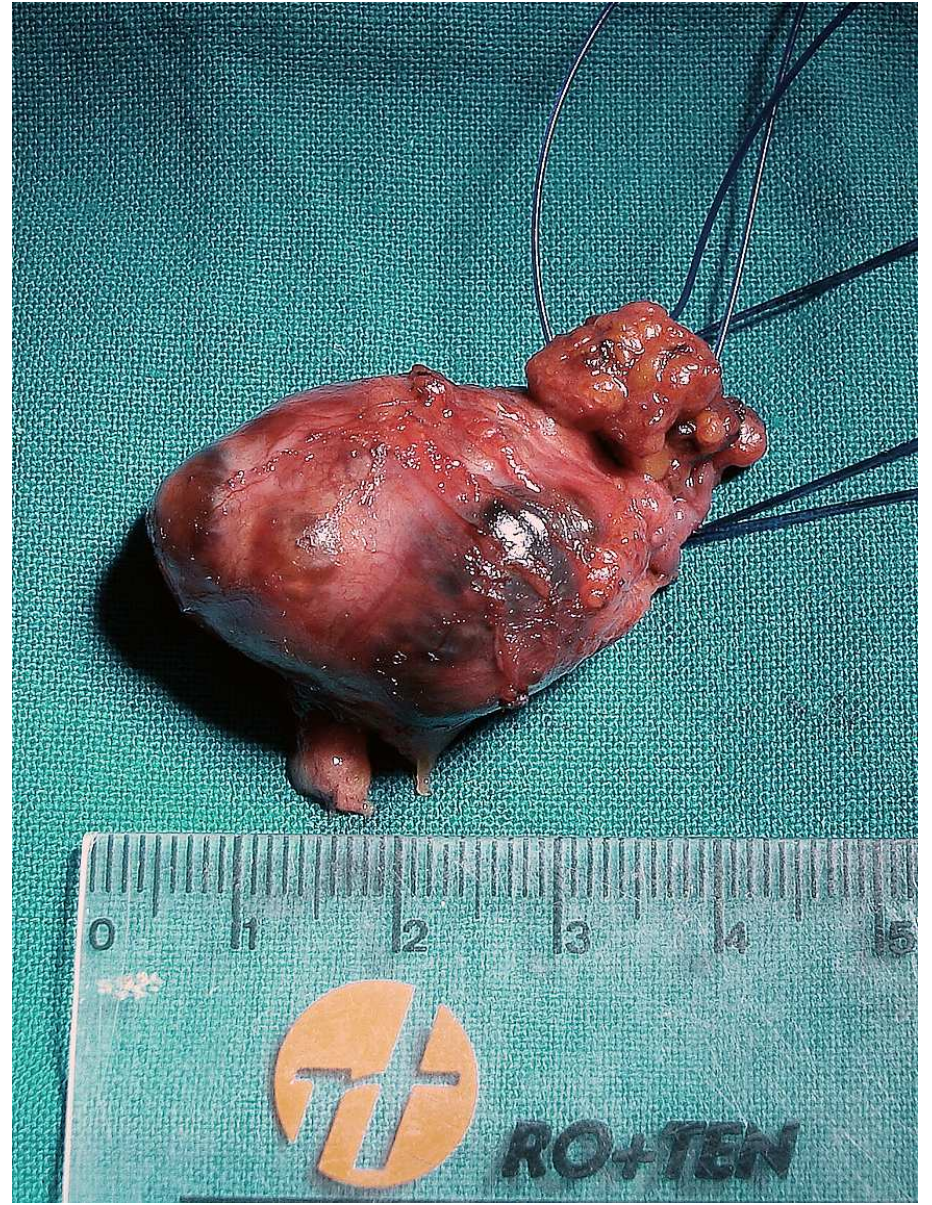
Vena anonima - Arteria carotide (loop giallo) - Vena giugolare



Linfectomia cervico-mediastinica

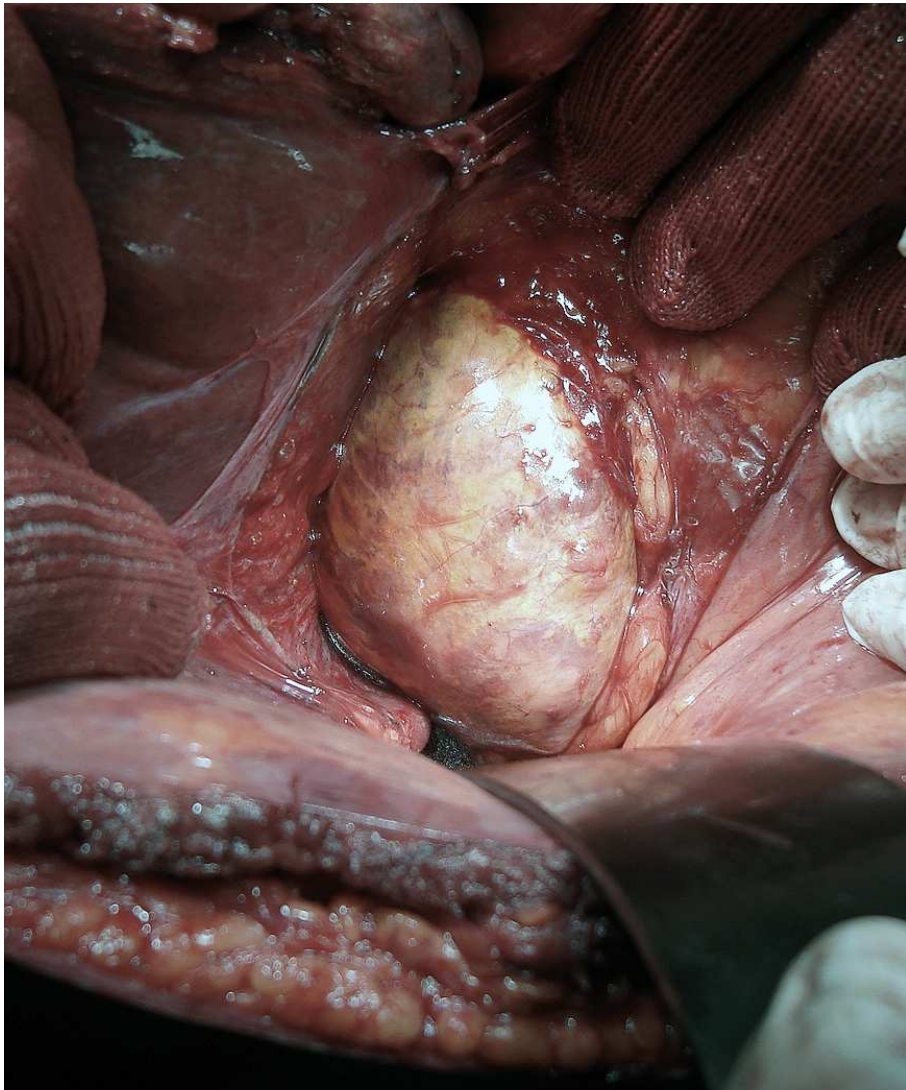


Pacchetto linfonodale cervicale



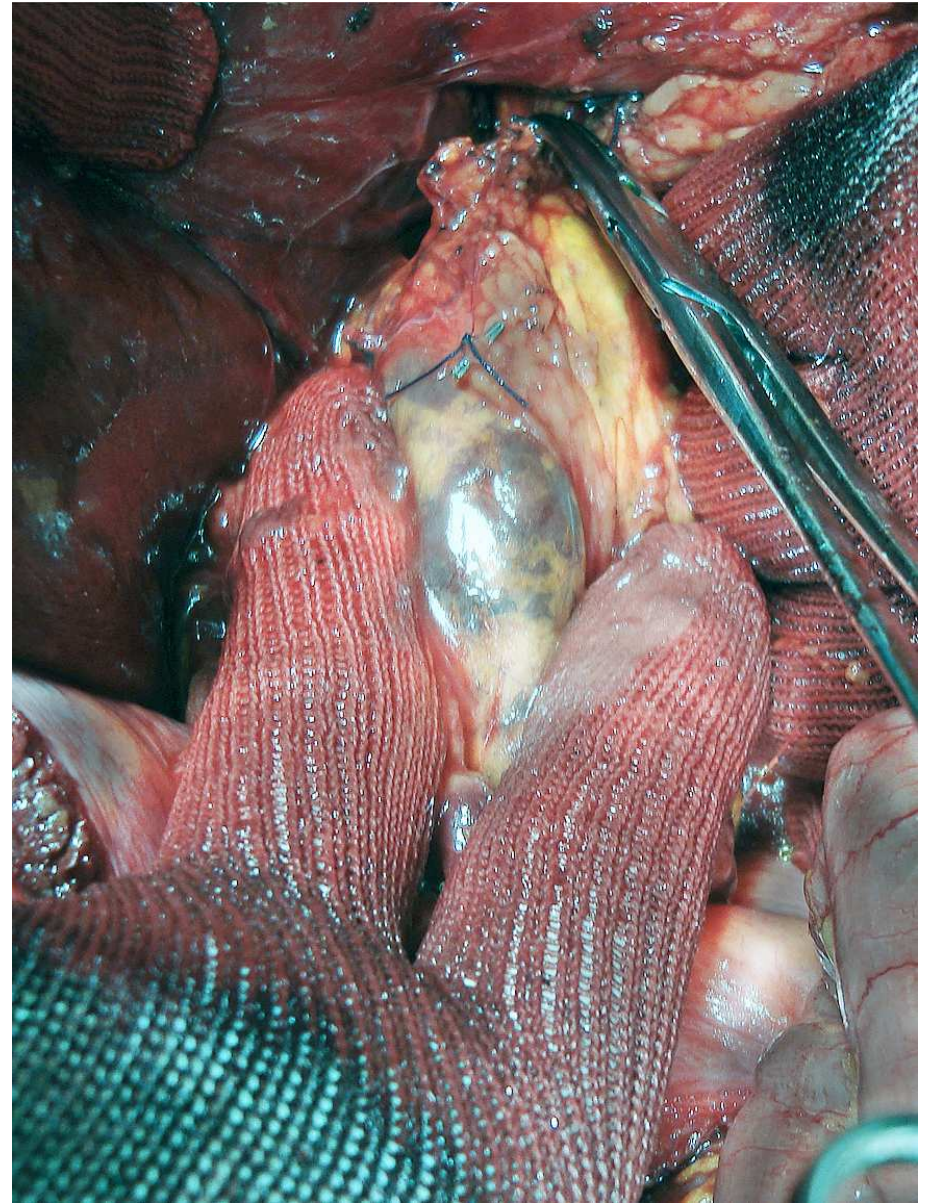
Pacchetto linfonodale mediastinico

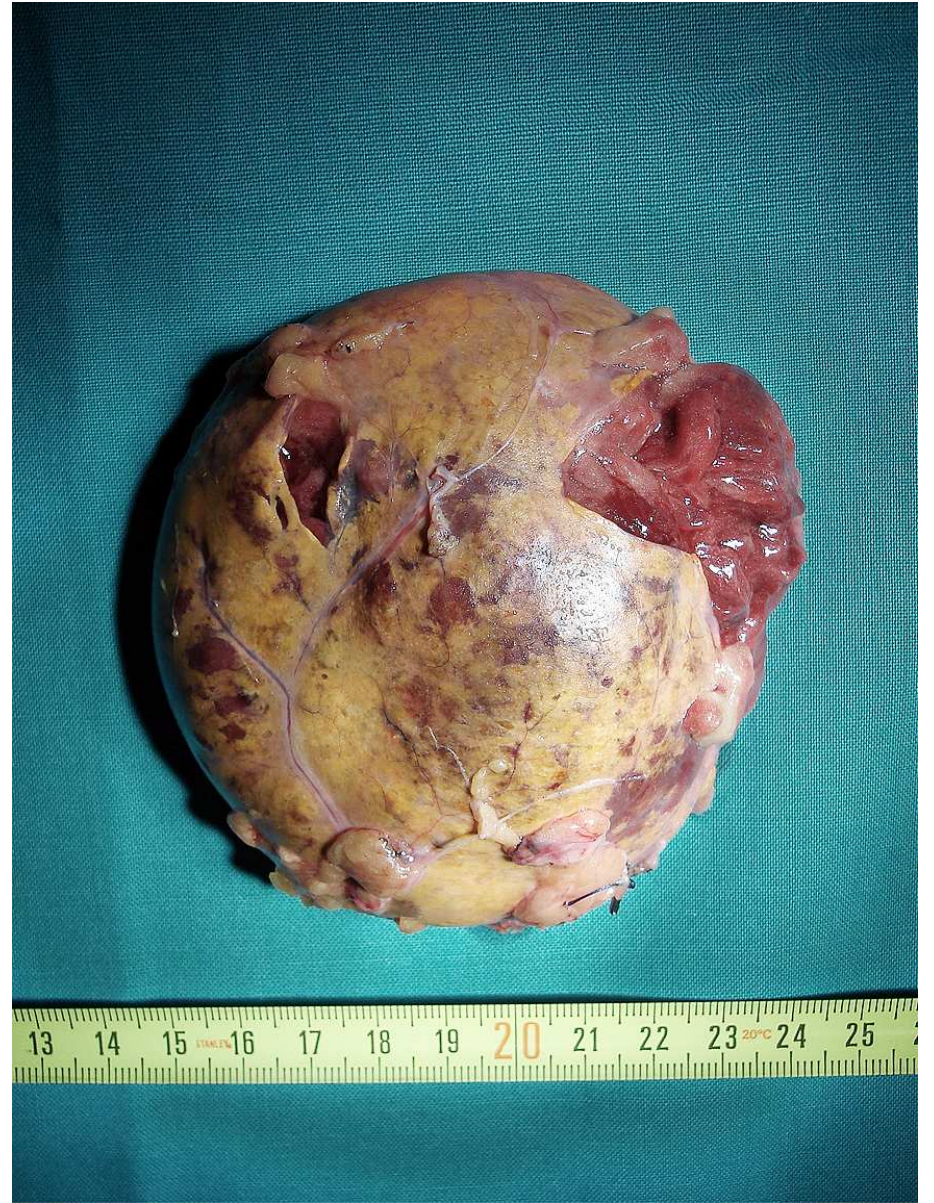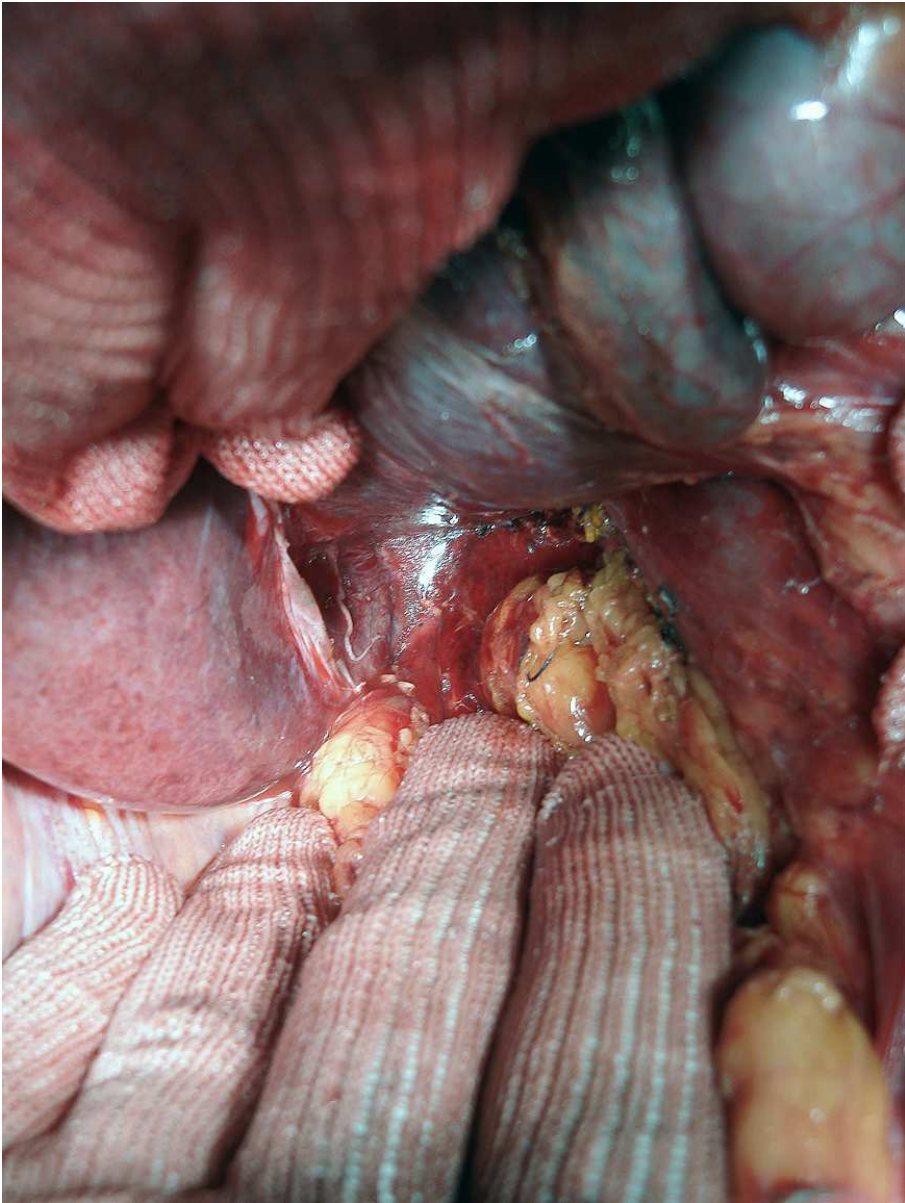


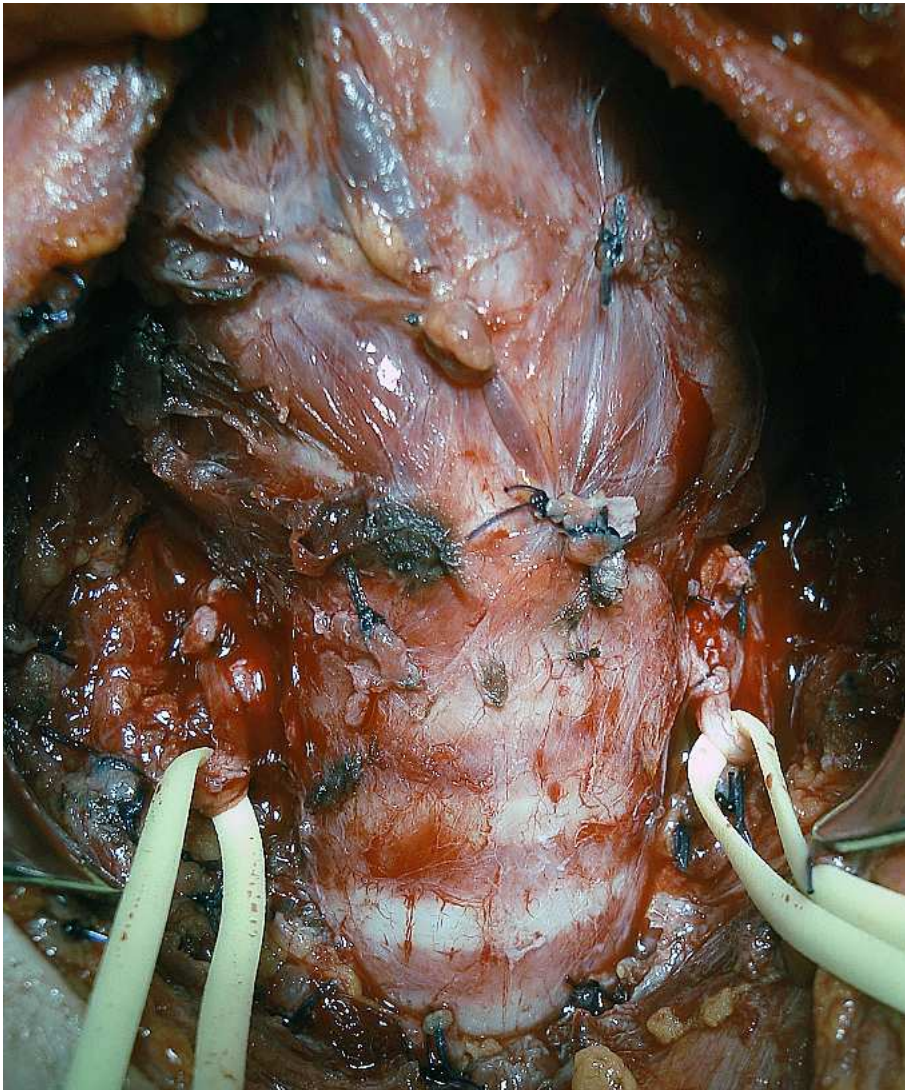



A.A. • Anni: 54 - M 🍏 Record: 46 • 16-10-2008

Surrenectomia dx per mielolipoma

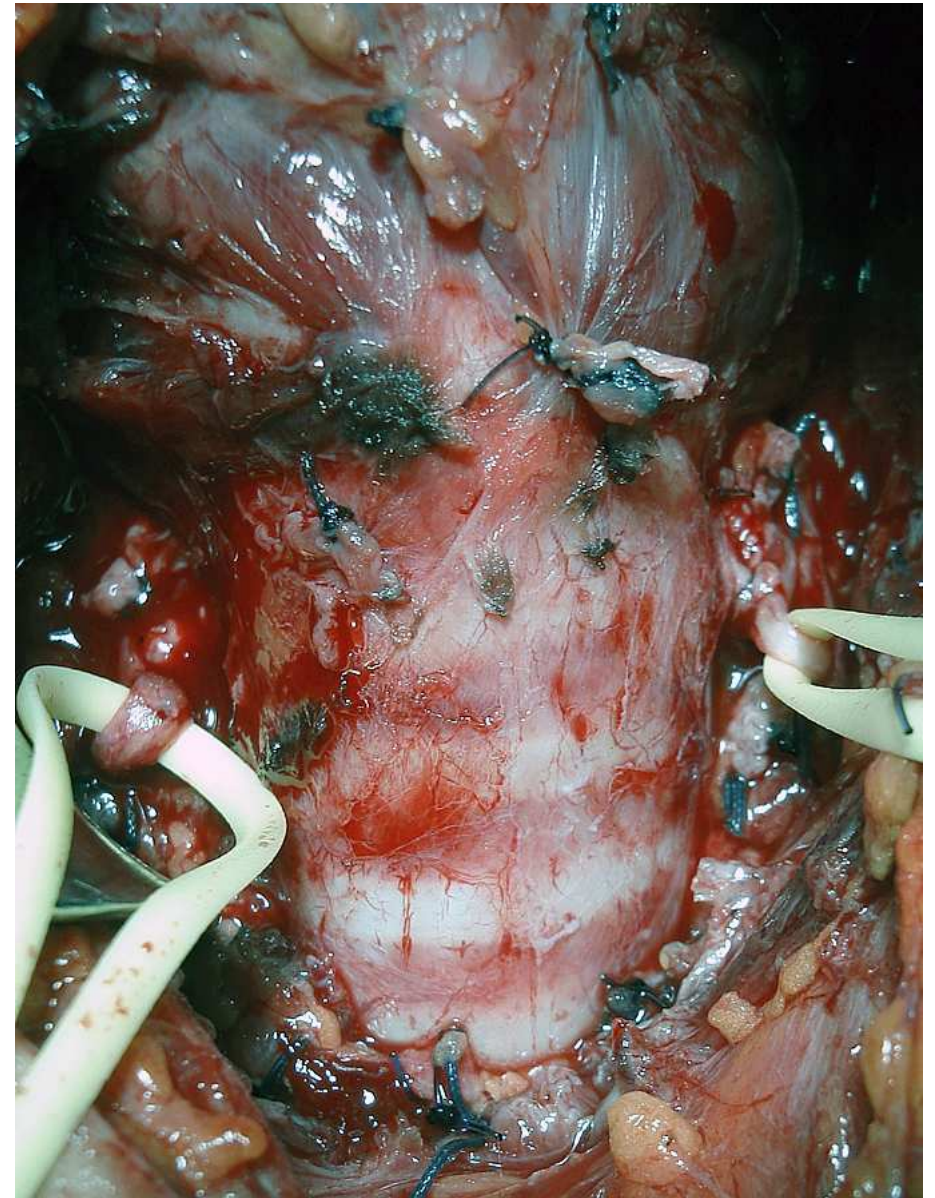




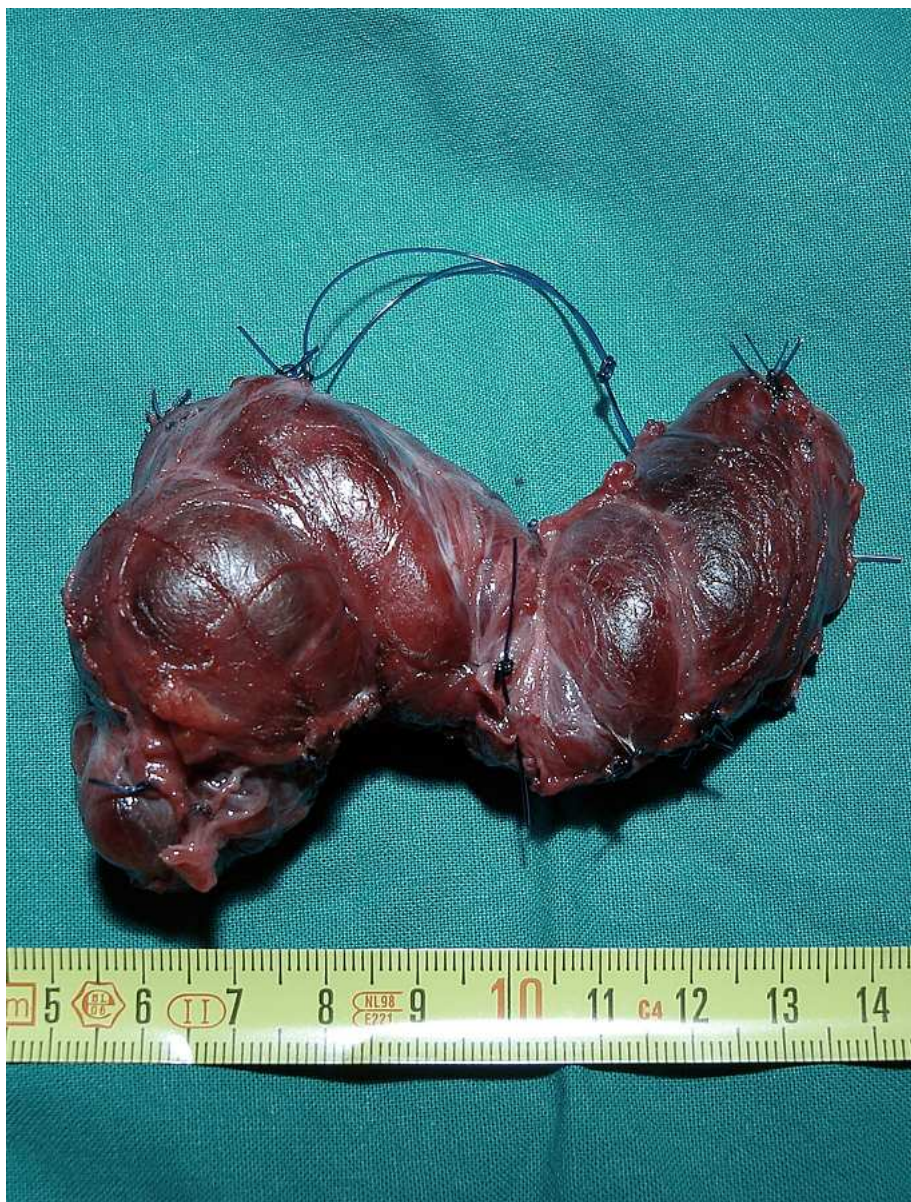

M.G. • Anni: 46 - M  Record: 47 • 11-12-2008

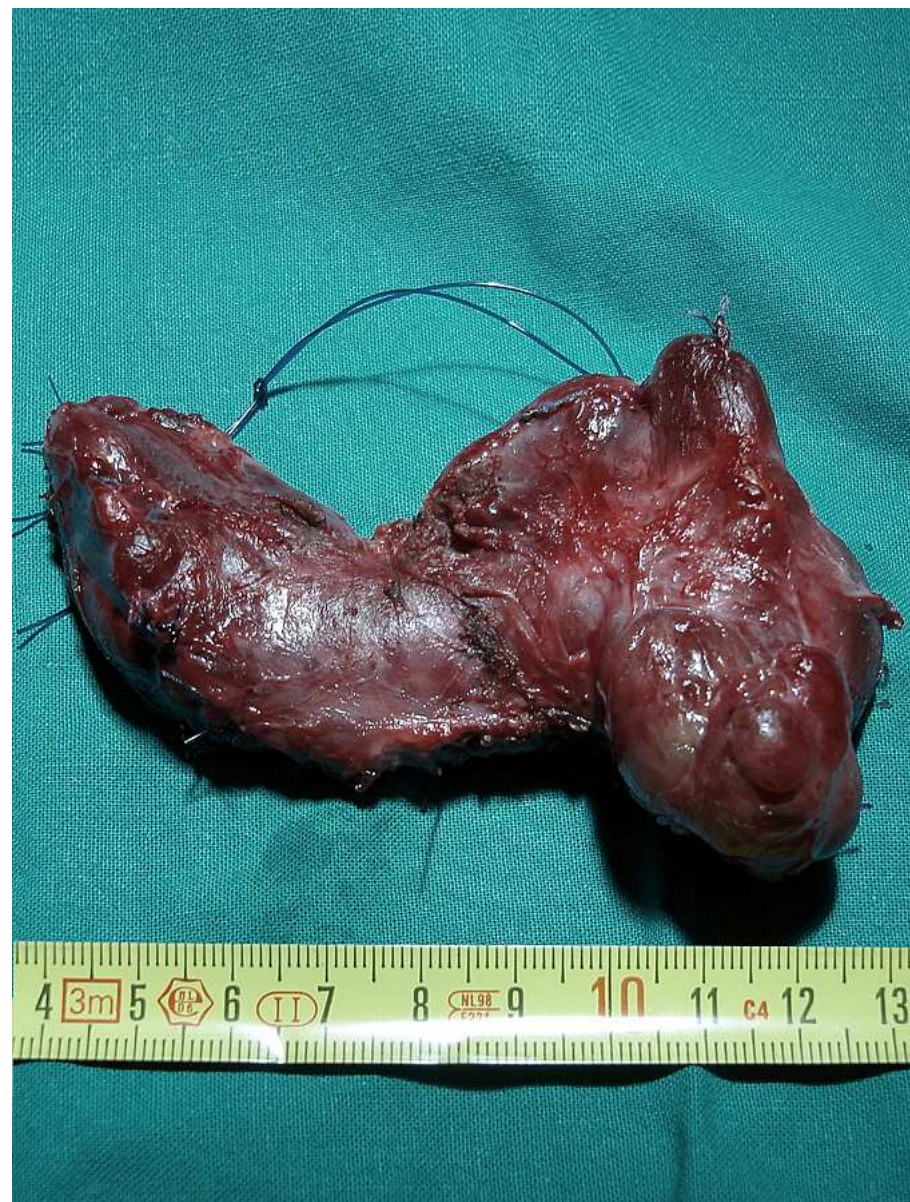Tiroidectomia totale extracapsulare per gozzo plurinodulare plongeant a dx



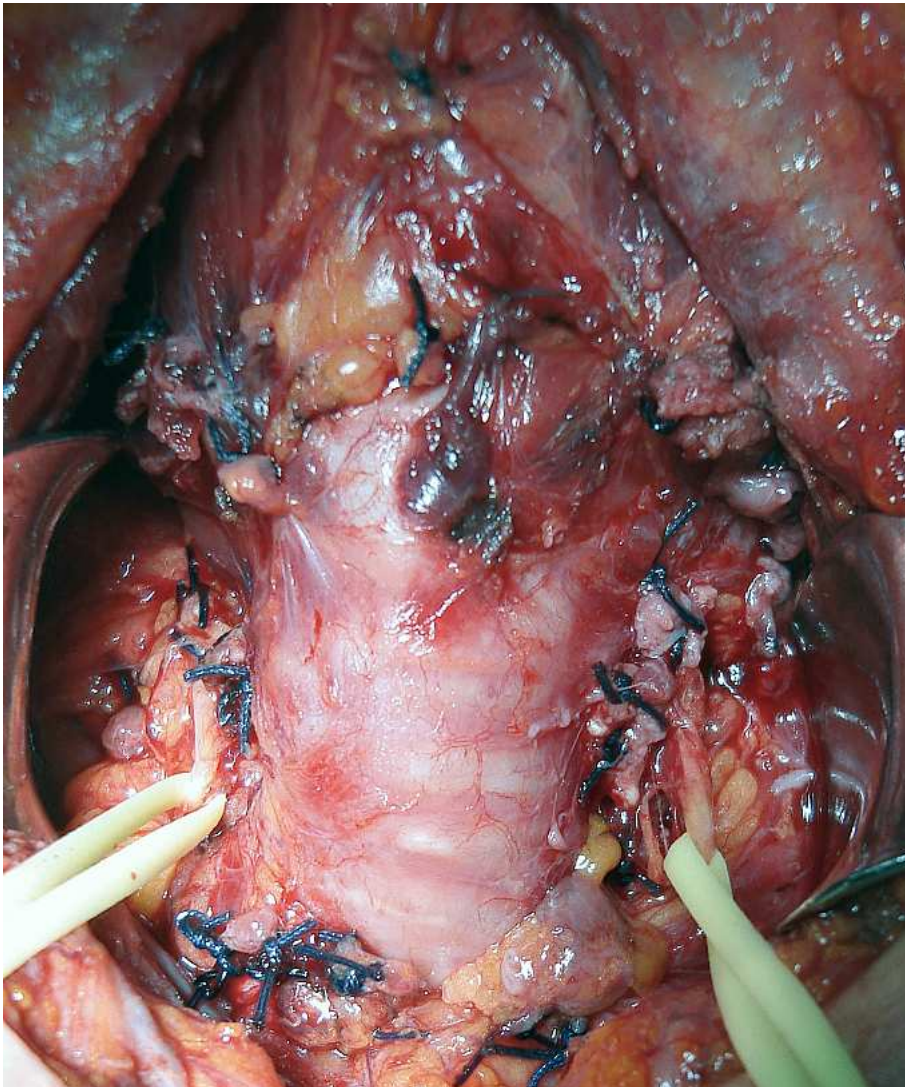
Isolamento dei nervi laringei inferiori (ricorrenti)



Lobo destro - Istmo - Lobo sinistro (superficie anteriore)

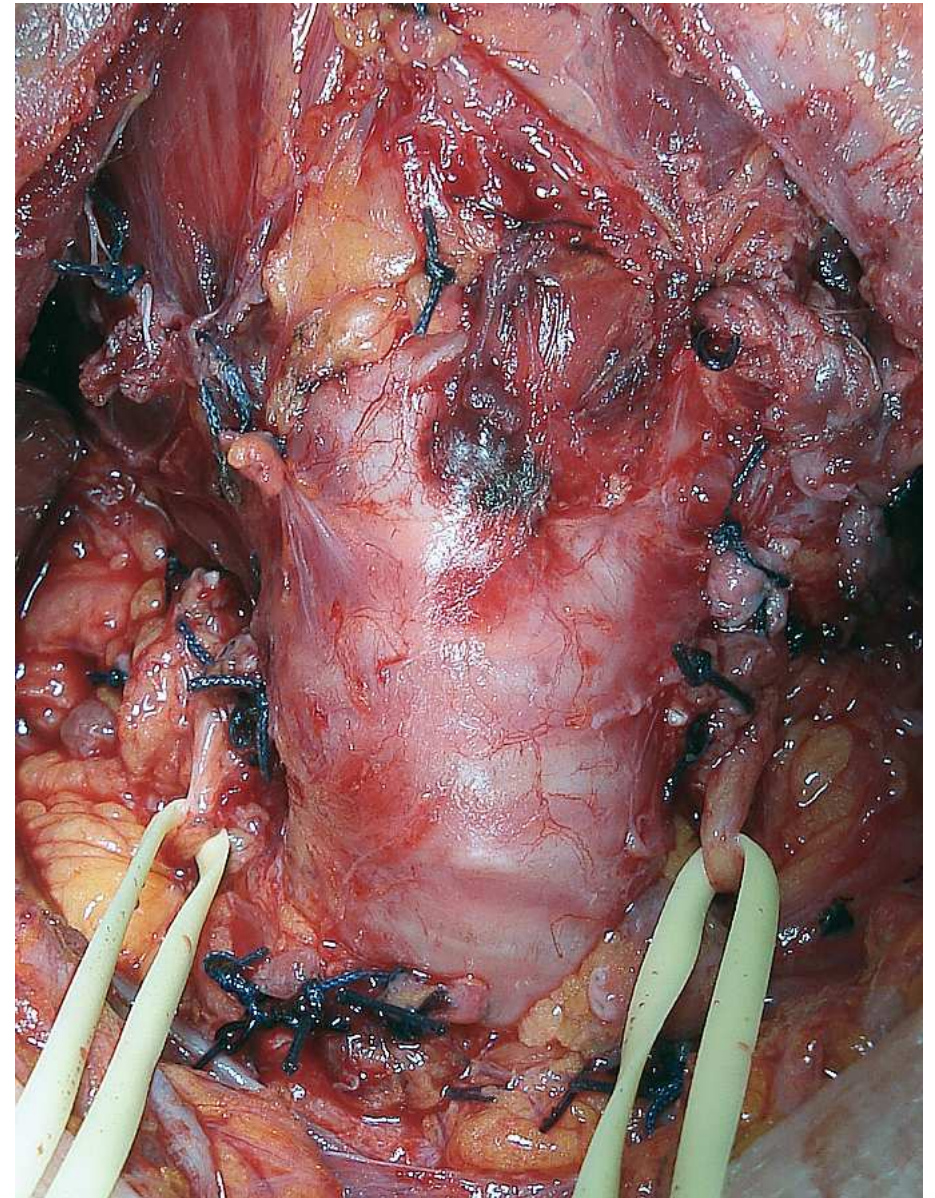


Lobo sinistro - Istmo - Lobo destro (superficie posteriore)

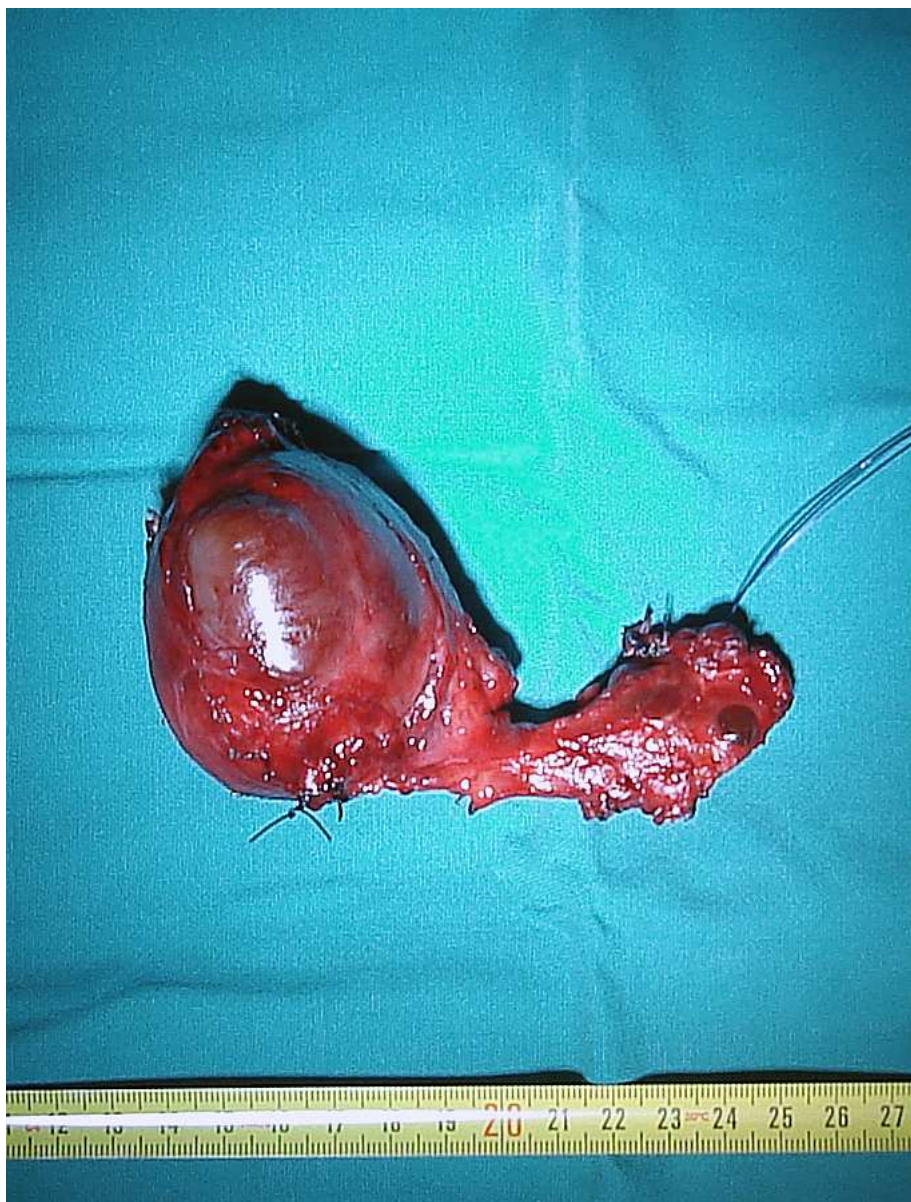


V.A. • Anni: 62 - M • Record: 48 • 12-03-2009

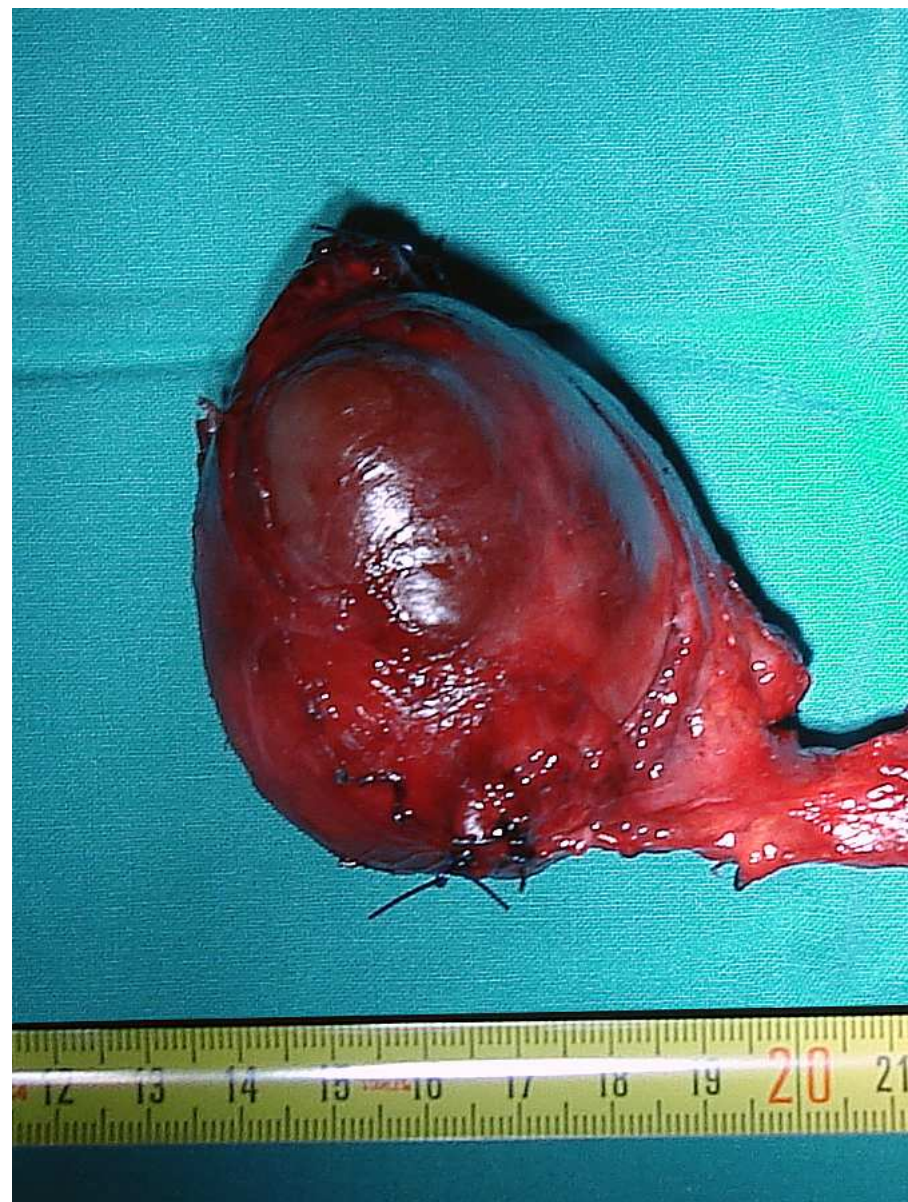Tiroidectomia totale extracapsulare per gozzo plurinodulare plongeant a sn



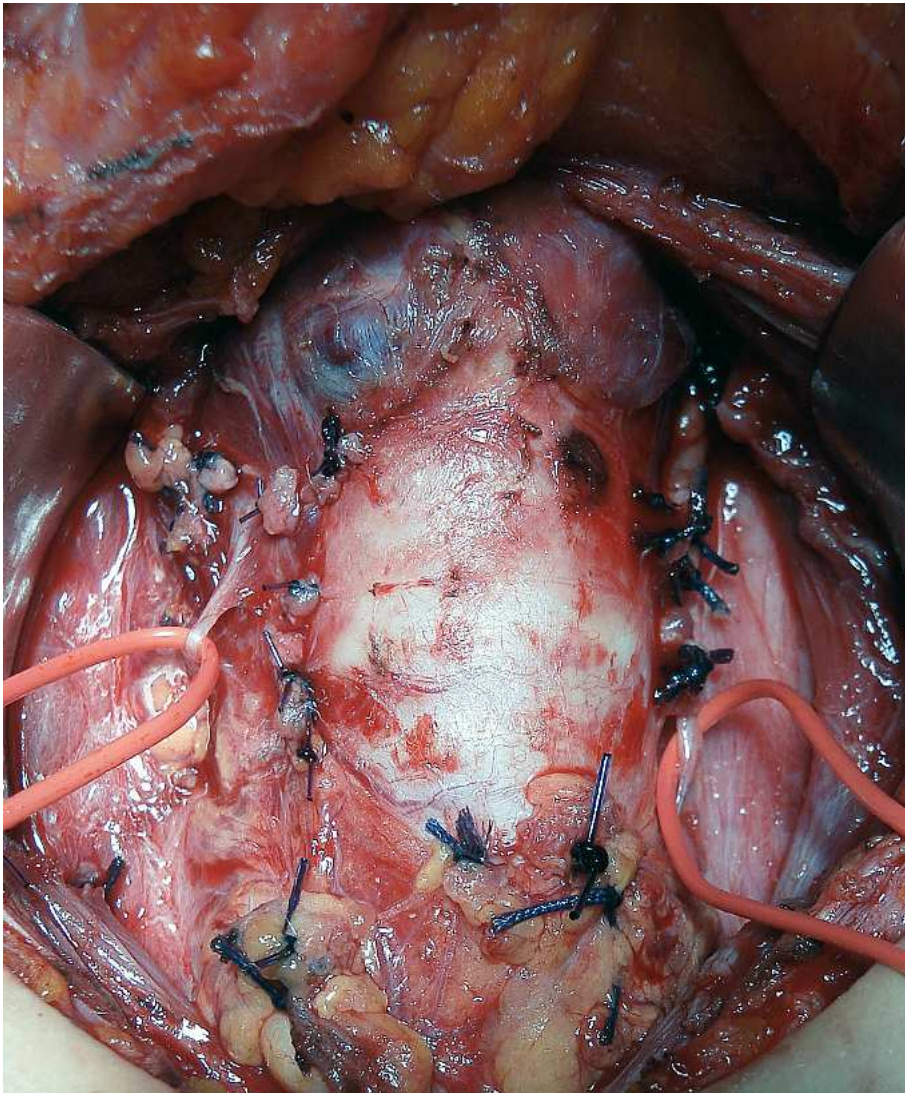
Isolamento dei nervi laringei inferiori (ricorrenti)



Lobo sinistro - Istmo - Lobo destro (superficie posteriore)

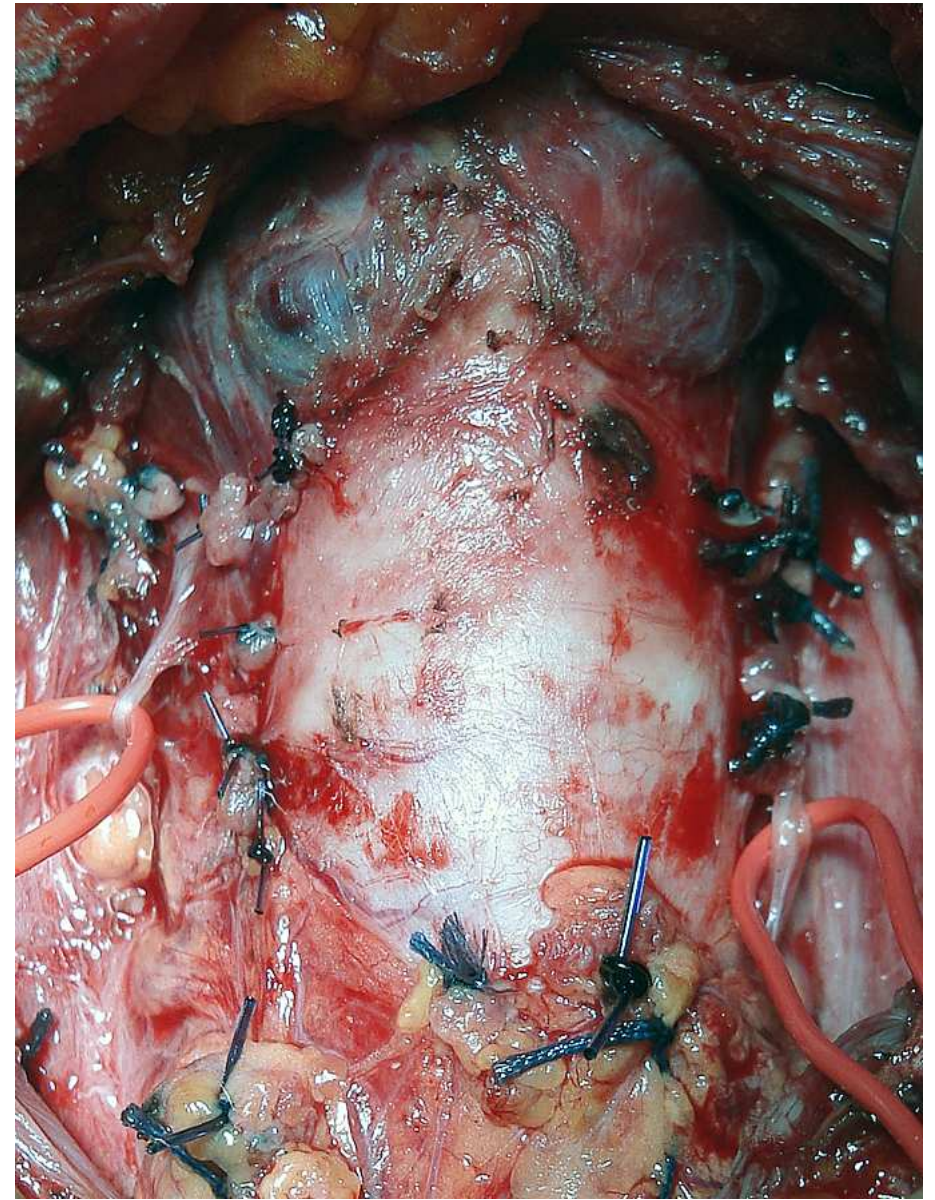


Lobo sinistro (superficie posteriore)

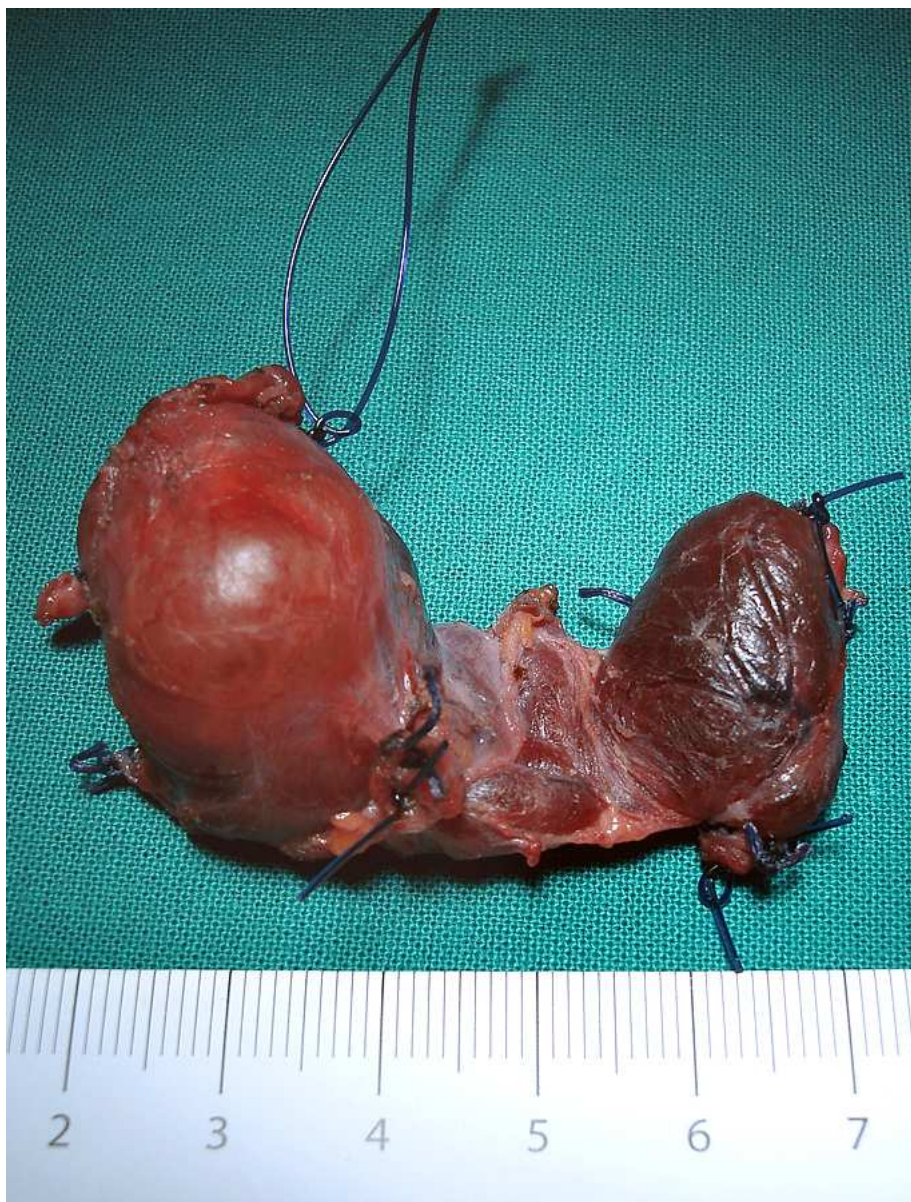

I.R. • Anni: 24 - F • Record: 49 • 23-03-2009

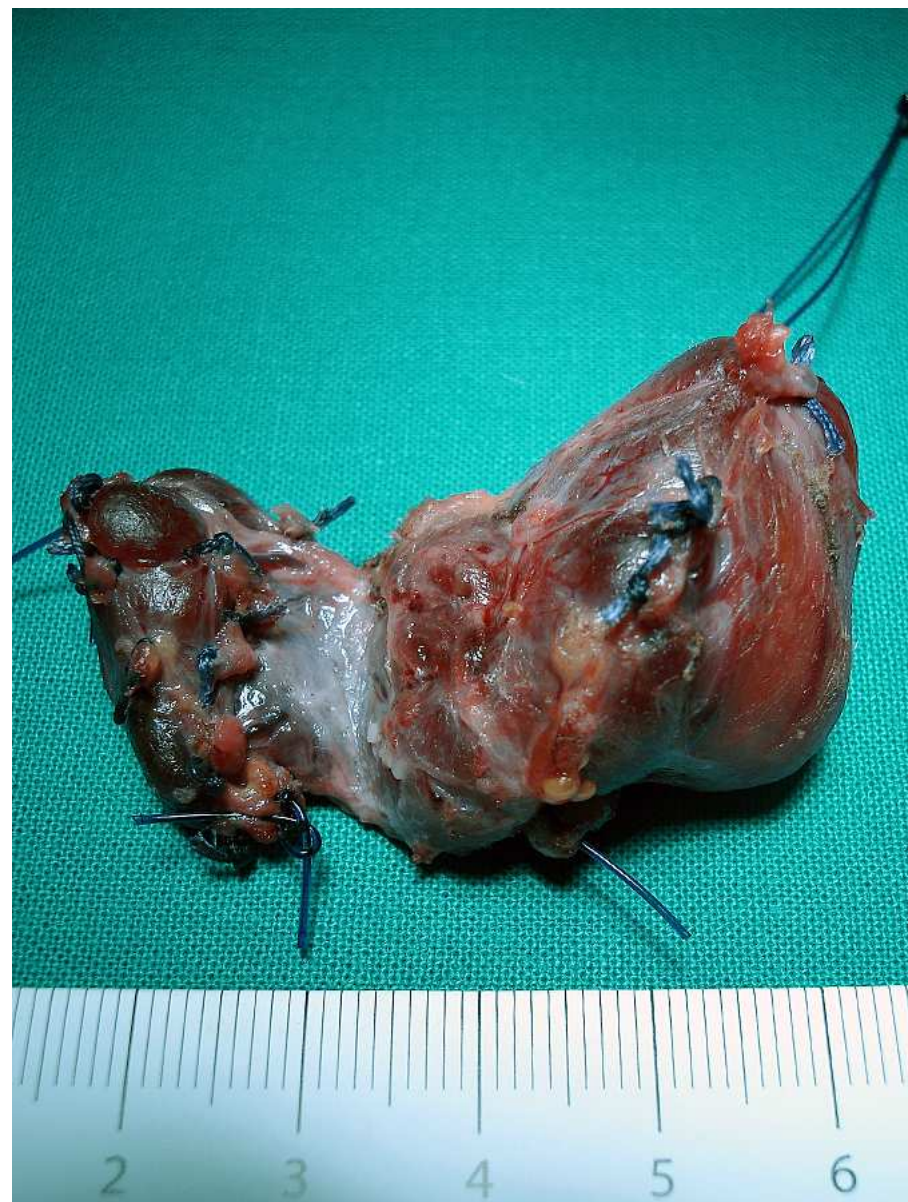
Tiroidectomia totale extracapsulare per gozzo nodulare pretossico a dx



Isolamento dei nervi laringei inferiori (ricorrenti)

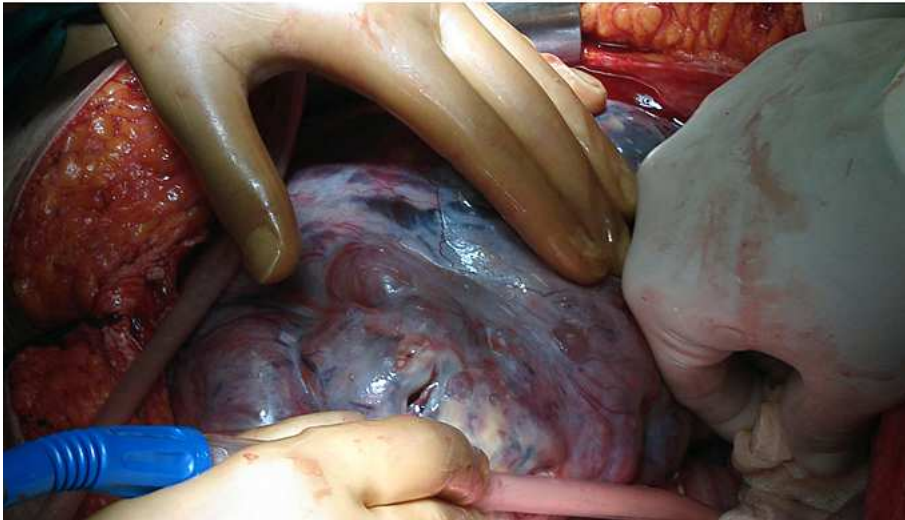
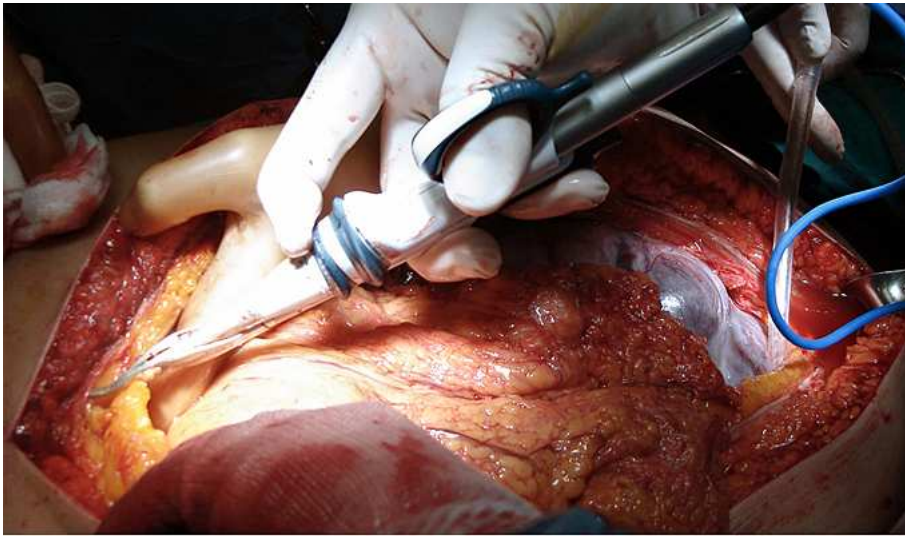


Lobo destro - Istmo - Lobo sinistro (superficie anteriore)



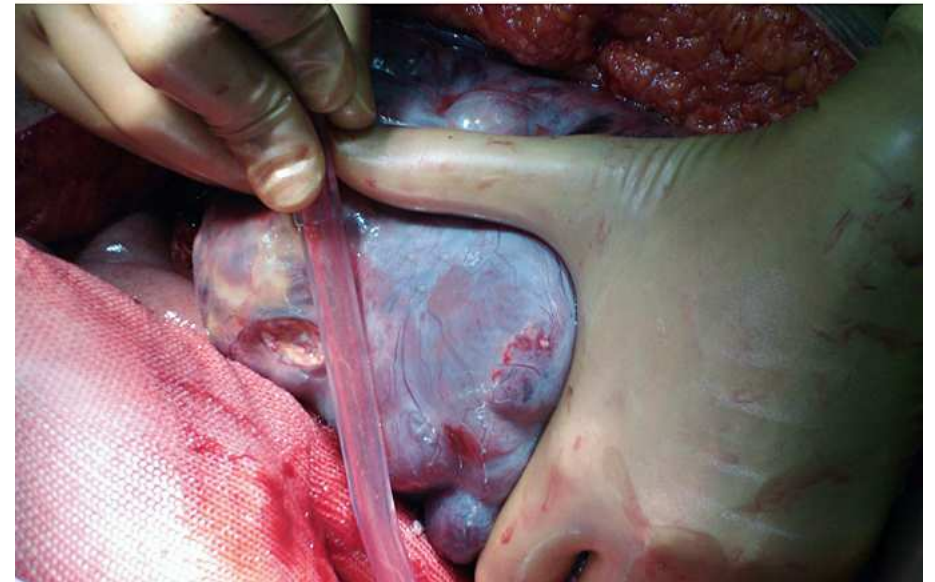
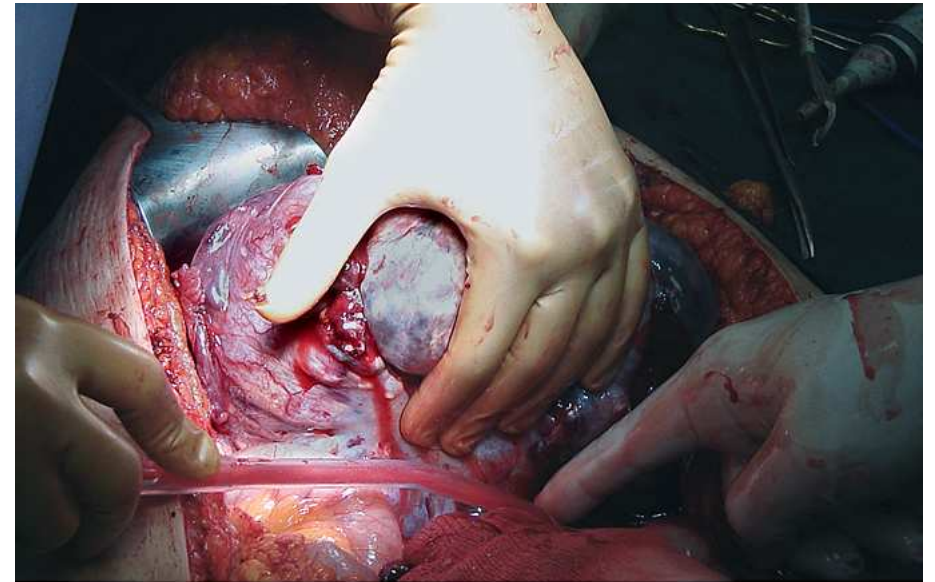
Lobo sinistro - Istmo - Lobo destro (superficie posteriore)

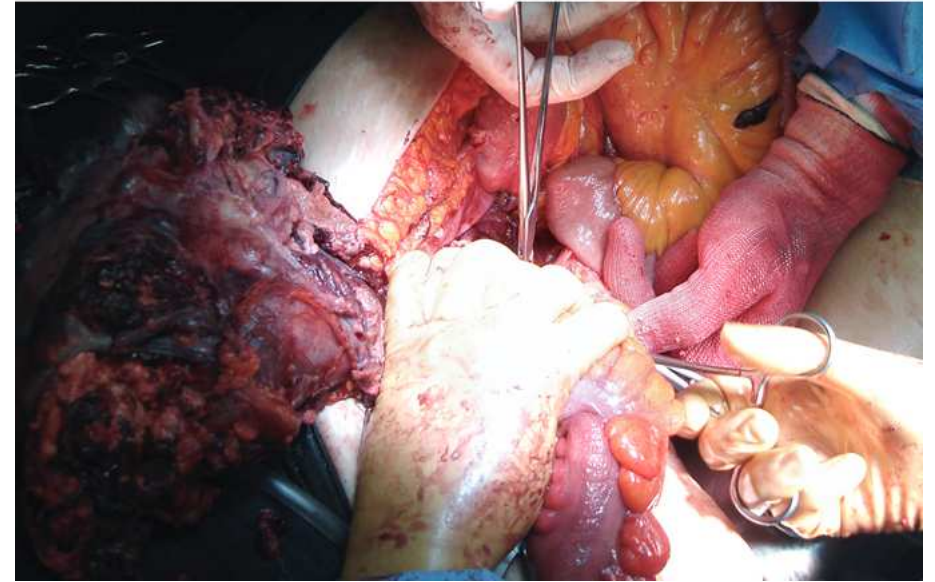
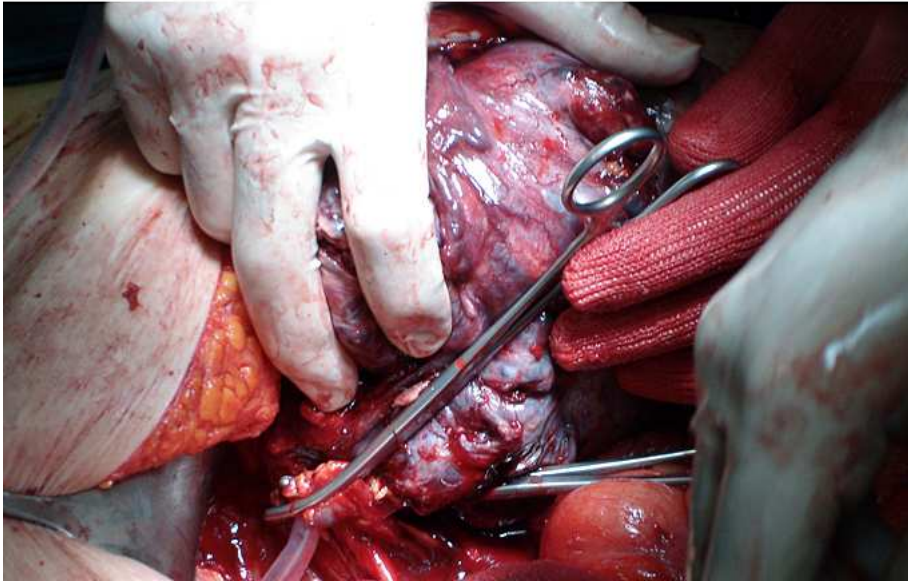
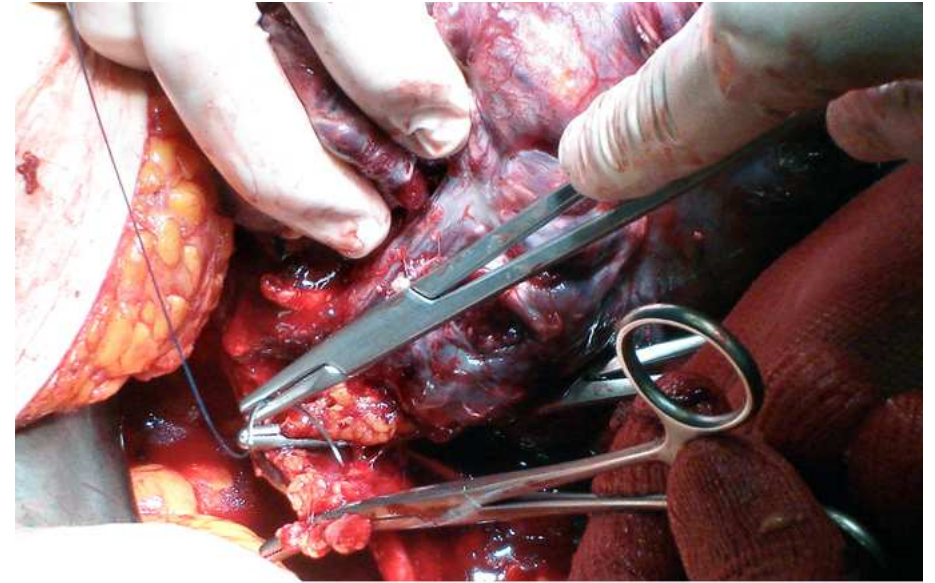
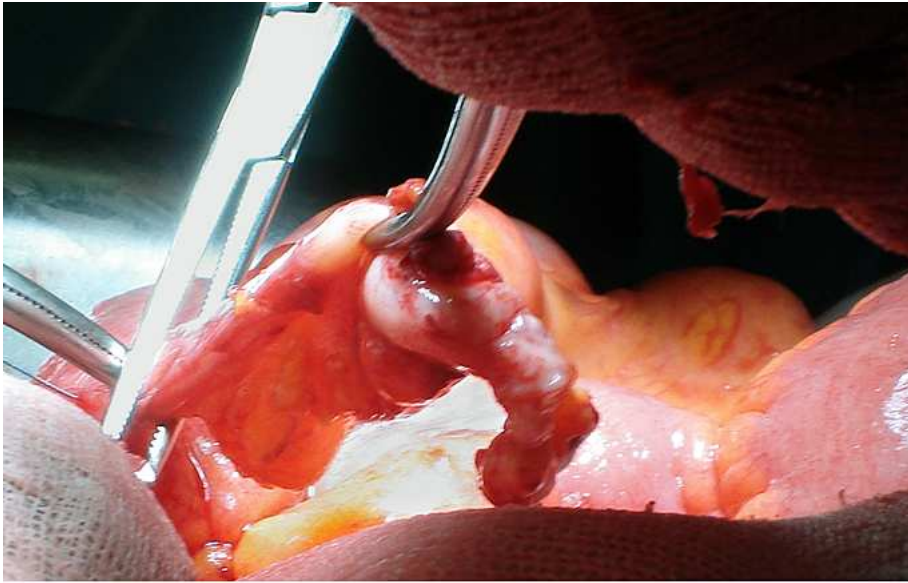


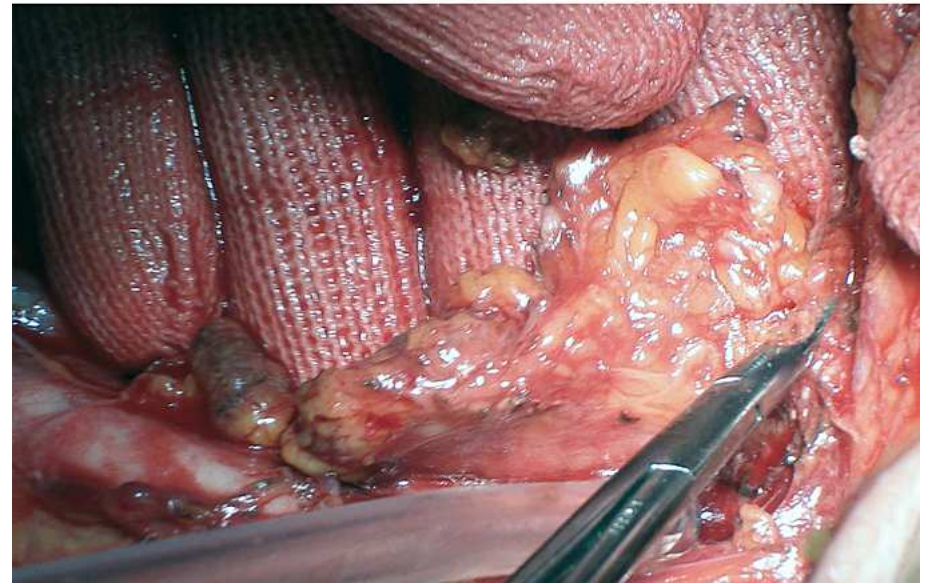
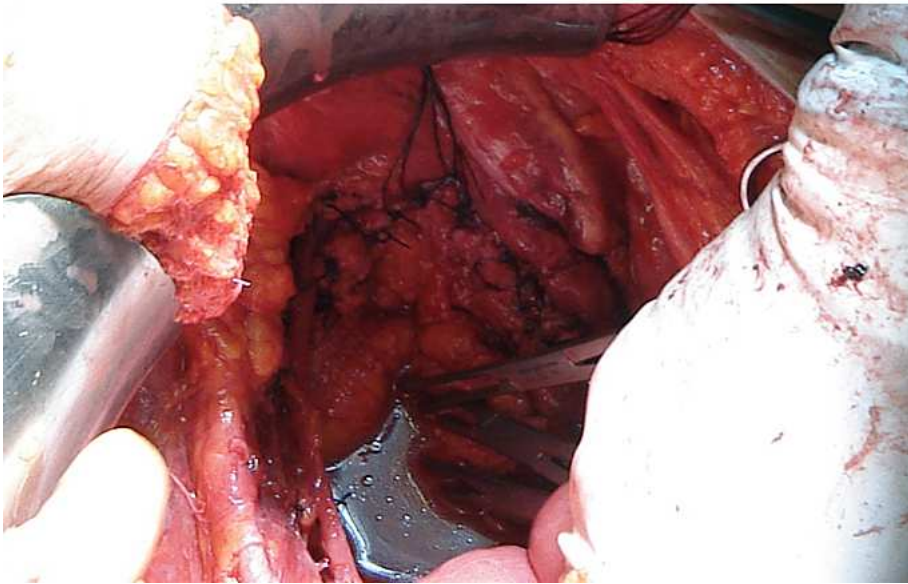
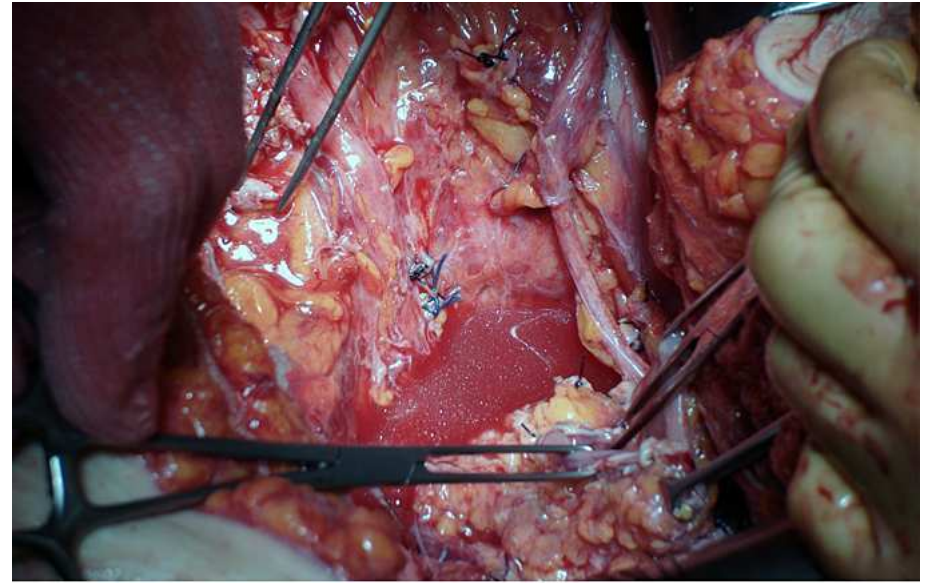
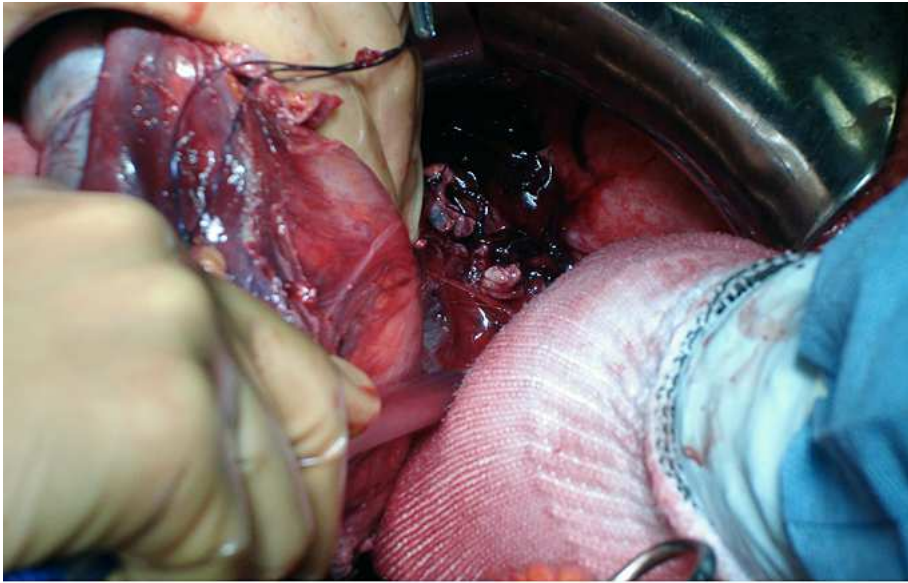


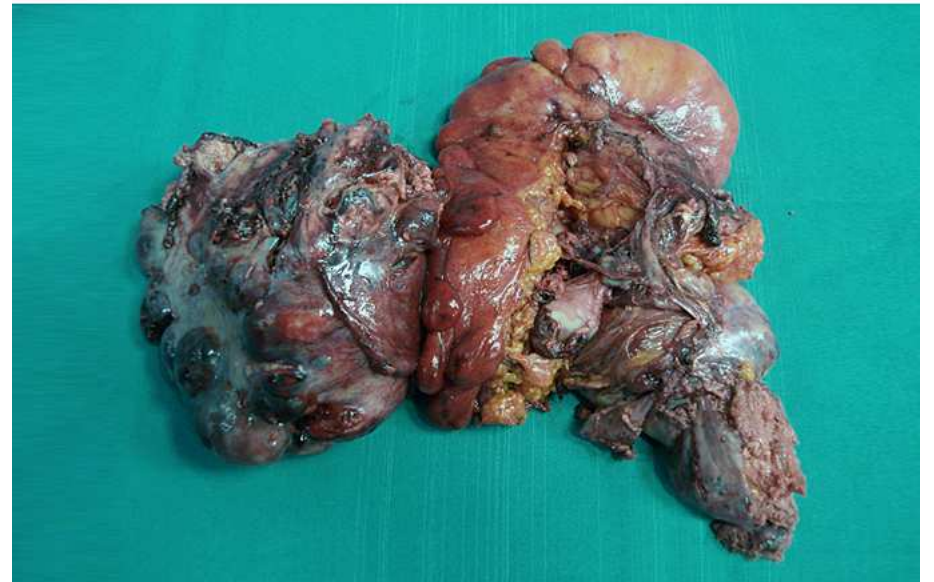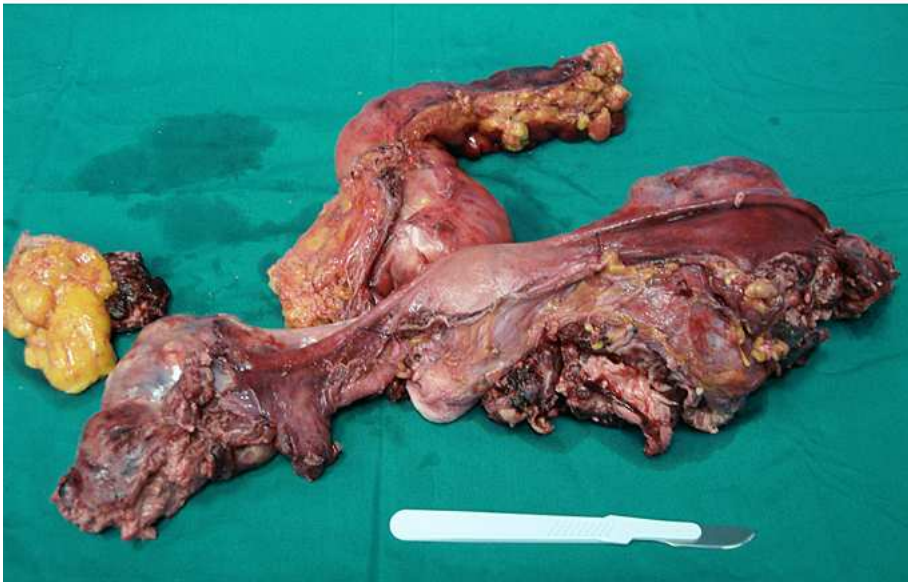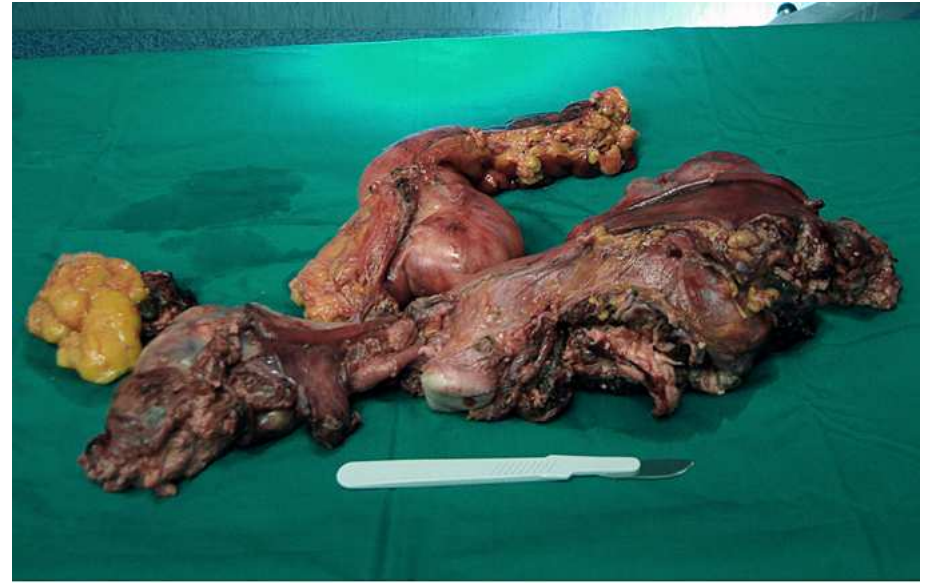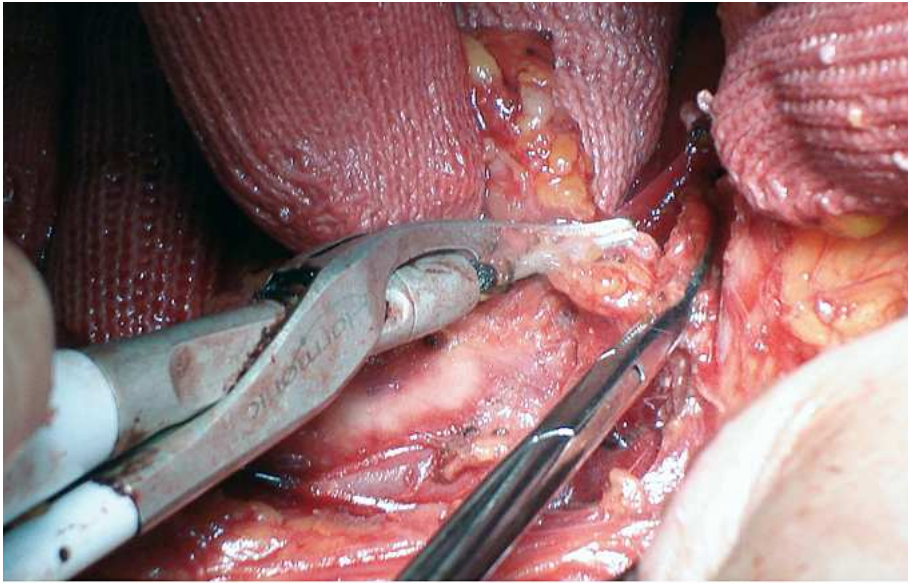
S.O. • Anni: 56 - F • Record: 50 • 03-12-2010

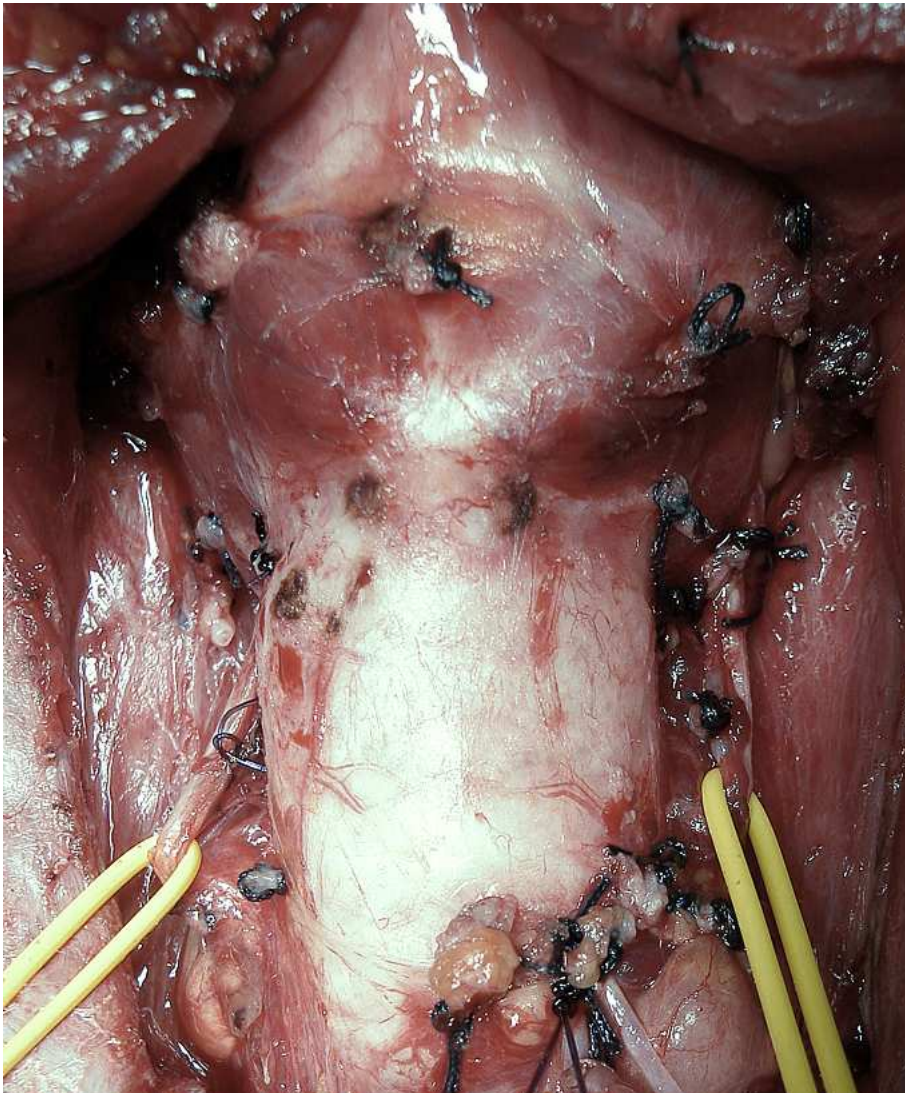
Isteroannessectomia bilaterale con resezione sigmoide-rettale "en bloc" (evisceratio posteriore) con appendicectomia, epiploiectomia e linfadenectomia lombo-aorto-iliaca per neoplasia ovarica bilaterale





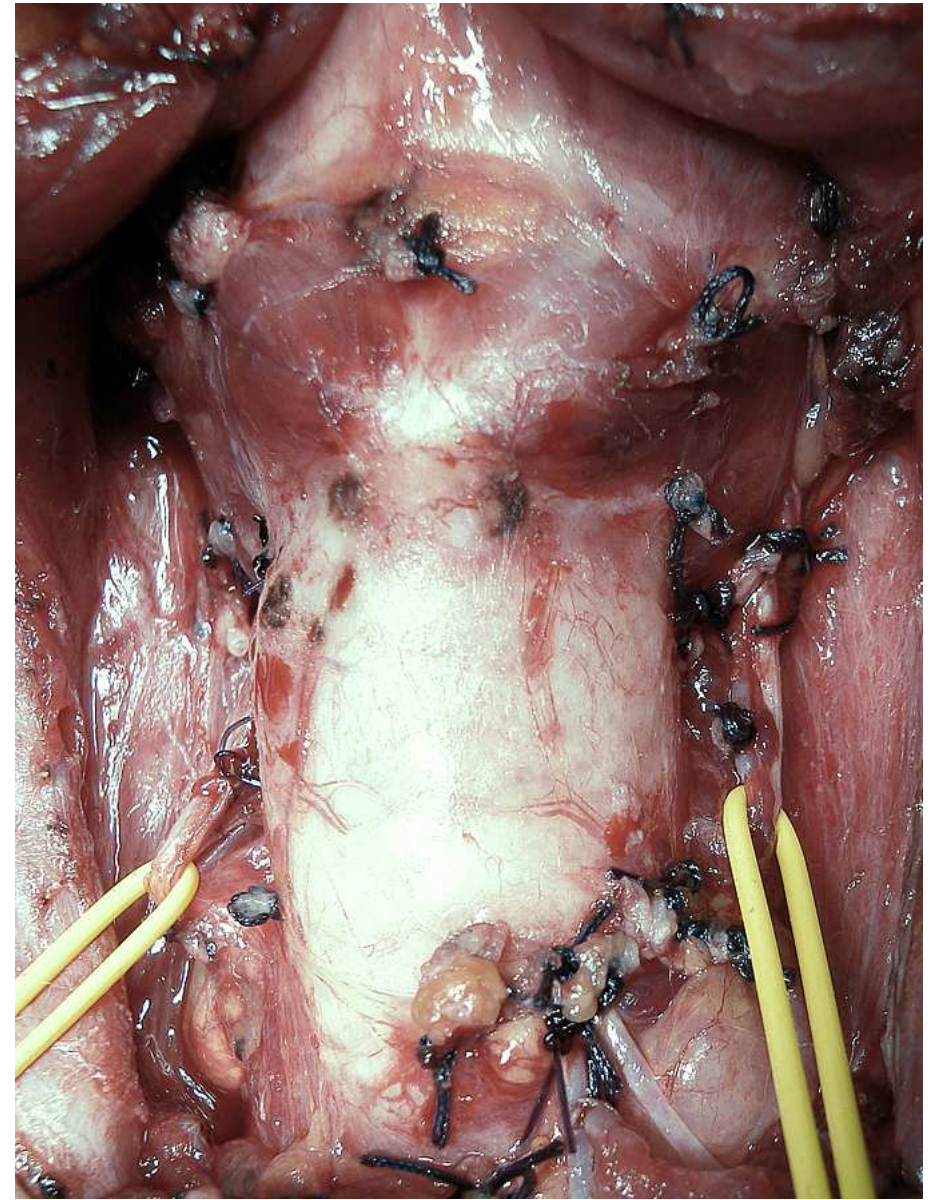




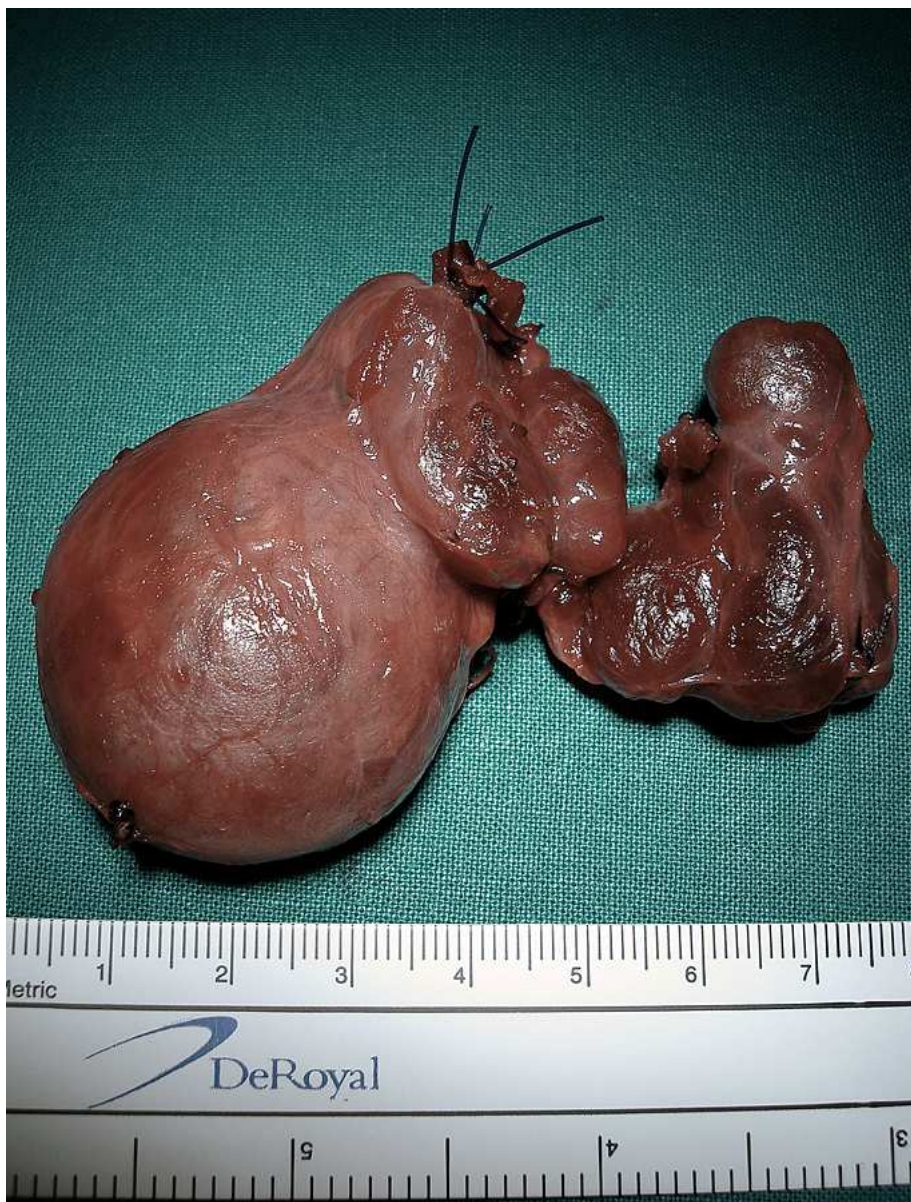


L.A. • Anni: 24 - F • Record: 51 • 05-10-2006

Tiroidectomia totale extracapsulare per adenoma follicolare in gozzo plurinodulare con sezione dei muscoli pretiroidei



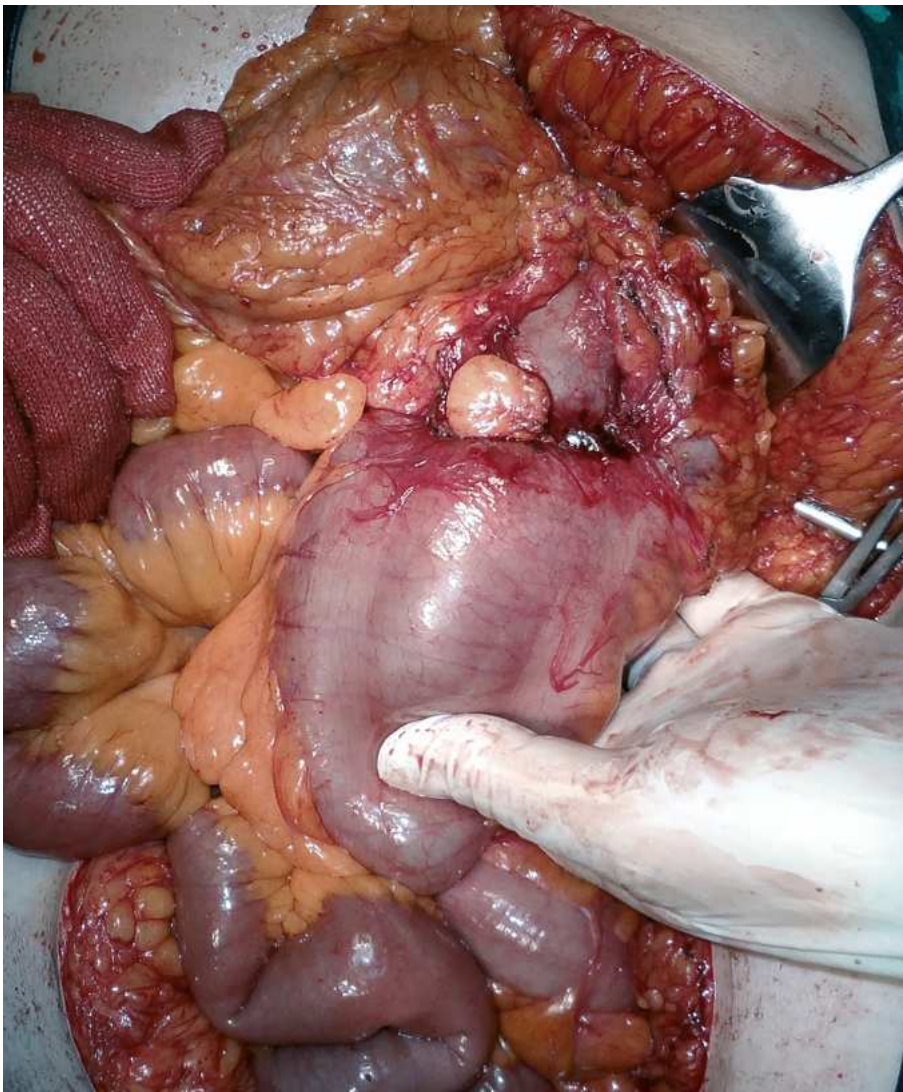
Isolamento dei nervi laringei inferiori (ricorrenti)



Lobo destro - Istmo - Lobo sinistro (superficie anteriore)

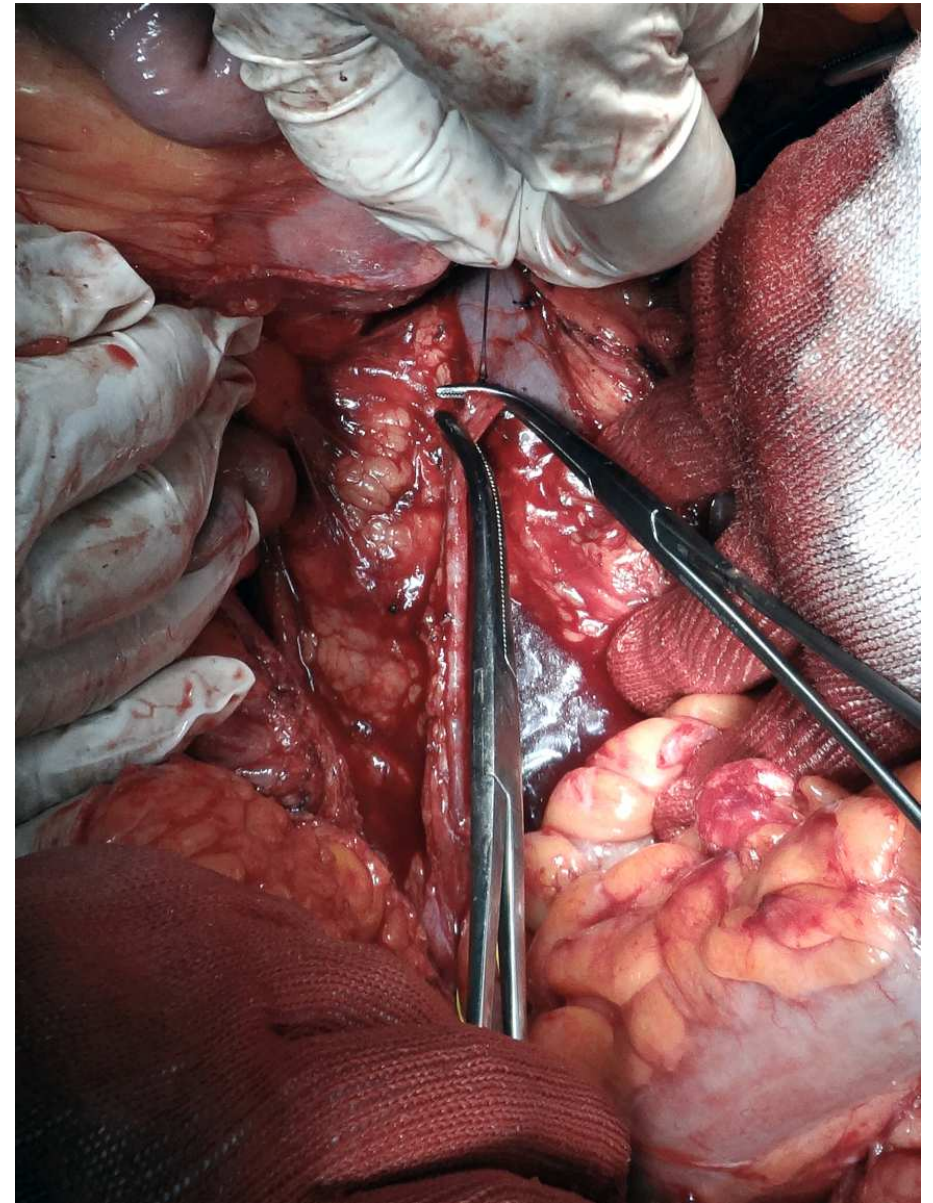


Lobo sinistro - Istmo - Lobo destro (superficie posteriore)

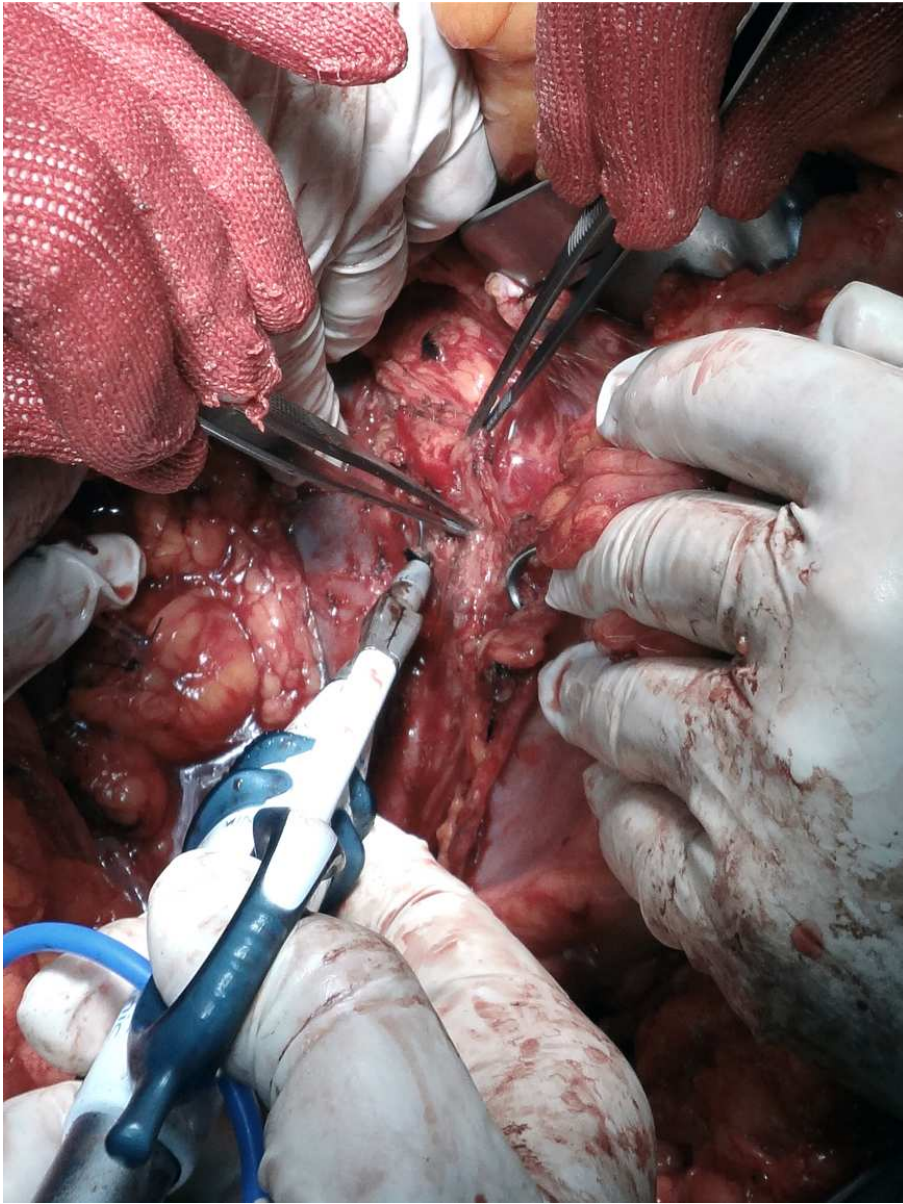


C.L. • Anni: 41 - F • Record: 1 • 20-04-2012

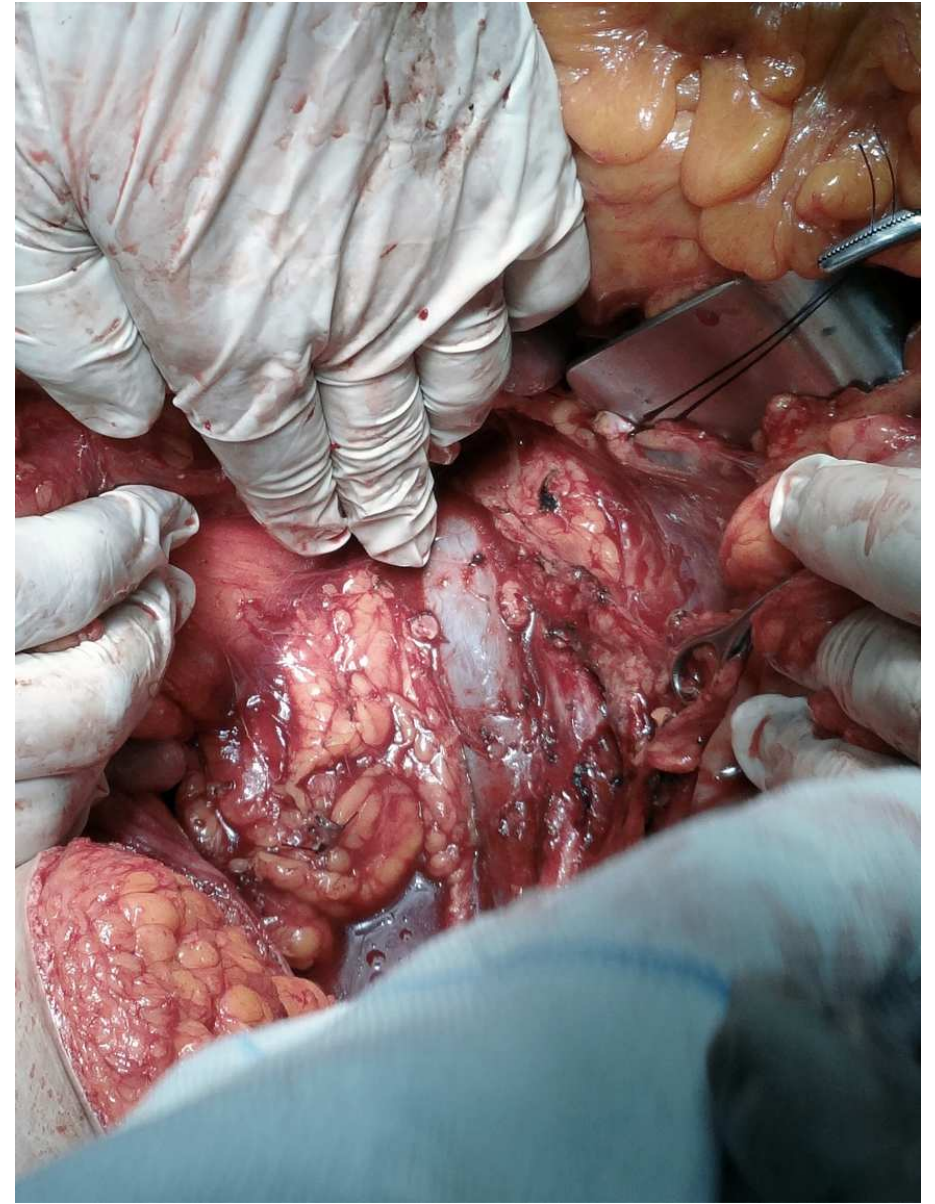
Emicolectomia sn allargata con isteroannessectomia sn, linfadenectomia lombo-aorto-iliaca e presacrale per adenocarcinoma mucinoso in operata di ovariectomia dx con metastasi mesenteriche



Legatura e sezione della vena ovarica dx

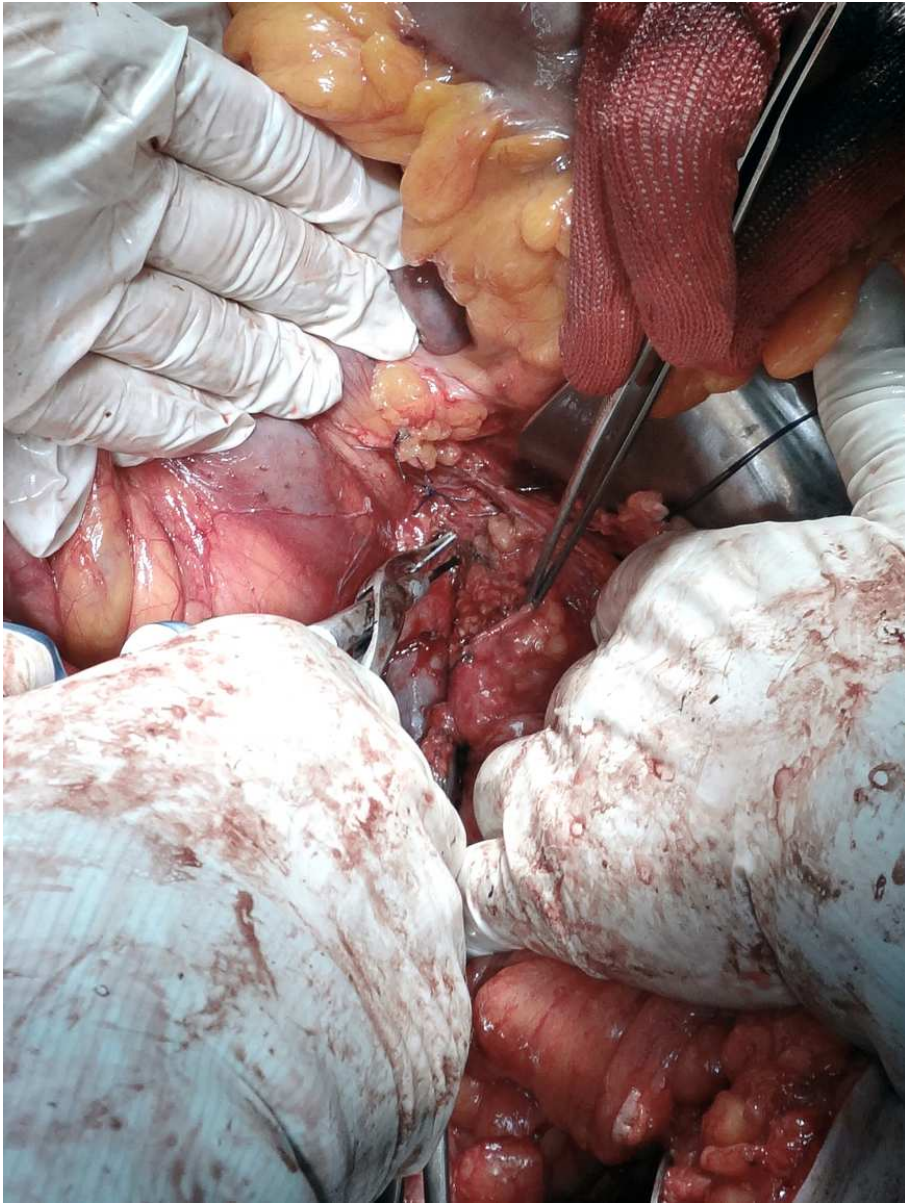


Emicolectomia sn allargata con linfadenectomia lombo-aorto-iliaca "en bloc"

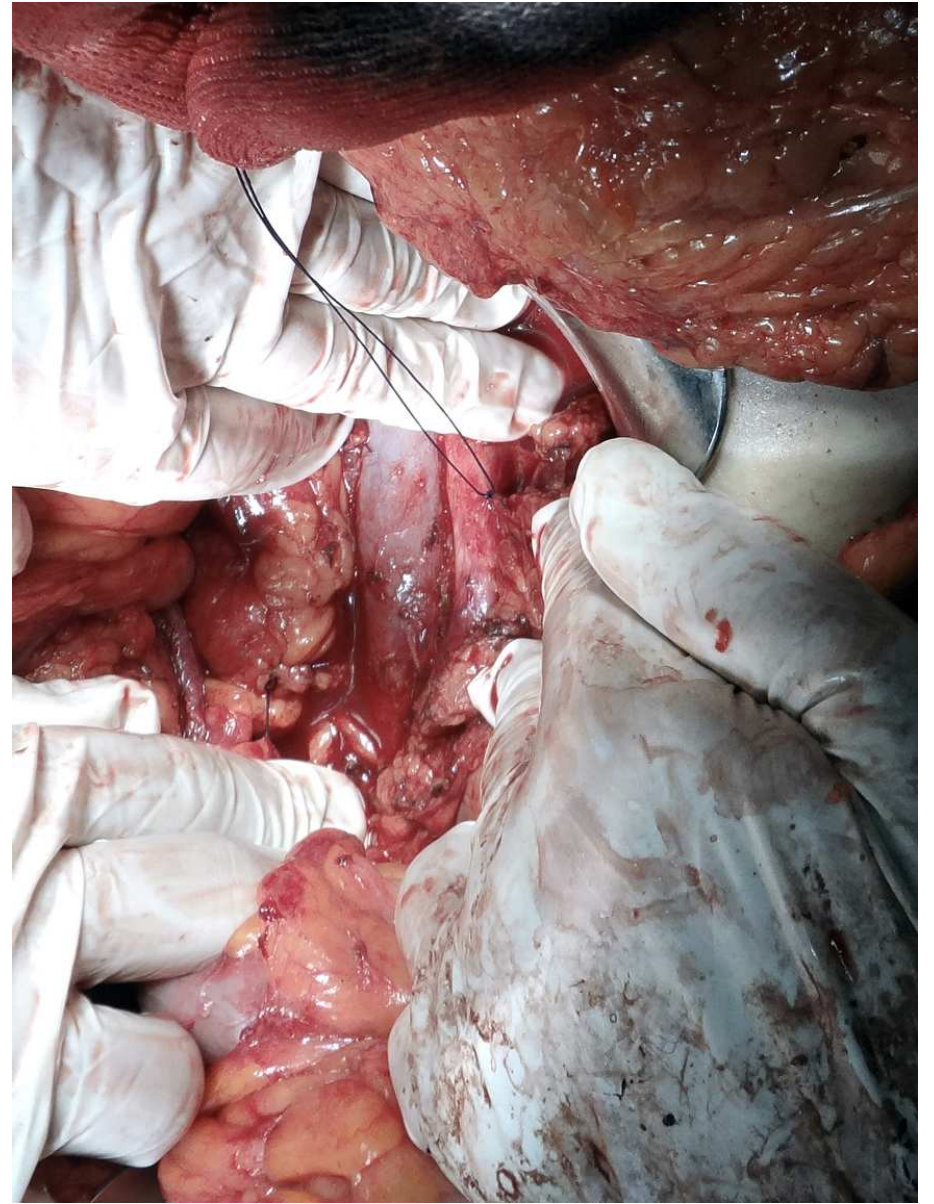


Linfadenectomia lombo-aorto-iliaca

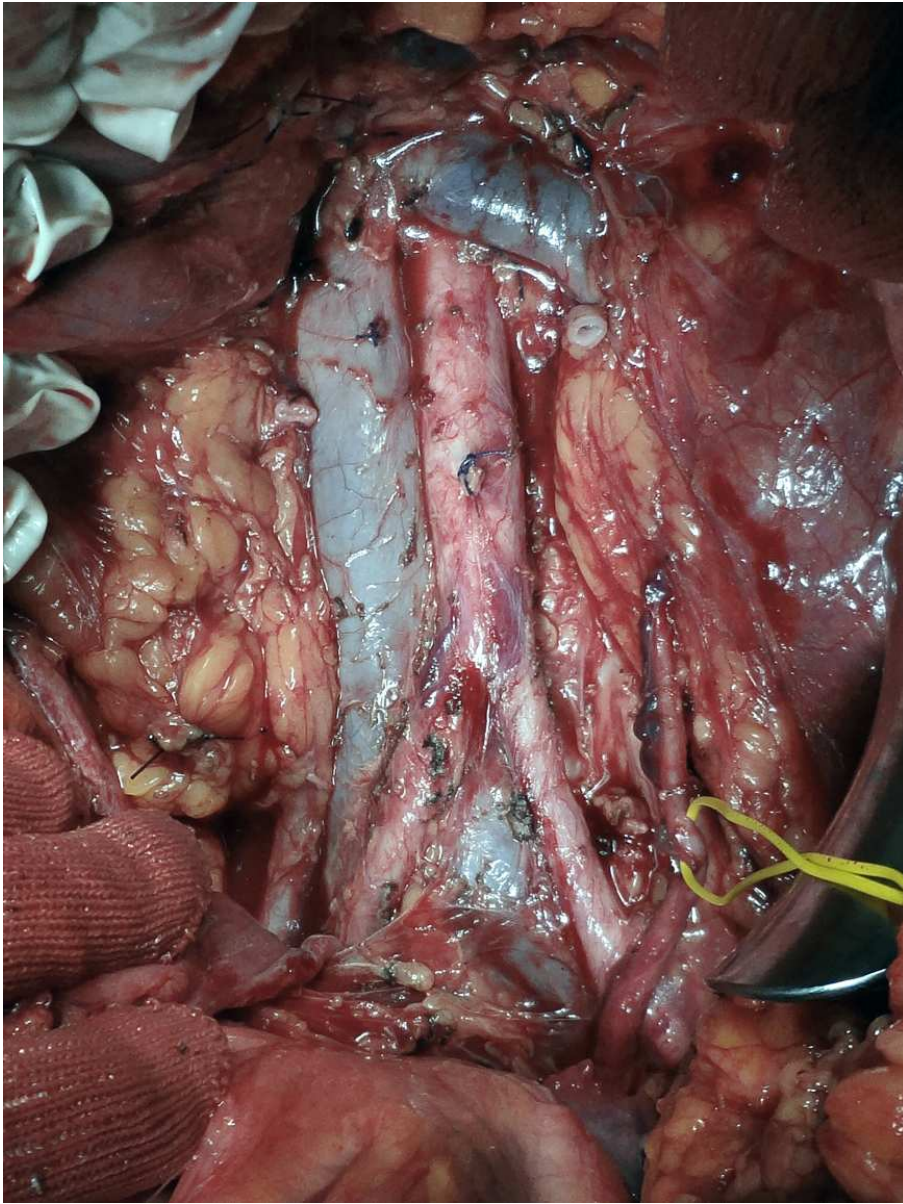




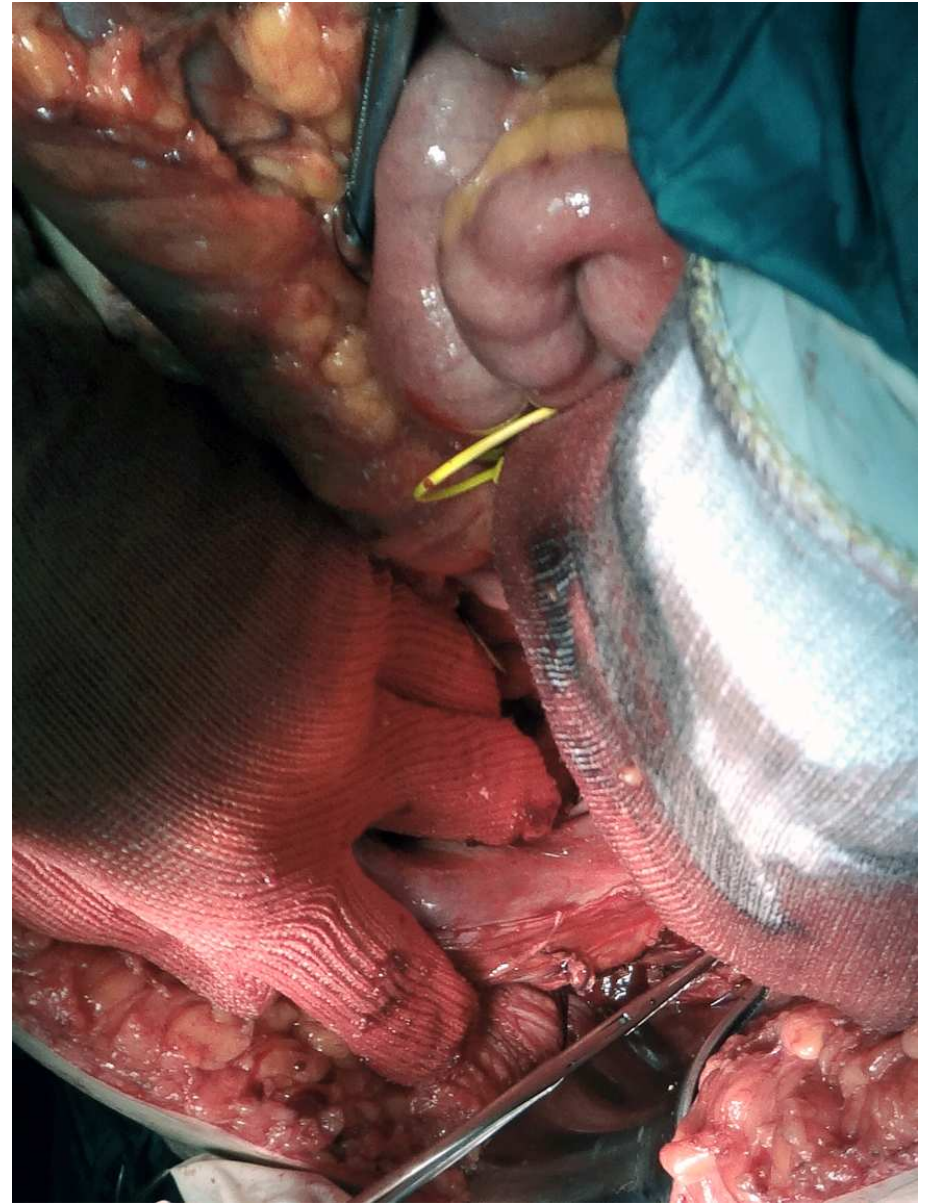
Linfadenectomia lombo-aorto-iliaca



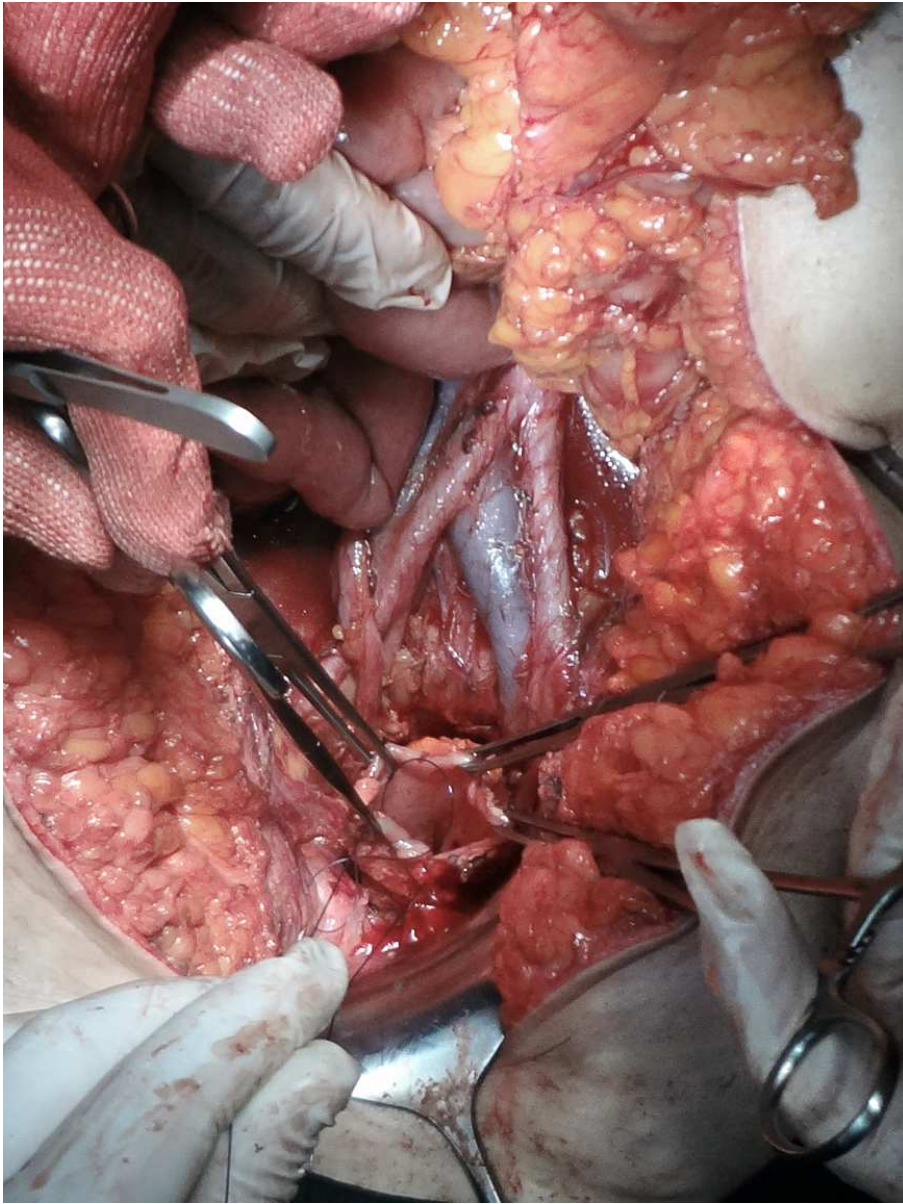
Legatura e sezione dell'arteria mesenterica inferiore



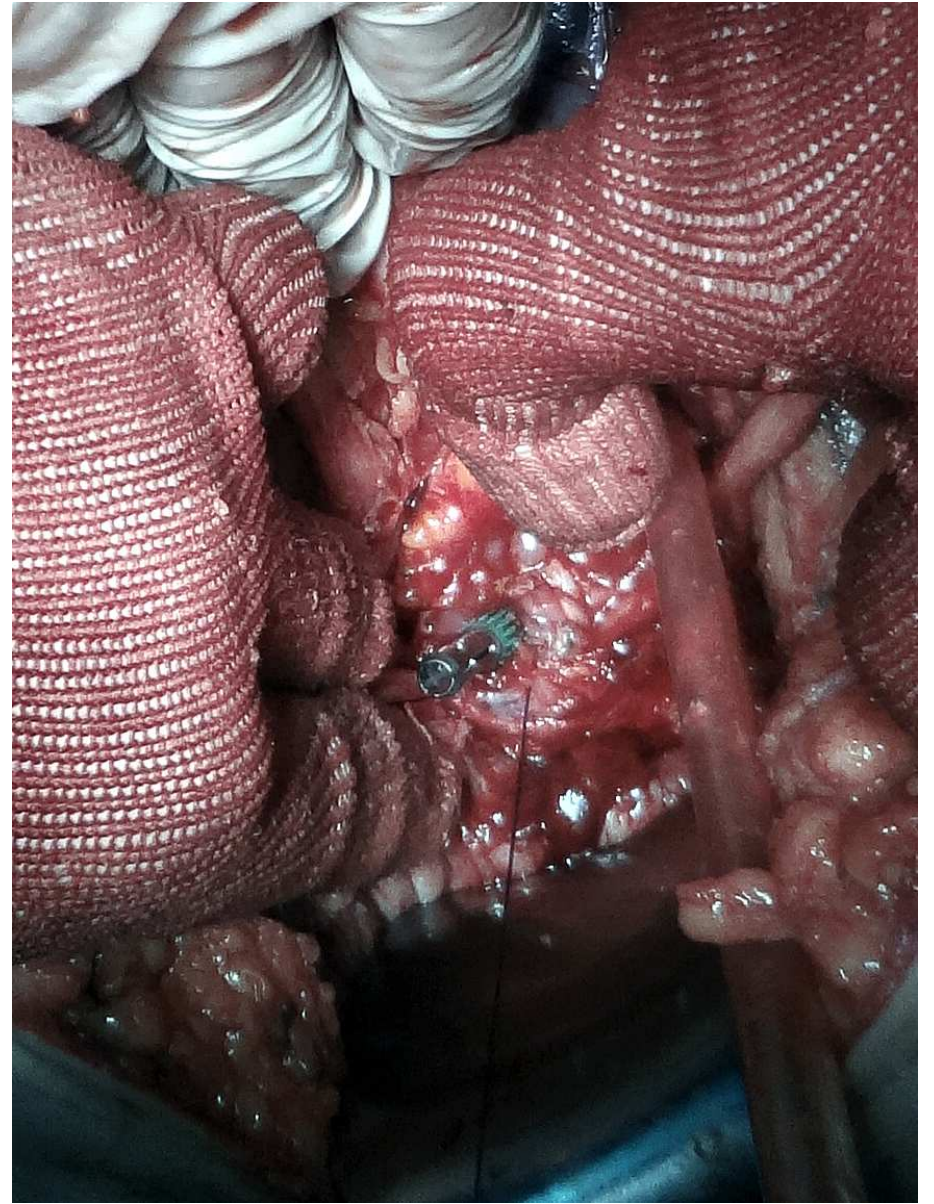Linfadenectomia lombo-aorto-iliaca, intercavaoortica e presacrale completata



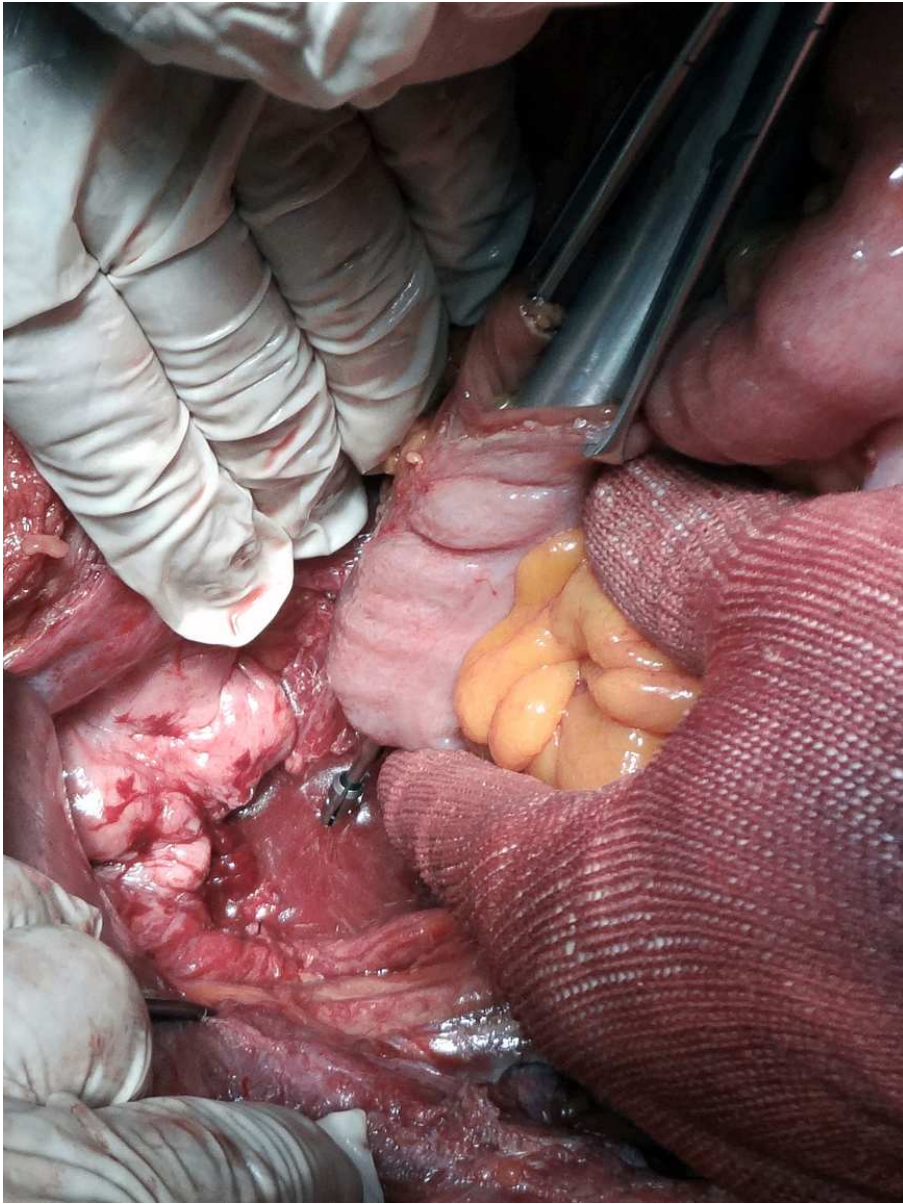
Istero-annessectomia sn



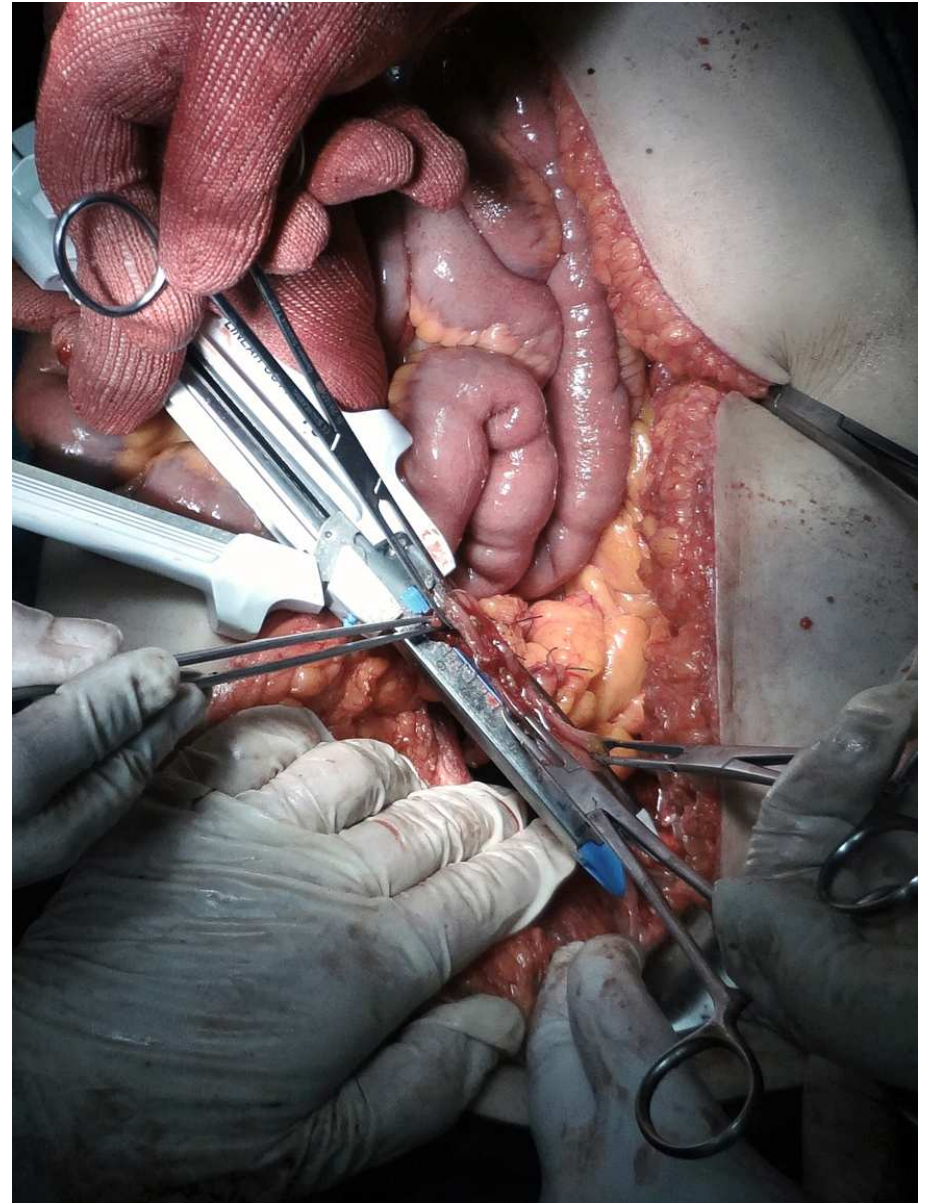
Preparazione del moncone rettale



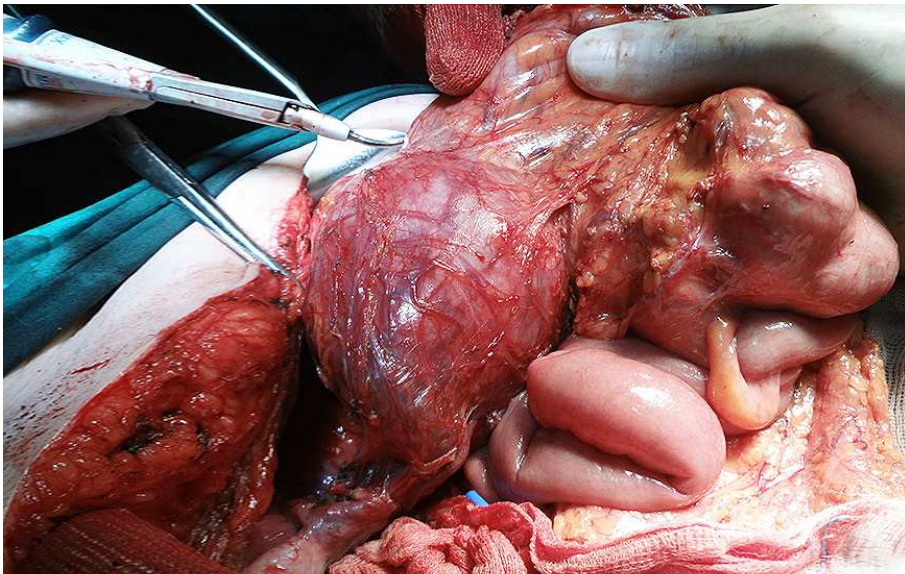
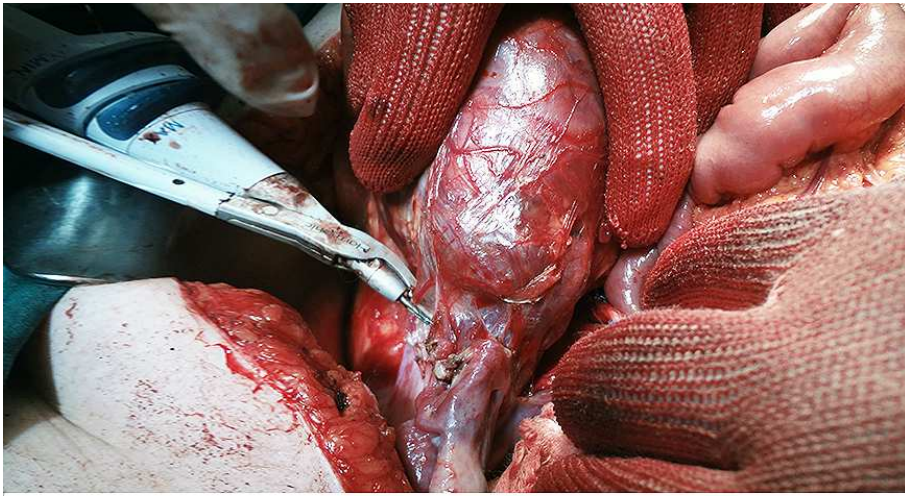
Preparazione del moncone rettale



Anastomosi trasverso-rettale

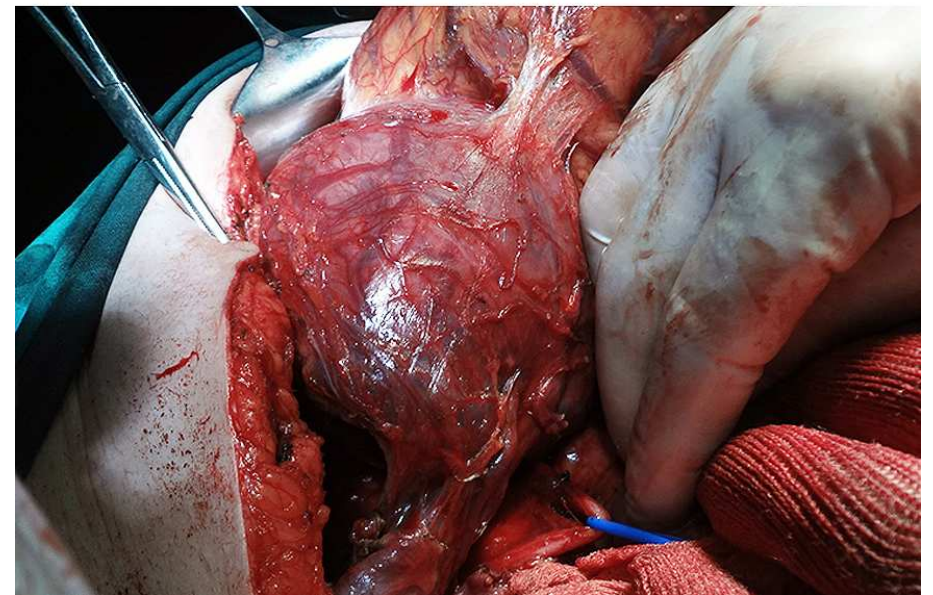
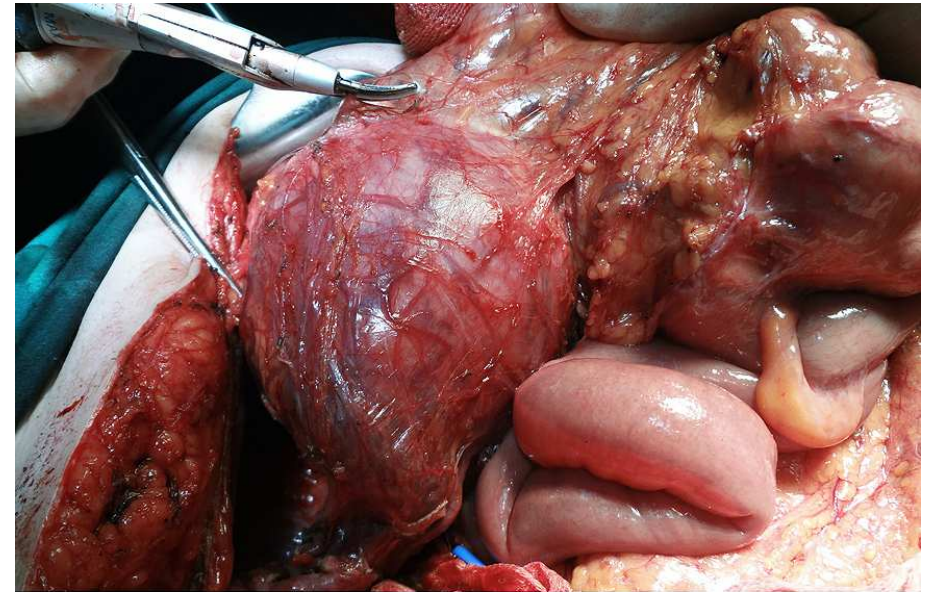


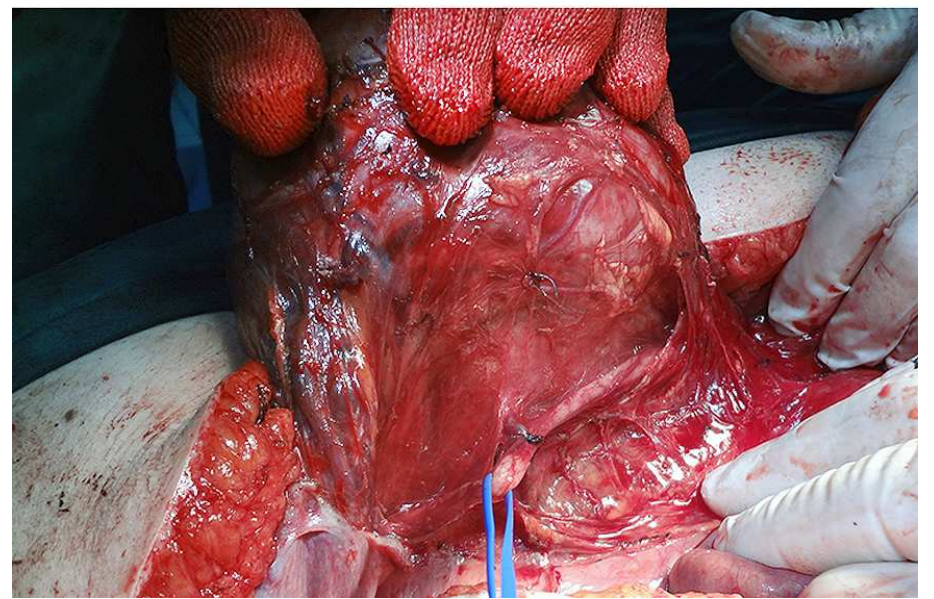
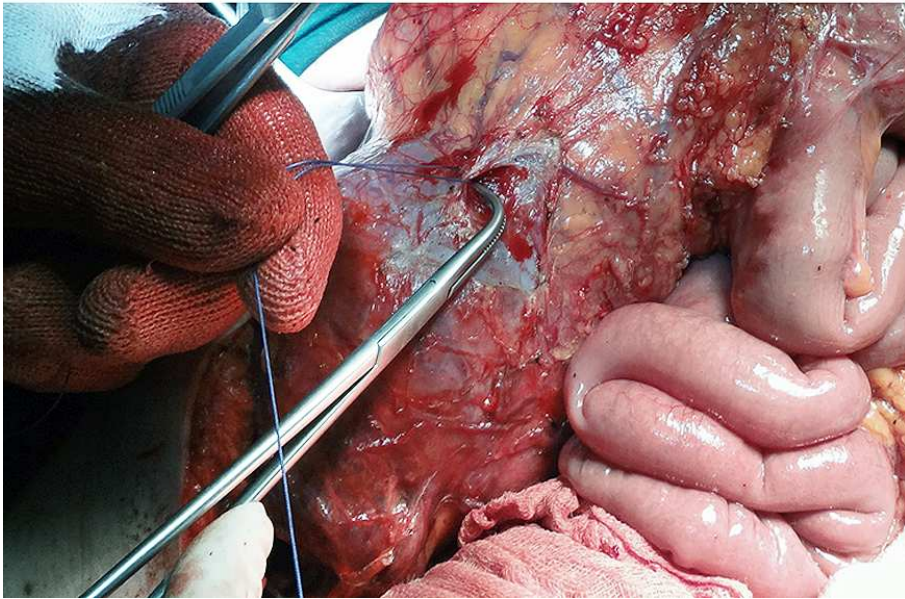
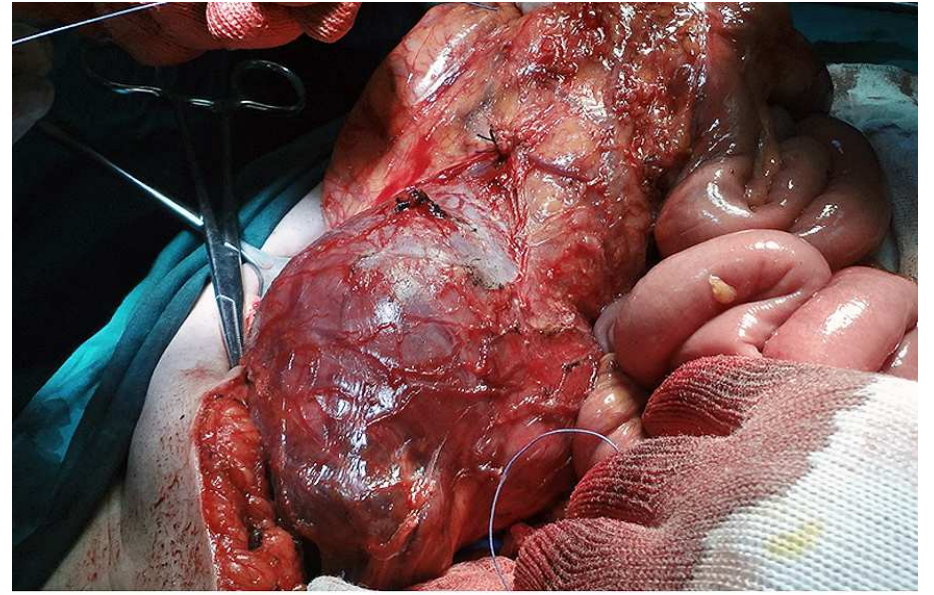
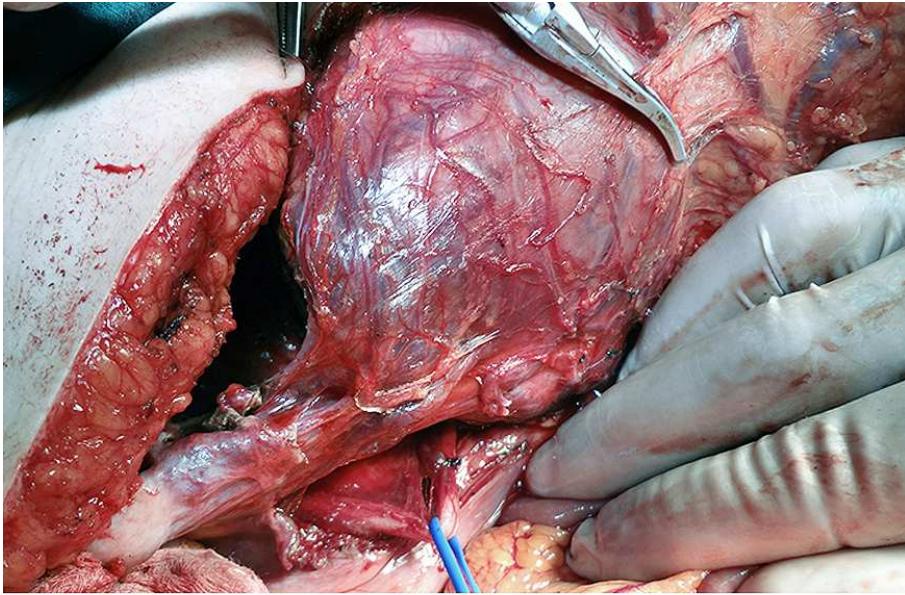
Sutura del fondo cieco del trasverso

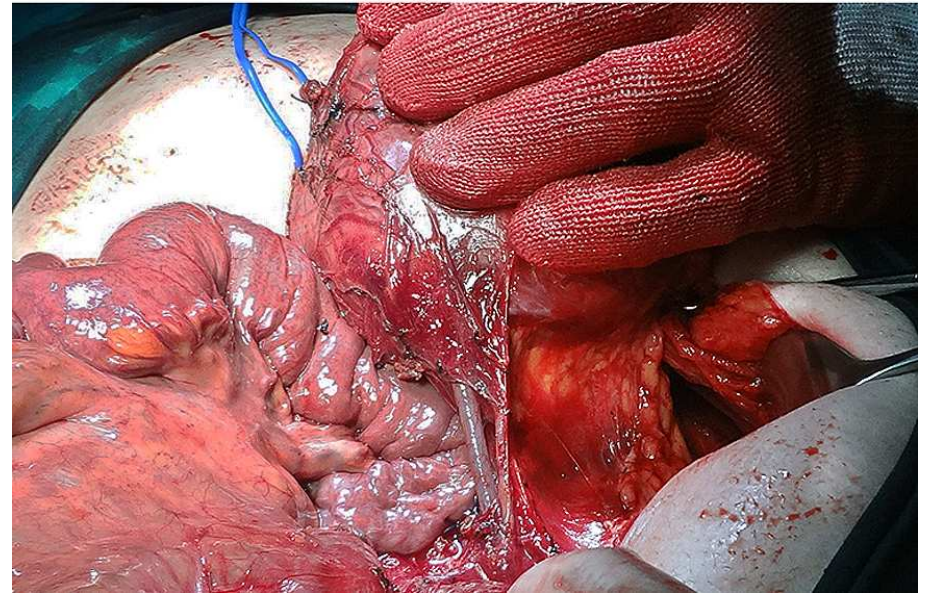
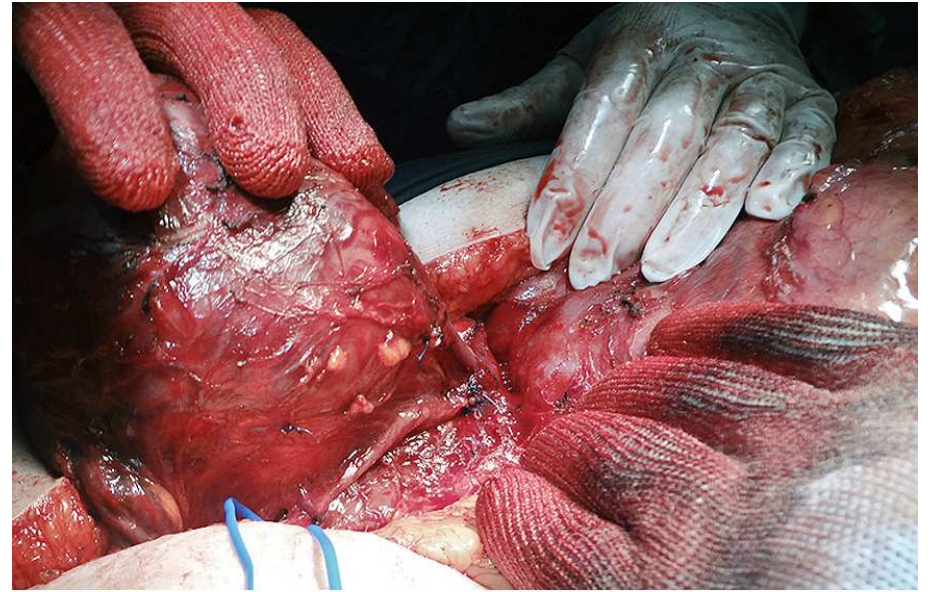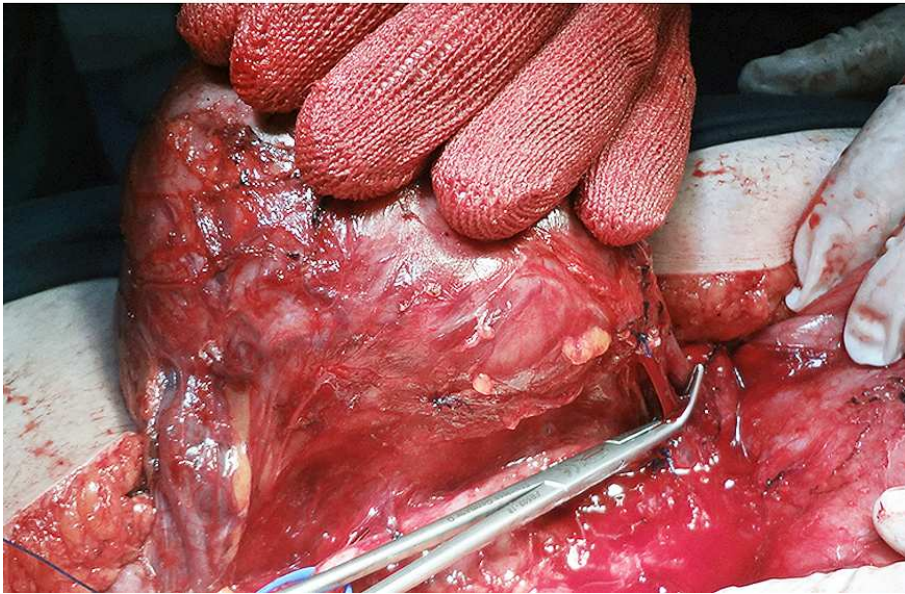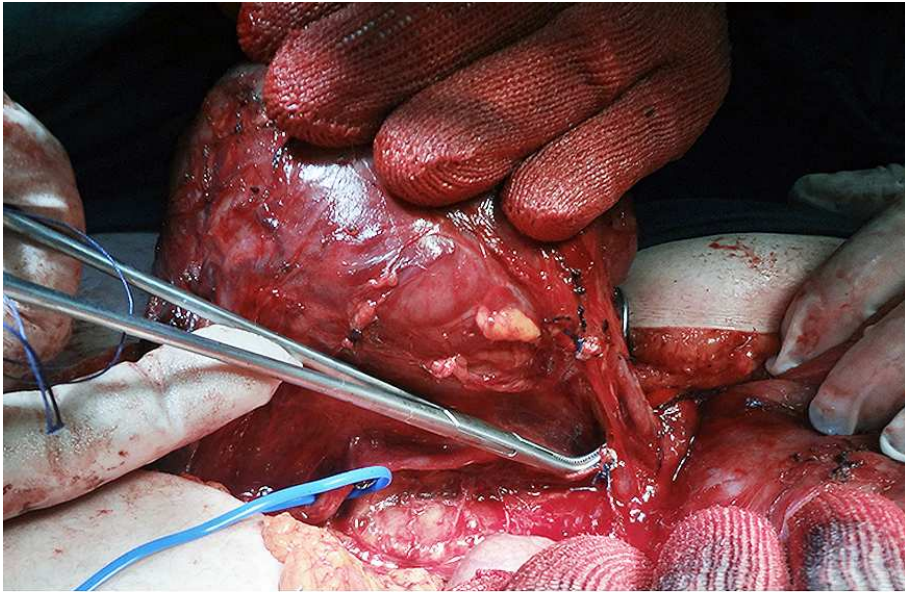


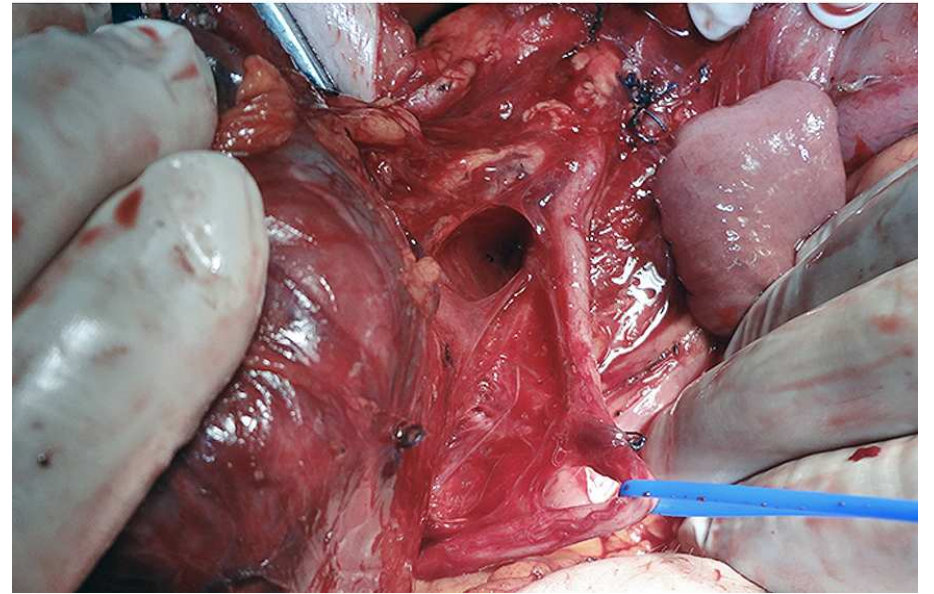
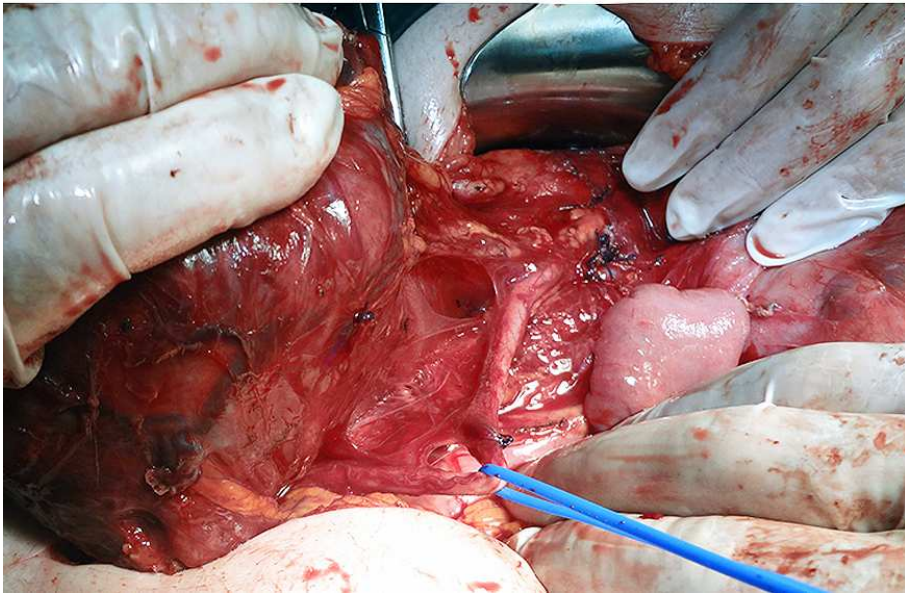
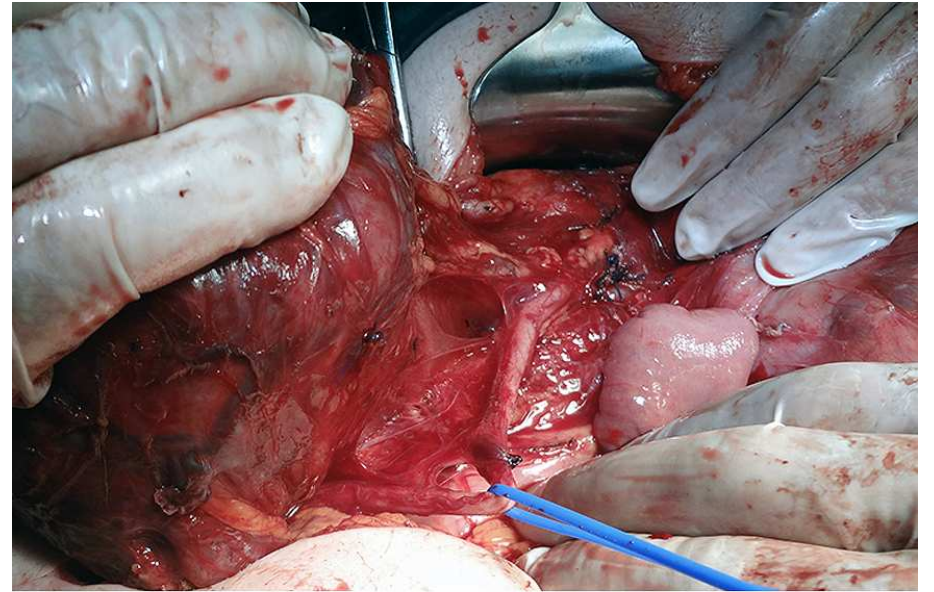
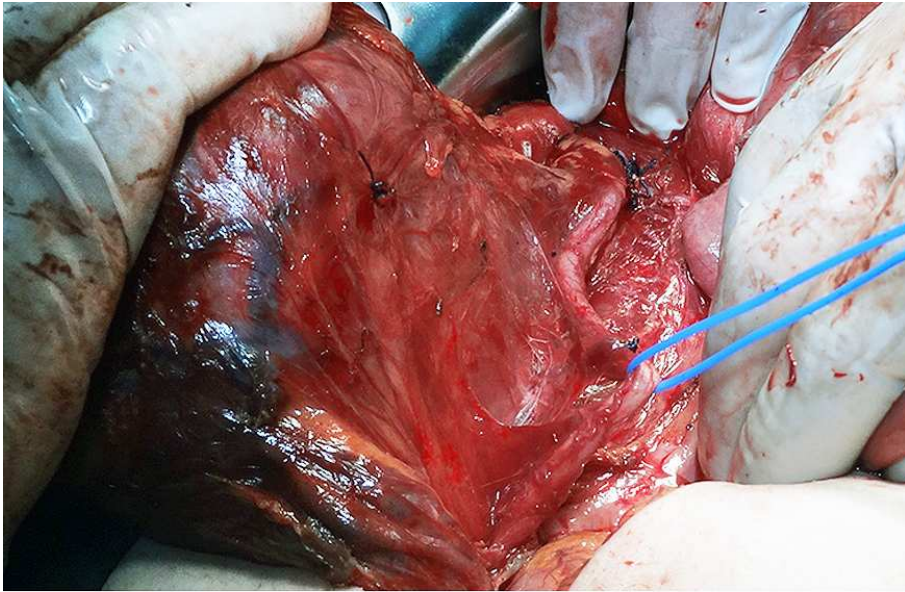
C.A. • Anni: 41 - F • Record: 2 • 08-03-2013

Enucleazione fibro-sarcoma retroperitoneale della doccia parieto-colica dx con annessectomia omolaterale "en bloc"

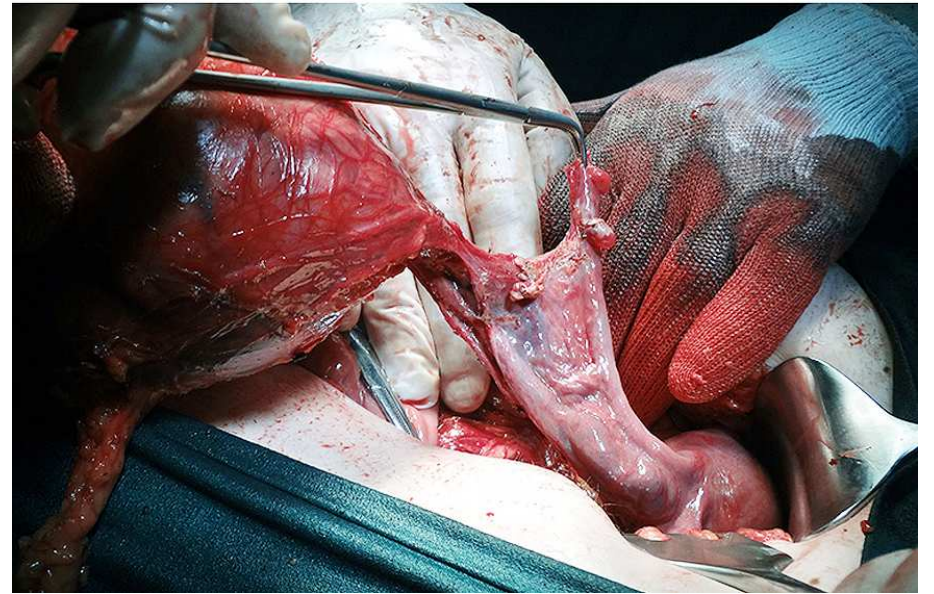
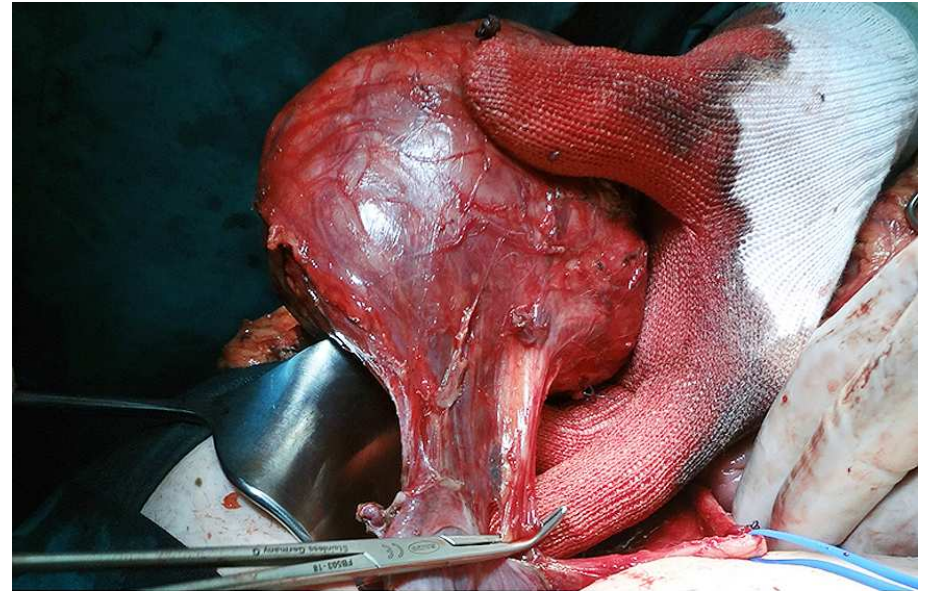
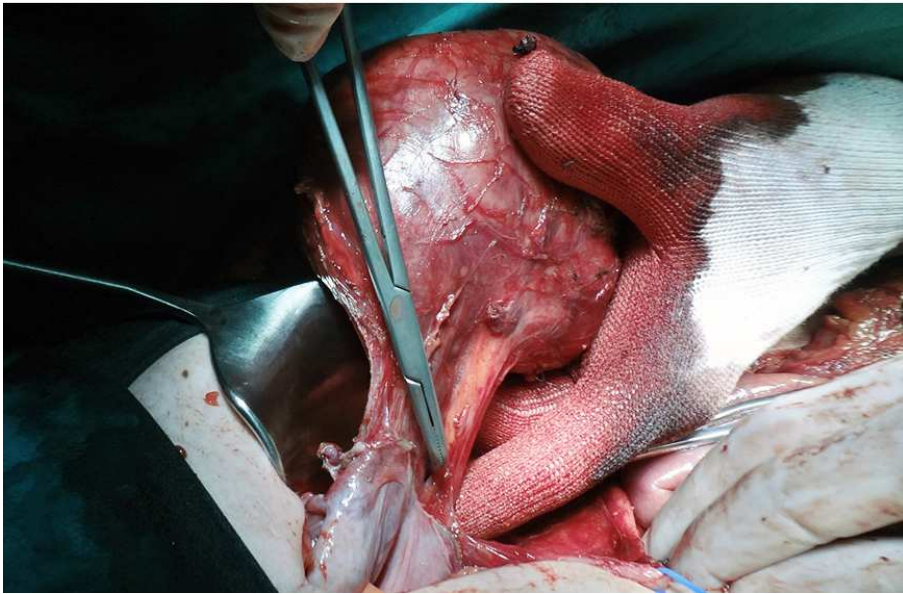
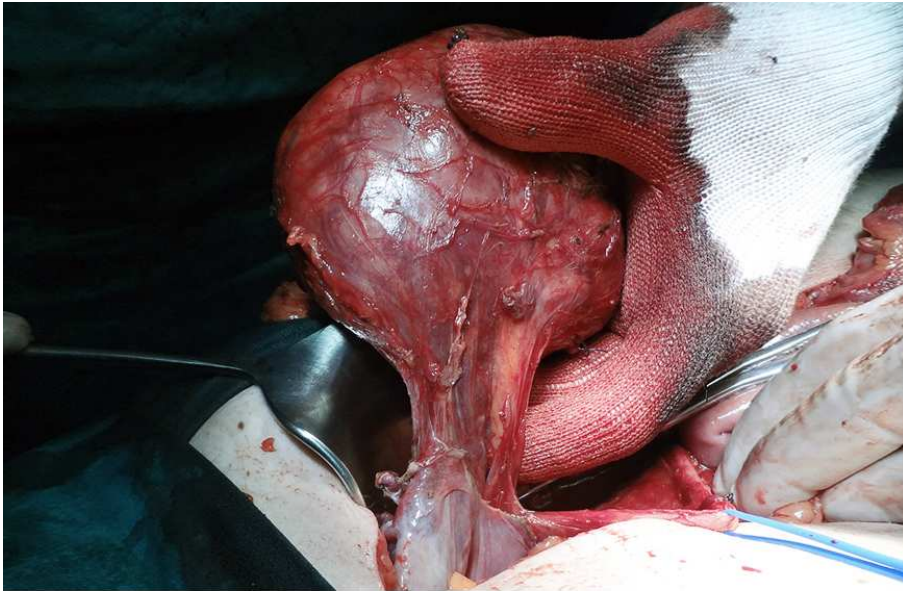

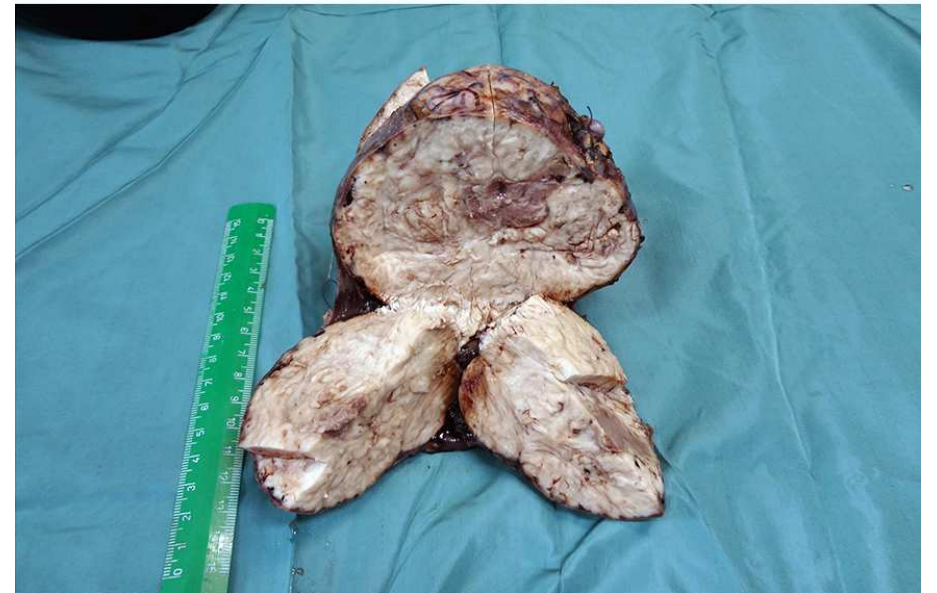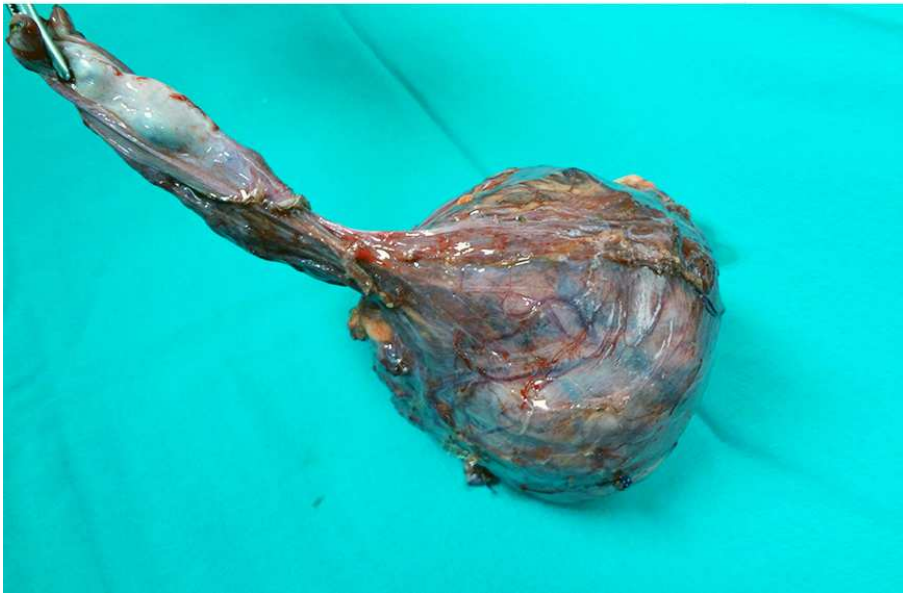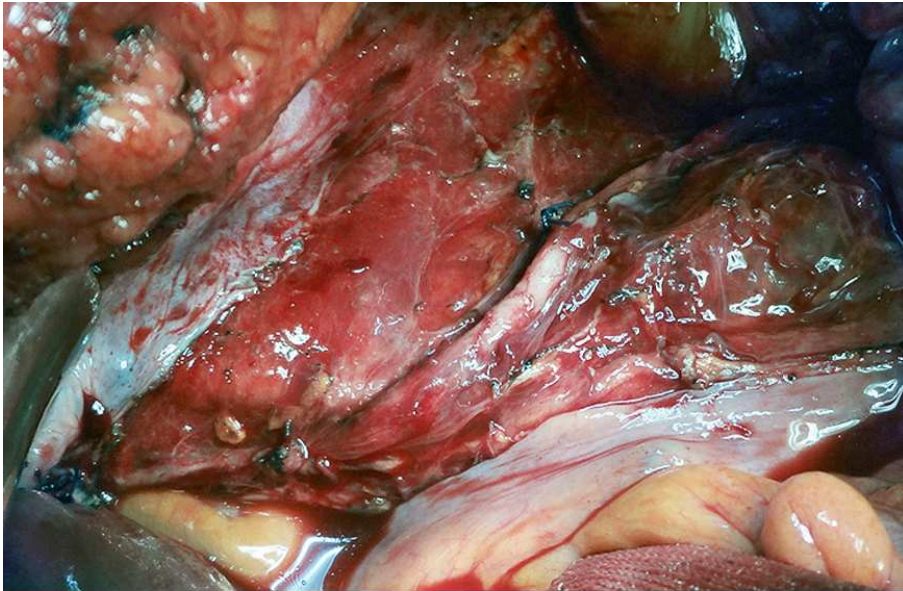


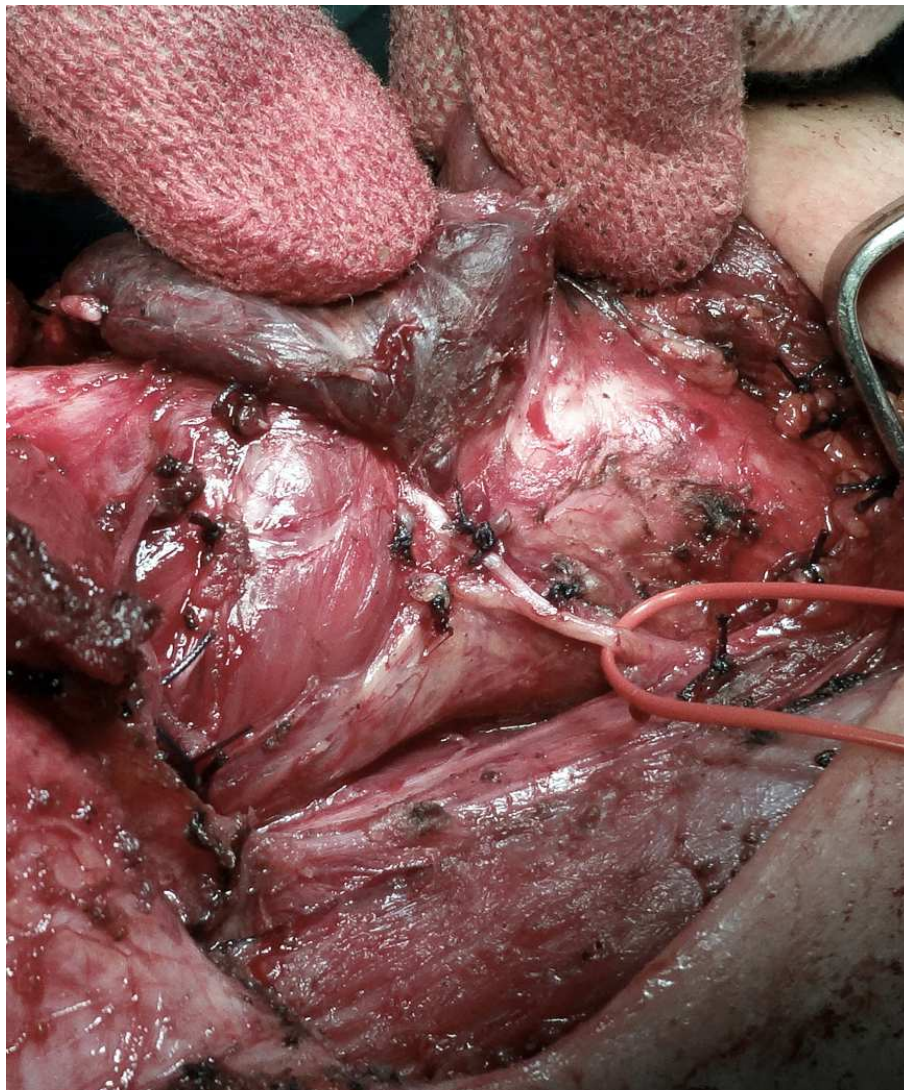






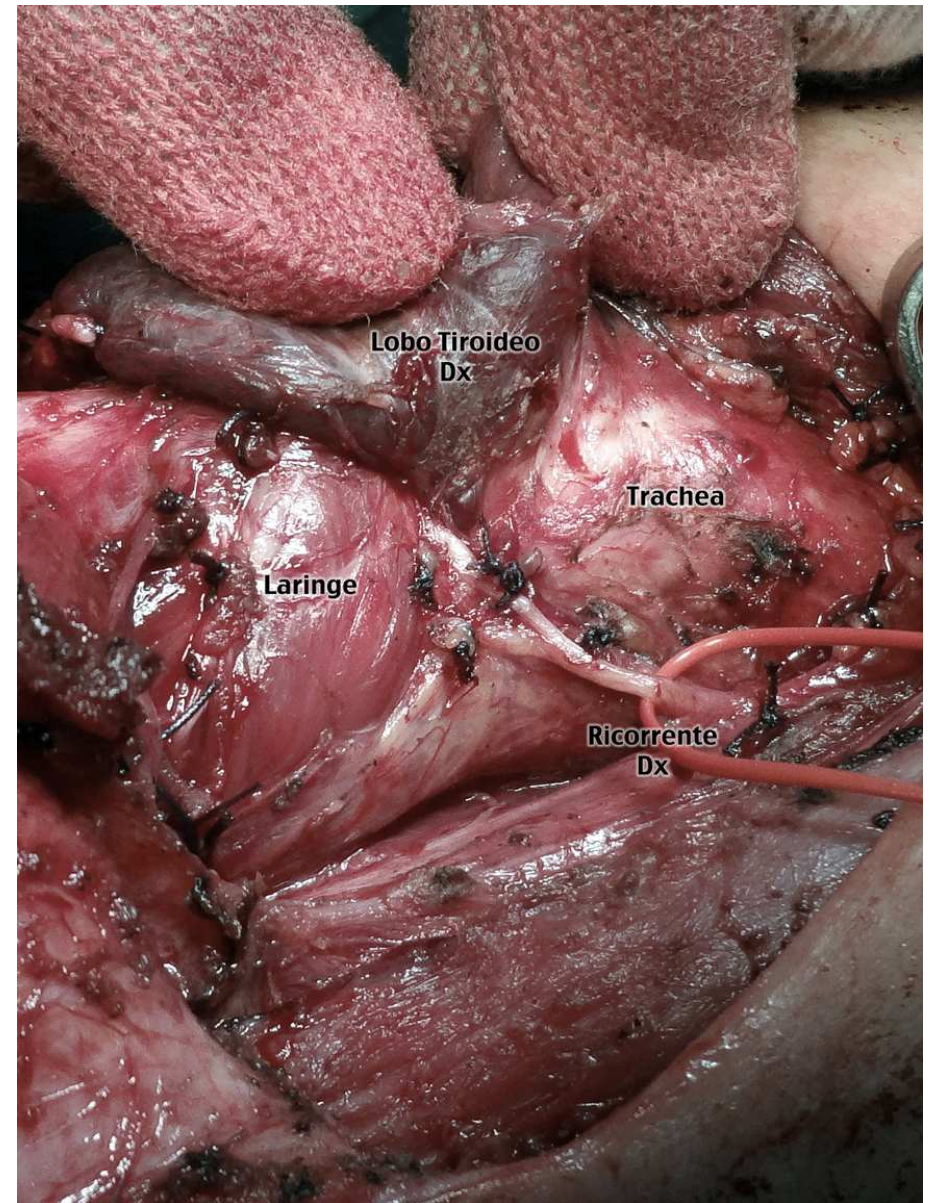


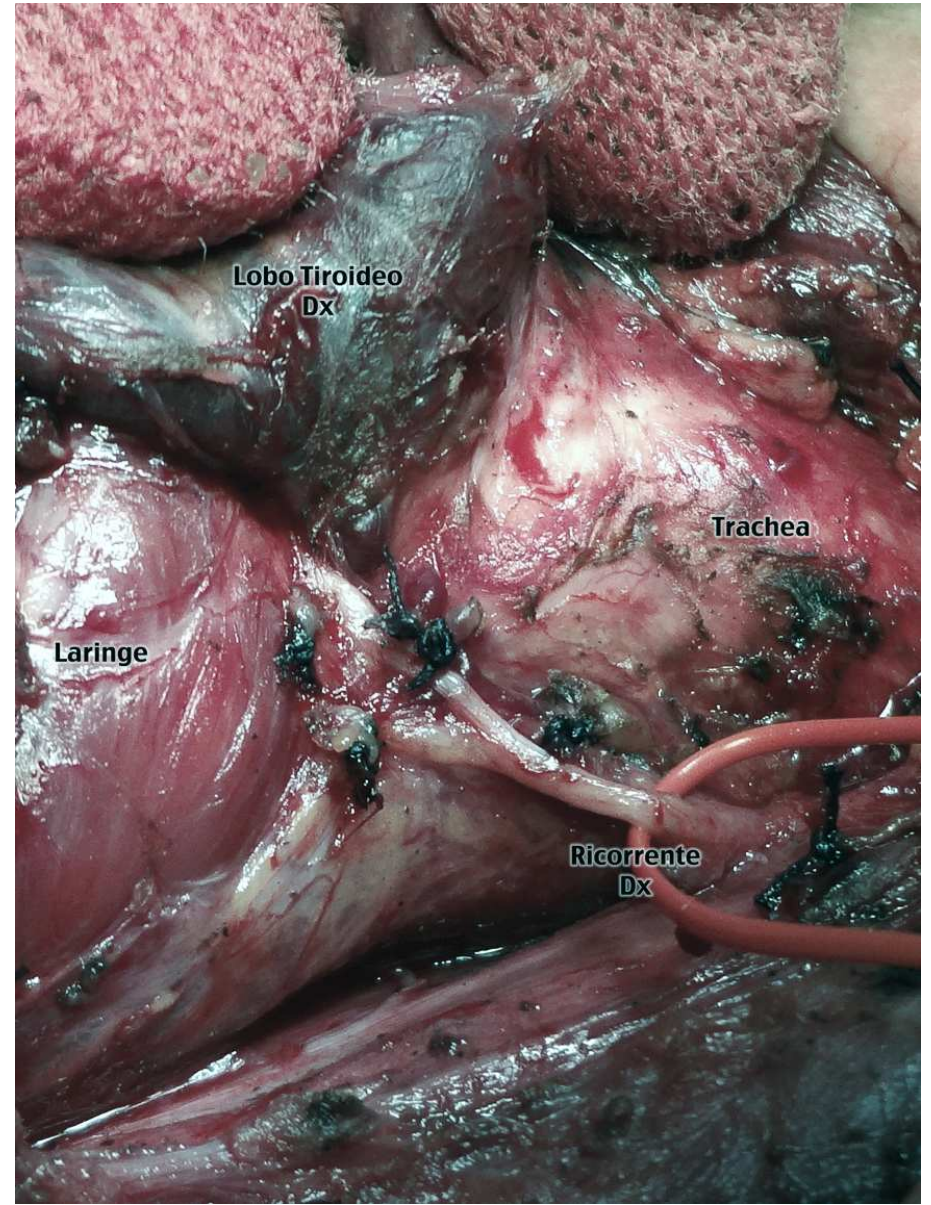
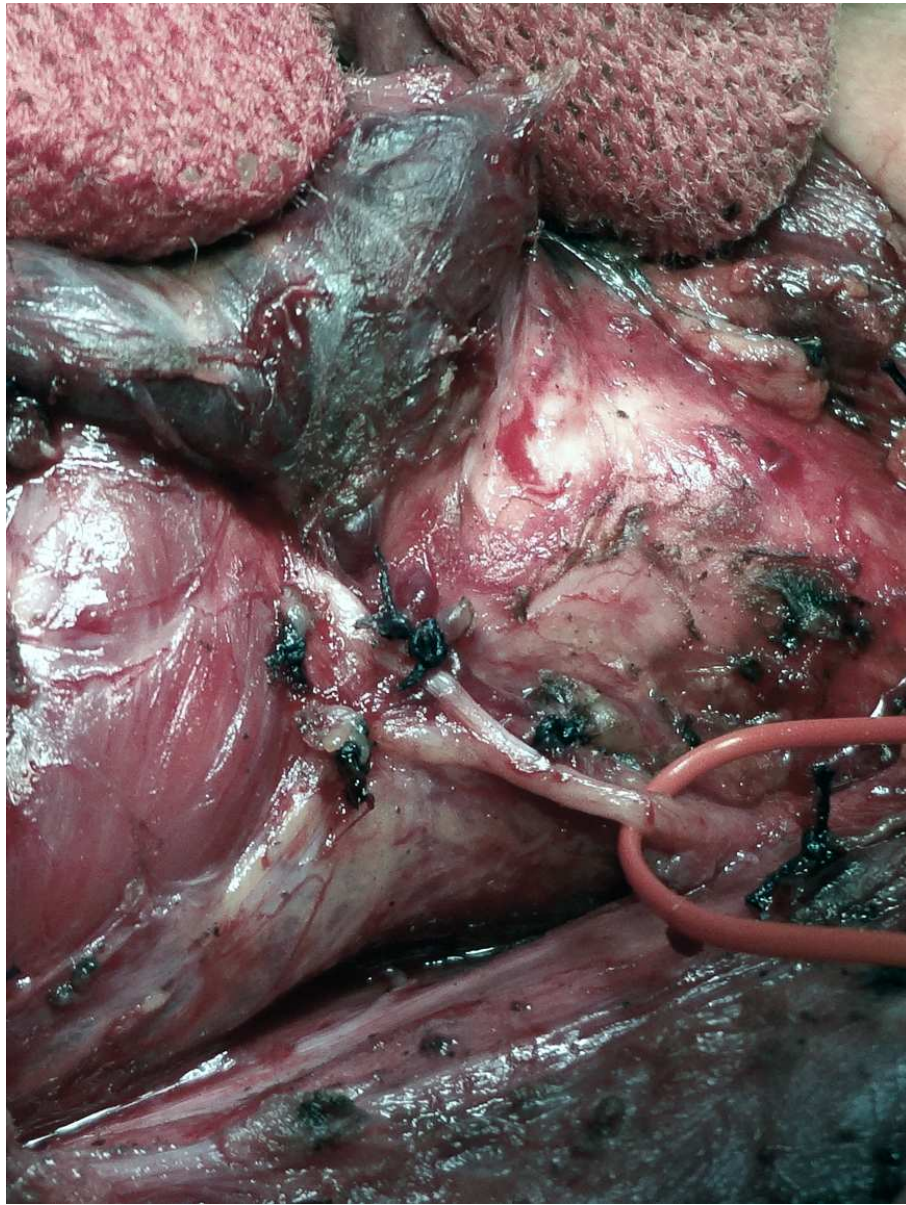


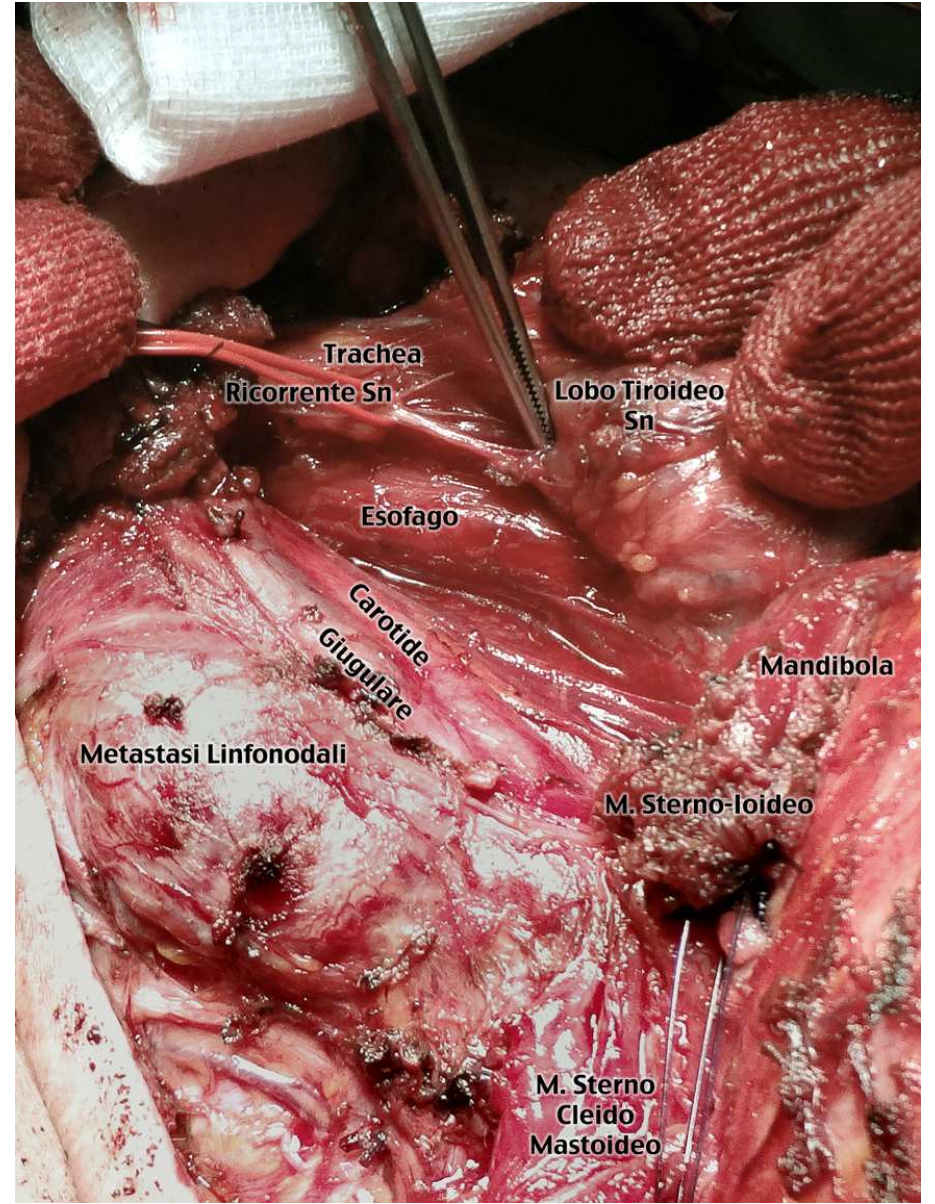
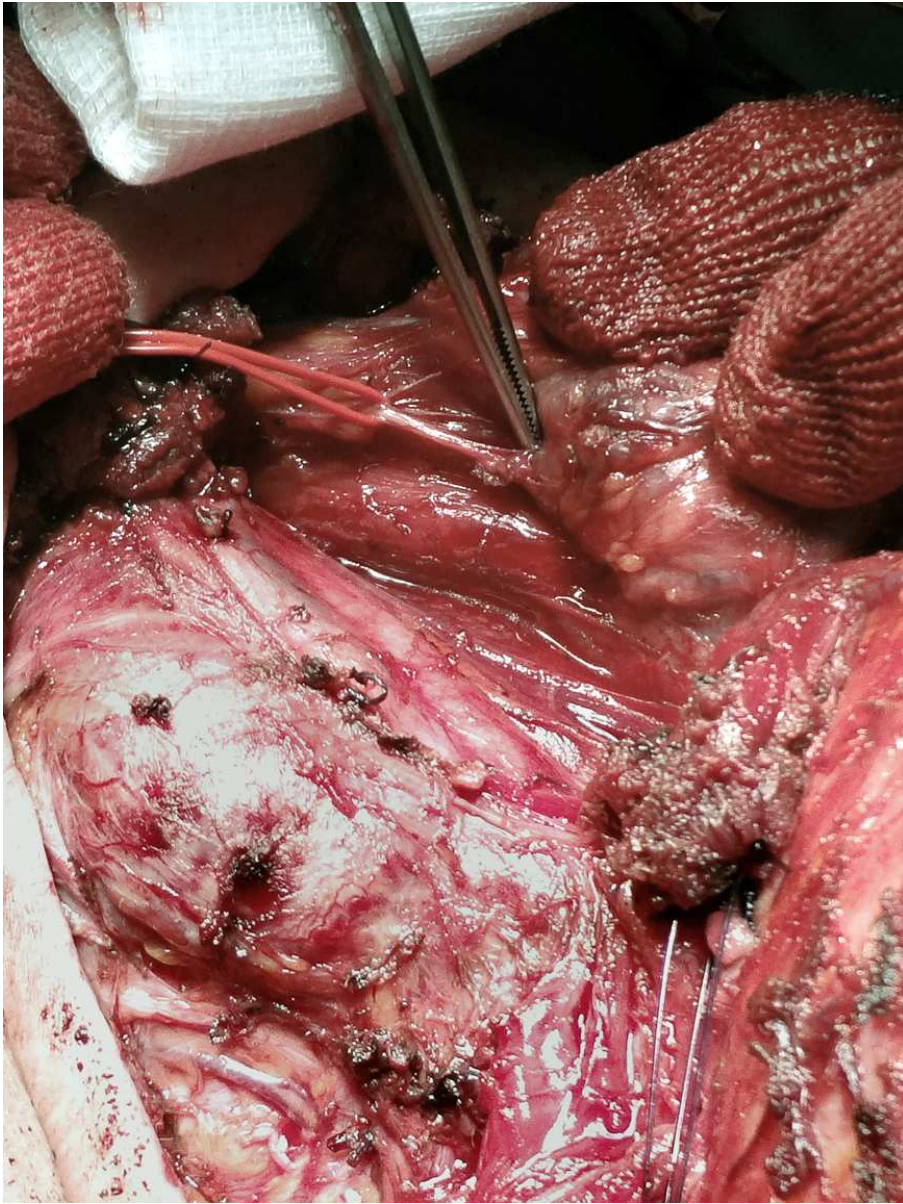


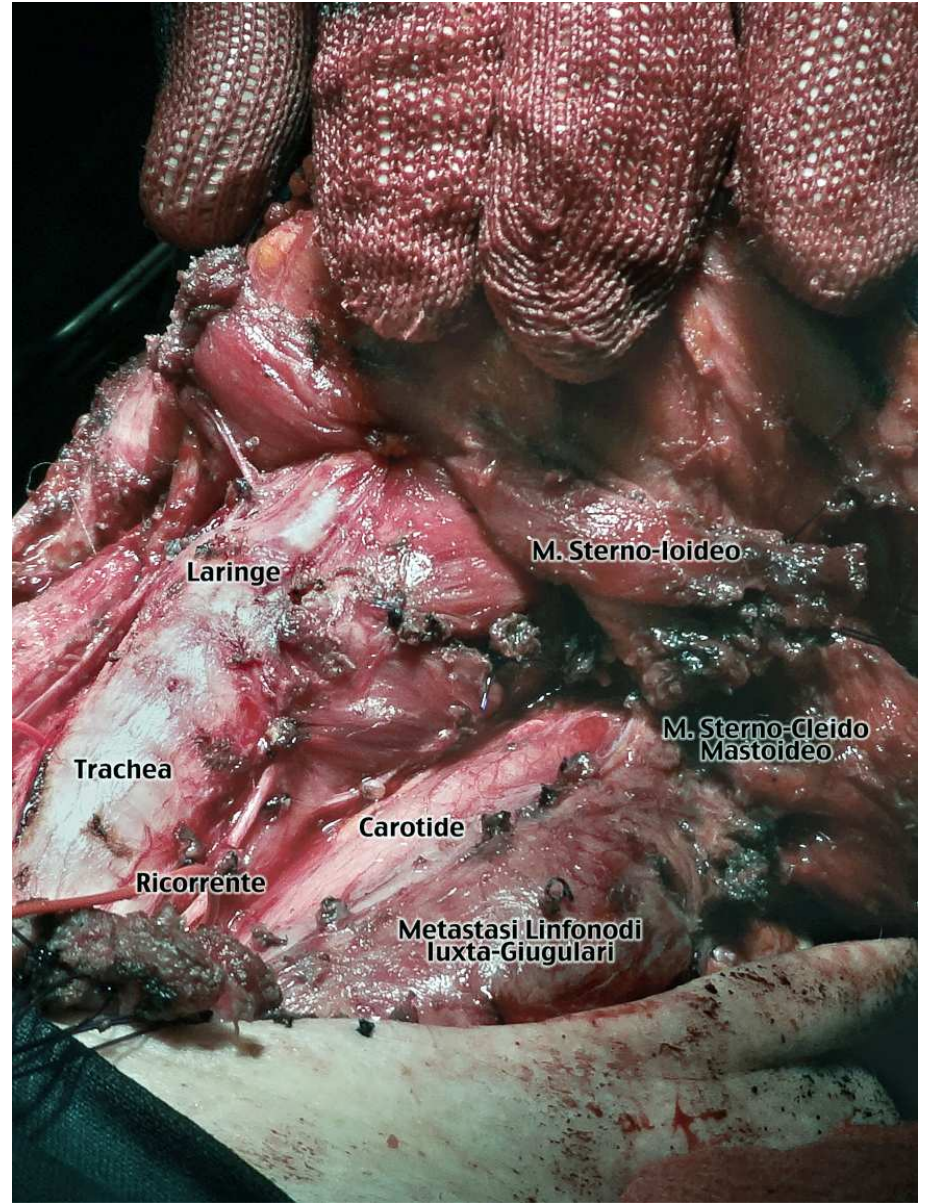
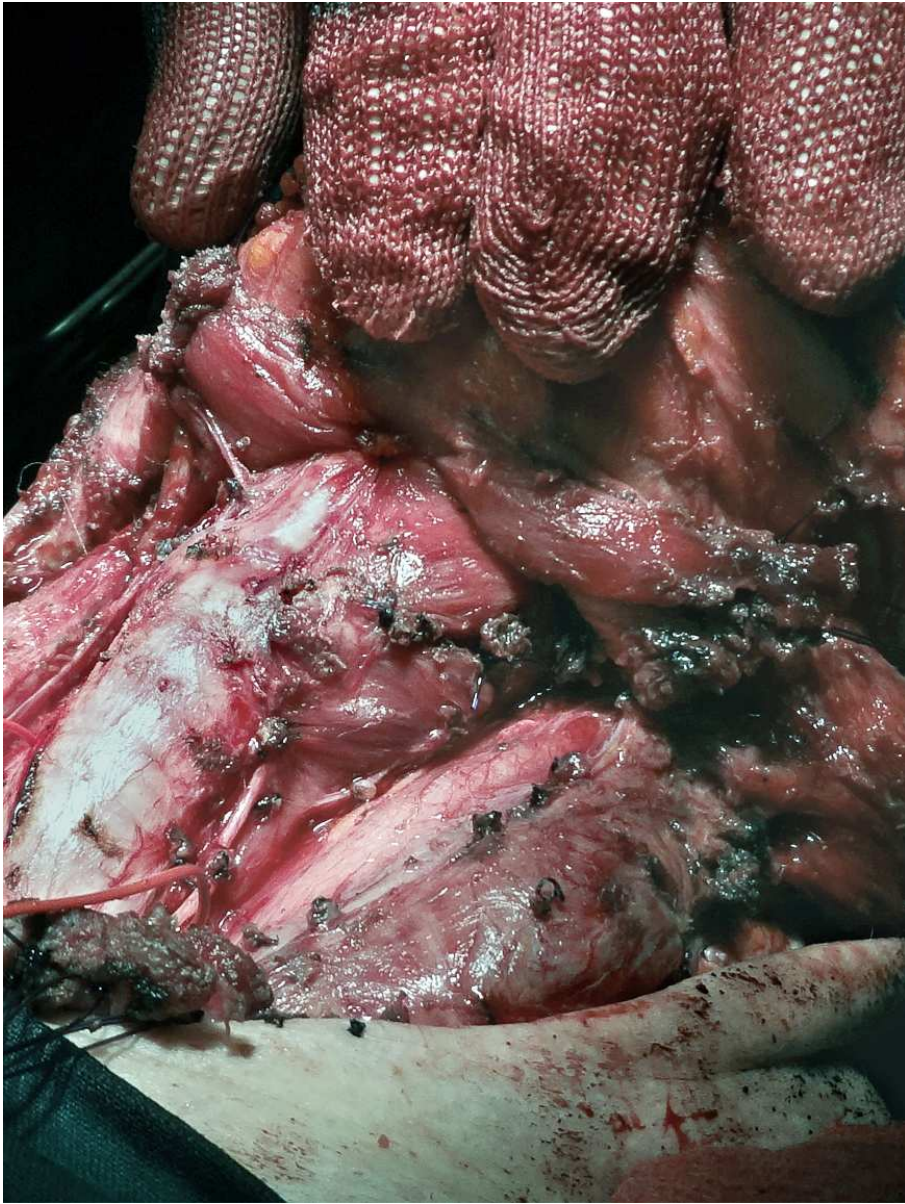
C.N. • Anni: 34 - F • Record: 3 • 17-05-2013

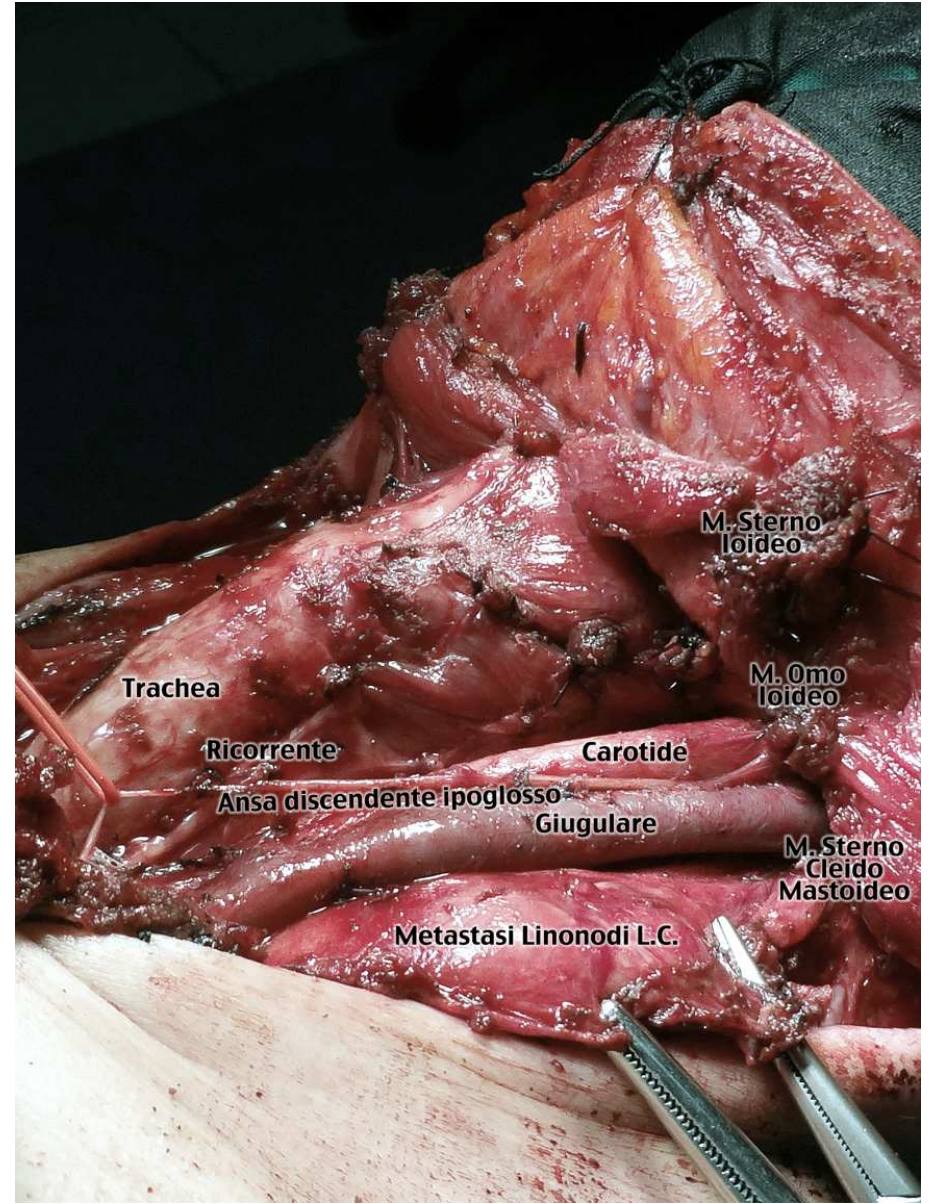
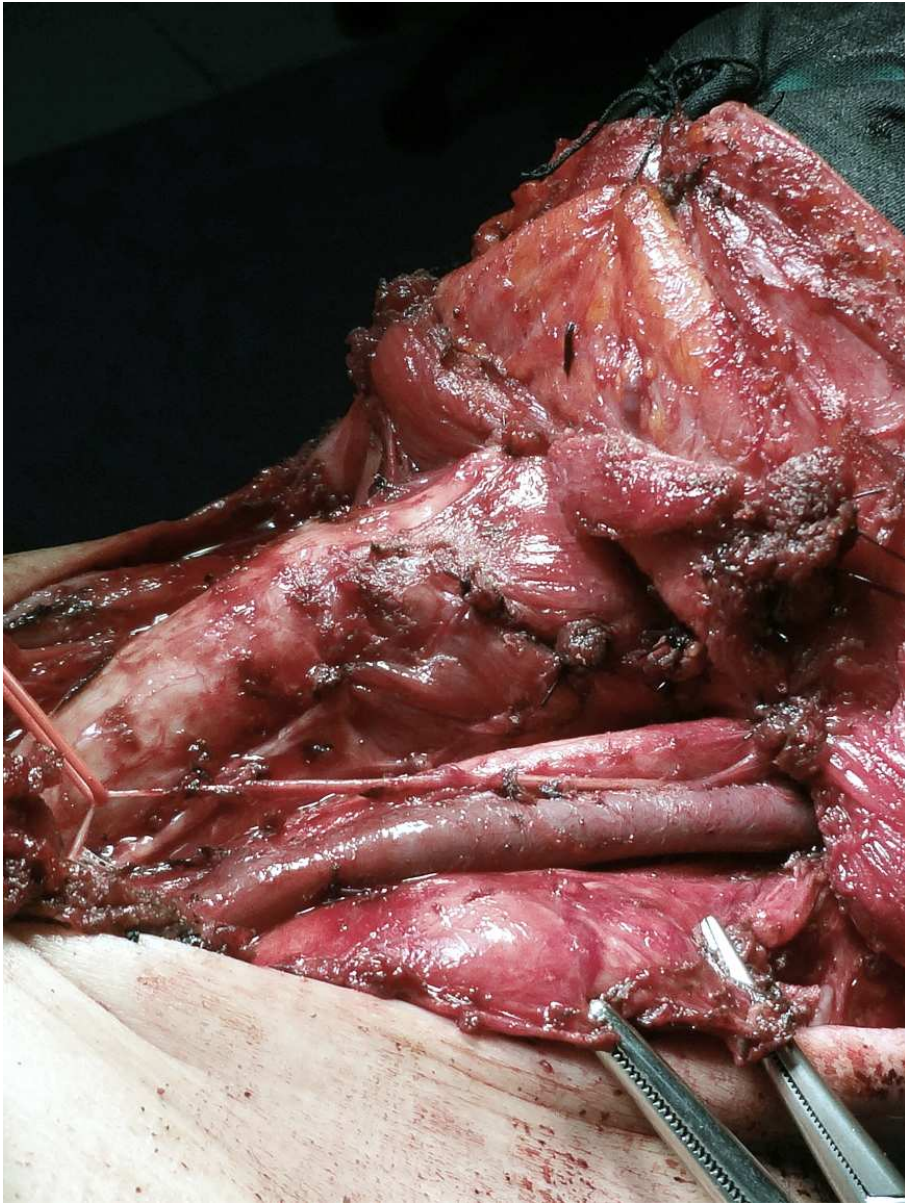Tiroidectomia totale extracapsulare con linfectomia cervicale sn e mediastinica anterior-superiore per carcinoma papillifero del lobo sn con metastasi linfonodali omolaterali

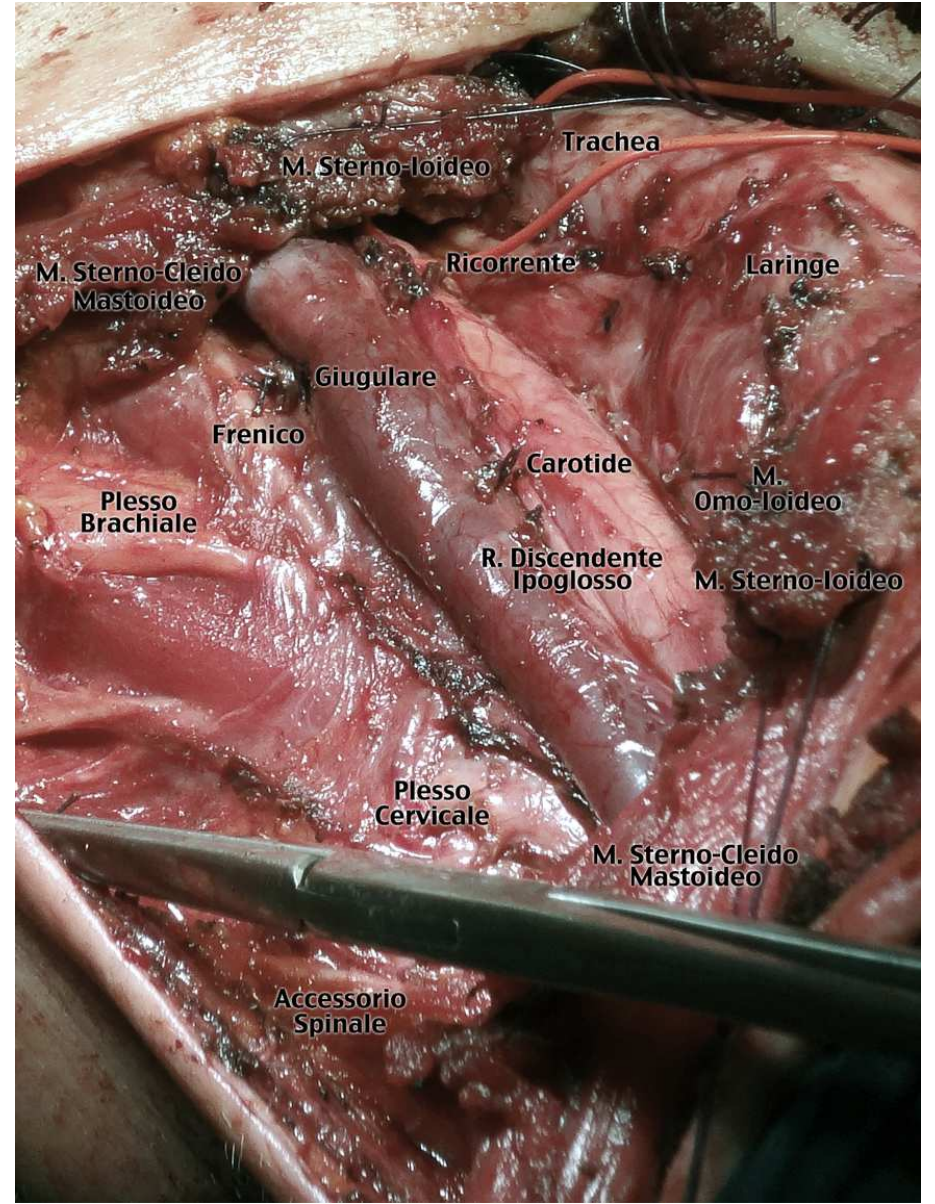
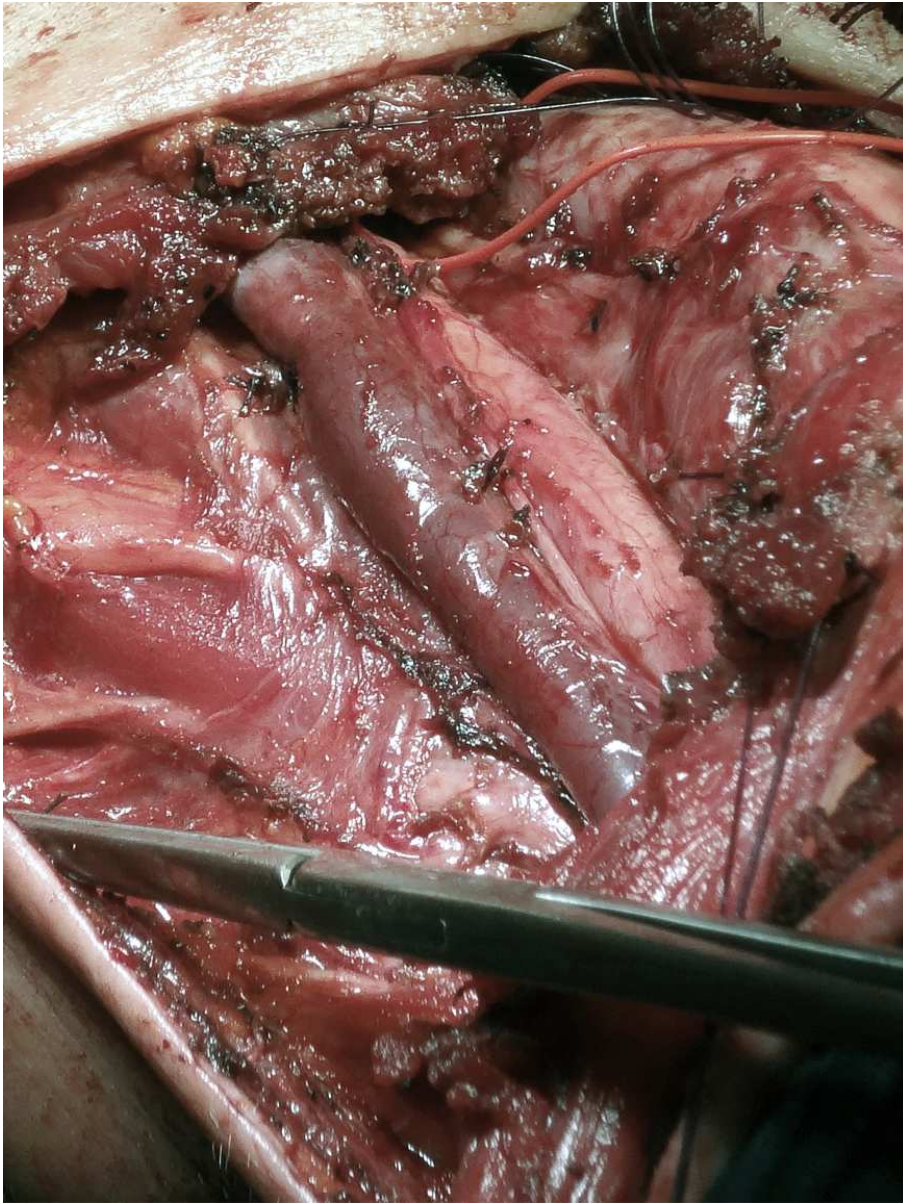




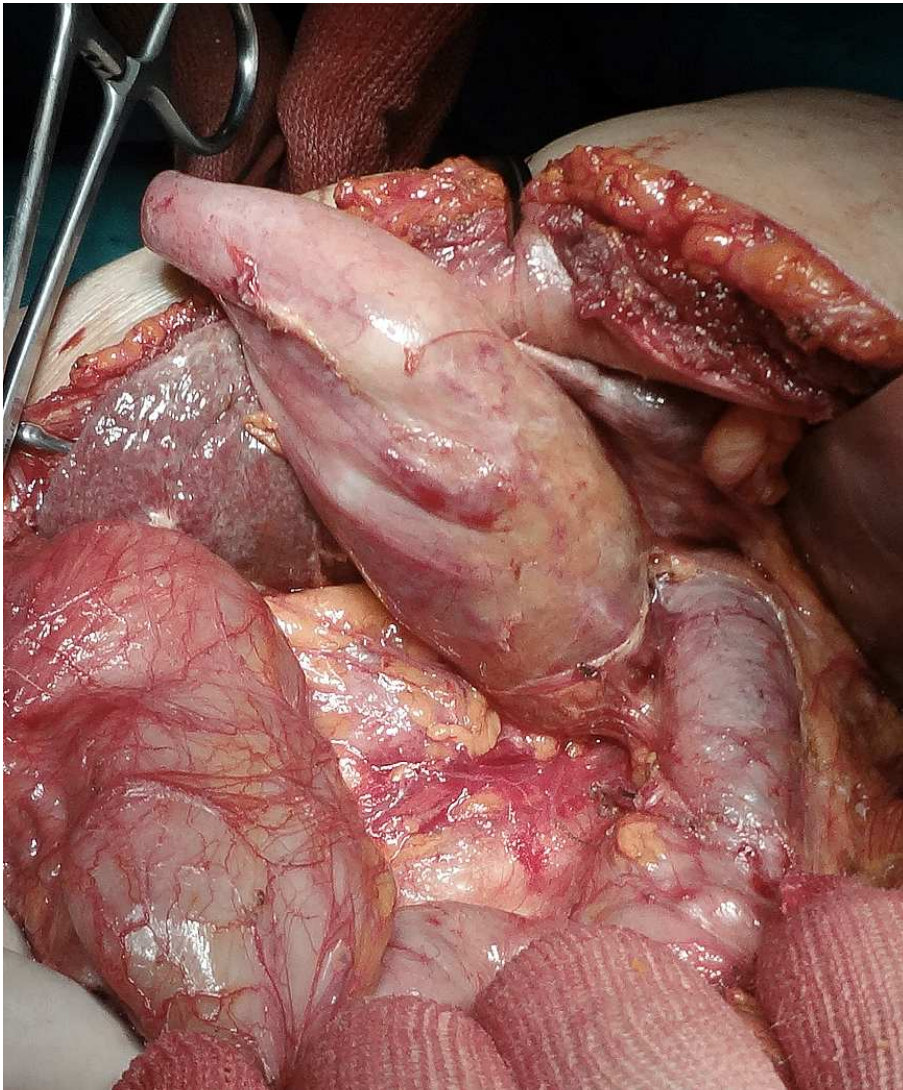




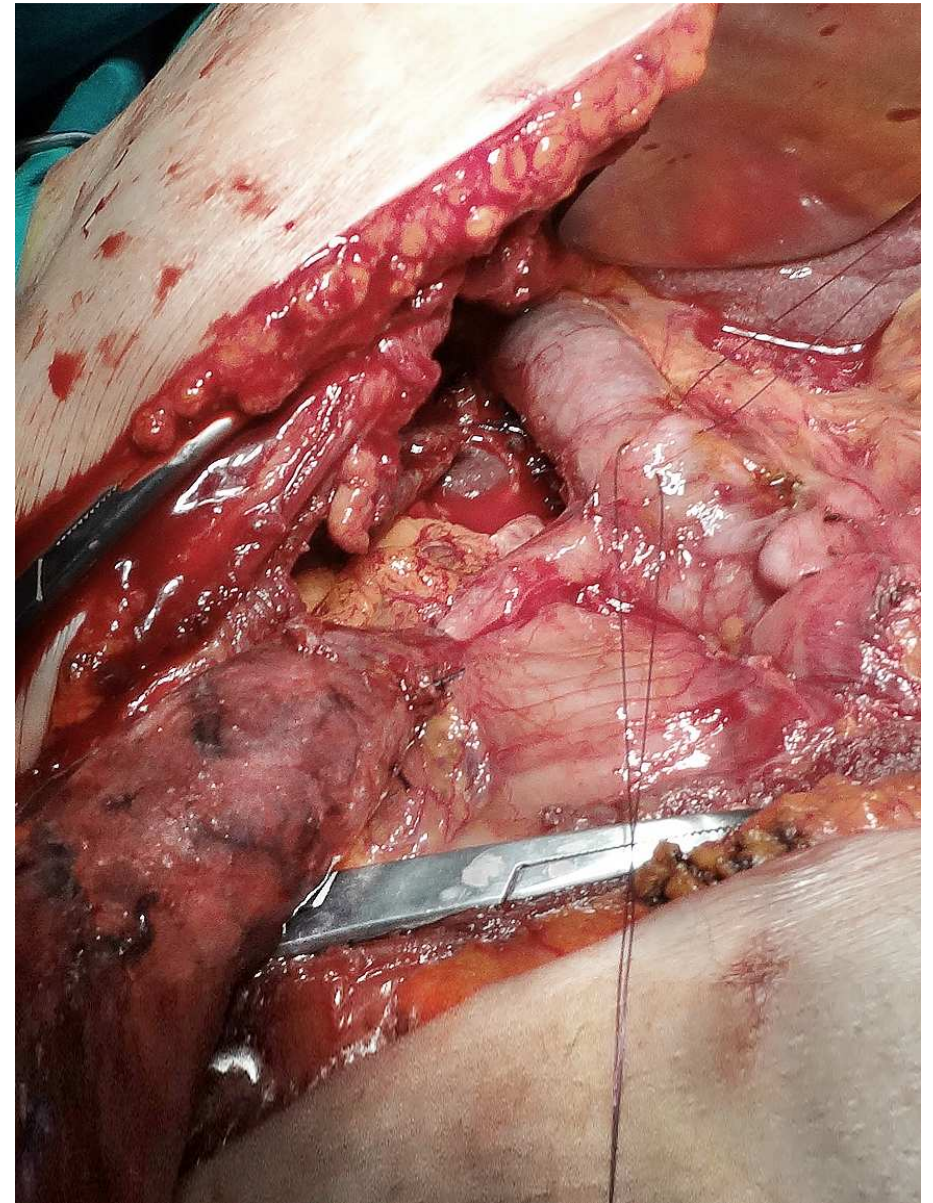


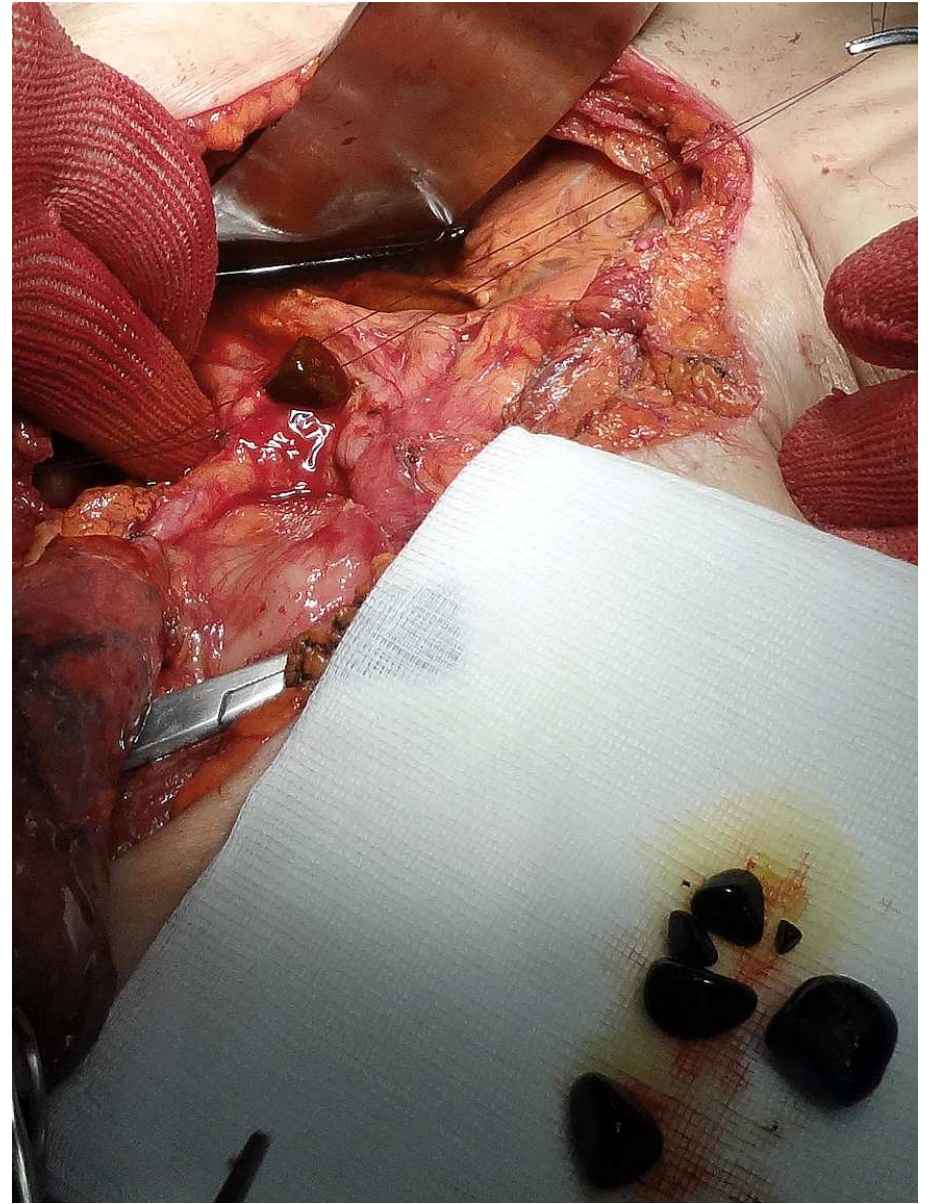
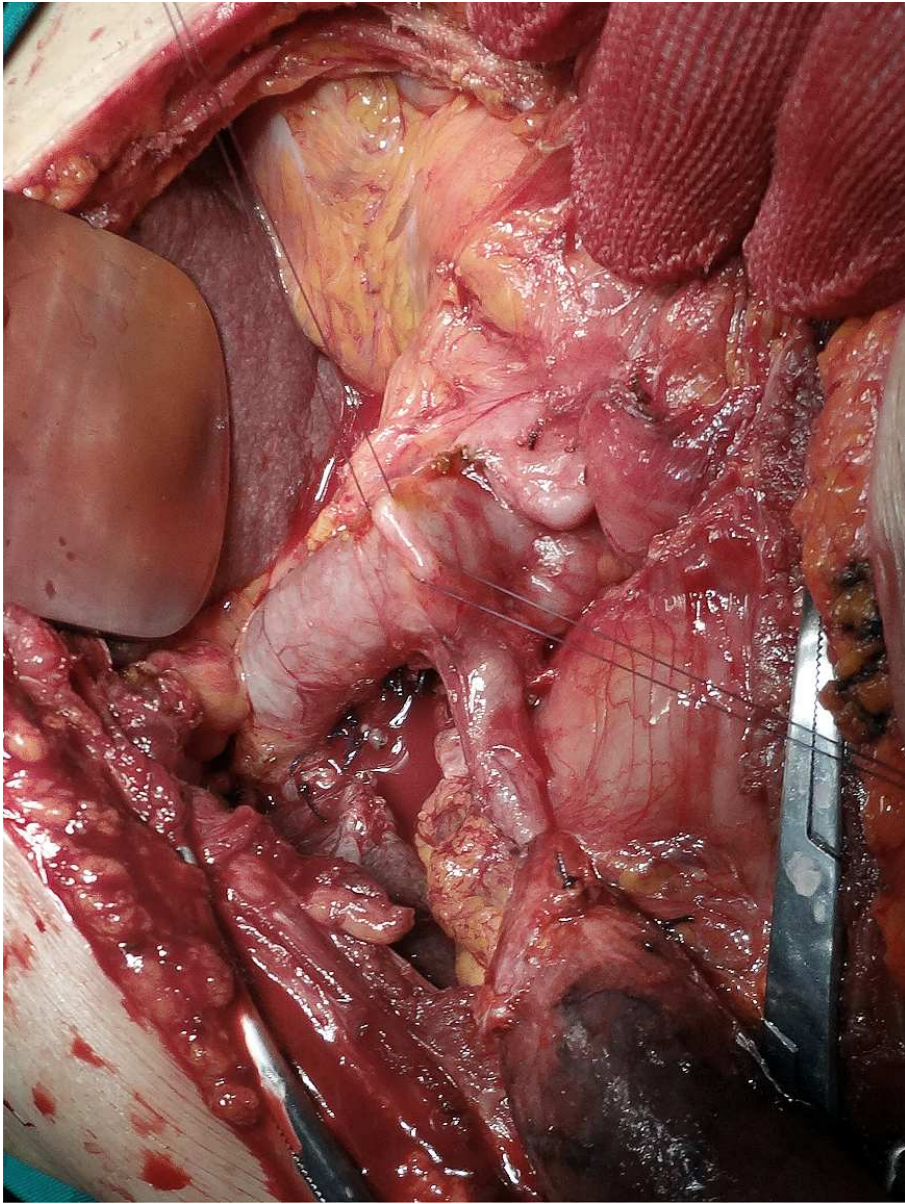


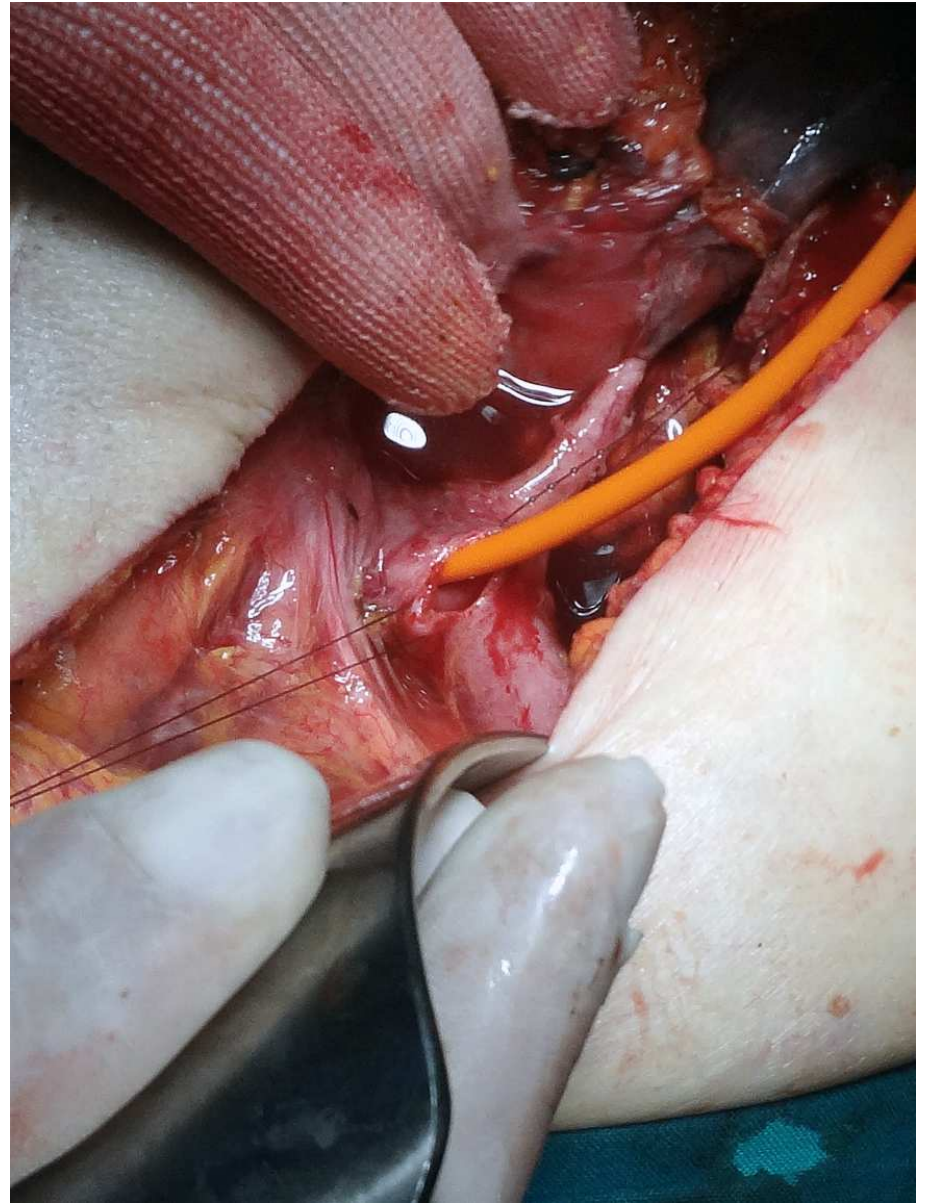
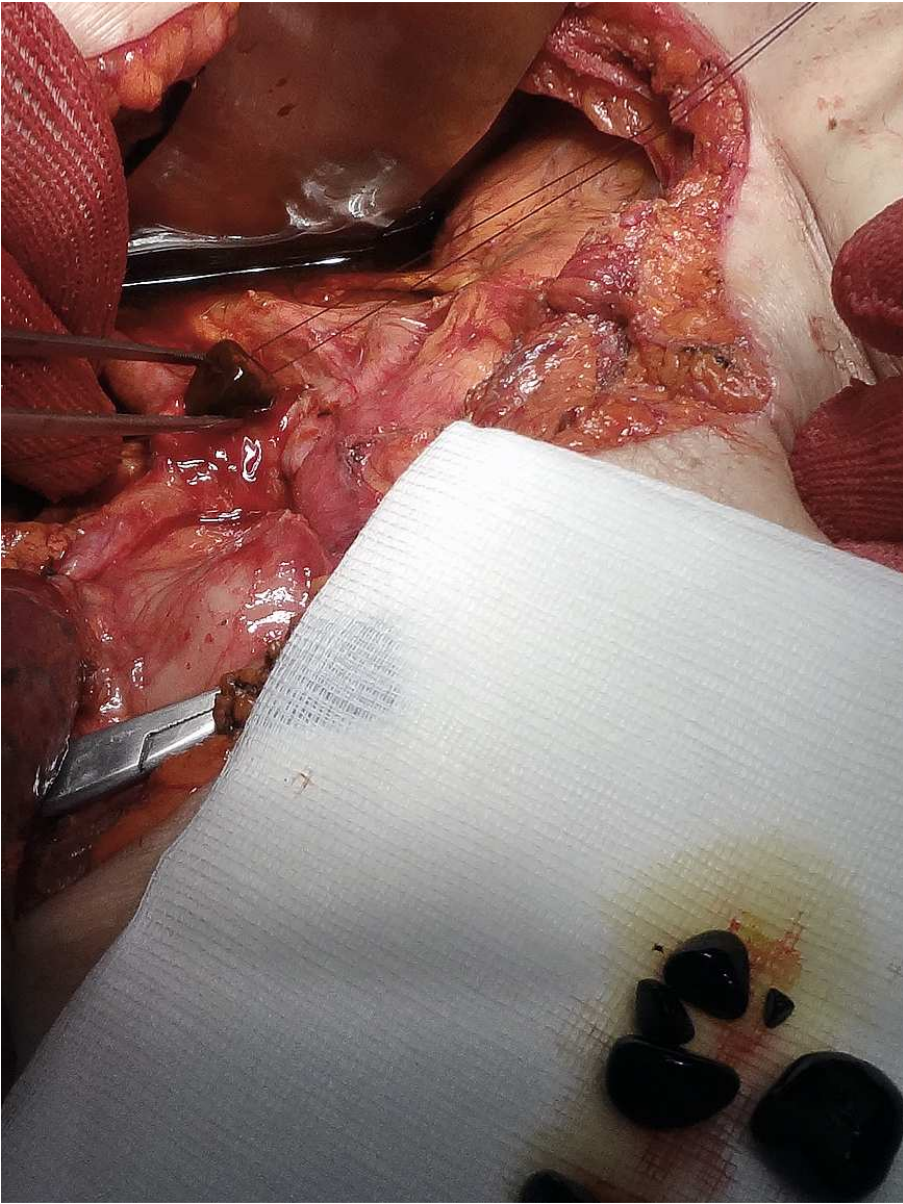


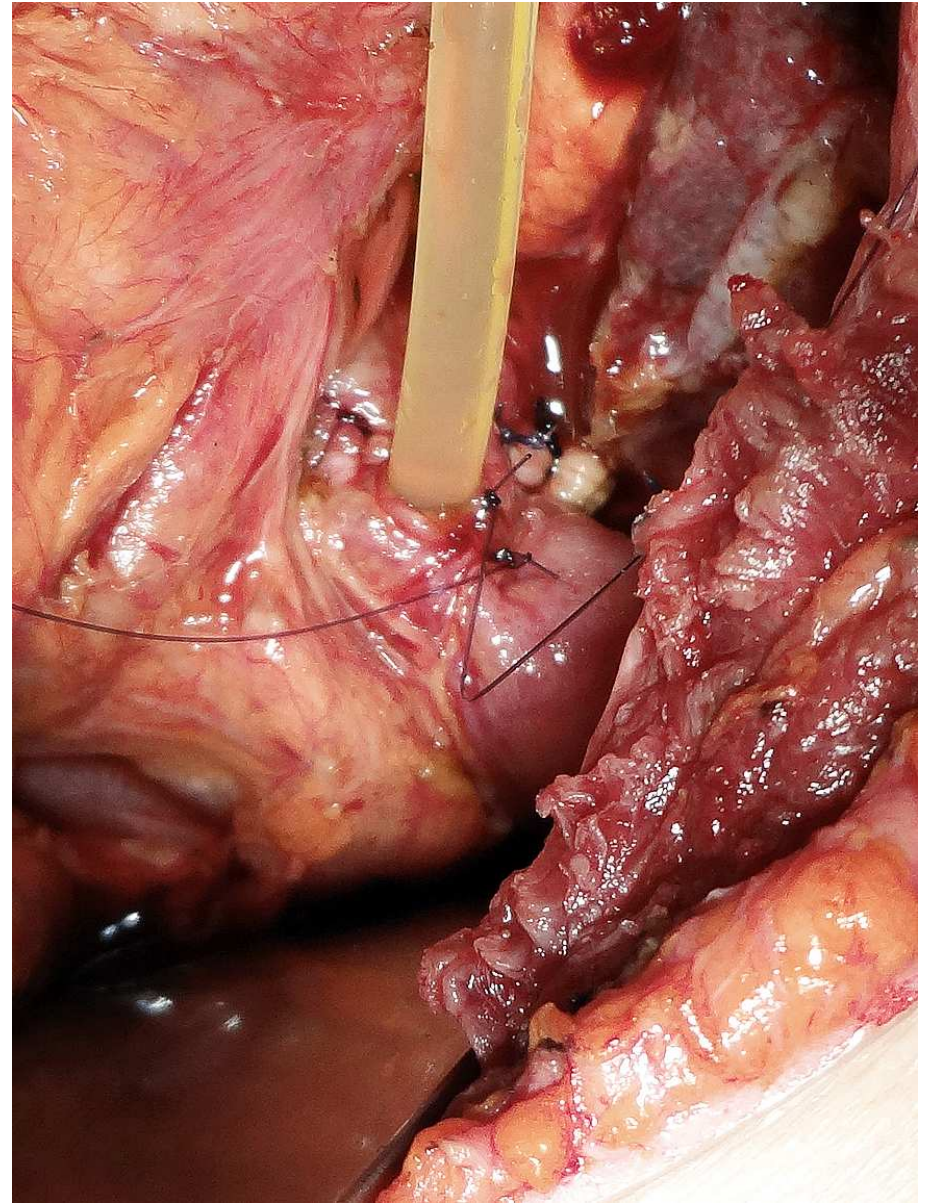
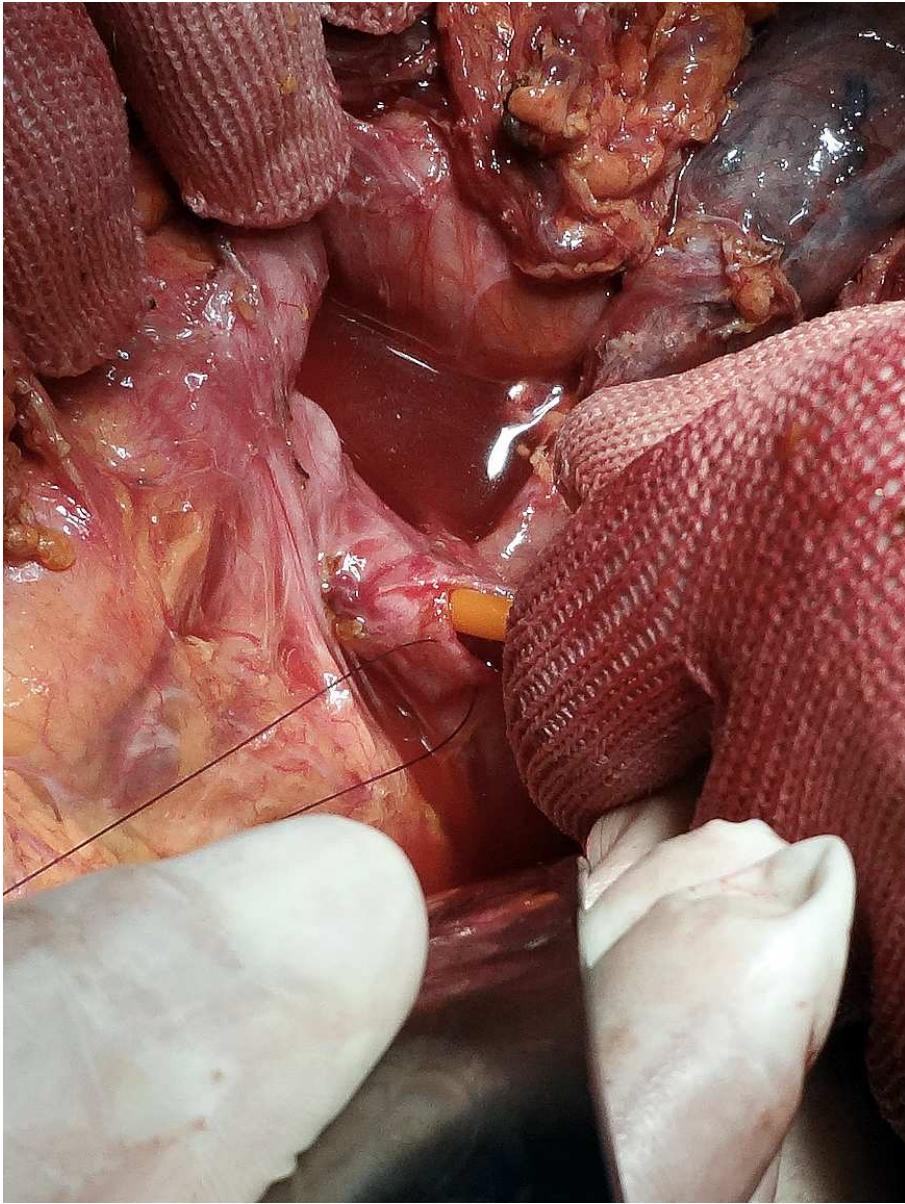
A.A. • Anni: 90 - M 🍏 Record: 4 • 27-07-2013

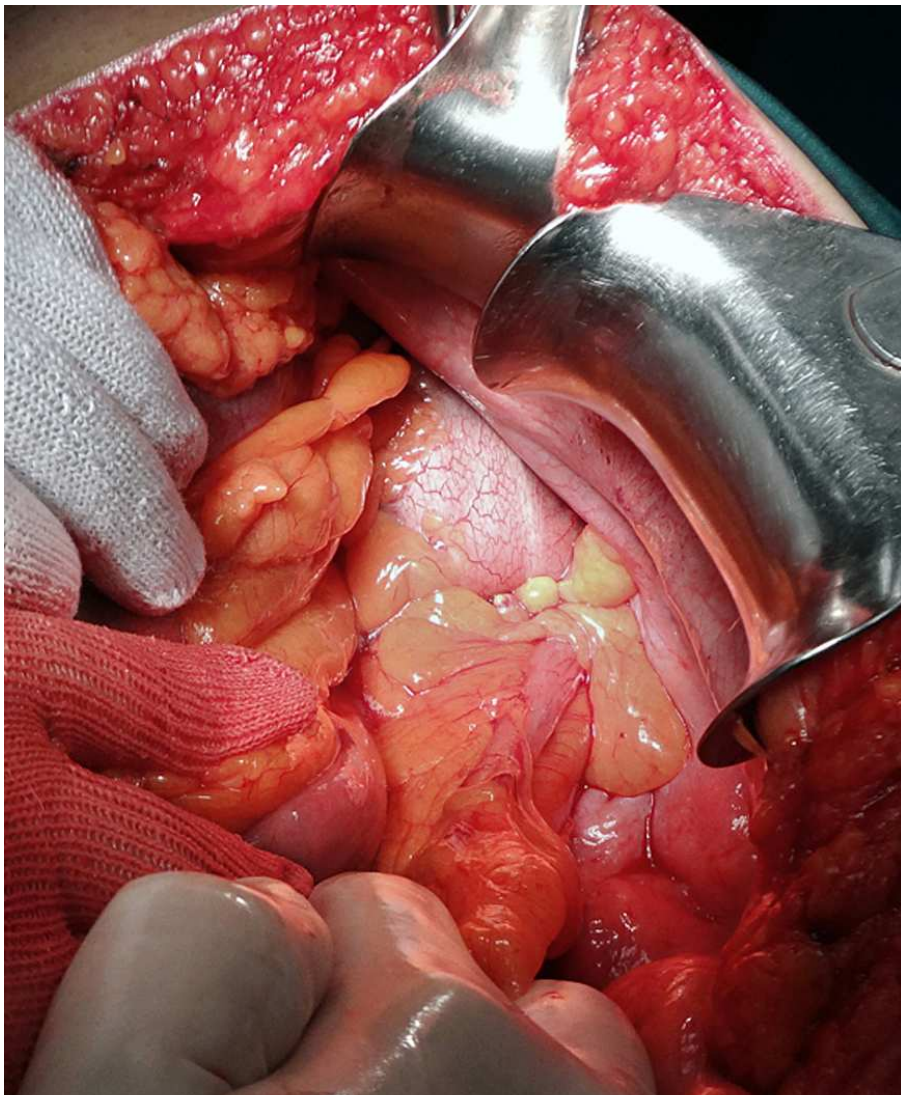
Colecistectomia retrograda, coledocotomia ed estrazione di 17 calcoli dalla VBP, sondaggio della papilla di Vater e coledocorrafia su Kher per colangio-colecistite e pancreatite acuta da calcocolosi della colecisti e della VBP





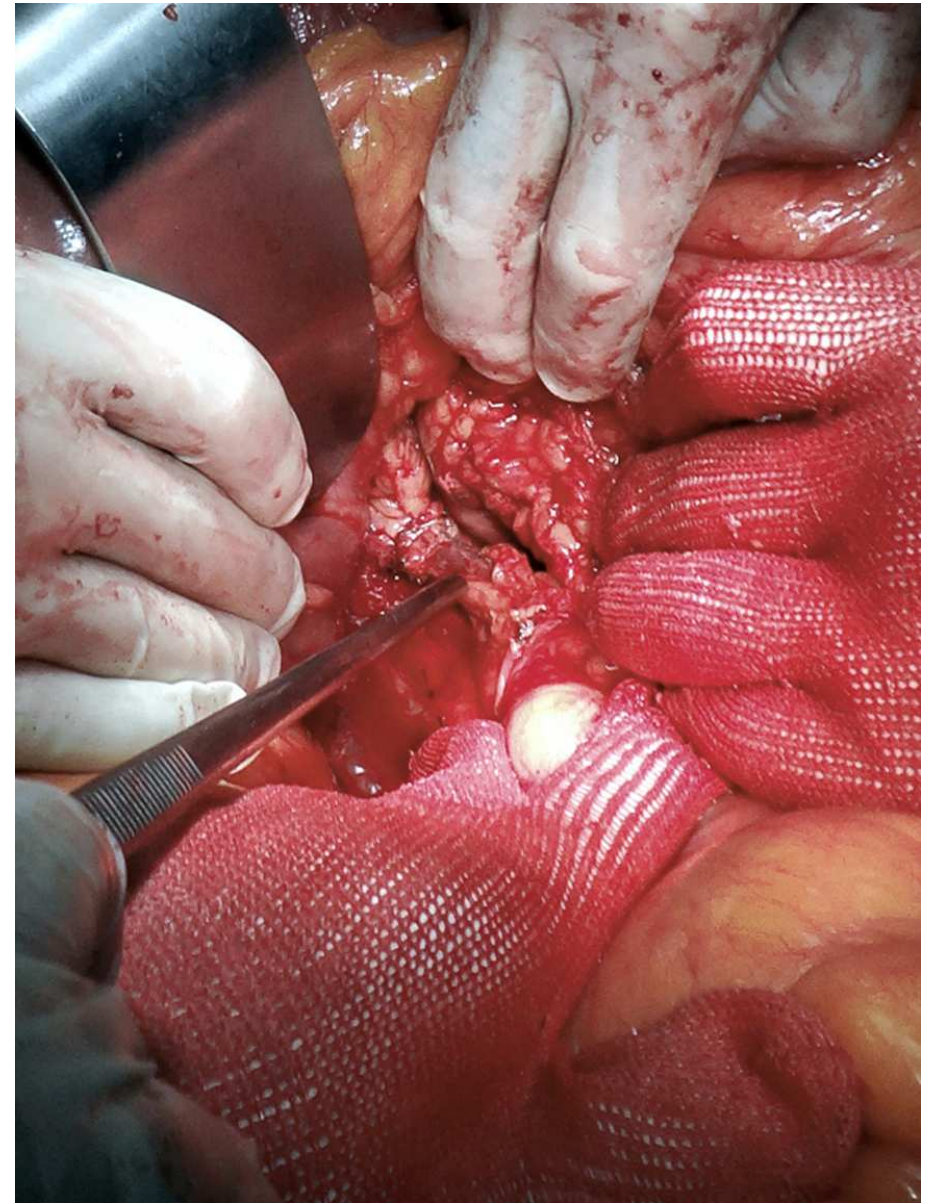




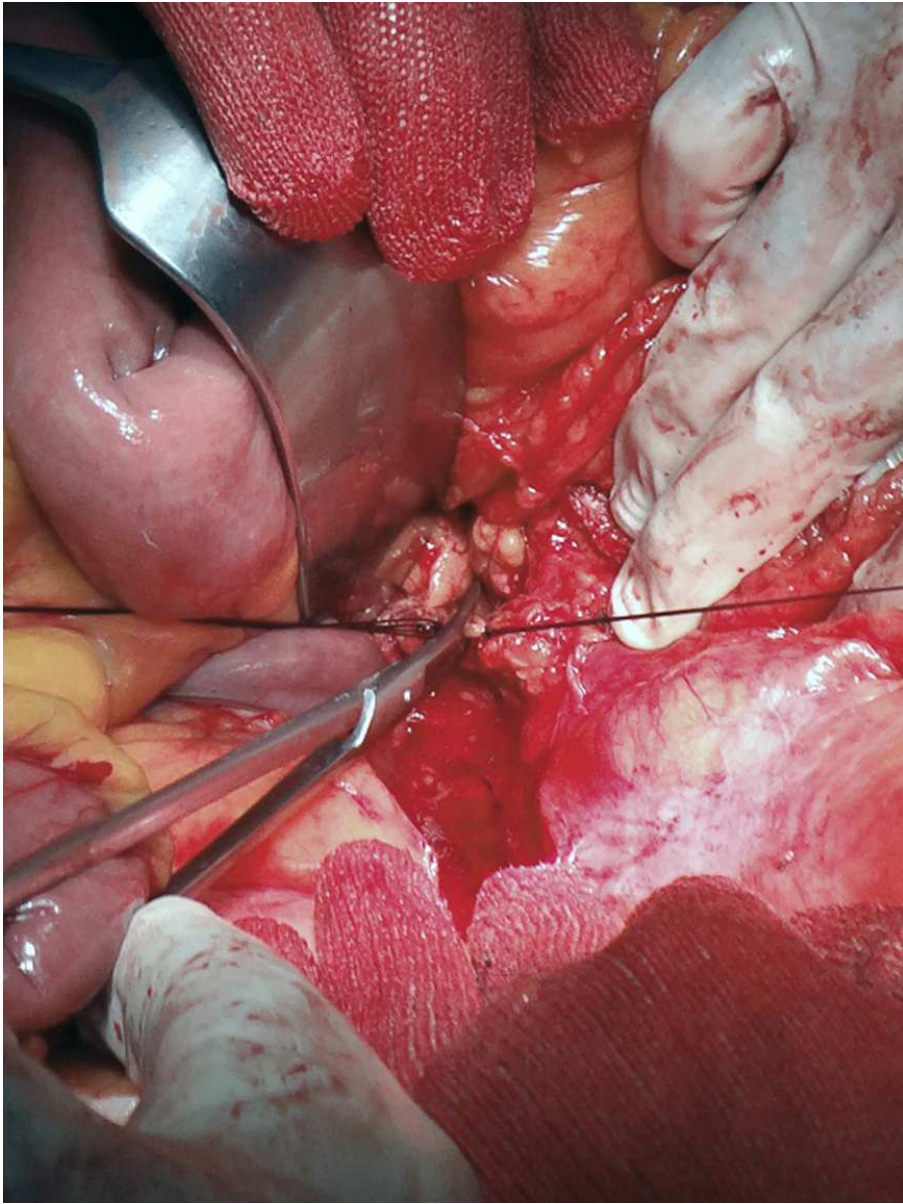


D.M.G. • Anni: 58 - M 🍏 Record: 1 • 14-12-2018

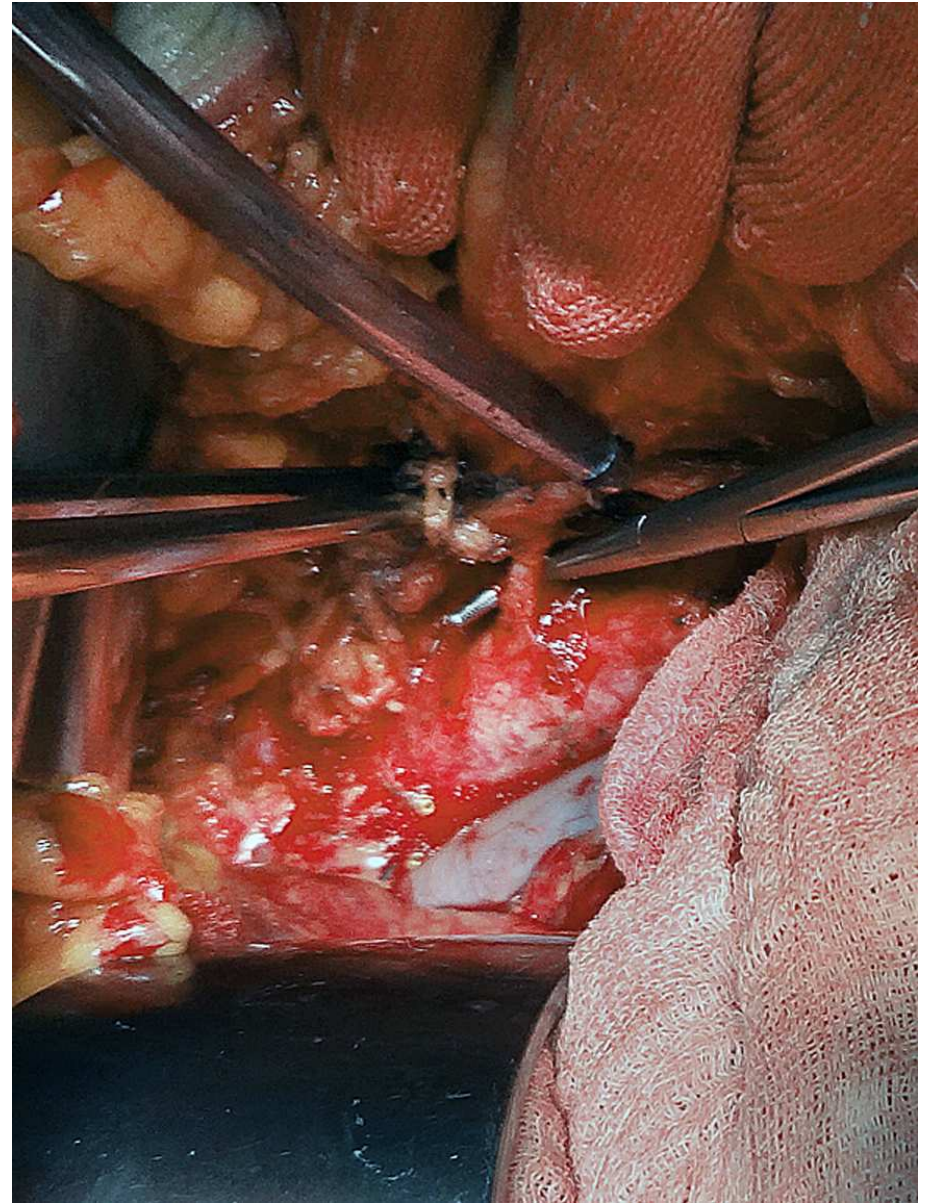
Emicolectomia sn tipica con linfadenectomia preaorto-cavale, intercavo-aortica, para-aortica sn, iliaca bilaterale e presacrale en bloc e confezionamento di ano iliaco temporaneo a sn per occlusione intestinale da adenocarcinoma (G2) infiltrante e stenosante del colon discendente



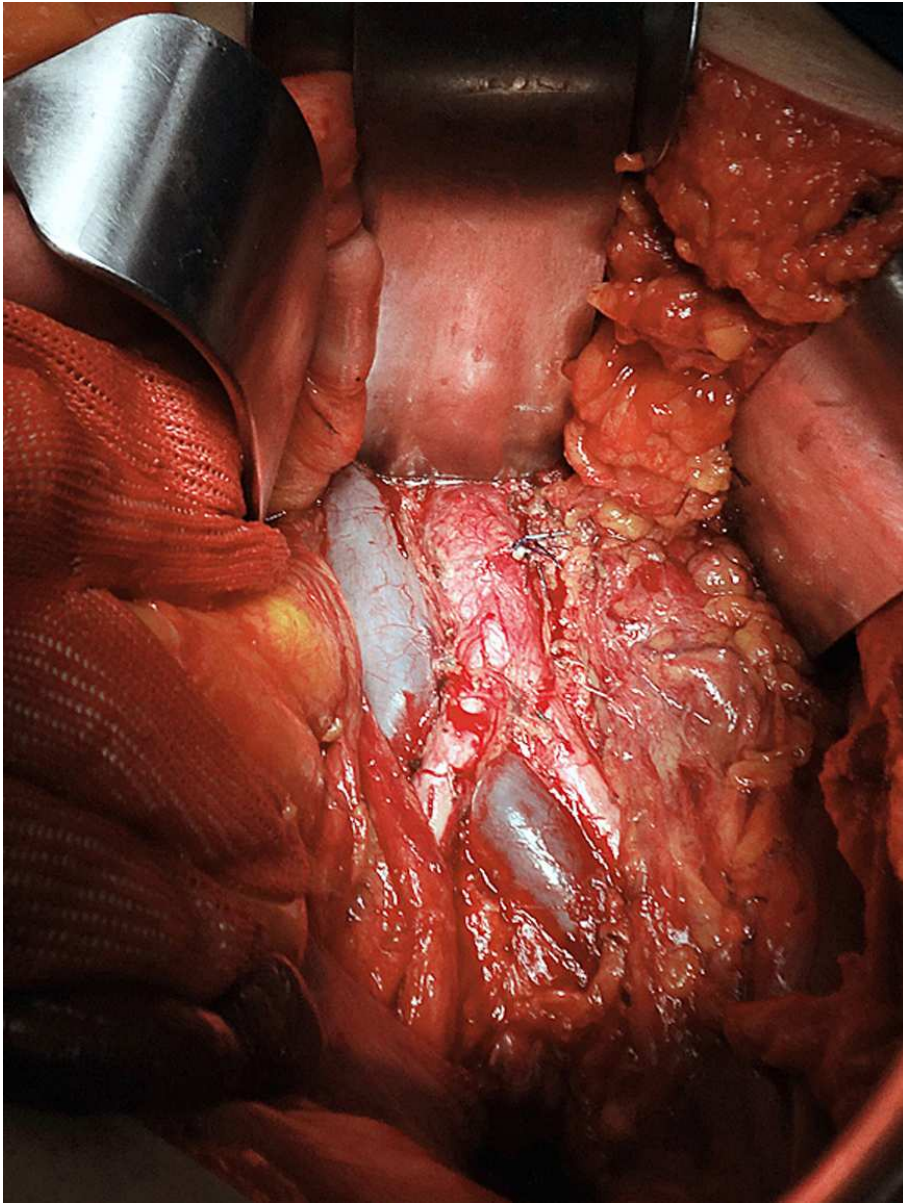
Isolamento della vena mesenterica inferiore



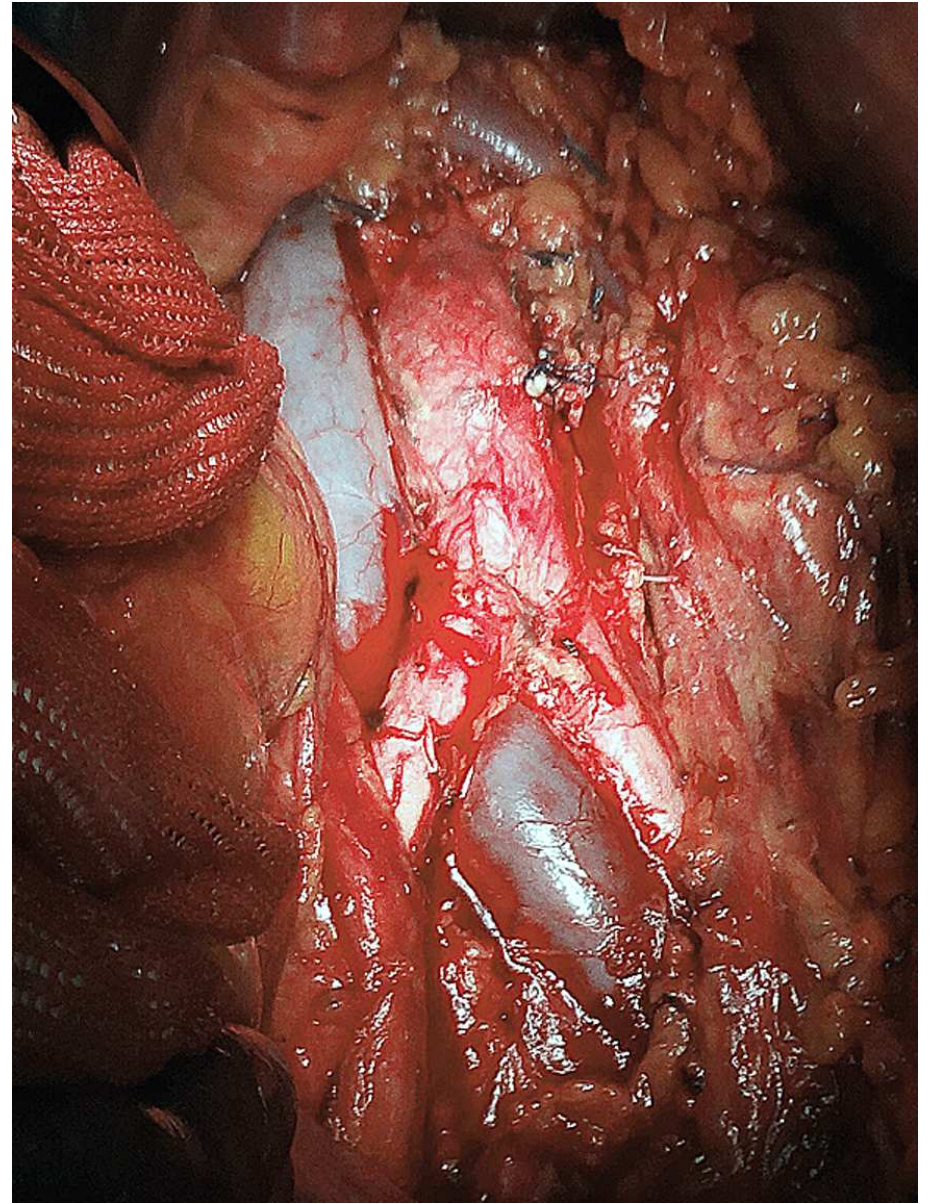
Sezione vena mesenterica inferiore



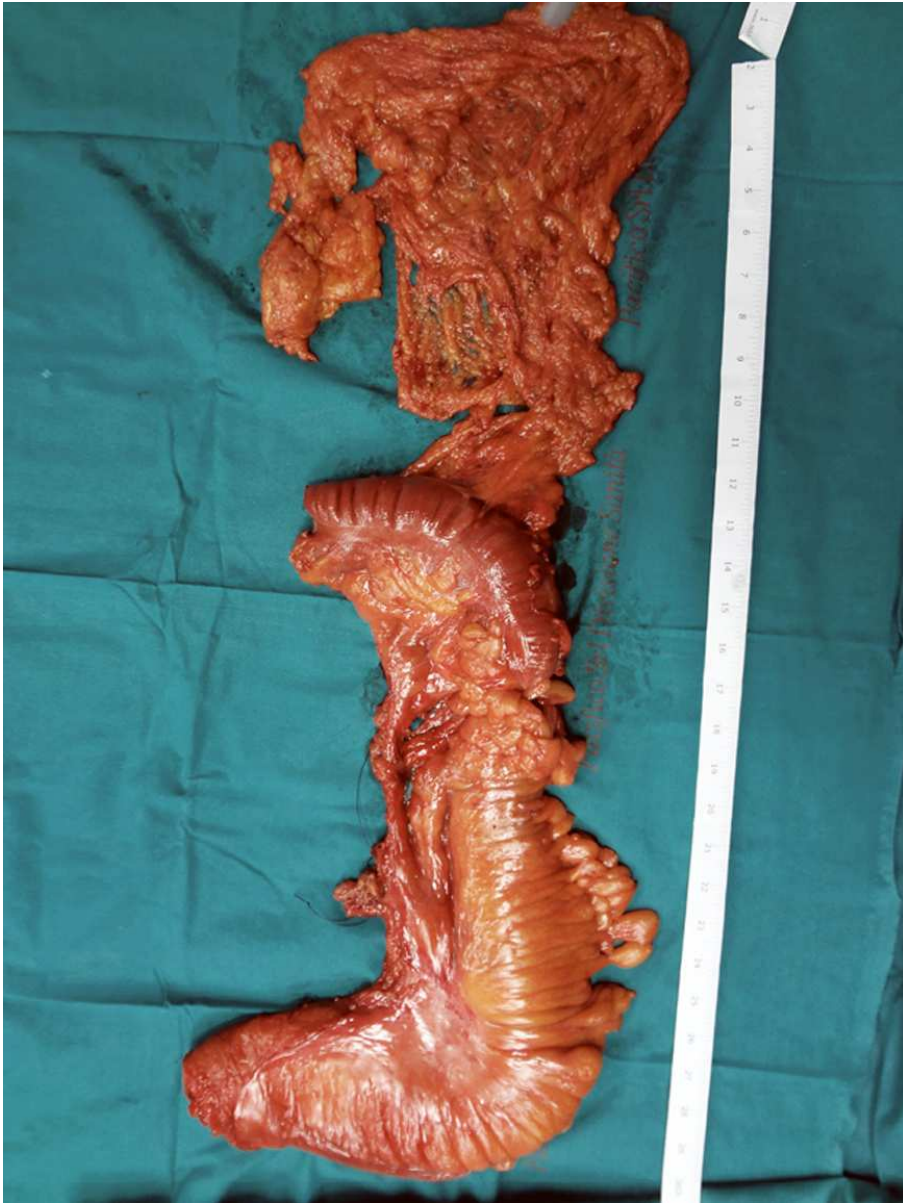
Isolamento arteria mesenterica inferiore



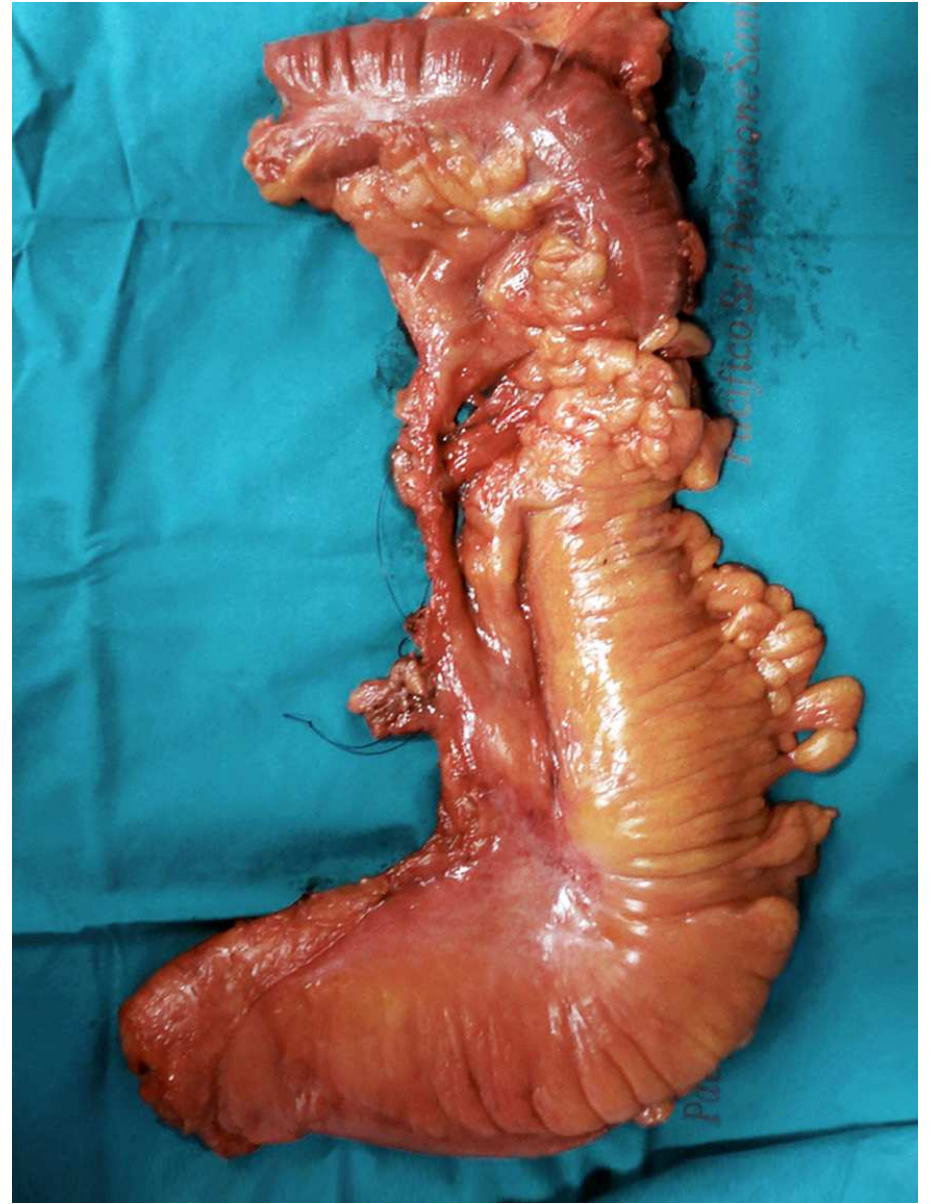
Asse aorto-cavale - Vena iliaca sn - Ureteri



Asse aorto-cavale - Vena renale, spermatica e iliaca sn - Ureteri

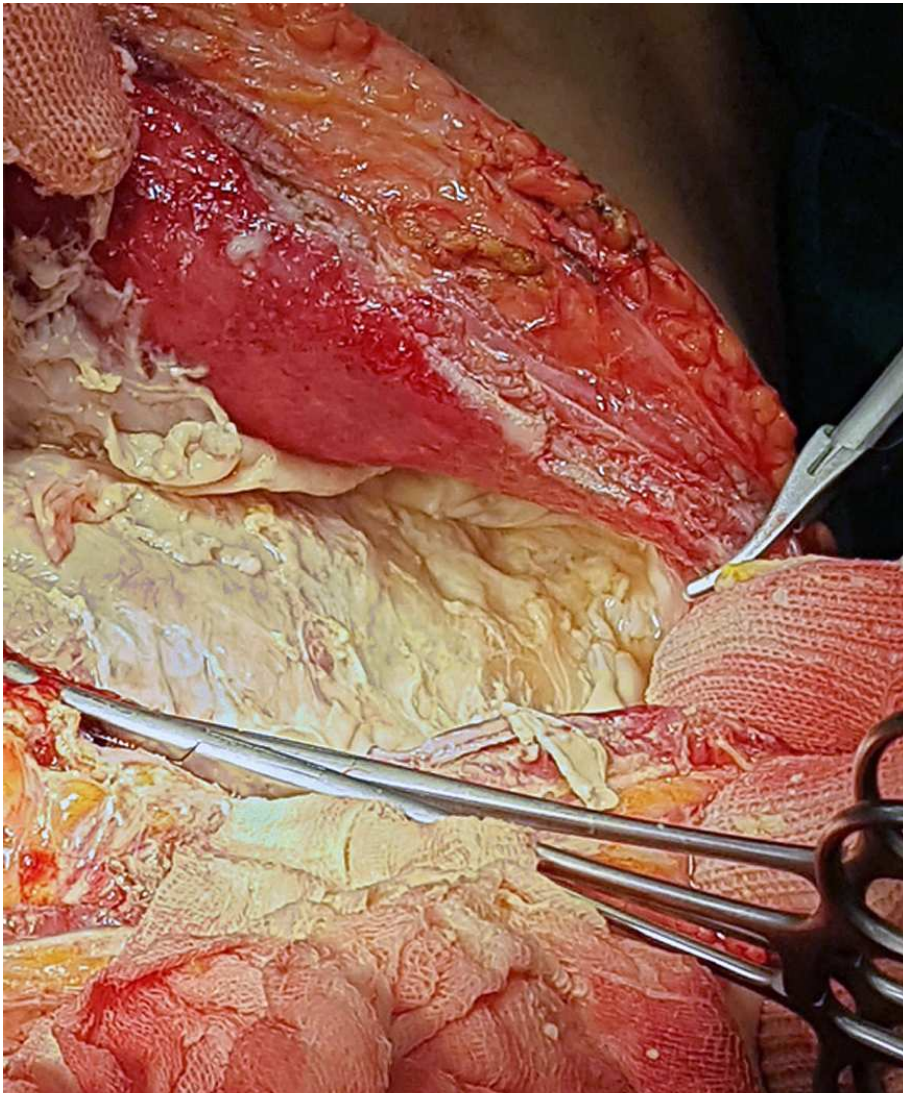


Emicolectomia sn típica con linfadenectomía lombo-aorto-iliaca e presacrale en bloc



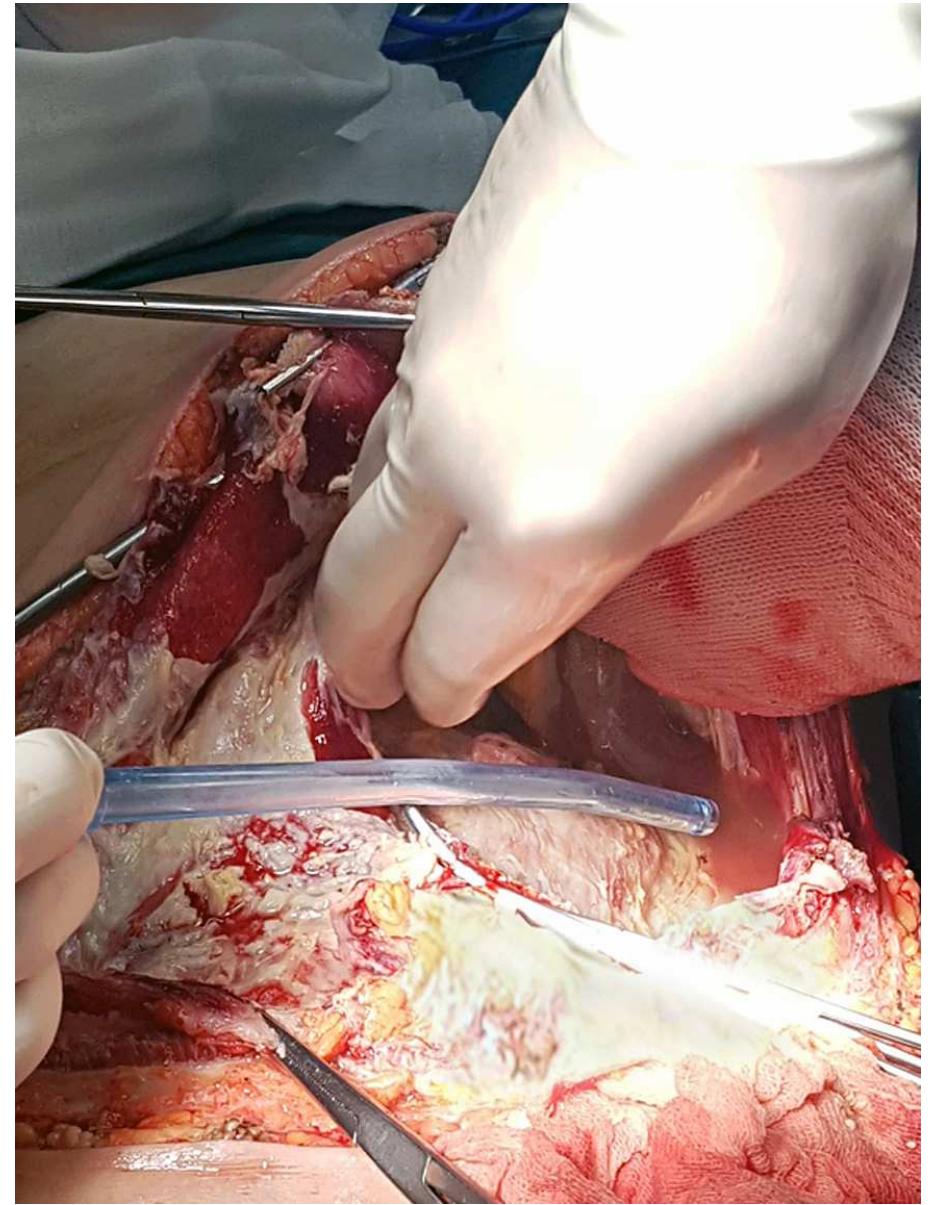Emicolectomia sn típica con linfadenectomía lombo-aorto-iliaca e presacrale en bloc



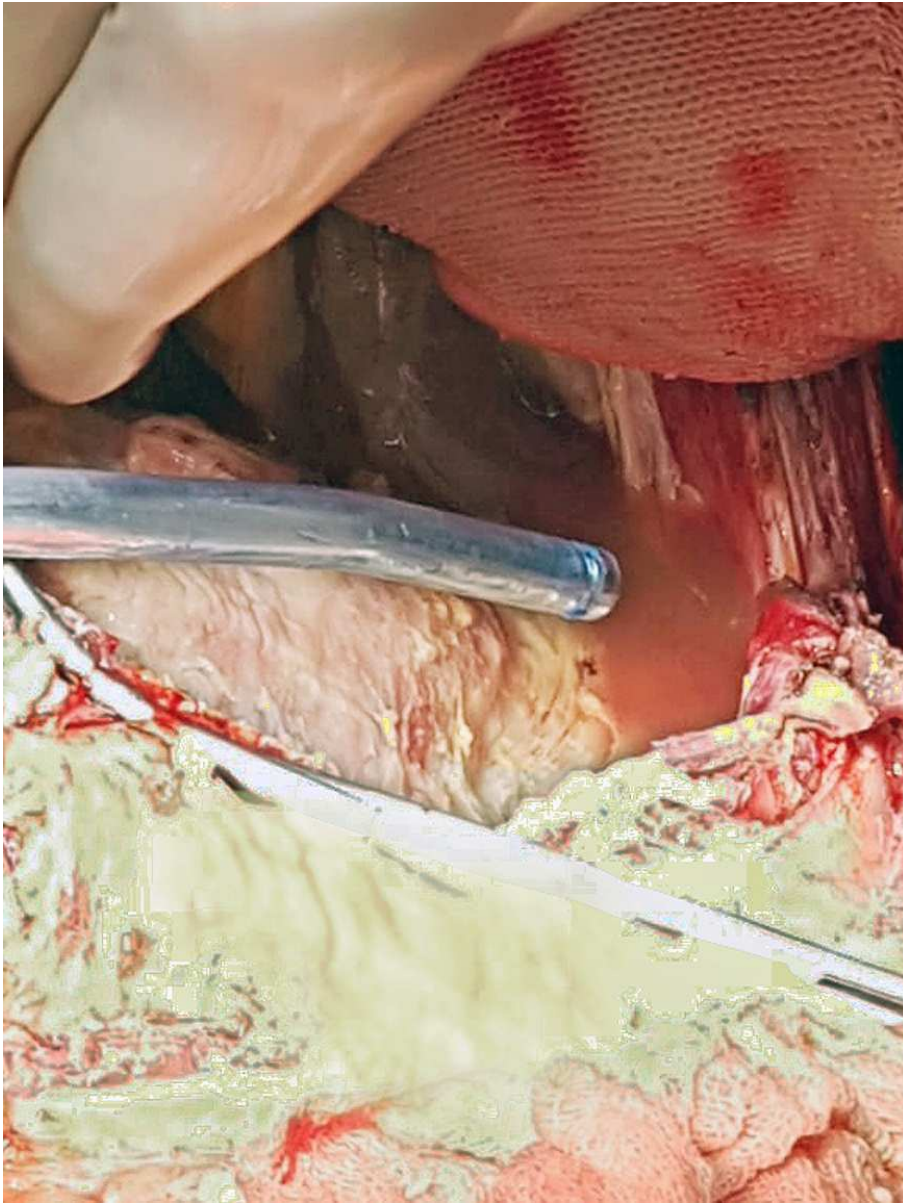

K.O. • Anni: 44 - F • Record: 2 • 04-02-2019

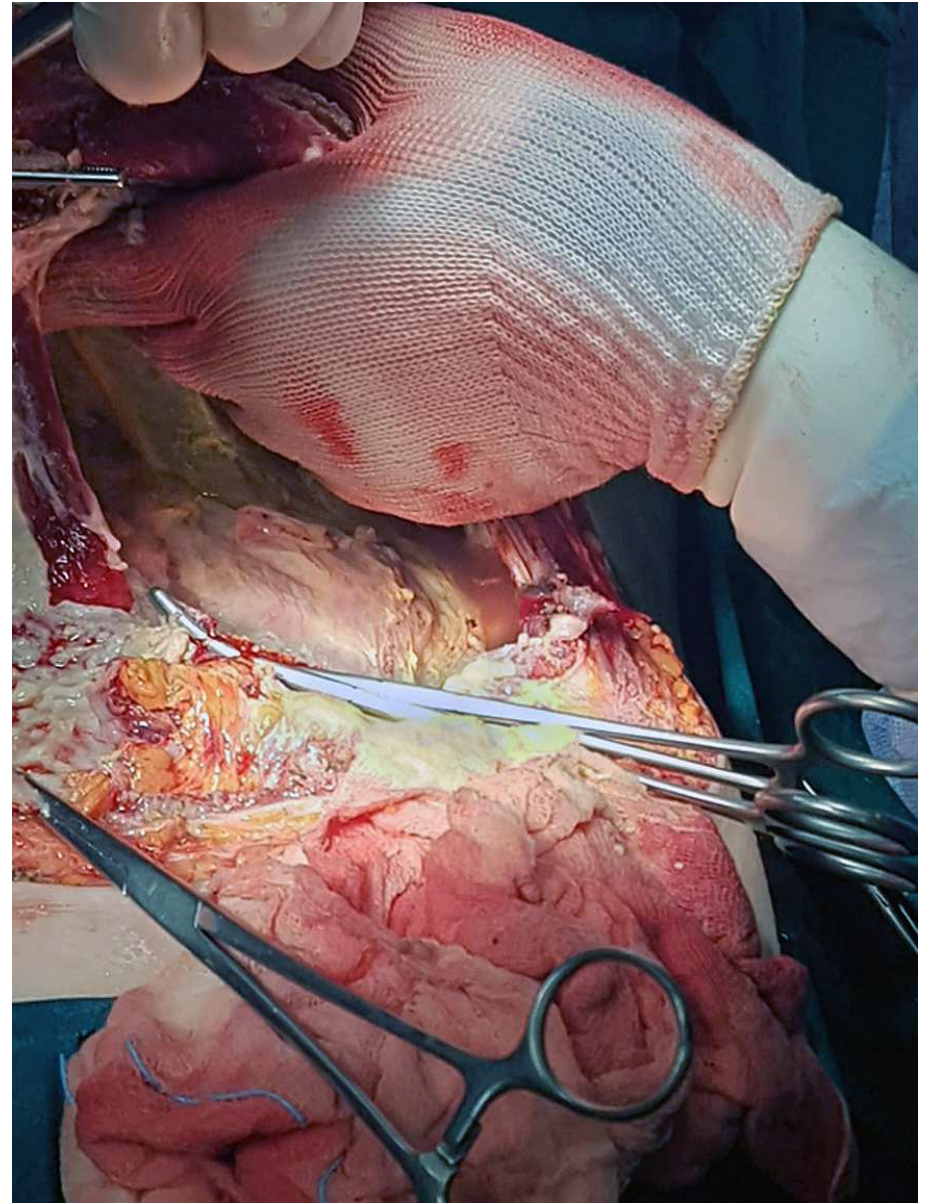
Cisto-digiunostomia transmesocolica per peritonite diffusa inveterata da rottura di pseudocisti del pancreas.



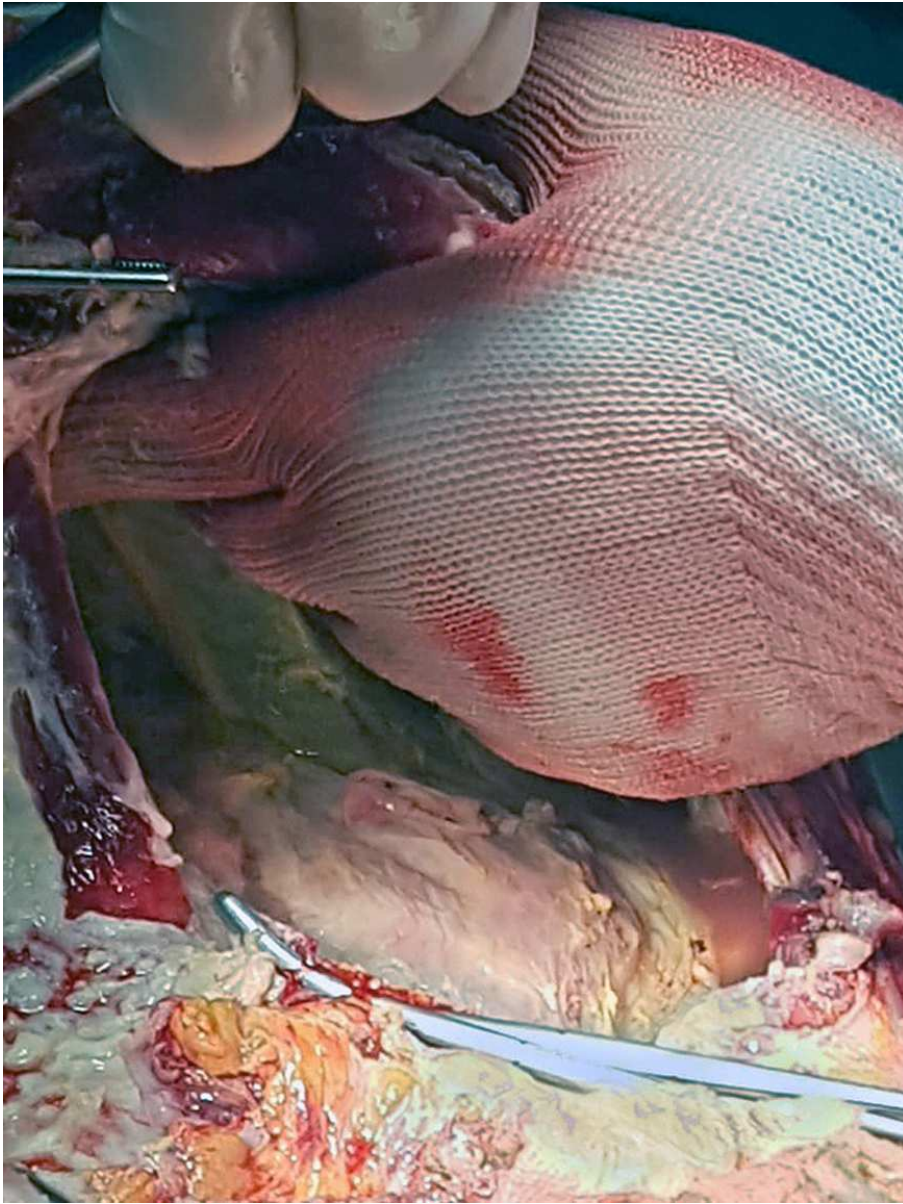
Laparotomia bisottocostale ed aspirazione di liquido pancreatico libero in cavità



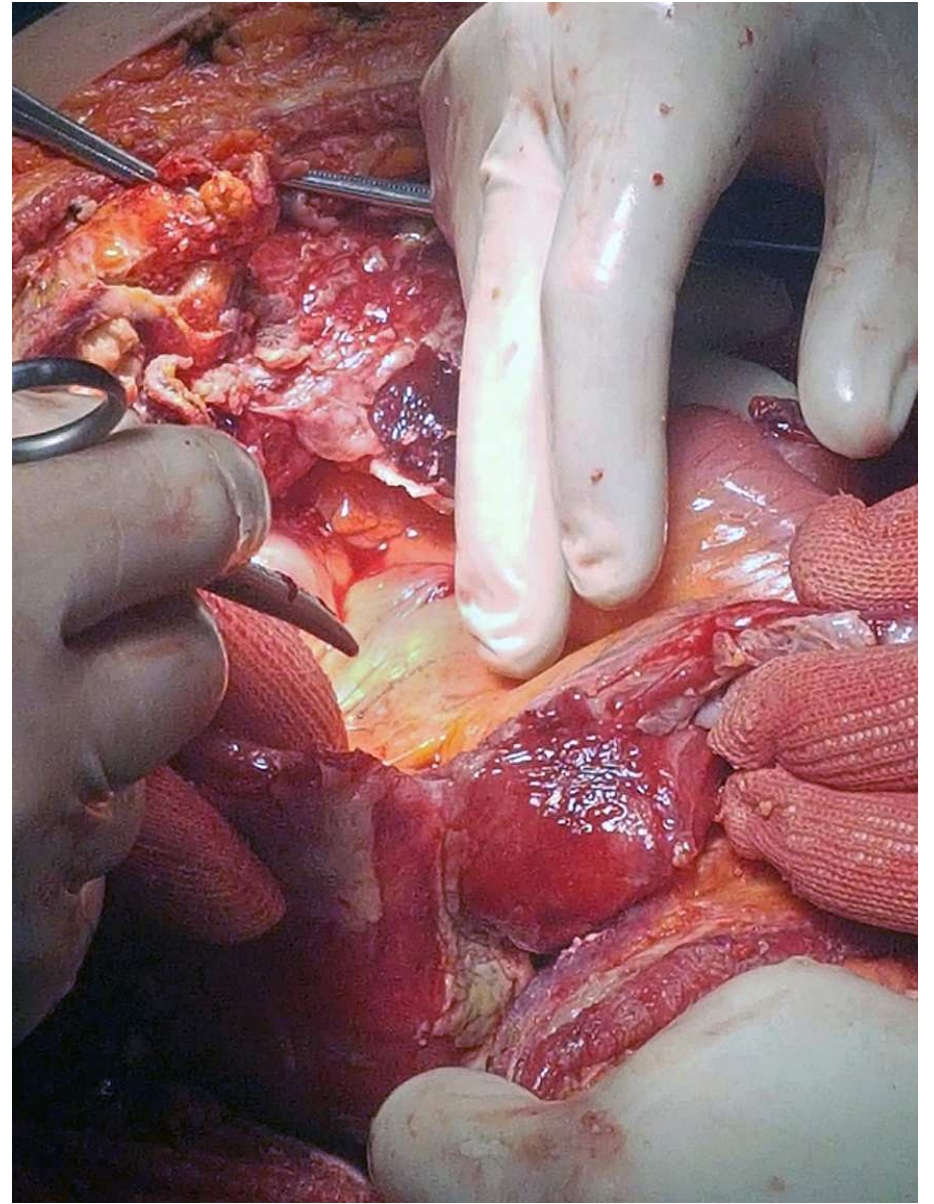
Aspirazione di liquido pancreatico libero in cavità



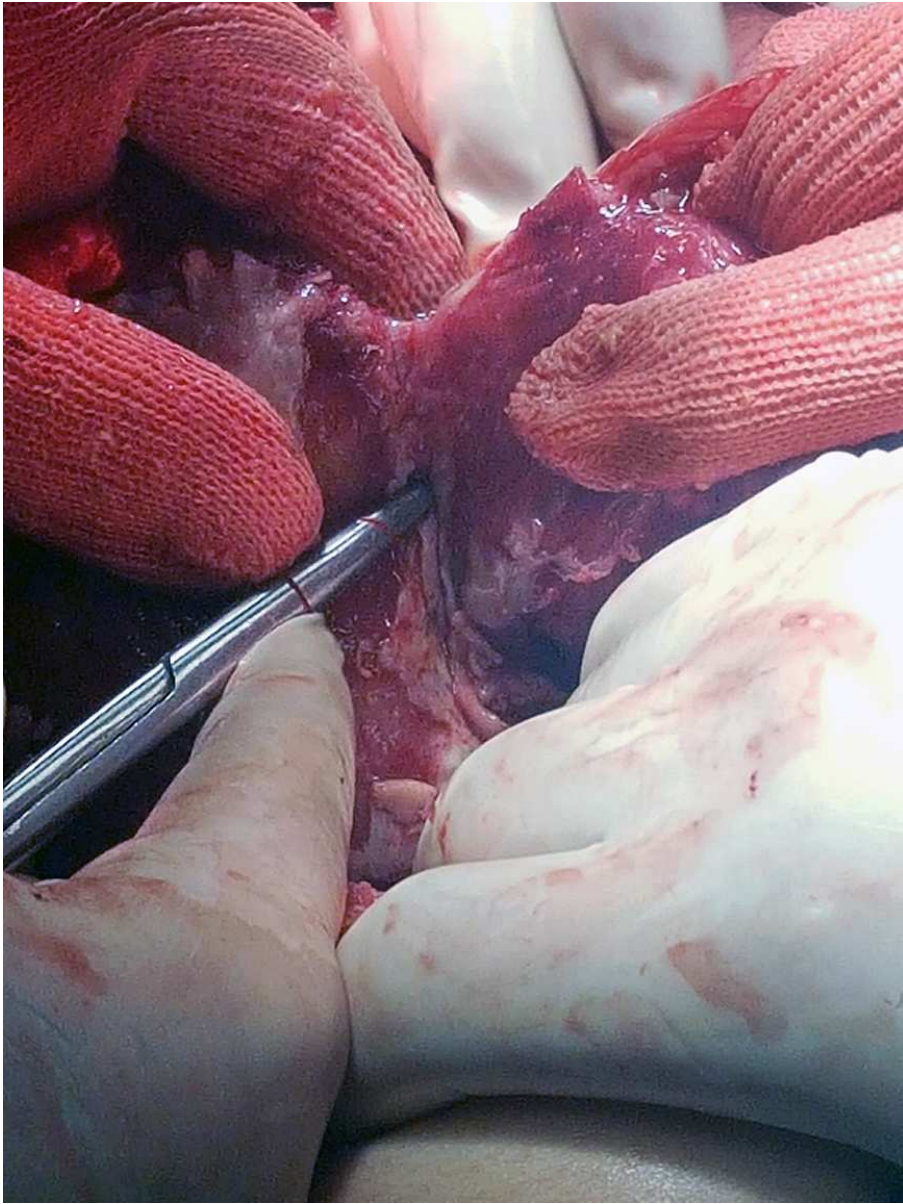
Isolamento dei visceri addominali



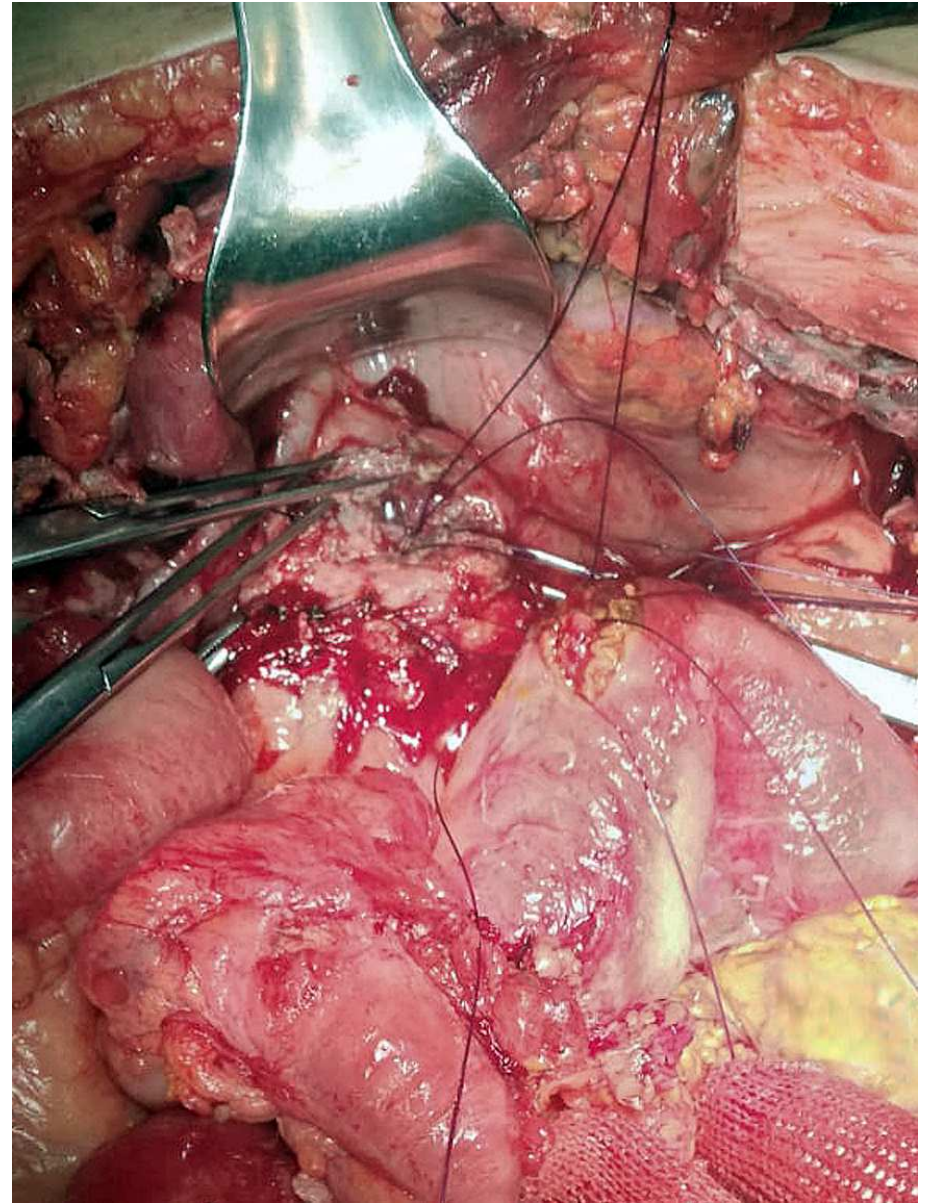
Liberazione delle tenaci aderenze da esiti di peritonite inveterata



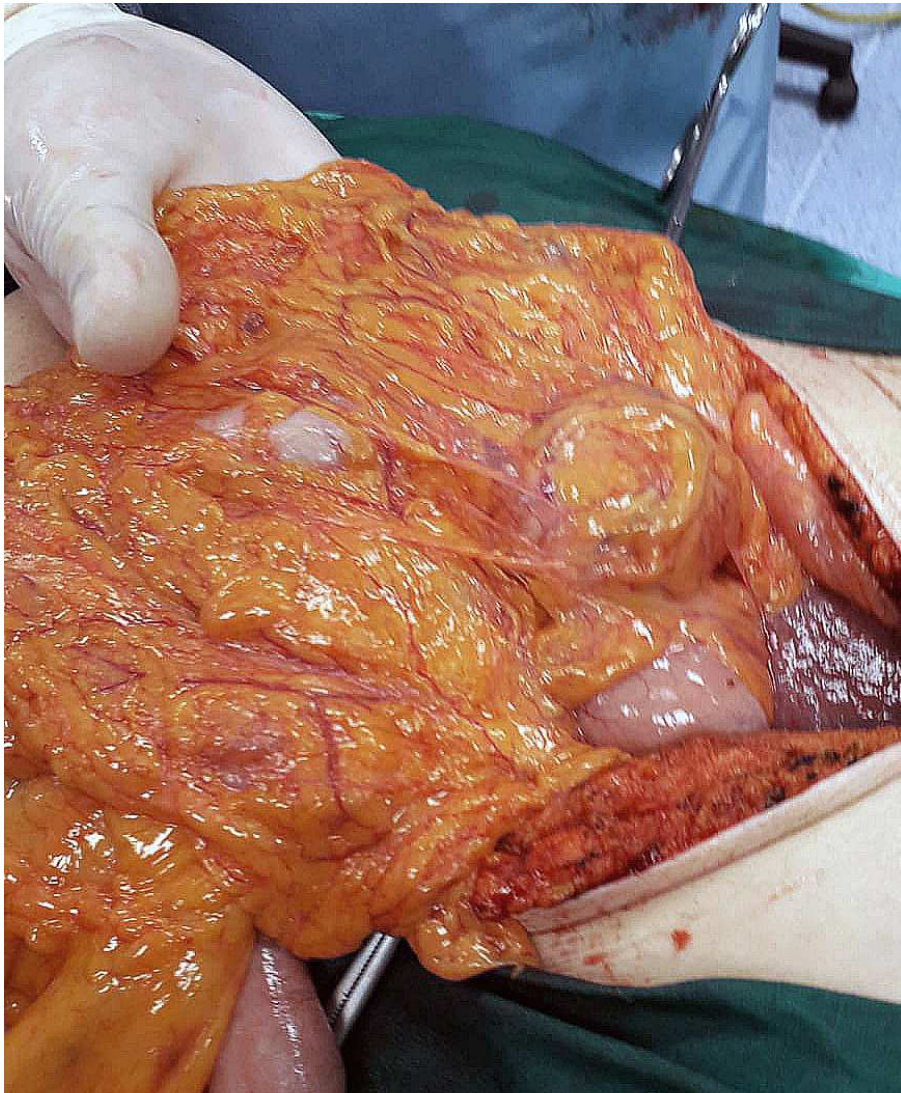Adesiolisi di anse ileali



Adesiolisi di anse ileali

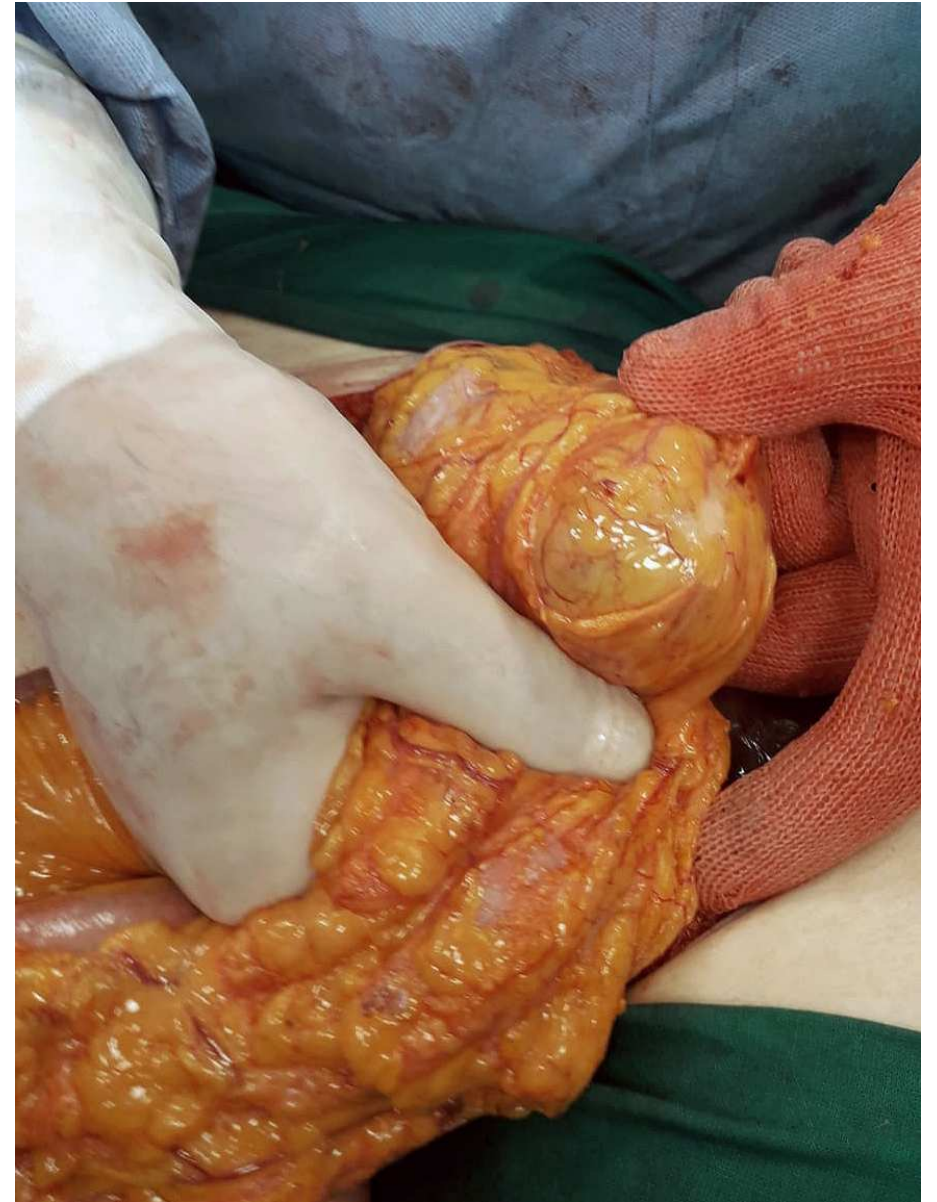

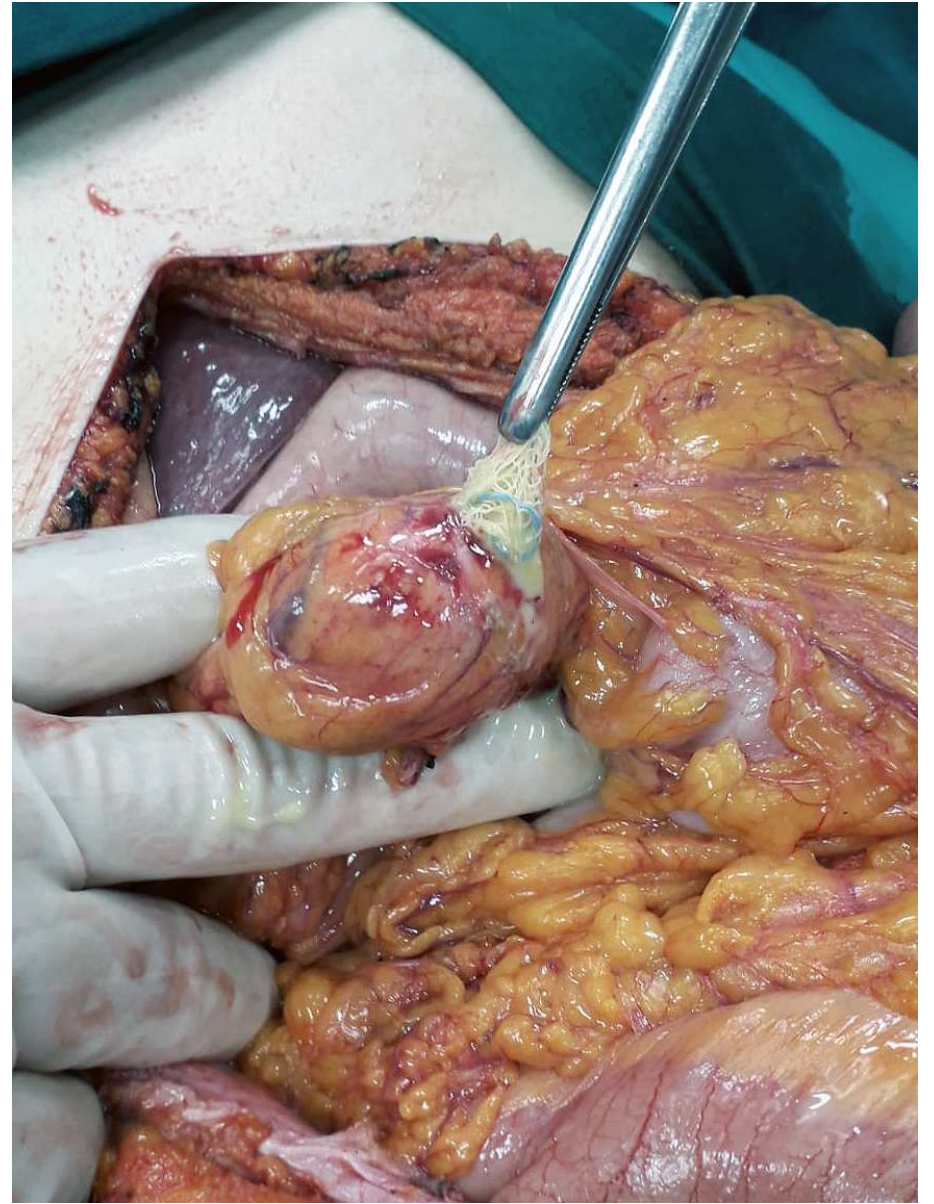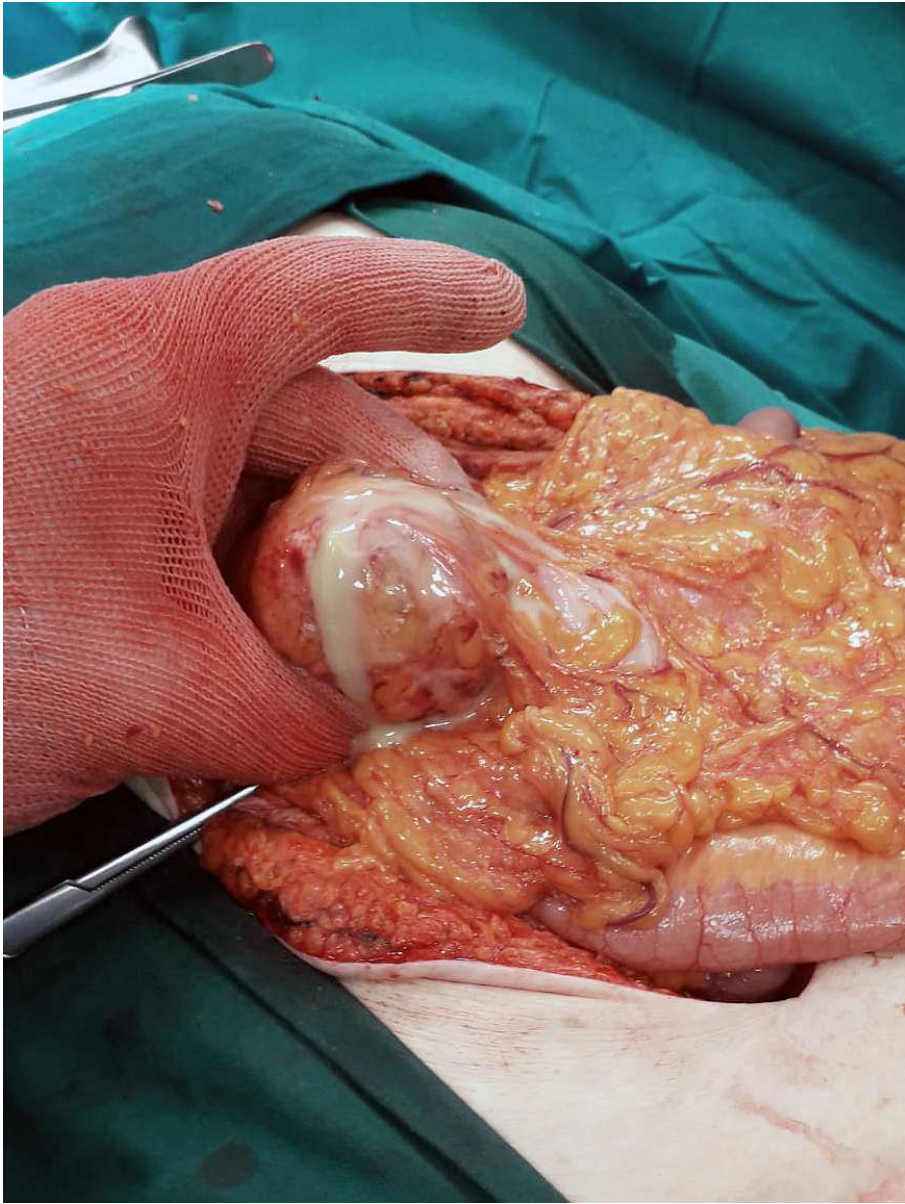Cisto-digunostomia

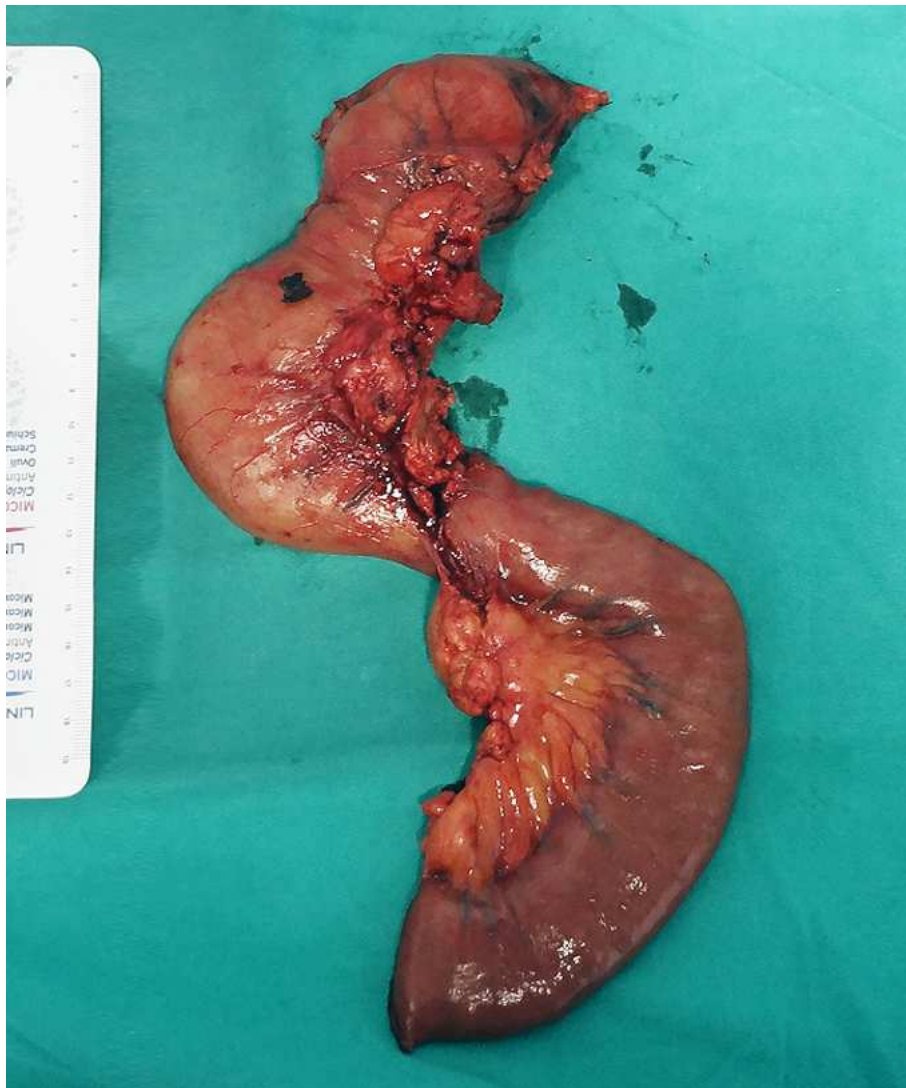

M.M.G. • Anni: 80 - F • Record: 3 • 06-03-2019

Rimozione corpo estraneo ritenuto in addome (batuffolo di garza) ed ernioalloplastica crurale sn properitoneale

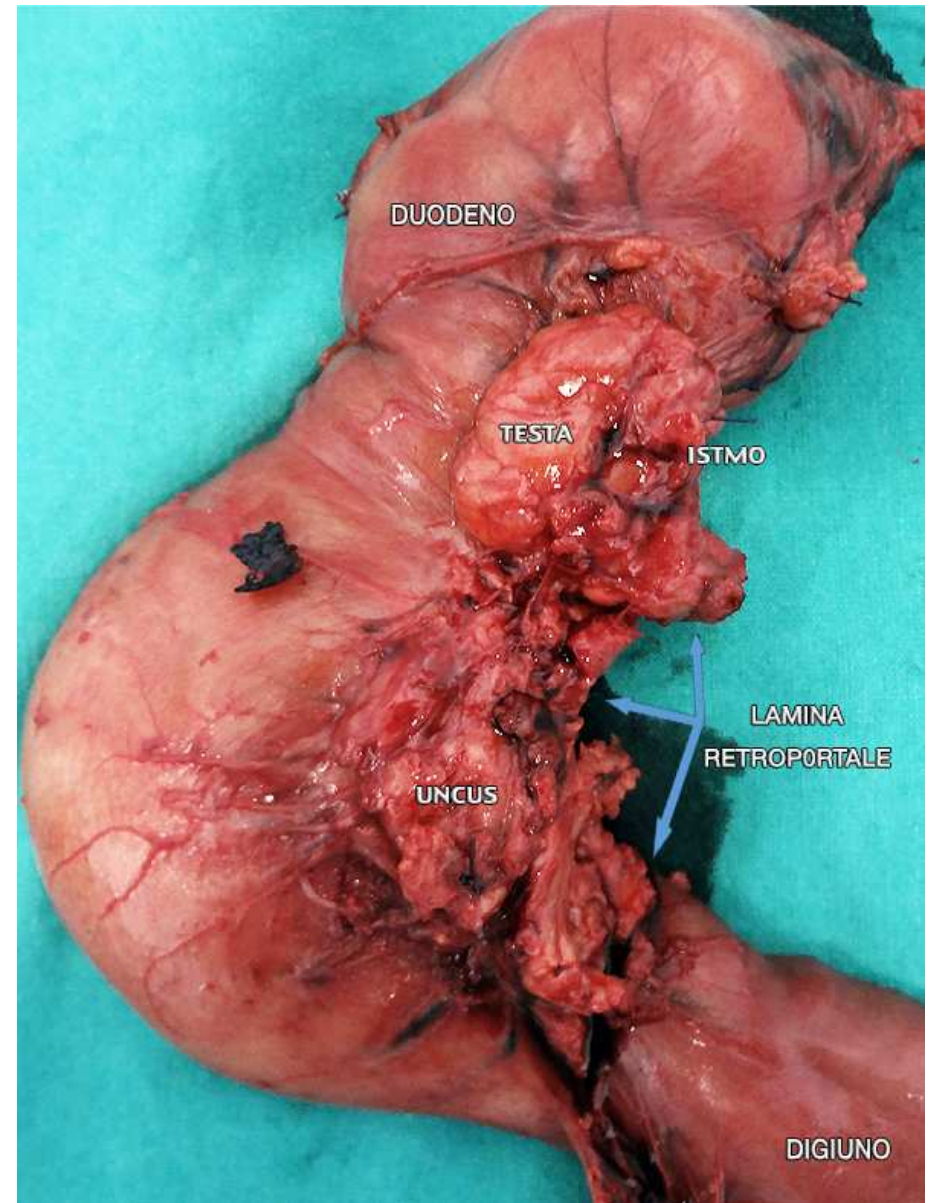




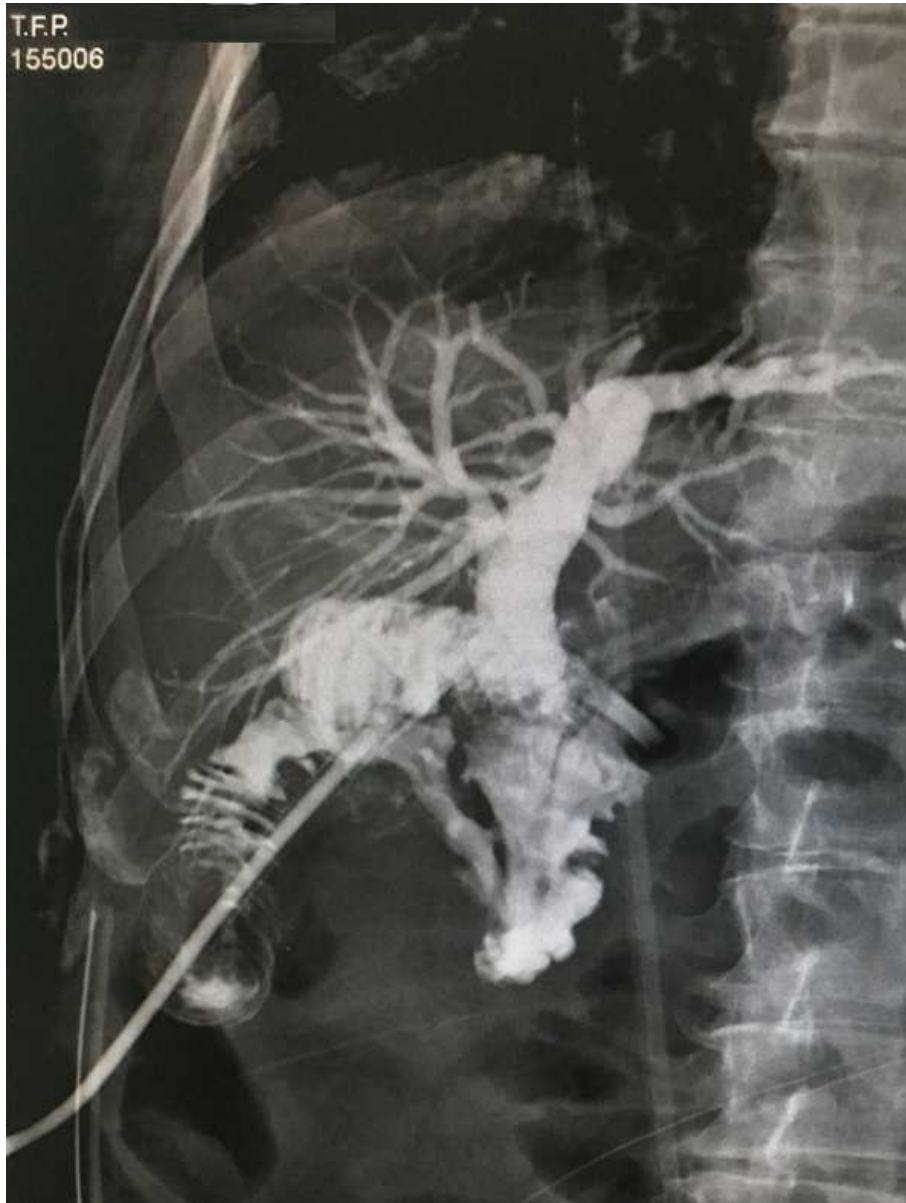

T.F.P. • Anni: 73 - M • Record: 4 • 29-03-2019

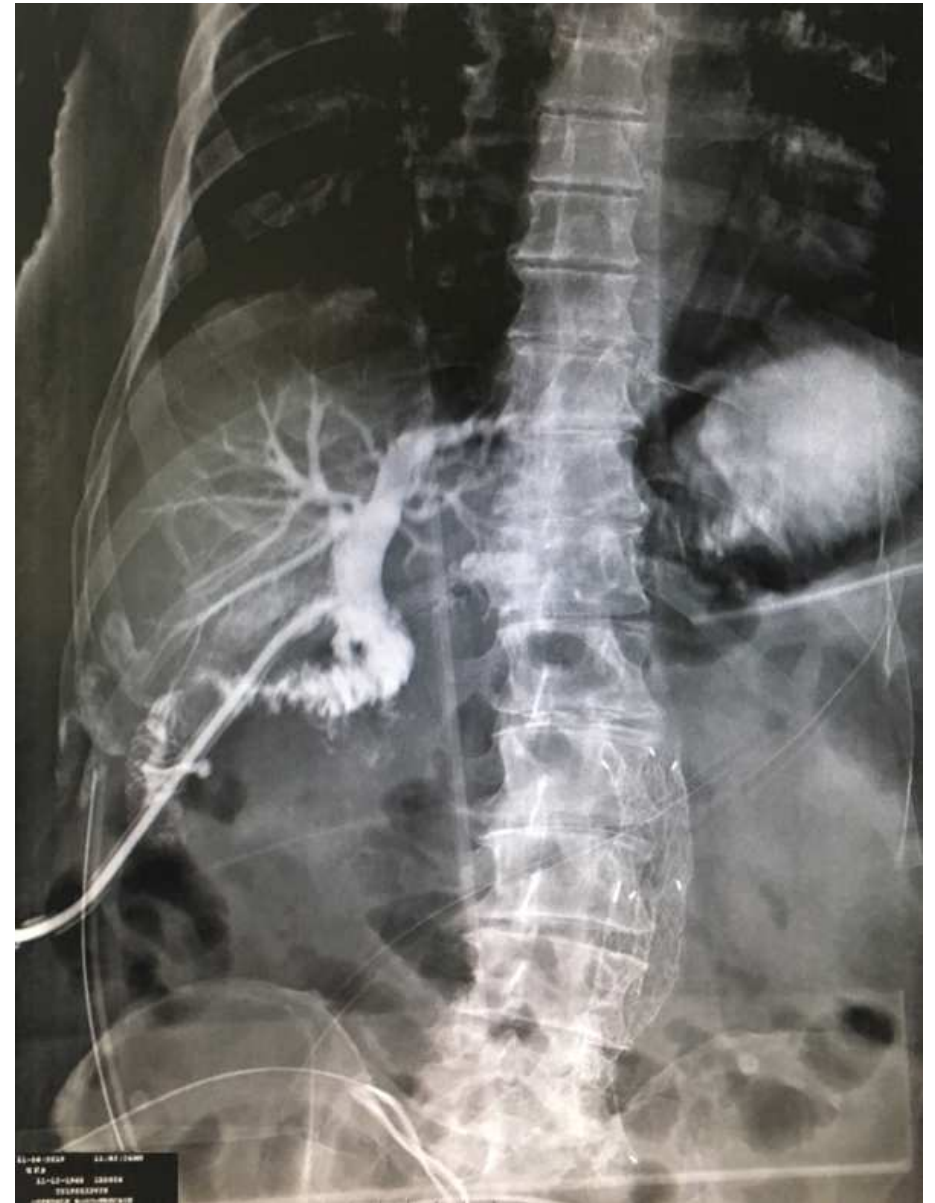Duodenocefalopancreatectomia sec. Kausch-Whipple con anastomosi digiunopancreatica T-T su tutore a perdere nel Wirsung, epatico-digiunale T-L, gastro-digiunale L-L e colecistectomia per ittero ostruttivo da adenocarcinoma duttale (G2-G3) della testa del pancreas e metastasi linfonodali (pT3N1)



Duodenocefalopancreasectomia sec. Kausch-Whipple

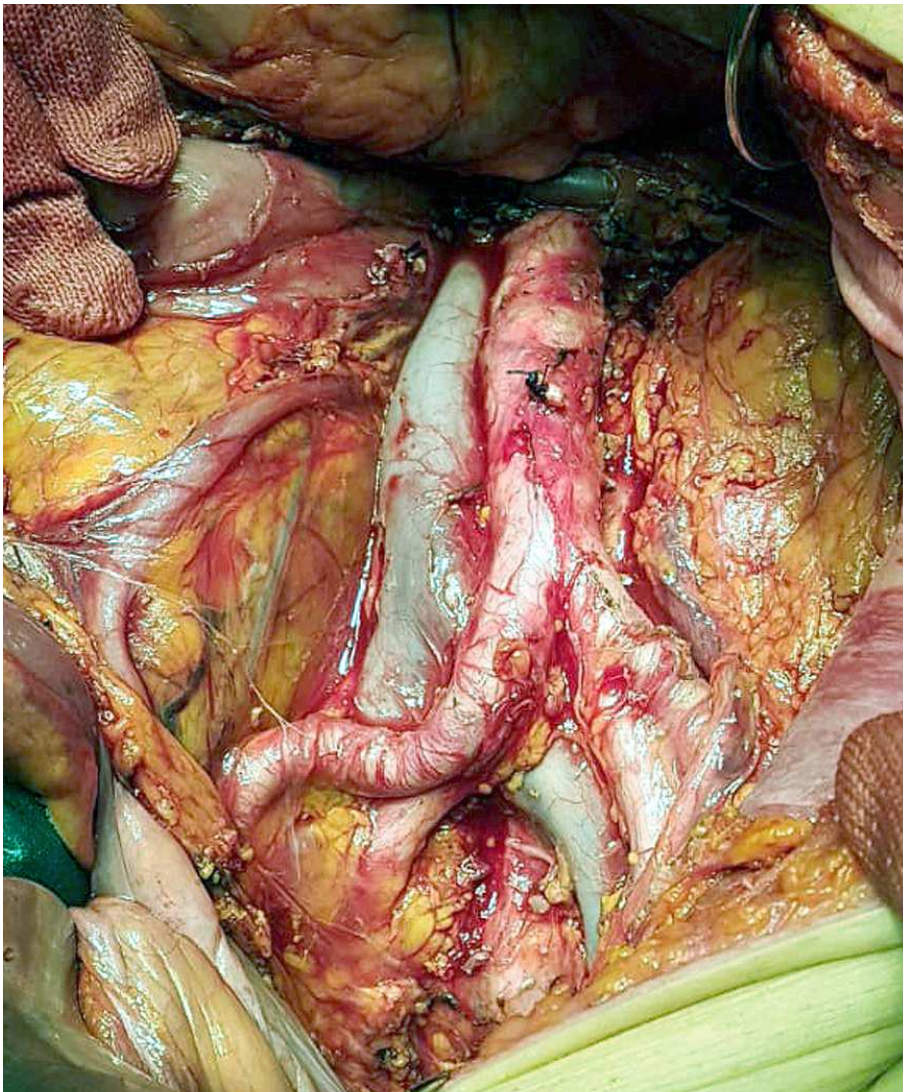


Colangiografia post-operatoria trans-Kehr



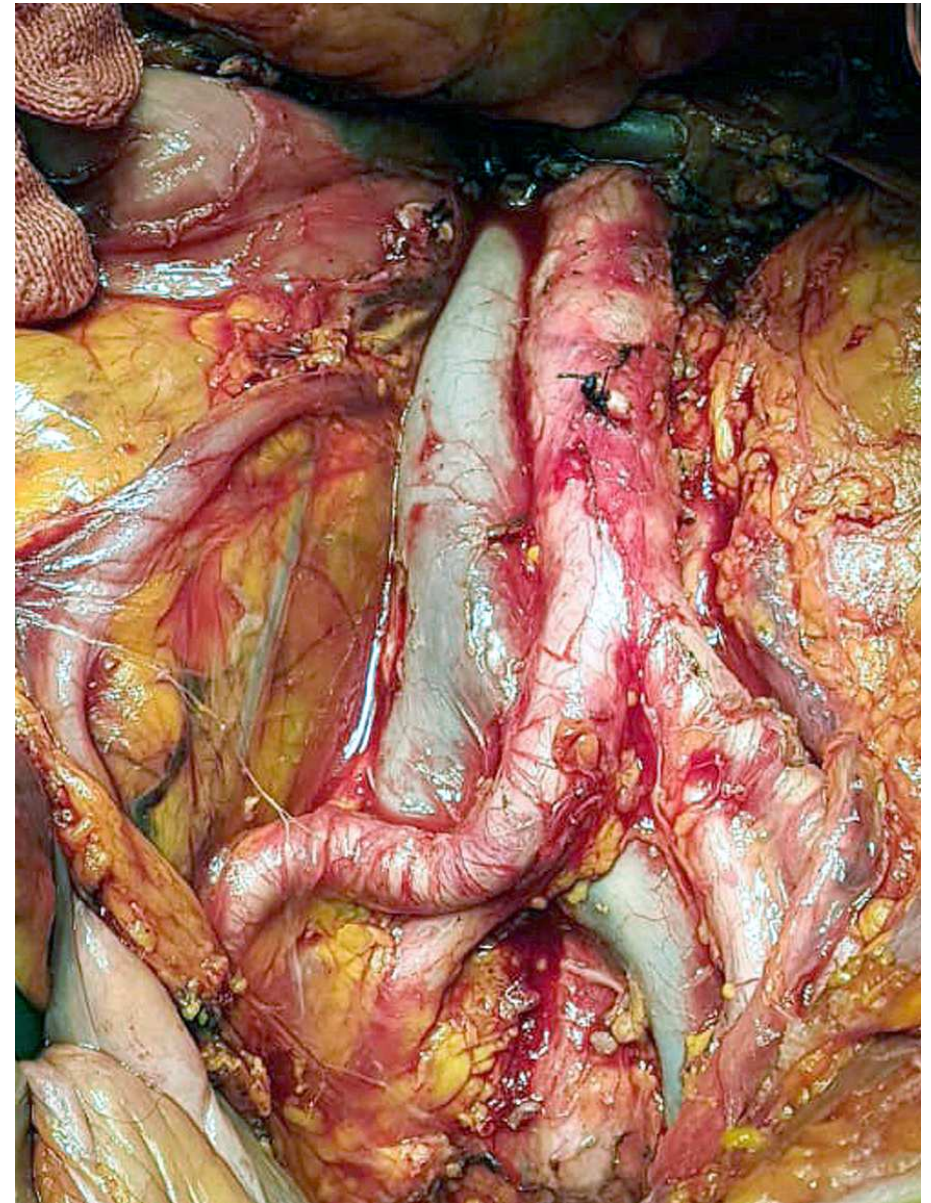
Colangiografia post-operatoria trans-Kehr

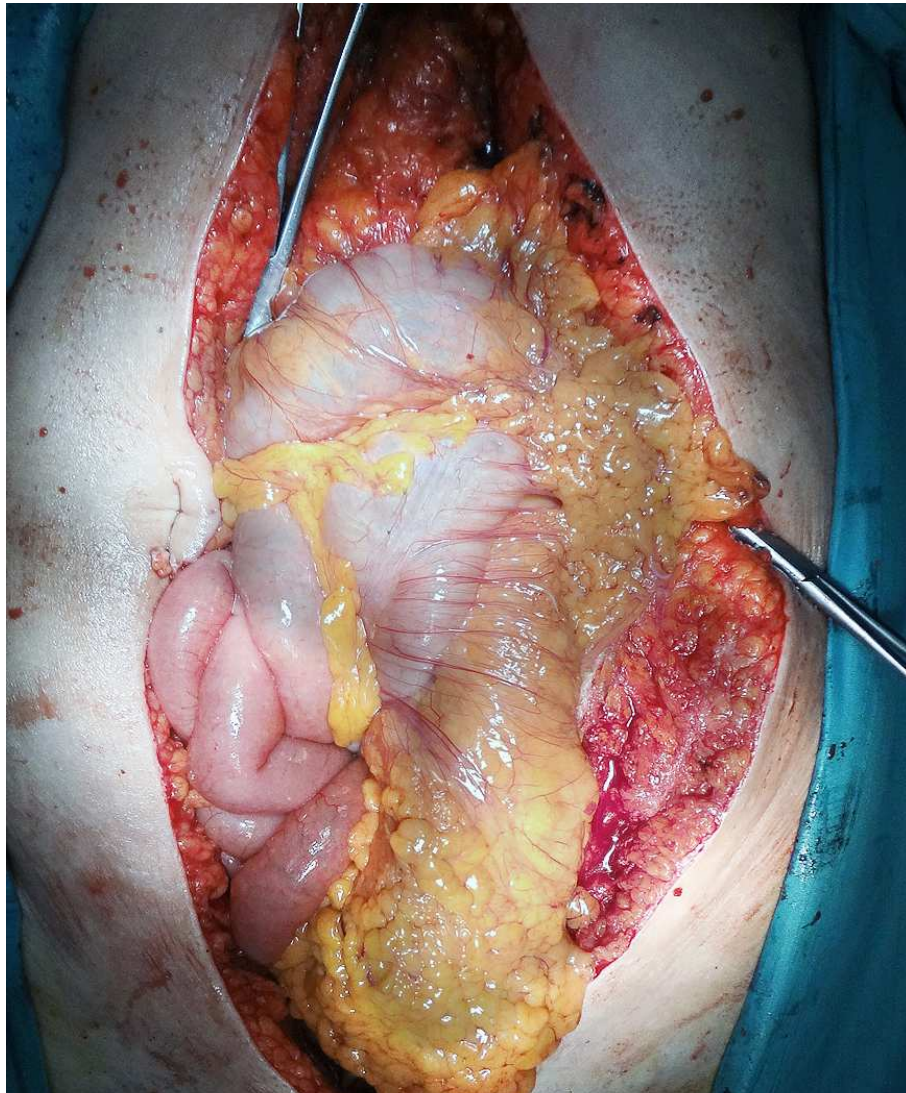



M.B. • Anni: 76 - M • Record: 5 • 27-05-2019

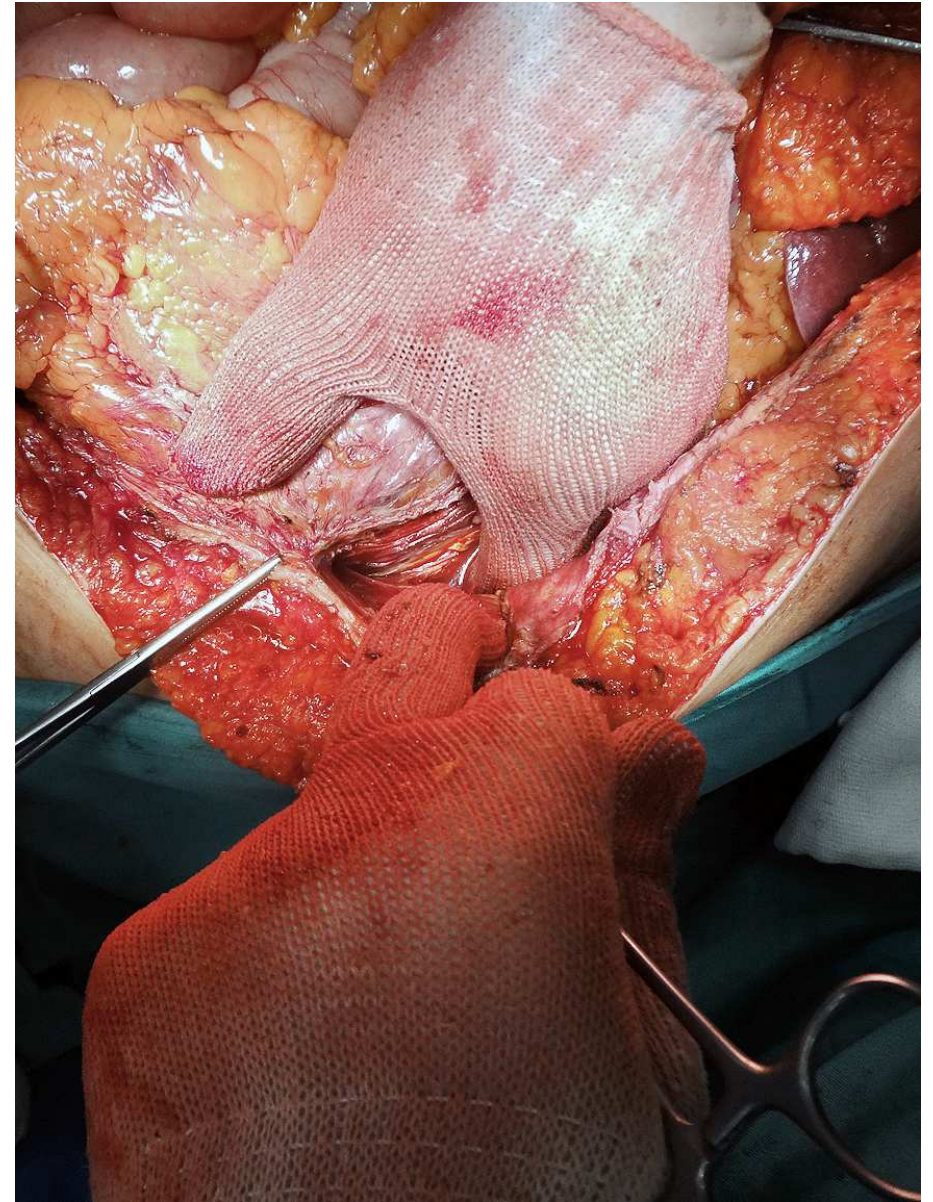
Linfoadenectomia lombo-aorto-iliaca bilaterale e presacrale nerve sparing en bloc in emicolectomia sn allargata al III° medio del trasverso per occlusione intestinale da adenocarcinoma vegetante, ulcerato e stenosante del discendente-sigma

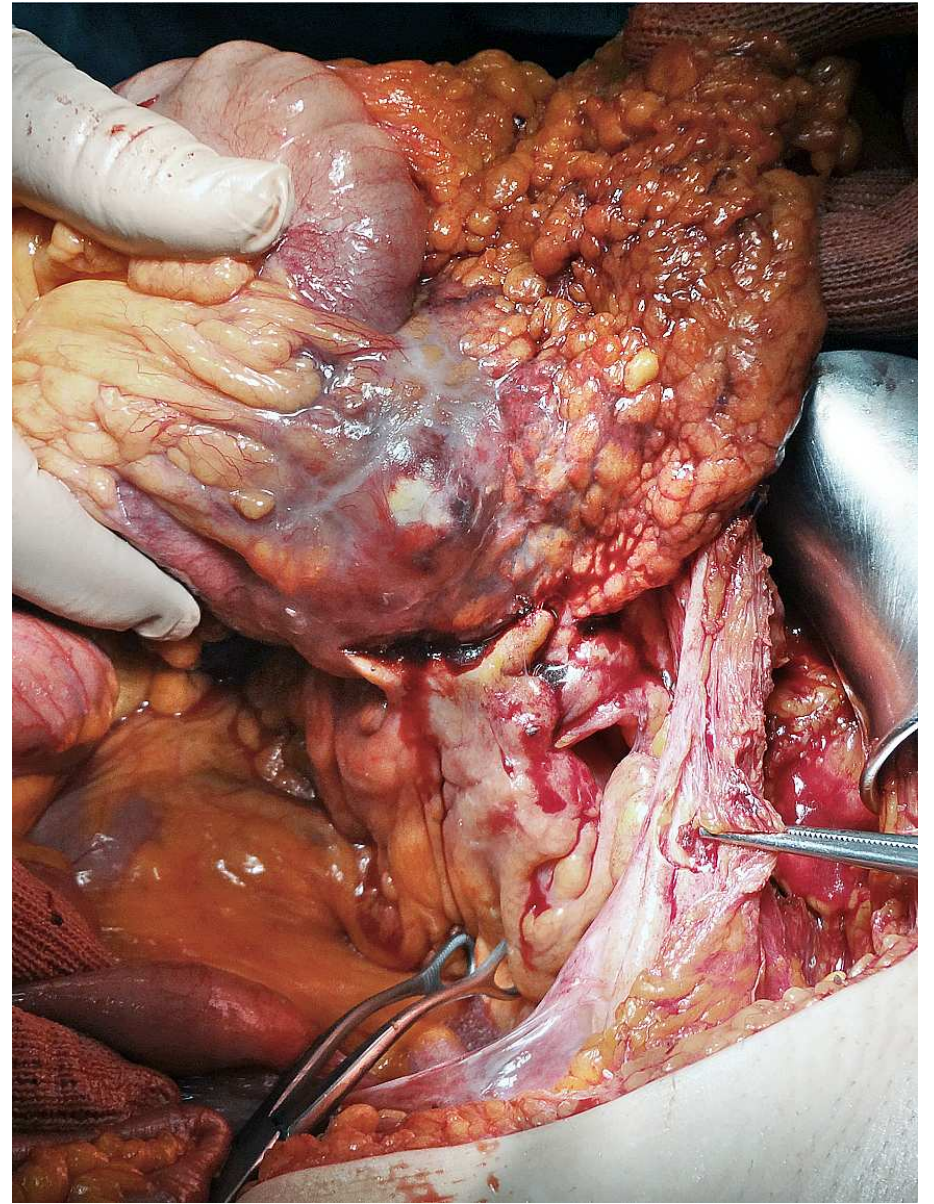
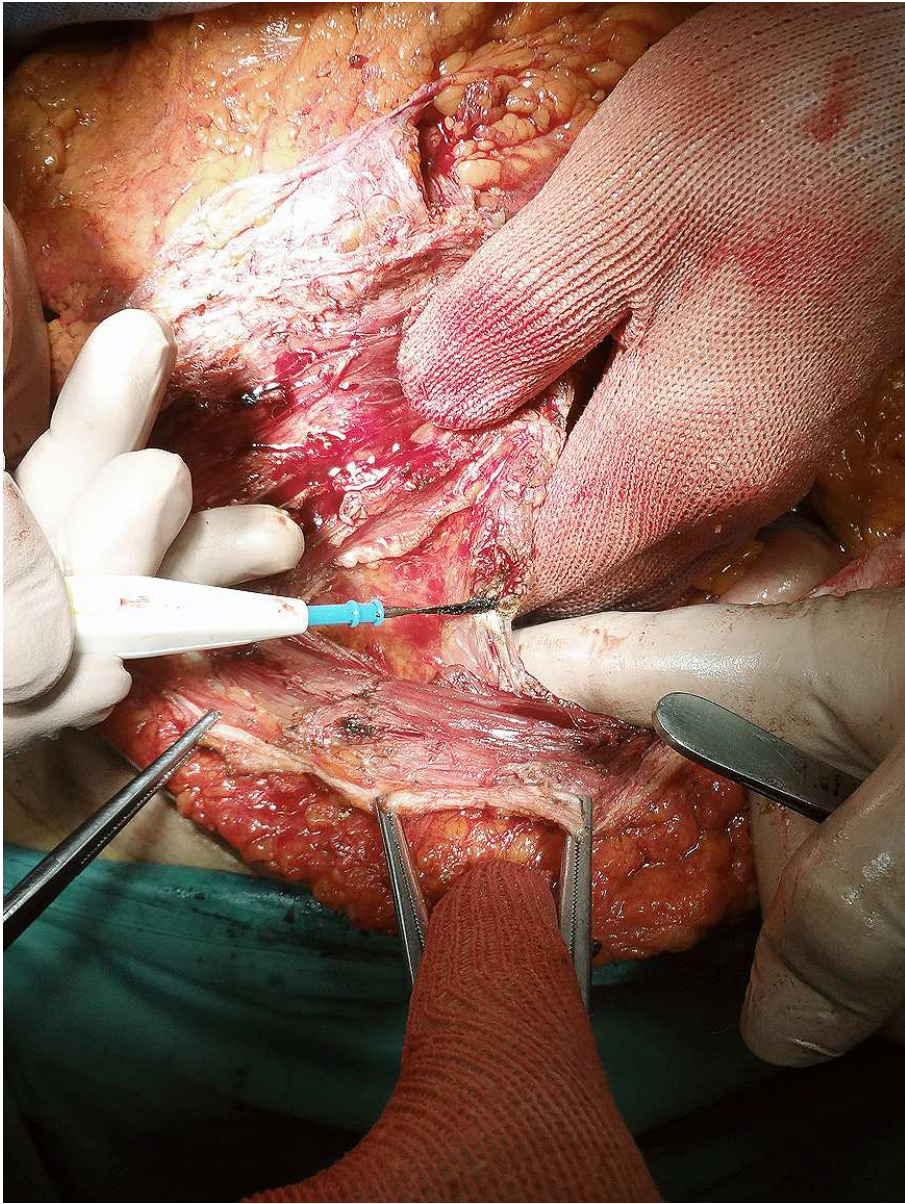


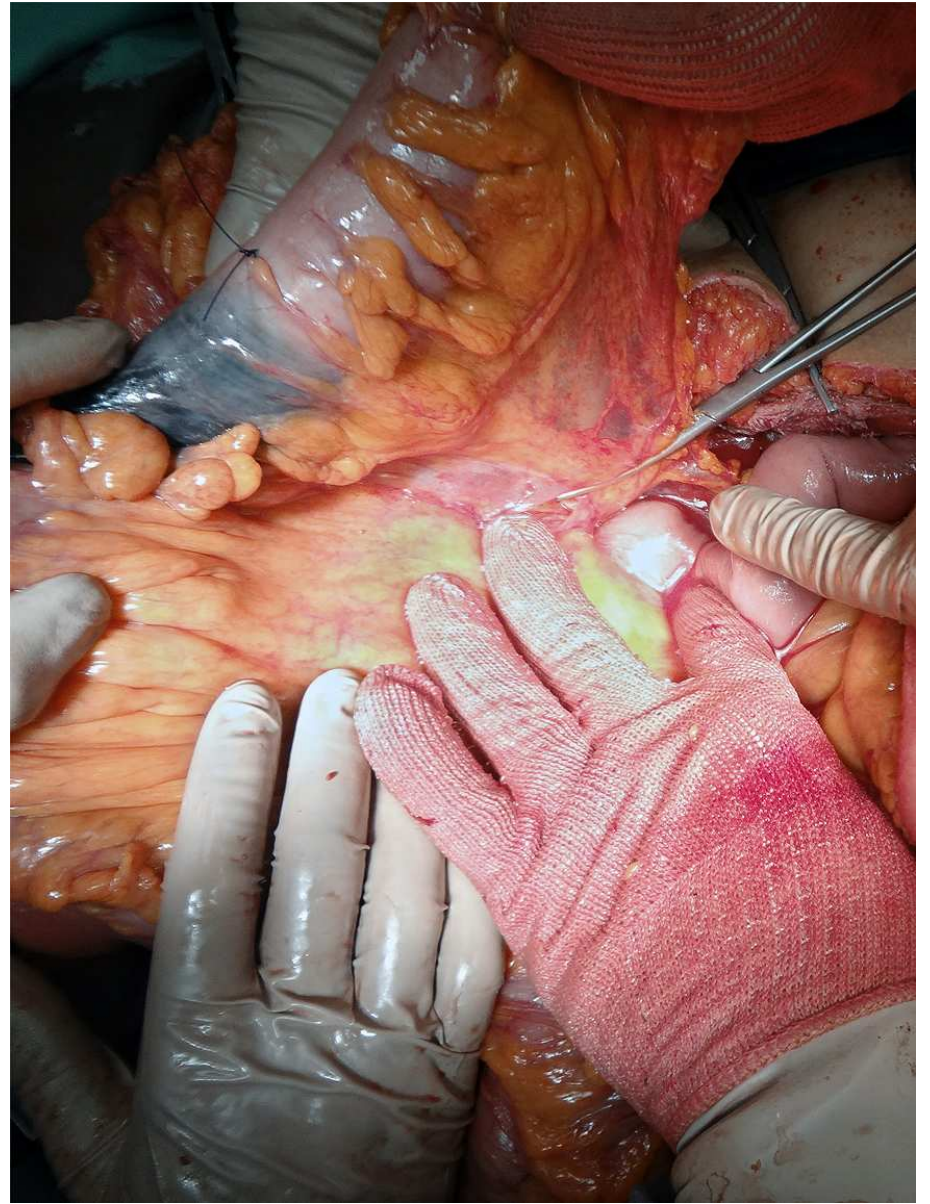
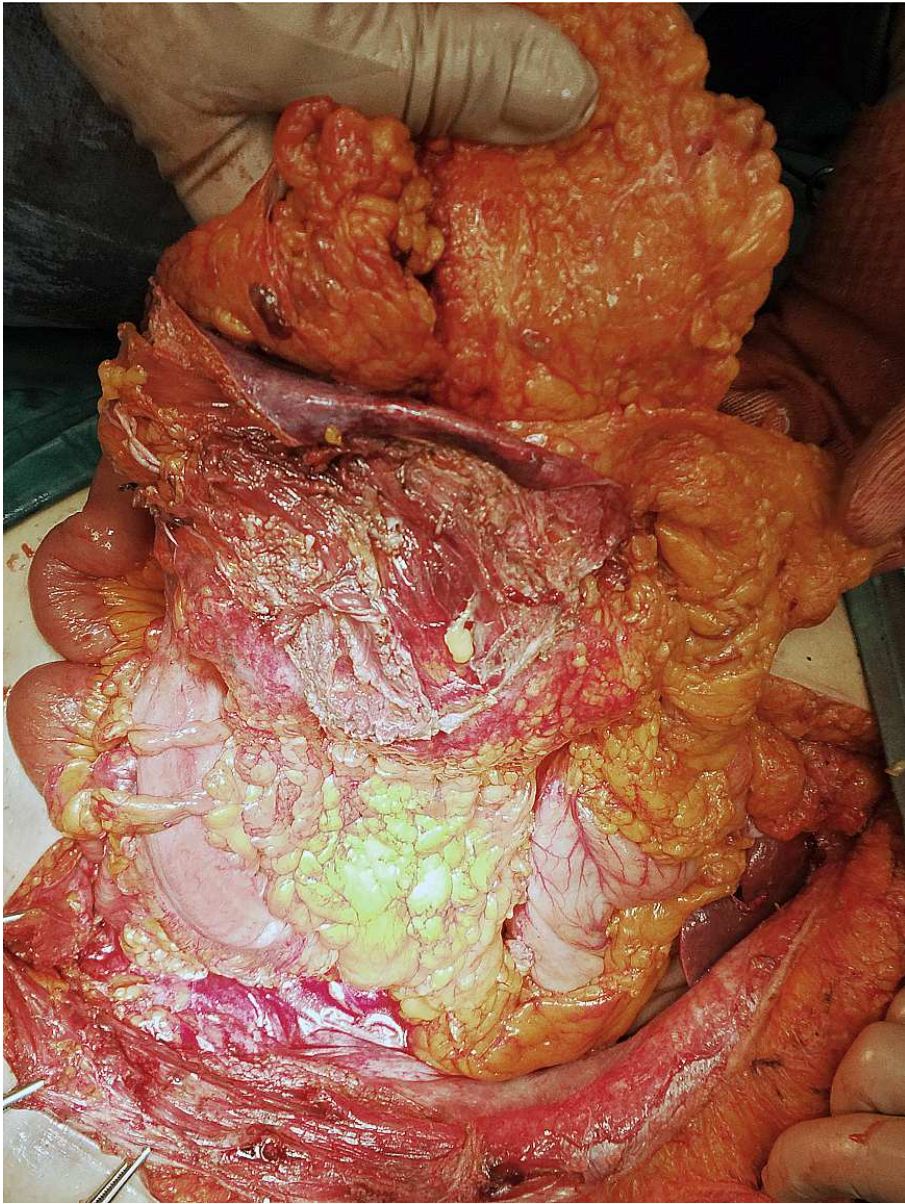


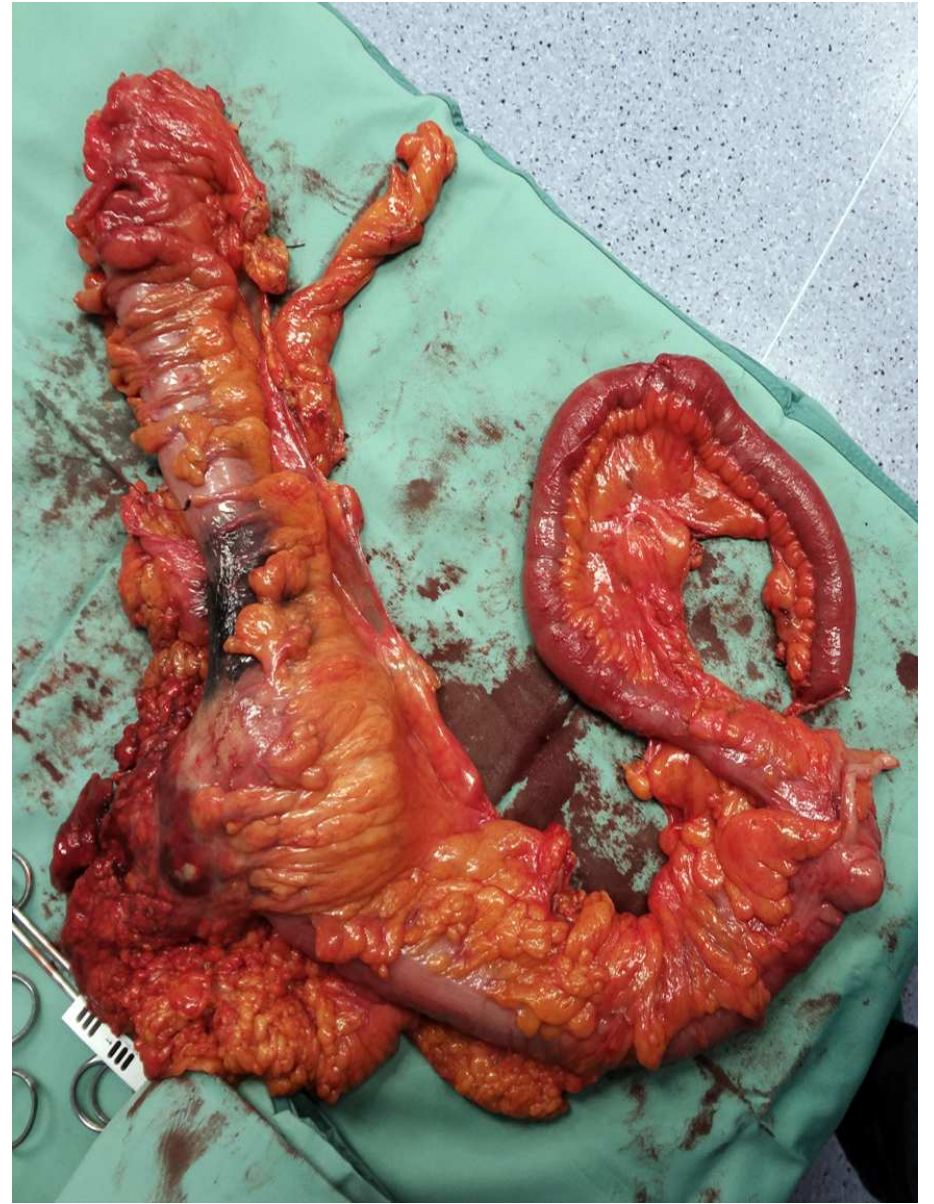
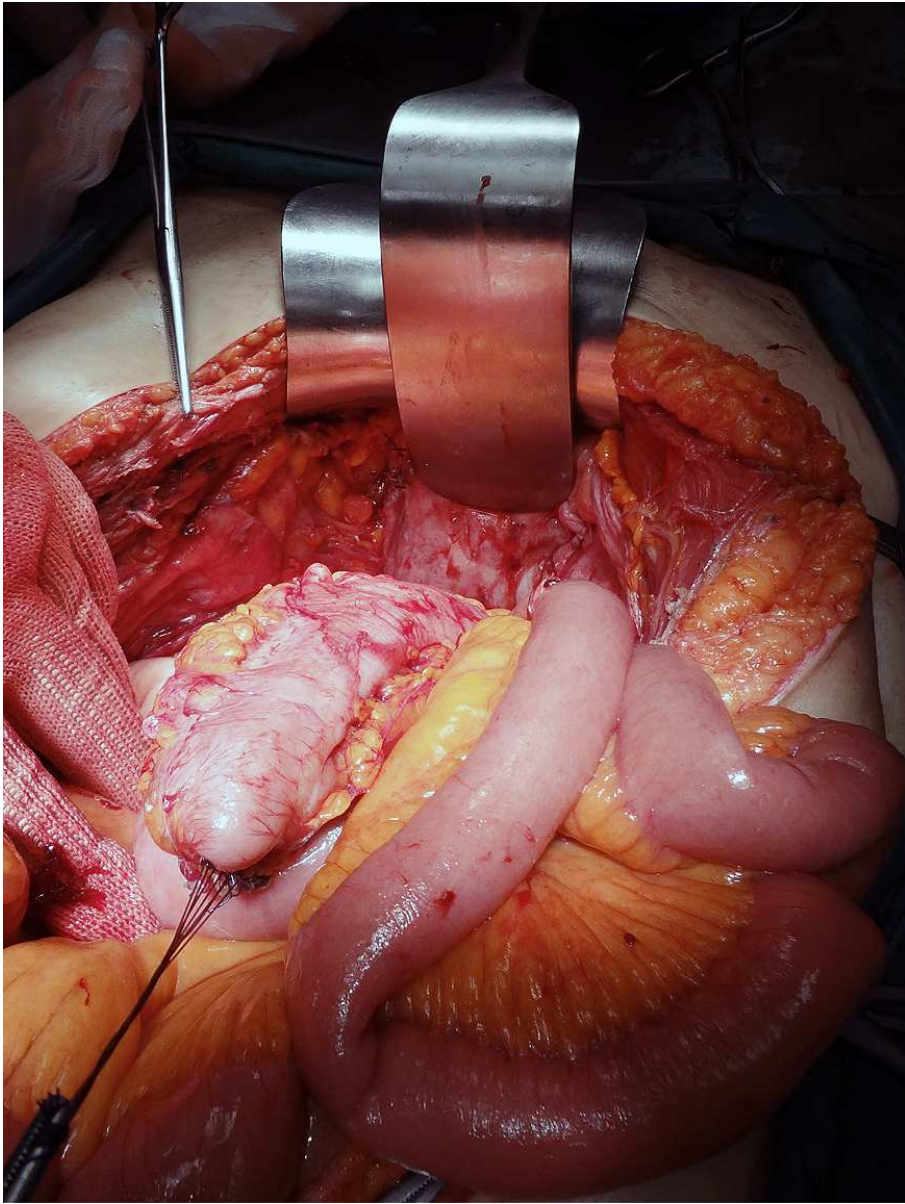
R.V. • Anni: 66 - F • Record: 6 • 05-07-2019

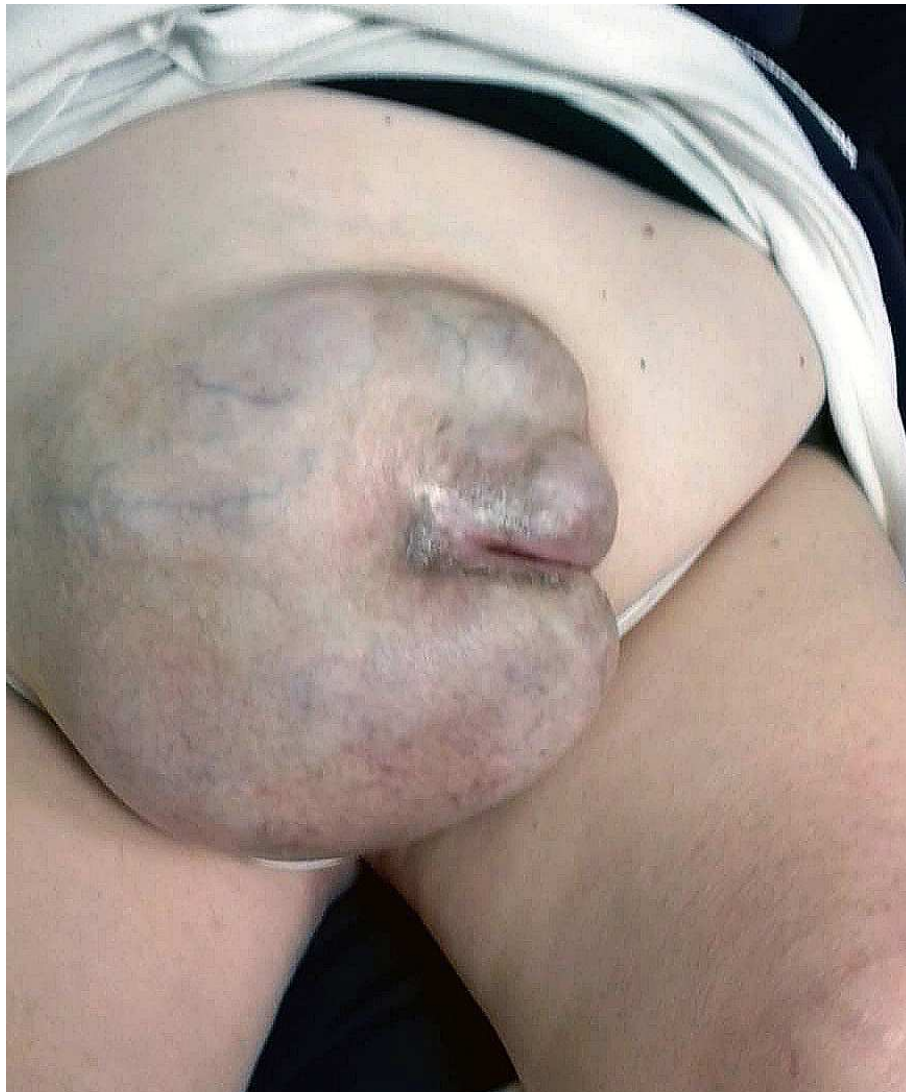
Emicolectomia dx allargata al discendente-sigma con epiploiectomia, rese-zione in massa della parete addominale anteriore sn e della cupola vescicale, linfadenectomia perimesenterica superiore, inferiore e gastro-epiploica dx con ileo-sigmoidostomia L-L e cistorrafia per adenocarcinoma del colon trasverso





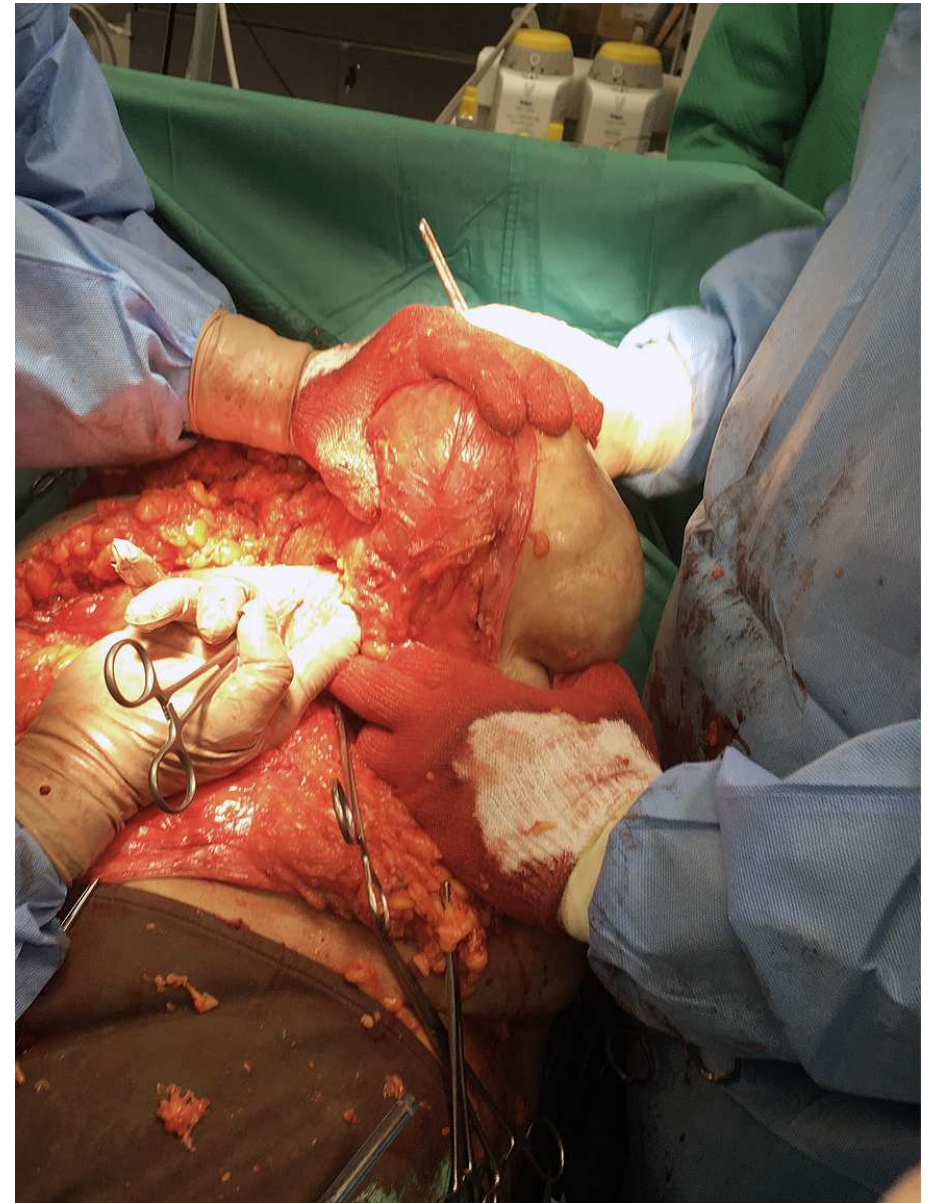

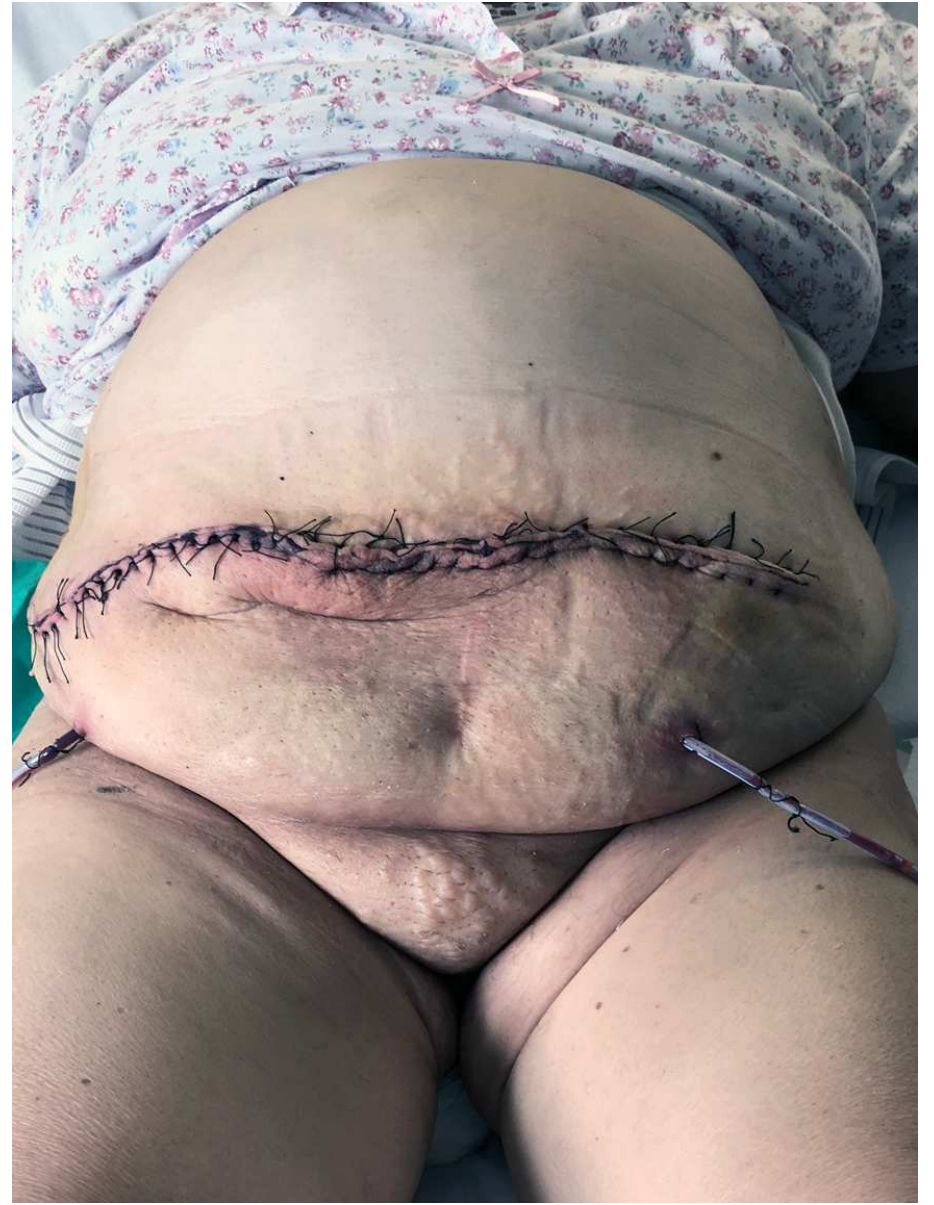
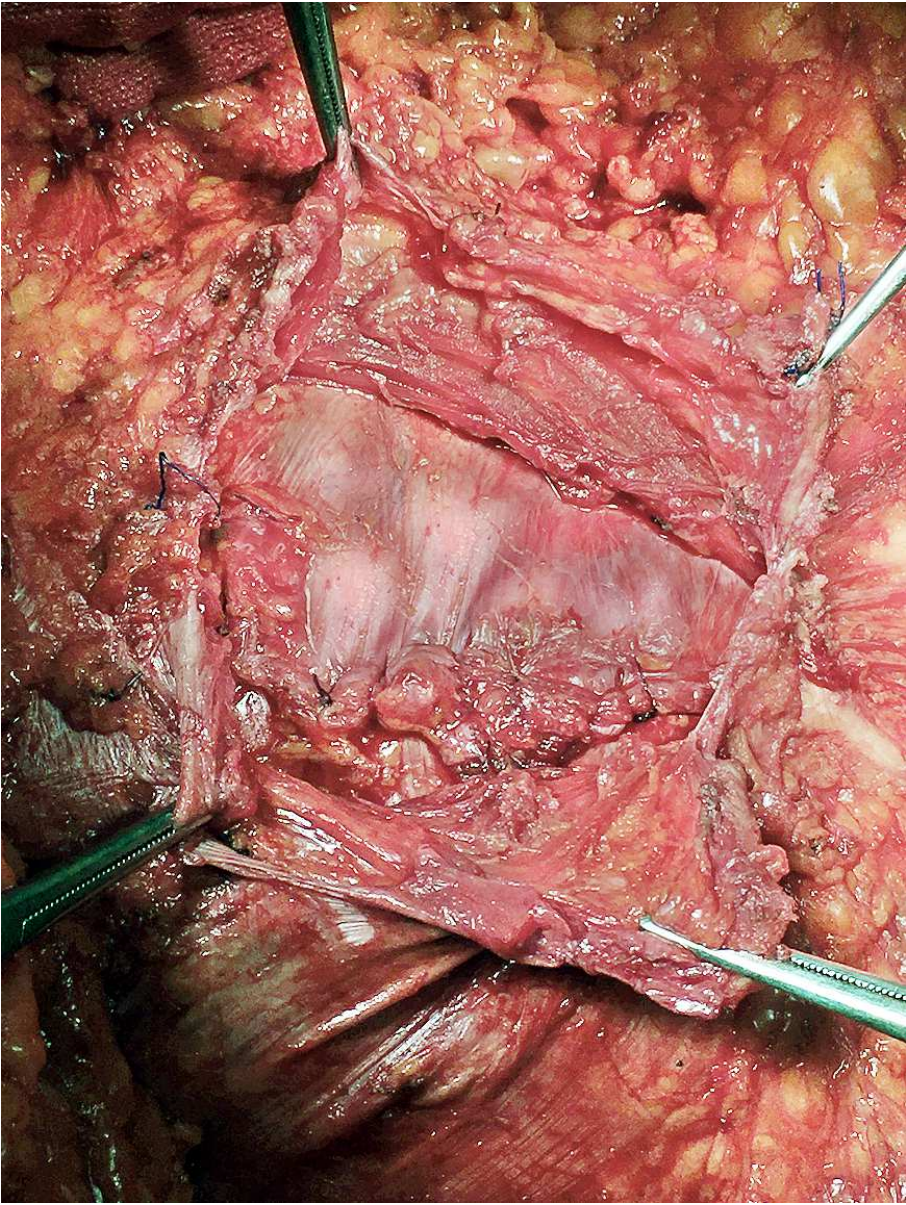


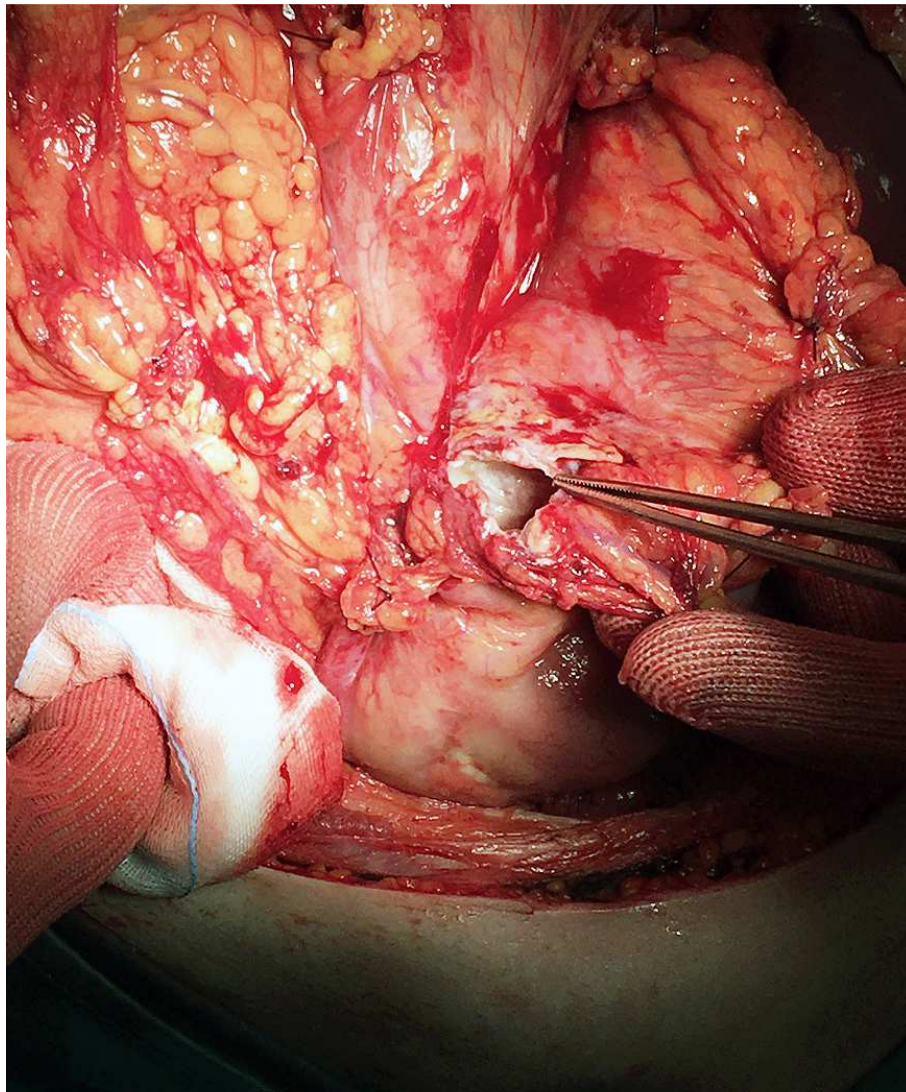


D.M.G. • Anni: 68 - F • Record: 7 • 29-11-2019

Laparoalloplastica per voluminosa ernia ombelicale pluriconcamerata recidiva strozzata

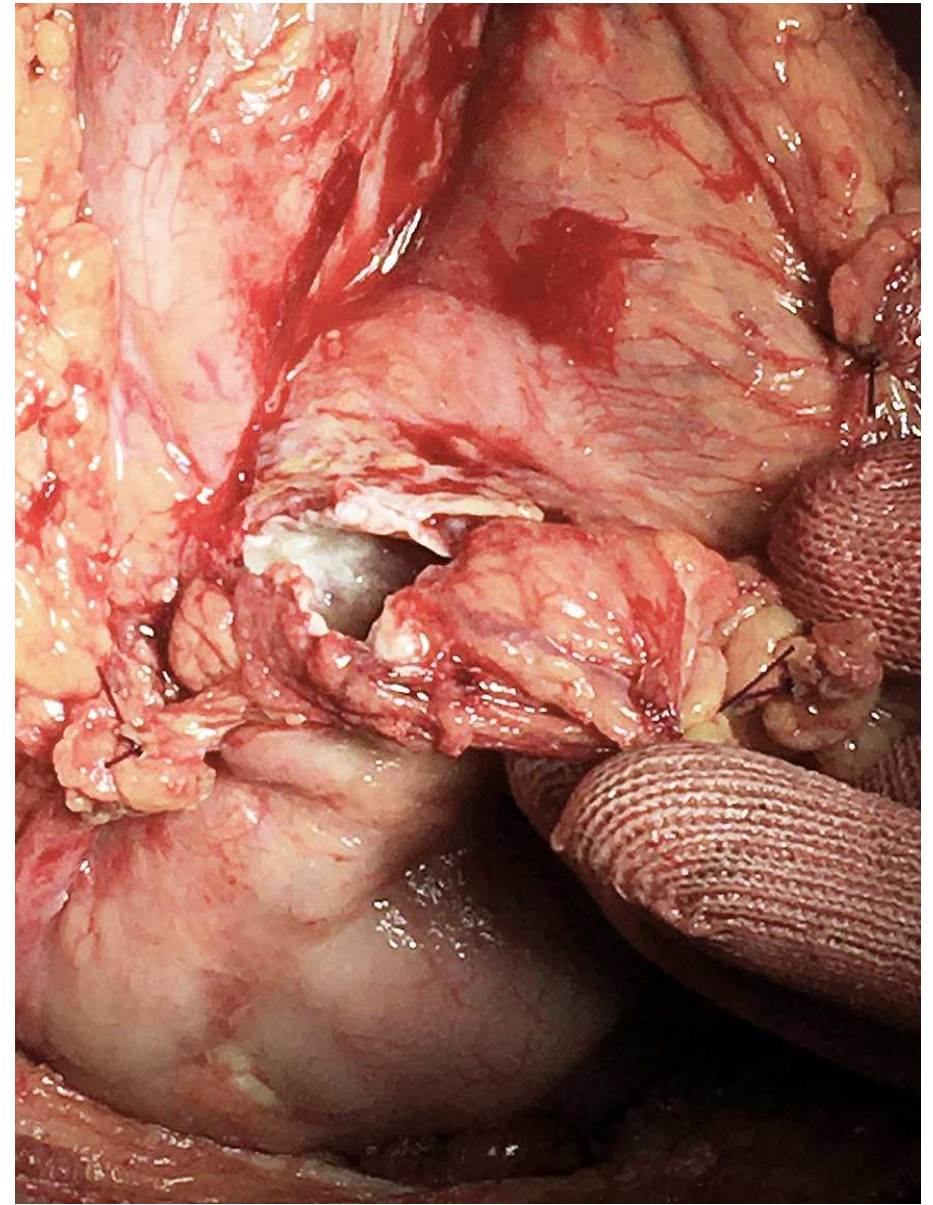




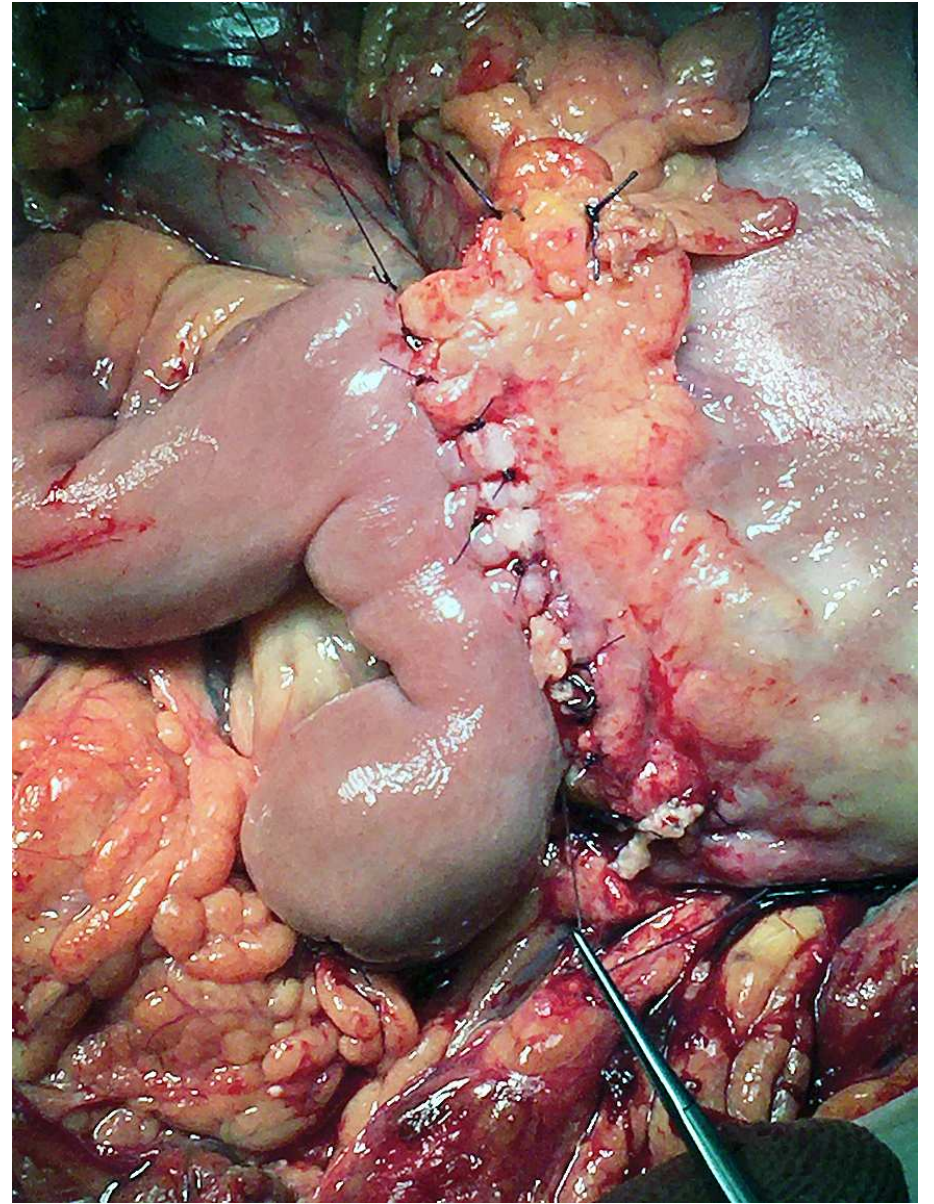
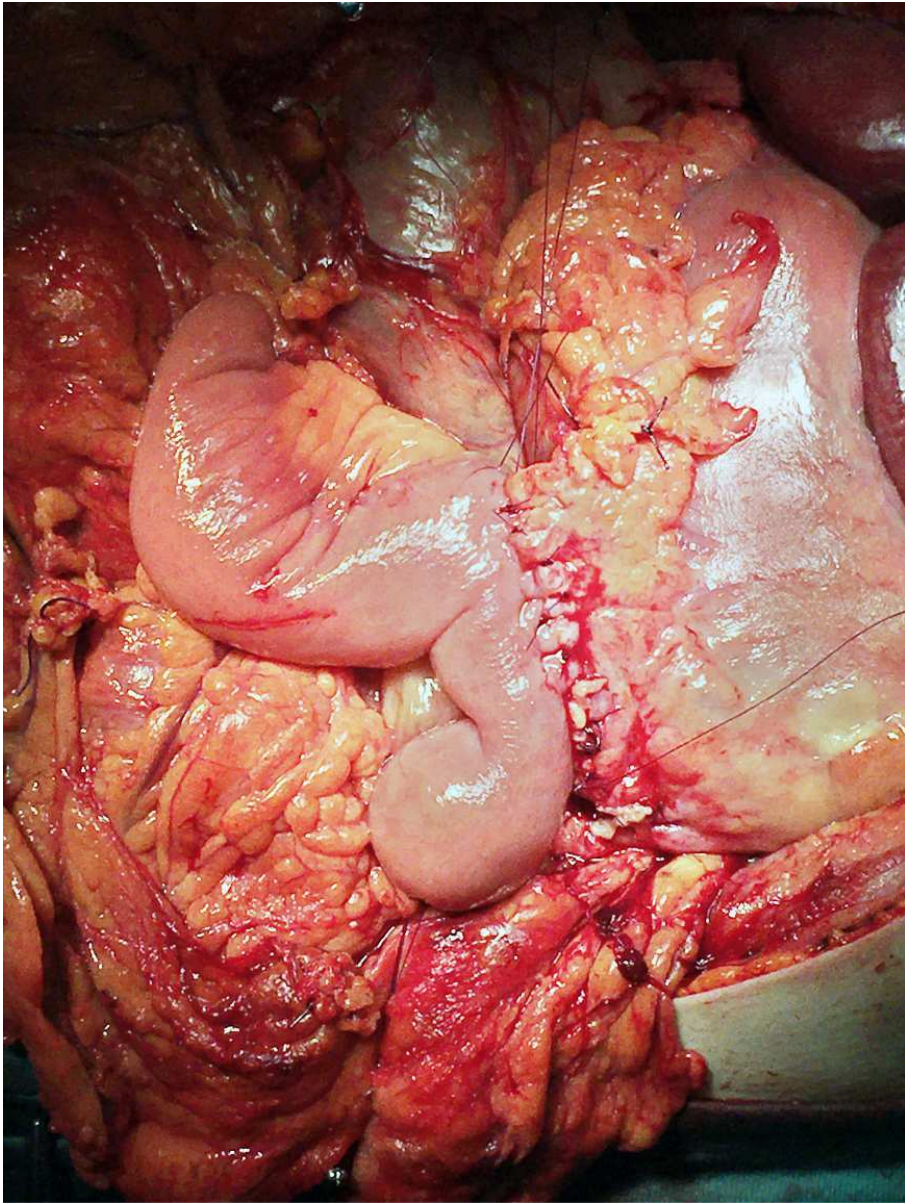


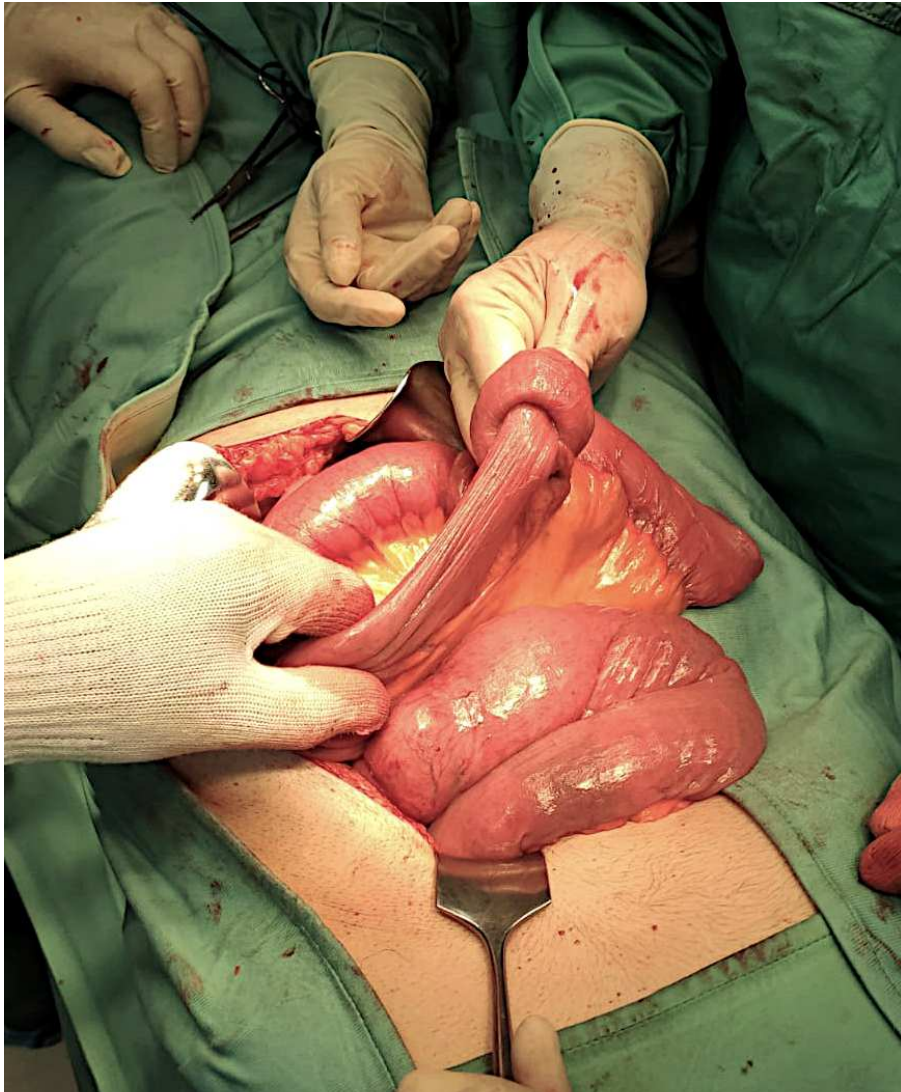
N.C. • Anni: 43 - M • Record: 8 • 30-11-2019

Cisto-digiunostomia per peritonite diffusa da rottura di pseudocisti pancreatica



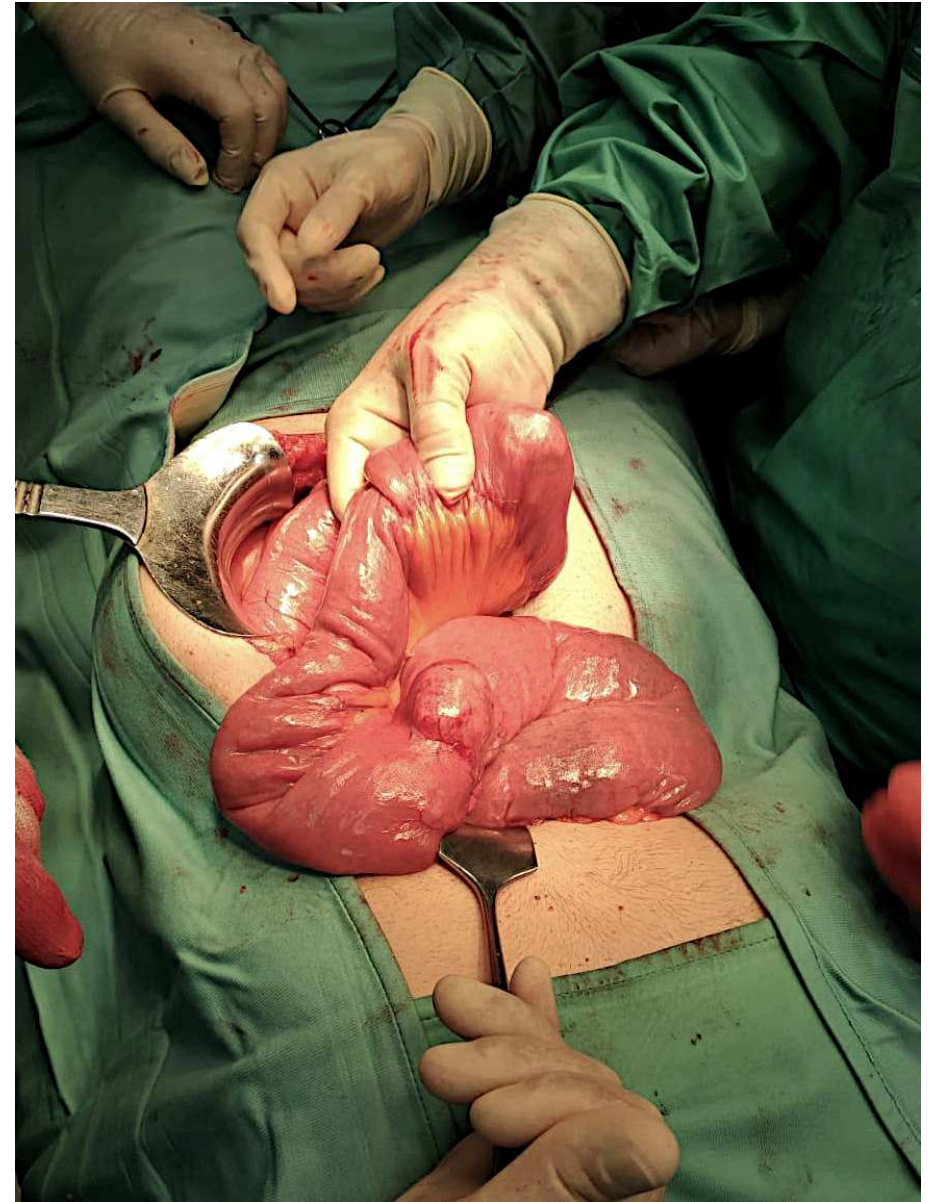


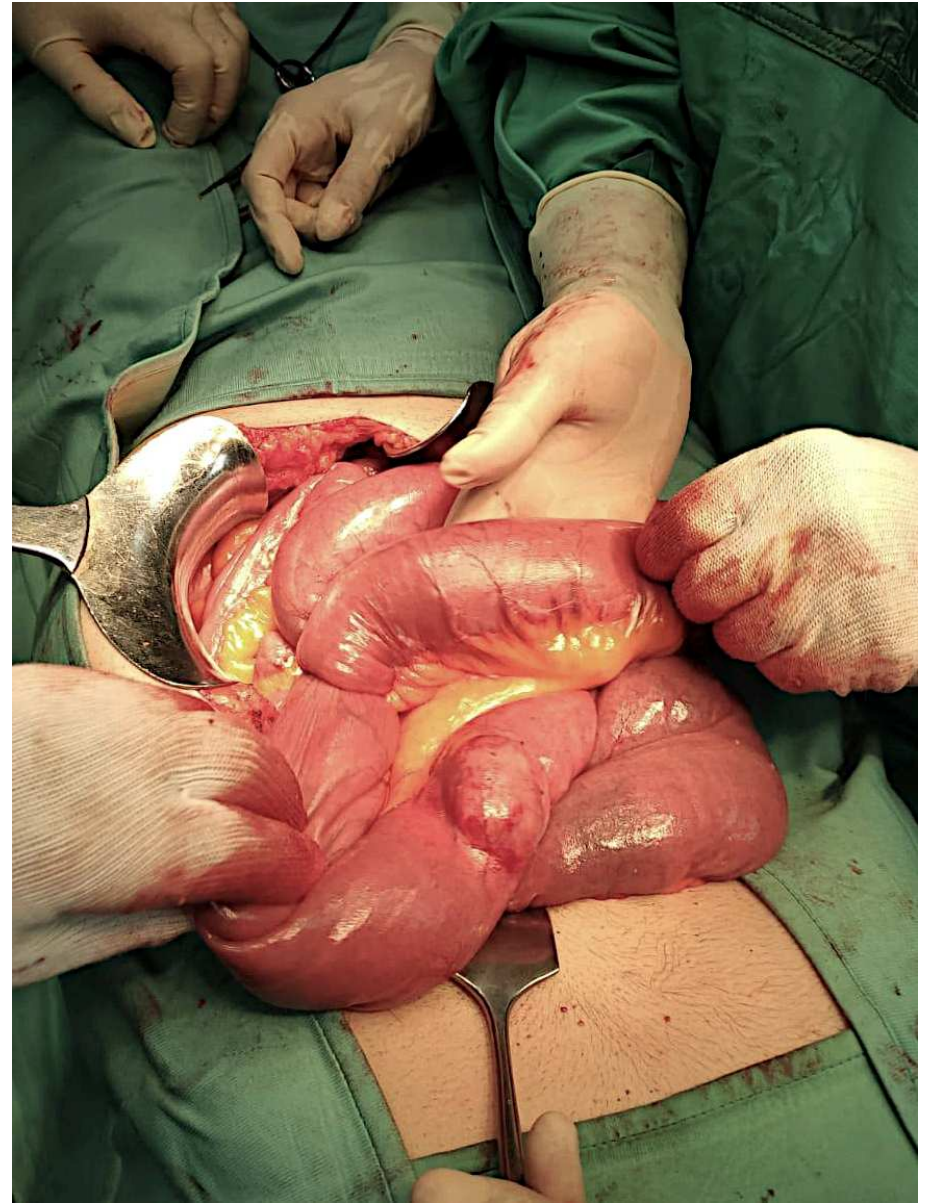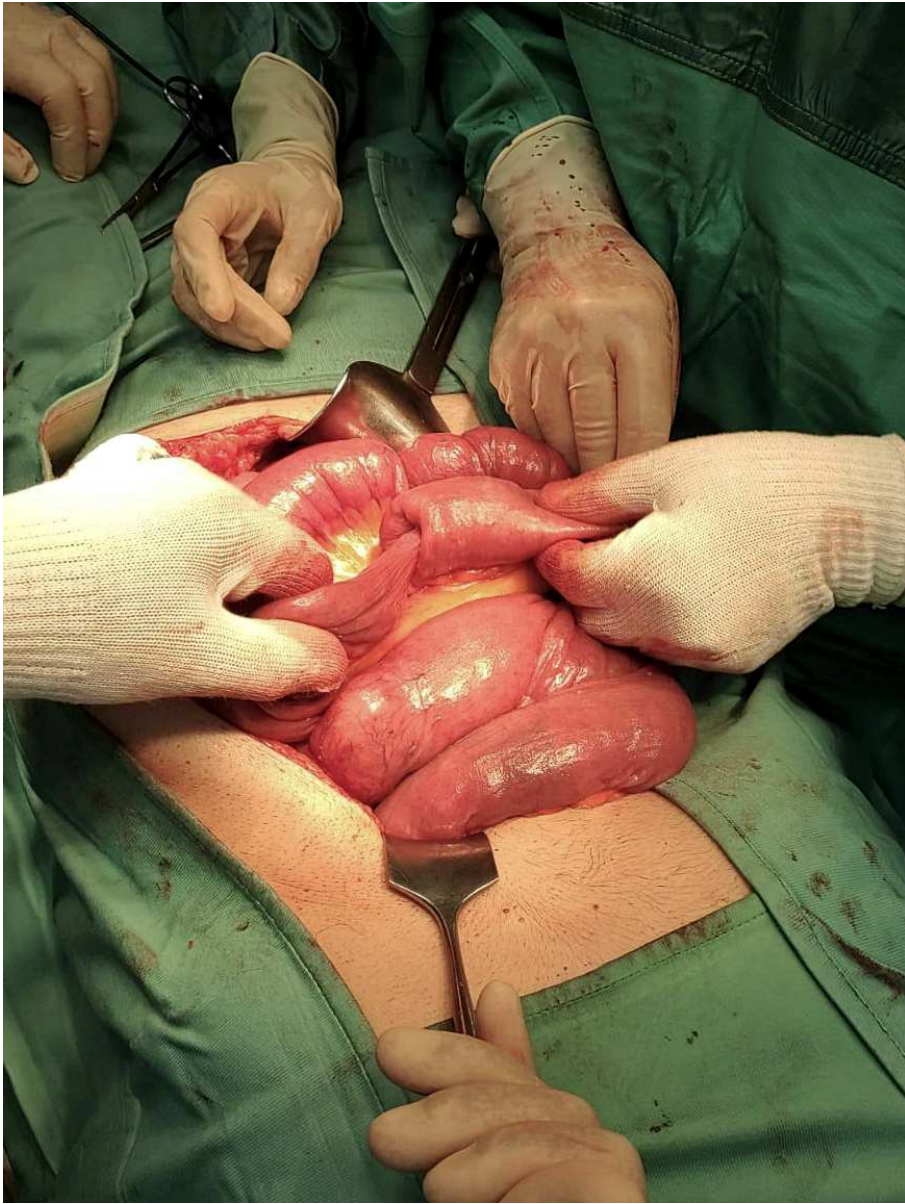


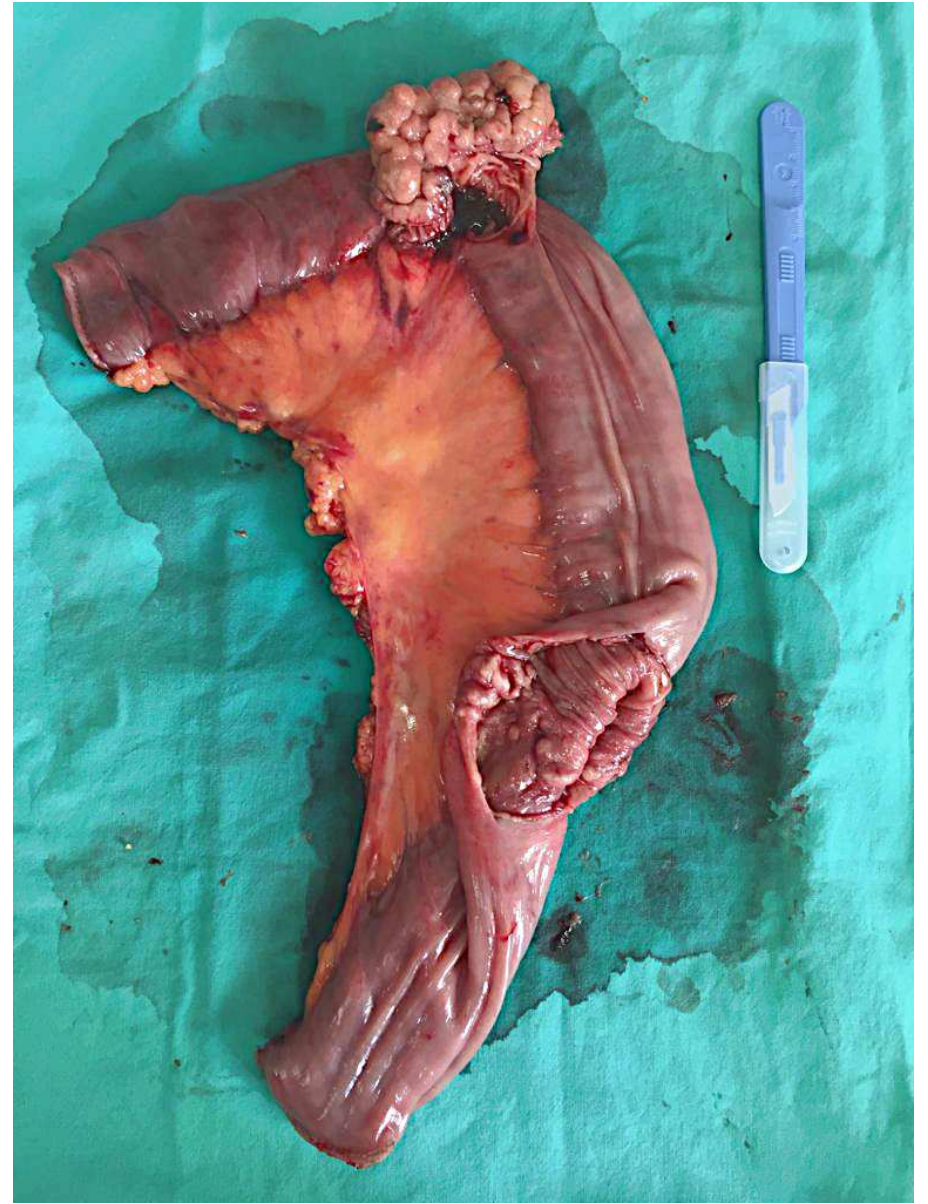
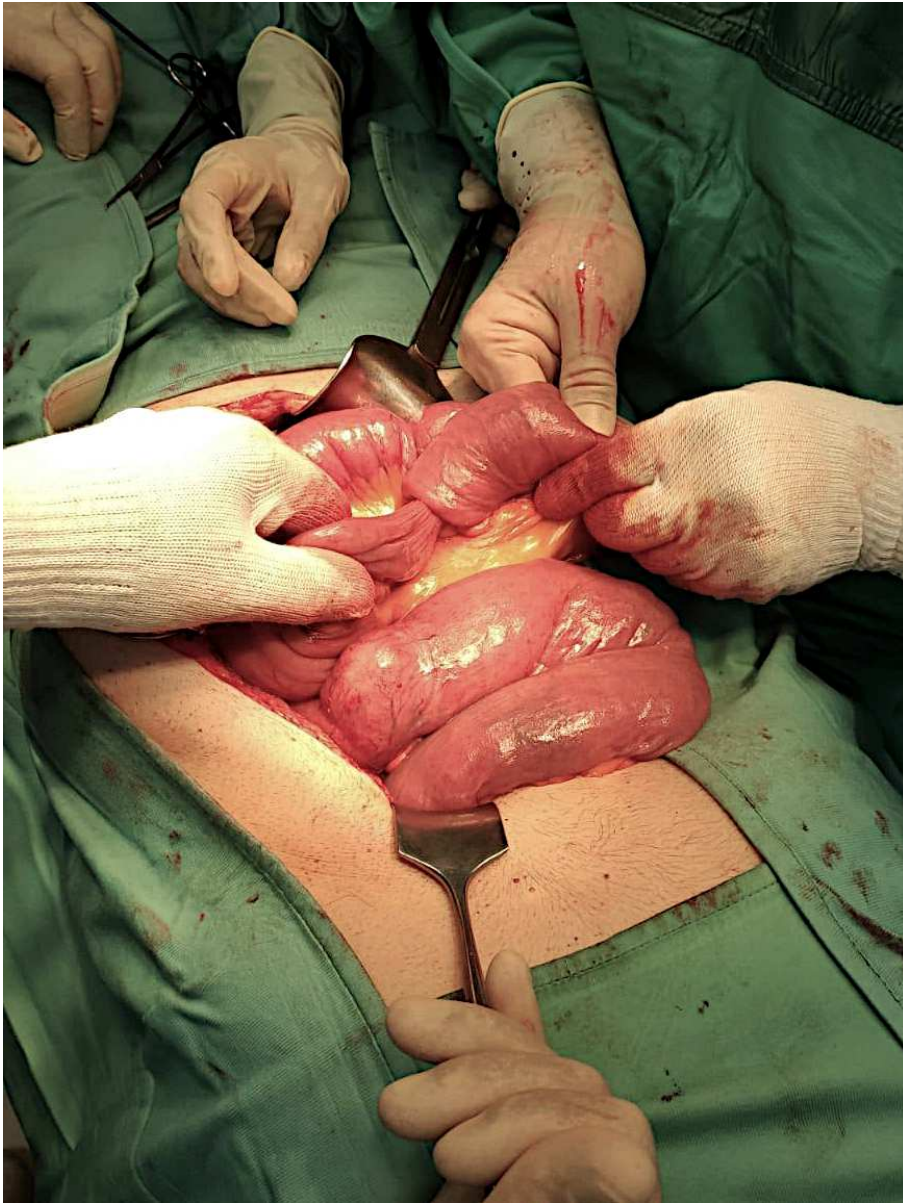


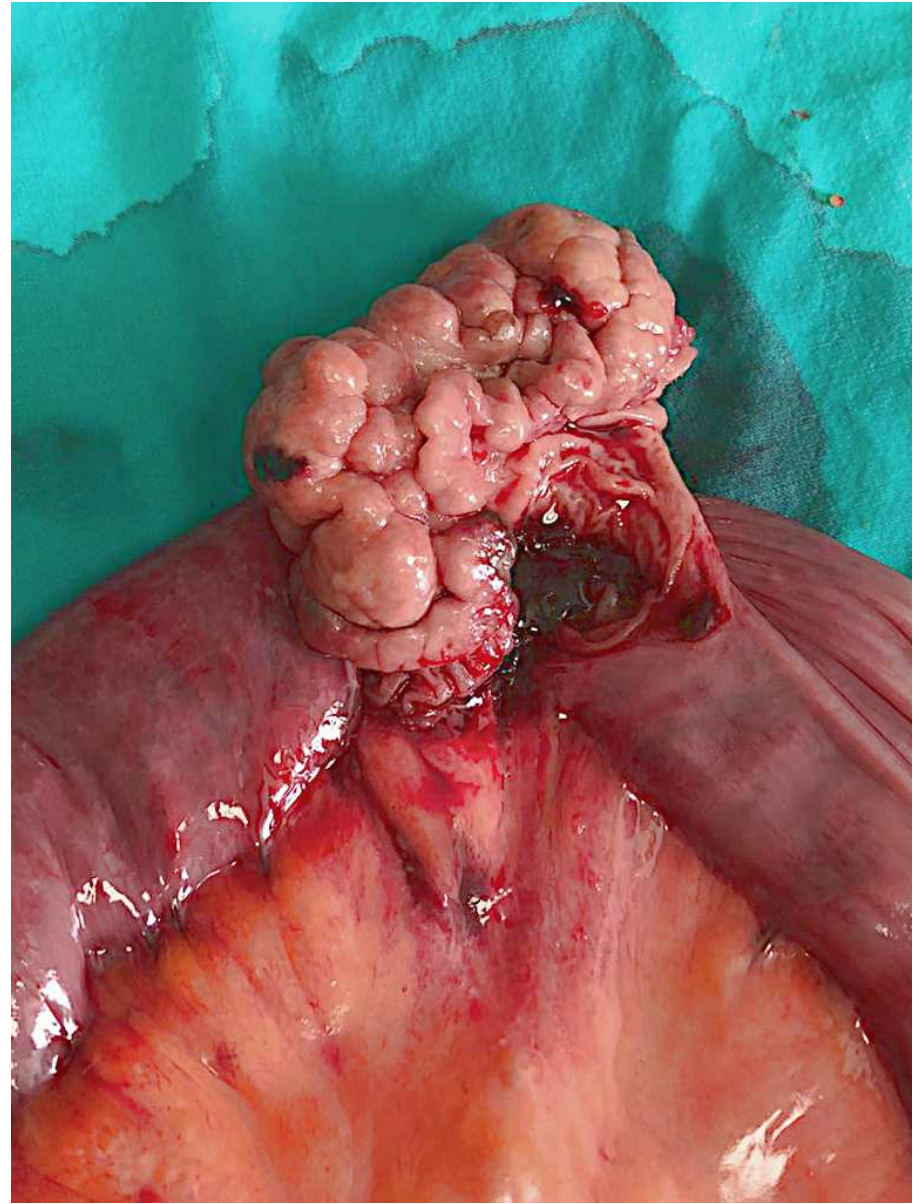
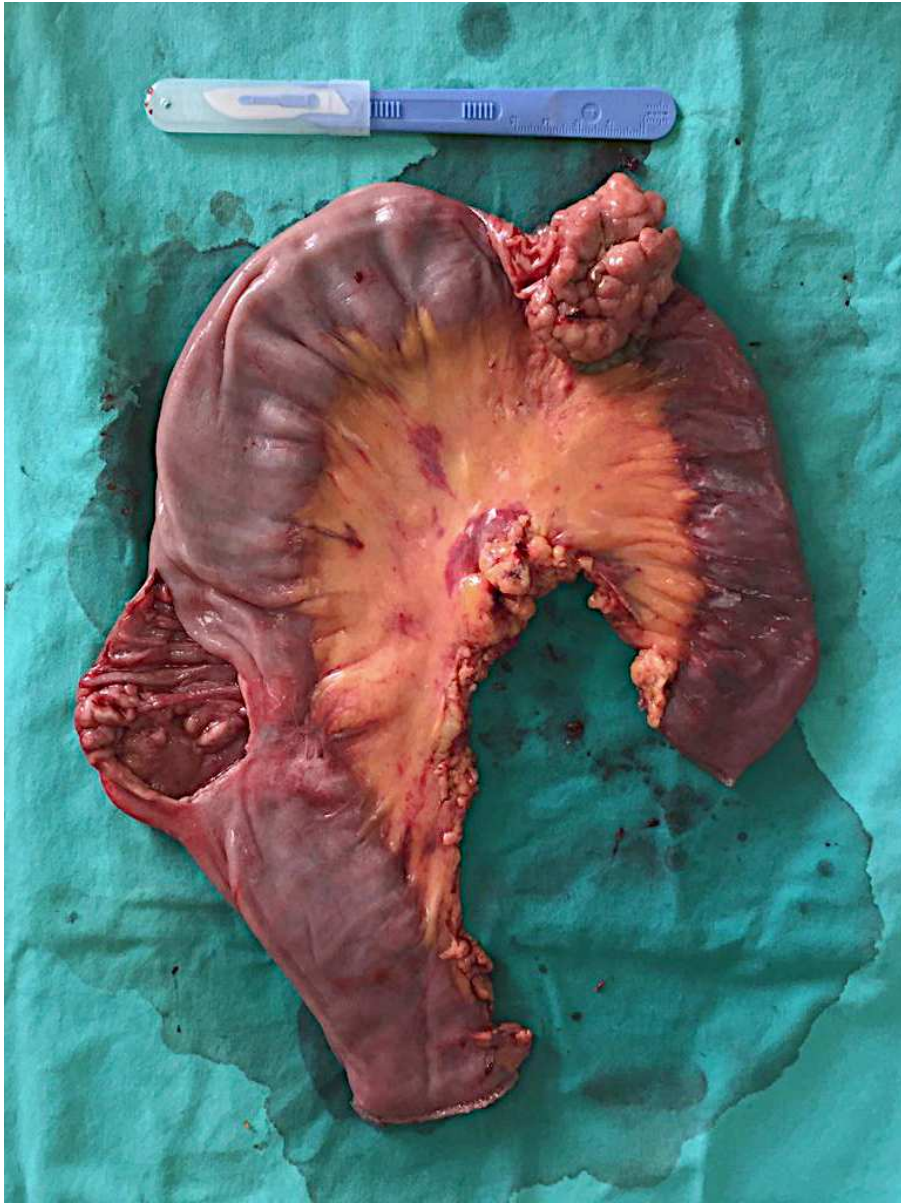V.D. • Anni: 57 - M • Record: 9 • 03-07-2020

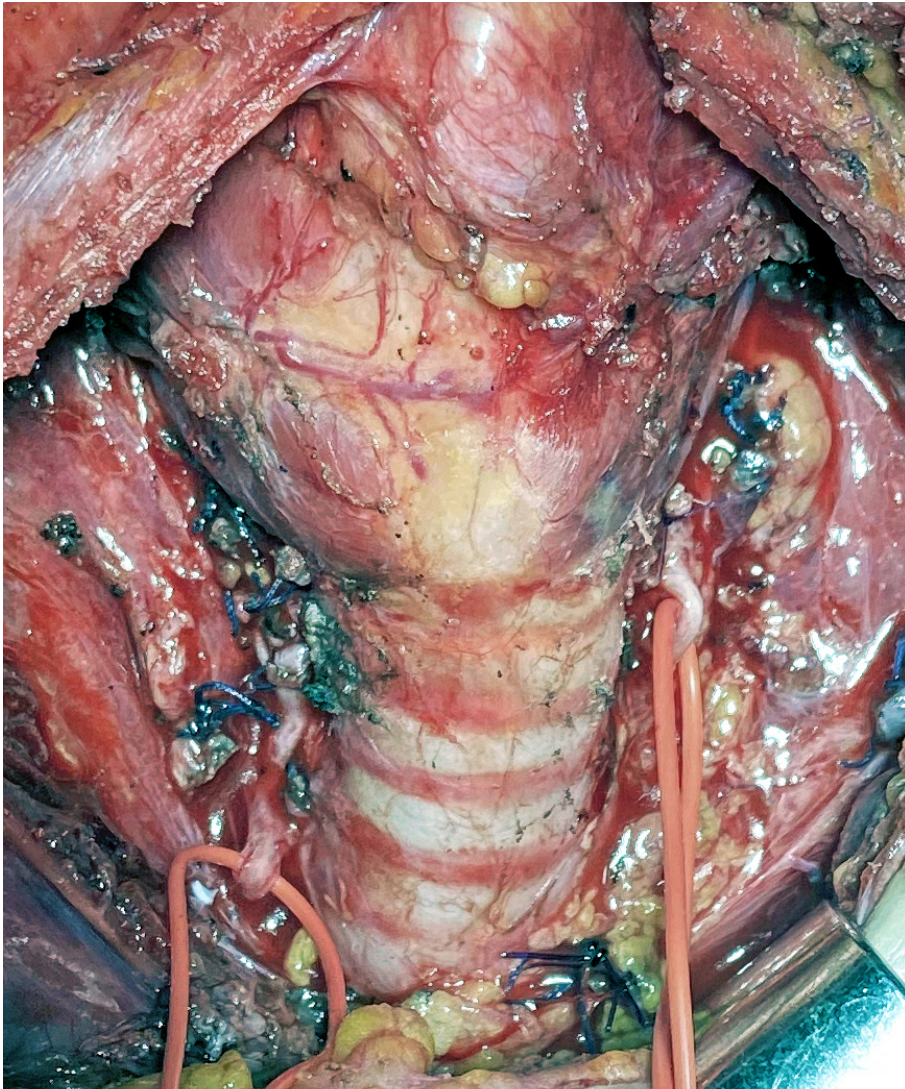
Resezione ileale con ileo-ileostomia L-L isoperistaltica in duplice strato per occlusione intestinale da intussuscezione ileale su duplice area pseudopolipoide da linfoma non Hodgkin, a cellule T periferiche, intestinale





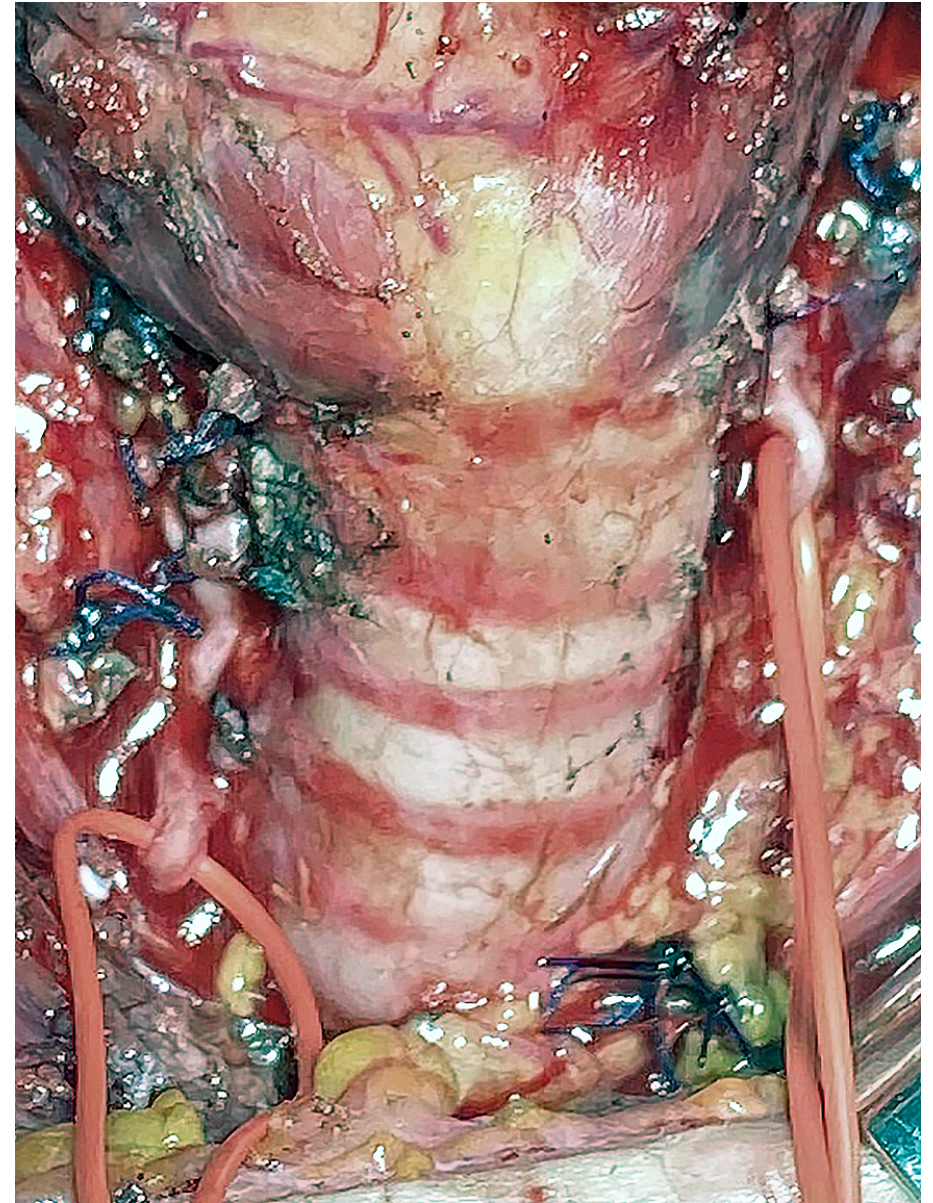



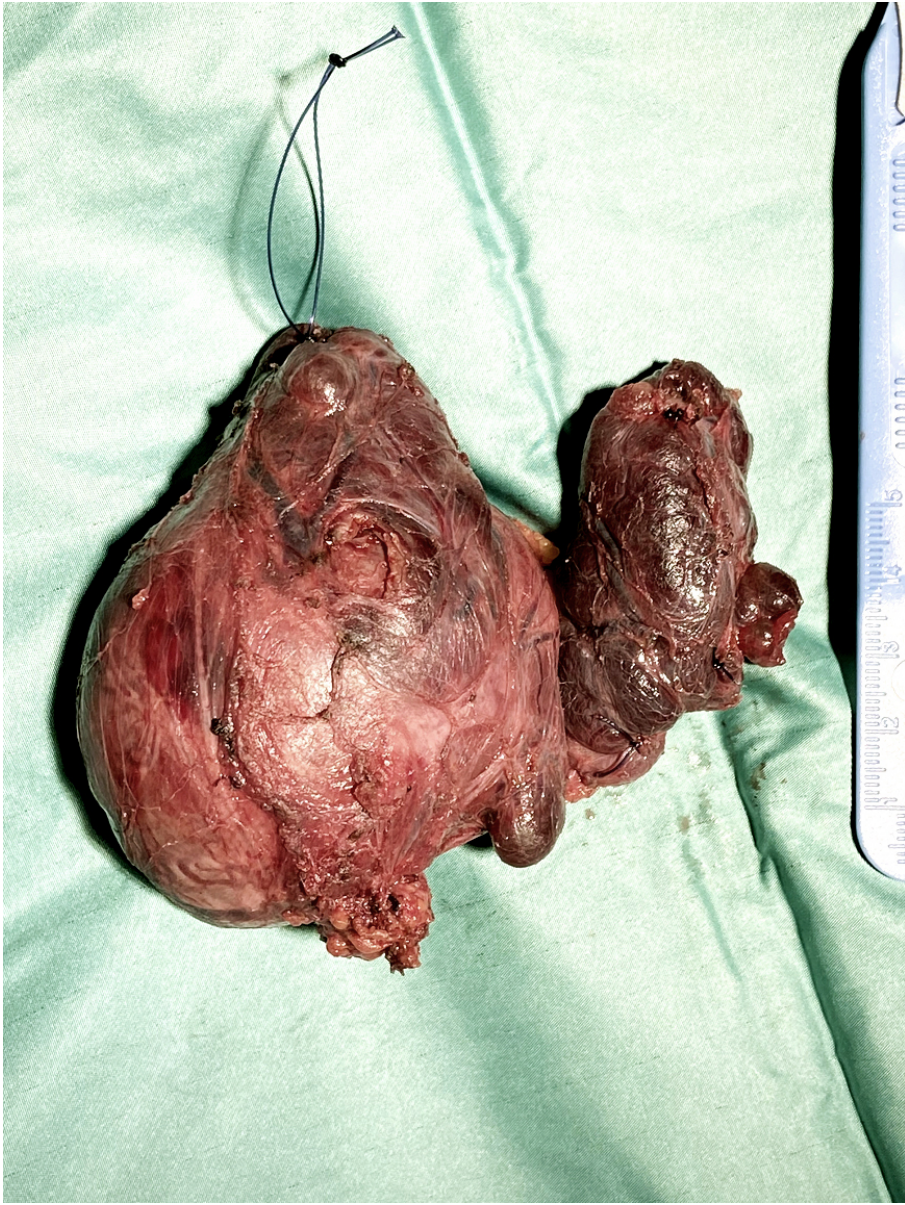


D.F.G. • Anni: 46 - M • Record 1 • 18-03-2021

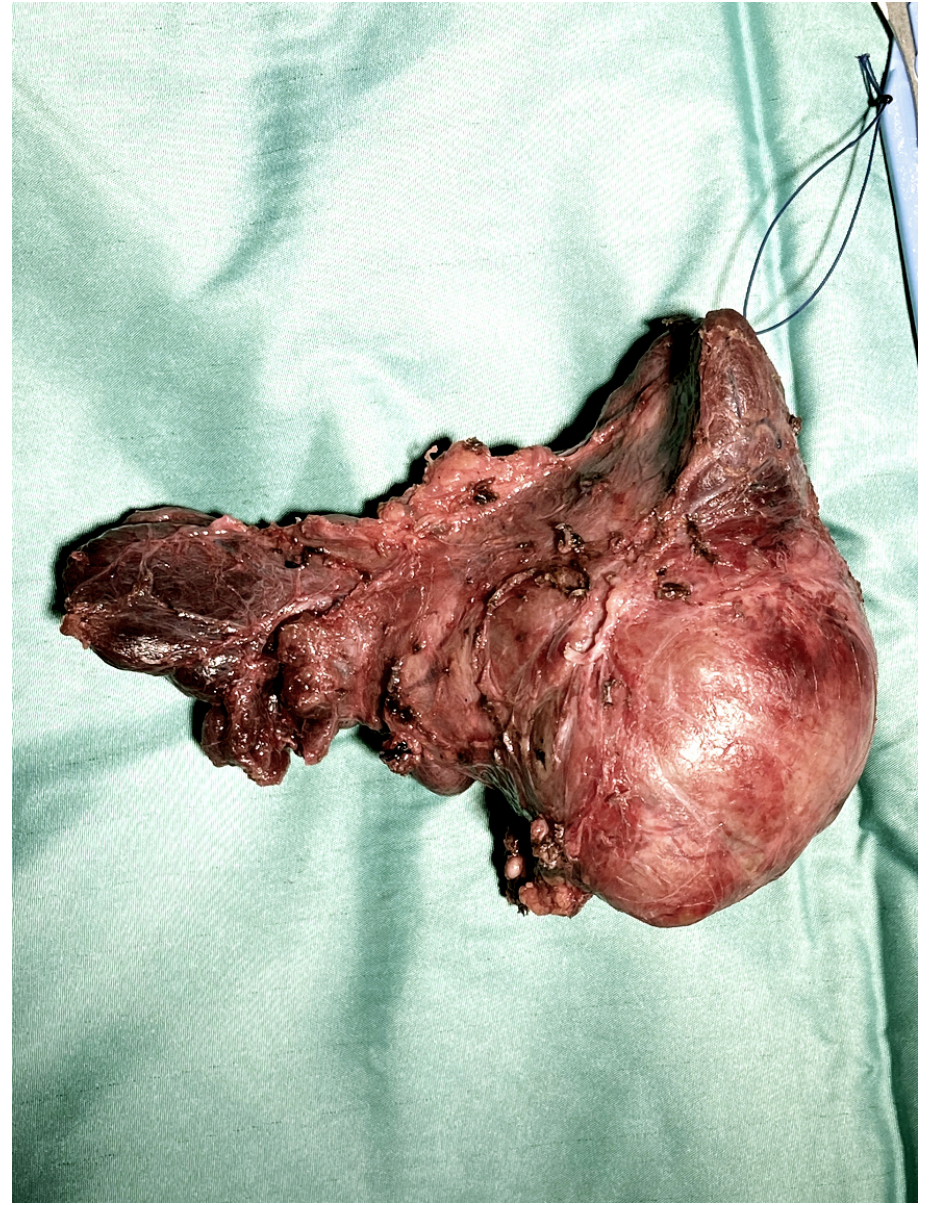Tiroidectomia totale extracapsulare per adenoma oncocitario a cellule di Hürtle del lobo dx plongeant in gozzo plurinodulare pretossico



Isolamento dei nervi laringei inferiori (ricorrenti)



Lobo destro - Istmio - Lobo sinistro (superficie anteriore)



Lobo sinistro - Istmio - Lobo destro (superficie posteriore)